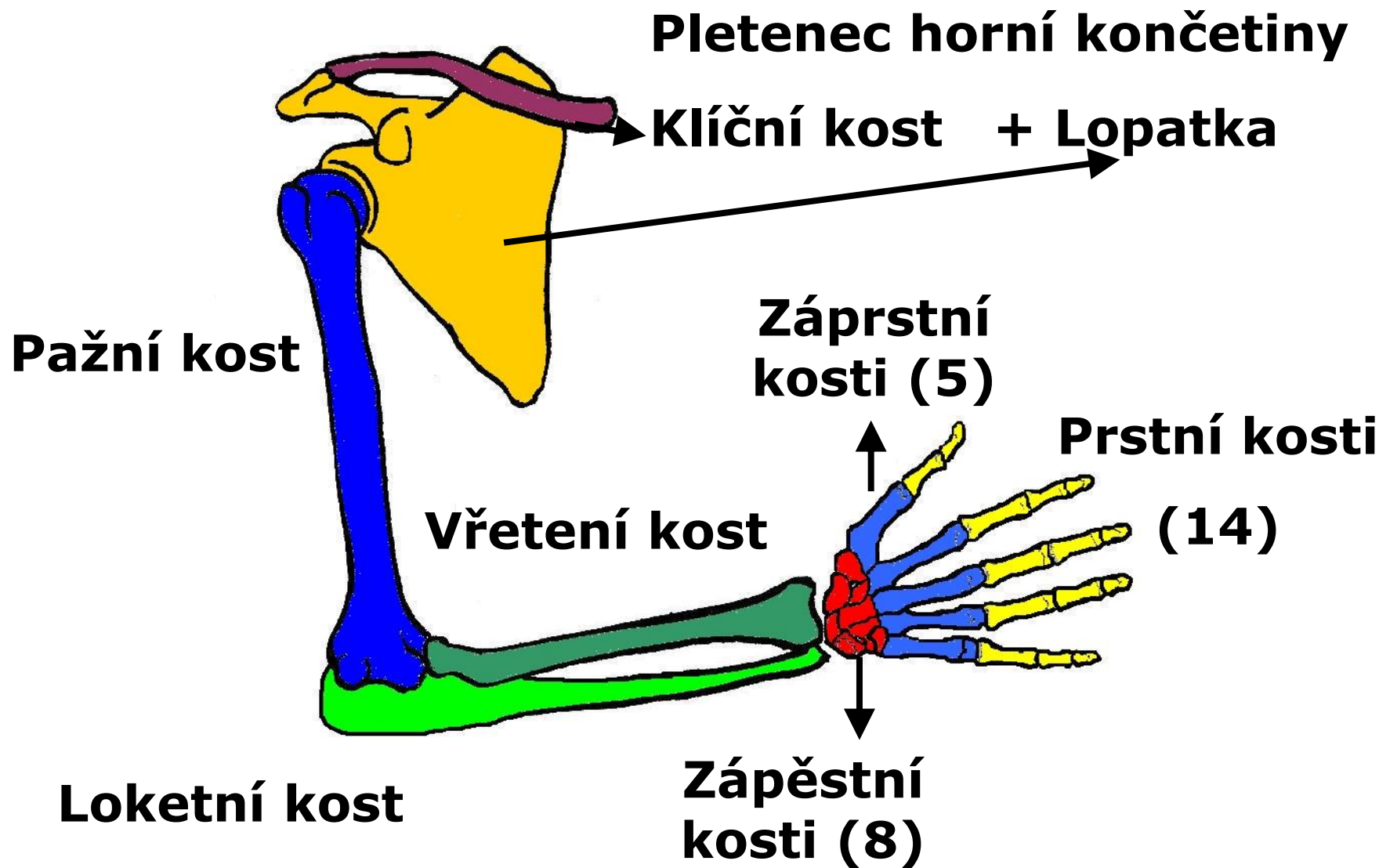


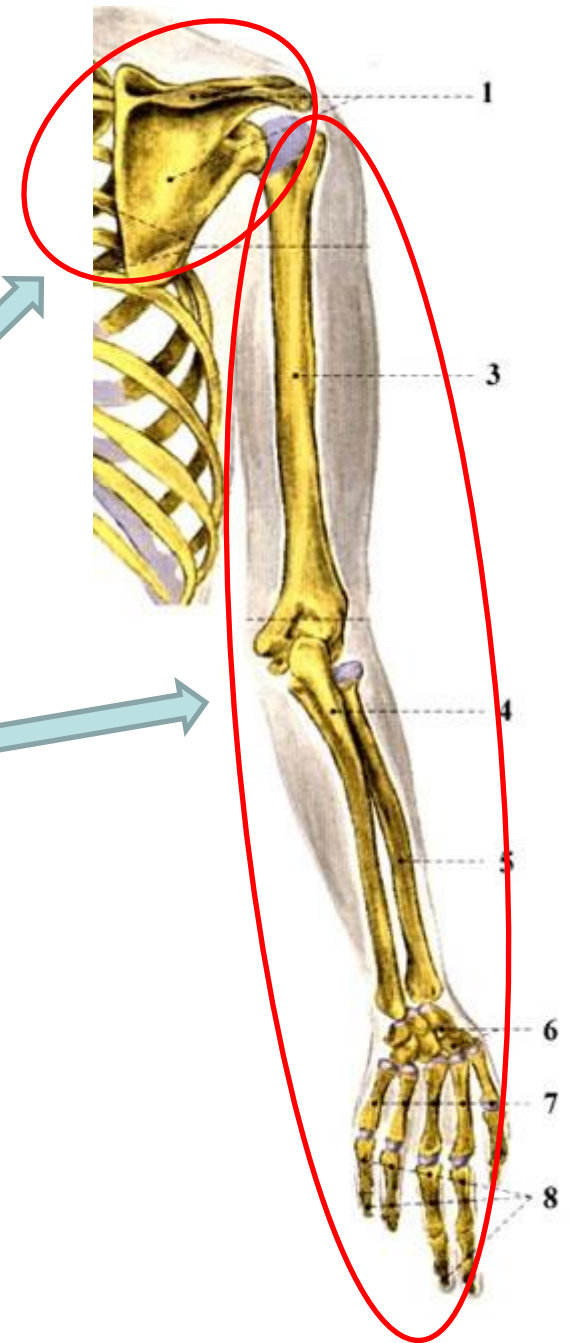
Kostra horní končetiny

KOSTRA HORNÍ KONČETINY



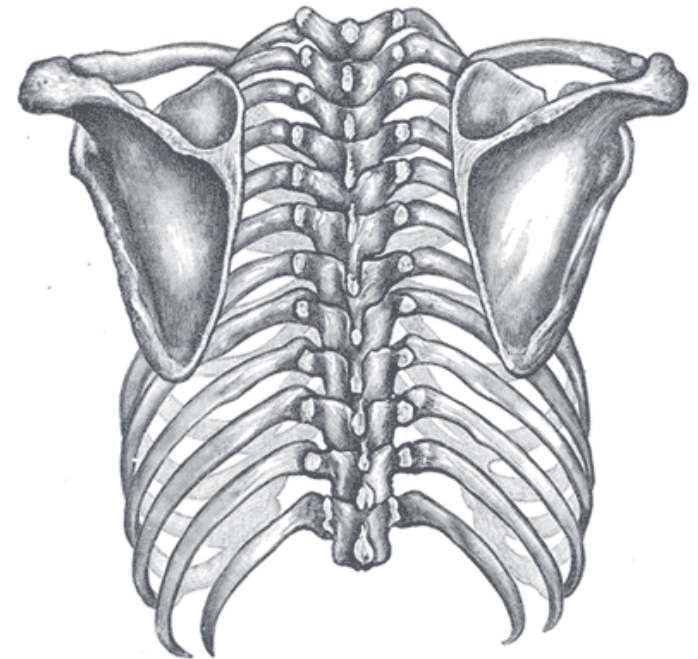
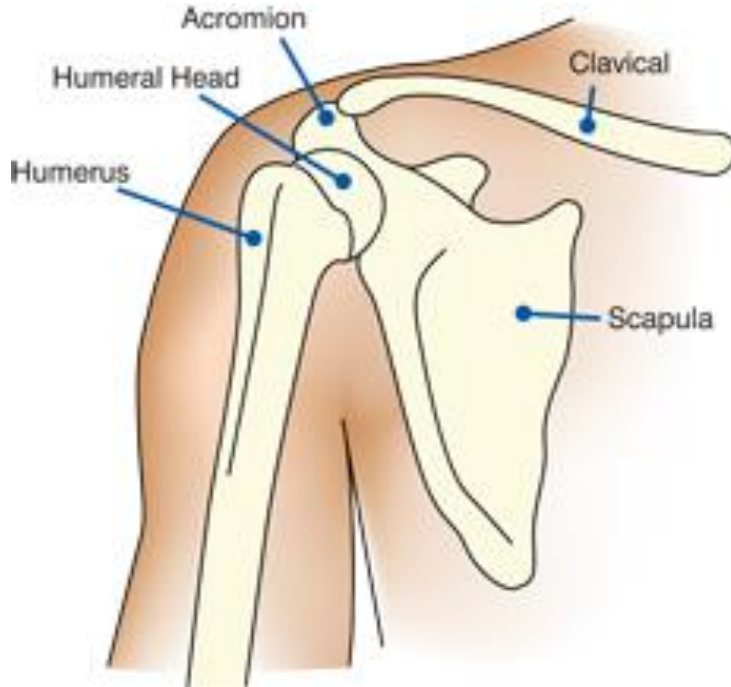
Ossa membri superioris

- pletenec horní končetiny
 - *Cingulum membri superioris*
- volná horní končetina
 - *Pars libera membri superioris*



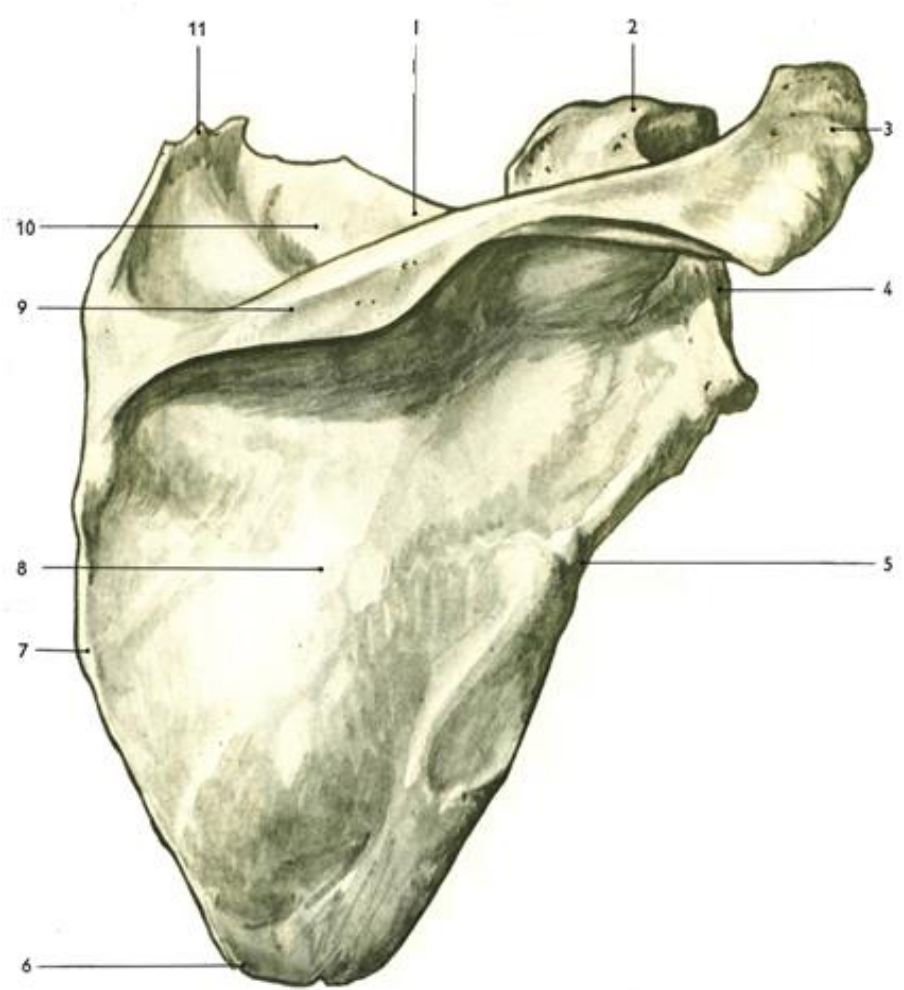
Lopatka - scapula

- Okraj-**margo**: lateralis, medialis, superior
- Úhel-**angulus**: superior, lateralis, inferior
- Plocha-**facies**: dorsalis, costalis



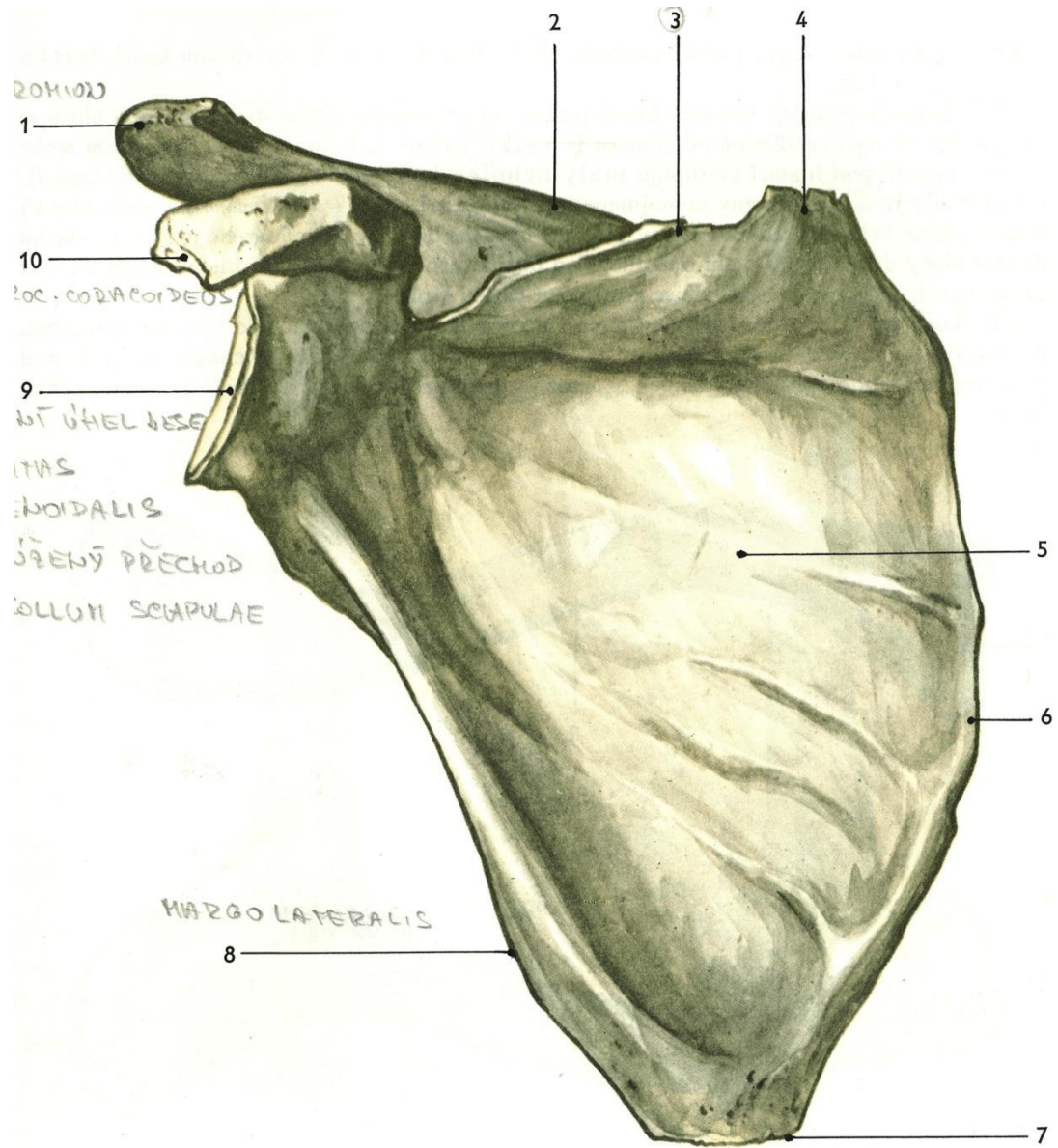
Scapula

- ***Facies dorsalis***
- přední plocha - naléhá na 2. - 7. žebro
- spina scapulae, acromion
- fossa supraspinata a infraspinata
- cavitas glenoidalis
- processus coracoideus



Scapula (dx.)

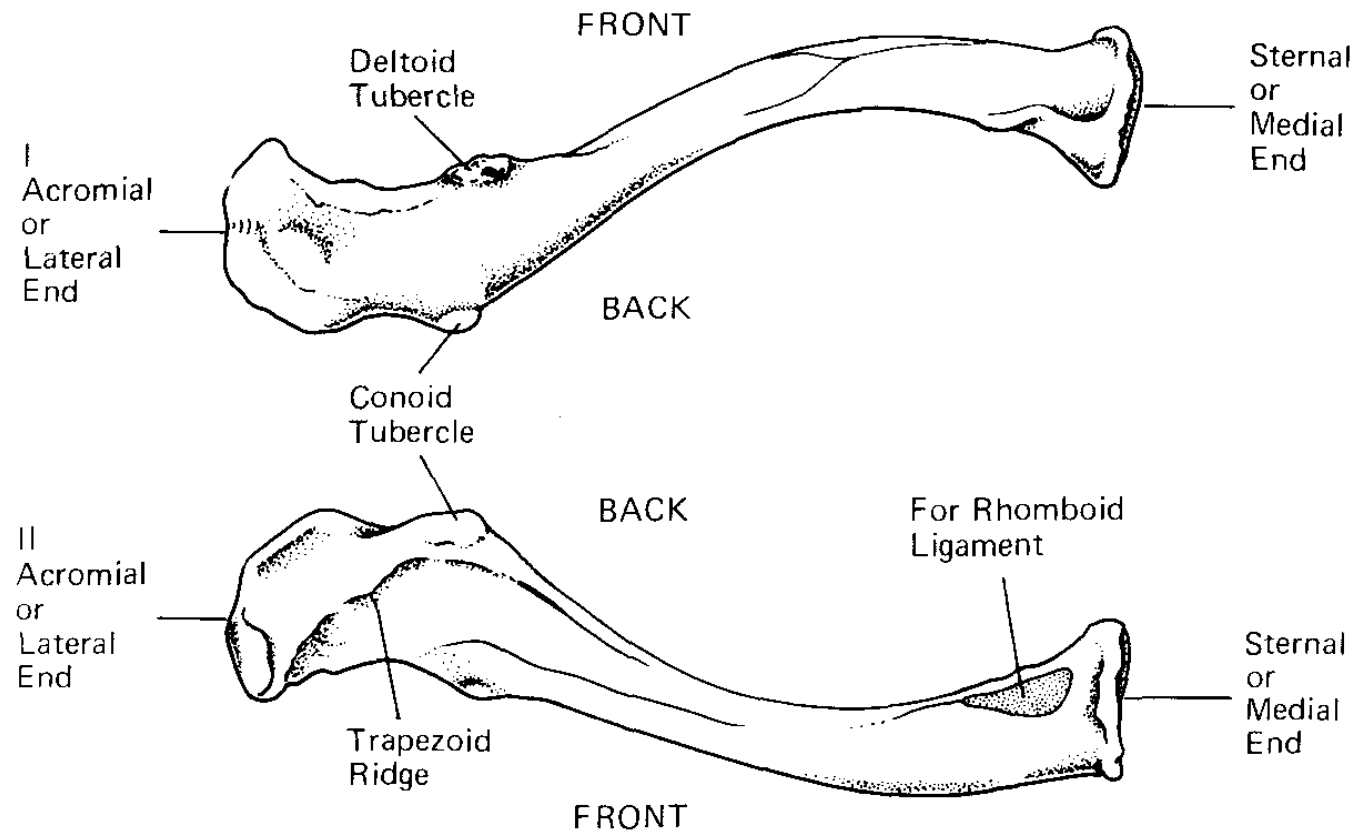
- *Facies costalis*
- Lineae musculares
- Collum scapulae



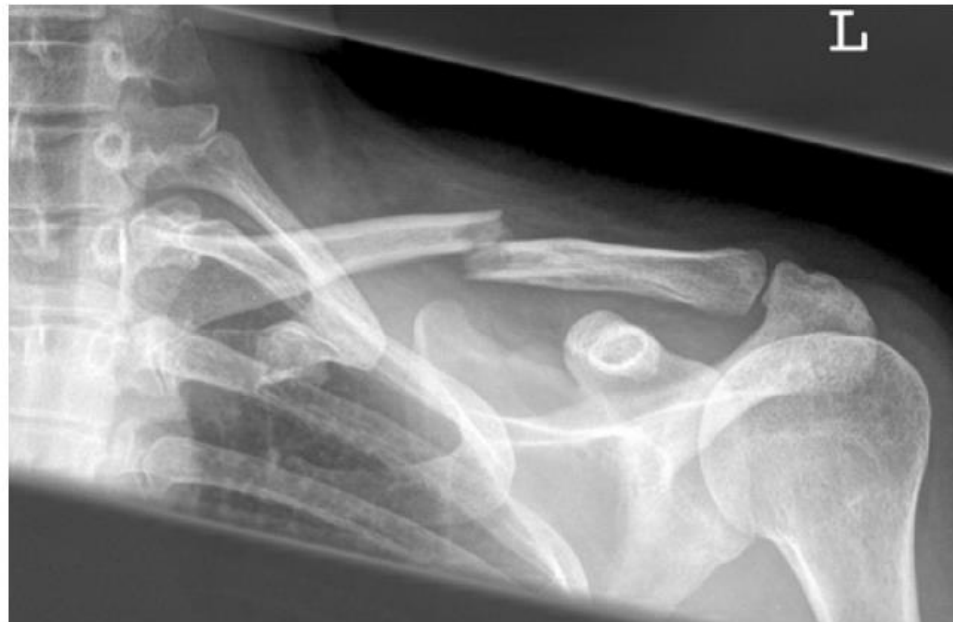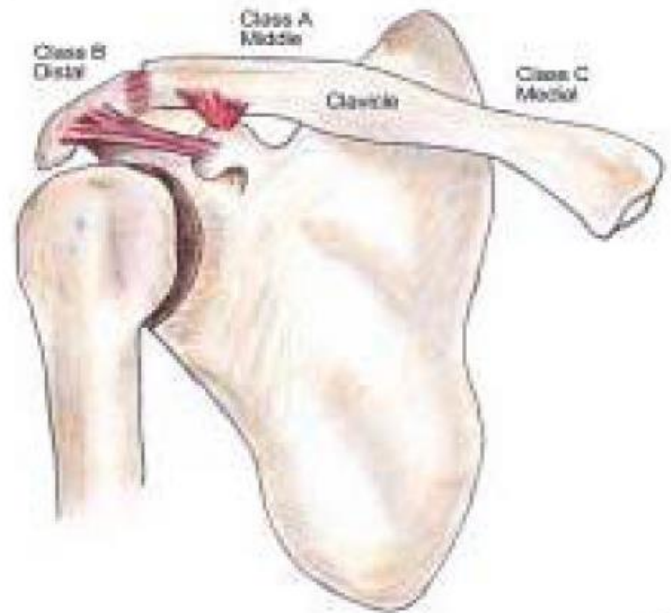
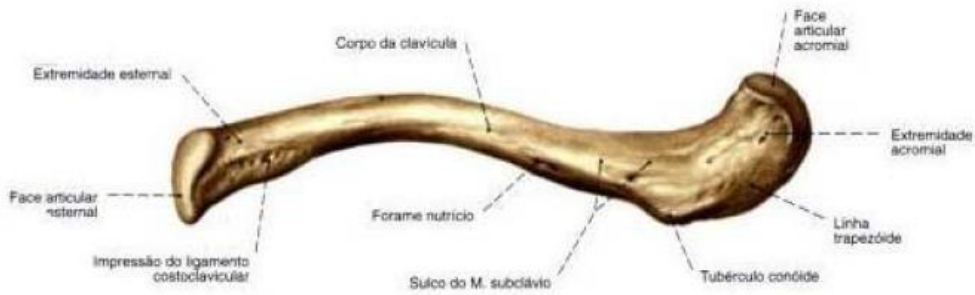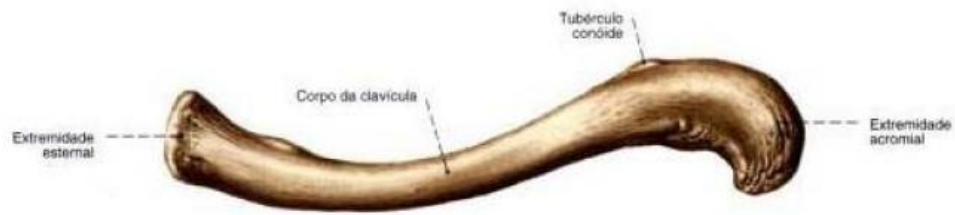
120. Lopatka pravá, zředu (*FACIES COSTALIS*) ?
 1 - nadpažek, 2 - hřeben lopatky, 3 - horní okraj lopatky, 4 - horní úhel lopatky, 5 - přední žeburní plocha lopatky, 6 - vnitřní okraj lopatky, 7 - dolní úhel lopatky, 8 - zevní okraj lopatky, 9 - jamka kloubu ramenního, 10 - výběžek hákovitý

- 12-16cm
- Extremitas sternalis
- Extremitas acromialis

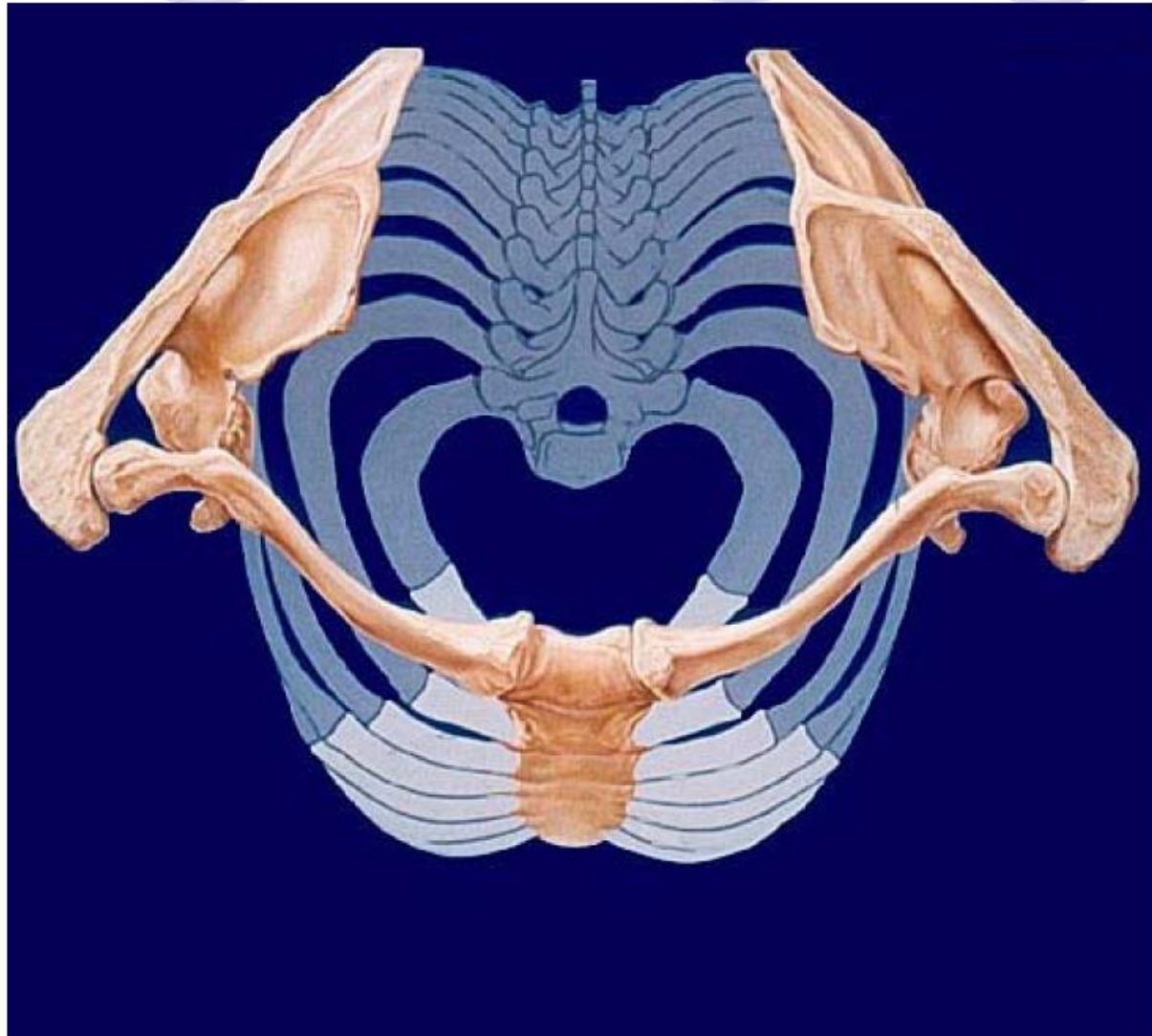
Clavicula



Left clavicle from above (*top*) and from below.

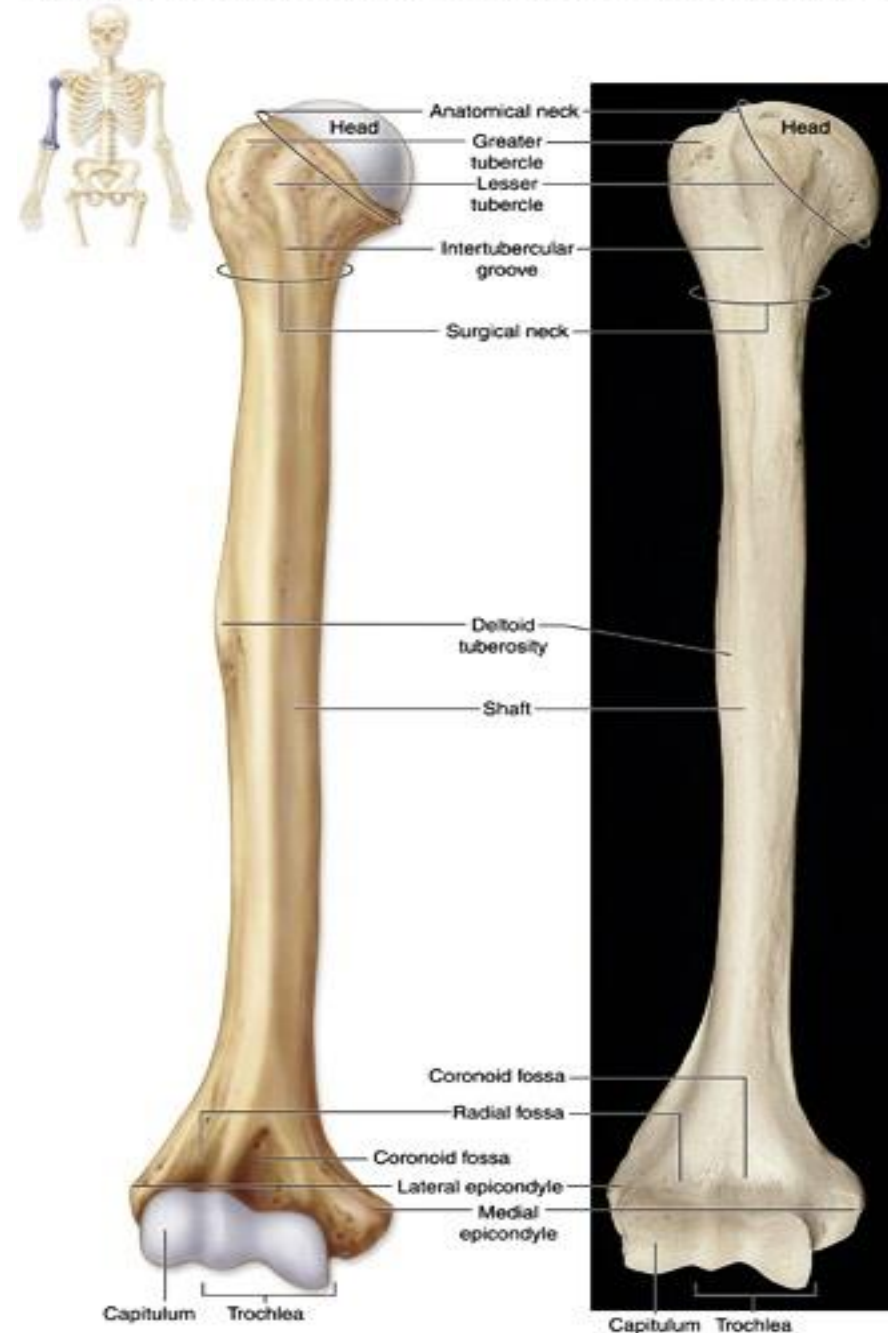


Pletenec HK – horní pohled



Humerus

- Caput humeri
- Collum anatomicum
- Collum chirurgicum
- Tuberculum majus, minus
- Tuberositas deltoidea
- Corpus
- Epicondylus medialis, lateralis

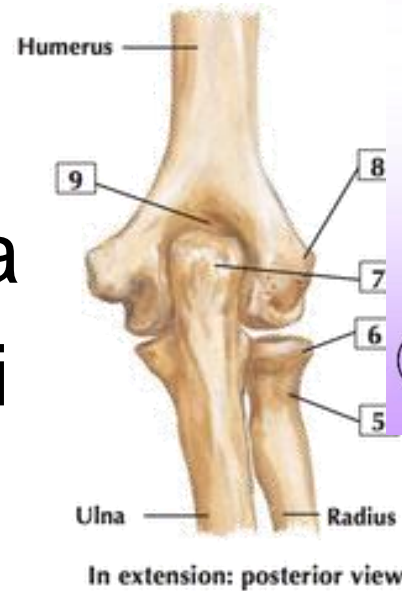


(a) Right humerus, anterior view

Humerus - distální č

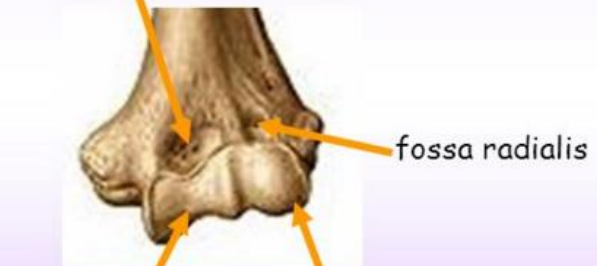- Trochlea humeri
- Fossa coronoidea
- Capitulum humeri
- Fossa radialis

- Fossa olecrani



HUMERUS - epiphysis distalis

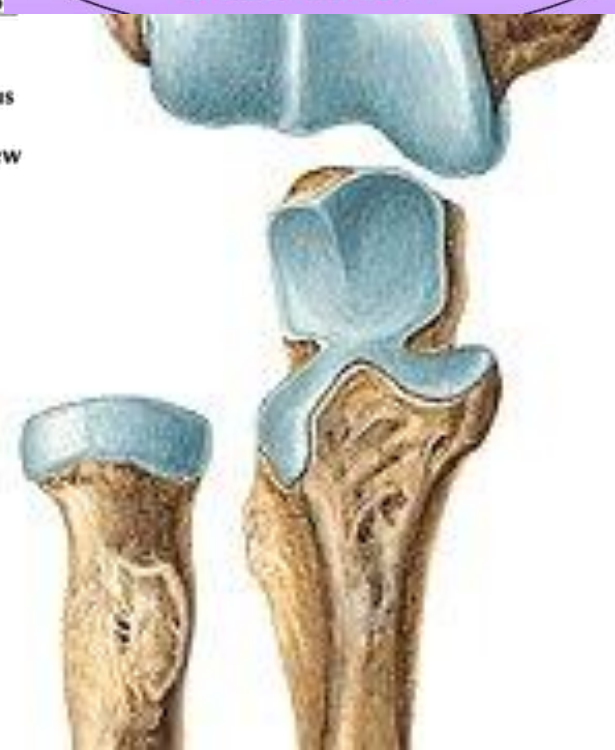
fossa coronoidea



trochlea humeri

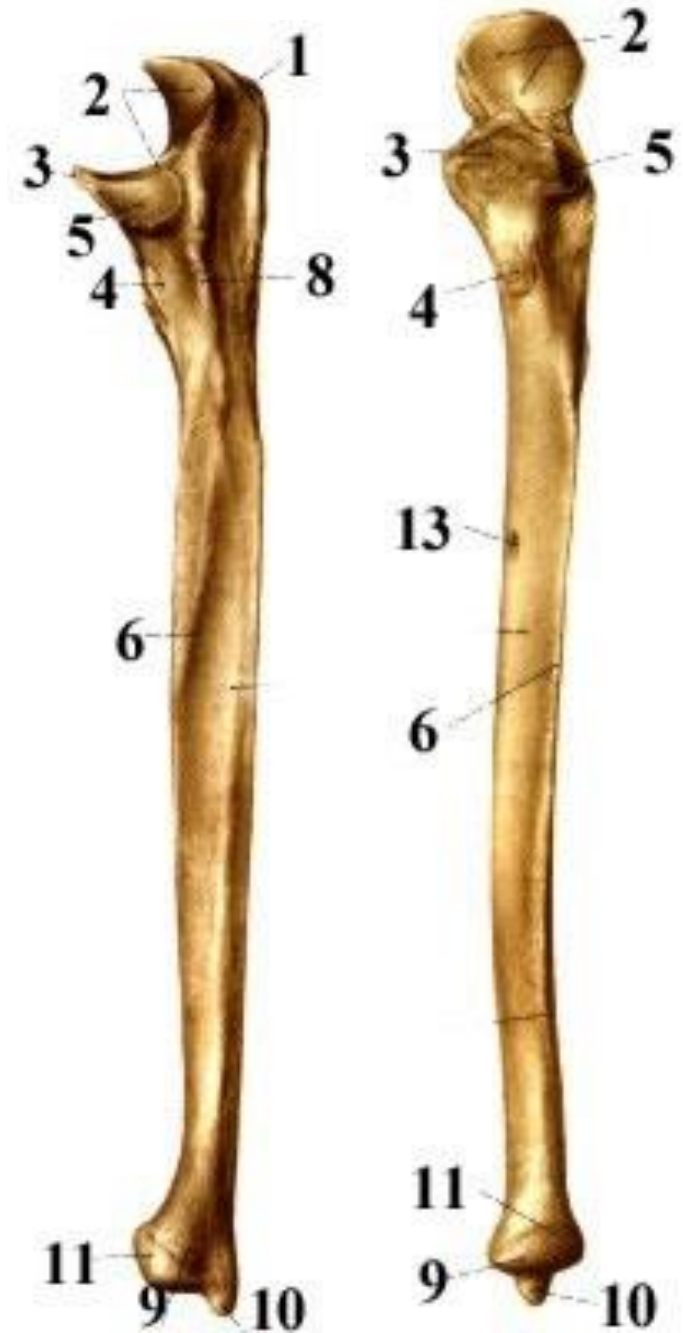
capitulum humeri

GELENKKOPF



Ulna

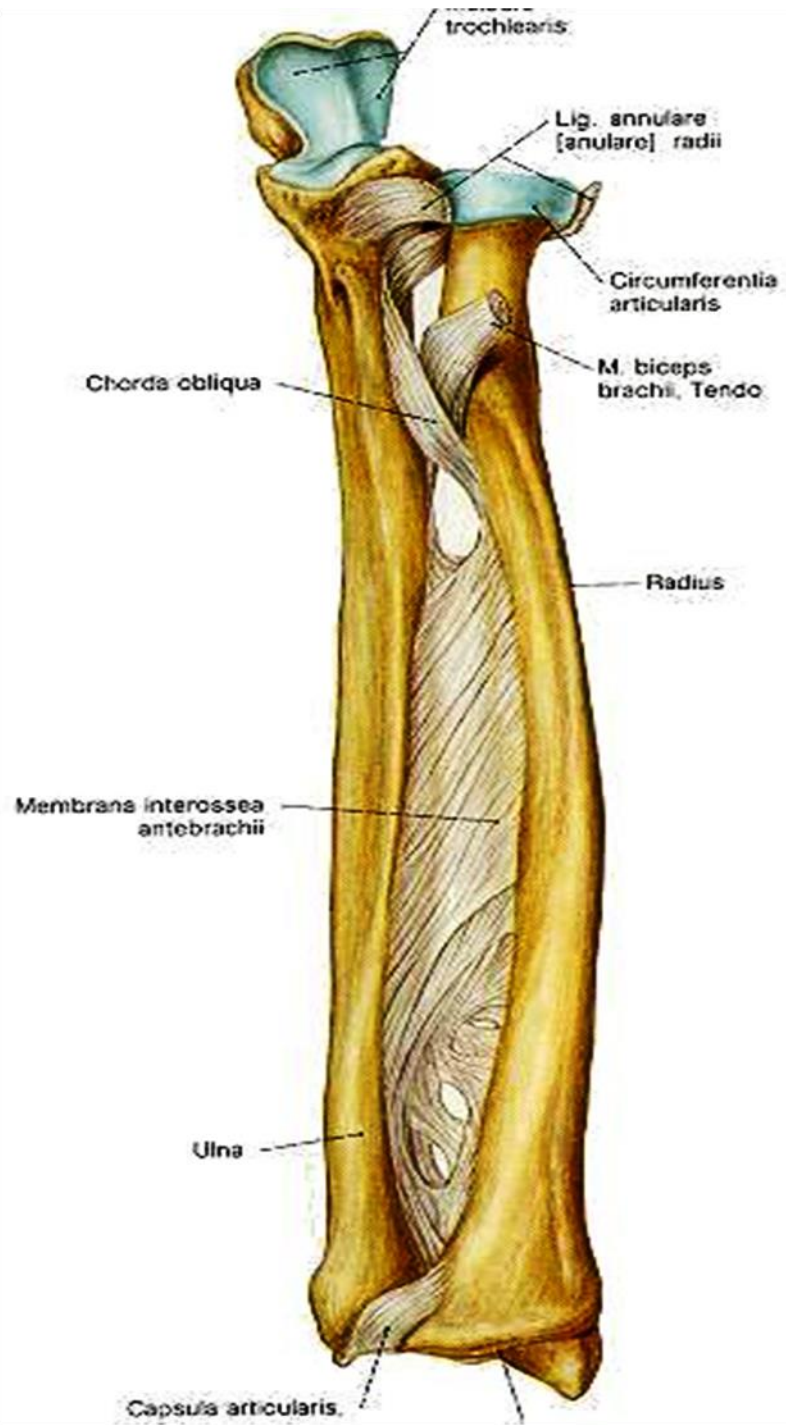
- Olecranon ulnae (1)
- Incisura trochlearis (2)
- Processus coronoideus (3)
- Incisura radialis (5)
- Corpus
- Margo interosseus (6)
- Caput ulnae (11)
- Processus styloideus (10)

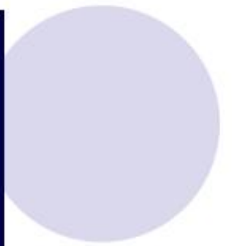
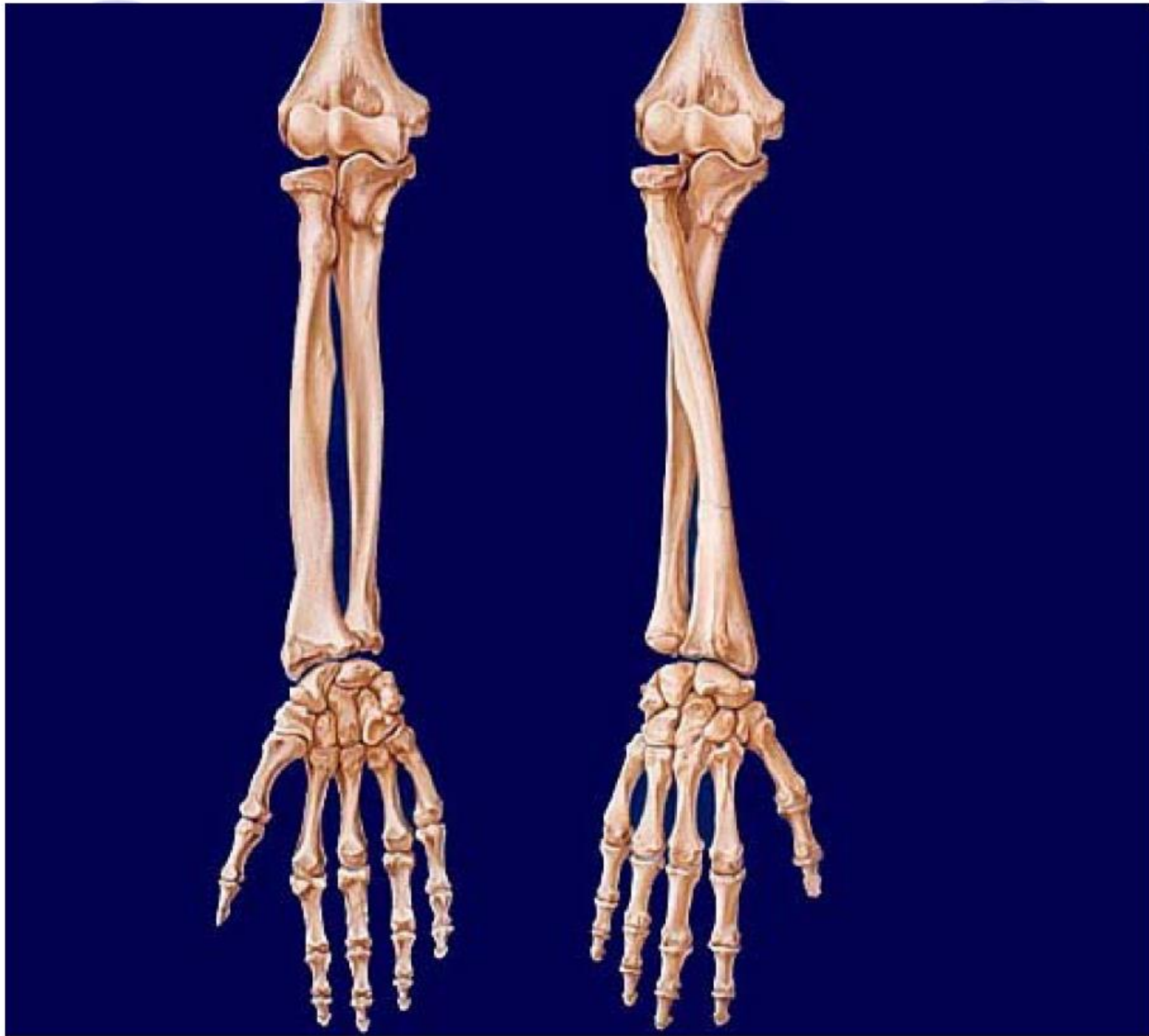


Radius

- Caput radii (1)
- Circumferentia articularis (2)
- Fovea capitis
- Collum radii (4)
- Tuberositas radii (5)
- Corpus radii
- Margo interosseus
- Facies articularis carpea
- Processus styloideus (11)

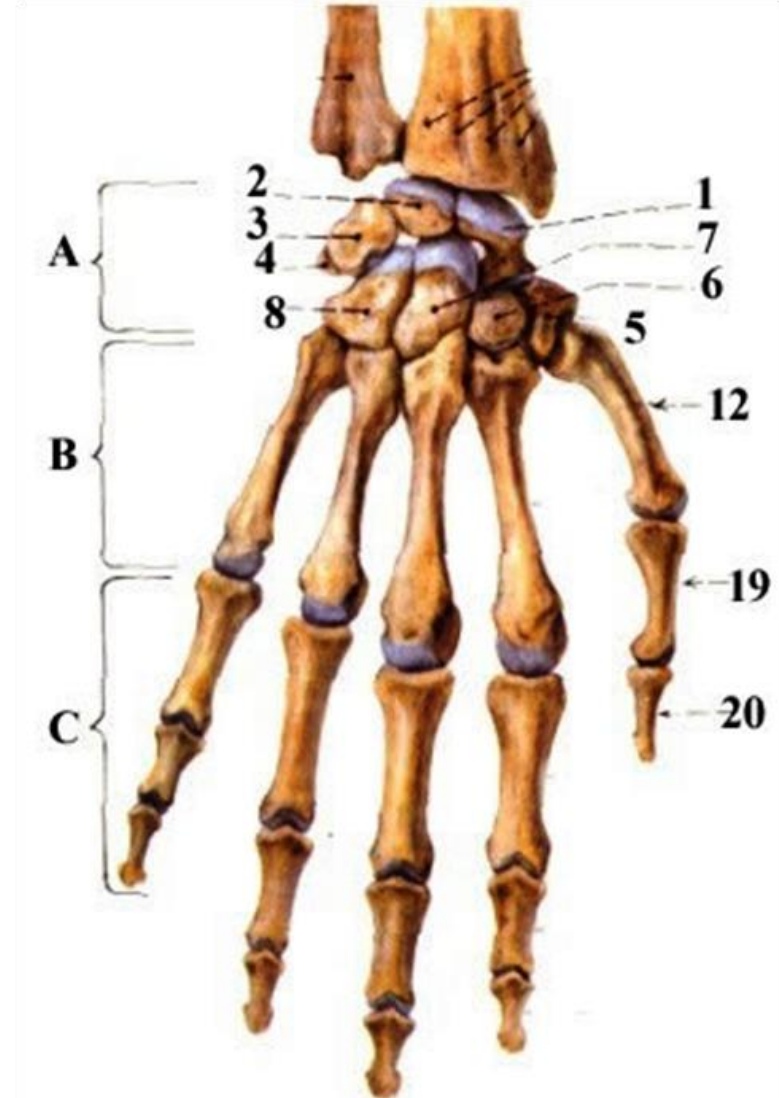


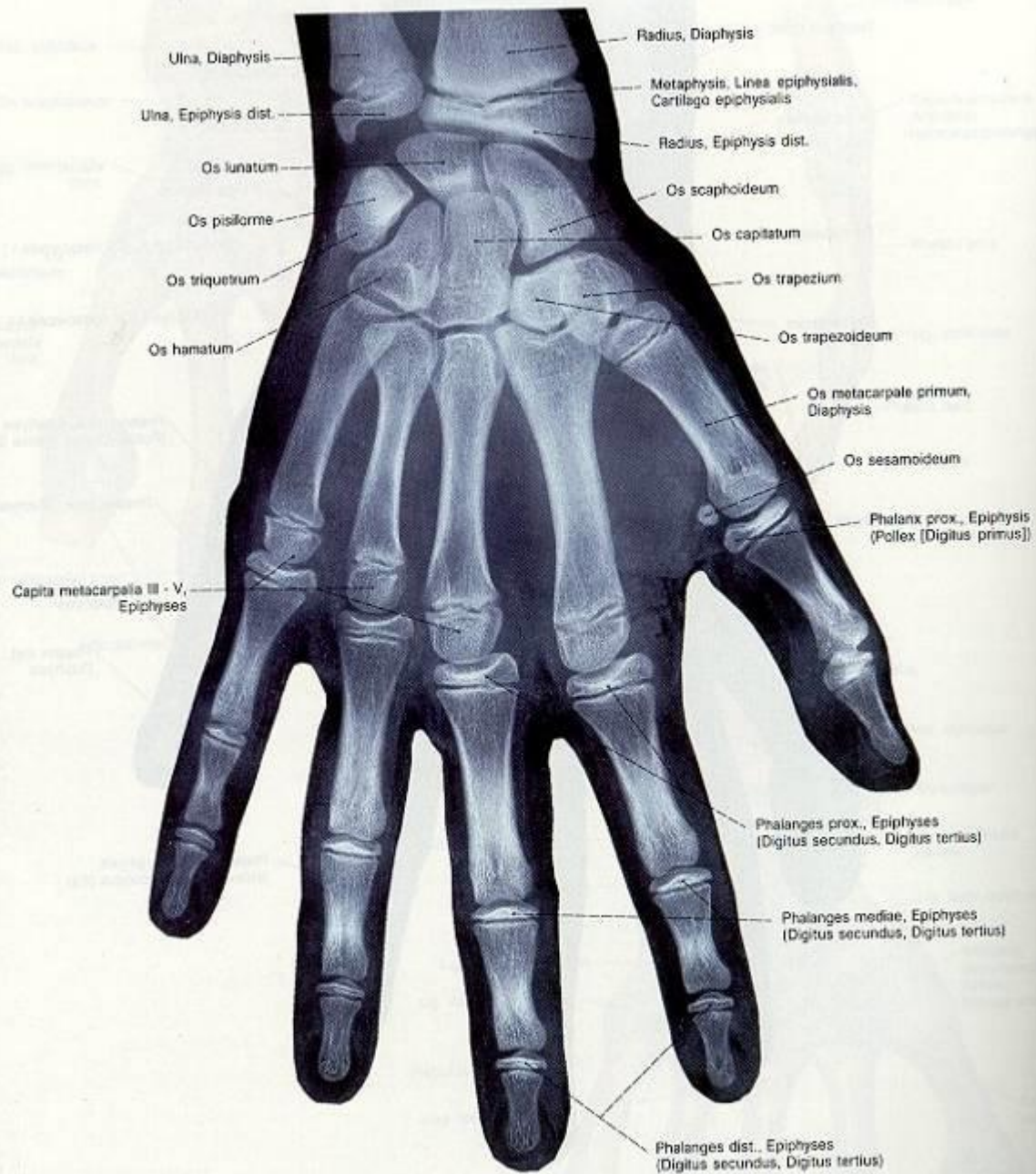



Ossa carpi - A

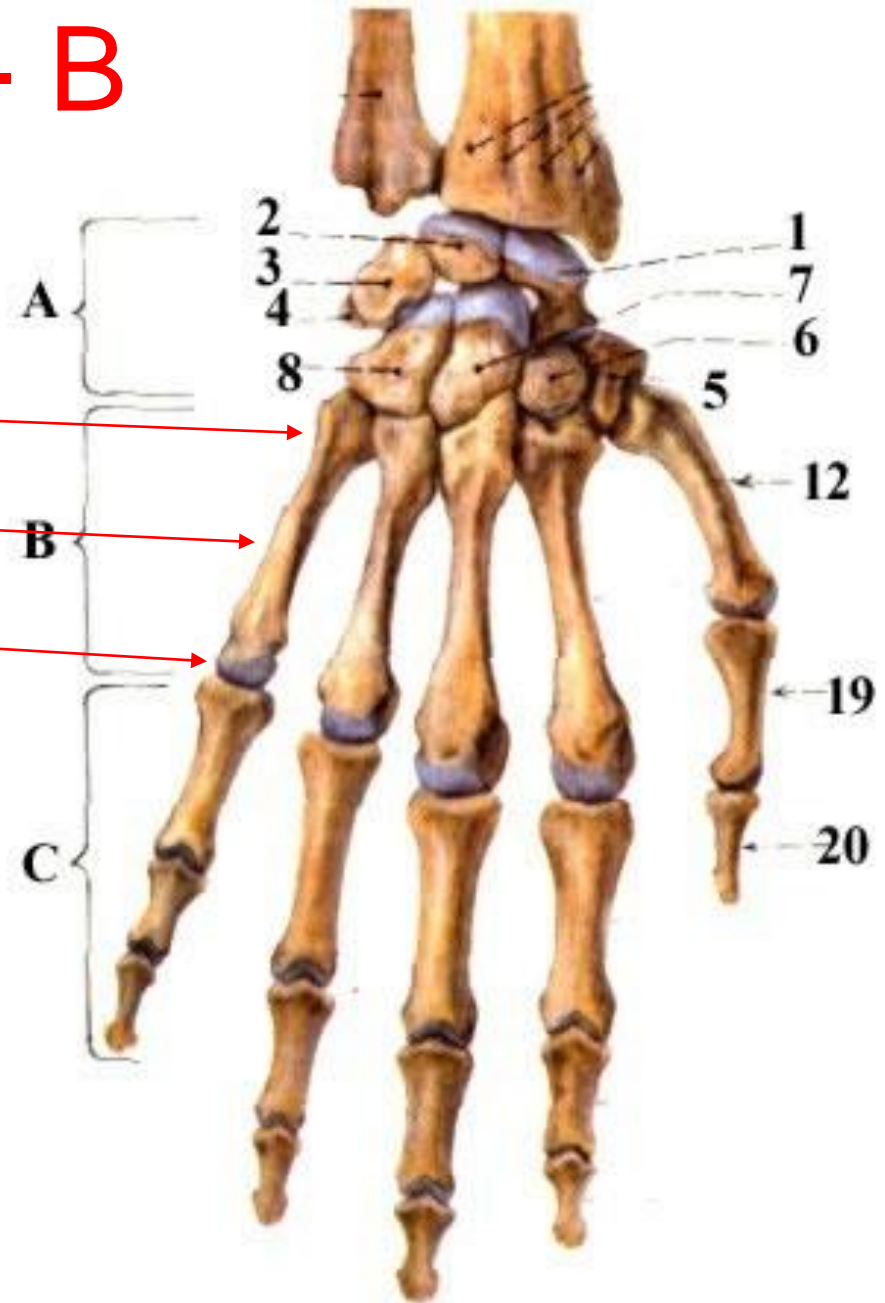
- os scaphoideum (1)
- os lunatum (2)
- os triquetrum (3)
- os pisiforme (4)
- os trapezium (5)
- os trapezoideum (6)
- os capitatum (7)
- os hamatum (8)



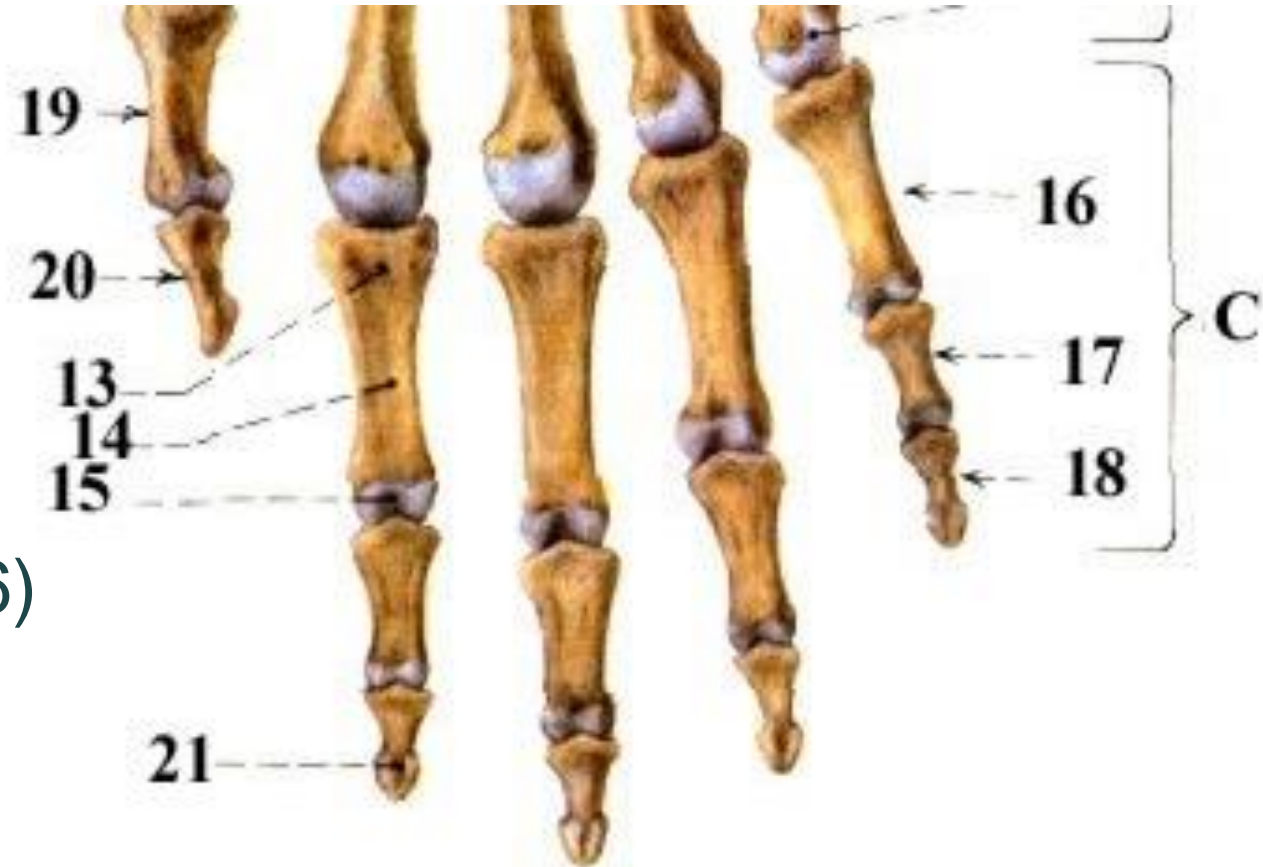

Ossa metecarpi - B

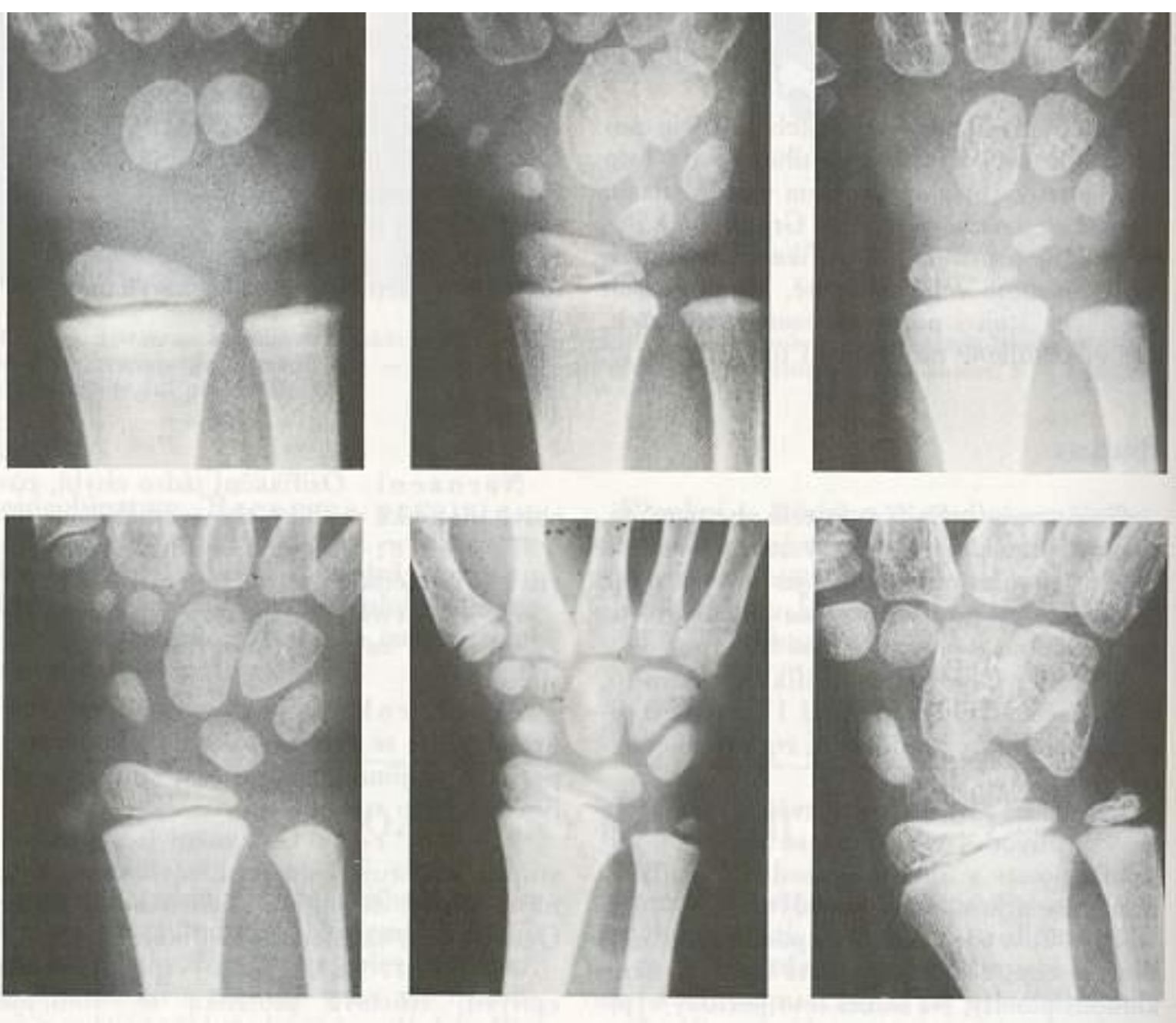
- Os metacarpale I-V
 - Basis
 - Corpus
 - Caput



OSSA DIGITORUM MANUS

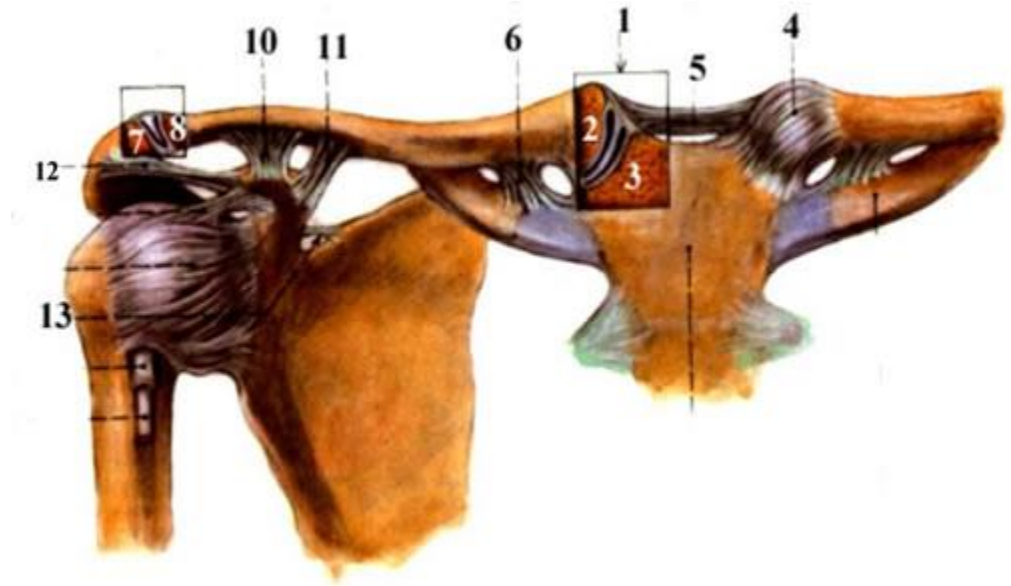


- Phalanges
- Phalanx
 - proximalis (16)
 - Media (17)
 - Distalis (18)
 - basis phalangis (13)
 - corpus phalangis (14)
 - caput phalangis (15)



postupná osifikace, kostní věk

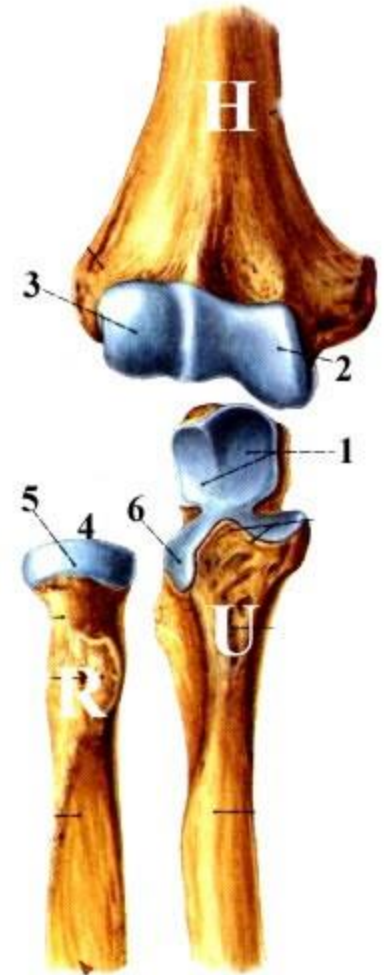
Articulatio sternoclavicularis



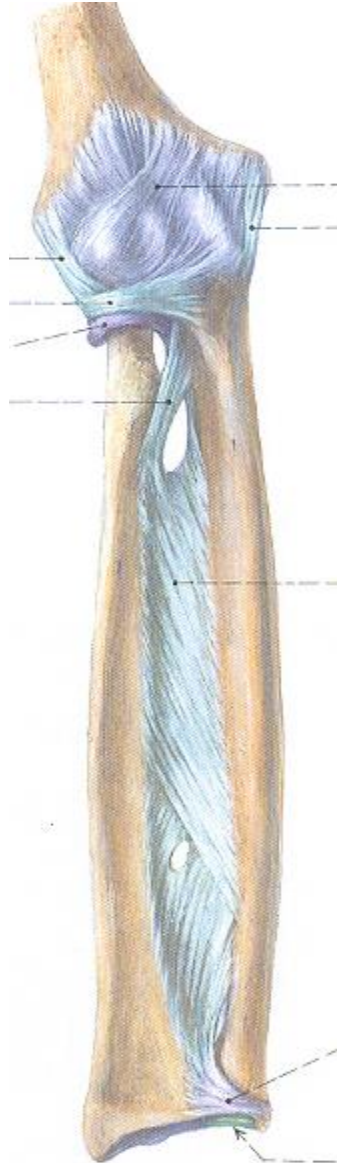
- Articulatio acromioclavicularis

Articulatio cubiti

- Articulatio humeroulnaris
- Articulatio humeroradialis
- Articulatio radioulnaris proximalis
lig. collaterale radiale
lig. collaterale ulnare
lig. anulare radii



Articulatio cubiti



- *Articulatio radioulnaris distalis*- zde je možná pronace a supinace spojení radia a ulny na distálním konci
- *Membrana interossea antebrachii*- přidržuje předloketní kosti a je místem začátku řady svalů

Articulationes manus

- Retinaculum flexorum

