

Anatomy practice 1

Mgr. Kateřina Vymazalová, Ph.D.

Email: vymazalova@med.muni.cz

INTRODUCTION TO ANATOMY


Lectures:

Seminar room S4-5


Seminars:

Dissection room P2

Safety at work



- pr
- Lc



- Accident
- Pregnancy



Credit

- attendance (95%)

	Přednášky	Semináře	Lectures	Seminars
1.	Úvod do anatomie Obecná osteologie Kostra hrudníku a páteře	Anatomické názvosloví Úvod do rtg anatomie Exkurze do anat. muzea	Anatomical terminology General osteology Skeleton of the spine and thorax	Introduction into the study of anatomy Anatomical terminology RTG anatomy
2.	Kosti horní končetiny	Kostra hrudníku a páteře	Skeleton of the upper extremity	Skeleton of the spine and thorax
3.	Kosti dolní končetiny	Kosti horní končetiny	Skeleton of the lower extremity	Skeleton of the upper extremity
4.	Stručný popis kostí lebky Lebka jako celek	Kosti dolní končetiny	Bones of the skull Cavities of the skull	Skeleton of the lower extremity
5.	Obecná arthrologie Spoje hlavy, hrudníku a páteře	Stručný popis kostí lebky Lebka jako celek	General arthrology Joints of the head, spine and thorax	Bones of the skull Cavities of the skull
6.	Obecná myologie Svaly hlavy, krku a hrudníku	Spoje hlavy, hrudníku a páteře	General myology, muscles of head, neck and thorax	Joints of the spine, thorax and skull
7.	Svaly zad a břicha Inguinální kanál	Svaly hlavy, krku a hrudníku	Muscles of back and abdomen, Inguinal canal	Muscles of the head, neck and thorax
8.	Spoje horní končetiny	Svaly zad a břicha, inguinální kanál	Joints of the upper extremity	Muscles of the abdomen and back, inguinal canal
9.	Svaly horní končetiny I	Spoje horní končetiny	Muscles of the upper limb I	Joints of the upper extremity
10.	Svaly horní končetiny II	Svaly horní končetiny I	Muscles of the upper limb II	Muscles of the upper limb I
11.	Spoje dolní končetiny	Svaly horní končetiny II	Joints of the lower extremity	Muscles of the upper limb II
12.	Svaly dolní končetiny I	Spoje dolní končetiny	Muscles of the lower limb I	Joints of the lower extremity
13.				
14.	Svaly dolní končetiny II	Svaly dolní končetiny	Muscles of the lower limb II	Muscles of the lower limb

Lending of bones

PŮJČOVÁNÍ KOSTÍ *LENDING OF BONES*

1. – 5. týden

1. – 5. week

PONDĚLÍ
MONDAY 10.00 – 16.00

ÚTERÝ
TUESDAY 8.00 – 16.00

STŘEDA
WEDNESDAY 10.00 – 17.00

ČTVRTEK
THURSDAY 10.00 – 17.00

PÁTEK
FRIDAY 8.00 – 14.00

Půjčování a vracení kostí probíhá vždy v celou hodinu!

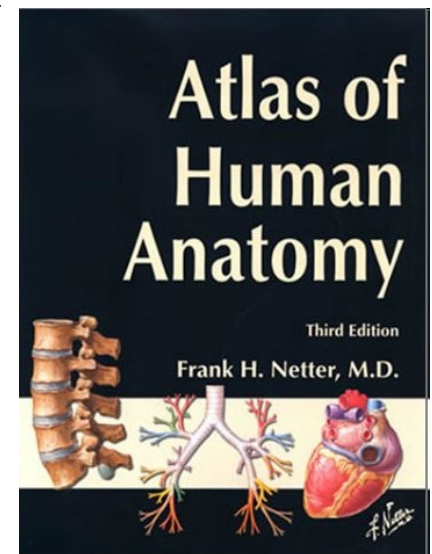
Lending and returning of bones is held every single hour!

RECOMMENDED LITERATURE

- **Páč, L., Horáčková, L., Nechutová, H.:**
Anatomy of human locomotor system. Brno
2010

Atlases for example:

- **Netter, F. H.:** ***Atlas of Human Anatomy***
- **Sobotta:** ***Atlas of Human Anatomy***



Anatomical nomenclature

The first word is name of described formation,
next adjectives specificate it
and in the end there is a name of formation where the
described formation is located.

Examples:

Collum (neck) **radii** (of radius)

Collum (a neck) **anatomicum** (anatomical) **humeri** (of humerus)

Collum (a neck) **chirurgicum** (surgical) **humeri** (of humerus)

Tuberculum (a tubercle, a bulge) **majus** (big) **humeri** (of humerus)

Spina (a thorn) **iliaca** (iliac) **anterior** (fore) **superior** (upper) **ossis coxae** (of coxal bone)

Epicondylus medialis humeri

Epicondylus medialis femoris

PARTS OF HUMAN BODY

head – **caput**

neck – **collum (cervix)**

trunk – **truncus**

 chest – **thorax**

 belly – **abdomen**

pelvis – **pelvis**

back – **dorsum**

Upper limb– **membrum superius**

 arm – **brachium**

 forearm – **antebrachium**

 hand – **manus**

Lower extremity– **membrum inferius**

 thigh – **femur**

 leg – **crus**

 foot- **pes**

Positive and negative relief

- **Sulcus** – a groove
- **Incisura** – a notch
- **Canalis** – a canal
- **Fossa** – a pit, hollow
- **Fovea** – a pit, hollow
- **Processus** – a projection, prominence
- **Spina** – a thorn
- **Tuberculum** – a tubercle
- **Tuber** – a torus
- **Tuberositas** – a tuberosity
- **Foramen** – an opening, orifice, gap
- **Facies** – a facet, surface
- **Articulatio** – a joint
- **Os, ossis, ossa** – a bone, bones

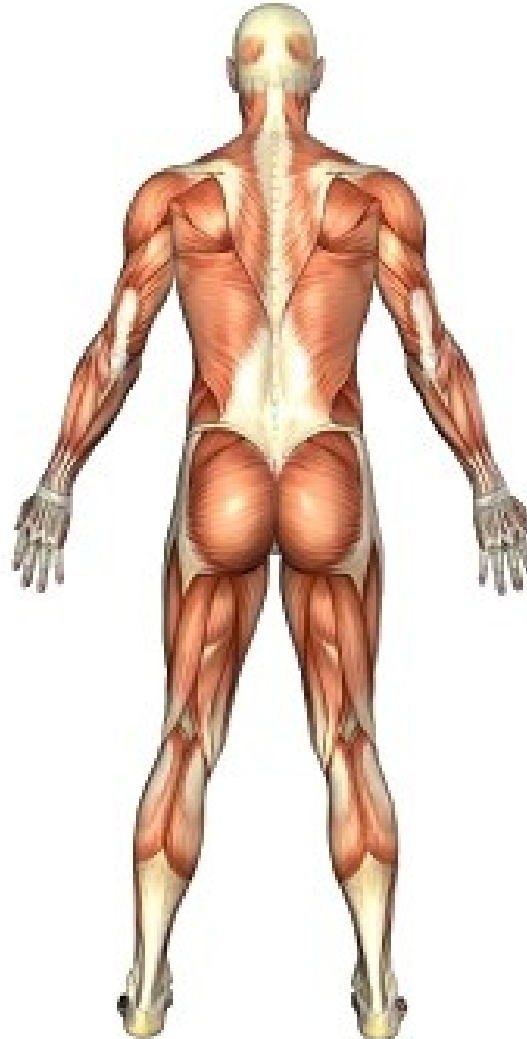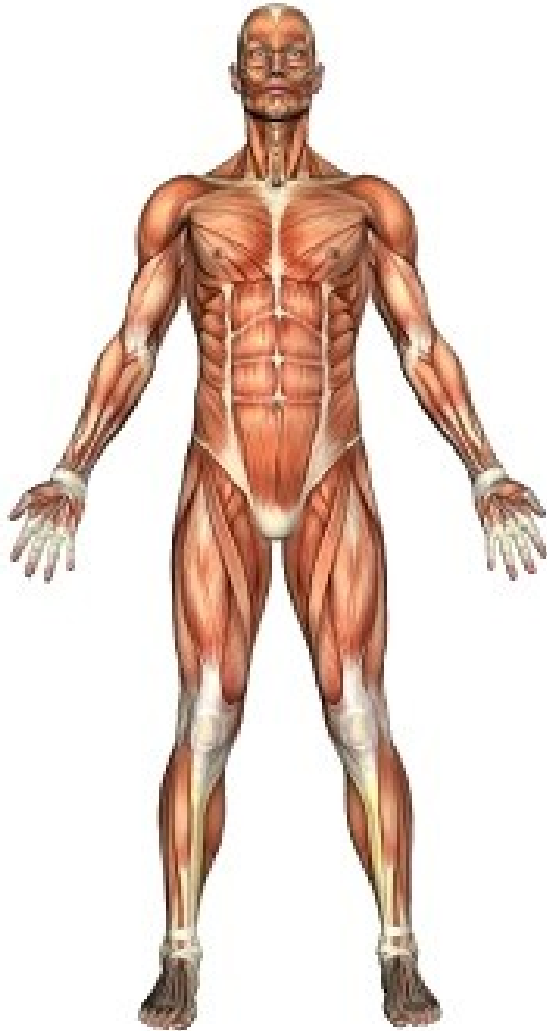Caput – a head

Capitulum – a small head

Collum, cervix – a neck

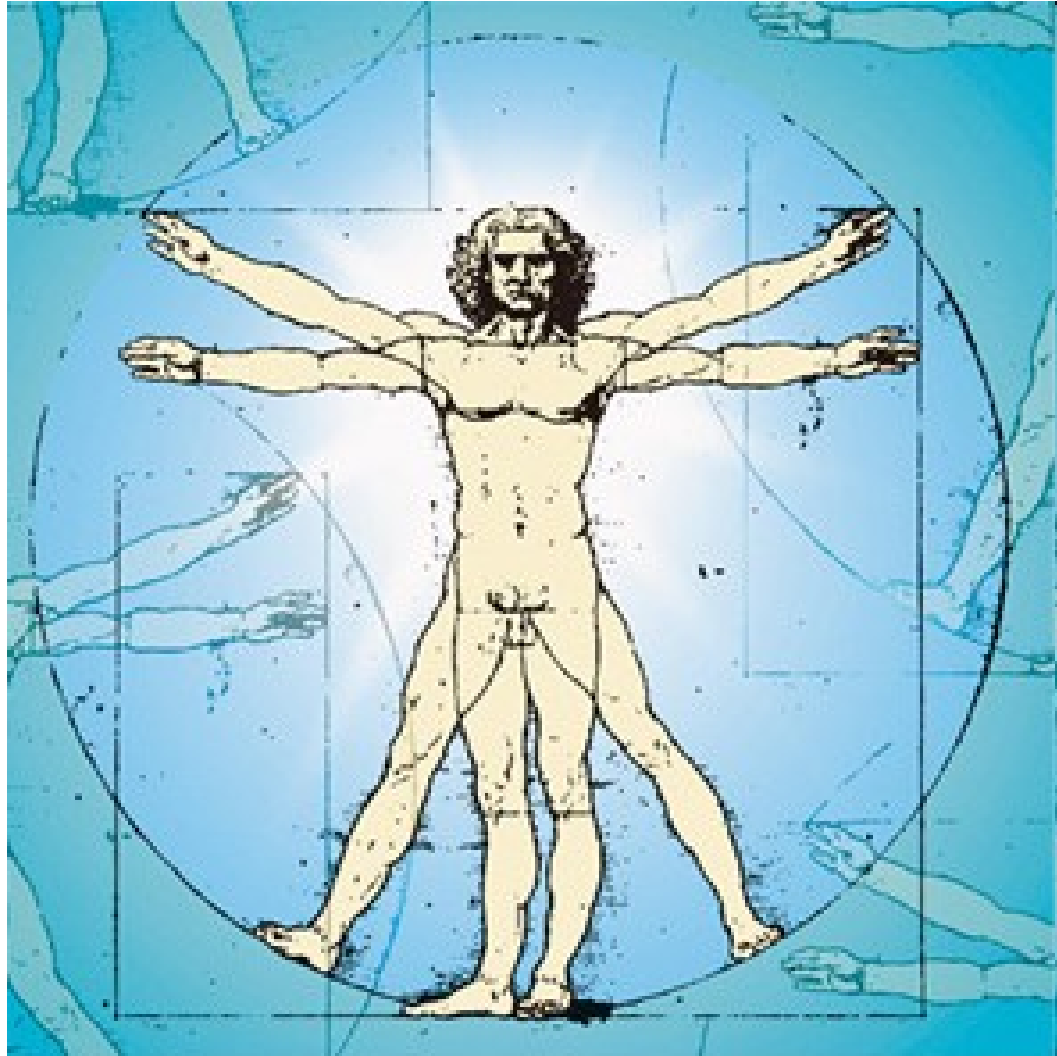
Anatomical position standard erect position

Not
a military
position


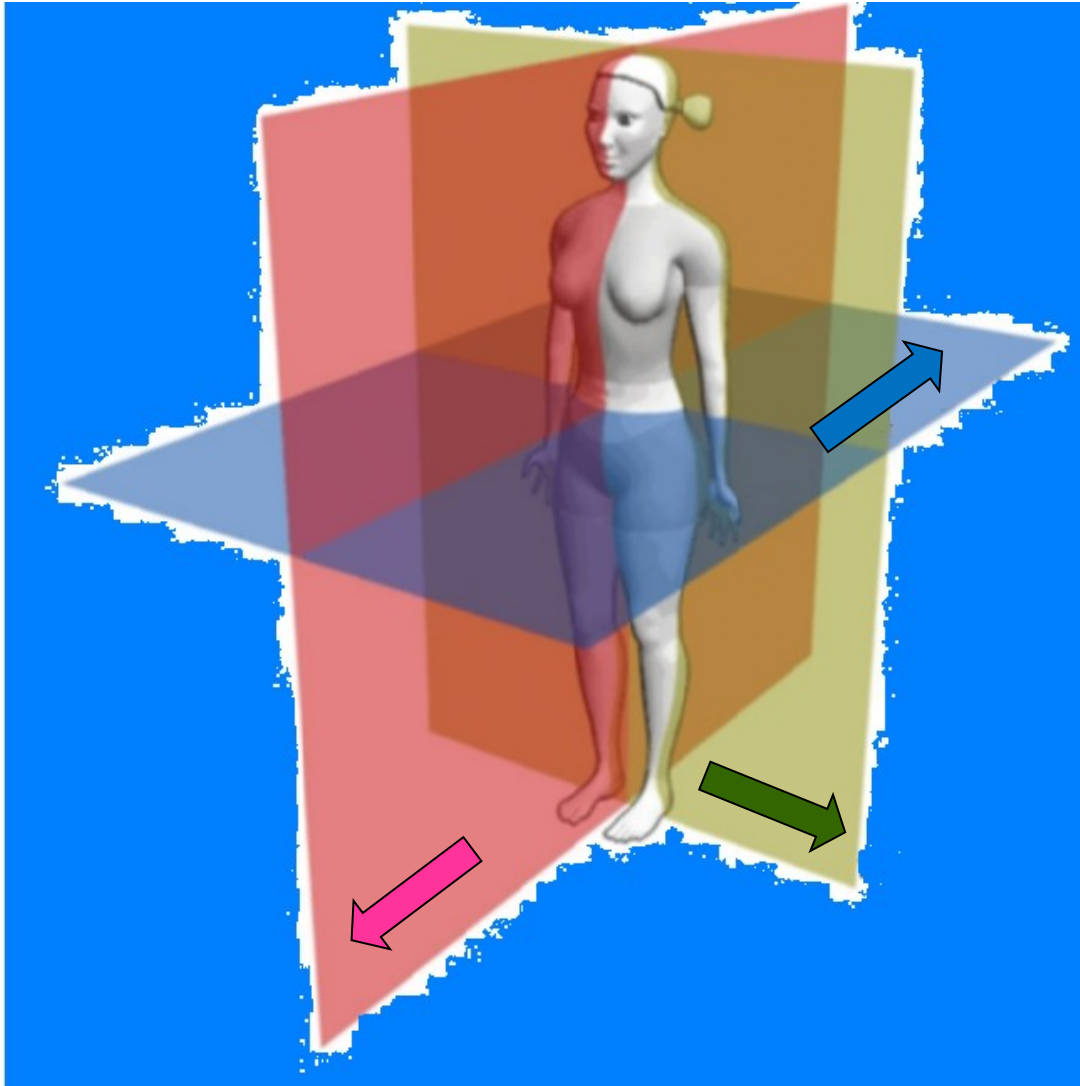


Colourbox

Orientation on the body



PLANES – 3 anatomical planes or sections



Sagittal plane
Right and left

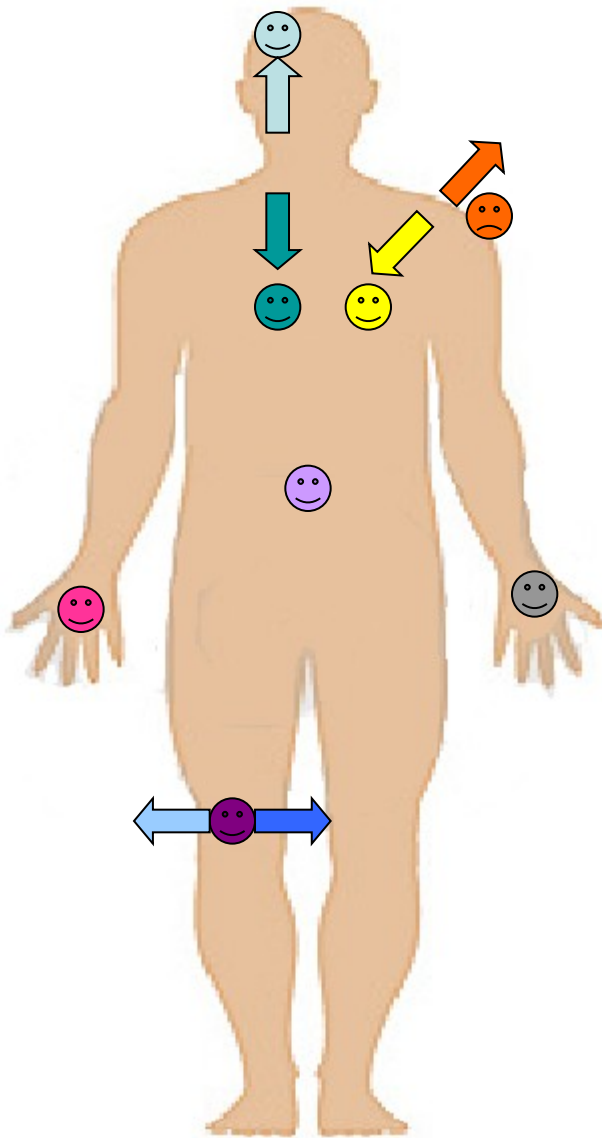


Transversal plane (horizontal)
Superior and inferior



Frontal plane (coronal)
Anterior and posterior

Directions on the body



→ cranialis

😊 superior

→ ventralis

😊 anterior

→ medialis

😊 medianus

😊 dexter

● superficilais

😊 internus

→ caudalis

😊 inferior

→ dorsalis

😊 posterior

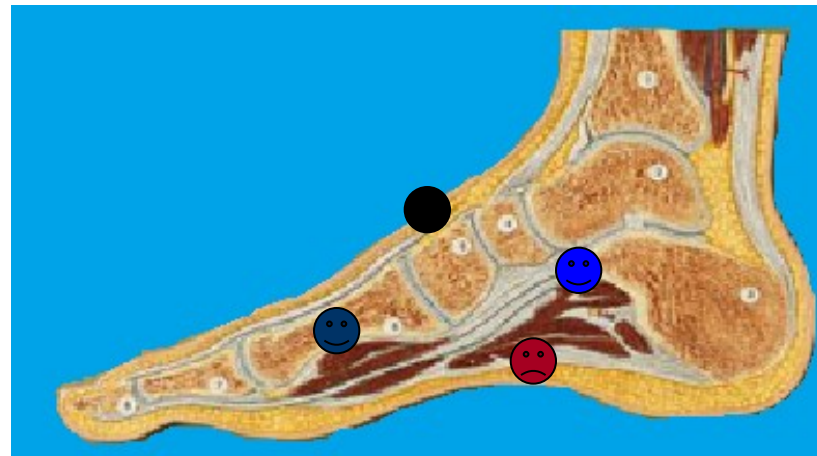
→ lateralis

😊 medius (intermedius)

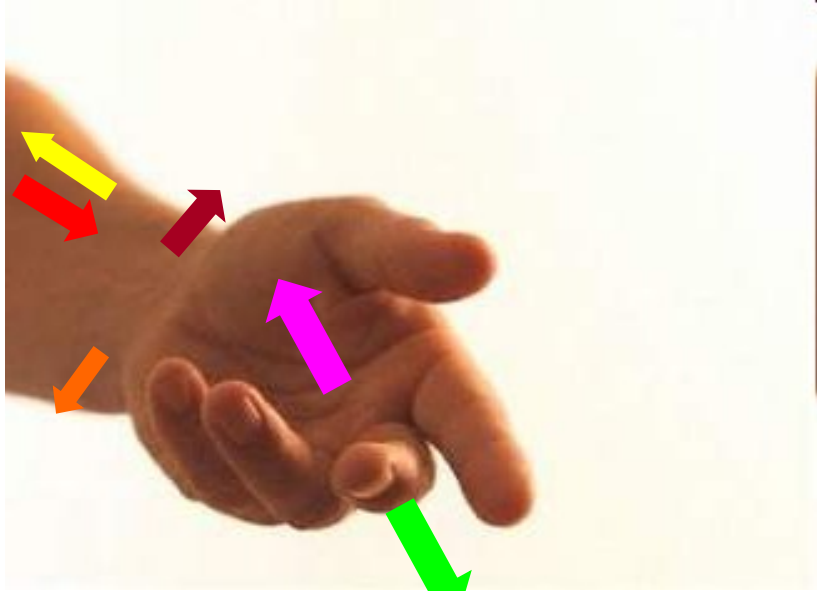
😊 sinister










😊 profundus

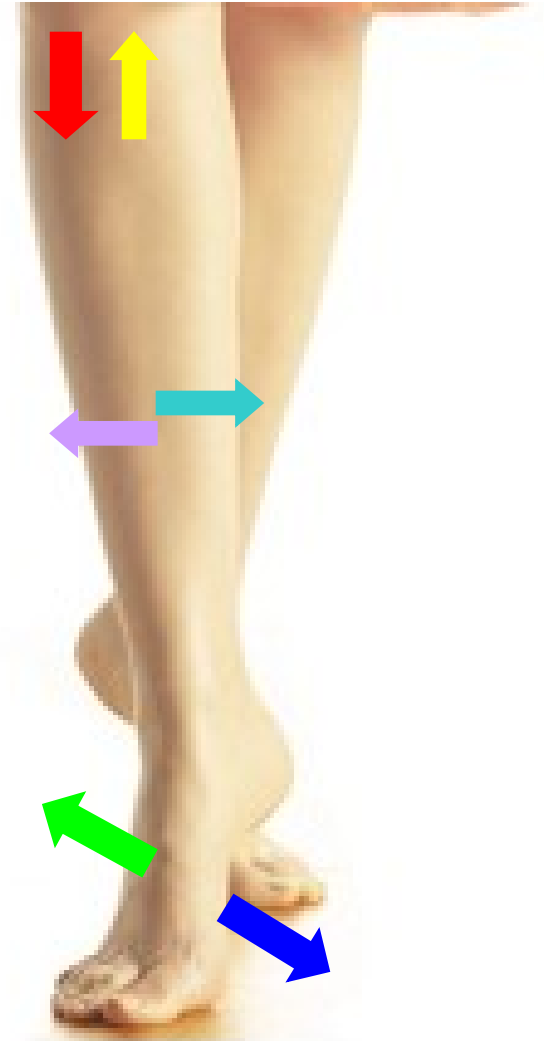😊 externus



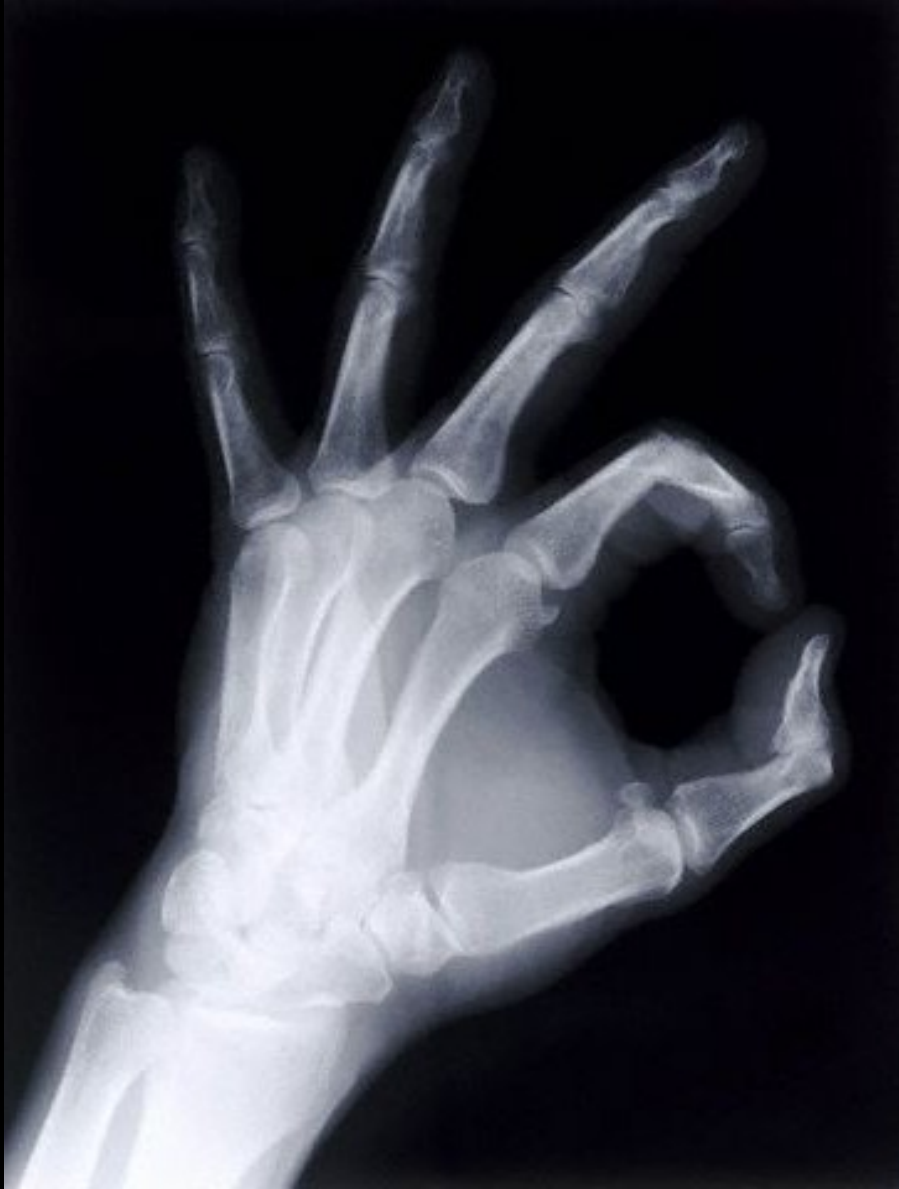Directions at the limbs



- proximalis 
- distalis 
- radialis 
- ulnaris 
- tibialis 
- fibularis 
- palmaris 
- plantaris 
- dorsalis 

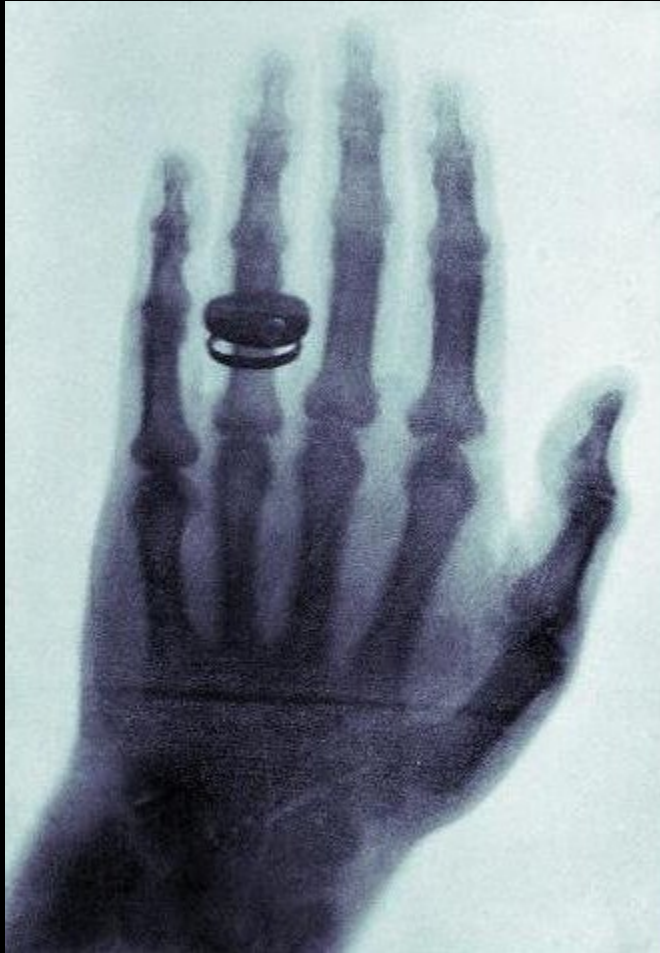


X-ray's anatomy



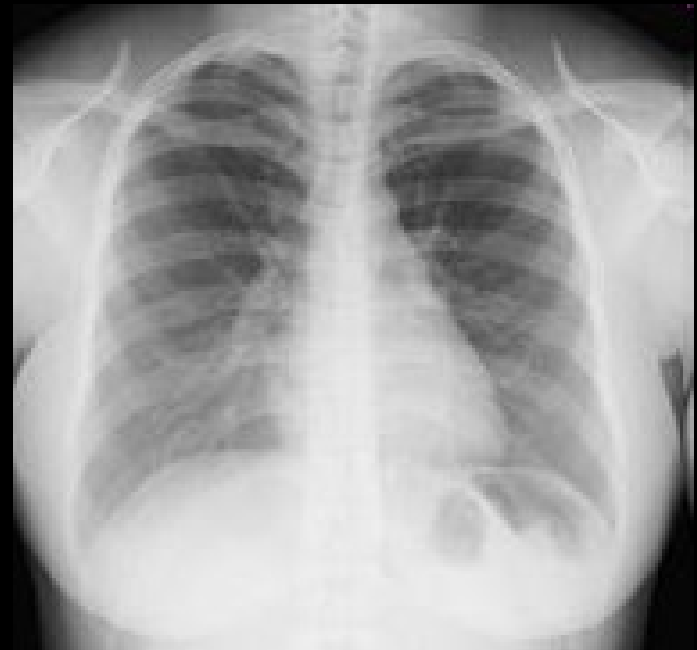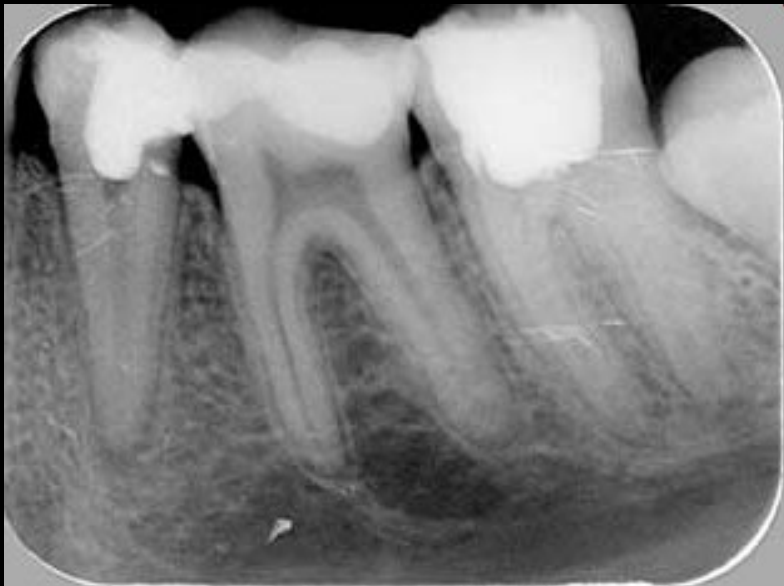Anatomy is essential for understanding radiology.

Wilhelm Conrad Röntgen 1845-1923
1895 – discovery of x-ray
1901- awarded by Nobel price in physics

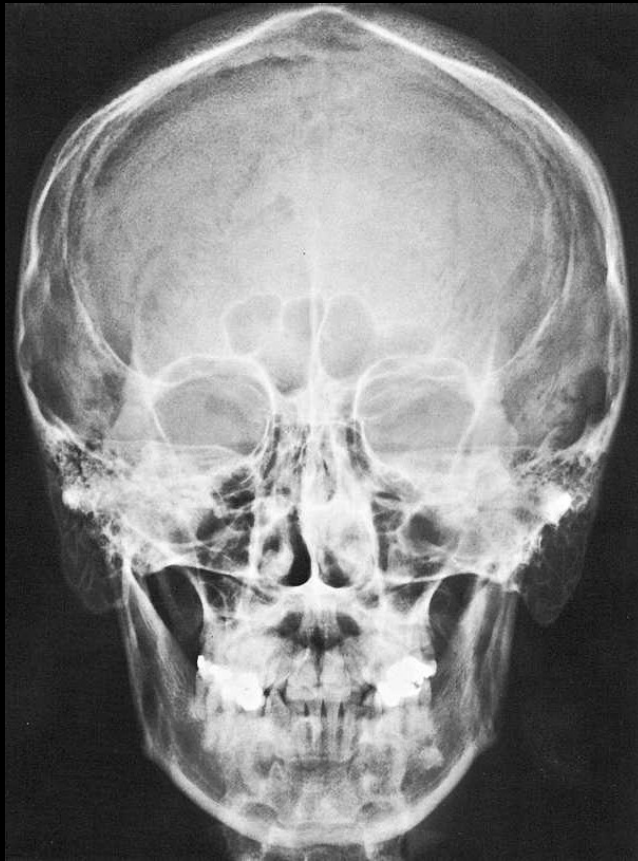


X-rays principle

- A highly penetrating beam of x-rays „transluminates“ the patient, showing tissues of differing densities on x-ray film.
- A tissue or organ that is relatively dense absorbs (stops) more x-rays than a less dense tissue.
- Like a negative
- Light structures –shadows
- Dark structures -brightening

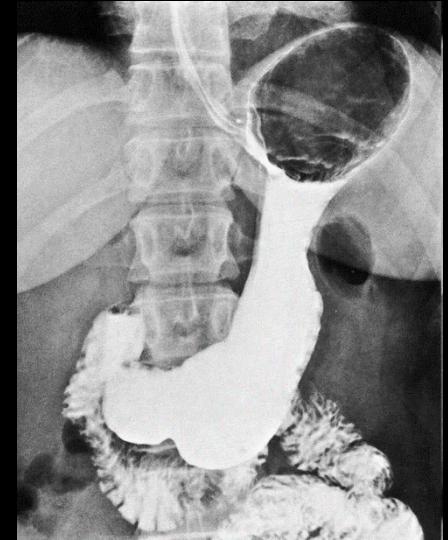


NATIVE x-ray
without using of
contrast agent



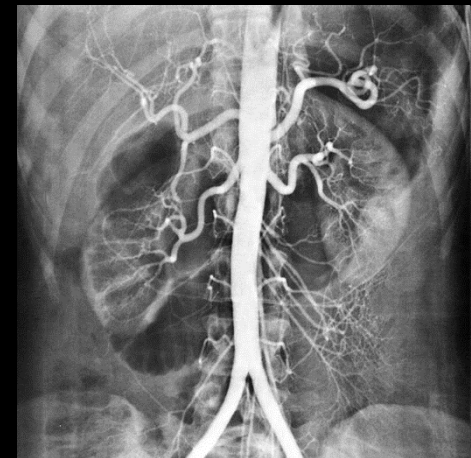
**X-rays with contrast
material** (Contrast
examination)

Negative
Gass, air



Positive
Barium sulfate

Iodine-based molecules



Thank you for your attention!

