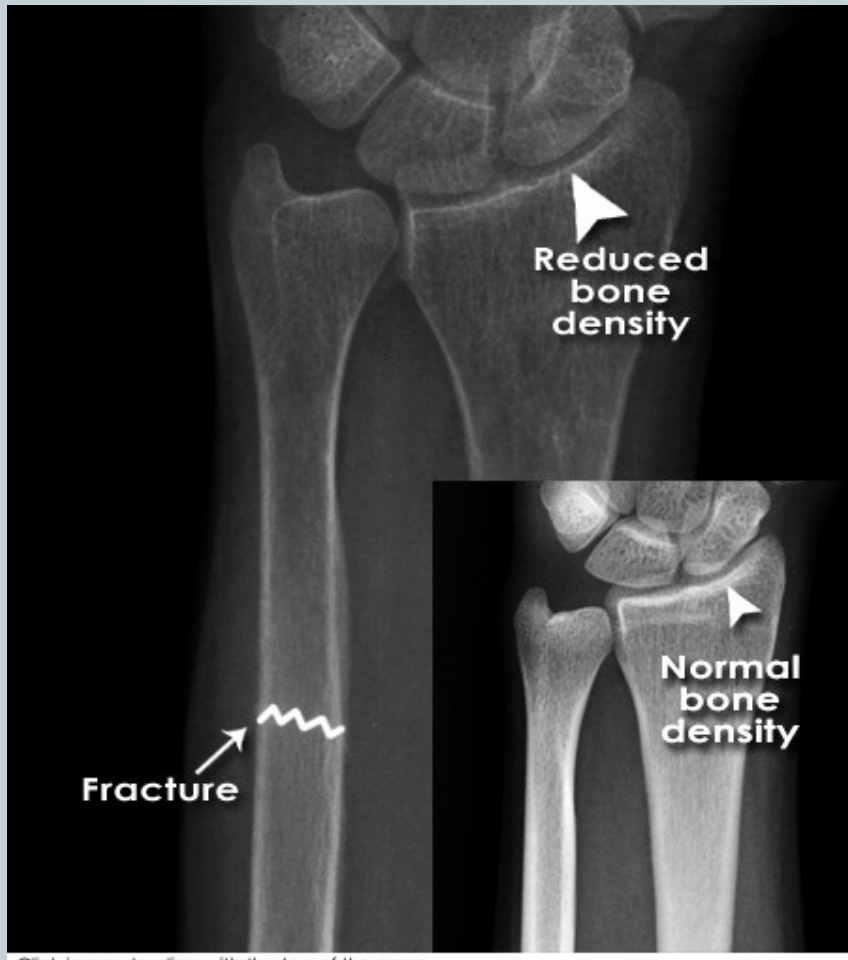

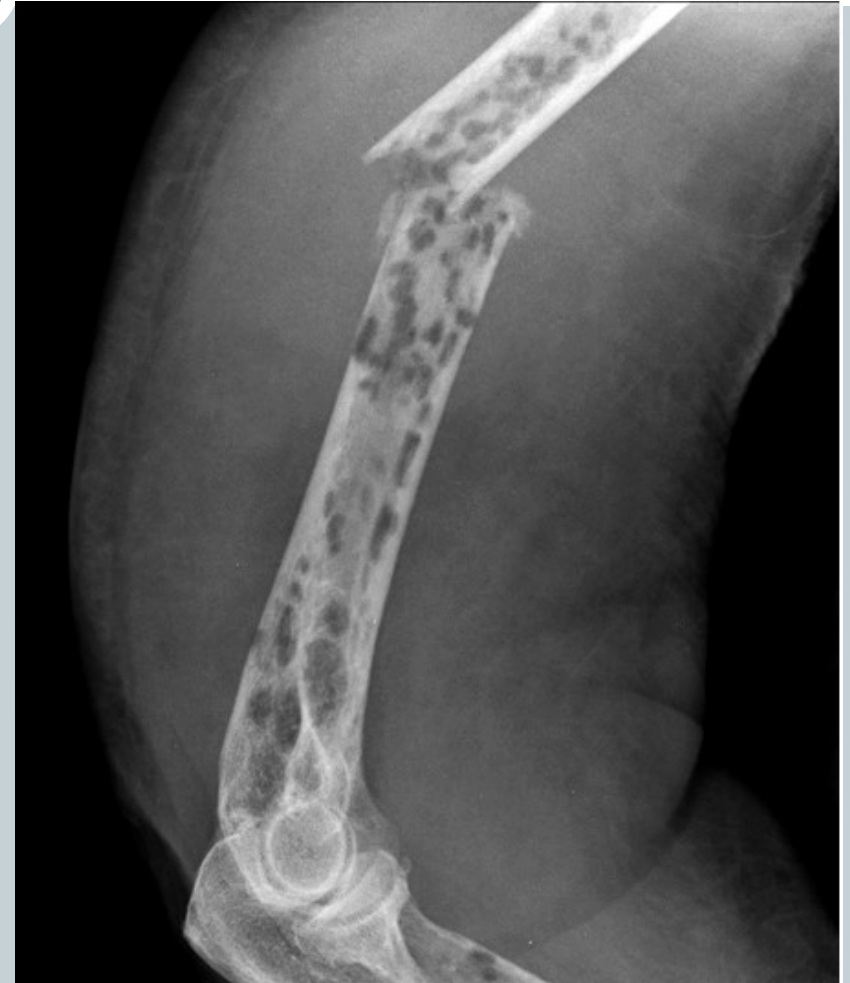Fractures



Fractura pathologica

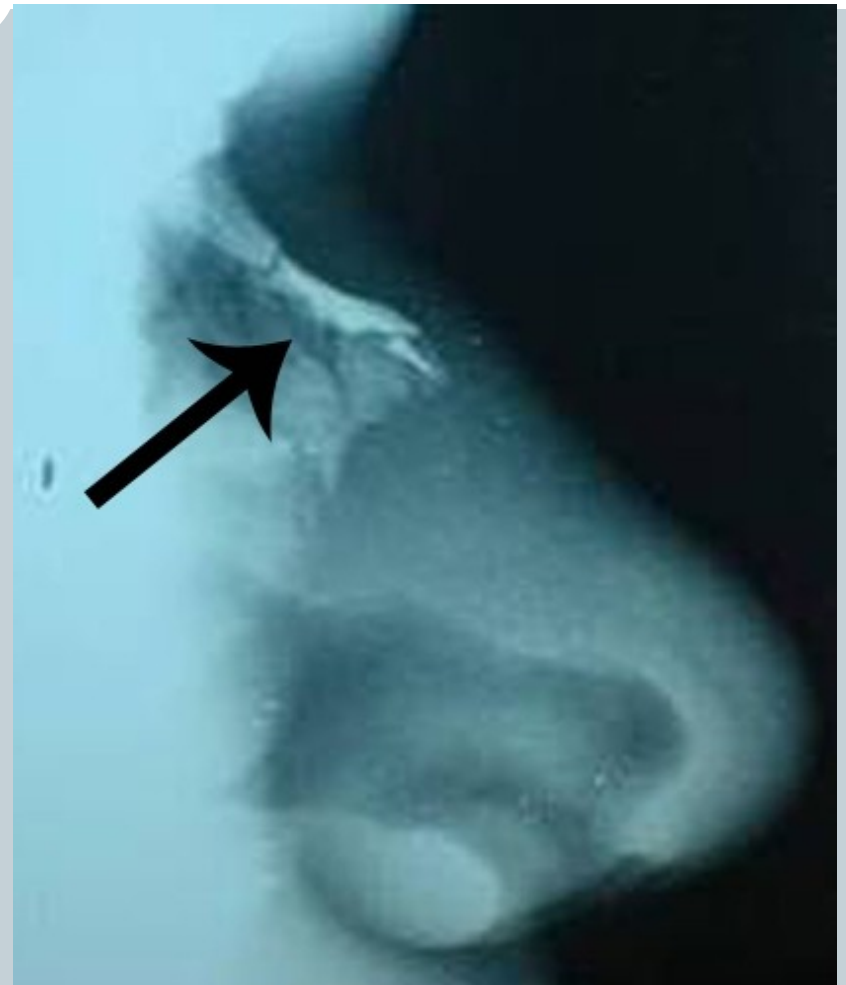
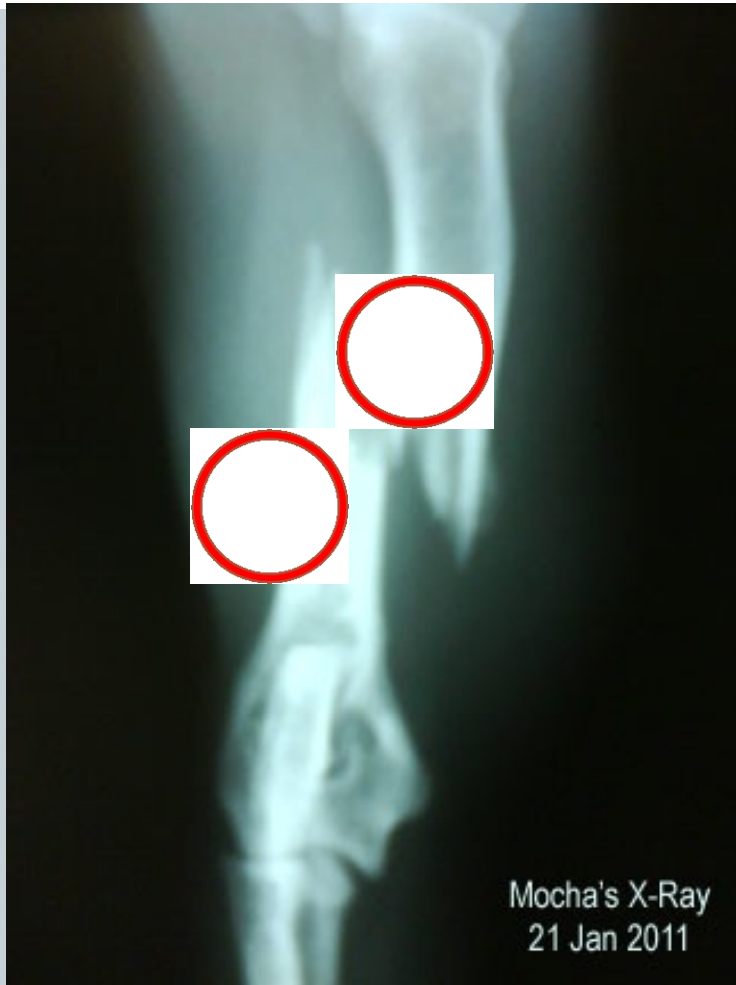

Click image to align with the top of the page

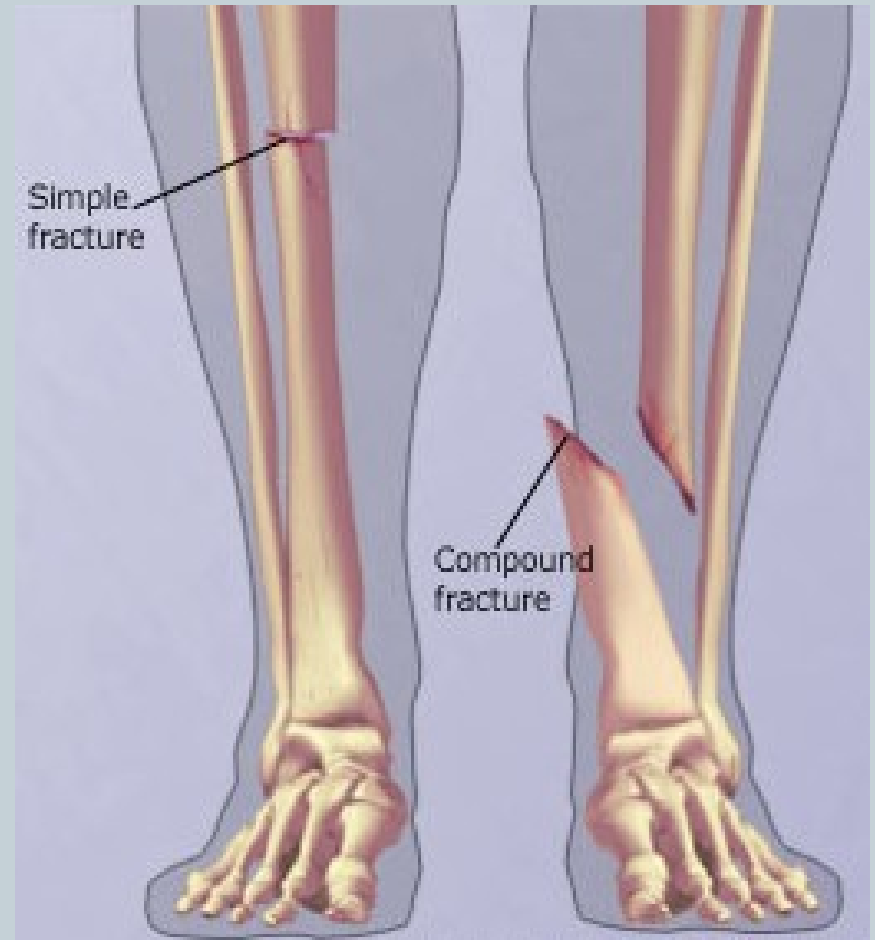
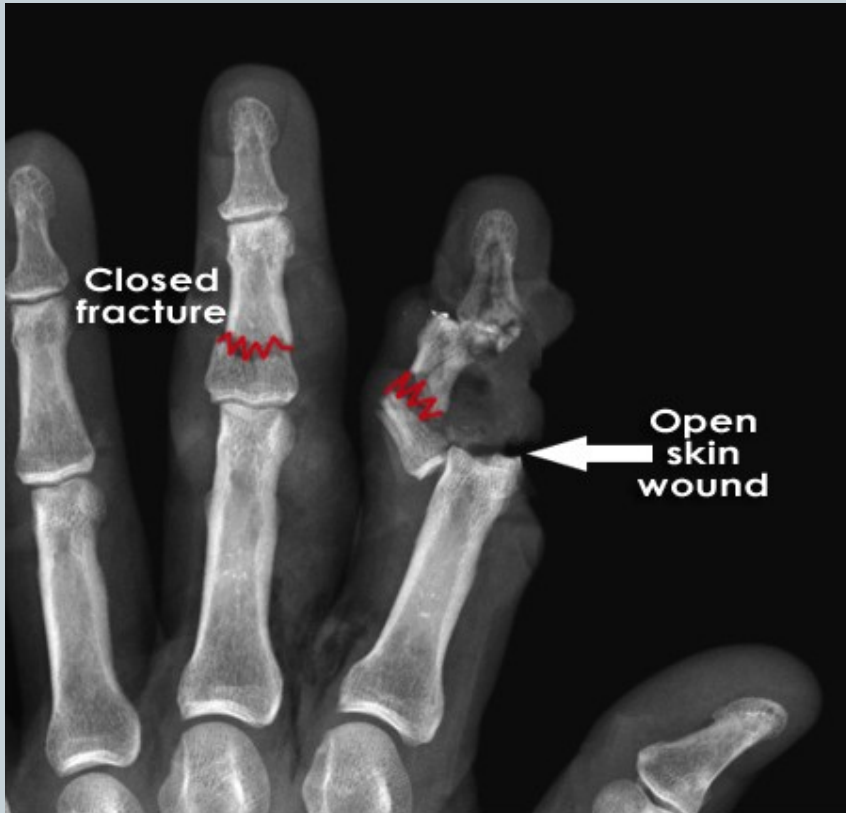

Myeloma -The plasma membrane of a muscle fiber

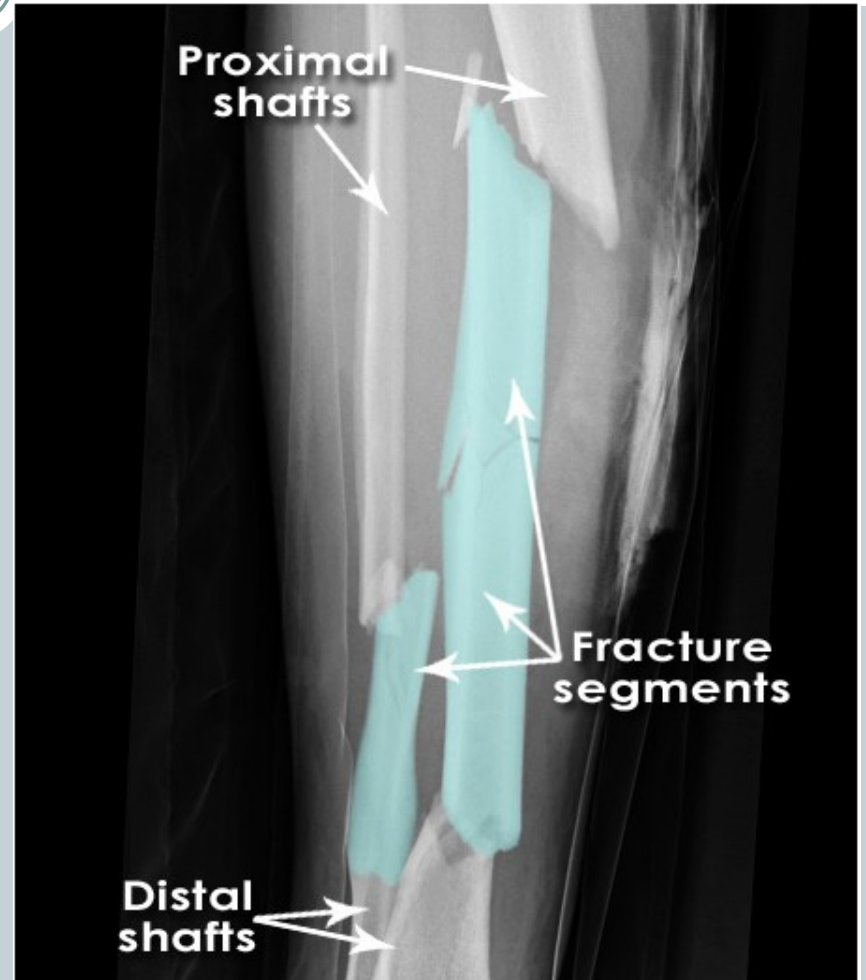
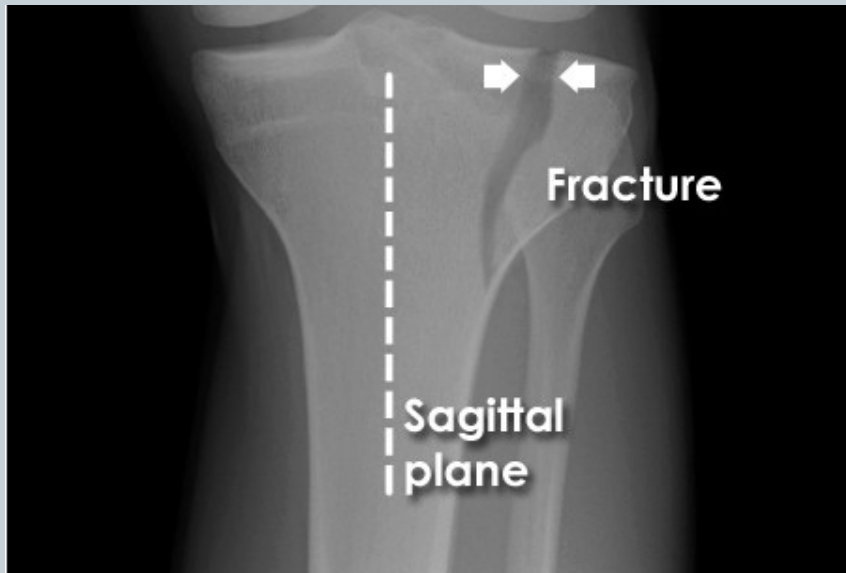
Fractura traumatica



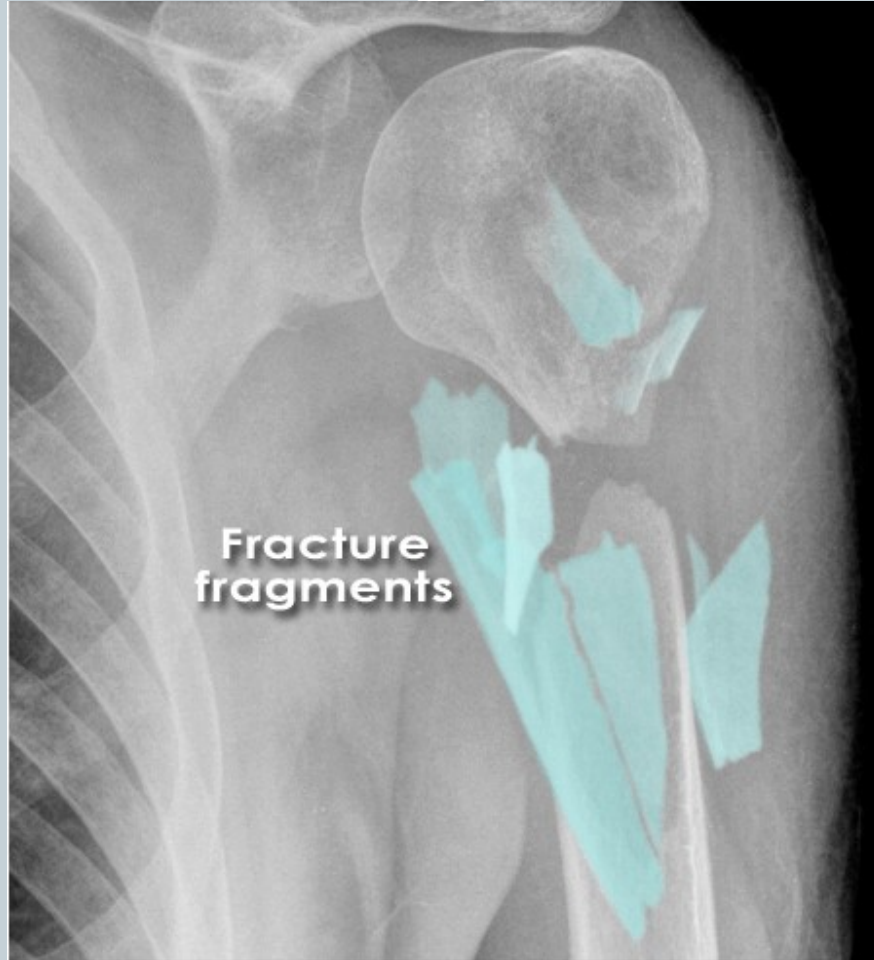
Fractura aperta/clausa



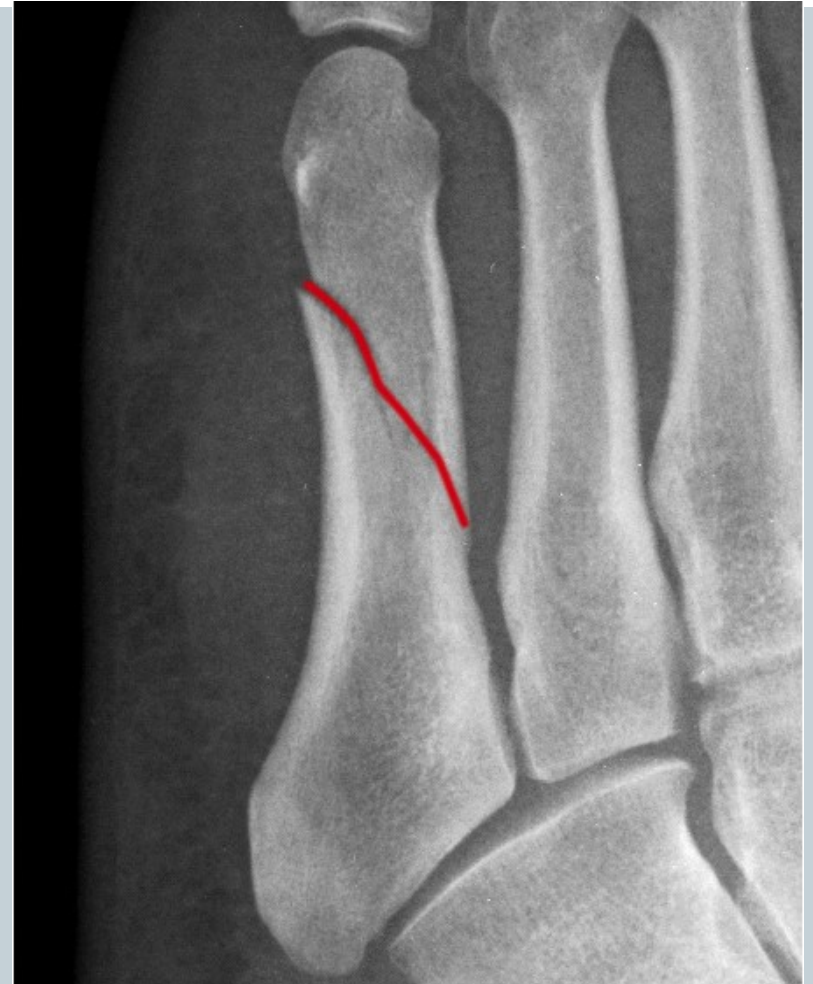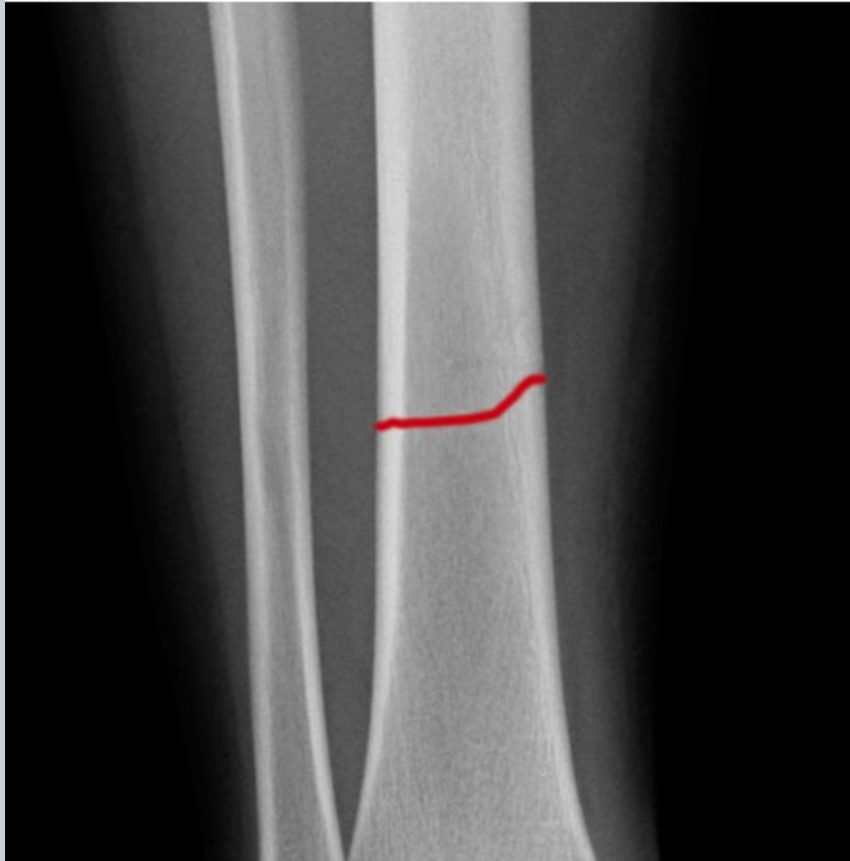Fractura simplex/multiplex



Fractura comminutiva



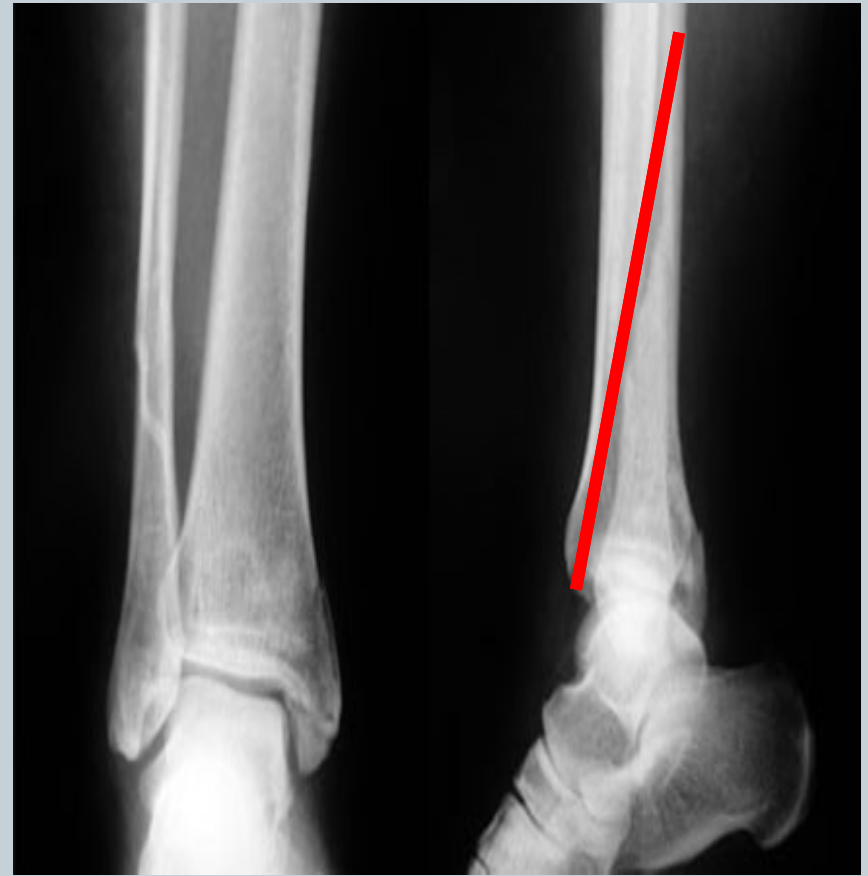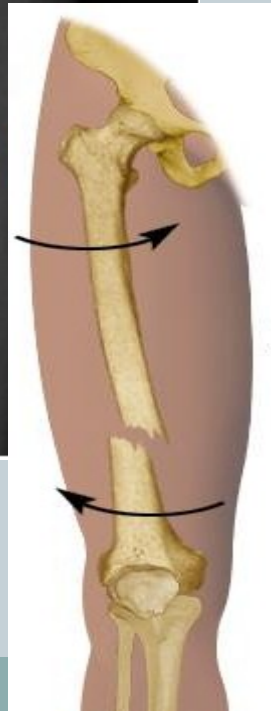
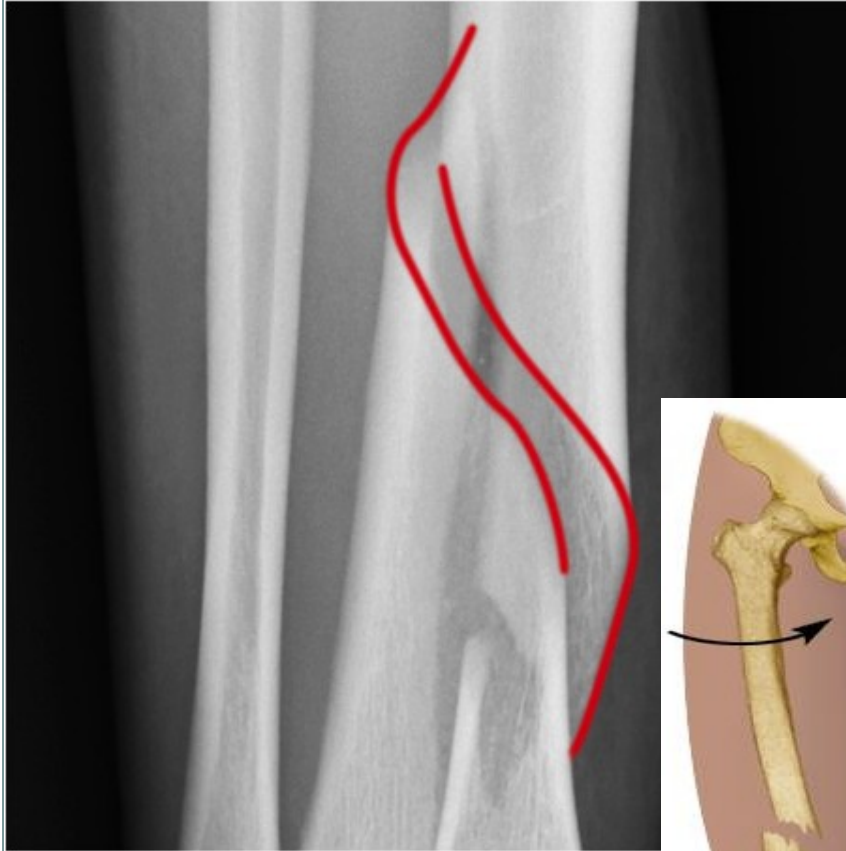
Fractura transversa/obliqua



Fractura spiralis

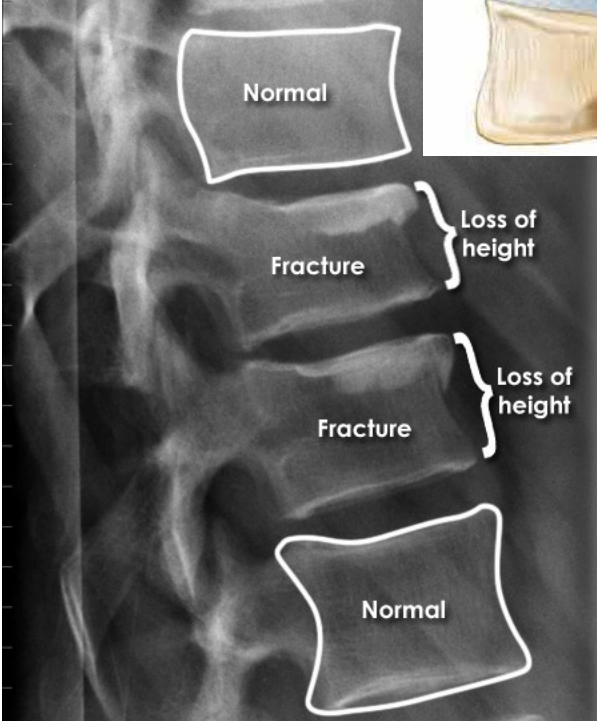
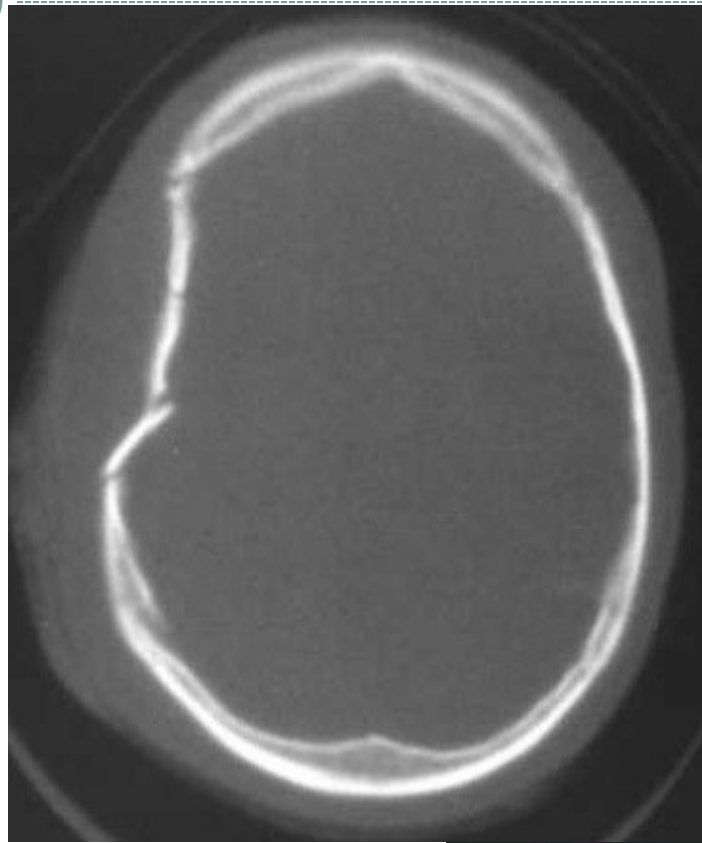
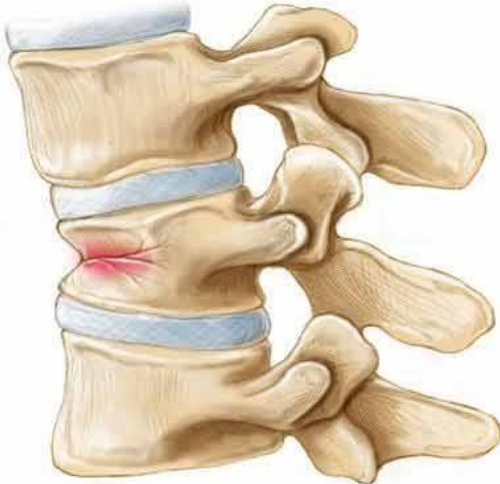/

longitudinalis

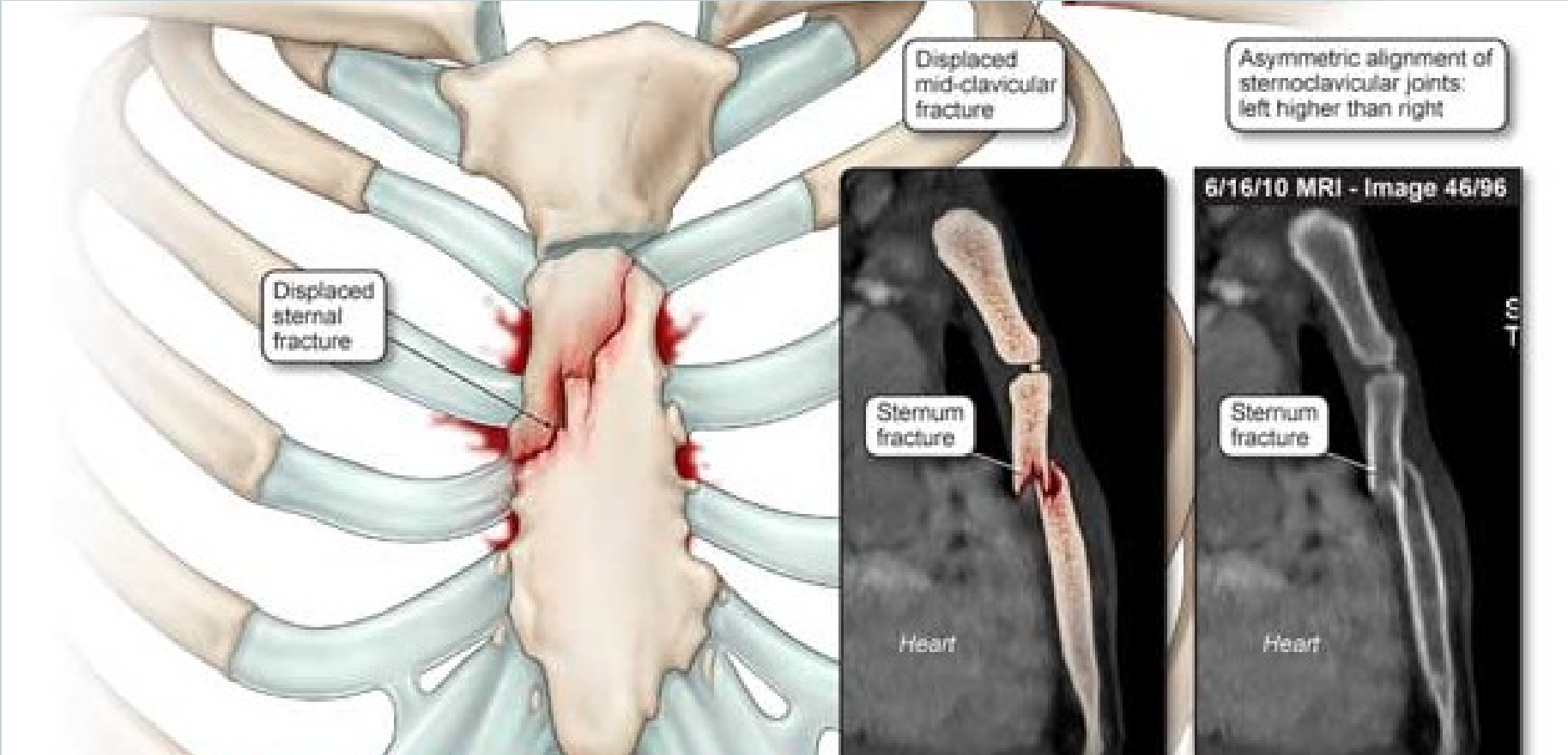


Fractura compressiva

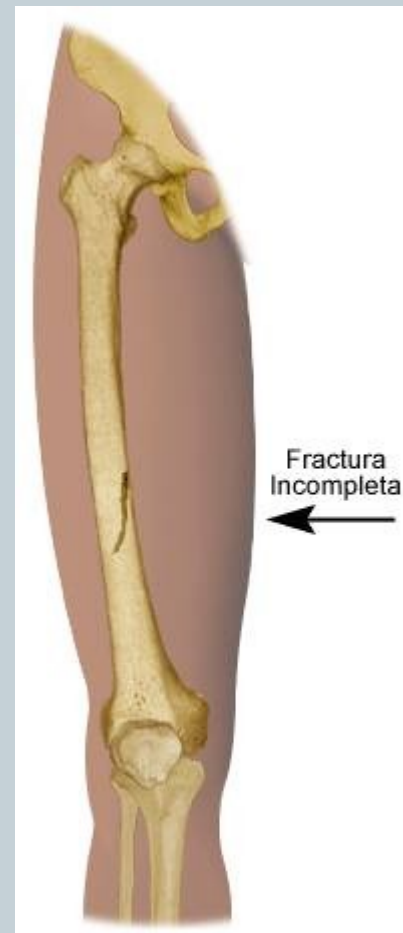
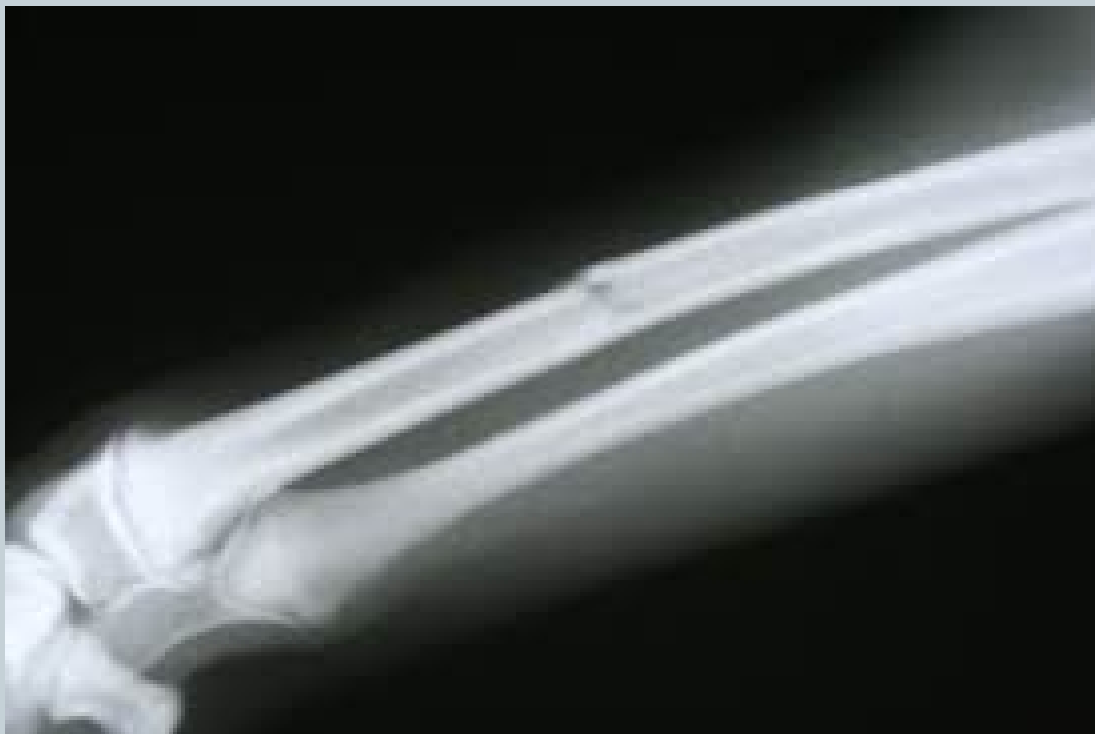/ impressiva



Fractura incuneata

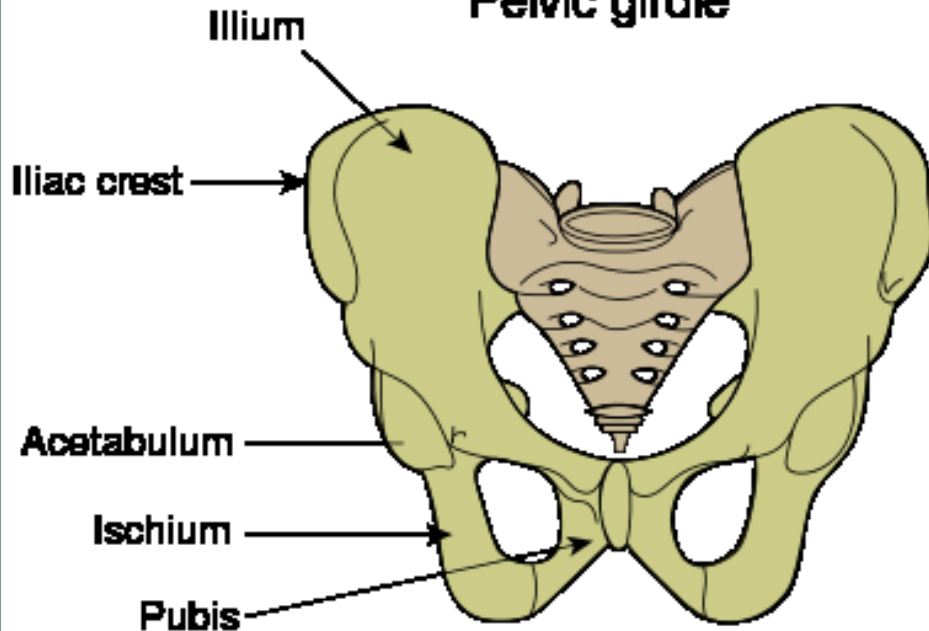


Infractio = f. partialis = f. incompleta

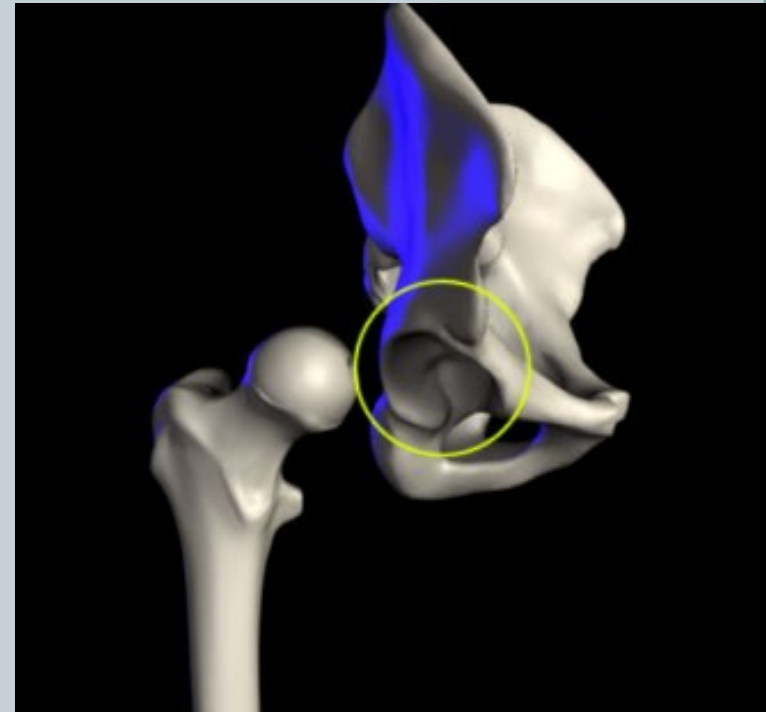


Fractura
Incompleta

Pelvic girdle

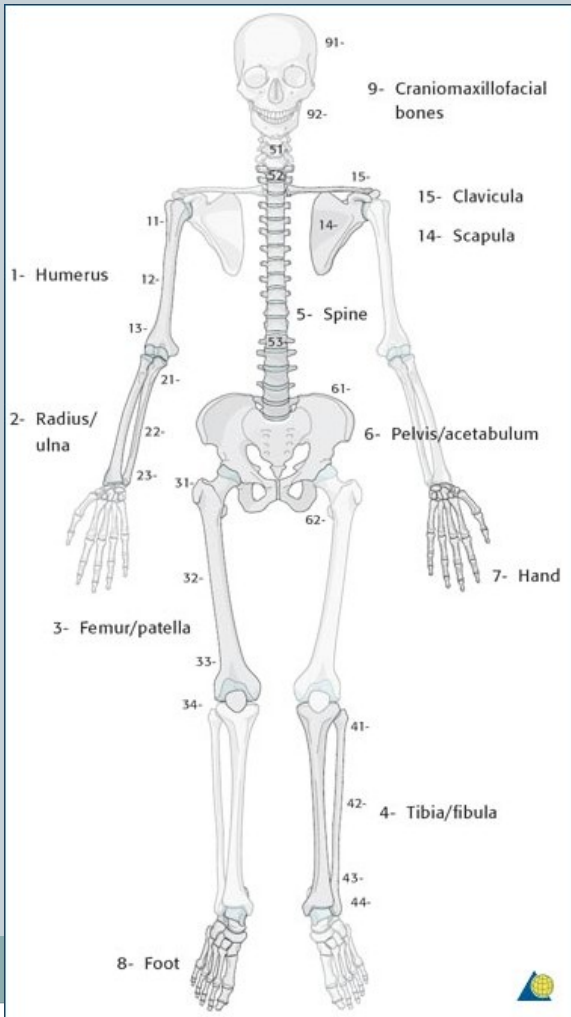




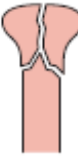
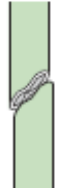
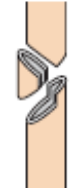


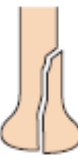

The **acetabulum** (cotyloid cavity) is a concave surface of the pelvis. The head of the femur meets with the pelvis at the acetabulum, forming the hip joint.



AO Classification of fractures

S 4220 Fractura colli chirurgici humeri l. dx. comminutiva AO 11-C3

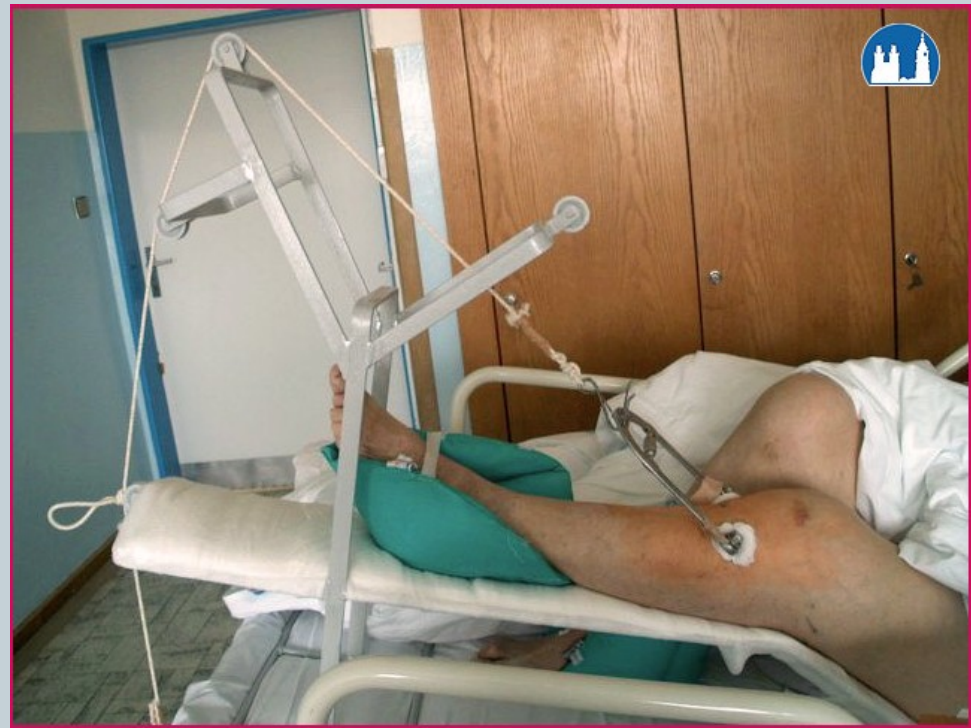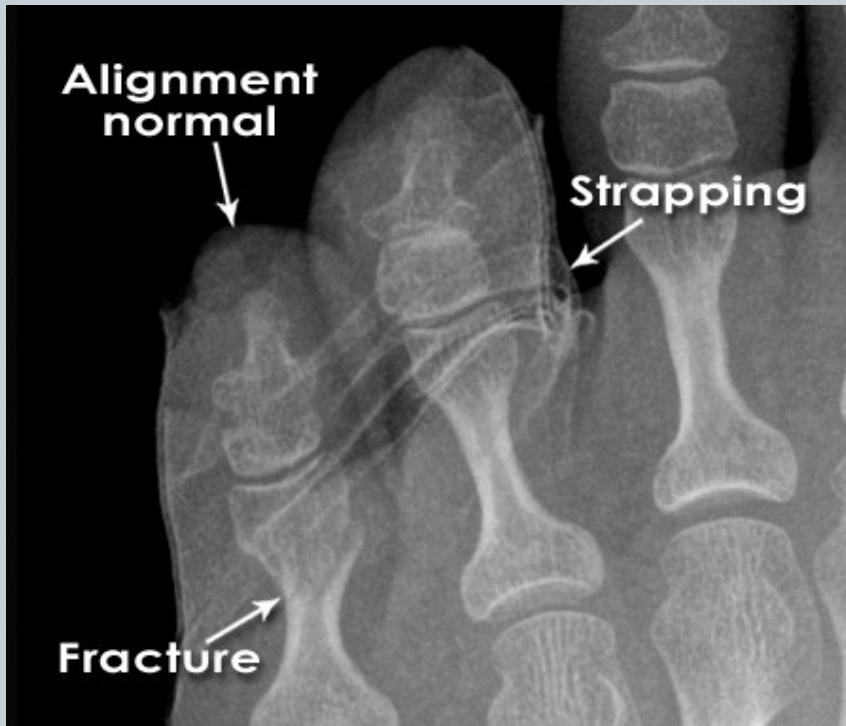


	A	B	C
1 Proximal	 <p>Extraarticular</p> <p>No involvement of displaced fractures extending into the articular surface</p>	 <p>Partial articular</p> <p>Part of the articular component is involved, leaving the other part attached to the meta-/diaphysis</p>	 <p>Complete articular</p> <p>Articular surface involved, metaphyseal fracture completely separates articular component from the diaphysis</p>
2 Diaphyseal	 <p>Simple</p> <p>One fracture line, cortical contact between fragments exceeds 90% after reduction</p>	 <p>Wedge</p> <p>Three or more fragments, main fragments have contact after reduction</p>	 <p>Complex</p> <p>Three or more fragments, main fragments have no contact after reduction</p>
3 Distal	 <p>Extraarticular</p> <p>No involvement of displaced fractures extending into the articular</p>	 <p>Partial articular</p> <p>Part of the articular component is involved, leaving the other part</p>	 <p>Complete articular</p> <p>Articular surface involved, metaphyseal fracture completely</p>

Fracture Healing:

1: REPOSITIO = REDUCTIO fragmentorum

CLOSED (short /long term)

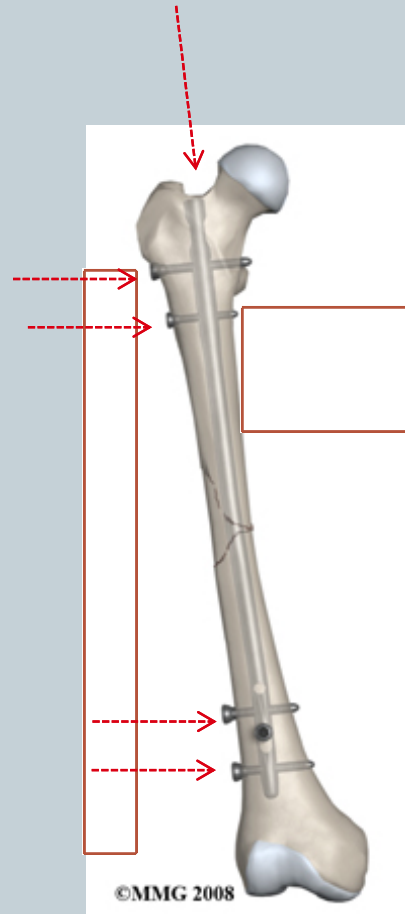
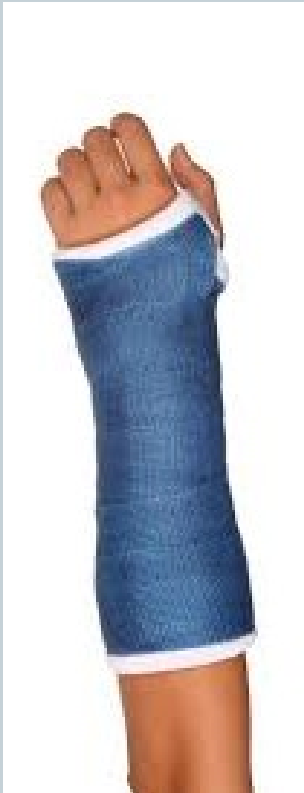

Fracture Healing:

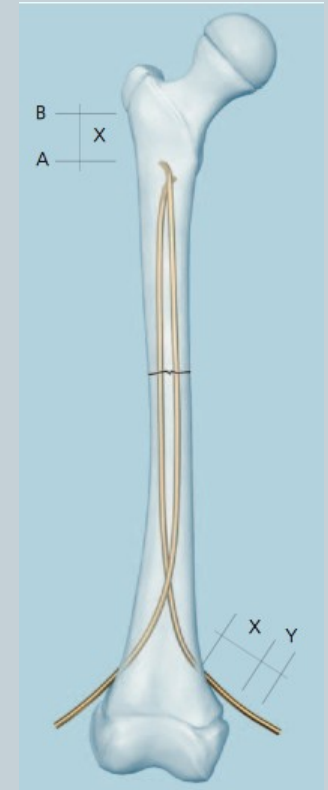
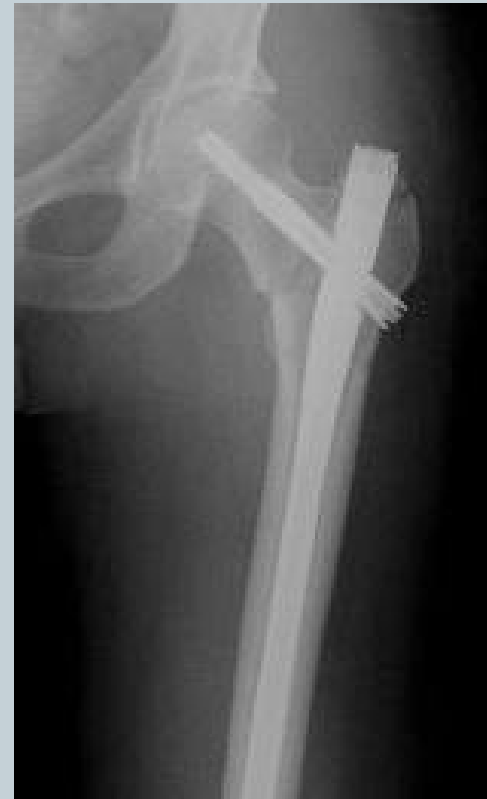2: FIXATIO = STABILISATIO fragmentorum



PLASTER CAST



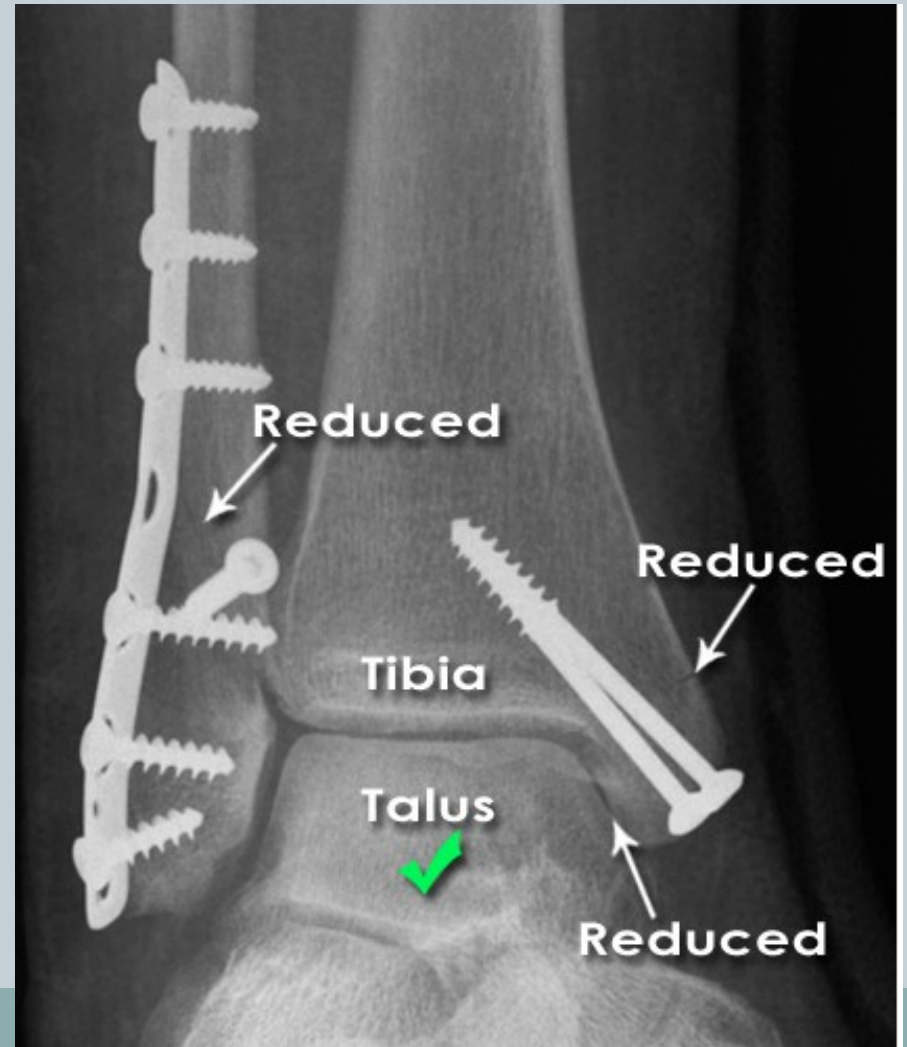

INTERNAL FIXATION



Fracture Healing:

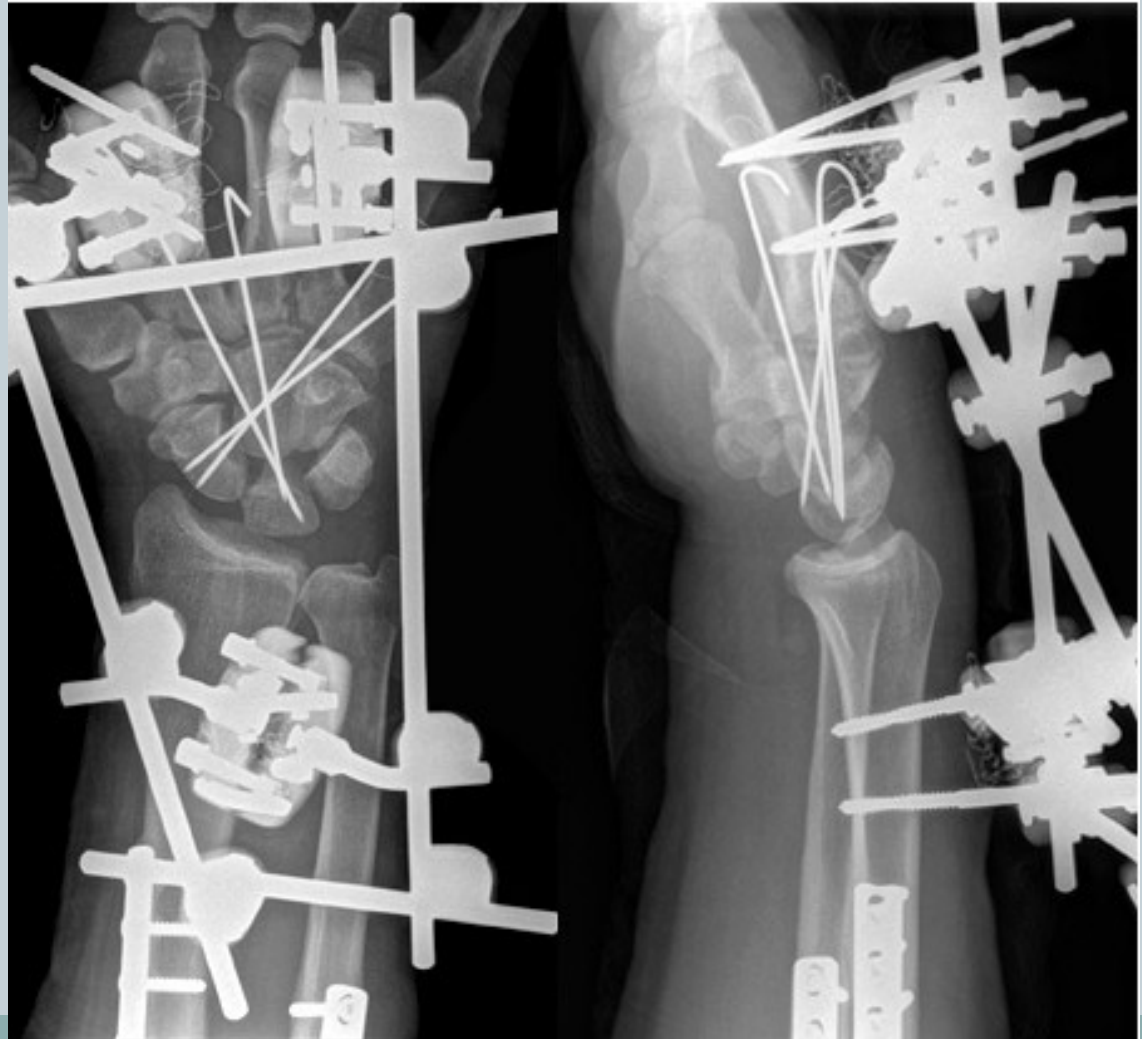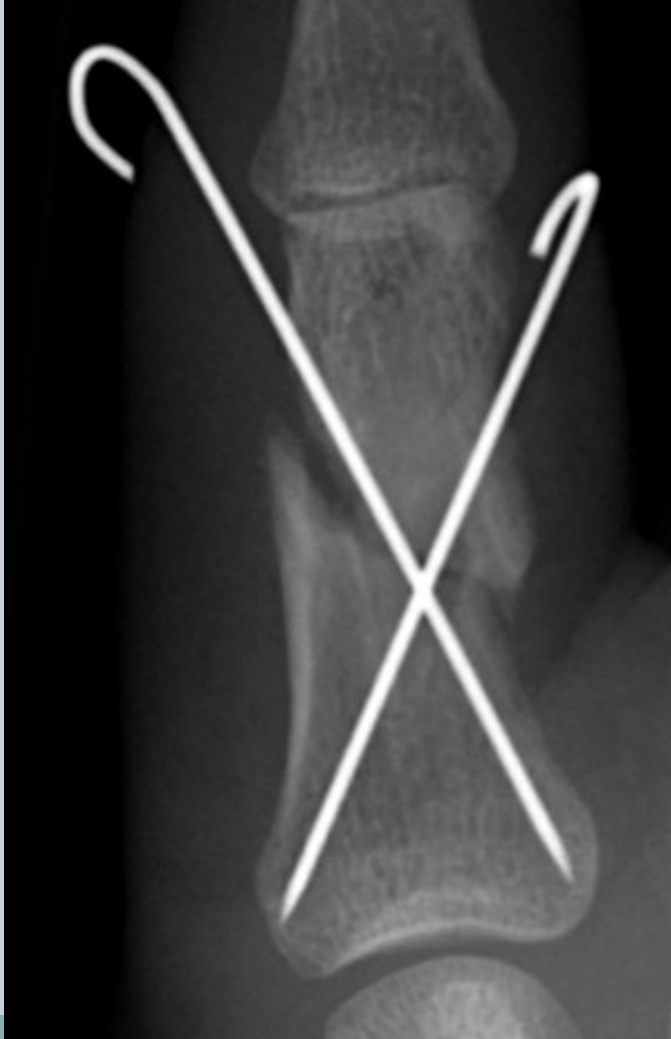2: FIXATIO = STABILISATIO fragmentorum

INTERNAL FIXATION

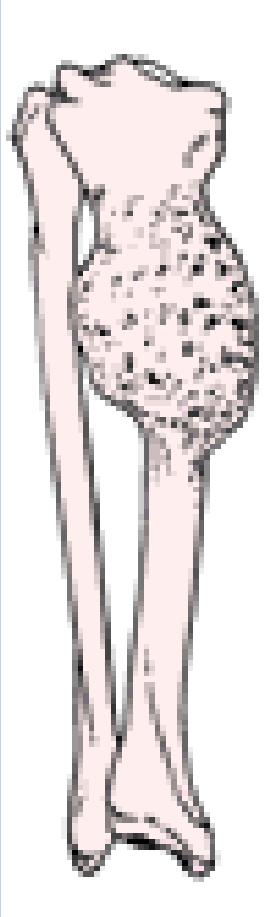


Fracture Healing:


2: FIXATIO = STABILISATIO fragmentorum




Name the type of fracture



A



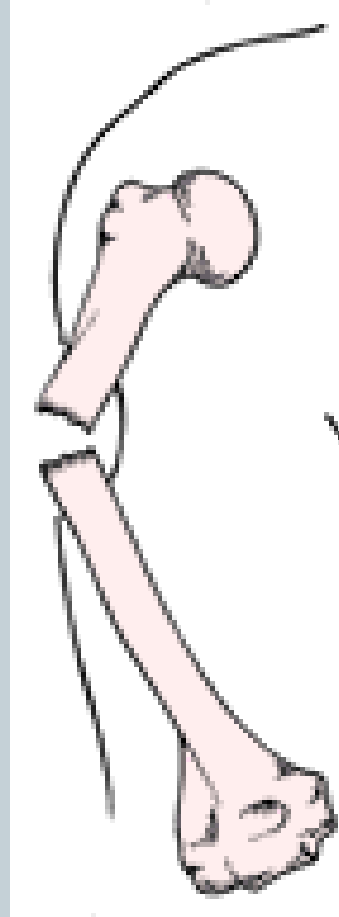B



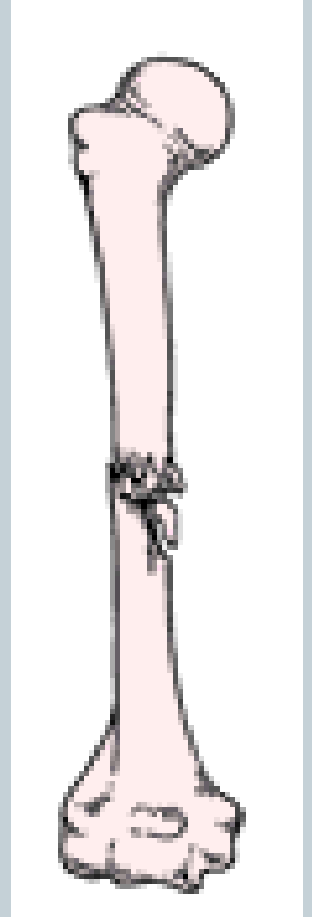
C



D



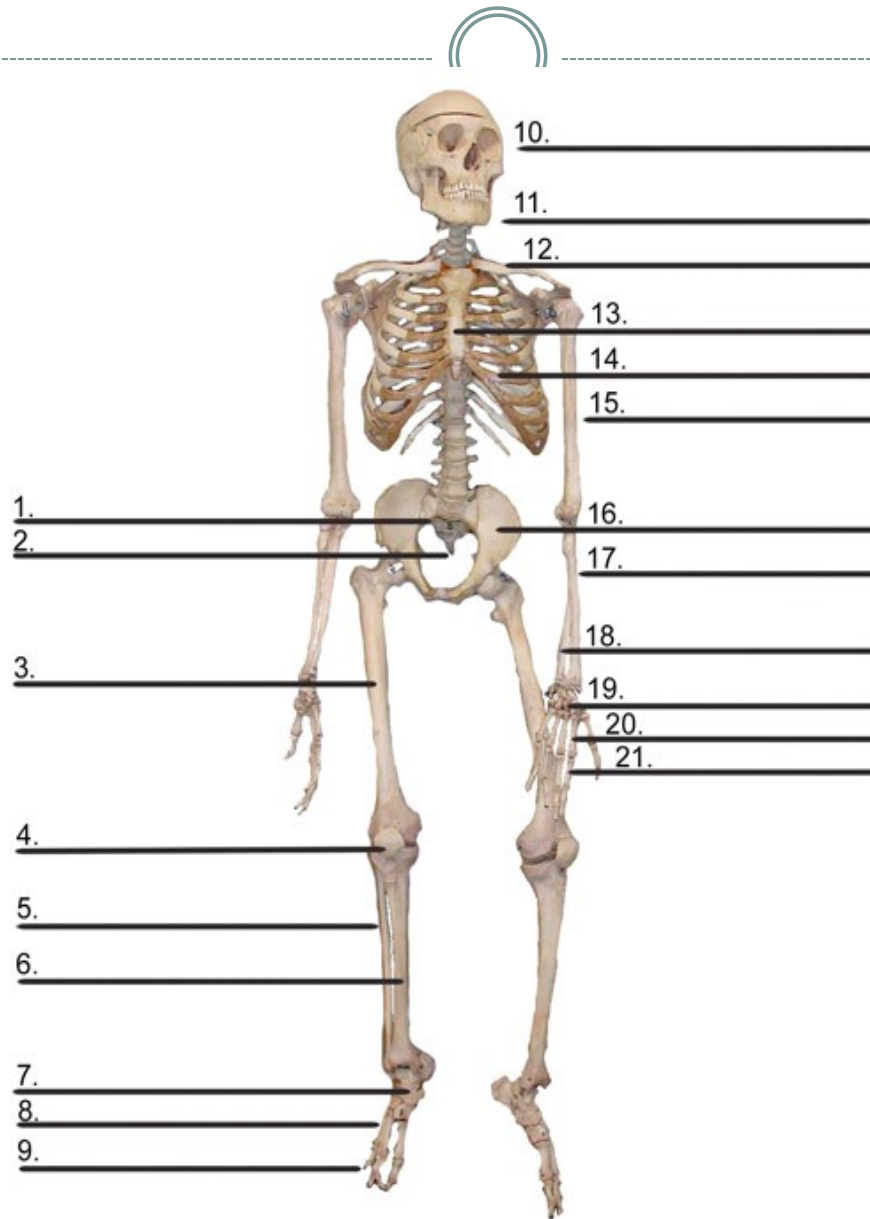
E



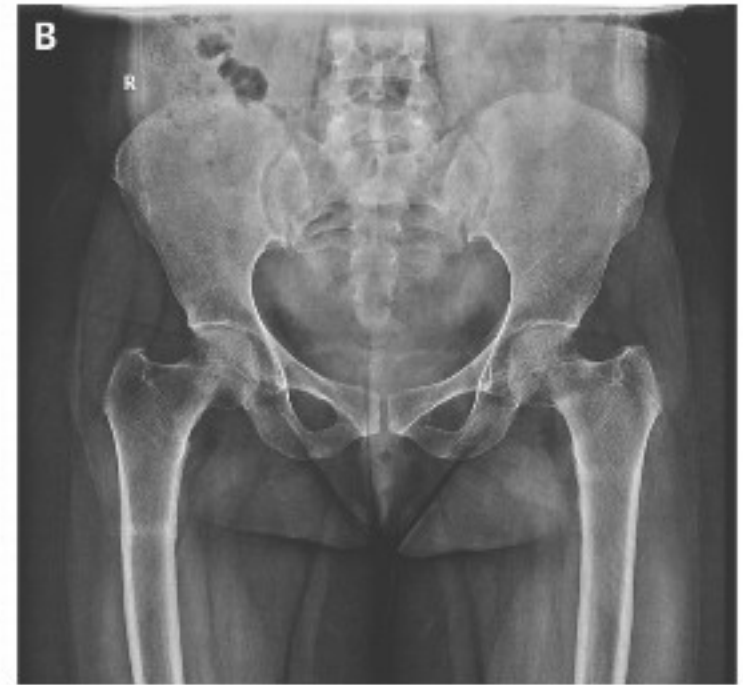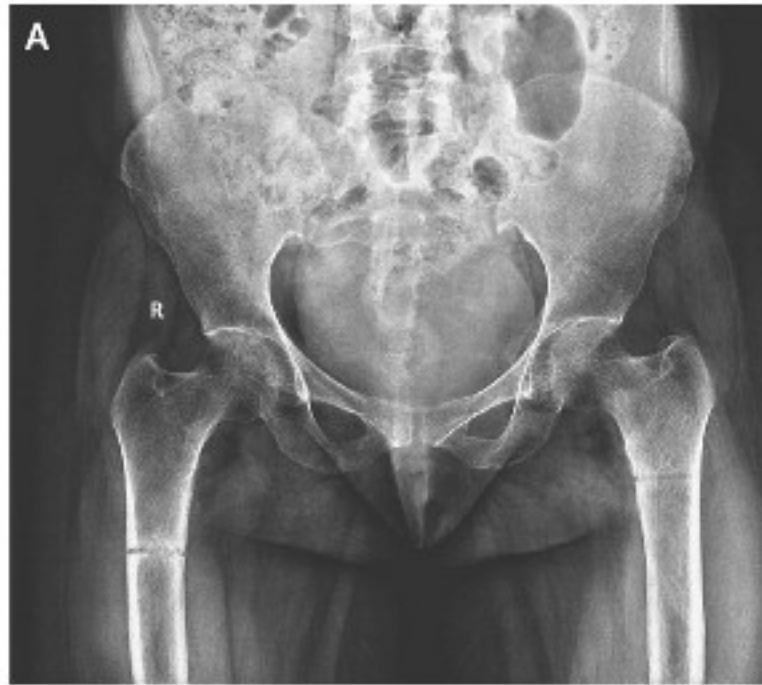F

A) Name different bones of the human body

B) Write down different types of fractures of named bones

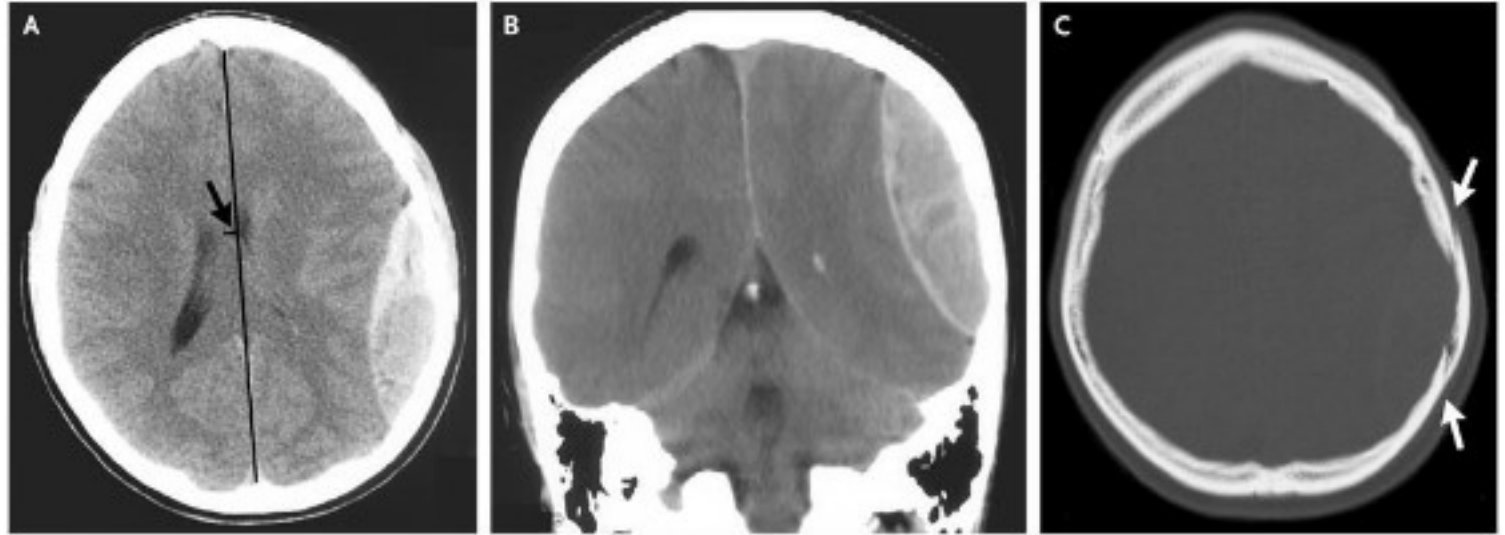


1



A 45-year-old woman presented with a 3-month history of generalized body pains nonresponsive to analgesic agents. Along with low back pain, she had progressive difficulty in getting up from sitting and supine positions and in walking. There was no history of trauma or any medication intake. She is an orthodox believer who wears a black veil outdoors and is completely covered, with little exposure to the sun. An anteroposterior radiograph of the pelvis showed an *undisplaced transverse fracture of the shaft of both femurs*. The patient was treated with therapeutic doses of calcium and vitamin D supplements.

2



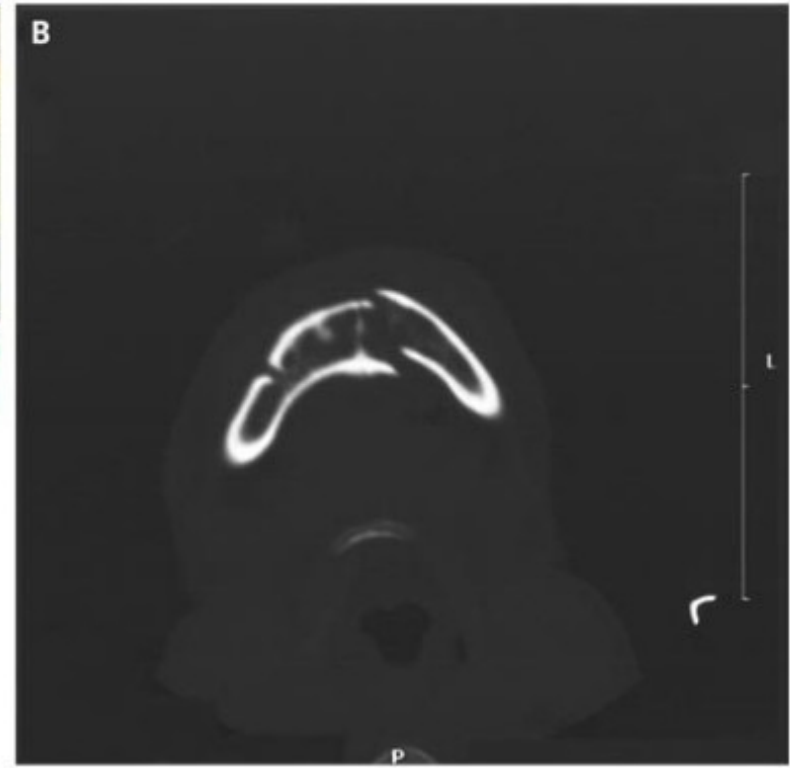
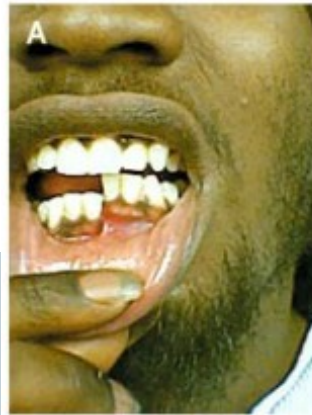An 18-year-old slightly intoxicated man was assaulted with a glass bottle on the left parietal region of his head and had a 5-minute loss of consciousness. Two hours after the injury he was presented to a local emergency with severe headache, nausea, and repeated vomiting. Computed tomography of the head revealed a 2.5-cm *epidural hematoma in the left parietal region* (Panels A and B) *underlying a linear nondisplaced skull fracture* (Panel C, arrows).

3

A 21-year-old man presented after being struck with a gun on his right lower jaw.

Examination revealed displacement of the

left half of his mandible with malocclusion on biting (Panel A). Computed tomography showed a **fracture of the left mandible and a fracture of the right mandibular body and angle** (Panel B). Given the U shape of the mandible, it is common for contralateral fractures to result from major injury. Intravenous analgesics and antibiotics were given; the patient underwent *open reduction with internal fixation of his fractures*.



Literature



- Mazánek, J.: Traumatologie orofaciální oblasti. Praha : Grada, p. 24
- <http://radiologymasterclass.co.uk>
- <http://anthropology.si.edu>
- <http://nejm.org> (The New England Journal of Medicine)