

INFORMATIONS FOR THE DISSECTION WEEK

10.12.- 15.12.2017 (+ exam Monday 18.12., Tuesday 19.12. during the given times, will be posted on the dissection)

You will be divided in groups according to the schedule and you will attend it in following times (one term of them) according to the groups you belongs.

8.00-12.00 a.m. groups 30, 31, 32, 33, 34

1.00-5.00 p.m. groups 35, 36, 37, 38, 39

Breaks: 9.45-10.15

2.45-3.15

At the end of the course students should be able to:

1. Describe all components (bones, joints, **muscles, vessels and nerves**) of the upper and lower limb and back
2. Relate features of limb and back with respect to adjacent structures
3. Review arrangement of layers from the superficial to deep ones in all regions of the upper and lower limbs and back
4. Create the anatomical prosection of some studied region using specified dissecting procedures
5. Distinguish abnormalities of the prosections.

What you can study from? What you will need to prepare.

Recommended literature:

DUBOVÝ, Petr. Instructions for anatomical dissection course. Masarykova univerzita, Brno. ISBN: 978-80-210-4229-2.

Atlas of anatomy : Latin nomenclature. Edited by Anne M. Gilroy - Brian R. MacPherson - Lawrence M. Ross - Michael Schu. New York: Thieme Medical, 2009. xv, 656 p. ISBN 978-1-60406-099-7. (or any other atlas you have)

DRAKE, Richard L. *Gray's anatomy for students.* ISBN 9780443069529.

Additional source of study:

Stingl, J., Grim, M., Druga, R. : *Regional anatomy, Galén*, ISBN 978-80-7262-879-7.)

Preliminary dissection schedule:

1st day:

Back - skin incisions, subcutis - nerves, vessels;

Upper limb - dissection of the deltoid and scapular regions, skin incisions in the arm;

Lower limb - dissection of the gluteal region

2nd day:

Back - dissection of the trapezius, latissimus dorsi;

Upper limb - completion of the dissection of the arm;

Lower limb - dissection of the anterior femoral region

3rd day:

Back - dissection of the rhomboids, levator scapulae, erector spinae, splenius, semispinalis, serrati

Upper limb - dissection of the forearm - skin, subcutis, superficial muscles;

Lower limb - dissection of the posterior femoral and crural regions

4th day:

Upper limb - completion of the dissection of the forearm, palm, dorsum of the hand;

Lower limb - completion of the dissection of the crus, dorsum of foot, sole

Back - dissection of the deep nuchal muscles, suboccipital trigone, multifidi;

5th day: completion of dissection of all regions, study on the material

Completion of the course is assessed by the course-unit credit. A precondition for obtaining the course-unit credit is 100% attendance and demonstration of the basic knowledge during an examination at the close of the dissection course.

The results of the examination will be included in the results of the practical part of the final examination in Anatomy. A minimum of 6 out of 10 possible points (grade E) in the examination at the end of the course is required for fulfillment. For unsuccessful students a resit date will be offered (involved in the final exam date).

WHAT YOU WILL NEED?

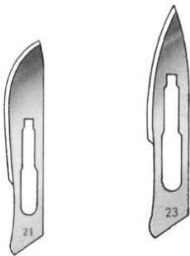
- Lab coat
- Plastic shoe covers
- Forceps 14,5 or 16 cm long (anatomical, without hooks)



- Scalpel handle No.4



- Scalpel blades no. 23 or 21



Books:

DUBOVÝ, Petr. Instructions for anatomical dissection course. Masarykova univerzita, Brno. ISBN: 978-80-210-4229-2. (each working group will have it)

Atlas

KNOWLEDGES!!!!

STUDY FOR THE FIRST DISSECTION

Learn the muscles (**back, upper and lower limb**)! (origin, insertion, function, innervation, groups)

Knowledge of the nerves (plexus brachialis, sacralis, partly lumbalis), **vessels and topography of the limbs** is obvious!

You should be able to identify the main structures on the specimen and to explain (description, borders, content, layers) following terms and regions:

REGIONAL ANATOMY OF THE LIMBS

UPPER LIMB

REGIO SCAPULARIS

- Borders
- Layers
- Content
- Fossa supraspinata, infraspinata
- Passage of the nerves and vessels around the lig. scapulae
- ***anastomosis of a. suprascapularis and a. circumflexa scapulae***

REGIO INFRACLAVICULARIS

- Borders
- Layers
- Content
- ***trigonum deltoideopectorale (sulcus deltoideopectoralis, fossa deltoideopectorale Mohrenheimi)***

REGIO DELTOIDEA

- Borders
- Layers

- Content
- subcutaneous: nn. supraclaviculares; n. cutaneus brachii lat. sup.
Subcutaneous veins
- Fascia deltoidea
- M. deltoideus. Vasa circumflexa humeri post. N. axillaris
- Foramen humerotricipitale

REGIO AXILLARIS

- Borders
- Layers
- Content
- Foramen humerotricipitale (content - vasa circumflexa humeri post., n. axillaris, borders) x foramen omotricipitale (content - a. circumflexa scapulae, borders)

ROTATOR CUFF

REGIO BRACHII

Regio brachii ant.

- borders
- subcutaneous: n. cutaneus brachii lat. inf.; n. cutaneus brachii med. V. cephalica et v. basilica
- Fascia brachii (sulcus bicipitalis medialis et lateralis)
- M. biceps brachii; m. brachialis; m. coracobrachialis.
- Vasa brachialia.
- N. musculocutaneus; n. ulnaris; n. medianus; n. cutaneus antebrachii med.

Regio brachii post.

- borders
- subcutaneous: n. cutaneus brachii post.
- v. cephalica et v. basilica
- Fascia brachii
- M. triceps. Vasa profunda brachii. N. radialis

REGIO CUBITI ET ANTEBRACHII

Regio cubiti et antebrachii ant.

- borders
- subcutaneous: n. cutaneus antebrachii med.; n. cutaneus antebrachii lat. V. cephalica et v. basilica. Nll. cubitales superficiales
- Fascia antebrachii
- Retinaculum flexorum, canalis carpi
- Anterior group of muscles: m. pronator teres; m. flexor carpi radialis et ulnaris; m. palmaris longus; m. flexor digitorum superficialis; m. flexor digitorum profundus; m. flexor pollicis longus; m. pronator quadratus. Lateral group of muscles: m. brachioradialis; m. extensor carpi radialis longus et brevis; m. supinator.
- Vasa ulnaria; vasa radialis; vasa interossea ant. N. ulnaris; n. radialis; n. medianus (n. interosseus ant.). Nll. cubitales prof.

Regio cubiti et antebrachii post.

- borders
- subcutaneous: n. cutaneus antebrachii post. Tributaries of v. cephalica et v. basilica
- Fascia antebrachii
- Retinaculum extensorum
- M. extensor digitorum; m. extensor digiti minimi; m. extensor carpi ulnaris; m. abductor pollicis longus; m. extensor pollicis longus et brevis; m. extensor indicis.
- Vasa interossea post. N. ulnaris; n. radialis (n. interosseus post.)

REGIO MANUS

Dorsum manus

- borders
- subcutaneous: nn. digitales dorsales communes (n. radialis, n. ulnaris). Tributaries of v. cephalica et v. basilica
- Fascia dorsalis manus superficialis
- Rete digitale dorsale. Tendons of extensors
- Fascia dorsalis manus prof.

- Mm. interossei dorsales

Palma manus

- borders
- subcutaneous: nn. digitales palmares (n. medianus, n. ulnaris). Arcus palmaris superficialis
- Fascia palmaris manus superficialis (aponeurosis palmaris)
- Muscles of the thenar: m. abductor pollicis brevis; m. flexor pollicis brevis; m. opponens pollicis; m. adductor pollicis.
- Muscles of the hypothenar: m. abductor digiti minimi; m. flexor digiti minimi brevis; m. opponens digiti minimi.
- Tendons of long flexors of the fingers
- Arcus palmaris profundus. N. ulnaris (r. profundus)
- Fascia palmaris manus prof.
- Mm. interossei palmares

Foveola radialis (anatomical snuff box)

DIGITI

- Borders
- Layers
- Content

LOWER LIMB

REGIO GLUTEA

- borders
- subcutaneous: nn. clunium sup., medii et inf. Subcutaneous veins
- Fascia glutea
- M. gluteus maximus, medius et minimus; m. piriformis; m. obturatorius internus; mm. gemelli; m. quadratus femoris.
- Vasa glutea sup. et inf.; vasa pudenda interna. Nn. glutei sup. et inf.; n. ischiadicus; n. cutaneus femoris post.; n. pudendus
- **Foramen suprapiriforme et infrapiriforme**

REGIO FEMORIS

Regio femoris anterior

- Borders
- subcutaneous: nn. cutanei femoris ant.; rr. cutanei z n. obturatorius; n. saphenus. V. saphena magna (v. saphena accessoria). Nll. femorales superficiales
- Fascia lata (hiatus saphenus)
- Anterior group of muscles: m. sartorius; m. quadriceps femoris.
- Medial group of muscles: m. gracilis; m. adductor longus, magnus, brevis; m. pectineus.
- Vasa femoralia (vasa profunda femoris, vasa circumflexa femoris med. et lat.); vasa obturatoria.
- N. femoralis; n. obturatorius. Nll. femorales prof.
- **Trigonum femorale, fossa iliopectinea**
- **Canalis adductorius, hiatus adductorius**

R. femoris posterior

- borders
- subcutaneous: n. cutaneus femoris post. Tributaries of v. saphena magna, v. femoropoplitea
- Fascia lata
- M. semimembranosus; m. semitendinosus; m. biceps femoris.
- Vasa profunda femoris (rr. perforantes). N. ischiadicus

REGIO GENUS POST. (FOSSA POPLITEA)

- borders
- subcutaneous: n. cutaneus femoris post. N. suralis. V. saphena parva. Nll. poplitei superficiales
- Fascia lata
- M. popliteus; m. plantaris. Vasa poplitea. N. ischiadicus; n. tibialis; n. fibularis communis. Nll. poplitei prof.

REGIO CRURIS

Regio cruris anterior

- borders
- subcutaneous: rr. cutanei cruris med. (n. saphenus); rr. cutanei surae lat. V. saphena magna
- Fascia cruris
- Anterior group of muscles: m. tibialis ant.; m. extensor hallucis longus; m. extensor digitorum longus.
- Lateral group of muscles: m. fibularis longus et brevis.
- Vasa tibialia ant. N. fibularis superficialis et profundus

Regio cruris posterior

- borders
- subcutaneous: n. cutaneus surale lat.; rr. cutanei cruris med. (n. saphenus); n. suralis. V. saphena parva
- Fascia cruris
- M. gastrocnemius; m. soleus; m. tibialis post.; m. flexor digitorum longus; m. flexor hallucis longus.
- Vasa tibialia, vasa fibularia. N. tibialis

REGIO MALLEOLARIS ET RETROMALLEOLARIS MEDIALIS ET LATERALIS

- Borders
- Layers
- Retinaculum flexorum et extensorum
- Structures

REGIO PEDIS

Dorsum pedis

- borders
- subcutaneous: n. cutaneus dorsalis medialis et intermedius (n. fibularis superficialis); n. cutaneus dorsalis lat. (n. suralis); n. fibularis prof. (for the 1. interdigital slot). Rete venosum dorsale pedis
- Fascia dorsalis pedis superficialis
- M. extensor hallucis brevis; m. extensor digitorum brevis. Tendons of long extensors.
- Vasa dorsalia pedis. N. fibularis prof.
- Fascia dorsalis pedis profunda
- Mm. interossei dorsales

Planta pedis

- borders
- subcutaneous: nn. plantares med. et lat. (rr. cutanei). Rete venosum plantare
- Fascia plantaris pedis superficialis
- Aponeurosis plantae
- Muscles of the thenar: m. abductor hallucis; m. flexor hallucis brevis; m. adductor hallucis; m. flexor digitorum brevis; m. abductor digiti minimi. Muscles of the hypothenar: m. abductor digiti minimi, m. flexor digiti minimi, m. opponens digiti minimi. Tendons of long flexors.
- Vasa plantaria medialis et lateralis. N. plantaris medialis et lateralis
- Fascia plantaris pedis profunda
- Mm. interossei plantares

DIGITI

- Borders
- Layers
- Content

REGIONS OF THE BACK

BACK (DORSUM)

Borders, distribution, content, orientation lines,

Regio colli posterior - borders, layers, content, *trigonum suboccipitale*

Regio vertebralis - borders, layers, content

Regio sacralis - borders, layers, content

Regio lumbalis - borders, layers, content

trigonum lumbale Petiti, Grynfelti, tetragon Krausei

MM. DORSI

(in muscles you need to know origin, insertion, innervation, function)

A) Extrinsic muscles (Heterochthonous muscles)

I. Spinohumeral muscles

M. trapezius (+ a. supply)

M. latissimus dorsi (+ a. supply)

M. levator scapulae

M. rhomboideus major et minor

II. Spinocostal muscles

M. serratus posterior superior et inferior

B) Intrinsic muscles of the back (autochthonous muscles) (mm. dorsi proprii)

Spinotransversales (m. splenius capitis et cervicis)

Sacrospinales (m. erector spinae - m. longissimus dorsi et cervicis, m. longissimus capitis, m. iliocostalis, m. spinalis thoracis)

Transversospinales (m. semispinalis, mm. multifidi et rotatores)

Short muscles of the back

Mm. interspinales cervicis

Mm. intertransversales posteriores cervicis

Mm. nuchae profundi (m. rectus capitis posterior major et minor, m. obliquus capitis superior et inferior) - Trigonum suboccipitale

FASCIAE DORSI

Aponeurosis m. erectoris (thoracolumbar fascia)