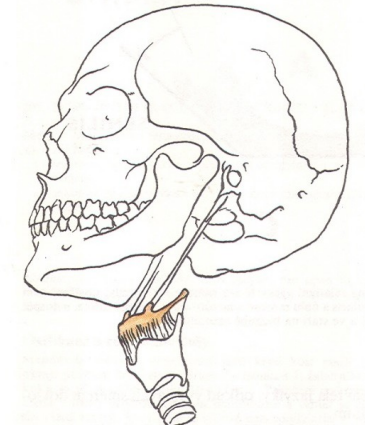
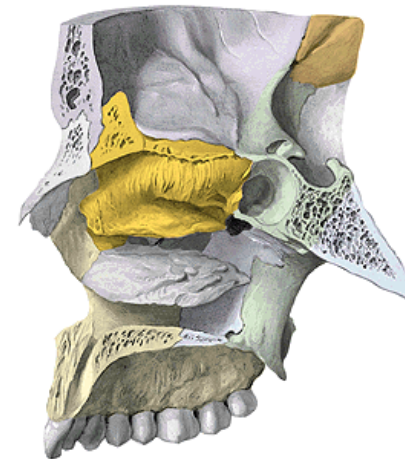
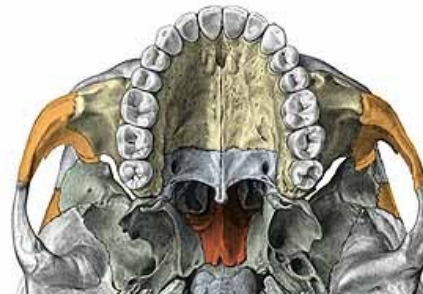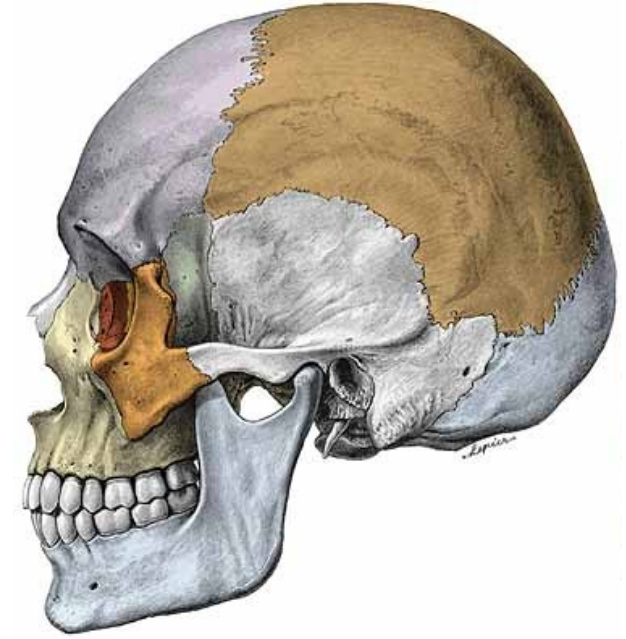
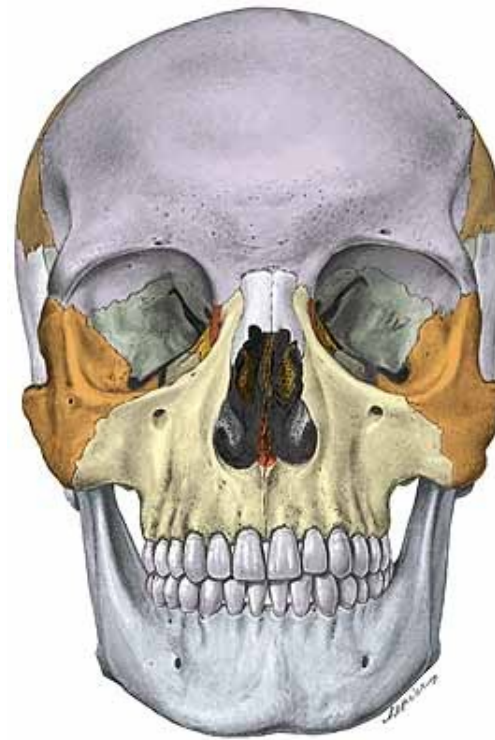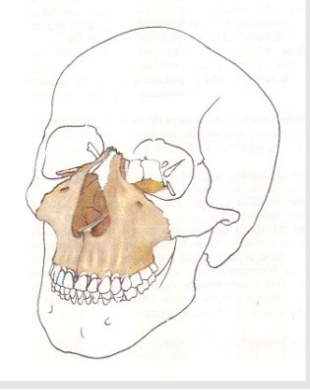


Splanchnocranium

(viscerocranium)

1. Maxilla
2. Os nasale (*Nasal bone*)
3. Os lacrimale (*Lacrimal bone*)
4. Os zygomaticum (*Zygomatic bone*)
5. Vomer
6. Os palatinum (*Palatine bone*)
8. Concha nasalis inferior (*Inferior nasal concha – turbinate*)
9. Mandibula (*mandible*)
10. Os hyoideum (*Hyoid bone*)

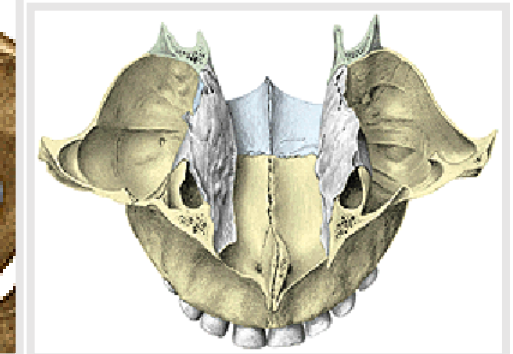
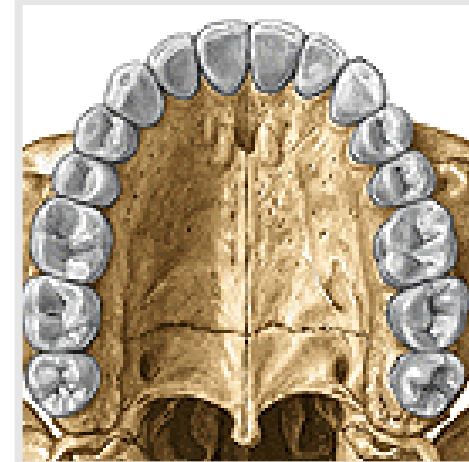
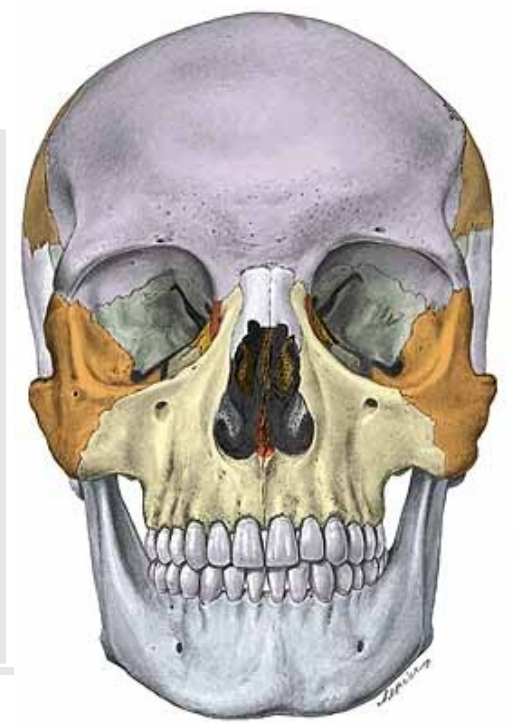
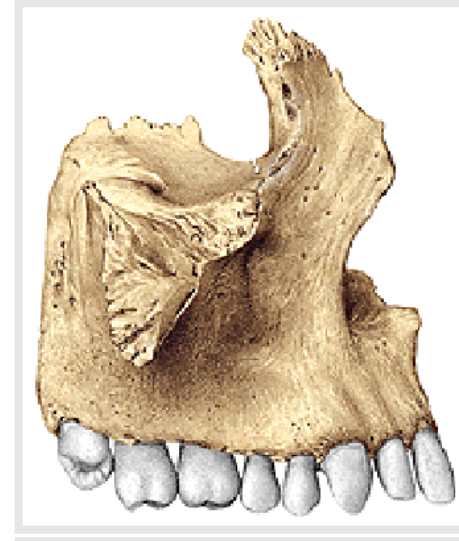


Maxilla (dextra et sinistra)

1. **Corpus maxillae (Body of maxilla)** with *sinus maxillaris (maxillary sinus)*
 - a) **Facies orbitalis corporis maxillae (orbital surface)**
 - b) **Facies anterior (anterior surface)**
 - c) **Facies nasalis (nasal surface)**
 - d) **Facies infratemporalis (infratemporal surface)**

2. **Processes of maxilla**
 - a) **Processus frontalis (Frontal process)**
 - b) **Processus zygomaticus (Zygomatic process)**
 - c) **Processus alveolaris (Alveolar process)**
 - d) **Processus palatinus (Palatine process)**



Ad 1. Corpus maxillae

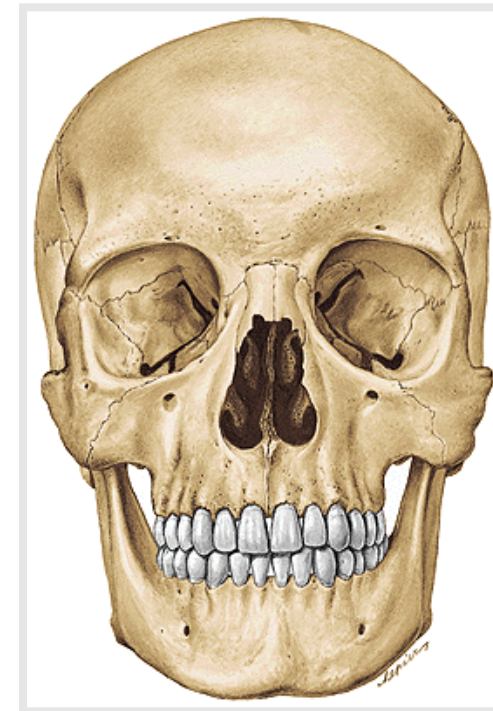
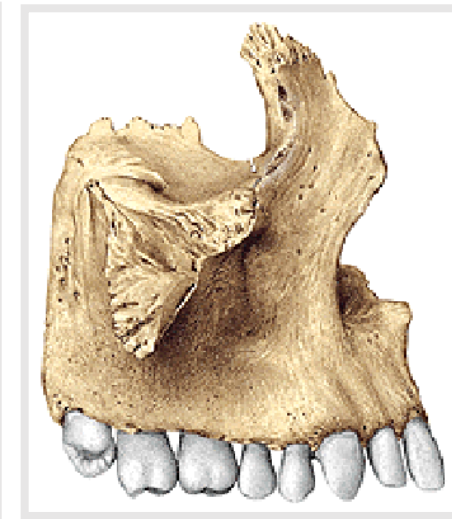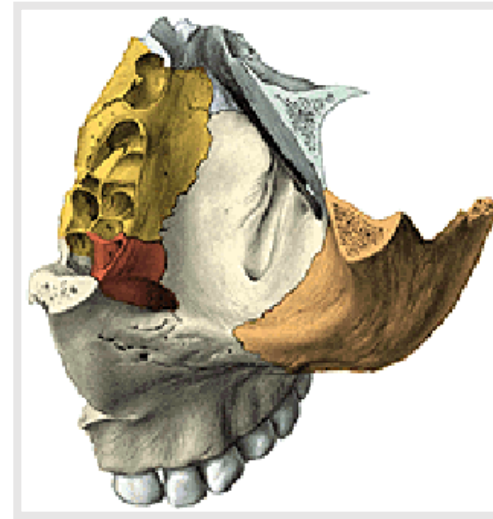
(Body of maxilla)

1a) Facies orbitalis *(Orbital surface)*

Margo infraorbitalis *(infraorbital margin)*

Sulcus infraorbitalis *(infraorbital groove)*

Canalis infraorbitalis *(infraorbital canal)*
= canal for vessels and nerves to anterior teeth



1b) **Facies anterior corporis maxillae**

(Anterior surface of maxillary body)

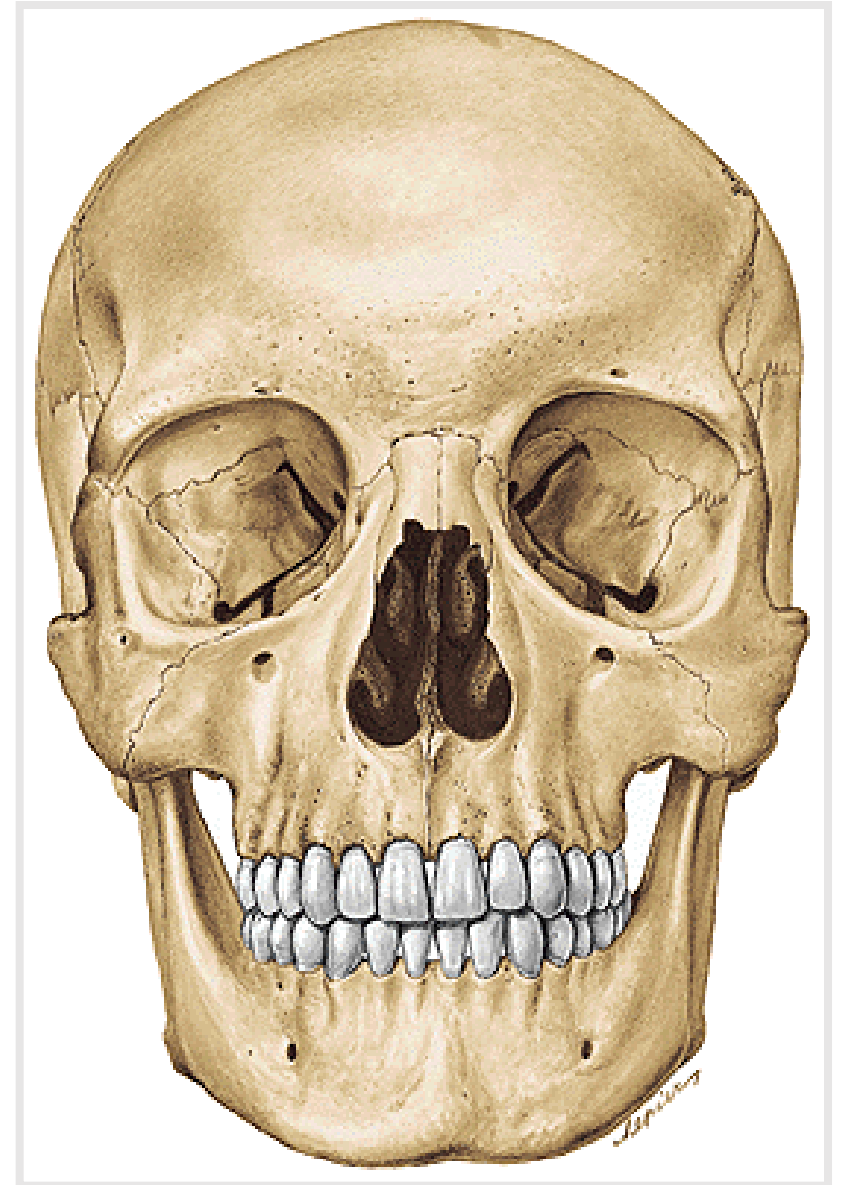
Foramen infraorbitale (*infraorbital foramen*)

Incisura nasalis (*nasal notch*) **Apertura piriformis**

Fossa canina (*canine fossa*)

Spina nasalis anterior (*anterior nasal spine*)

Crista infrazygomatica (*infrazygomatic crest*)

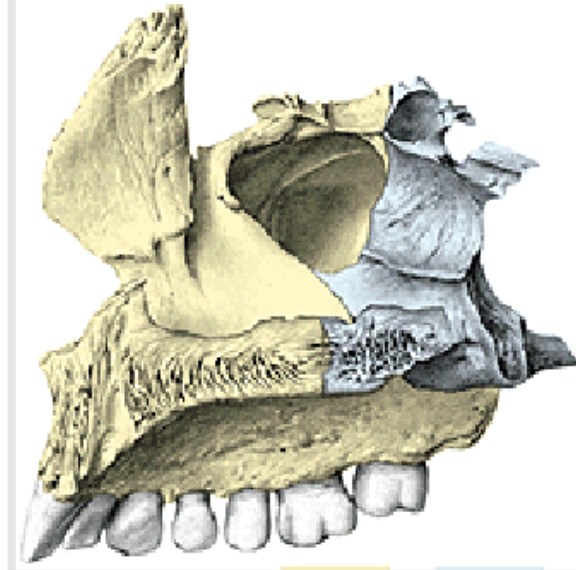


1c) **Facies nasalis corporis maxillae**

(Nasal surface of maxillar body)

hiatus sinus maxillaris *(maxillary hiatus)*

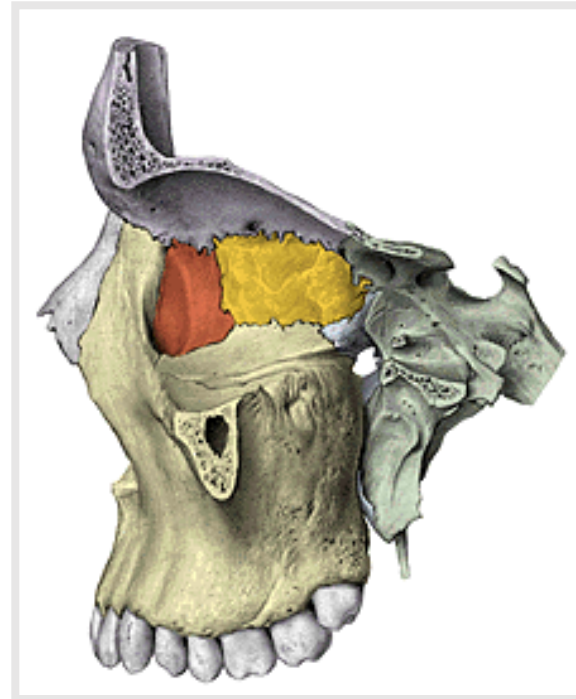
[**antrum Highmori** *(maxillary sinus)*]



1d) **Facies infratemporalis** *(Infratemporal surface of maxillar body)*

tuber maxillae *(maxillar tuberosity)*

foramina alveolaria posteriora - *posterior alveolar foramina and canals to molars*



Ad 2. Processes of maxilla

a) **Processus frontalis maxillae**

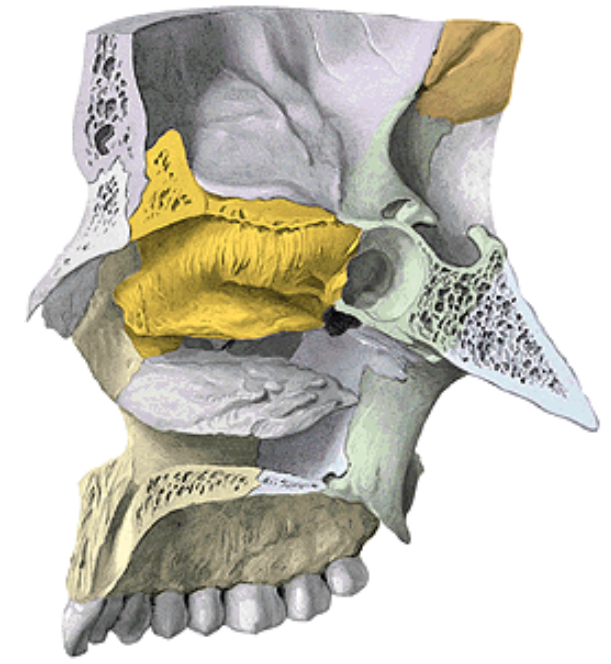
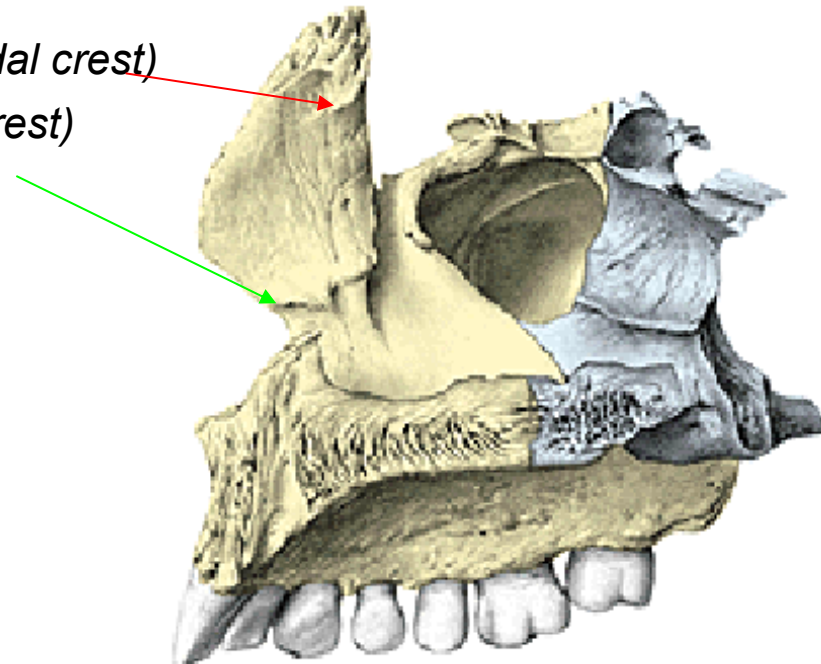
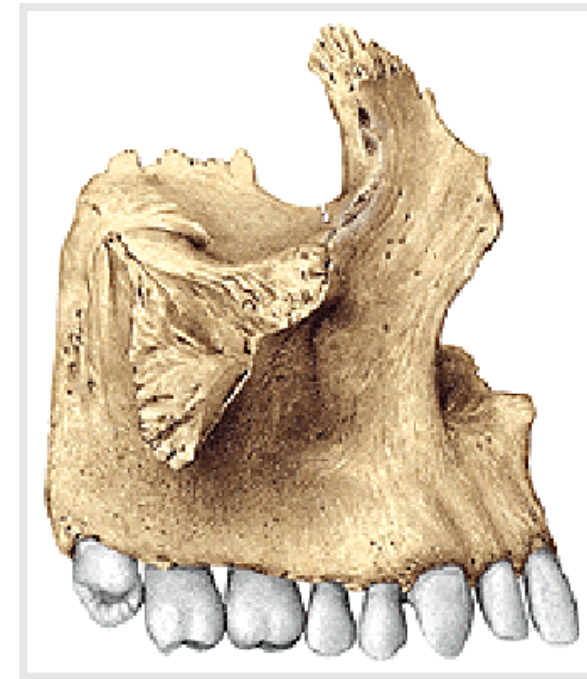(Frontal process of maxilla)

Incisura nasalis *(Nasal notch)* (**apertura piriformis**)

Crista lacrimalis anterior *(Anterior lacrimal crest)*

Crista ethmoidalis *(Ethmoidal crest)*

Crista conchalis *(Conchal crest)*



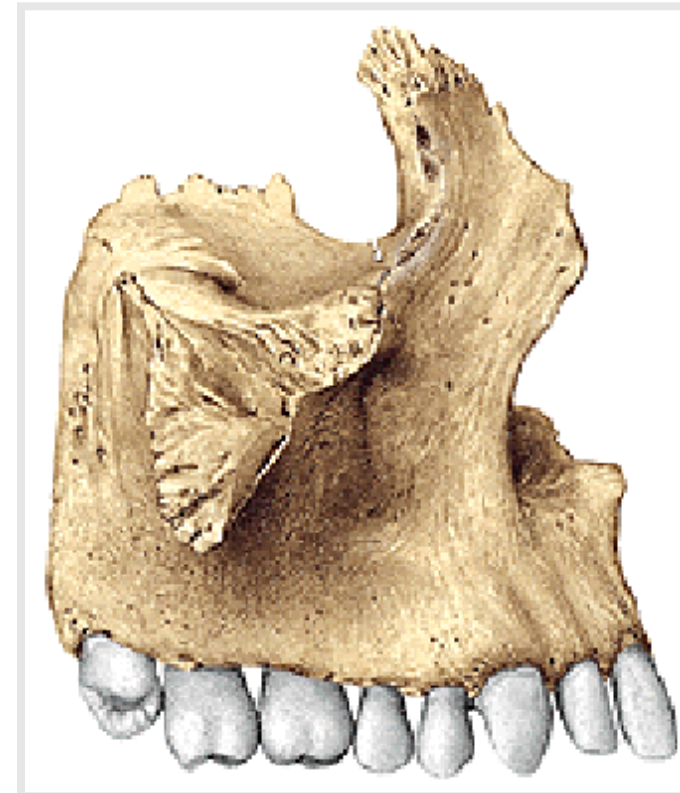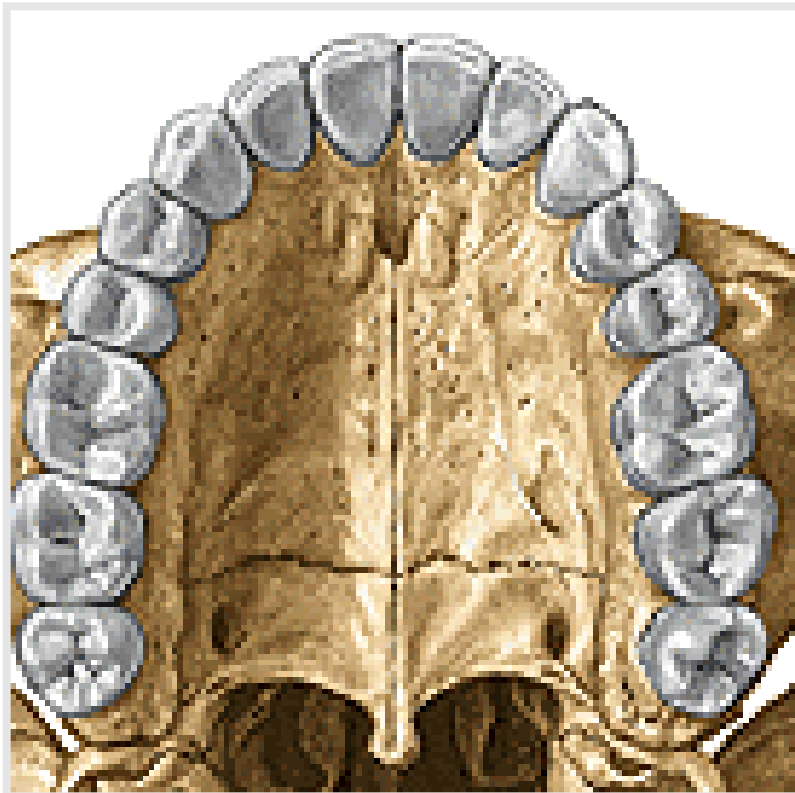
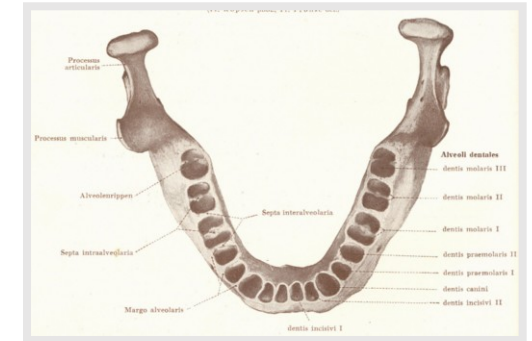
b) **Processus alveolaris** (*Alveolar process*) of maxilla

Alveoli dentales (*Dental alveoli*)

Juga alveolaria (*Alveolar juga*)

Septa interalveolaria (*Interalveolar septum*)

Septa intraalveolaria (*Intraalveolar septum*)



c) **Processus zygomaticus maxillae**

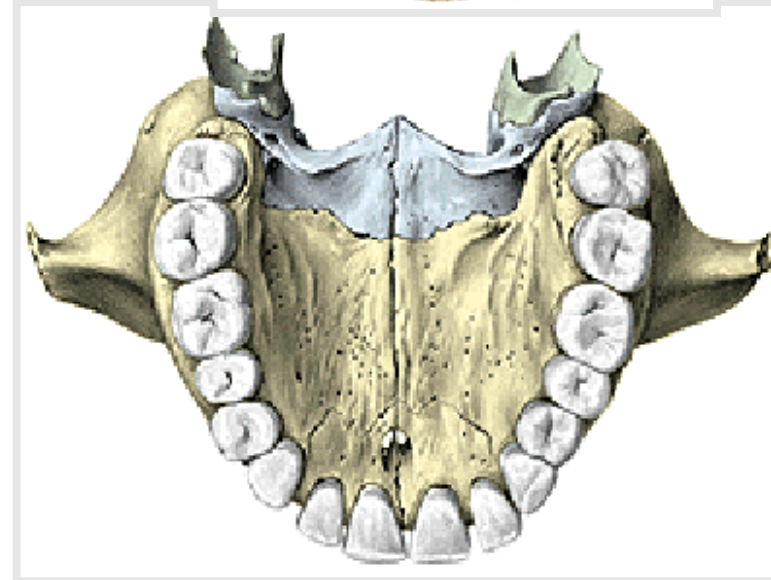
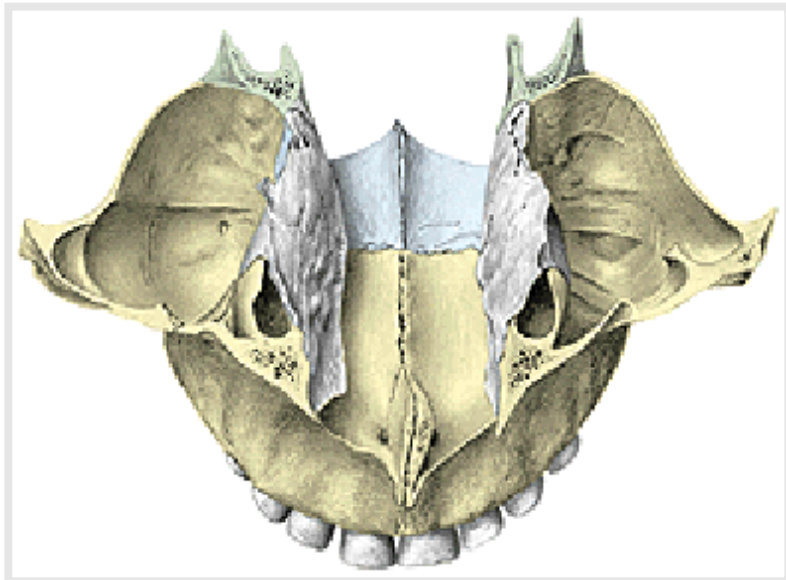
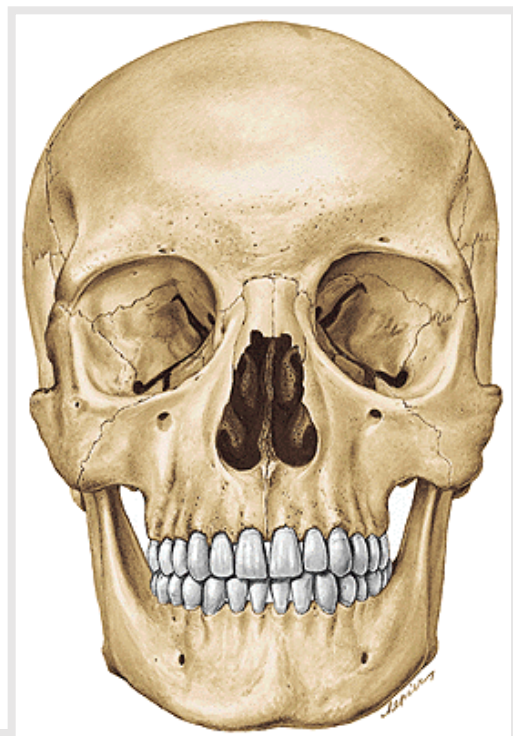
(Zygomatic process of maxilla)

d) **Processus palatinus** *(Palatine process)*

Os incisivum – praemaxilla *(Incisive bone)*

Foramen incisivum (canalis incisivus – n. nasopalatinus)

Crista nasalis *(Nasal crest)*



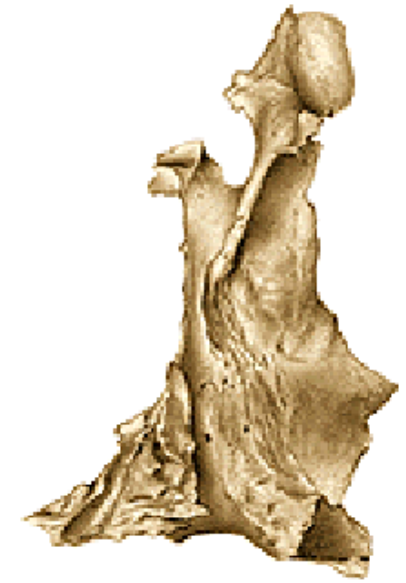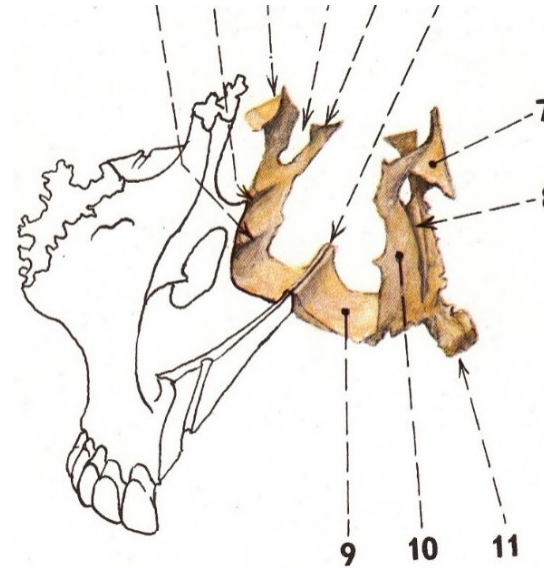
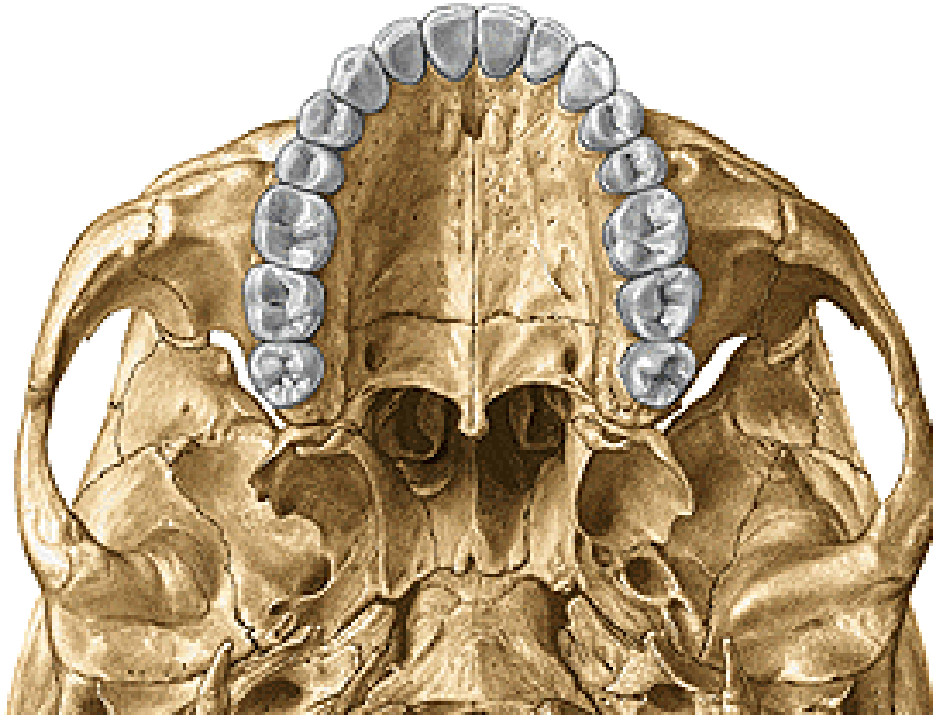Os palatinum (*Palatine bone*)

1. **Lamina horizontalis** (*Horizontal plate*)
2. **Lamina perpendicularis** (*Perpendicular plate*)

1. **Lamina horizontalis** (*Horizontal plate*)

Foramen palatinum majus (*Greater palatine foramen*)

Spina nasalis posterior (*Posterior nasal spine*)



Lamina perpendicularis (*Perpendicular lamina*) of palatine bone

Crista ethmoidalis (*Ethmoid crest*)

Crista conchalis - *Conchal crest* (*turbinate*)

Processus orbitalis et sphenoidalis (*Orbital and sphenoid process*)

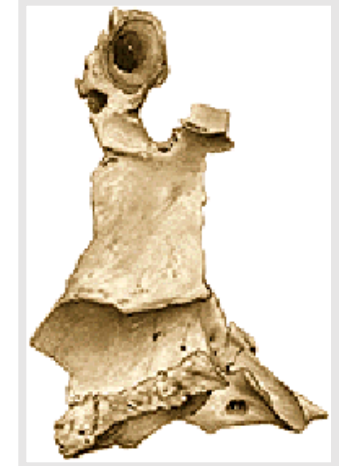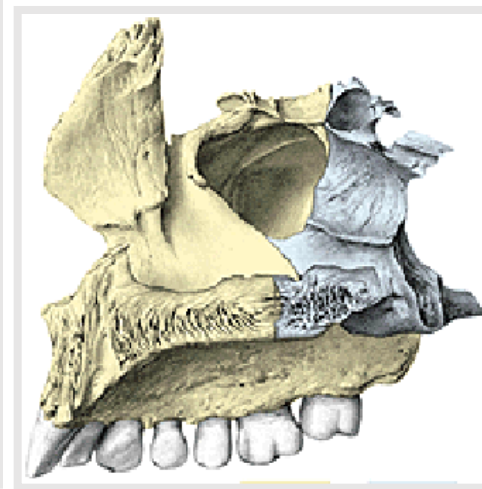
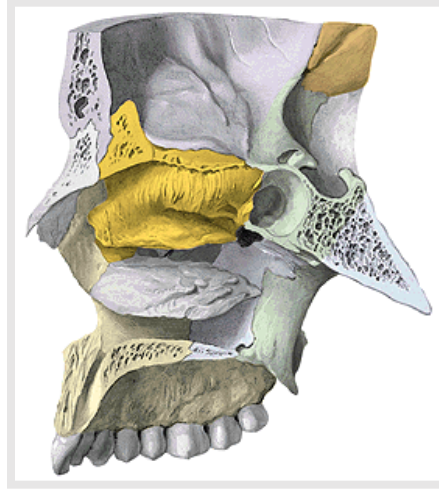
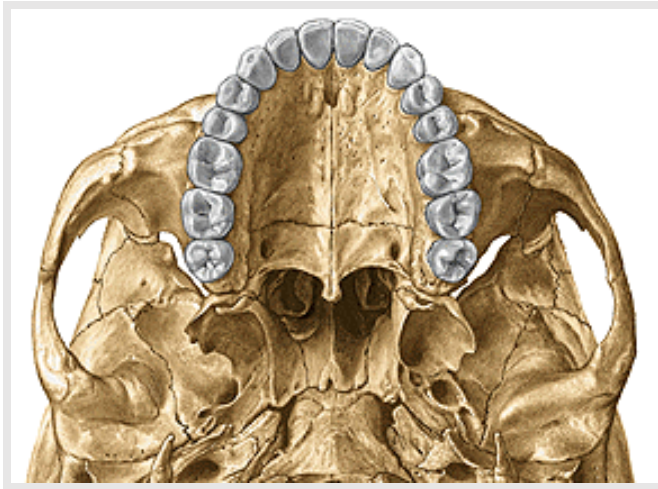
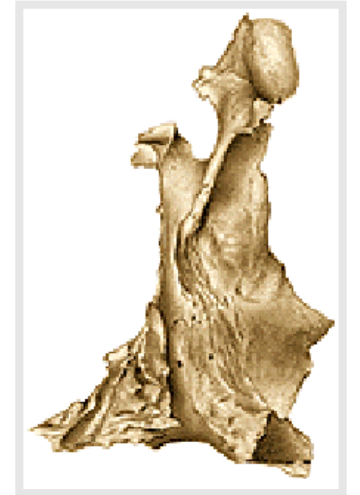Incisura sphenopalatina (*Sphenopalatine notch*)

Foramen sphenopalatinum (*Sphenopalatine foramen*)

Processus pyramidalis (*Pyramidal process*)

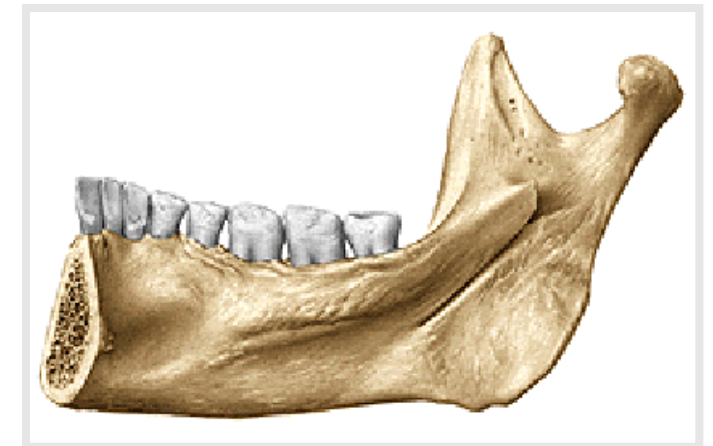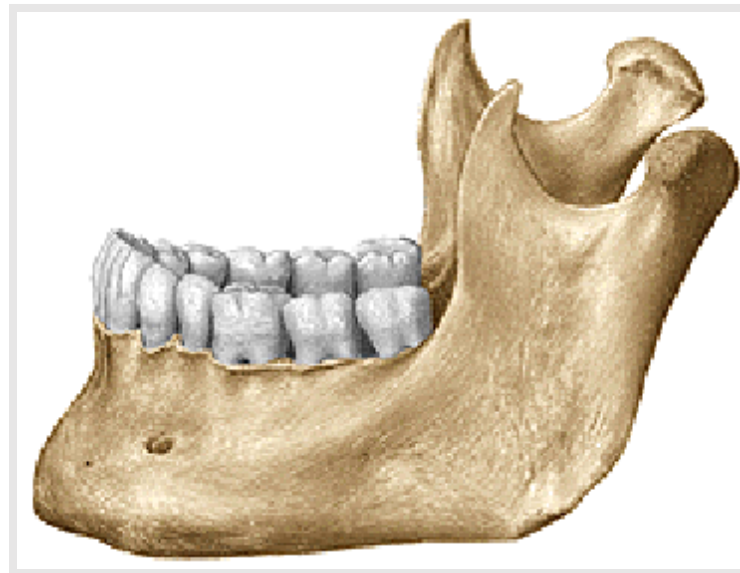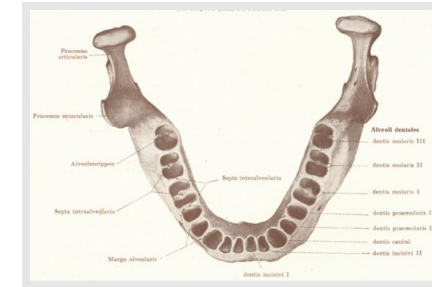
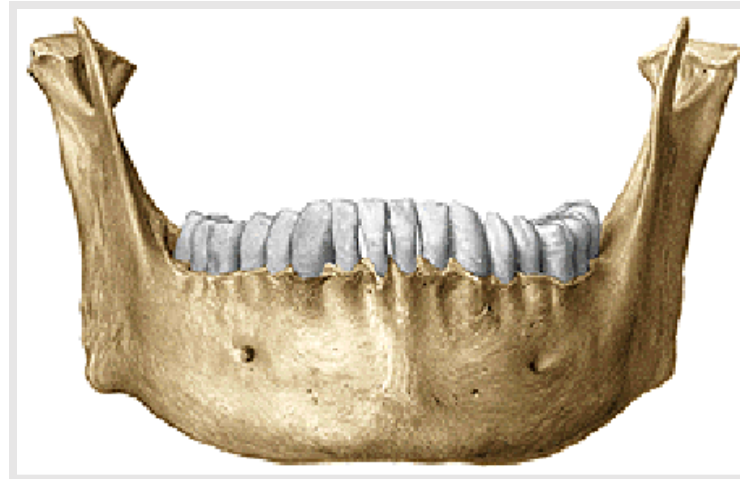Foramina palatina minora et canales palatini minores

(*Lesser palatine foramina and canals*)



Mandibula (*mandible*)

1. **Corpus** mandibulae - body
2. **Ramus** mandibulae
3. **Angulus** mandibulae (*angle*)



1. Corpus mandibulae (*Body*)

Fossae digastricae (*Digastric fossae*)

Spina mentalis (*Mental spina*)

Linea mylohyoidea (*Mylohyoid line*)

Fovea sublingualis (*Sublingual fossa*)

Fovea submandibularis (*Submandibular fossa*)

Protuberantia mentalis (*Mental protuberance*)

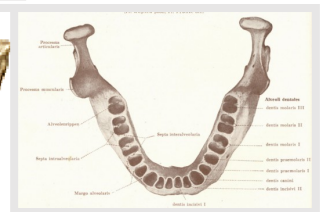
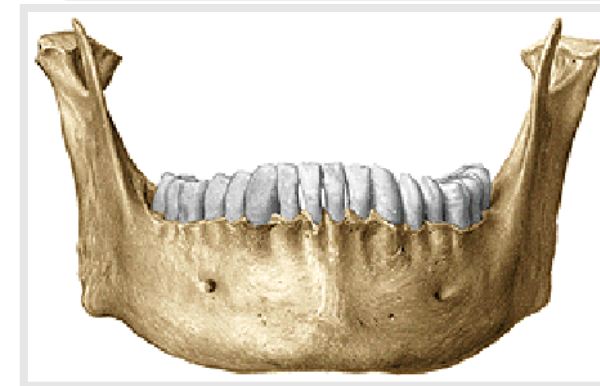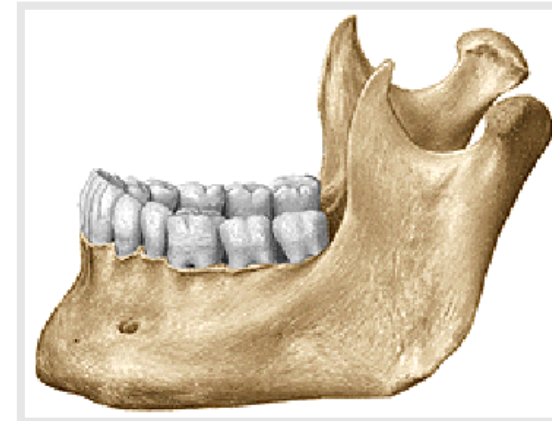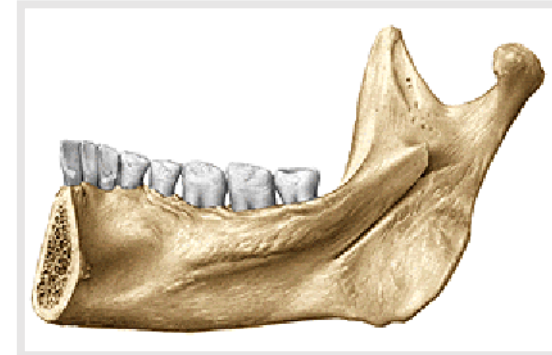Tuberculum mentale (*Mental tubercle*)

Foramen mentale (*Mental foramen*)

Processus alveolaris (*Alveolar process*)

Alveoli dentales (*dental alveoli, juga, septa*)

Trigonum retromolare (*retromolar trigon!*)



Ramus mandibulae (*Mandibular ramus*)

1) Processus condylaris (*Condylar process*)

caput mandibulae – *head of mandible*

collum – *neck*

fovea pterygoidea (*pterygoid fovea*)

Incisura mandibulae (*Mandibular notch*)

2) Processus coronoideus (*Coronoid process*)

Foramen mandibulae

(*canalis mandibulae - mandibular canal*)

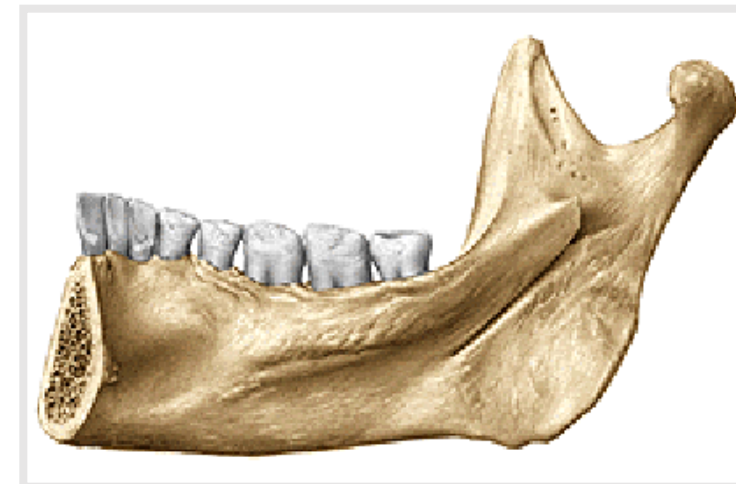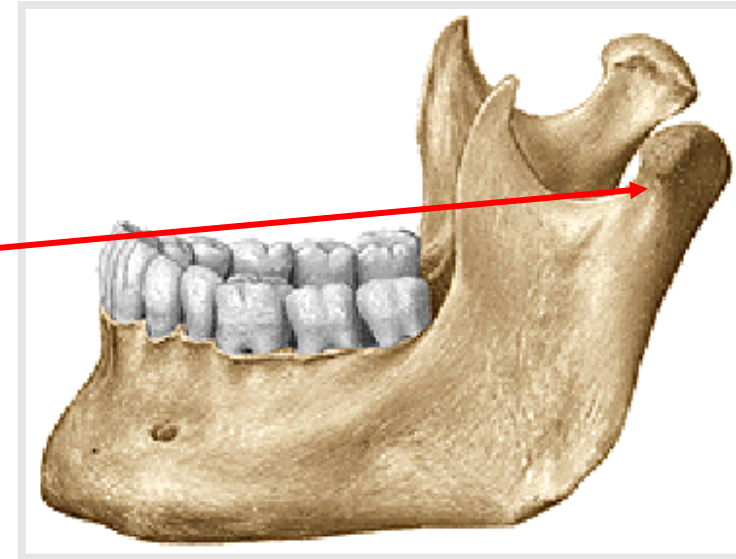
lingula mandibulae

sulcus mylohyoideus (*Mylohyoid groove*)

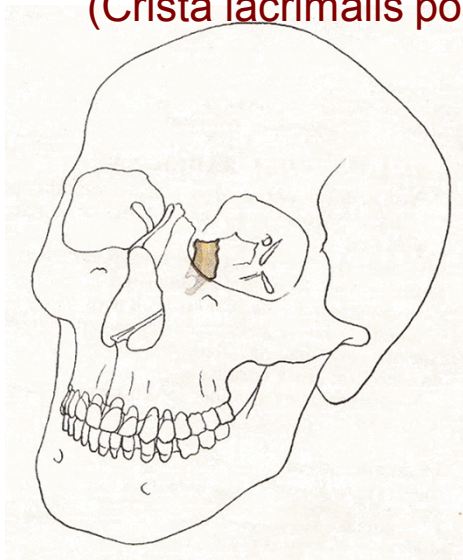
3) Angulus mandibulae (*Mandibular angle*)

Tuberositas masseterica (*Masseteric tuberosity*)

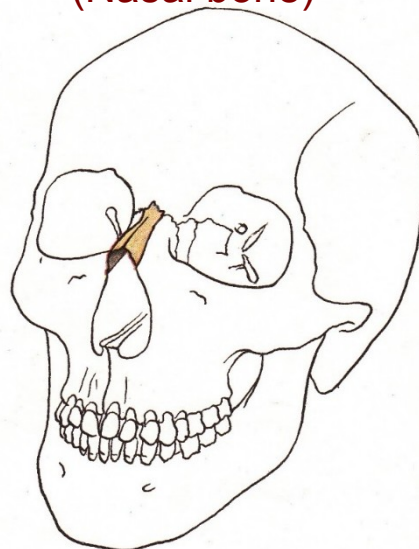
Tuberositas pterygoidea (*Pterygoid tuberosity*)



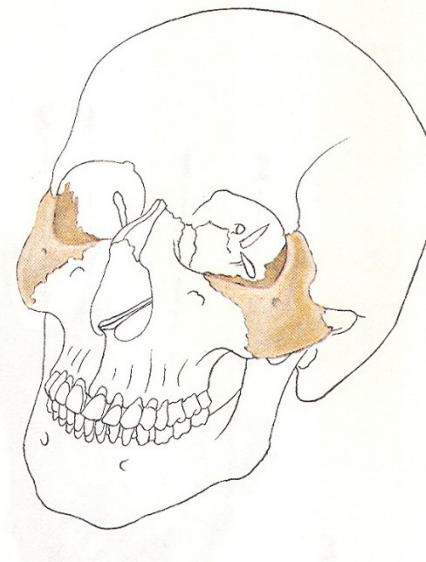Os lacrimale
(Crista lacrimalis posterior)



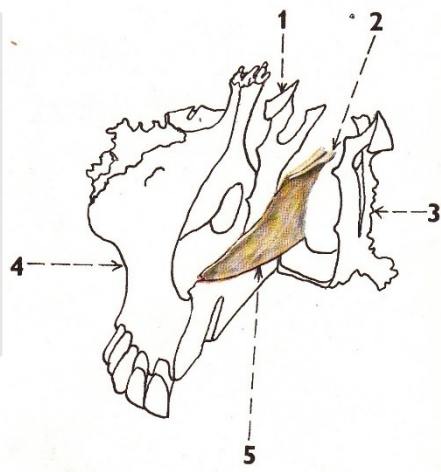
Os nasale
(Nasal bone)



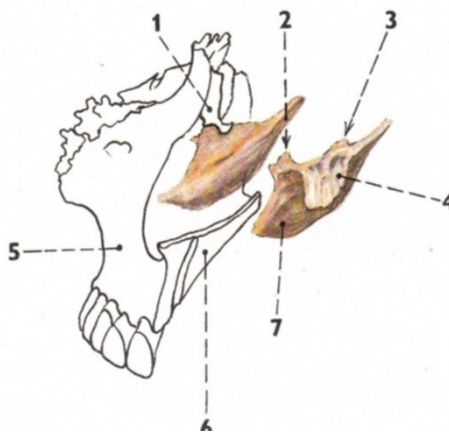
Os zygomaticum



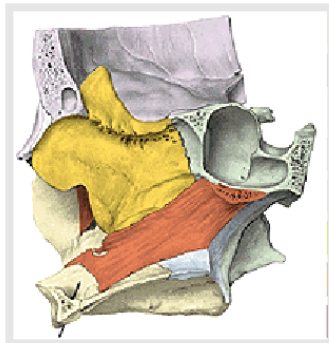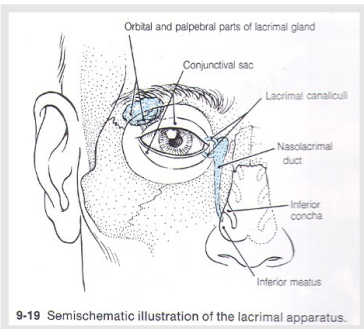
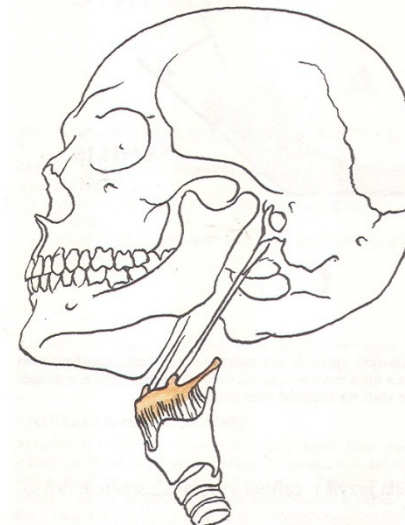
Vomer



Concha nasalis inferior
(processus maxillaris)



Os hyoideum



Os lacrimale

Crista lacrimalis posterior

(Posterior lacrimal crest)

Sulcus lacrimalis

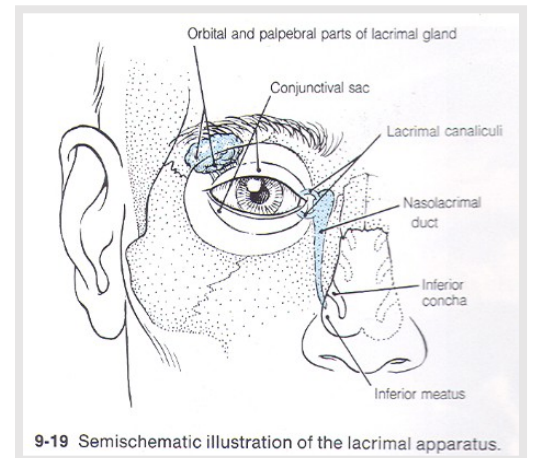
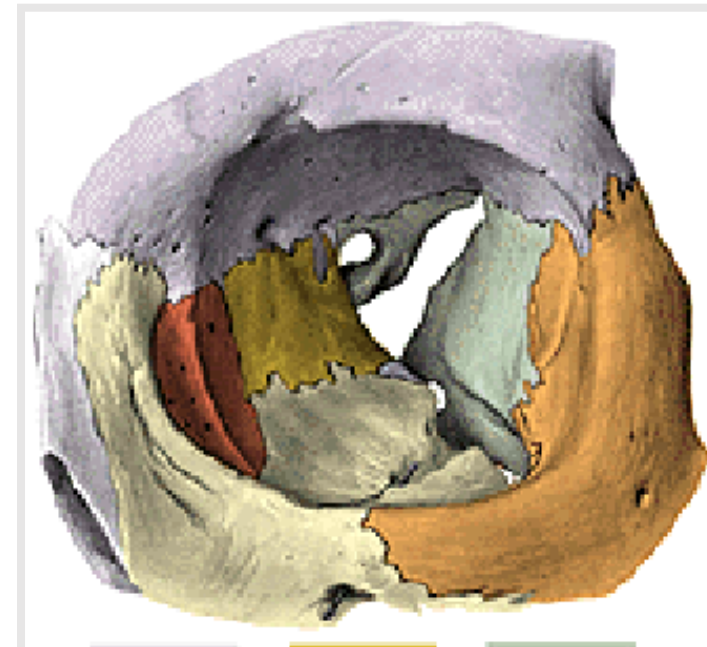
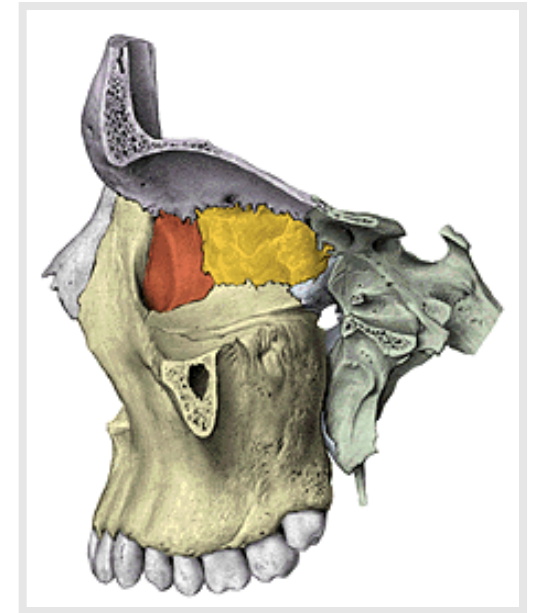
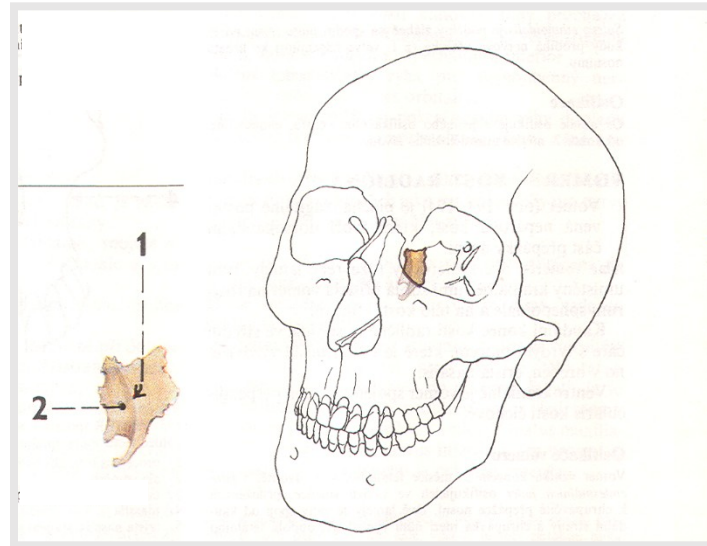
(Lacrimal groove)

Fossa sacci lacrimalis

(Fossa of lacrimal sac)

Canalis nasolacrimalis

(Nasolacrimal canal)



Os zygomaticum (Zygomatic bone)

Corpus ossis zygomatici (*Body of zygomatic bone*)

Facies lateralis (*Lateral surface*)
(**foramen zygomaticofaciale**)

Facies orbitalis (*Orbital surface*)
(**foramen zygomaticoorbitale**)

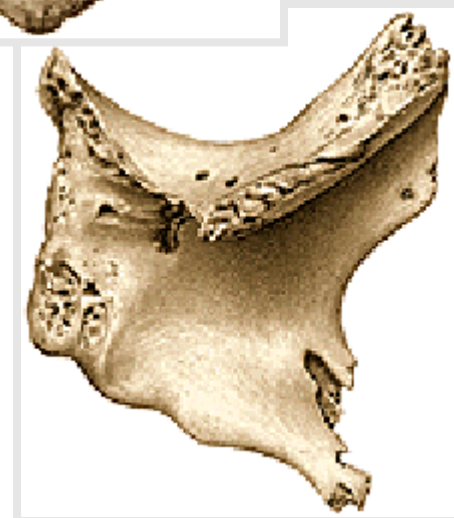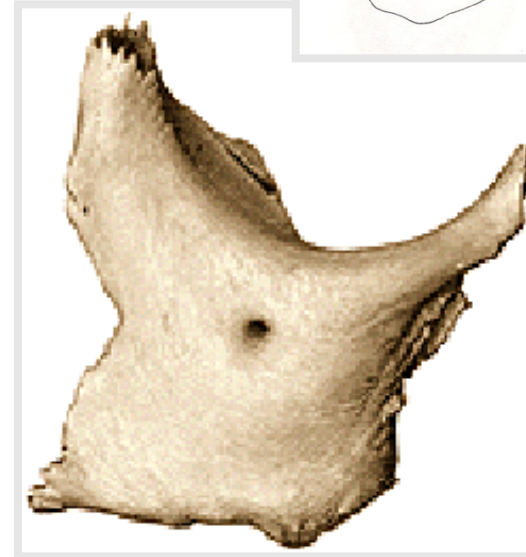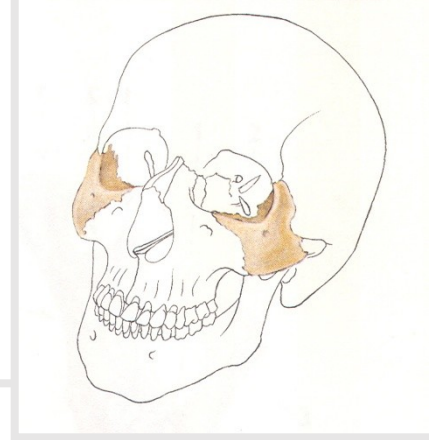
Facies temporalis (*Temporal surface*)
(**foramen zygomaticotemporale**)

Processus temporalis (*Temporal process*)

Processus frontalis (*Frontal process*)

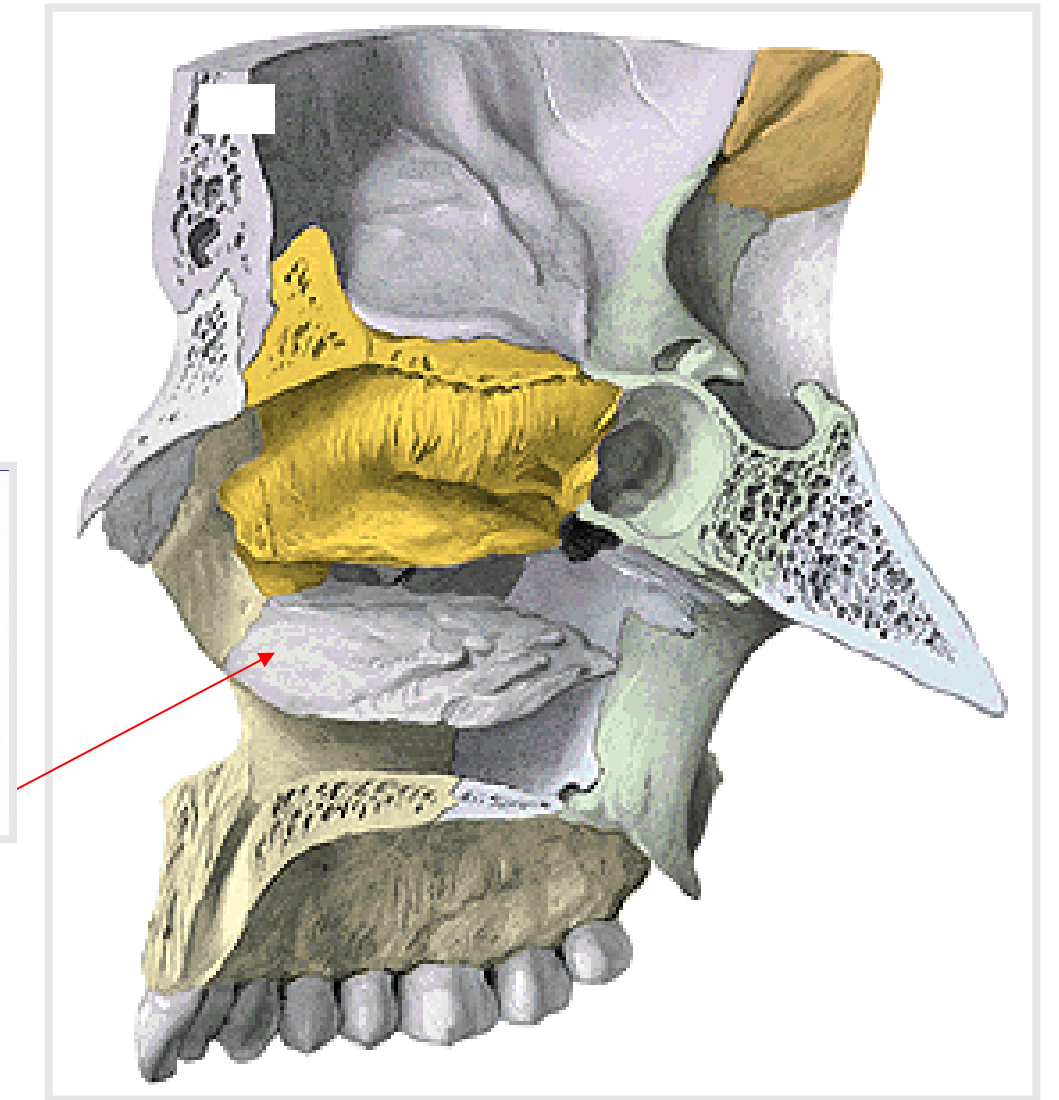
Processus maxillaris (*Maxillary process*)

Arcus zygomaticus (*Zygomatic arch*)



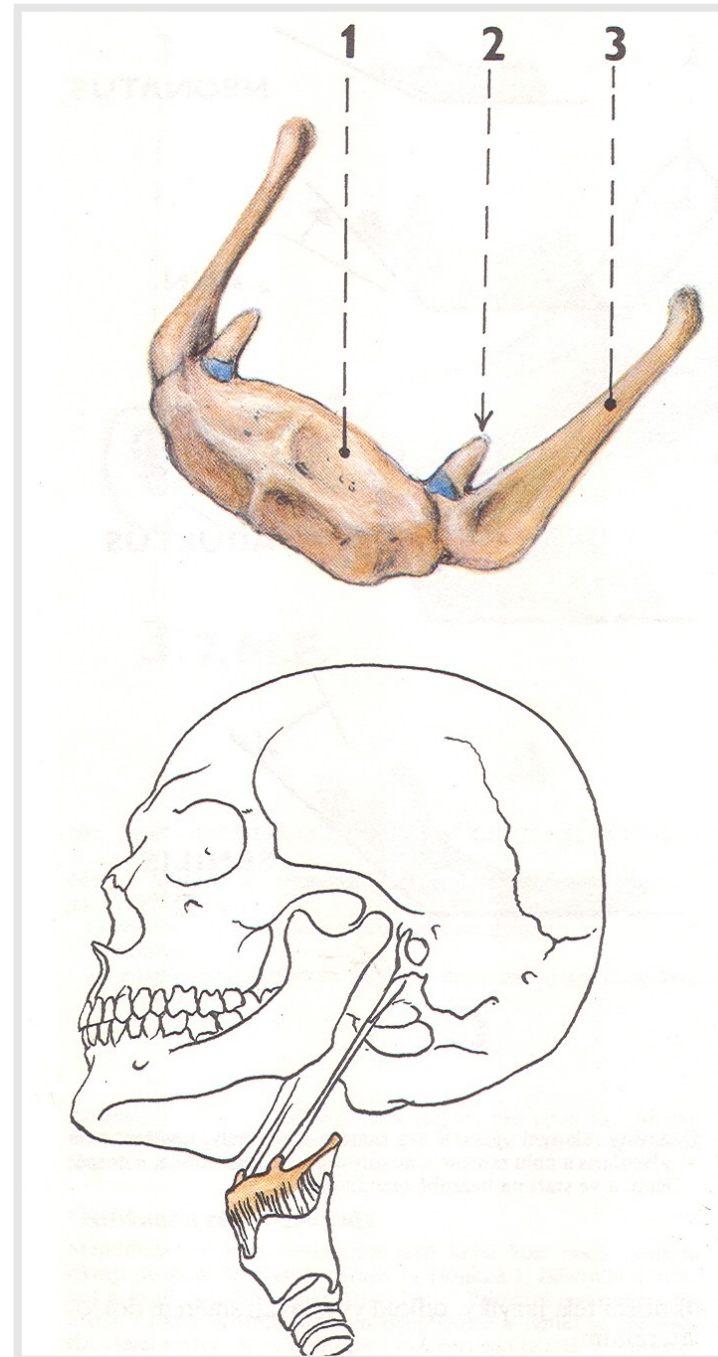
Concha nasalis inferior *(inferior nasal concha)*

Processus **maxillaris**, lacrimalis, ethmoidalis
(maxillary, lacrimal and ethmoid process)



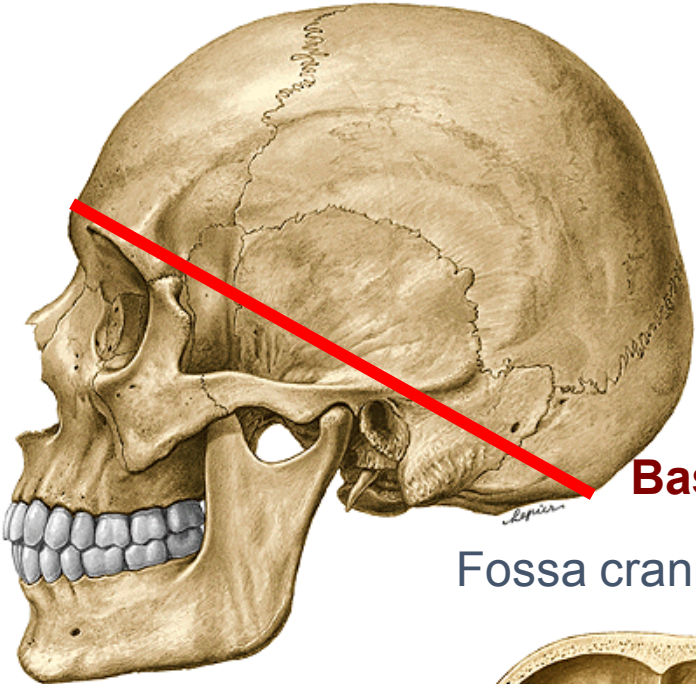
Os hyoideum (*Hyoid bone*)

1. **Corpus ossis hyoidei** - *body*
2. **Cornua minora** (*Lesser horns*)
3. **Cornua majora** (*Greater horns*)



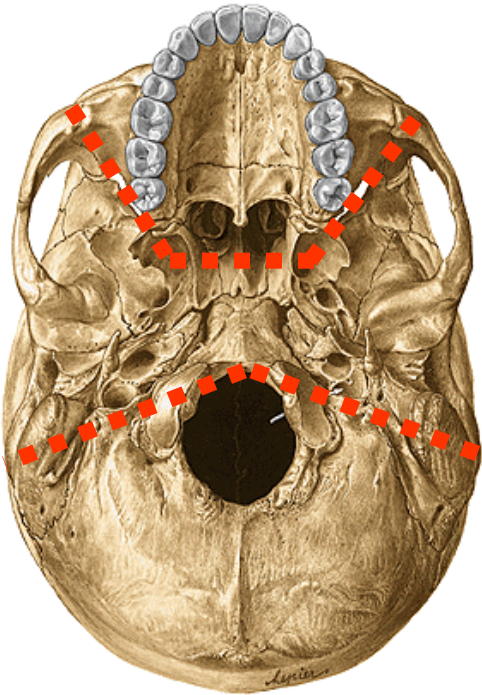
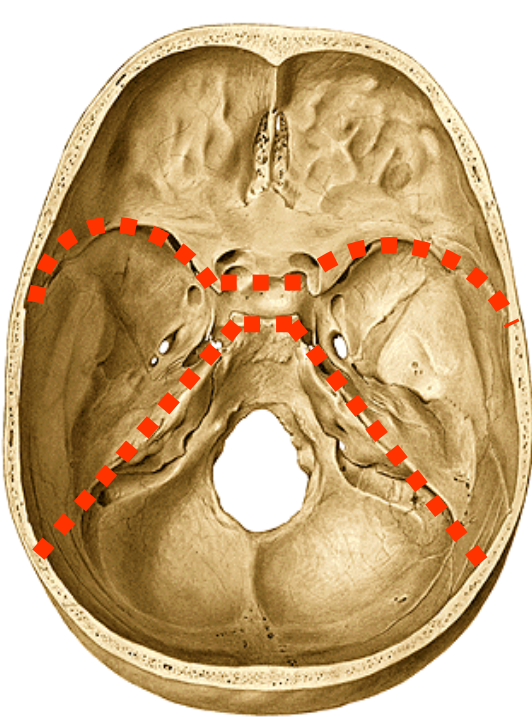
Cavities of the skull

Calvaria
frons, vertex, occiput



Basis cranii (interna et externa)

Fossa cranii anterior, media, posterior



FOSSAE CRANII

FOSSA TEMPORALIS

FOSSA INFRATEMPORALIS

FOSSA PTERYGOPALATINA

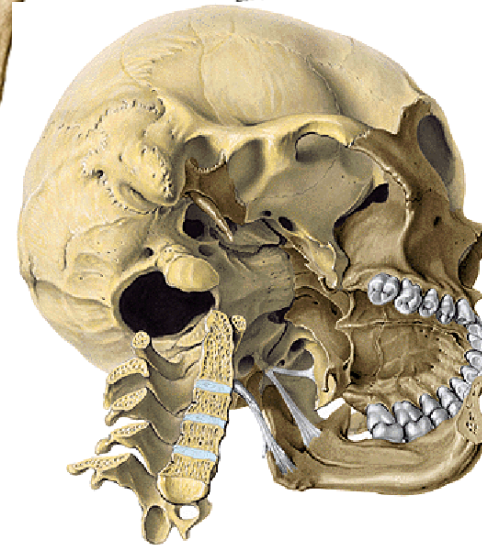
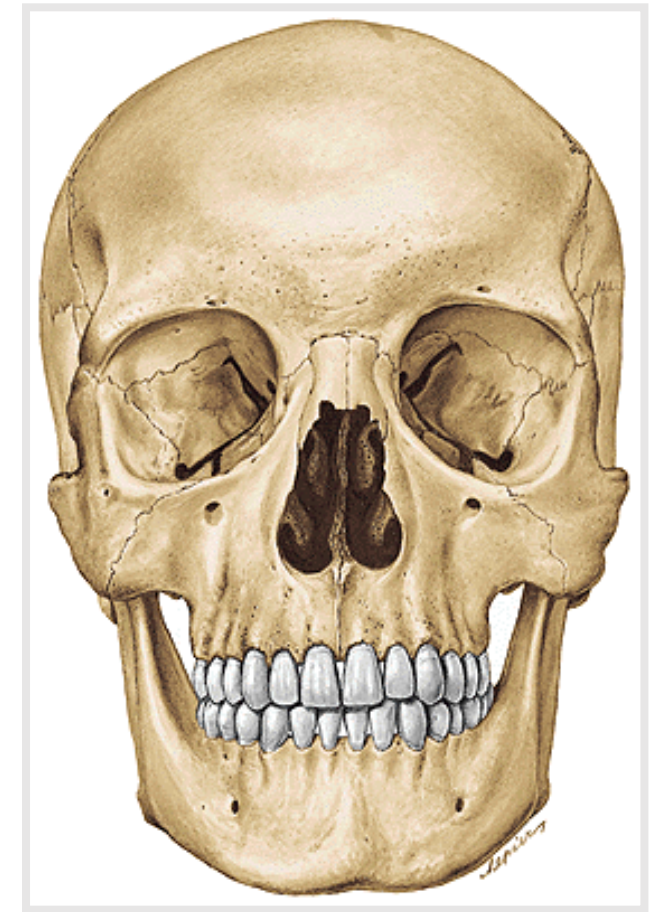
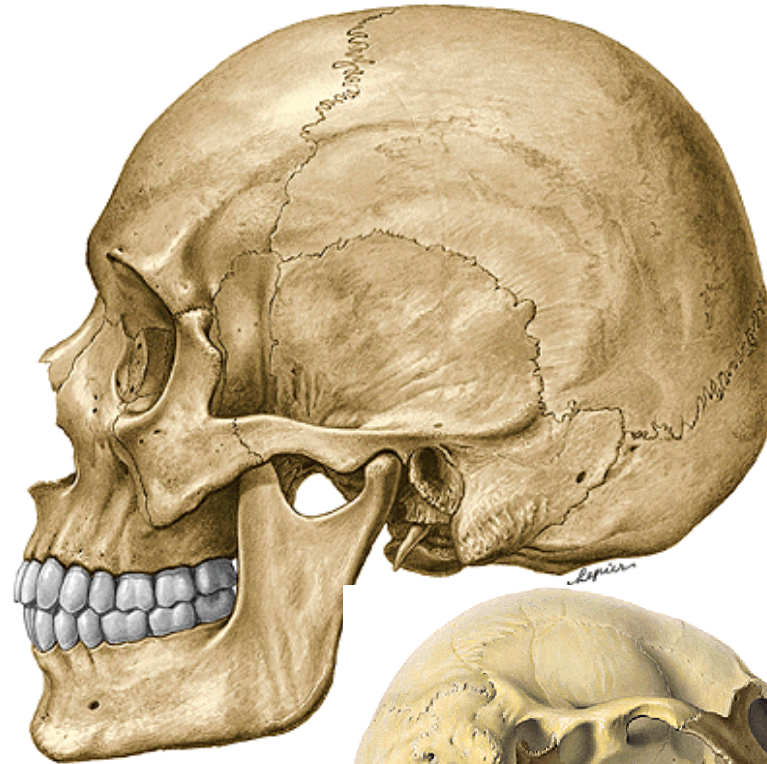
ORBITA

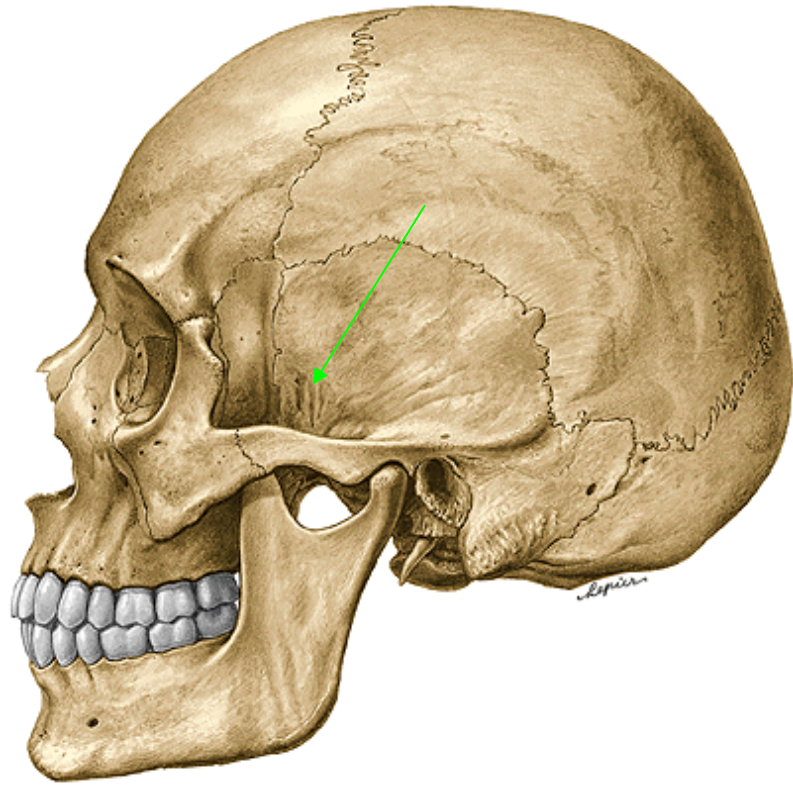
CAVITAS NASI OSSEA

(bone nasal cavity)

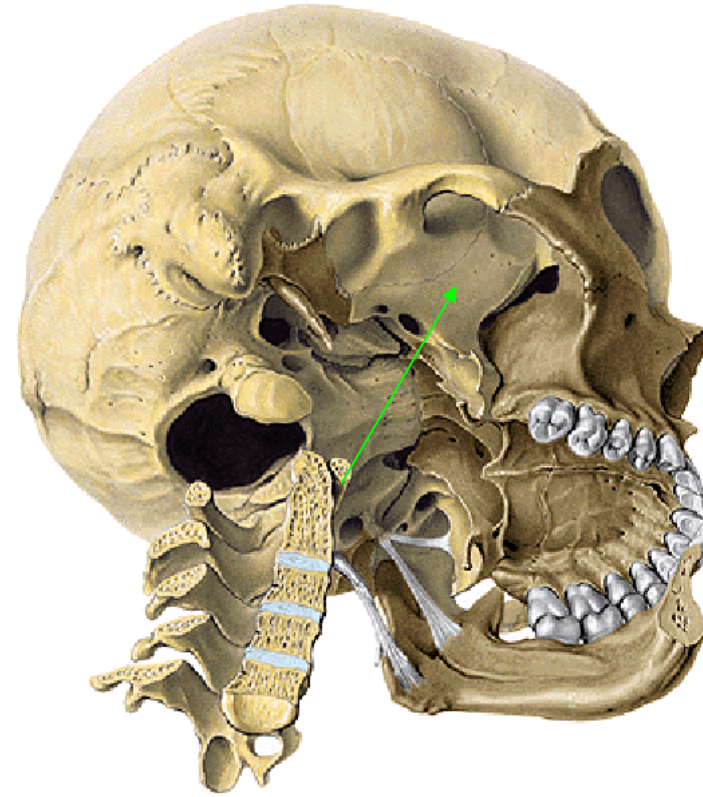
CAVUM ORIS

(mouth cavity)





Fossa temporalis
(temporal fossa)



Fossa infratemporalis
(infratemporal fossa)

Fossa temporalis (*temporal fossa*)

Content: m. temporalis + nerves and vessels

Medial wall

linea temporalis superior (*superior temporal line*)

facies temporalis alae majoris ossis sphenoidalis

(*temporal surface of the greater wing of the sphenoid bone*)

pars squamosa ossis temporalis

(*squamous part of the temporal bone*)

Ventral wall

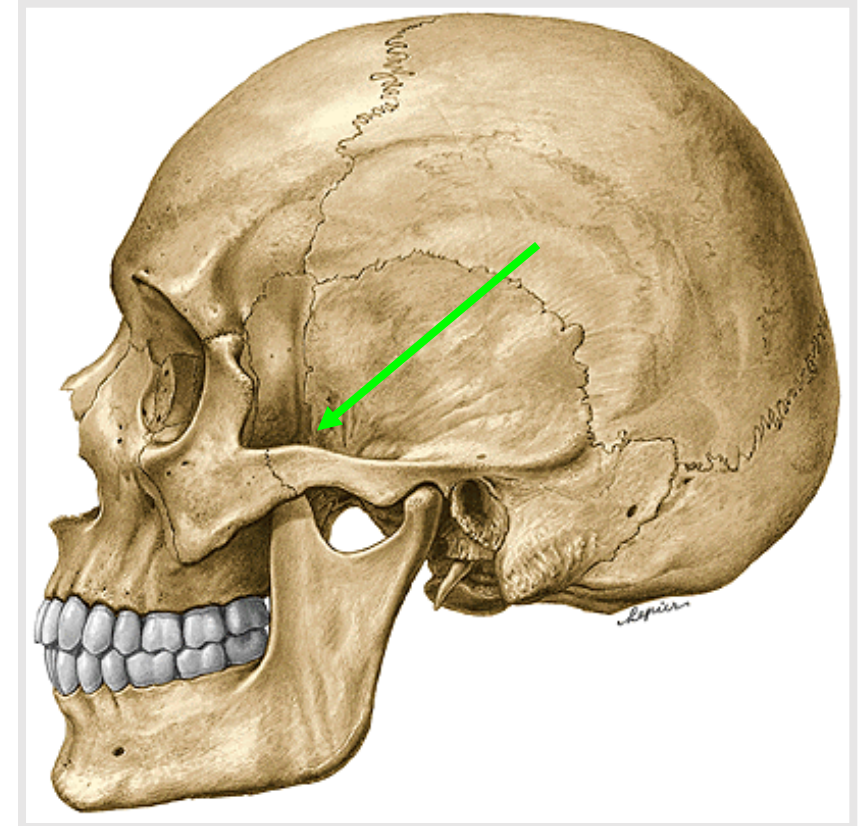
facies temporalis ossis zygomatici (*temporal surface of the zygomatic bone*)

processus zygomaticus ossis frontalis

(*zygomatic process of the frontal bone*)

Lateral wall

arcus zygomaticus (*zygomatic arch*)



Fossa infratemporalis (*infratemporal fossa*)

Content: mm. pterygoidei + nerves and vessels

Upper wall

Crista infratemporalis alae majoris ossis sphenoidalis
(*infratemporal crest of the greater wing of the sphenoid bone*)

Medial wall

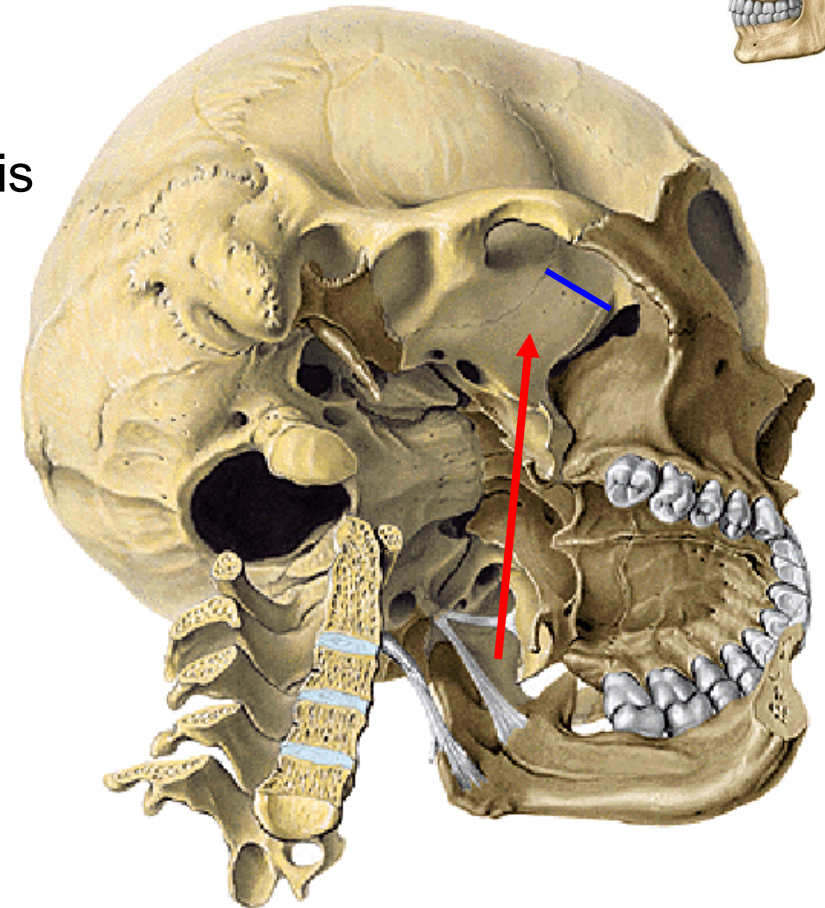
Lamina lateralis processus pterygoidei
(*lateral lamina of the pterygoid process*)

Ventral wall

Facies infratemporalis corporis maxillae
(*infratemporal surface of the maxillar body*)

Lateral wall

Ramus mandibulae (*mandibular branch*)



Fossa pterygopalatina (*pterygopalatine fossa*)

Content: vessels and nerves

Upper wall

Facies maxillaris alae majoris ossis sphenoidalis
(*maxillar surface of the greater wing of the sphenoid bone*)

Medial wall

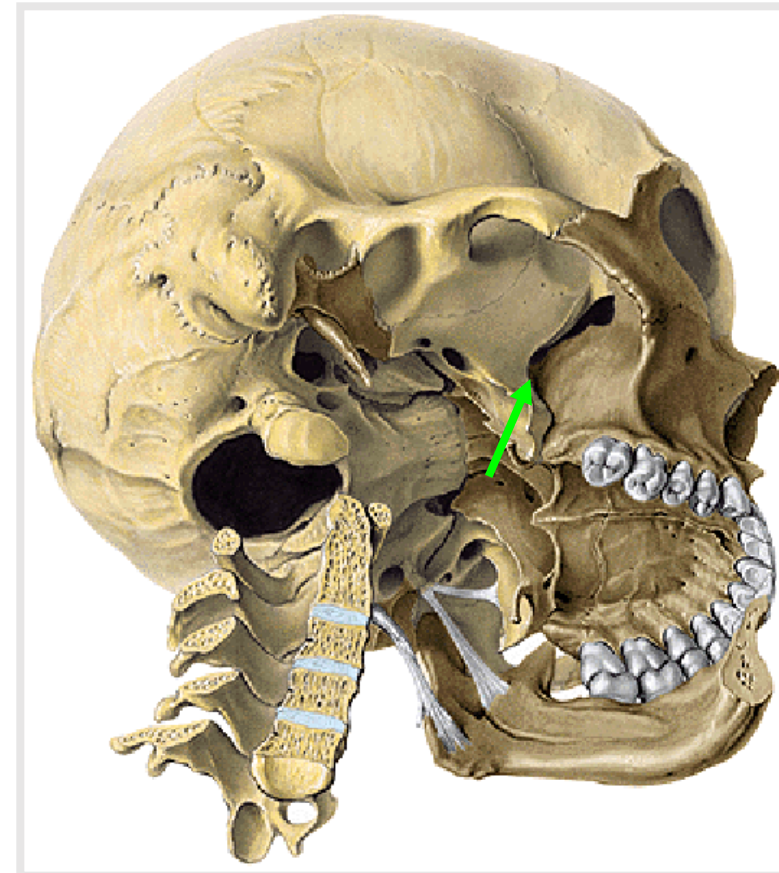
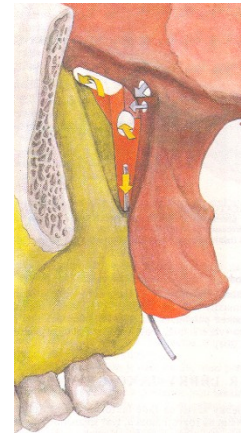Lamina perpendicularis ossis palatini
(*perpendicular plate of the palatine bone*)

Ventral wall

tuber maxillae
(*tuberosity of maxilla*)

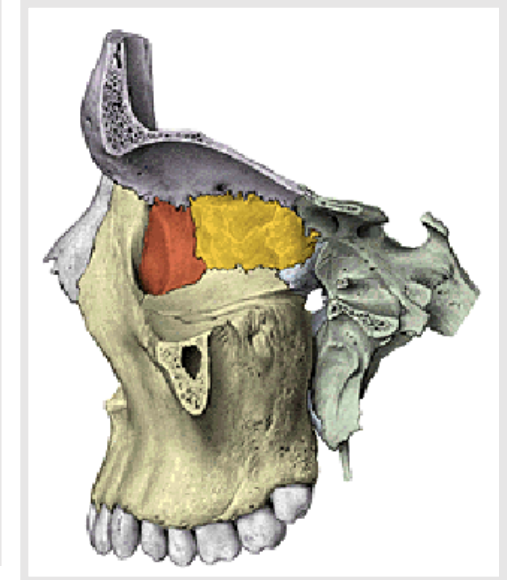
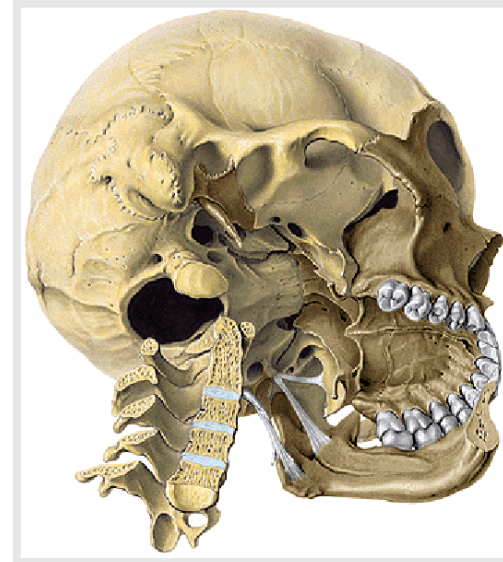
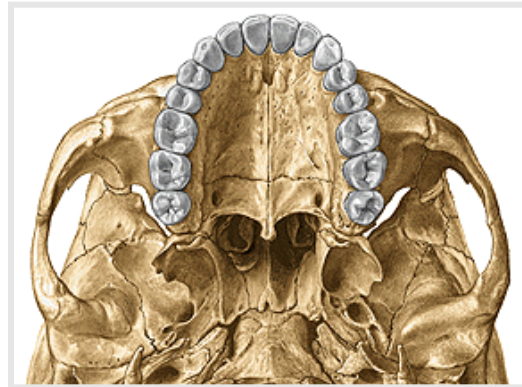
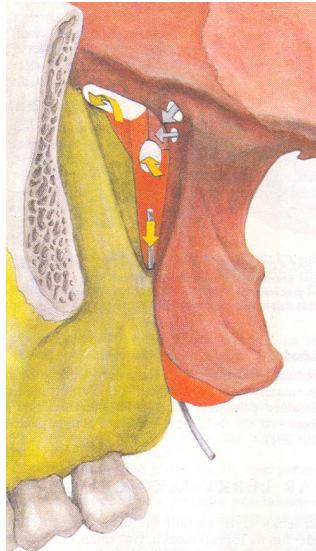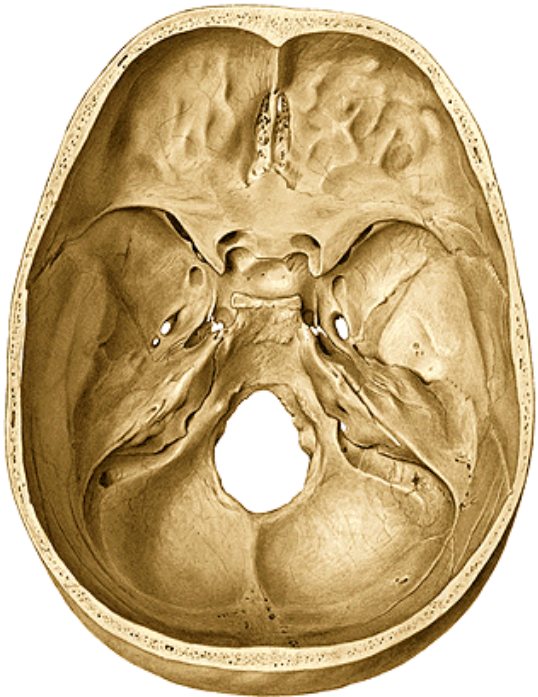
Dorsal wall

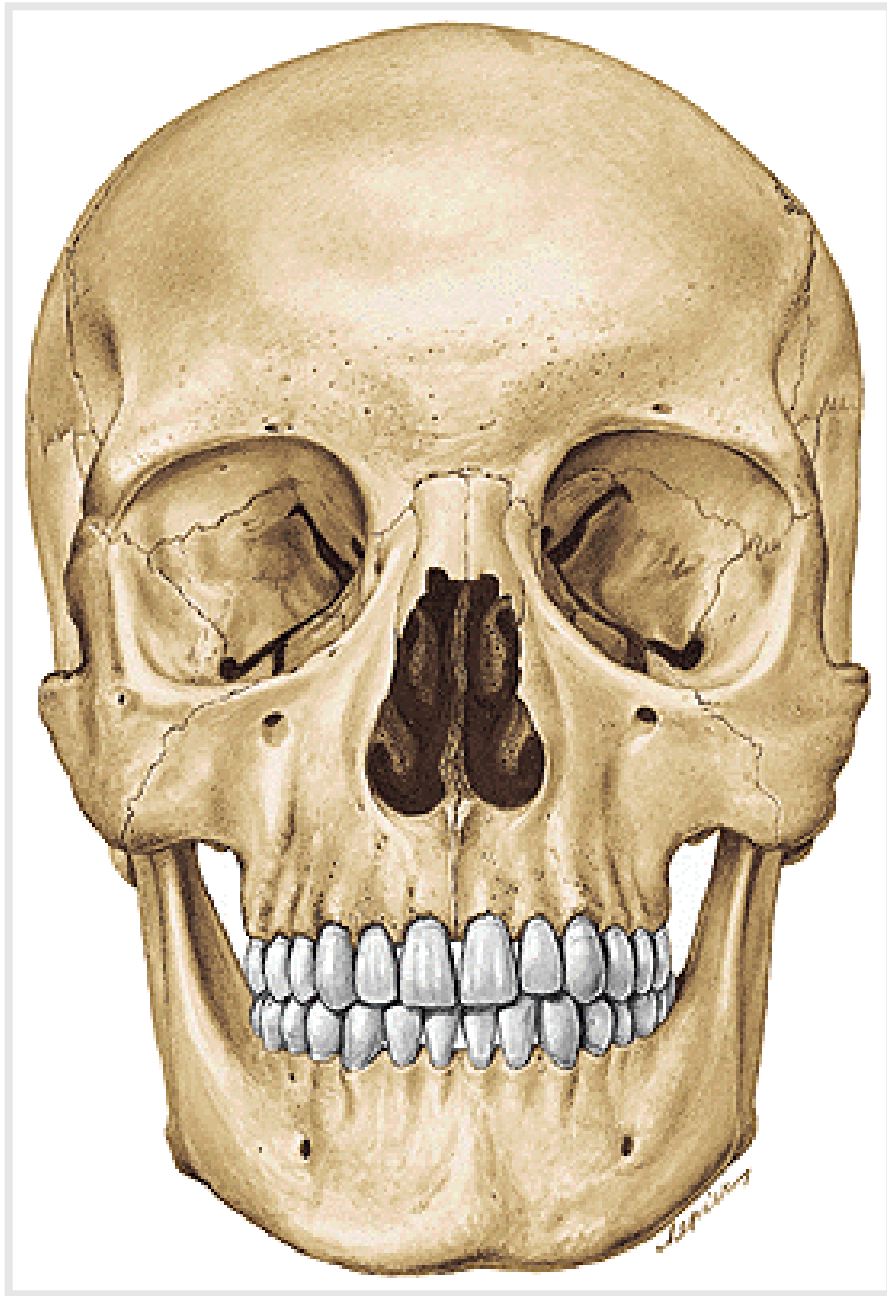
Processus pterygoideus ossis sphenoidalis
(*pterygoid process of sphenoid bone*)



Fossa pterygopalatina (*Pterygopalatine fossa*) has connection with:

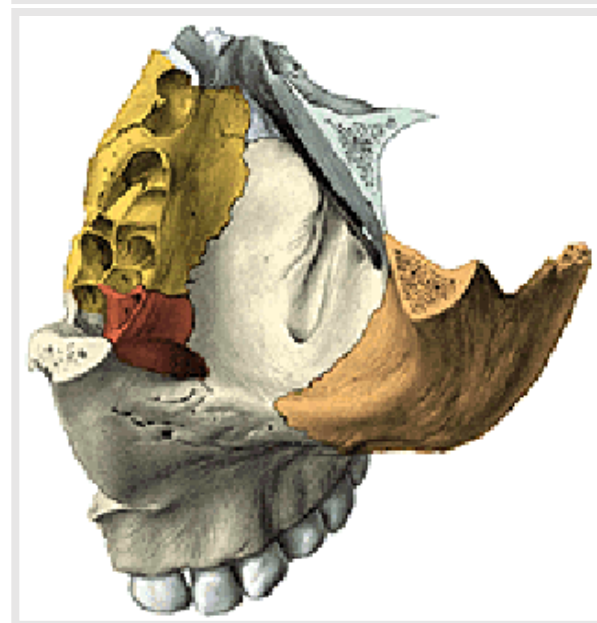
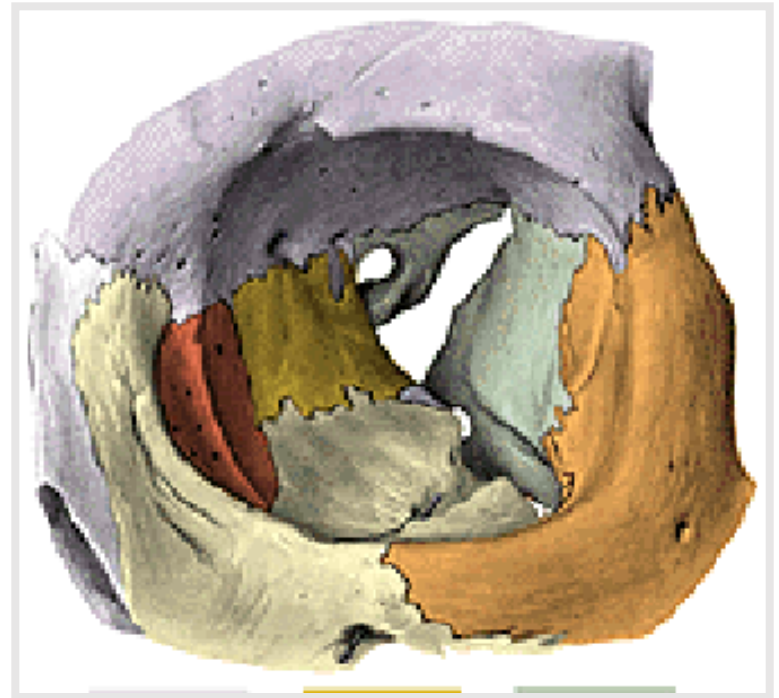
- 1) **Fossa cranii media** (*middle cranial fossa*) by **foramen rotundum**
- 2) **Cavum oris** (*oral cavity*) by **canalis palatinus major** (*greater palatine canal*)
- 3) **Orbita** by **fissura orbitalis inferior** (*inferior orbital fissure*)
- 4) **Cavum nasi osseum** (*bone nasal cavity*) by **foramen sphenopalatinum** (*sphenopalatine foramen*)
- 5) **External surface of basis** of the skull by **canalis pterygoideus** (*pterygoid canal*)





Orbita

(orbit)



Cavitas nasi ossea (bone nasal cavity)

Entrance: foramen piriforme
Exit: choanae

Upper wall

ossa nasalia (*nasal bones*)

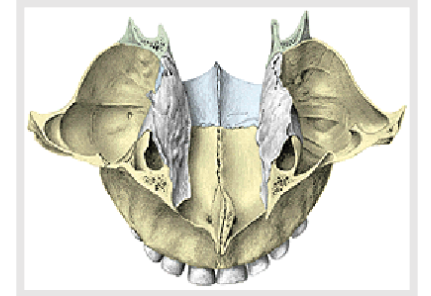
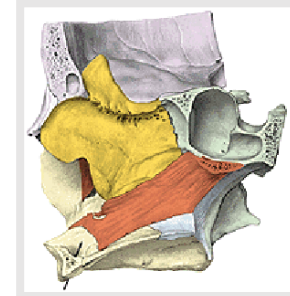
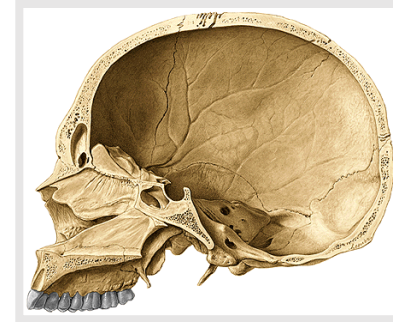
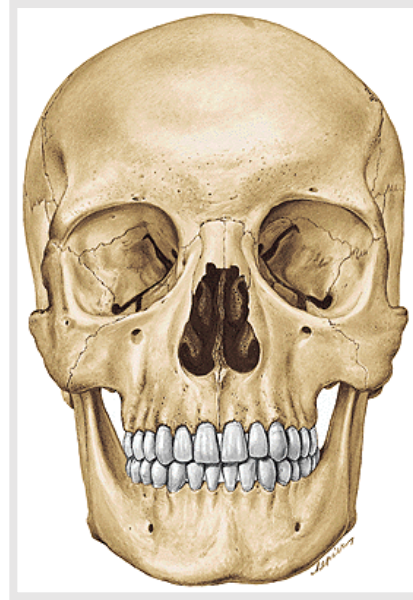
pars nasalis ossis frontalis (*nasal part of the frontal bone*)

lamina cribrosa ossis ethmoidalis (*cribriform plate of the ethmoid bone*)

corpus ossis sphenoidalis (*body of the sphenoid bone*)

Caudal wall

palatum durum (*hard palate*) – **processus palatinus maxillae** (*palatine process of the maxilla*) and **lamina horizontalis ossis palatini** (*horizontal plate of the palatine bone*)

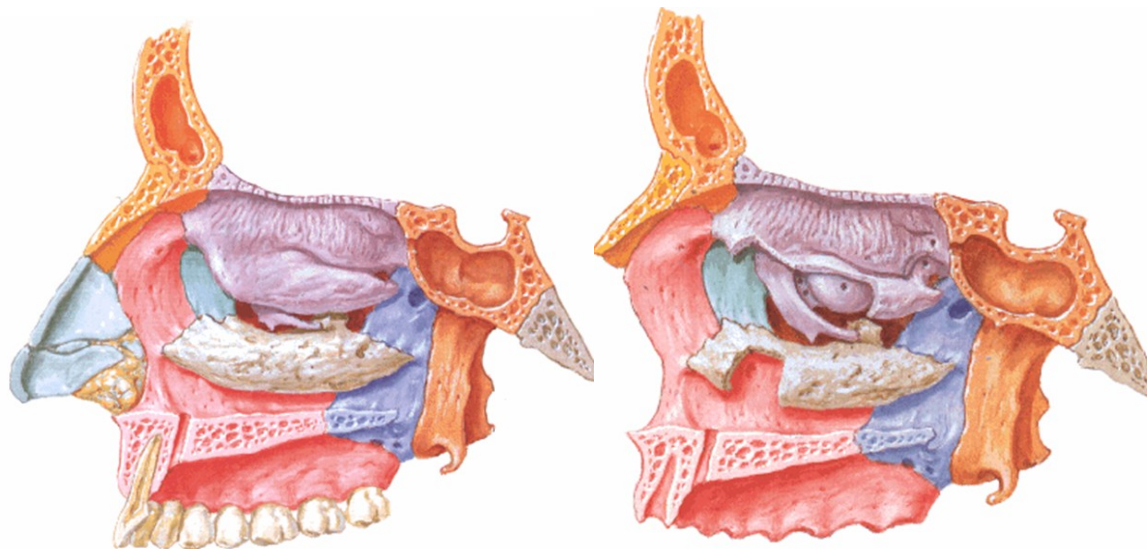
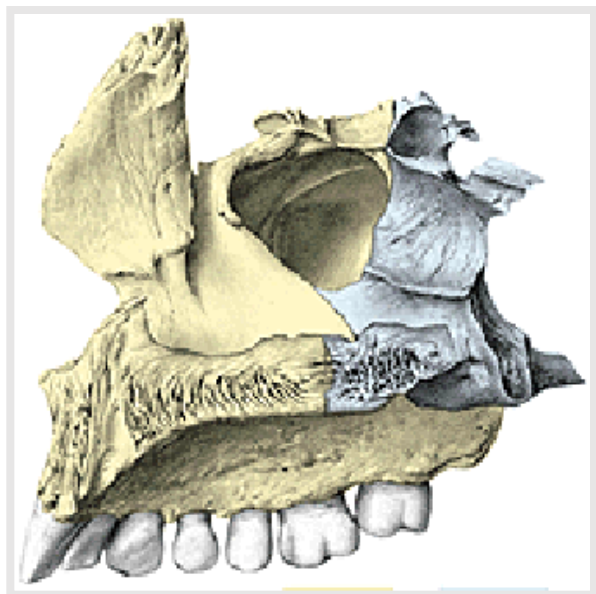


Lateral wall of the nasal cavity

- **processus frontalis maxillae** (*frontal process of maxilla*)
- **facies nasalis corporis maxillae** (*nasal surface of maxillar body*)
- **lamina medialis processus pterygoidei** (*medial plate of pterygoid process*)

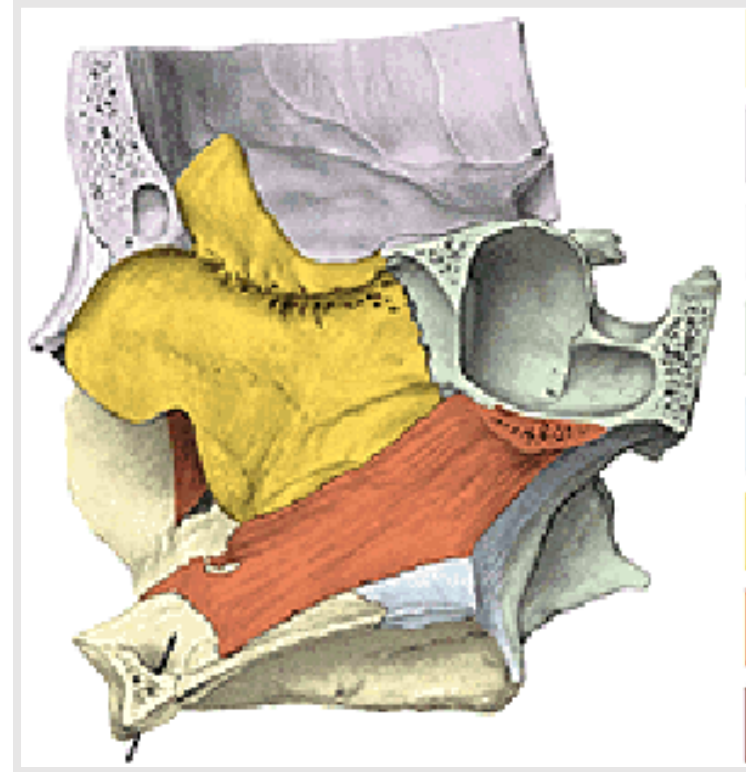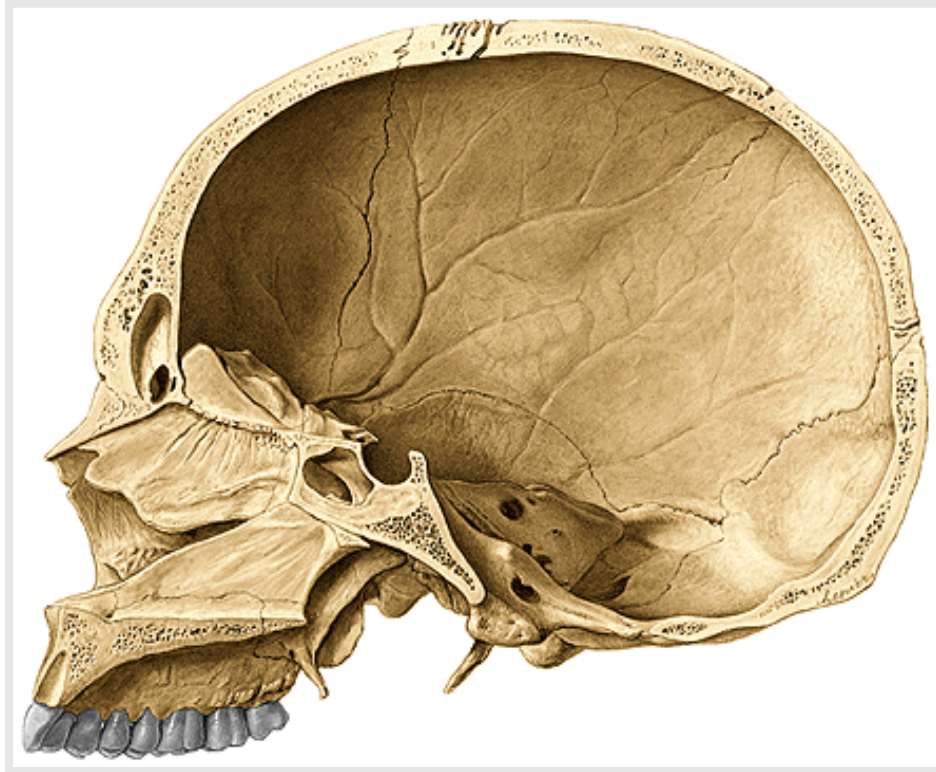
- ❖ **os lacrimale** (*lacrimal bone*)
- ❖ **lamina perpendicularis ossis palatini** (*perpendicular plate of palatine bone*)

- **labyrinthus ethmoidalis** (with *concha nasalis superior and media*)
(ethmoidal labyrinth with both superior and middle conchae)
- **concha nasalis inferior** (*inferior nasal concha-turbinate*)



Septum nasi osseum (*bone nasal septum*)

lamina perpendicularis ossis ethmoidalis (*perpendicular lamina of the ethmoidal bone*) + **vomer**



Space in the nasal cavity

■ **Meatus nasi superior** (*Superior nasal meatus*)

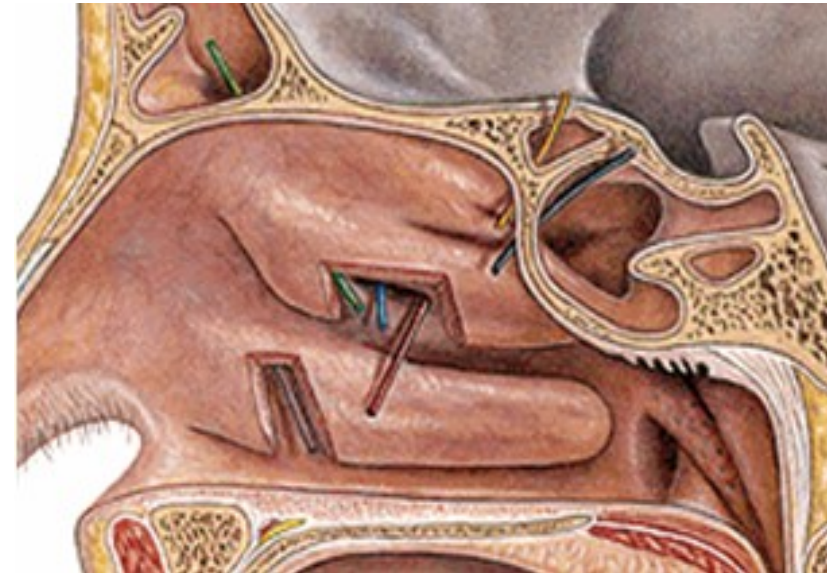
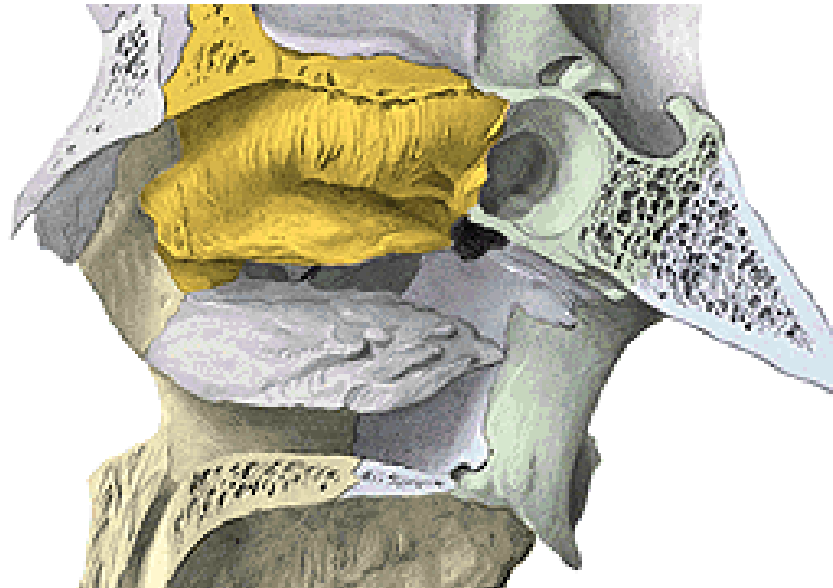- sinus sphenoidalis (*sphenoid sinus*), celullae ethmoidales posteriores (*posterior ethmoidal sinuses*)

❖ **Meatus nasi medius** (*Middle nasal meatus*)

- sinus frontalis (*frontal sinus*), sinus maxillaris (*maxillar sinus*)
- celullae ethmoidales anteriores (*anterior ethmoidal sinuses*)

➤ **Meatus nasi inferior** (*Inferior nasal meatus*)

- canalis nasolacrimalis (*nasolacrimal canal*)



Capacity of the skull

male about 1450 ccm

female about 1350 ccm

Microcephalia (less than 1100 ccm – Anatomy museum)

Macrocephalia

Newborn skull

Capacity about **370-380 ccm**

Circumference about **34 cm**

Length about **11 cm**

Breadth about **9 cm**

Large neurocranium

Instead of sutures strips of connective tissue

Fonticulus major, minor, sphenoidalis, mastoideus

(*Fonticuli - greater, lesser, sphenoidal, mastoid*)

Sutura frontalis (*frontal suture*)

Anulus tympanicus (*tympanic ring*)

Low splanchnocranium

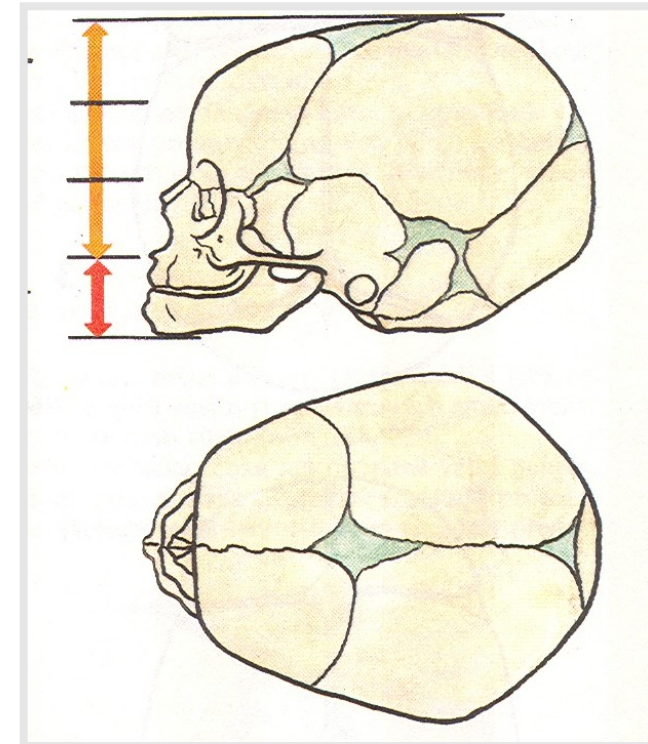
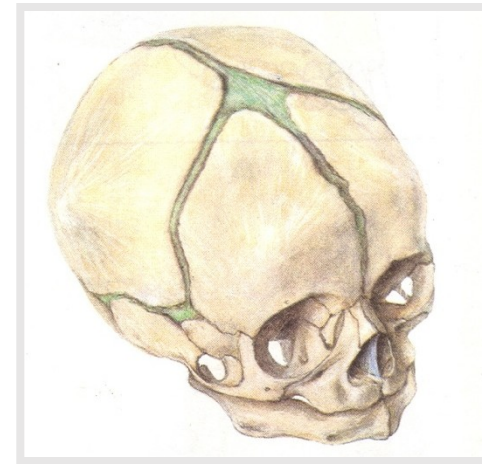❖ **without** *processus alveolares*

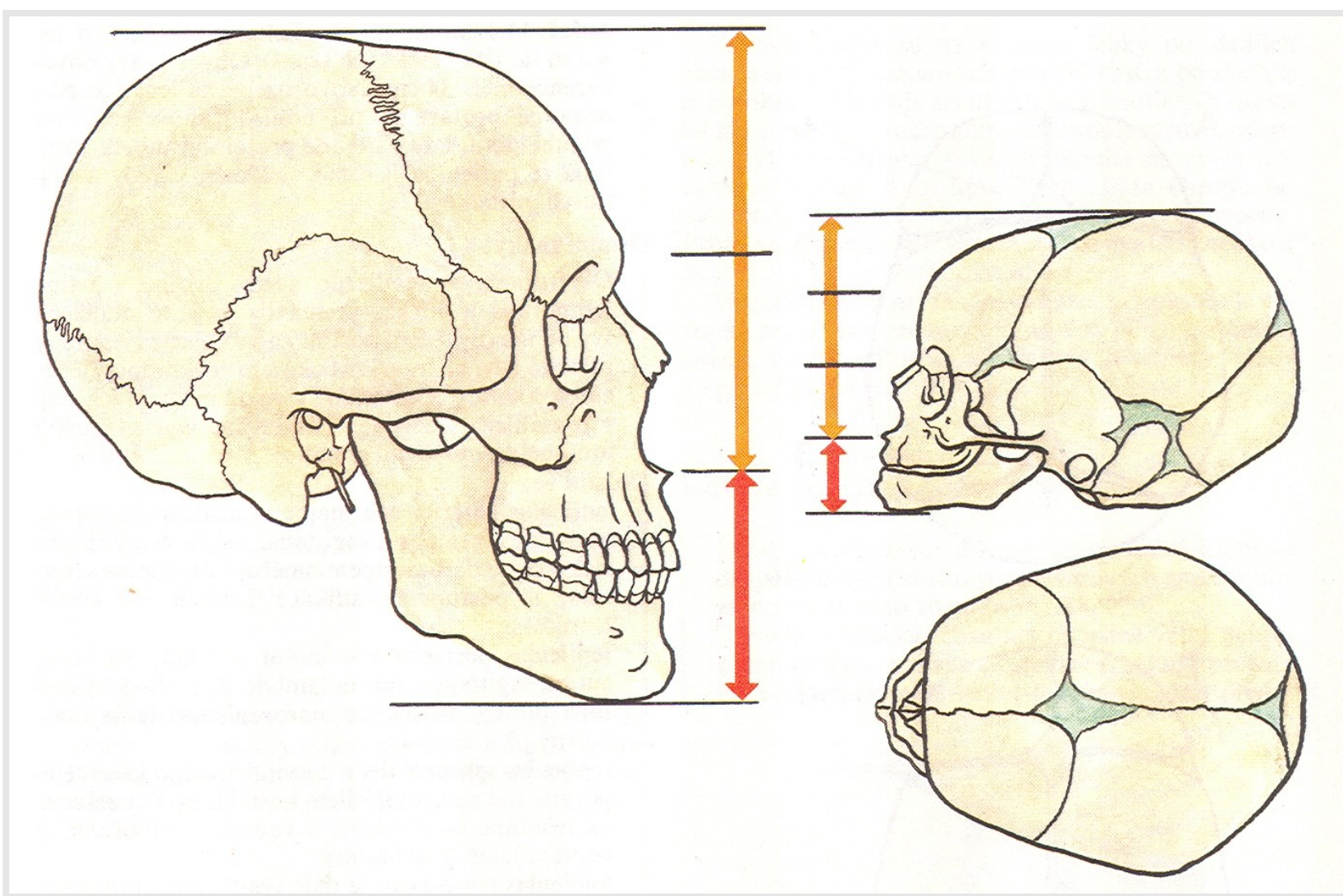
(without *alveolar processes* - of *maxillae* and *mandible*)

➤ without *paranasal cavities* (*sinuses*)

Symphysis menti

Angle of *mandible* about **140°**

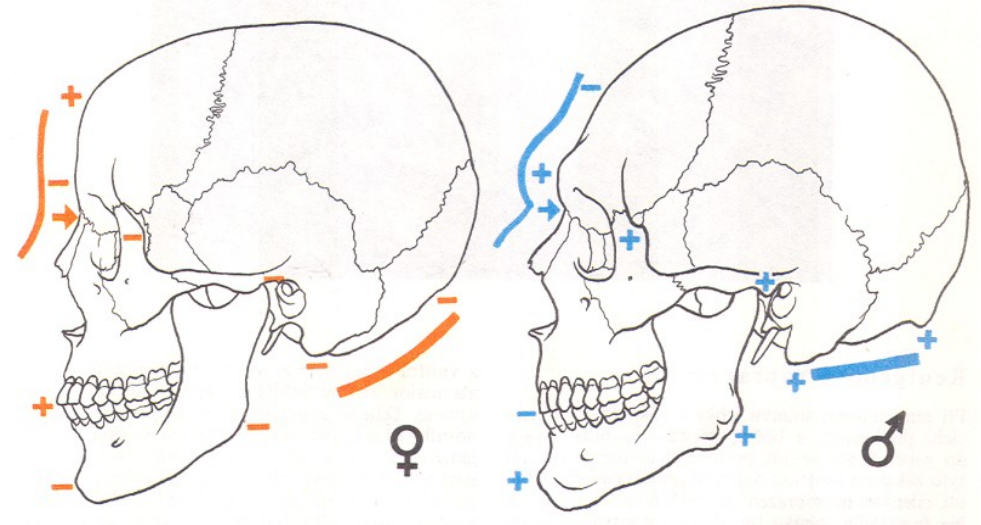




Proportion of the neurocranium and splanchnocranium of adult and newborn skulls

Gender differences (male and female skull)

- 1) Fronto-nasal region
- 2) Tuber frontale and parietale (*frontal and parietal tuberosity*)
- 3) Glabella
- 4) Processus mastoideus (*mastoid process*)
- 5) Arcus superciliares (*superciliary arches*)
- 6) Protuberantia occipitalis externa (*external occipital tuberosity*)
- 7) Regio nuchae (*nuchal region*)
- 8) Protuberantia mentalis (*mental tuberosity*)
- 9) Tuberositas masseterica (*masseter tuberosity*)
- 10) Processus alveolares (*alveolar processes of the mandible and maxilla*)



Used pictures come from:

Moore, K. L. (1992): Clinical oriented anatomy. Third edition.
Williams&Wilkins, A Waverly Company.

Gilroy, A. M. et al. (2009): Atlas of Anatomy. Thieme New York, Stuttgart.

Putz, R. (2008):
Atlas of Human Anatomy Sobotta. Elsevier Books.

Platzer, W., Kahle, W., Leonhardt H. (1992):
**Locomotor system. Georg Thieme Verlag, Stuttgart,
New York, 4th edition.**

Čihák, R. (1987): Anatomie 1. Avicenum, Zdravotnické nakladatelství.

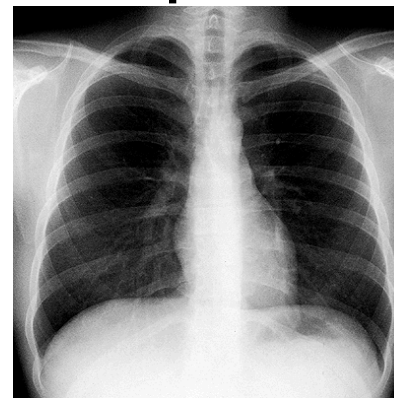
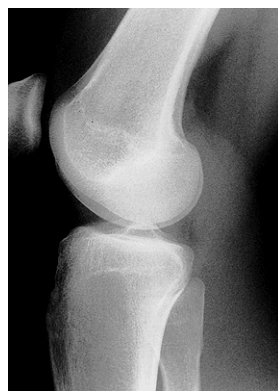Radiology and anatomy

1. Anatomy is essential for understanding radiology.
2. You will see anatomical structures this way much more frequently than during operation or autopsy.

X-ray (K. Roentgen 1895 – awarded by Nobel price in physics)

A highly penetrating beam of x-rays „transluminates“ the patient, showing tissues of differing densities on x-ray film.

A tissue or organ that is relatively dense absorbs (stops) more x-rays than a less dense tissue. Relatively fewer x-rays reach the silver emulsion in the film therefore only fewer grains of silver are developed at this area when the film is processed – „white area of bones“.



1. Simple X – ray
2. X– ray with contrast materials
 - a) positive (iodide preparations, barium meal)
 - b) negative (air, gases)
3. Projection according to the course of x-ray (anteroposterior, lateral)
4. New methods (sonography, CT (computerized tomography – using CT scanners, shows sections of the body – a small beam of x-rays is passed through a plane of the body while the x-ray tube moves in an arch or a circle around the body), MRI)

