

Connection of the upper limb - continuation

Juncturae radioulnares (*Connections of the forearm*)

Articulatio radioulnaris proximalis, articulatio radioulnaris distalis and membrana interossea antebrachii



A. Articulatio radioulnaris distalis (*distal radioulnar joint*)

Articular surfaces:

Articular capsule: is thin and loose ...

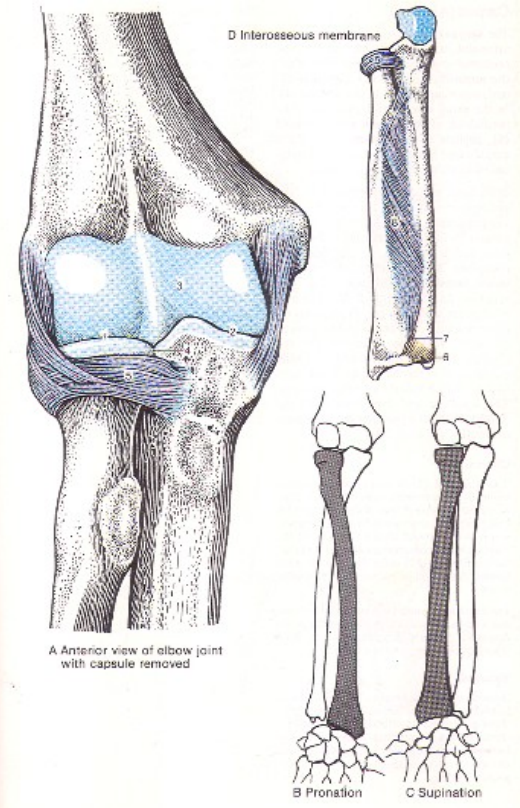
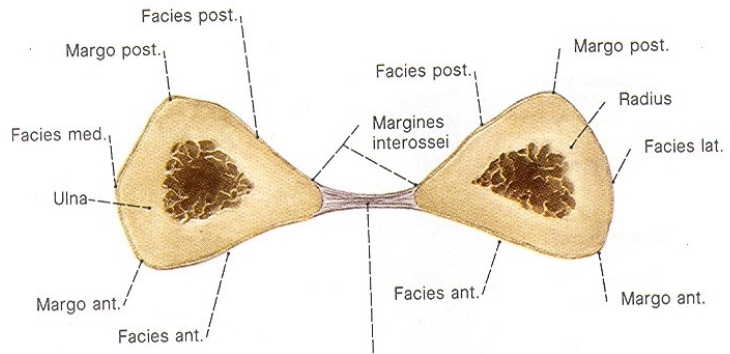
Auxiliary facilities: **discus articularis**, ligamentum radioulnare palmare and dorsale (*articular disc, radioulnar palmar and dorsal ligament*)

Type of joint: articulatio cylindroidea – *trochoid (pivot joint)*

Movements: rotation (pronation and supination).

B. Membrana interossea antebrachii

– serves for attachment of some muscles, it limits external rotation =supination, holds ulna and radius together



Articulationes manus (joints of the hand)

Articulatio radiocarpalis
(*radiocarpal joint*)

Articulatio mediocarpalis
(*mediocarpal joint*)

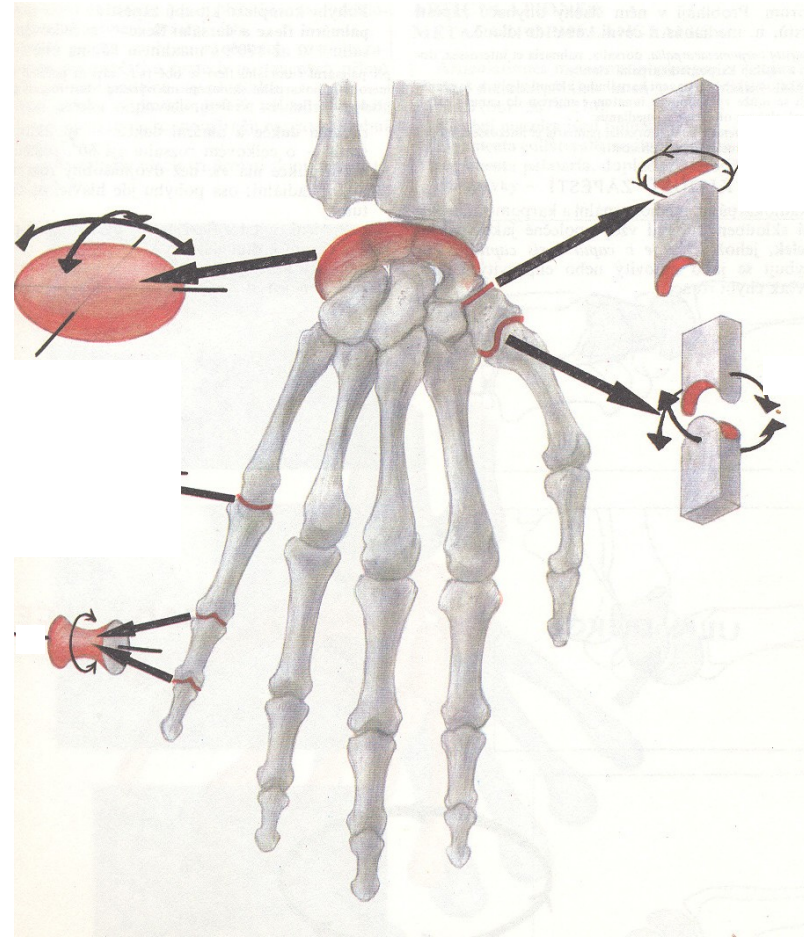
Articulatio ossis pisiformis

Articulatio carpometacarpalis pollicis

Articulationes carpometacarpales II.-V.

Articulationes metacarpophalangeales

Articulationes interphalangeales



4. Articulationes manus - Joints of the hand

A. Articulatio radiocarpalis (*radiocarpal joint*)

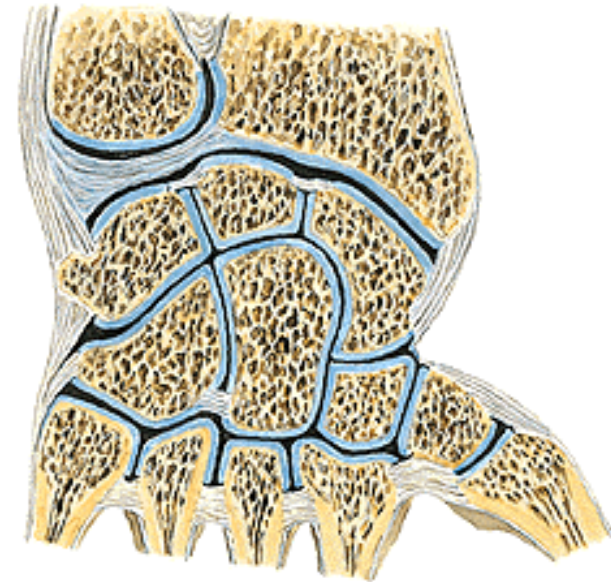
Articular surfaces: facies articularis carpea radii (*carpal articular facet of radius*) and os scaphoideum (*scaphoid bone*), *lunatum* and *triquetrum*

Articular capsule: shares together with articulatio mediocarpalis (*midcarpal joint*)

Auxiliary facilities: ulna is separated from carpal bones by *discus articularis* (*articular disc*). Ligaments shares with articulatio mediocarpalis (*midcarpal joint*)

Type of joint: articulatio ellipsoidea (*ellipsoidal joint*)

Movements: shares together with articulatio mediocarpalis (*midcarpal joint*)



B. *Articulatio mediocarpalis - midcarpal joint*

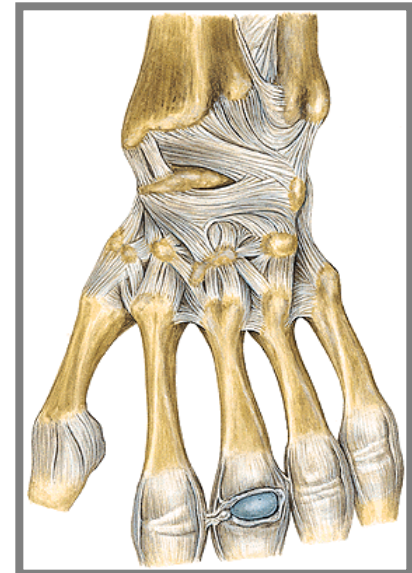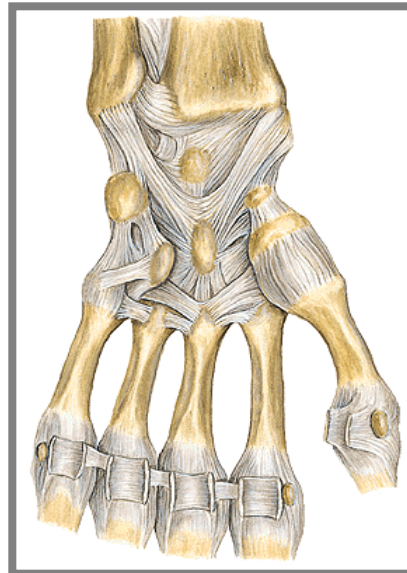
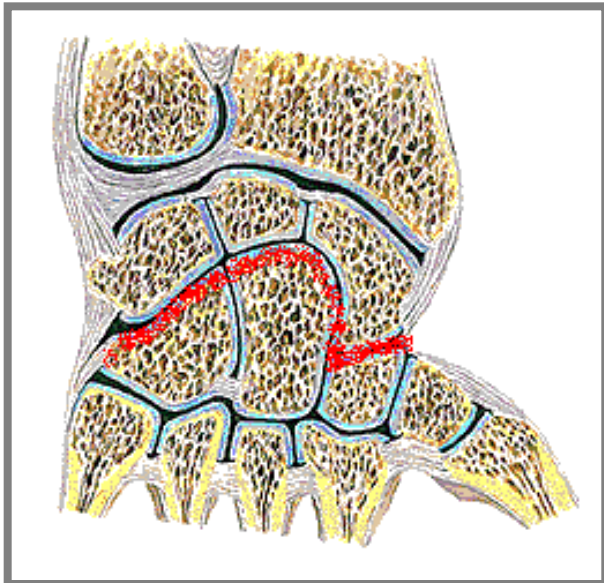
Articular surfaces:

Articular capsule: shares together with art. radiocarpalis (*radiocarpal joint*)

Auxiliary facilities: **lig. radiocarpeum** dorsale and palmare (*dorsal and palmar radiocarpal ligament*), **lig. ulnocarpeum palmare** (*palmar ulnocarpal ligament*), **lig. carpi radiatum** (*carpal radial ligament*), **ligg. intercarpea dorsalia, palmaria and interossea** (*intercarpal dorsal, palmar and interosseal ligaments*).

Type of joint: ellipsoid

Movements: together with art. radiocarpea (*radiocarpal joint*) – palmar and dorsal flexion, radial and ulnar duction and circumduction.



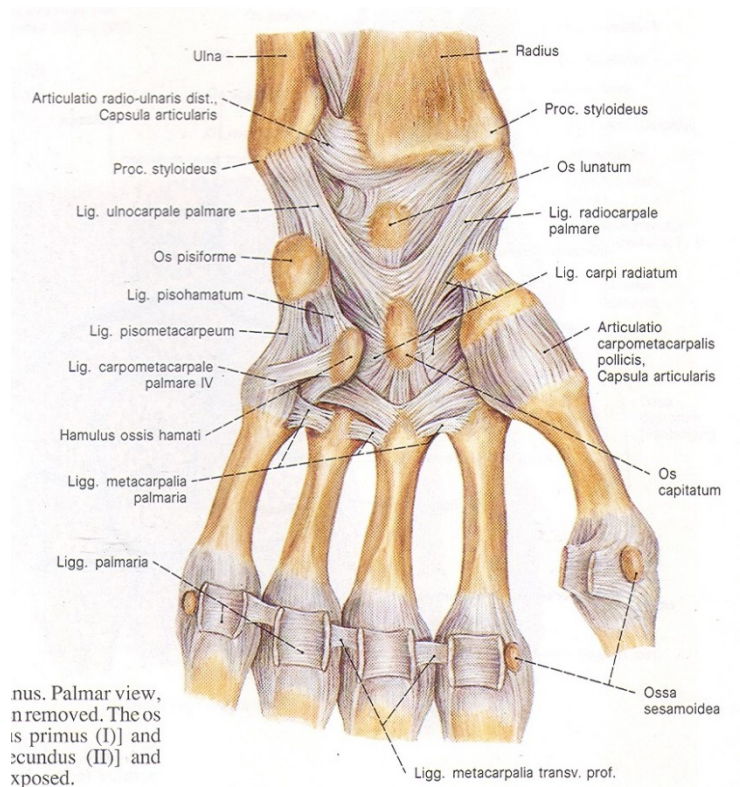
C. **Articulatio ossis pisiformis** (*Articulation of pisiforme bone*)

Articular surfaces:

Articular capsule:

Auxiliary facilities: articular capsule is reinforced by lig. pisohamatum and lig. pisometacarpeum.

Type of joint: amphiarthrosis



D. Articulatio carpometacarpalis pollicis

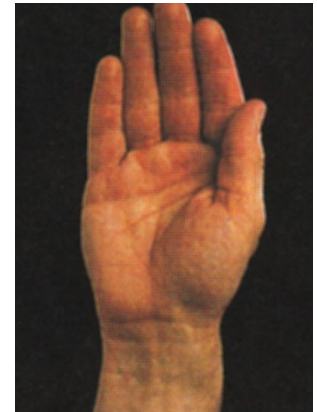
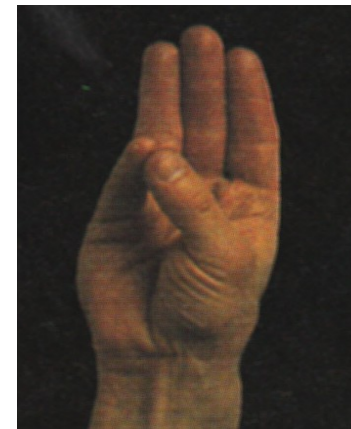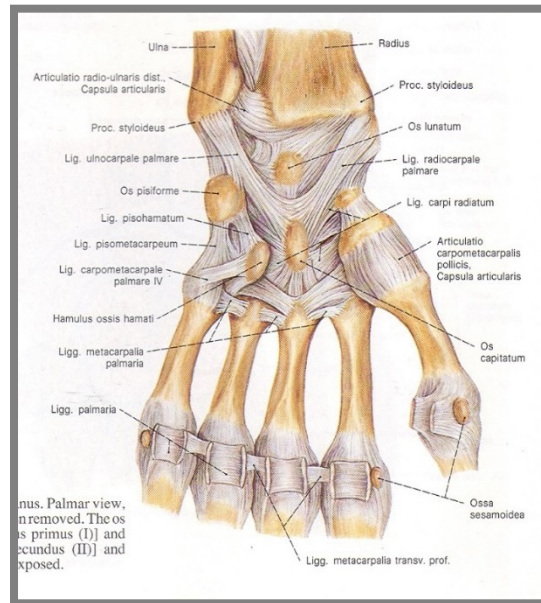
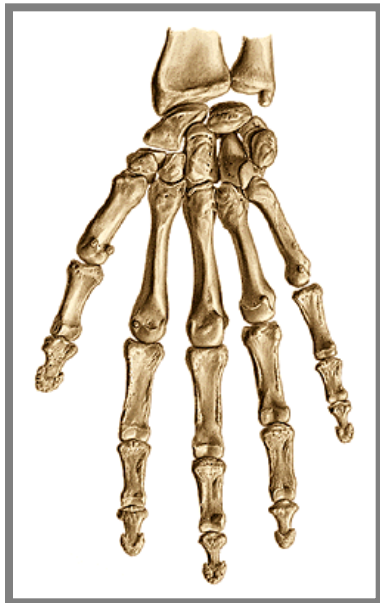(Carpometacarpal articulation of the thumb)

Articular surfaces: os trapezium and basis of the I. metacarpus (*metacarpal bone*)

Articular capsule: is relatively loose and it is attached to ...

Type of joint: articulatio sellaris (*saddle joint*)

Movements: abduction and adduction of the thumb, flexion and extension, opposition and reposition. Thumb is the most movable finger.



E. Articulationes carpometacarpales II. – V. (*carpometacarpal joints*)

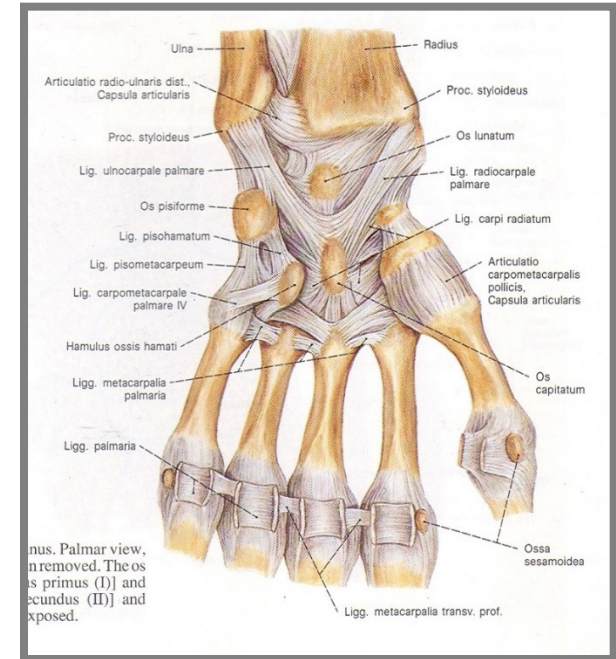
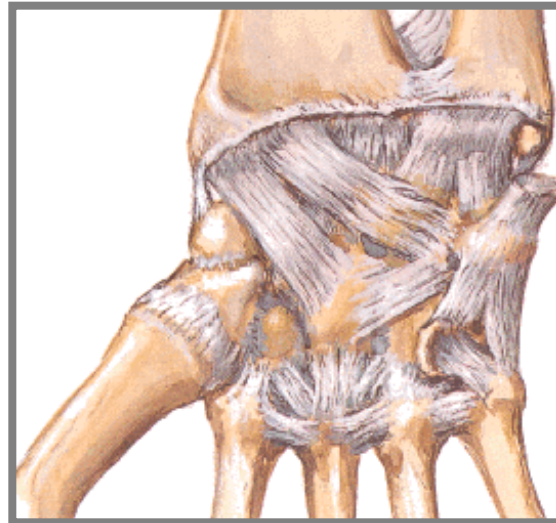
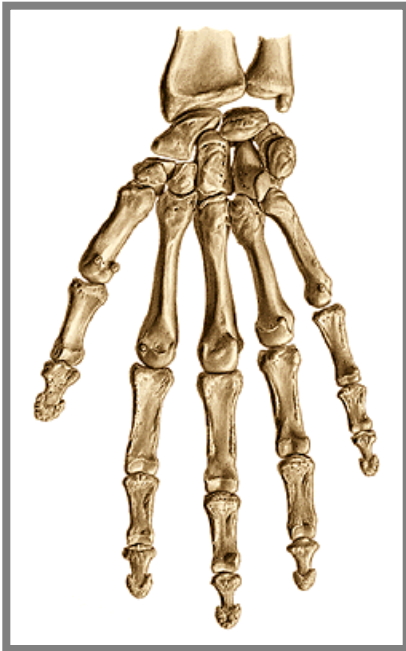
Articular surfaces:

Articular capsule: is attached to

Auxiliary facilities: (ligg. carpometacarpea palmaria, dorsalia and interossea) and in between bases of metacarpal bones ligg. metacarpea palmaria, dorsalia and interossea

Type of the joint: amphiarthrosis

Movements: minimal

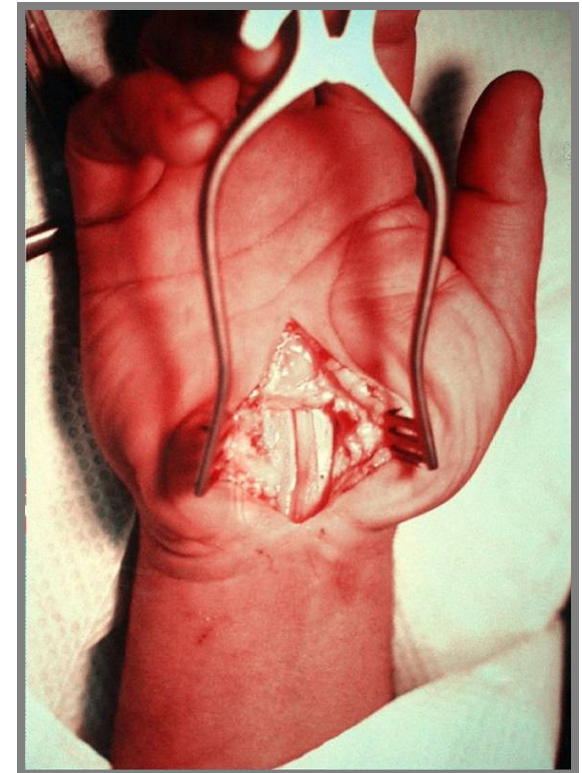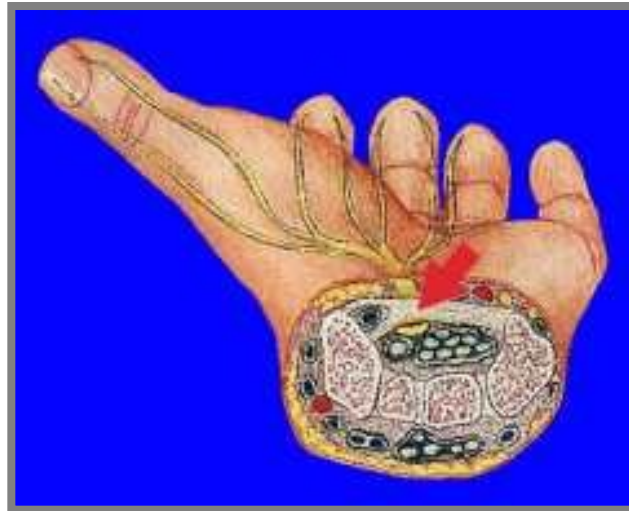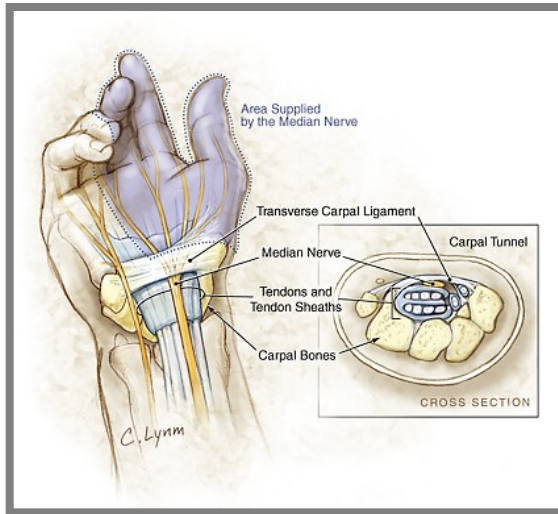


Sulcus carpi et canalis carpi

(Carpal groove and carpal canal)

ligamentum carpi transversum = **retinaculum flexorum**
(transverse carpal ligament) between eminentia carpi medialis and lateralis

Sulcus carpi + ligamentum carpi transversum = **canalis carpi**
(Carpal groove + transverse carpal ligament = carpal canal)



F. Articulationes metacarpophalangeae (*metacarpophalangeal joints*)

Articular surfaces:

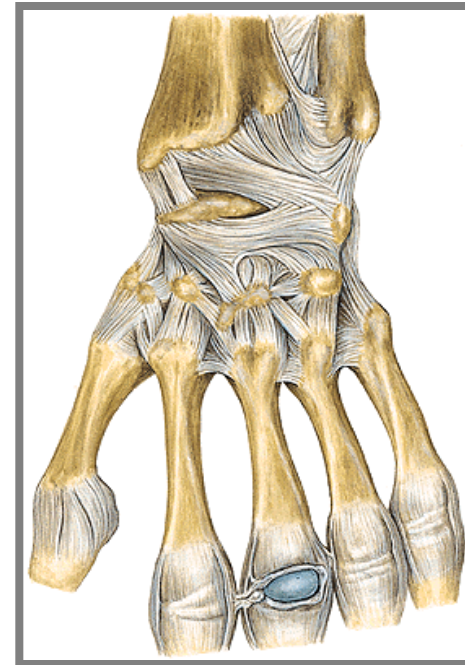
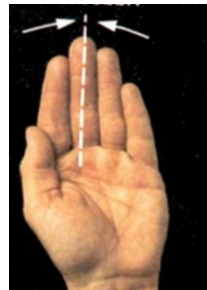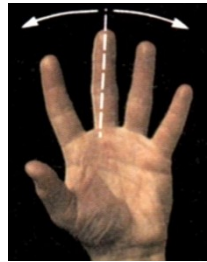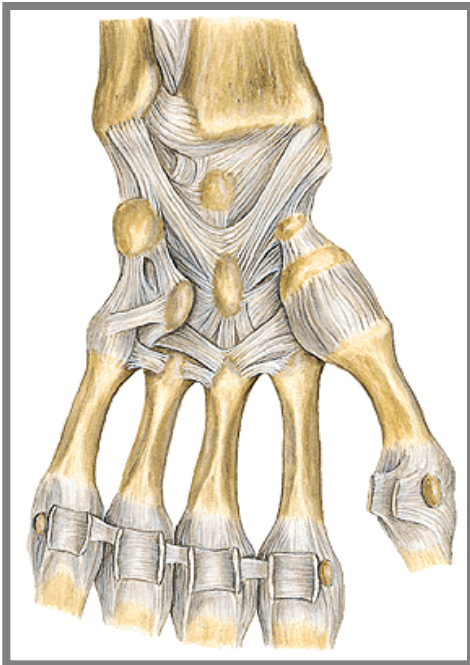
Articular capsule:

Auxiliary facilities: *laminae fibrocartilagineae palmares* (*palmar fibrocartilagineous plates*) and *ligg. collateralia* (*collateral ligaments*). Sesamoid bones (thumb).

II. to V. metacarpals are joined by *ligamentum metacarpeum transversum profundum* (*transverse metacarpal profound ligament*)

Type of joint: *articulatio ellipsoidea* (*ellipsoidal*)

Movements: flexion, extension, abduction and adduction



G. Articulationes interphalangeae manus (*interphalangeal joints*)

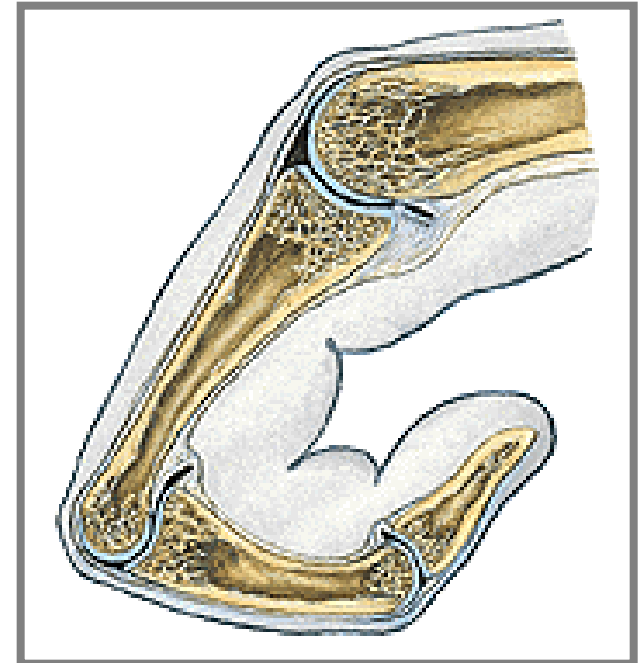
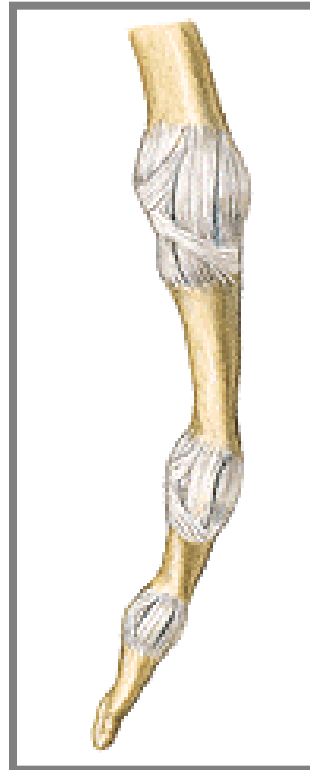
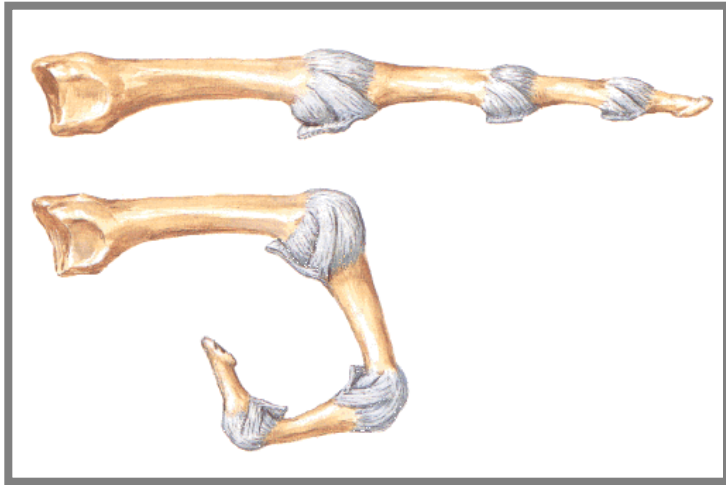
Articular surfaces:

Articular capsule:

Auxiliary features: lamina fibrocartilaginea palmaris (*palmar fibrocartilaginous lamina*),
ligg. collateralia (*collateral ligaments*)

Type of joint: trochlearis (*hinge*)

Movements: flexion and extension, distal phalanx even hyperextension



Connection of the lower limb bones

(juncturae ossium extremitatis inferioris)

includes connection of pelvic girdle and free part of lower limb

Connection of juncturae ossium cinguli extremitatis inferioris (*pelvic girdle*)

1. *Articulatio sacroiliaca* (*sacroiliac joint*)

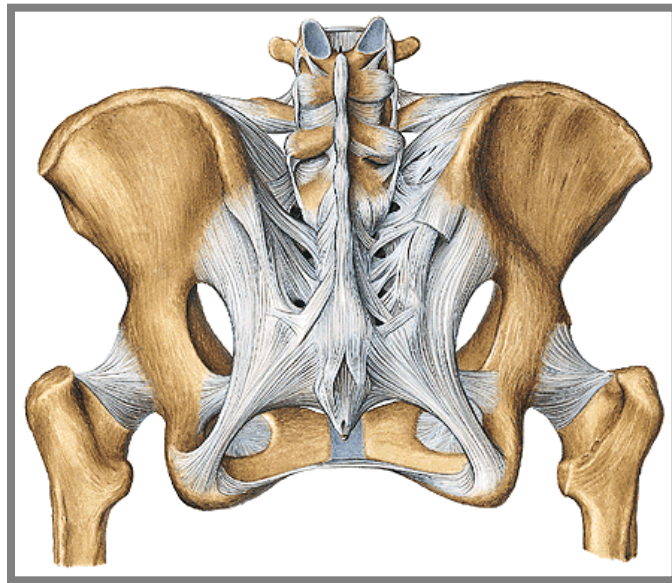
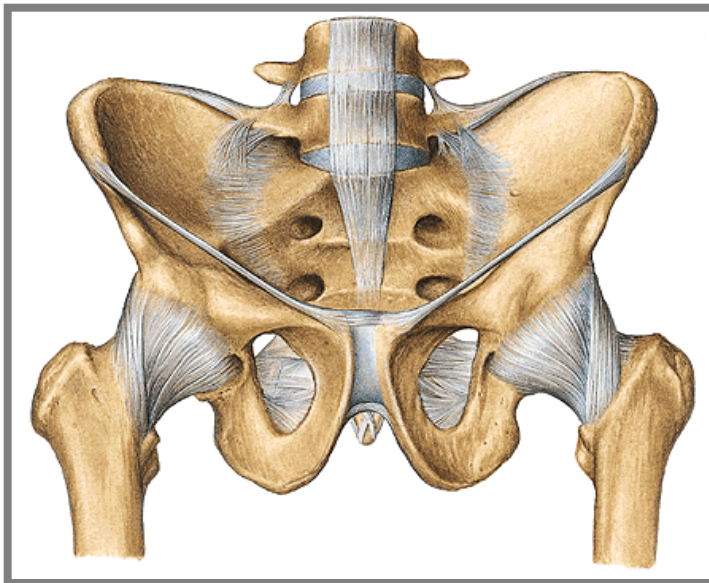
Articular surfaces:

Articular capsule: tight and is attached to.....

Auxiliary facilities: *ligg. sacroiliaca ventralia* and *dorsalia* (*ventral and dorsal sacroiliac ligaments*), *ligg. sacroiliaca interossea* (*interosseal sacroiliac ligaments*)

Type of joint: amphiarthrosis

Movements: minimal



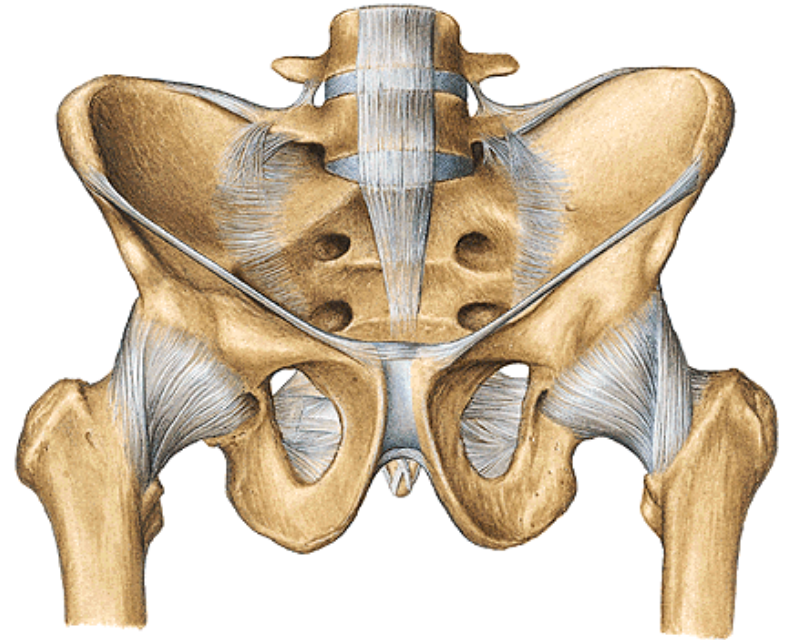
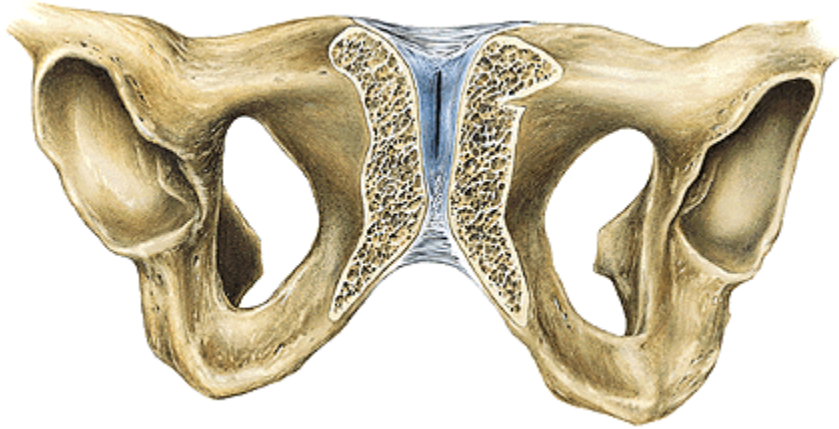
2. Symphysis pubica

cartilagenous *discus interpubicus* connects both pubic bones. Symphysis pubica is 4,5 – 5 cm in height.

lig. pubicum superius (*superior pubic ligament*) and stronger lig. arcuatum pubis (*arcuate pubic ligament*)

3. Membrana obturatoria

a stiff membrane which closes foramen obturatum (canalis obturatorius)



4. Ligaments in the pelvic region

Lig. sacrospinale (*Sacrospinal ligament*)

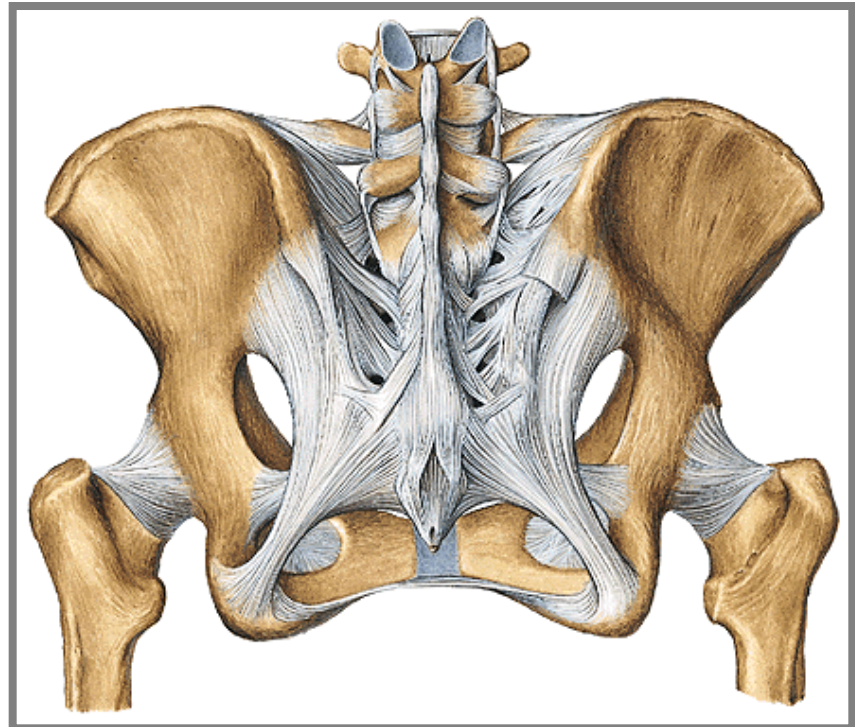
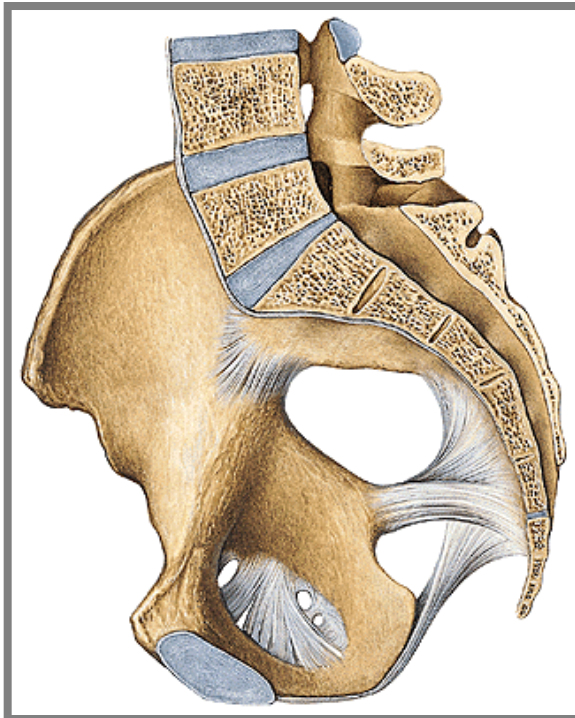
Lig. sacrotuberale (*Sacrotuberous ligament*)

Foramen ischiadicum majus (*Greater sciatic foramen*)

(Foramen suprapiriforme and foramen infrapiriforme - *Supra- and infrapiriform foramen*)

Foramen ischiadicum minus (*Lesser sciatic foramen*)

Lig. iliolumbale

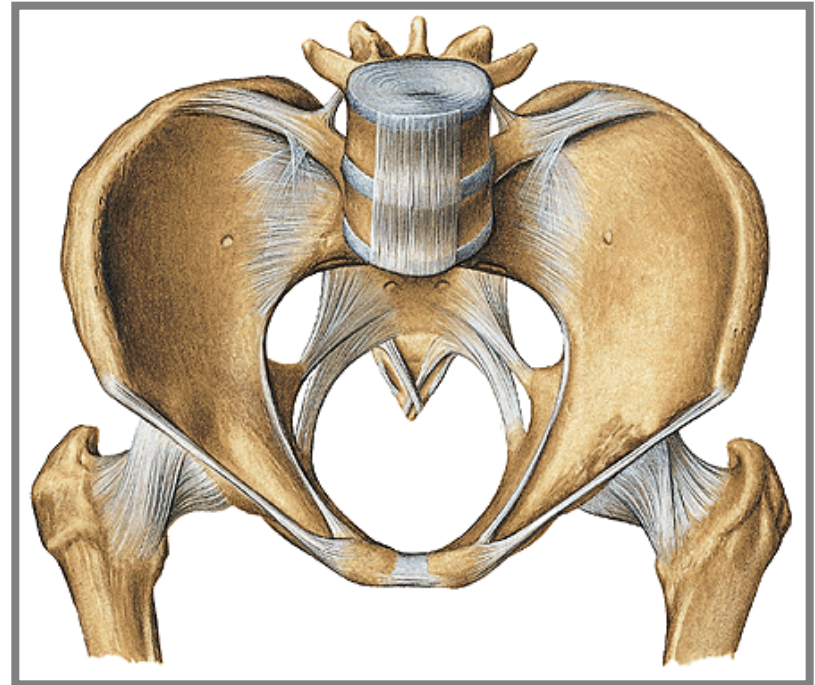
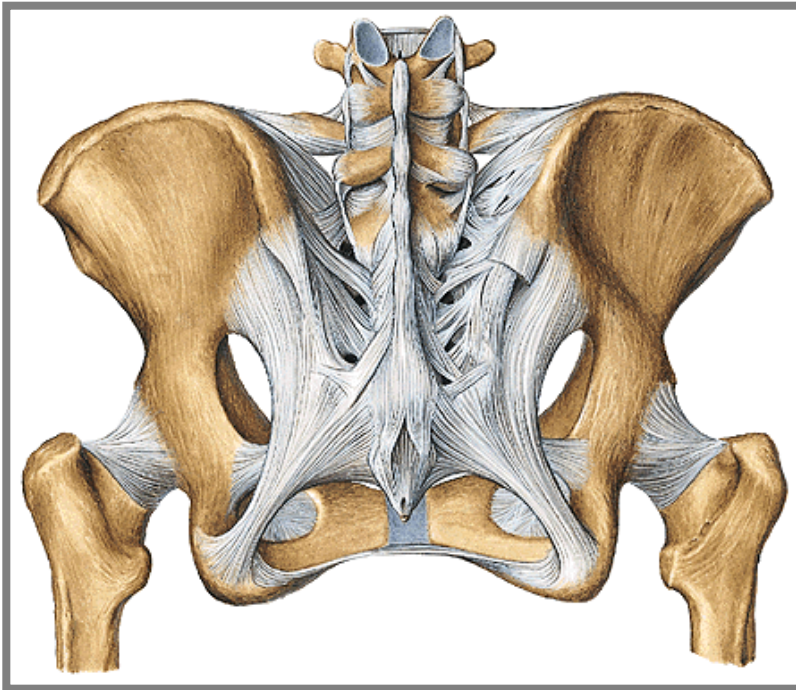


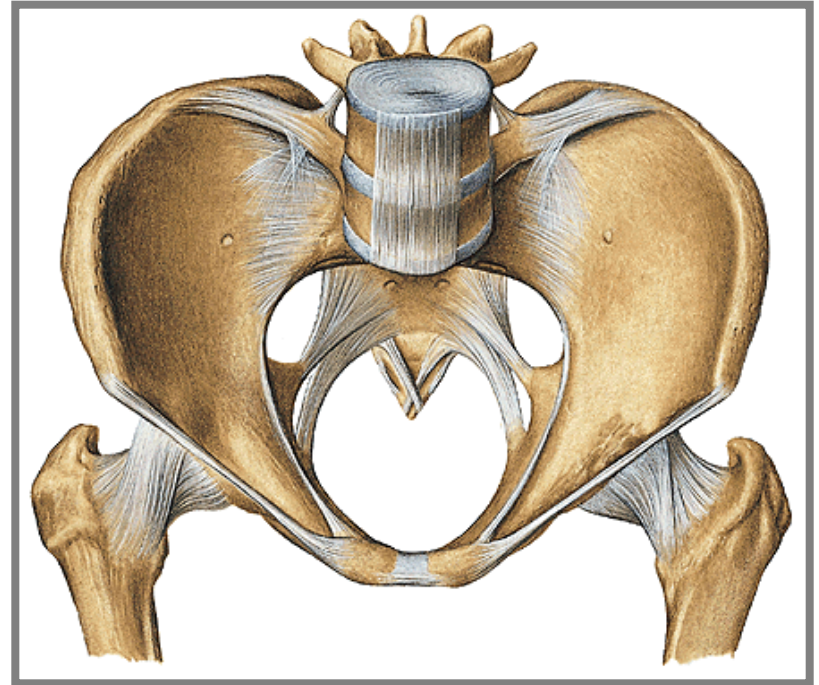
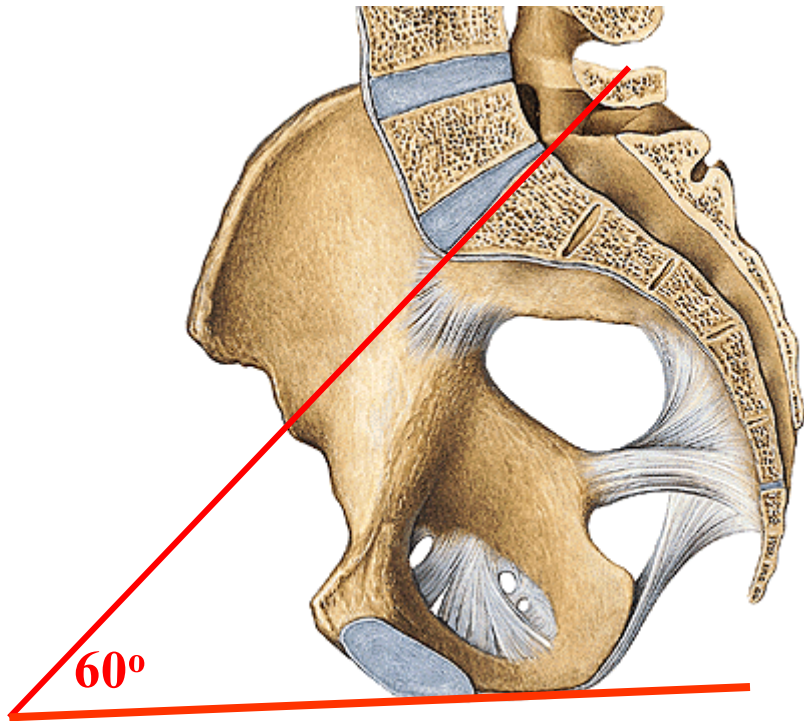
5. Pelvis major and minor (*greater and lesser pelvis*)

Aditus pelvis (*the pelvic inlet*) is bordered by linea terminalis which separates pelvis major and pelvis minor (*greater and lesser pelvis*).

Exitus pelvis (*the pelvic outlet*) is the region between the angulus subpubicus (*subpubic angle*), tubera ischiadica (*sciatic tuberosity*) and os coccygis

Pelvis minor (*lesser pelvis*) is „true pelvis“ (genital organs, a part of urinary and digestive system), an important childbirth way in female, it has great intersexual differences.

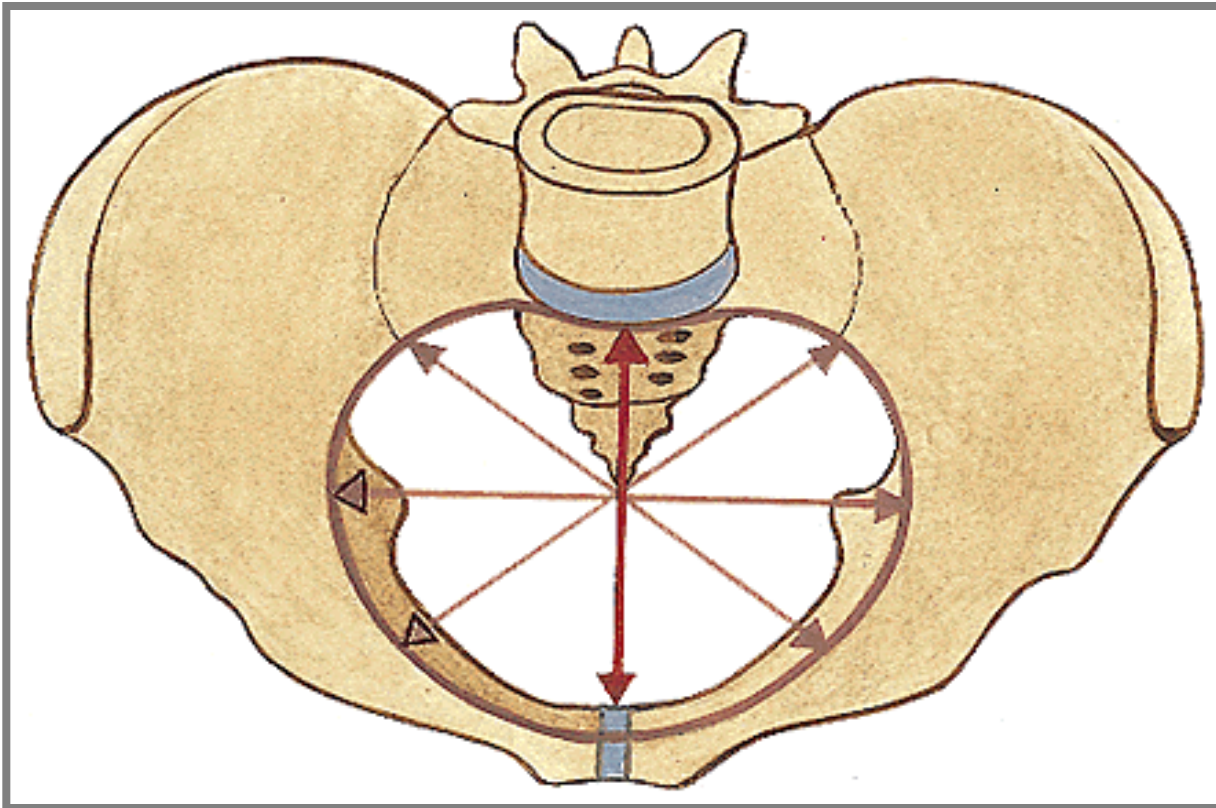
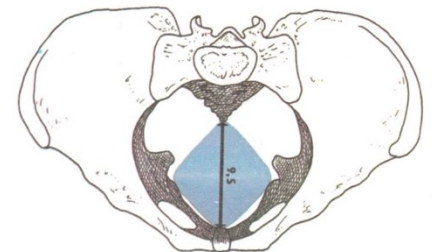
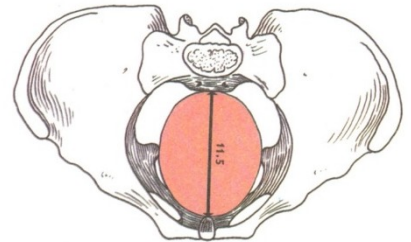
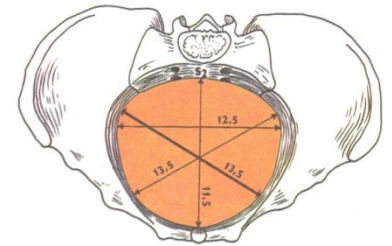
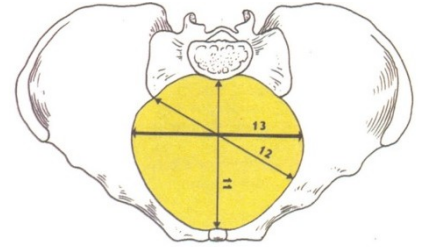




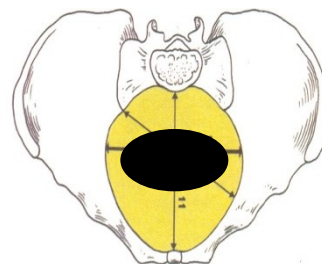
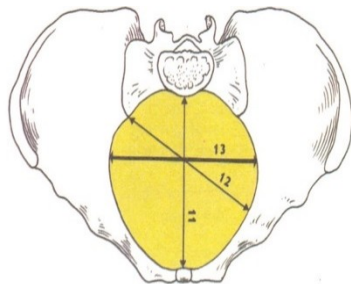
Inclinatio pelvis

Internal diameters of pelvis

1. **Aditus pelvis** = apertura pelvis superior (*inlet*) transverse diameter about 13 cm
2. **Amplitudo pelvis** (*width of pelvis*) about 12 cm
3. **Angustia pelvis** (*narrow part of bone pelvis*) about 10 cm
4. **Exitus pelvis**=apertura pelvis inferior (*outlet*) about 9 cm
5. **Conjugata diagonalis** 12.5 – 13 cm (per vaginam)

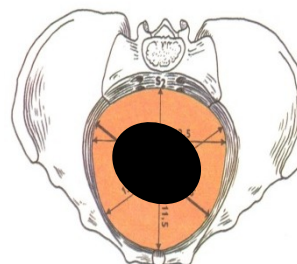
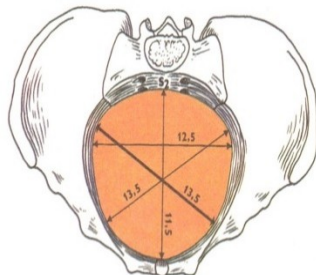


Aditus pelvis
(inlet)



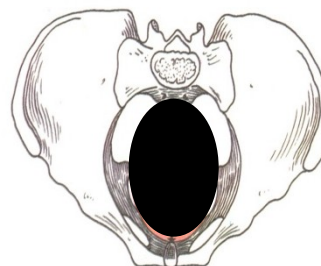
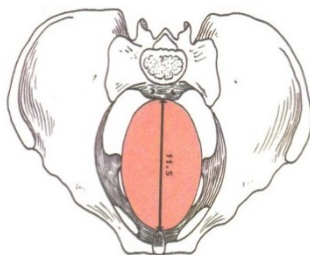
13 cm

Amplitudo pelvis
(width of pelvis)



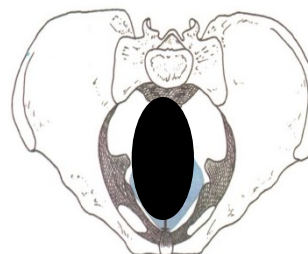
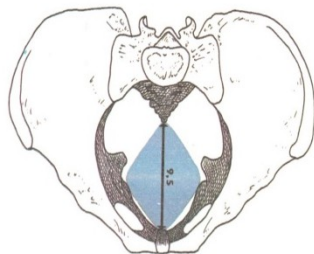
12 cm

Angustia pelvis
(narrow part)



10 cm

Exitus pelvis
(outlet)



9 cm

B. External diameters of pelvis

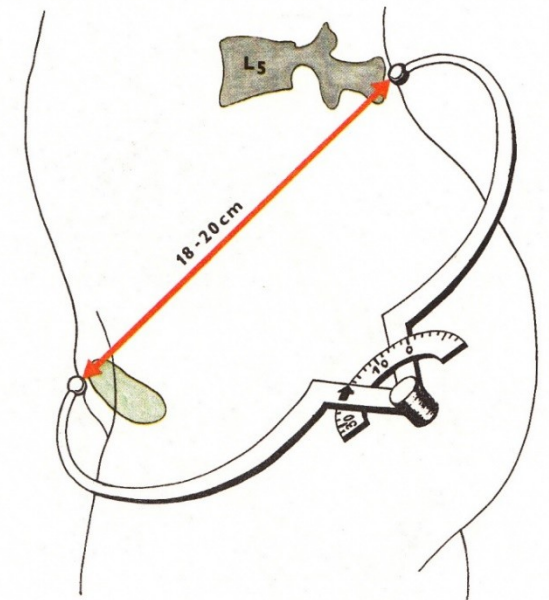
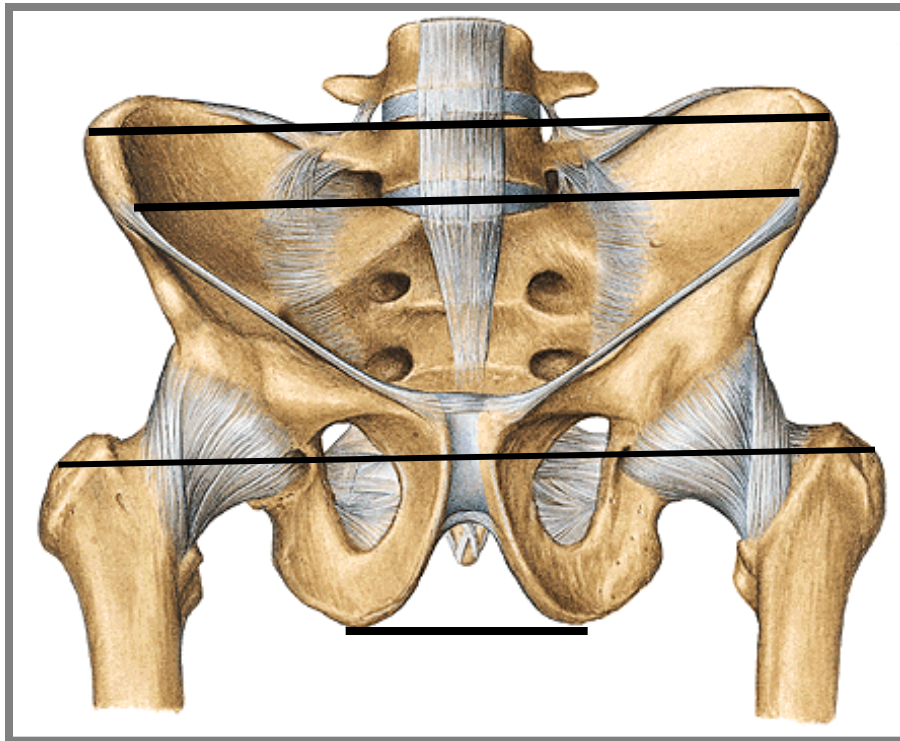
Distantia bispinalis (*bispinal diameter*) (about 26 cm)

Distantia bicristalis (*bicristal diameter*) (about 29 cm)

Distantia bitrochanterica (*bitrochanteric diameter*) (about 31 cm)

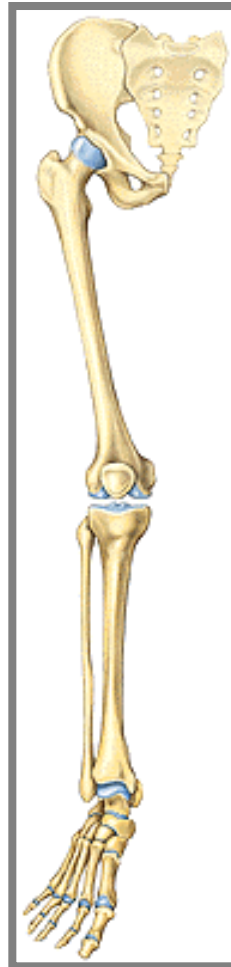Distantia bituberalis (*bituberal diameter*) (about 12 cm)

Conjugata externa (min. 18 cm)



Connection of free part of lower limb

(juncturae ossium extremitatis liberae inferioris)



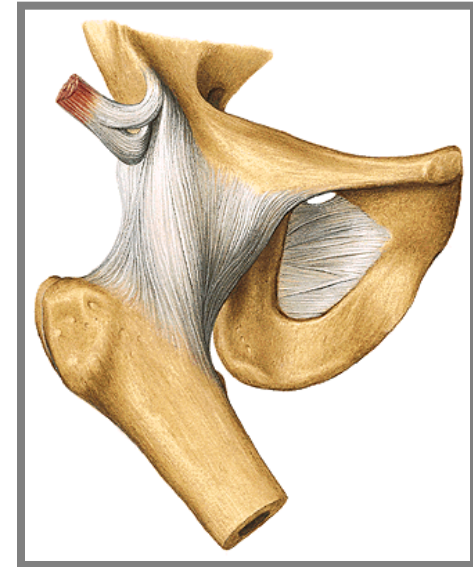
1. Articulatio coxae (*hip joint*)

Articular surfaces: facies lunata (*lunate facet*) of the acetabulum only !!!!!.....

Articular capsule: is attached to the margins of acetabulum. It reaches ventrally to linea intertrochanterica of femur, dorsally is attached to the collum femoris (*neck of femur*) medially away from fossa trochanterica.

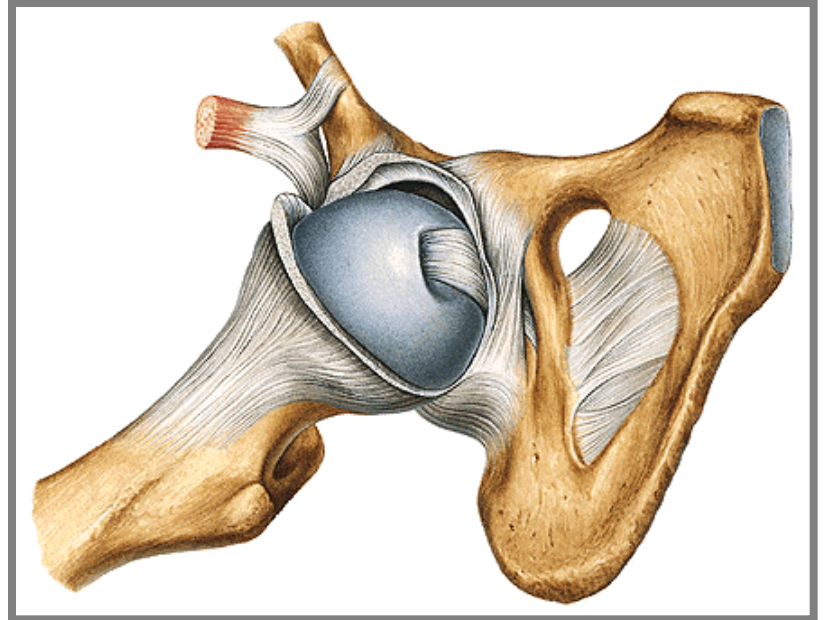
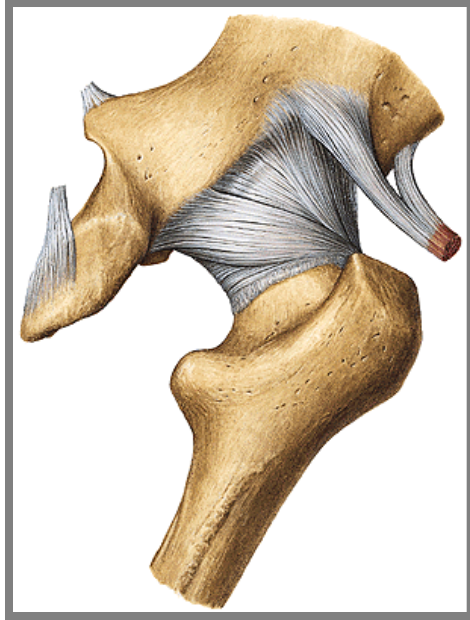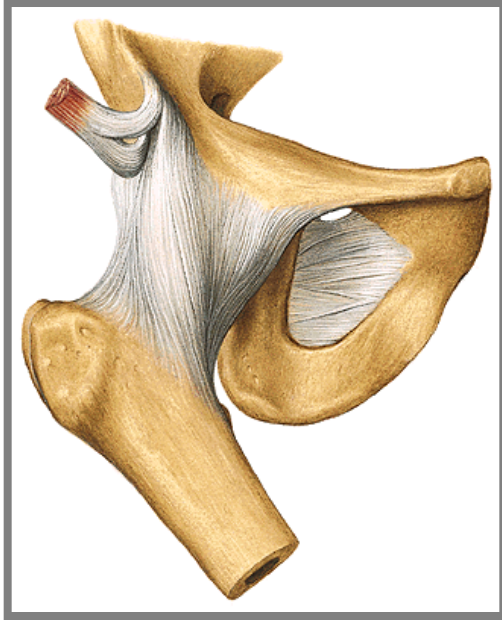
Auxiliary facilities:

- a) **Labrum acetabulare** formed by cartilage and fibrous tissue
- b) **Lig. transversum acetabuli** runs through incisura acetabuli.
- c) **Lig. iliofemorale** (the strongest lig.)
- d) **Lig. pubofemorale**
- e) **Lig. ischiofemorale**
- f) **Zona orbicularis**
- g) **Lig. capitis femoris**

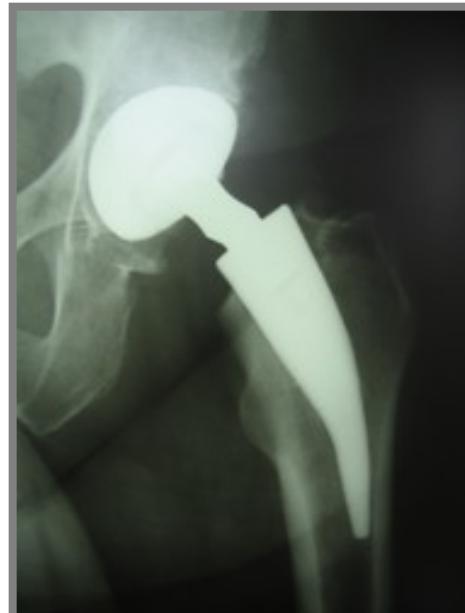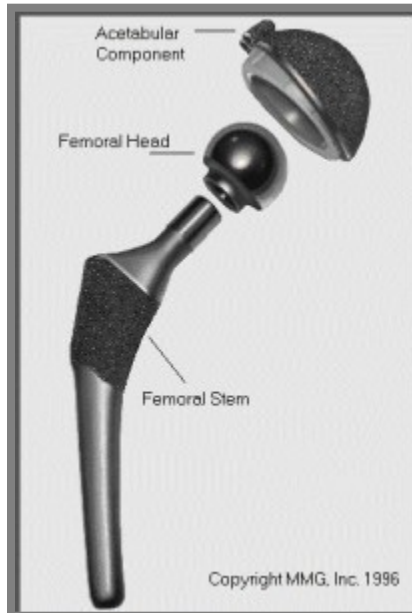
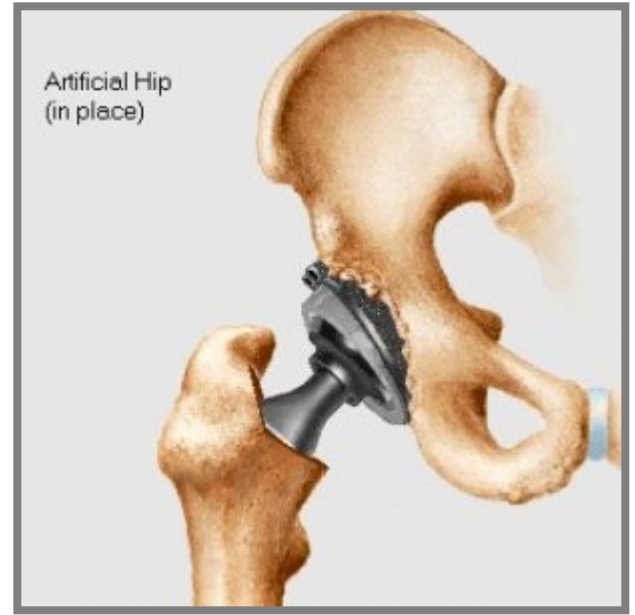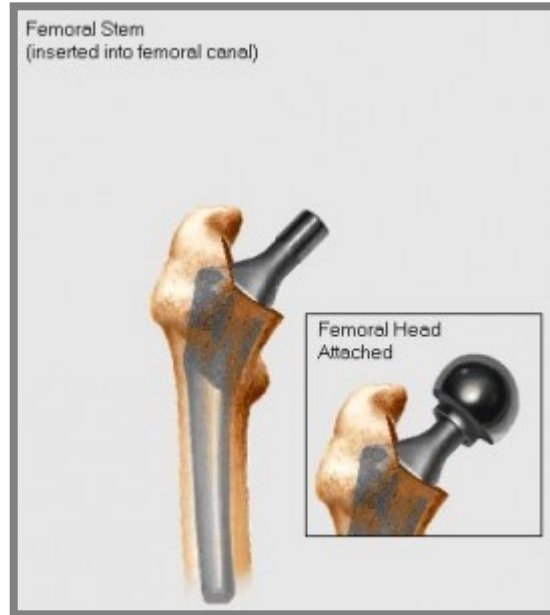
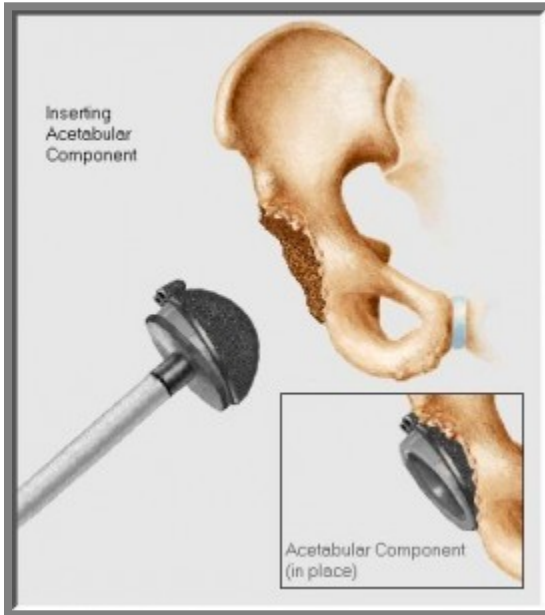


Type of joint: typical spheroid joint (*ball-and-socket*) with restricted movements (*enarthrosis*).

Movements: abduction, adduction, flexion, extension, pronation, supination



Total endoprosthesis of hip joint

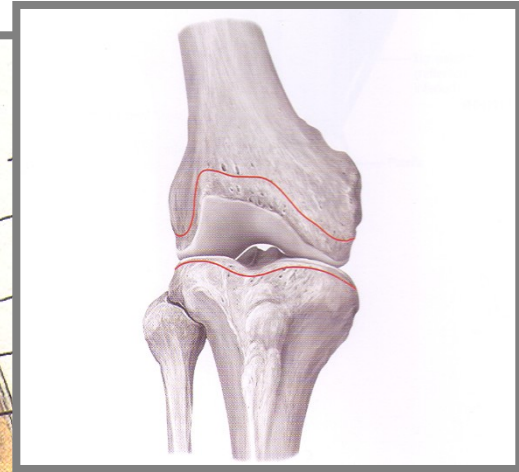
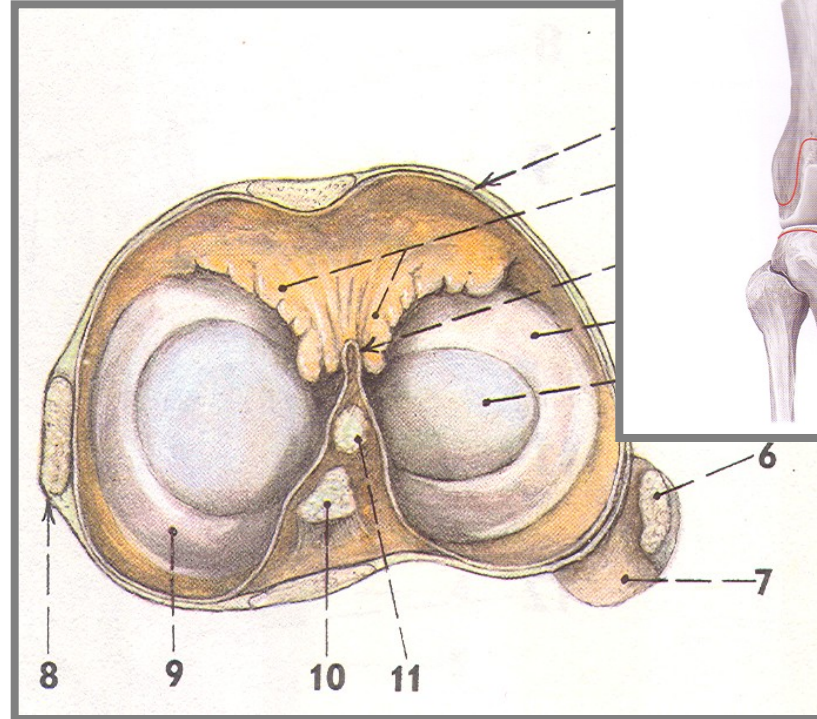
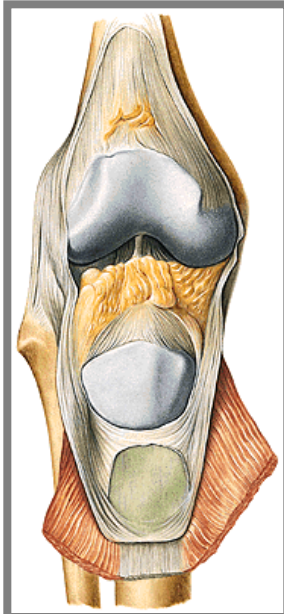
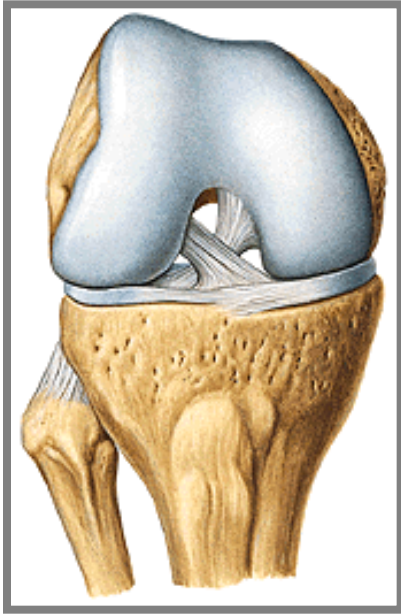


2. Articulatio genus (*knee joint*)

Articular surfaces:

Articular capsule: is strong, attached proximally a little above articular surface of the femur.

Capsula synovialis lines all articular cavity and runs from the sides to *ligg. cruciata* genus (*cruciate ligaments*) and continues ventrally as a **plica synovialis patellaris** (*synovial patellar plica*), ventrally is divided into two **plicae alares** (*alar plicae*).



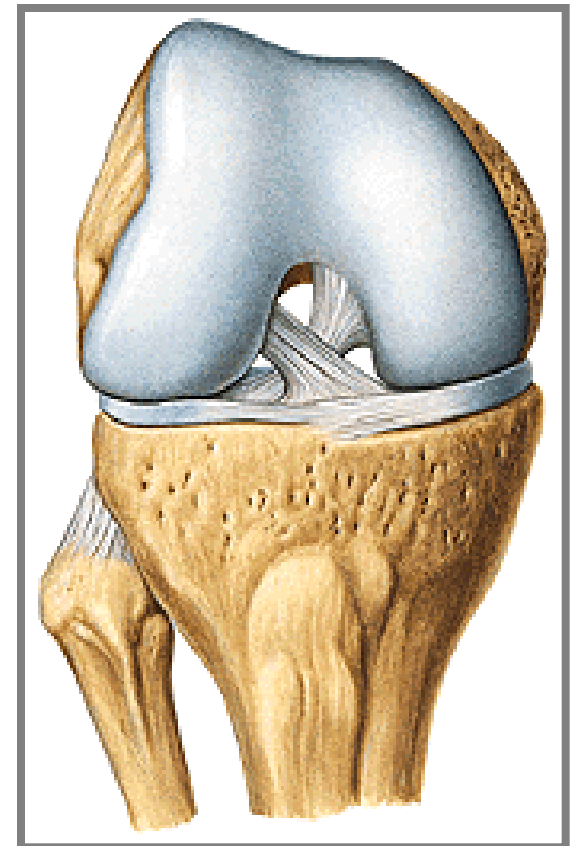
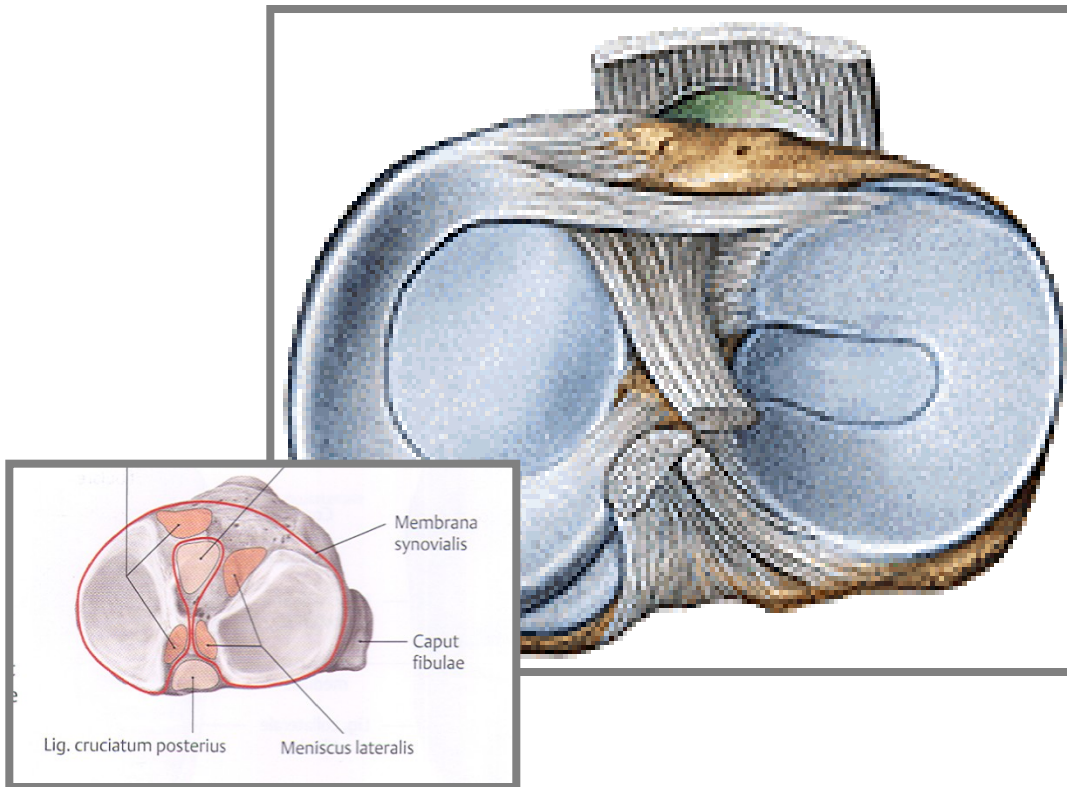
I. Intraarticular auxiliary facilities of the *articulatio genus* (knee joint):

1. **Meniscus** – Medial and lateral

2. **Ligamenta cruciata genus** (*cruciate ligaments of knee*):

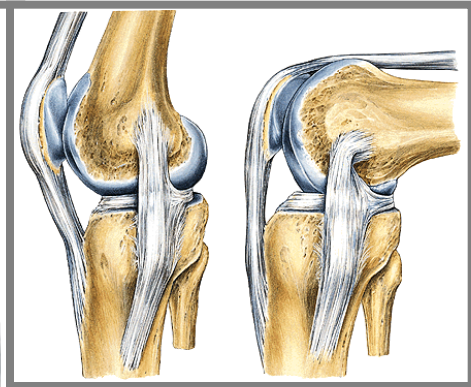
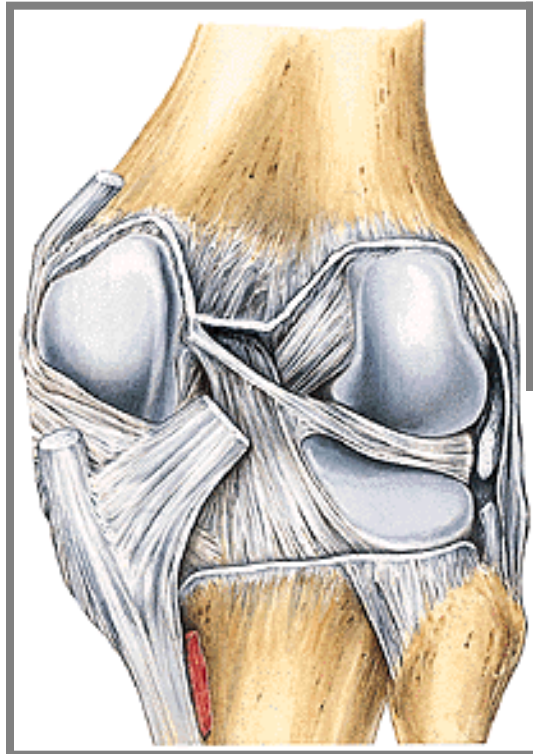
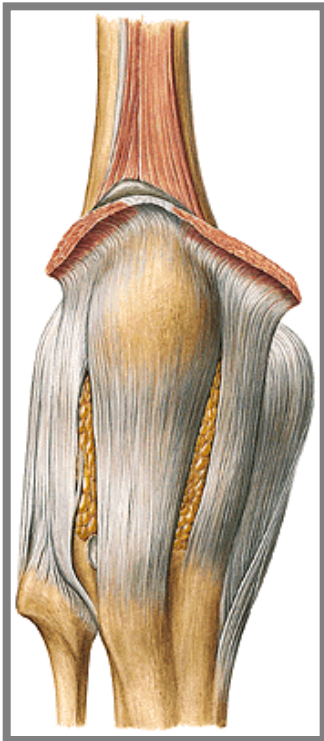
– **anterius** - limits extension and medial rotation

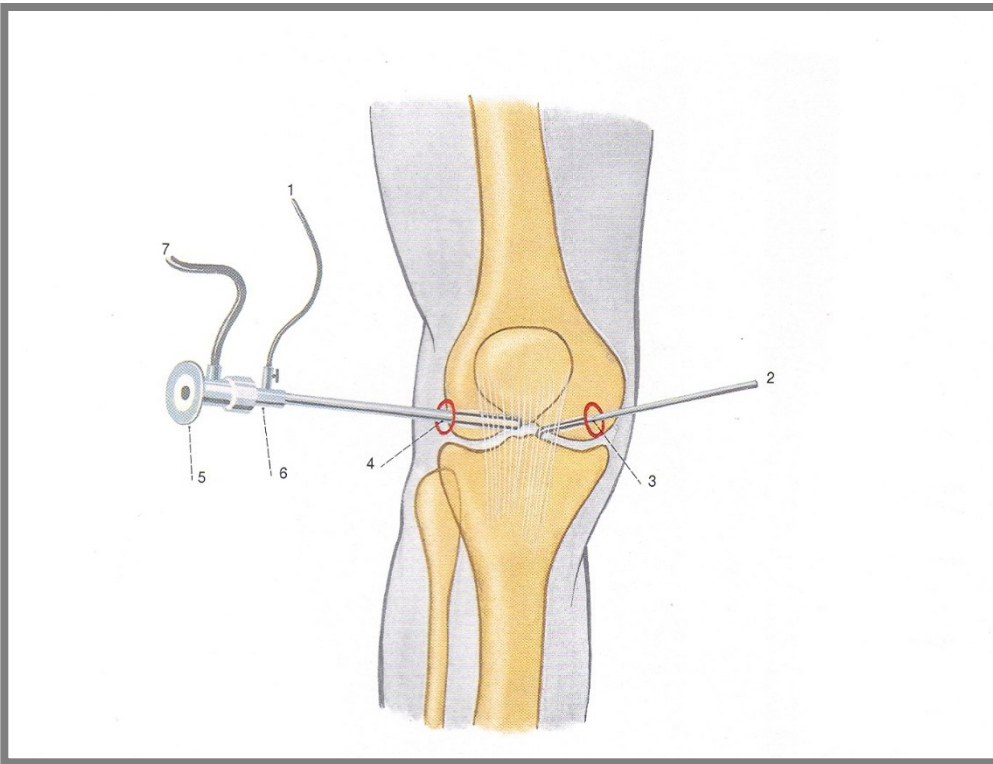
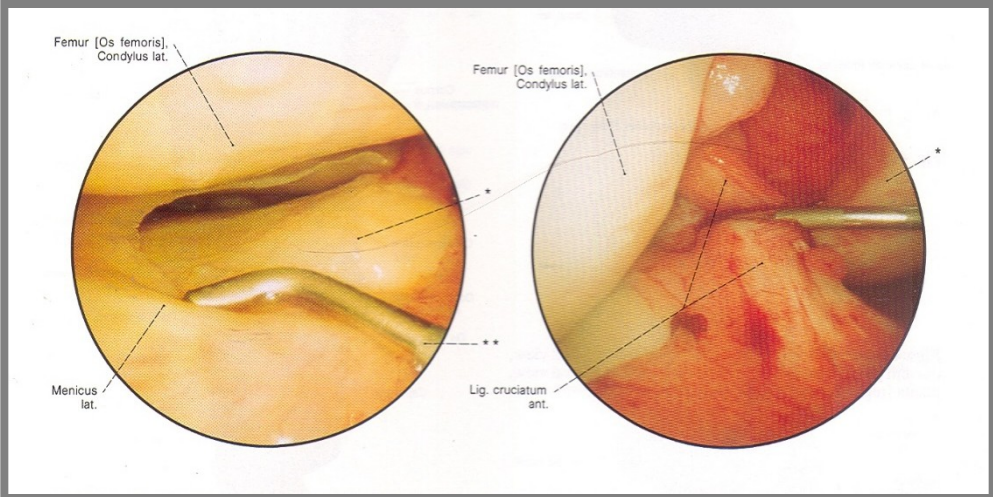
– **posterius** - limits extension and keeps stability of the joint



2. Extraarticular auxiliary facilities of articulatio genus

- a) **lig. patellae** (*patellar ligament*) – continuation of the m. quadriceps femoris tendon
- b) **retinacula patellae mediale and laterale**
- c) **lig. collaterale tibiale** (*collateral tibial ligament*)
- d) **lig. collaterale fibulare** (*collateral fibular ligament*)
- e) **lig. popliteum obliquum** (*oblique popliteal ligament*)





Arthroscopy

Bursae synoviales

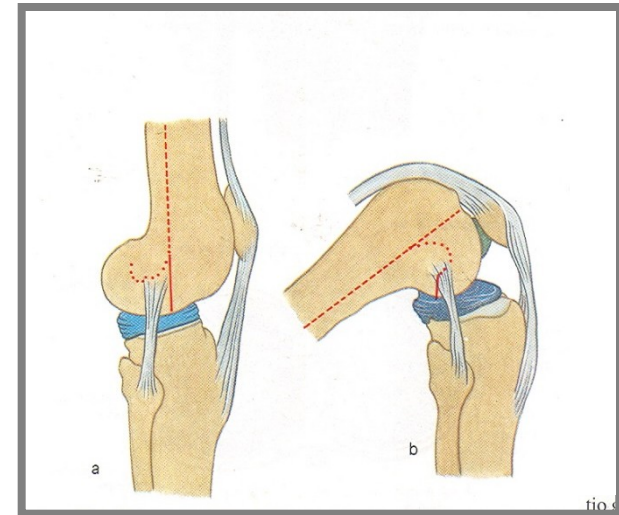
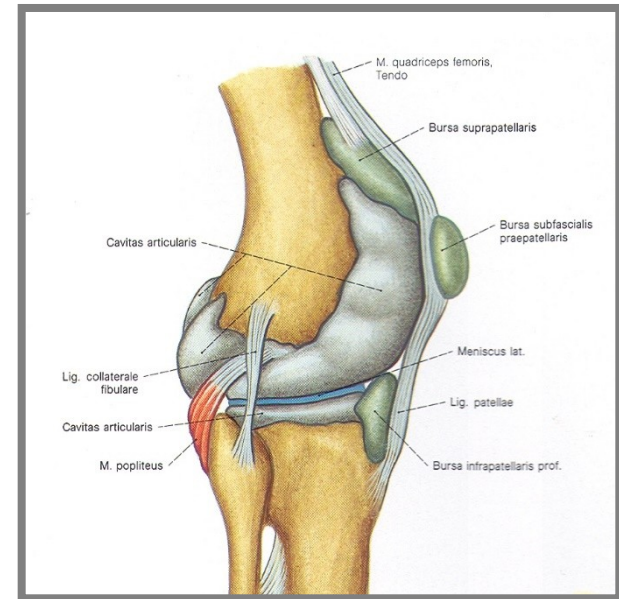
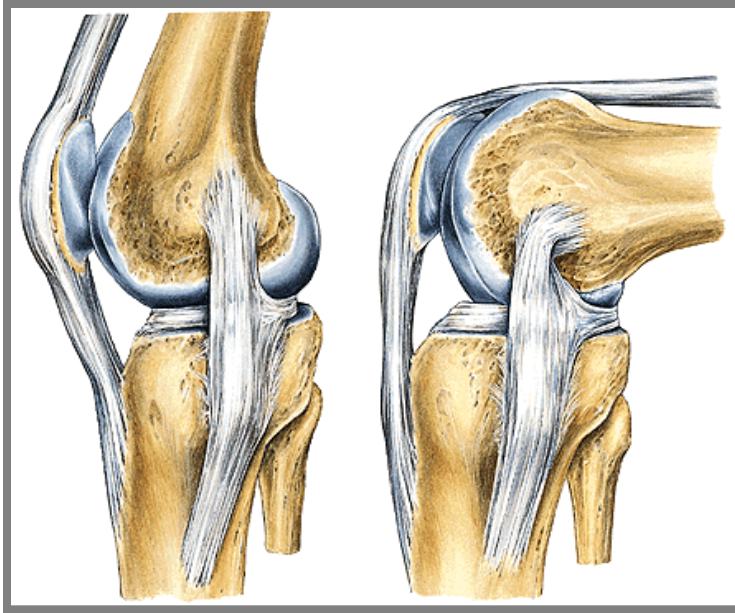
Suprapatellaris, praepatellaris (subcutanea),
infrapatellaris

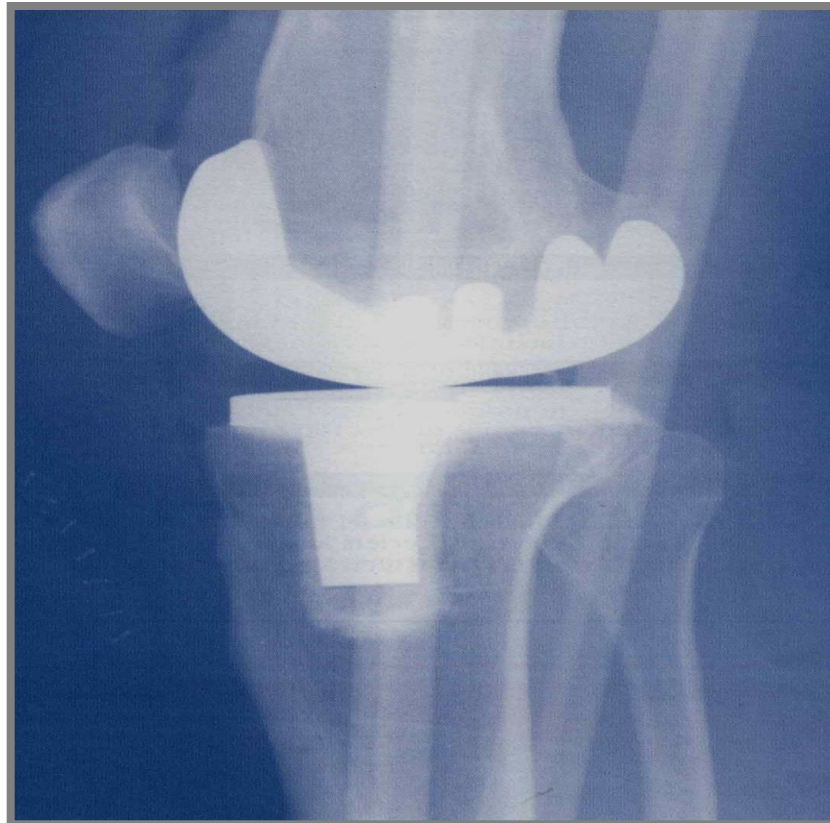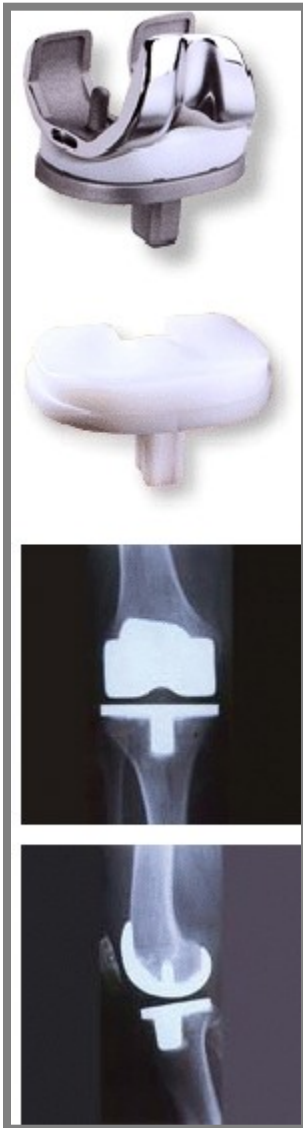Type of joint: hinge joint (trochoginglymus)

Movements: flexion and extension

During a slight flexion - slight external
and internal rotation

Middle position of the joint – slight flexion





Endoprosthesis of the knee joint

3. **Juncturae tibiofibulares** (*tibiofibular connections*)

Articulatio tibiofibularis, membrana interossea cruris and syndesmosis tibiofibularis.

A. Articulatio tibiofibularis (*tibiofibular joint*)

Articular surfaces:

Articular capsule: is short, stiff and attached to....

Auxiliary facilities: *lig. capitis fibulae anterius* and *posterius*

Type of joint kloubu: plane

Movements: slight movements ahead and back.

B. Membrana interossea cruris

stiff membrane. Serves as a site for insertion of some muscles.

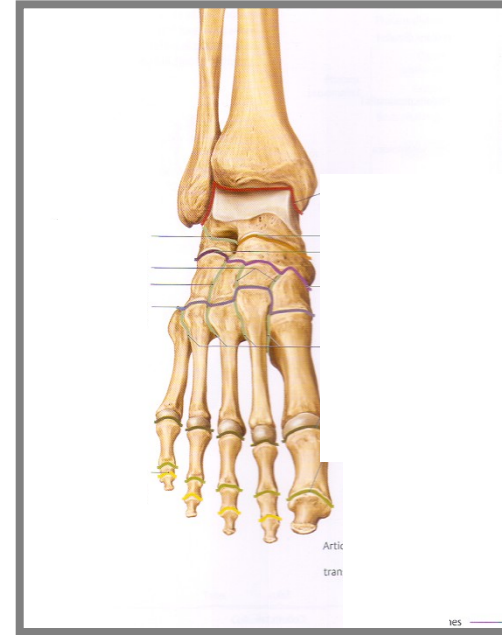
C. Syndesmosis tibiofibularis = *fibrous joint* between distal ends of tibia and fibula

Syndesmosis is reinforced by *lig. tibiofibulare anterius* and *lig. tibiofibulare posterius* (*tibiofibular anterior and posterior ligaments*).



Articulationes pedis (Joints of foot)

1. **Articulatio talocruralis** (*Talocrural joint*)
2. **Articulationes intertarseae** (*Intertarsal joints*)
 - Articulatio subtalaris (*subtalar joint*)
 - Art. talocalcaneonavicularis (*talocalcaneal joint*)
 - Art. calcaneocuboidea (*calcaneocuboid joint*)
 - „Articulatio tarsi transversa“ (*Chopart's joint*)
 - Articulatio cuneonavicularis (*Cuneonavicular joint*)
 - Articulatio cuneocuboidea (*Cuneocuboid joint*)
3. **Articulationes tarsometatarsae** (*Tarsometatarsal joints*) – **Lisfranck's joint**
4. **Articulationes metatarsophalangeae** (*Metatarsophalangeal joints*)
5. **Articulationes interphalangeae pedis** (*Interphalangeal joints*)



A. Articulatio talocruralis (*talocrural joint*)

Articular surfaces:

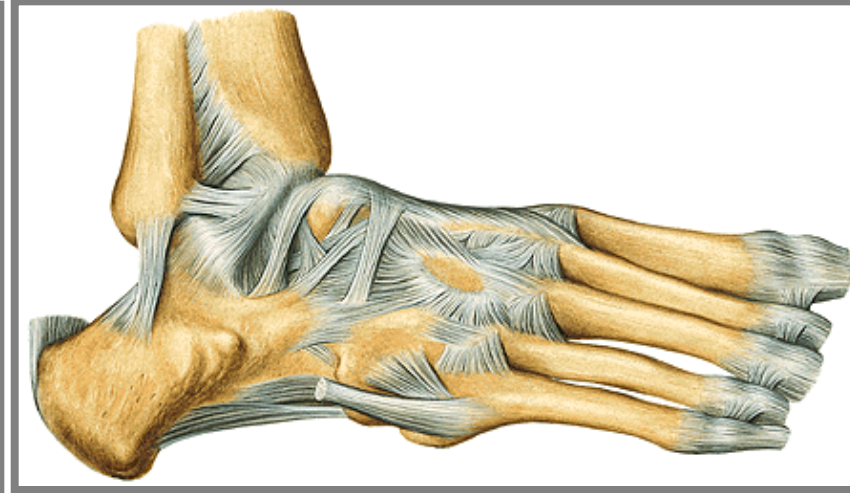
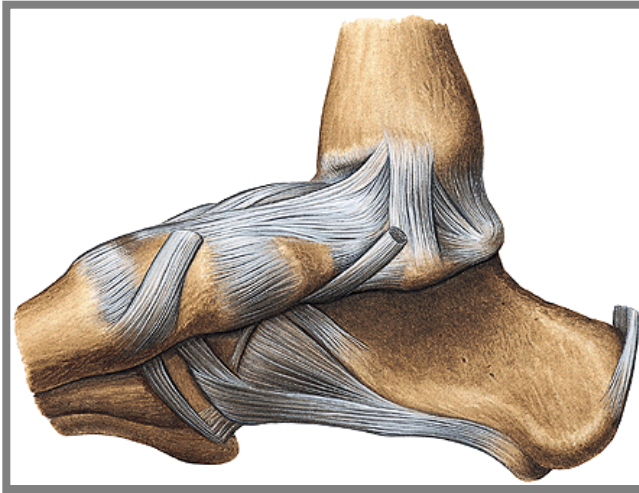
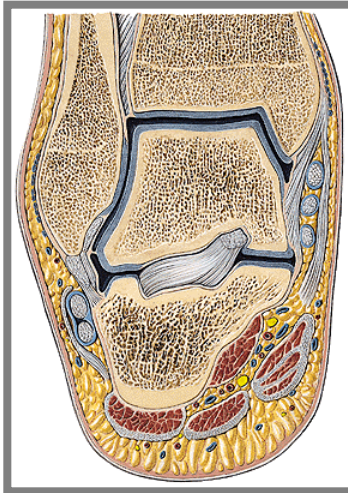
Articular capsule: is attached to ...

Auxiliary facilities: **Lig. collaterale mediale** = *deltoid lig.* with (pars tibionavicularis, tibiotalaris anterior, tibiotalaris posterior and pars tibiocalcanearis)

From the lateral ankle run three ligaments: **lig. talofibulare anterius**, **lig. talofibulare posterius** and **lig. calcaneofibulare** (*anterior and talofibular ligg., calcaneofibular lig.*).

Type of the joint: art. trochlearis (*hinge joint*)

Movements: plantar and dorsal flexion, slight side-to-side movements



B. Articulationes intertarseae (*intertarsal joints*)

a) *Articulatio subtalaris (lower ankle joint)*

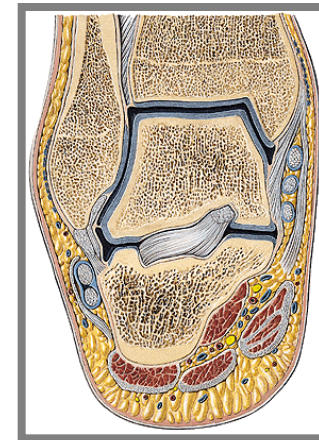
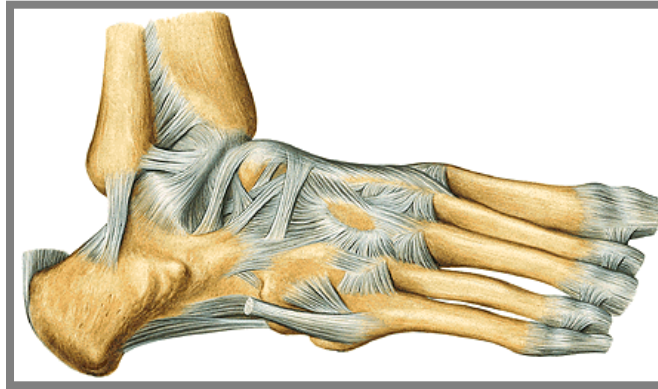
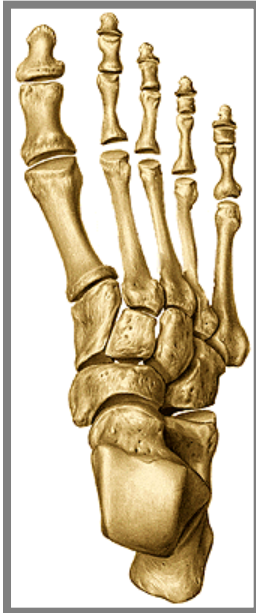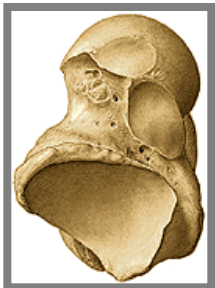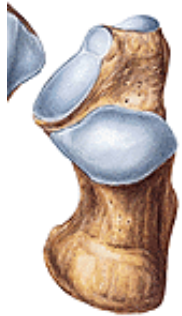Articular surfaces: facies articularis calcanea posterior and facies articularis talaris posterior

Articular capsule: is short and is attached to...

Auxiliary facilities: lig. talocalcaneum laterale, mediale and inside of sinus tarsi is located **lig. talocalcaneum interosseum**

Type of joint: together with art. talocalcaneonavicularis and calcaneocuboidea – forms functional unit.

Axis of **movements** - through **sinus tarsi**, inner rotation (pronation) and external rotation (supination).



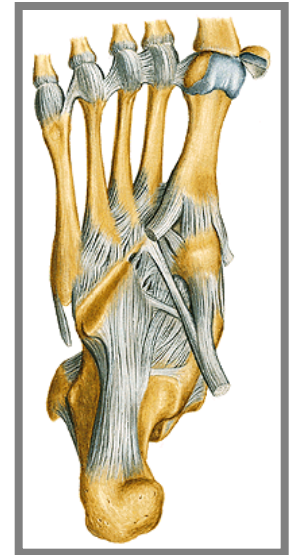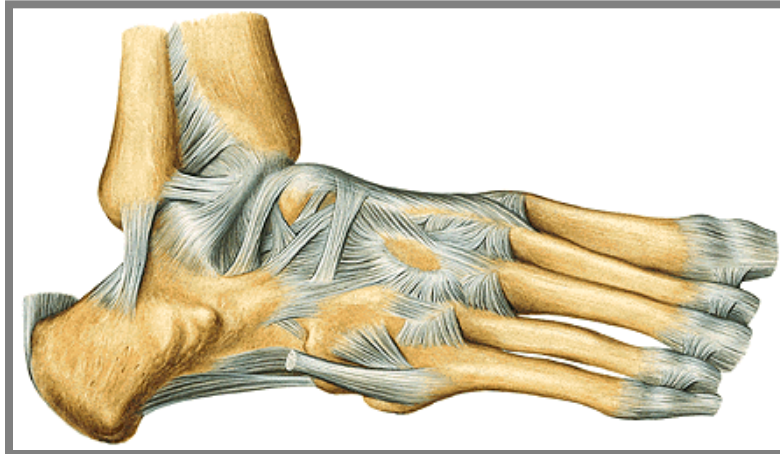
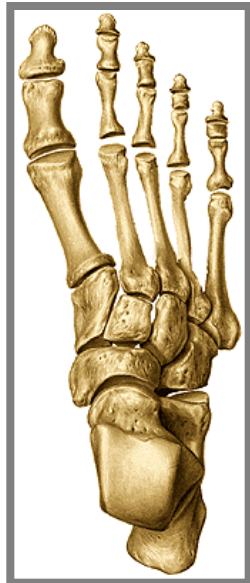b) **Articulatio talocalcaneonavicularis** (*talocalcaneonavicular joint*)

Articular surfaces: facies articularis calcanea anterior and media of talus and facies articularis talaris anterior and media of calcaneus, caput tali and articular surface of os naviculare.

Articular capsule: very thin and is attached to

Auxiliary facilities: lig. calcaneonaviculare plantare. Dorsally forms lig. calcaneonaviculare dorsale a part of **lig. bifurcatum**. Small dorsal, plantar and interosseal ligaments join talus, calcaneus and os naviculare.

Type of joint: together with art. subtalaris and calcaneocuboidea form a **functional unit**. The axis of **movements** - through sinus tarsi, inner rotation (pronation) and external rotation (supination).



c) **Articulatio calcaneocuboidea** (*Calcaneocuboid joint*)

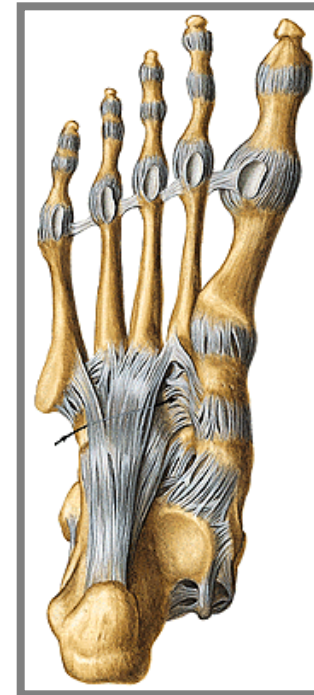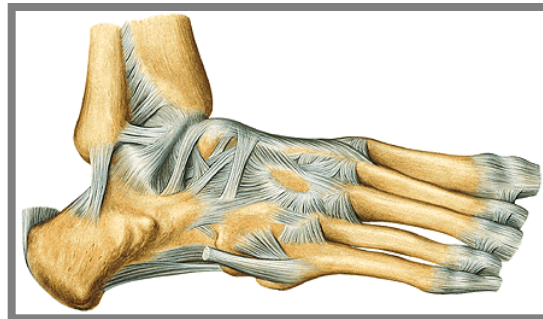
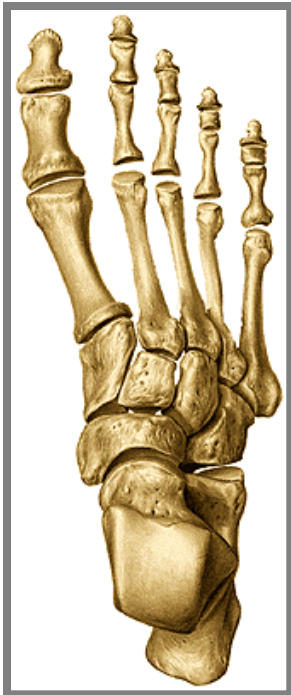Articular surfaces:

Articular capsule: thin and is attached to.....

Auxiliary features: *lig. calcaneocuboideum dorsale* (a part of *lig. bifurcatum*), *lig. plantare longum* and small ligaments among bones.

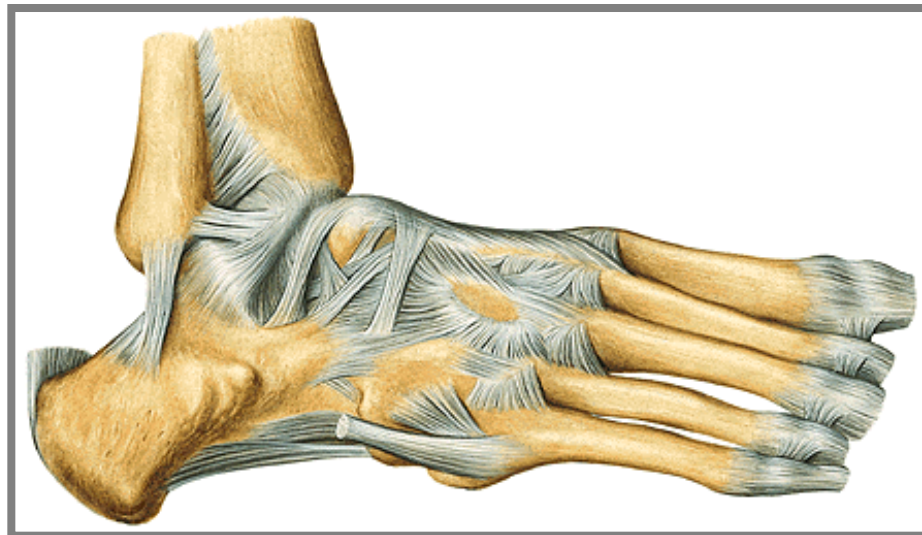
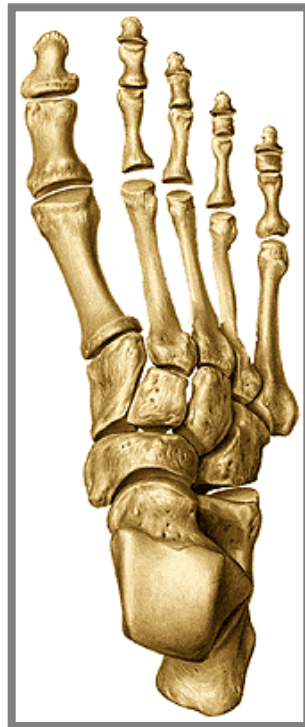Type of joint: sellaris

Movements: minimal



d) Chopart's joint – *articulatio tarsi transversa* – a fissure between talus and os naviculare medially and between calcaneus and os cuboideum (*cuboid bone*) laterally. Opening of this joint - by cut of **lig. bifurcatum = lig. calcaneonaviculare** and **lig. calcaneocuboideum (*calcaneonavicular and calcaneocuboid lig.*)**.

e) Articulationes cuneonavicularis, cuneocuboidea and intercuneiformia are joints between adjacent tarsal bones; dorsal, plantar and interosseous ligaments.
Springing movements



C. Articulationes tarsometatarseae (Lisfranc s joint)

Articular surfaces:

Articular capsule: is thin and is attached to ...

Auxiliary facilities: lig. tarsometatarsea dorsalia, plantaria and interossea

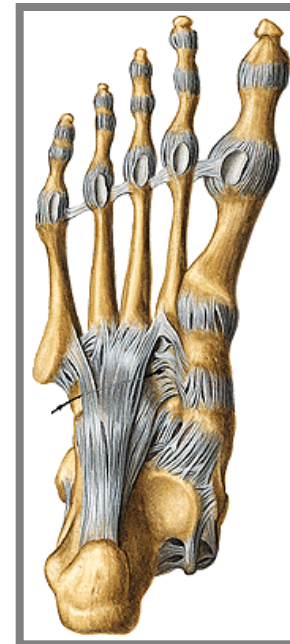
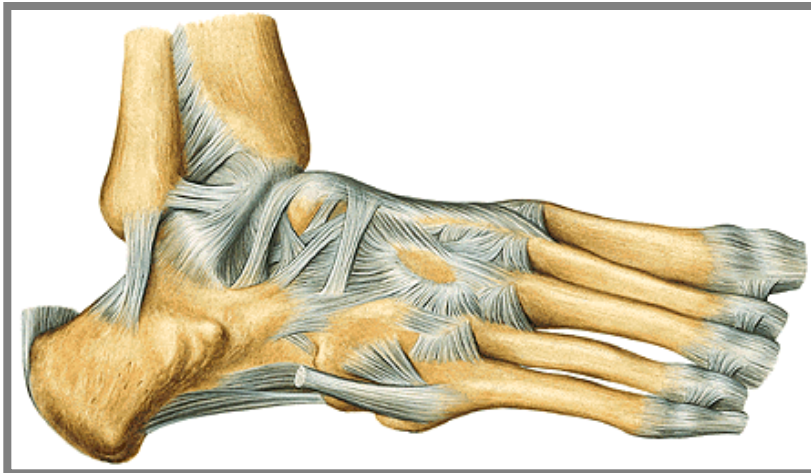
Type of joint: amphiarthrosis

Slight **movements**, specially during loading of plantar arch.

Between bases of metatarsal bones - (**articulationes intermetatarseae**)

– lig. metatarsea dorsalia, plantaria and interossea.

In the fissure of Lisfranc´s joint could be exarticulated toes of the foot.



D. Articulationes metatarsophalangeales

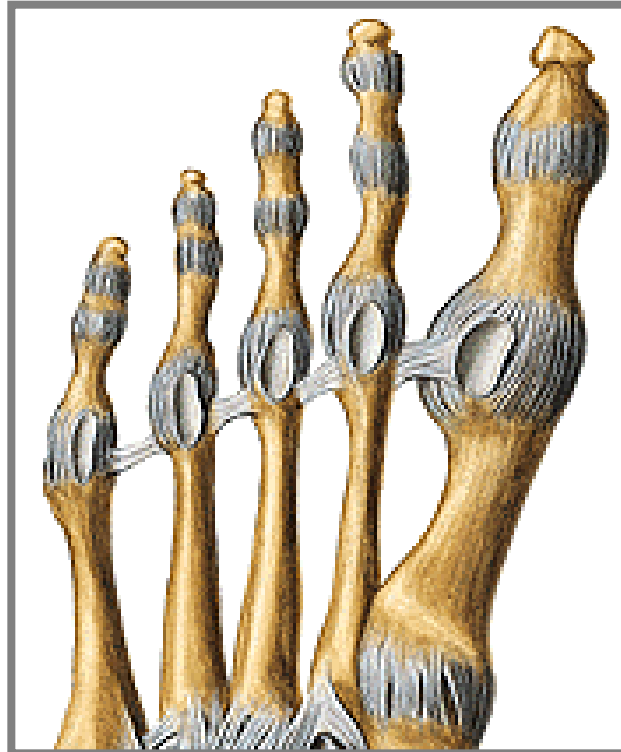Articular surfaces:

Articular capsule: is attached to

Auxiliary facilities: fibrocartilagineae plantares, in the joint of the big toe are two ossa sesamoidea. Collateral ligaments and lig. metatarsale transversum profundum.

Type of joint: art. spheroida (ball-and-socket joint)

Movements: mobility is restricted by collateral ligaments – flexion, extension, abduction and adduction.



E. *Articulationes interphalangeae pedis*

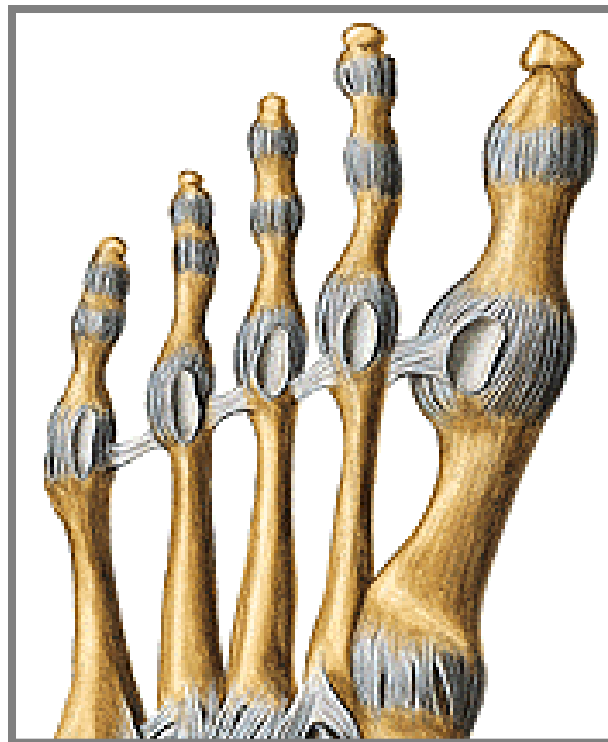
Articular surfaces:

Articular capsule: are attached to dorsally fuse with tendons of extensor muscles.

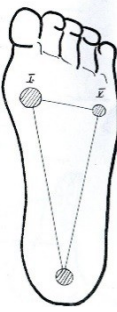
Auxiliary facilities: ligg. collateralia, fibrocartilaginea plantares

Type of joint: art. trochlearis (*hinge joint*)

Movements: flexion and extension of phalanges.

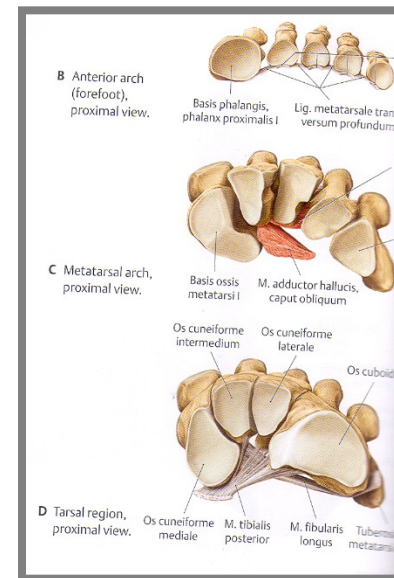
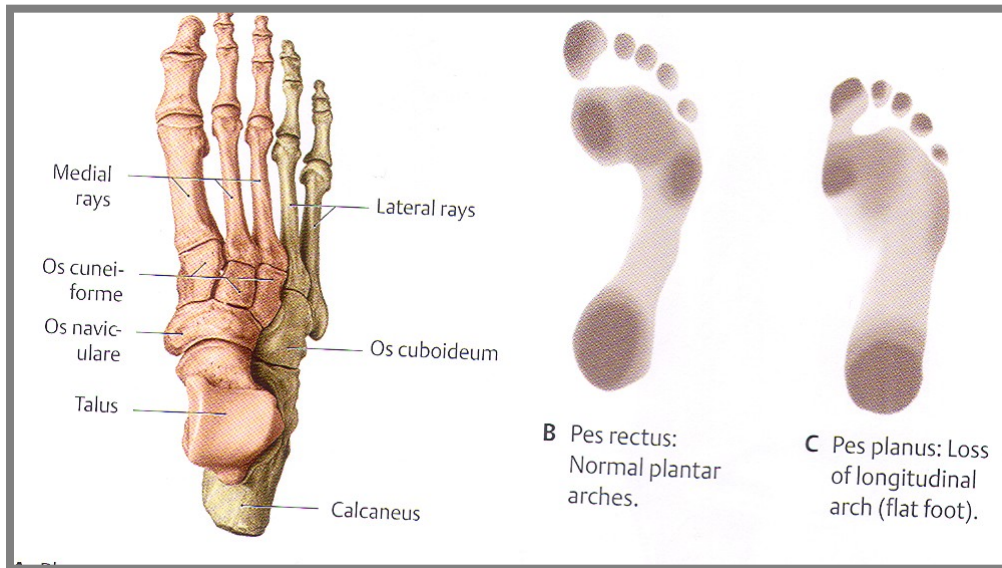


F. Plantar arch protects (vessels, nerves) from press, especially during long standing. Weight-bearing points are *tuber calcanei* and heads of the 1st and 5th metatarsal bones.

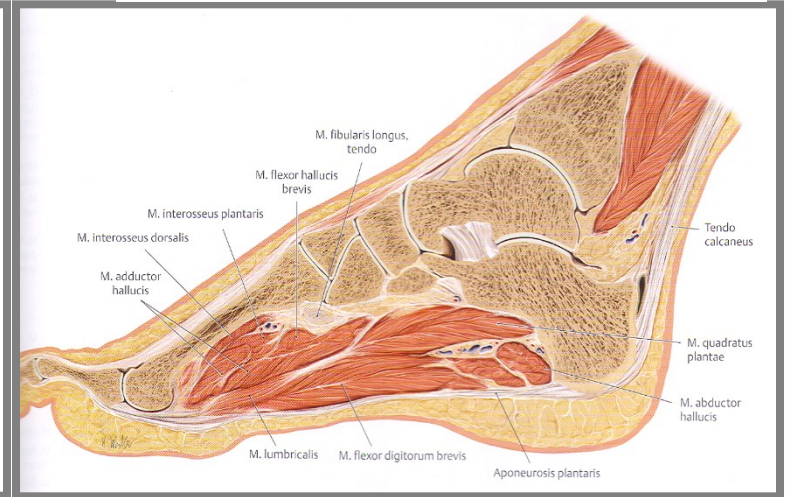
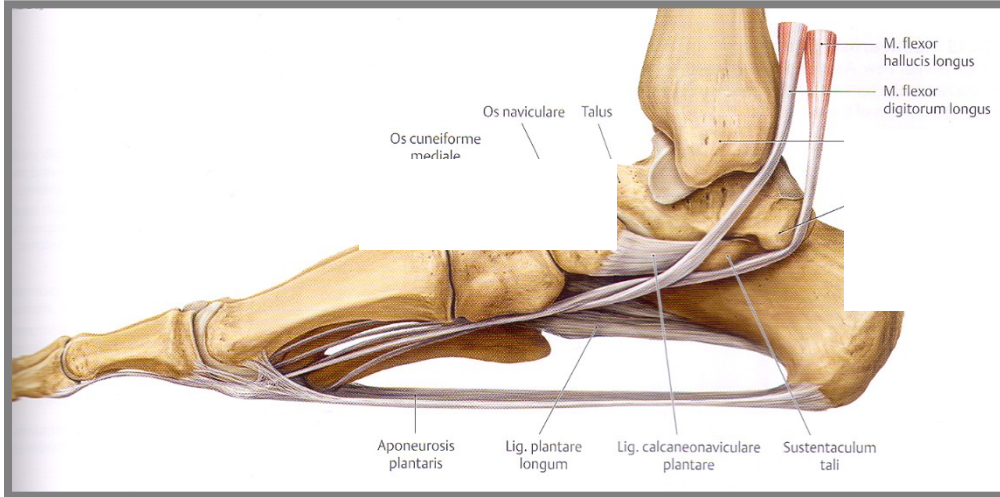
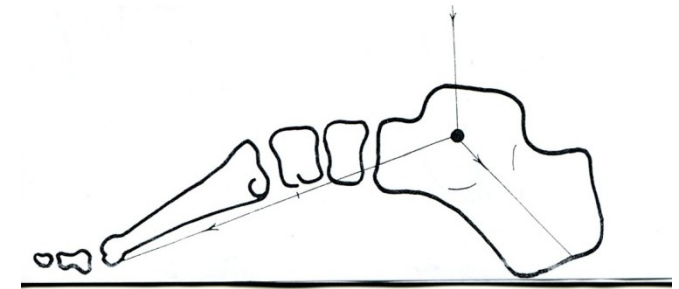
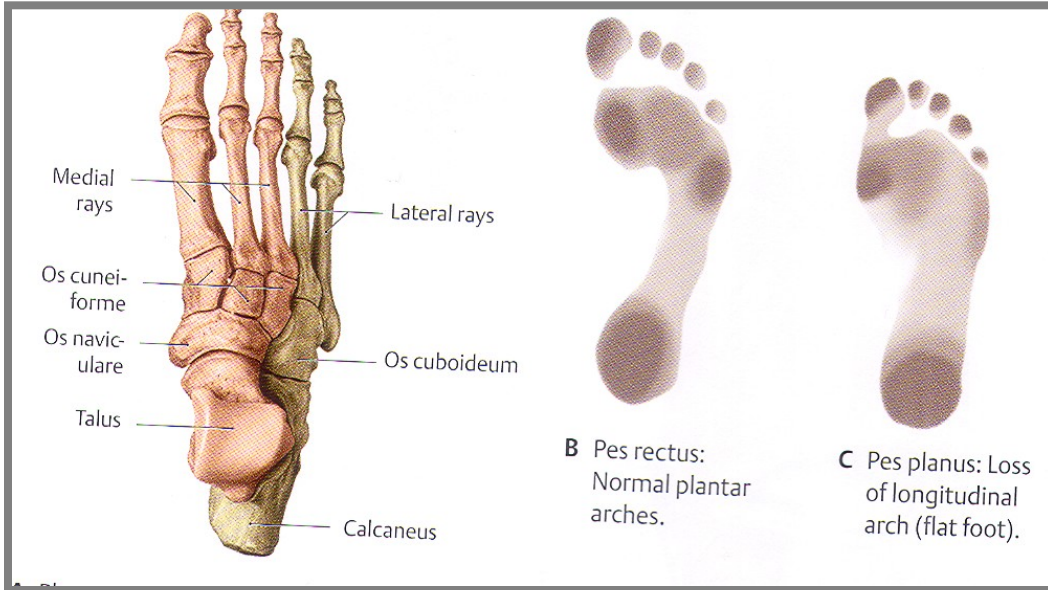


Two longitudinal plantar arches (1. **medially** talus, os naviculare and ossa cuneiformia and the I.–III. metatarsus, 2. **laterally** calcaneus, os cuboideum and the IV. – V. metatarsus) and **one transverse arch** - shape of ossa cuneiformia (*cuneiform bones*).

Medial plantar longitudinal arch is higher. Plantar arch is supported by ligaments and muscles of the foot.



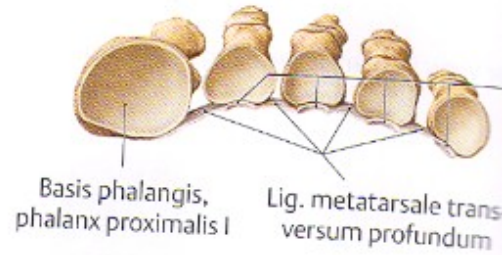
Longitudinal plantar arch



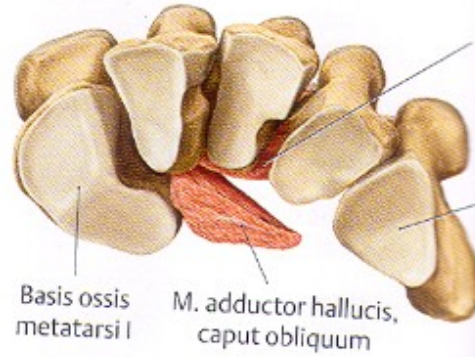
Lig. plantare longum, m. tibialis posterior et anterior, flexors of toes, aponeurosis plantaris

Transverse plantar arch

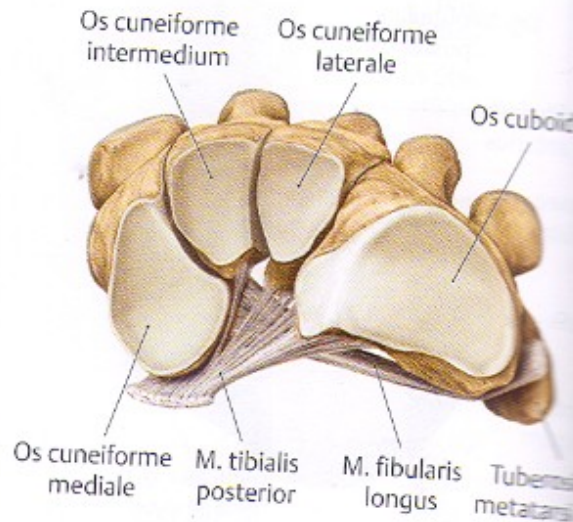
B Anterior arch
(forefoot),
proximal view.



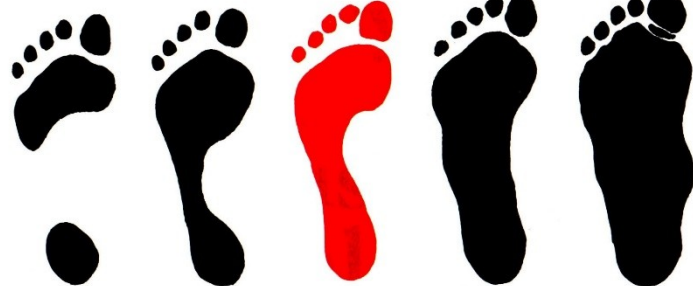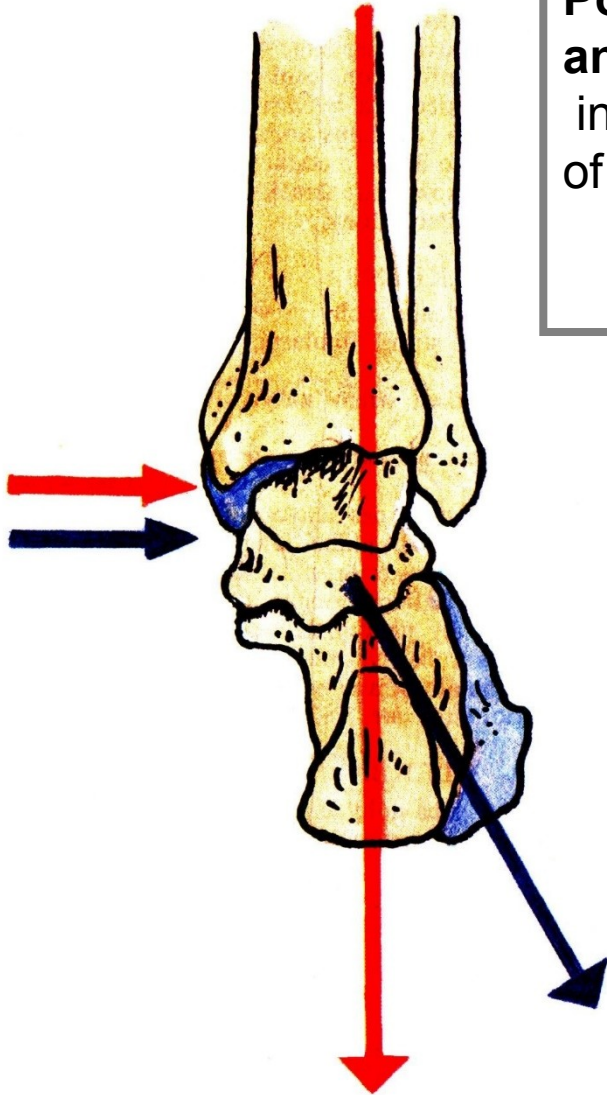
C Metatarsal arch,
proximal view.



D Tarsal region,
proximal view.



**Position of calcaneus – normal foot
and flatfoot („Flatfoot“ – *pes planus* – severe pain
in the foot and leg occurs, due to overstretching
of the long muscles and nerves and vessels of the sole.**




Pes cavus

Pes planus

Pes planovalgus

Textbook of anatomy
Atlas of anatomy
Personal notes, drawings



X-rays

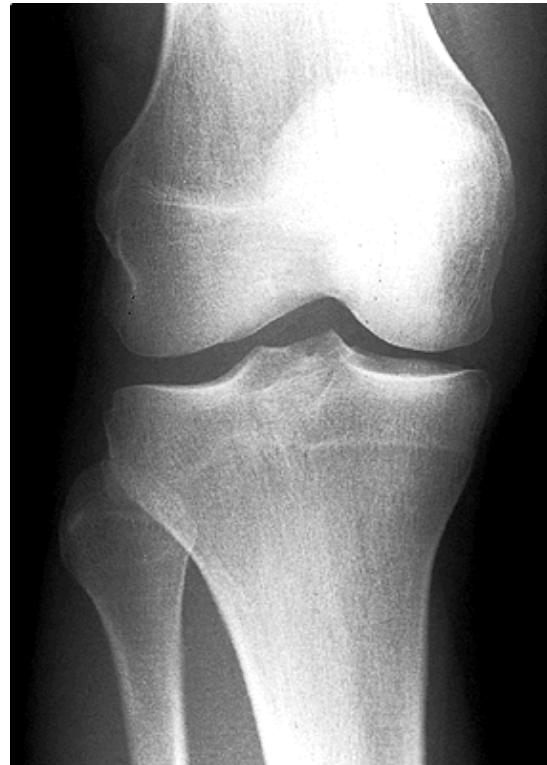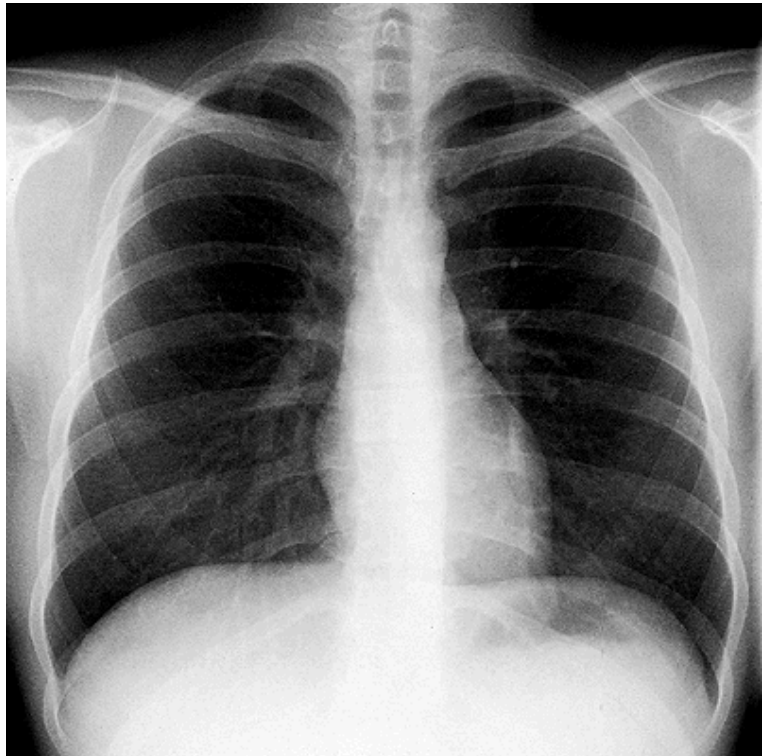
Radiology and anatomy

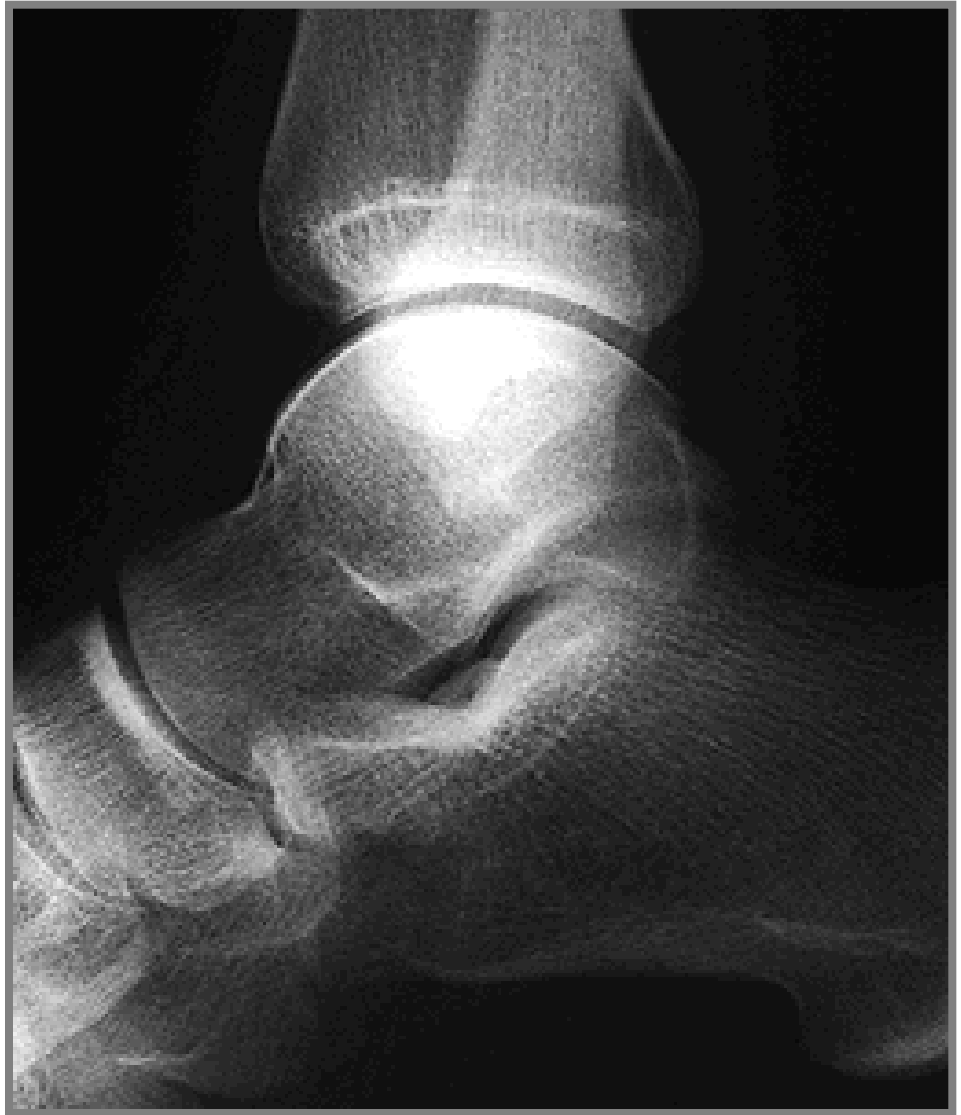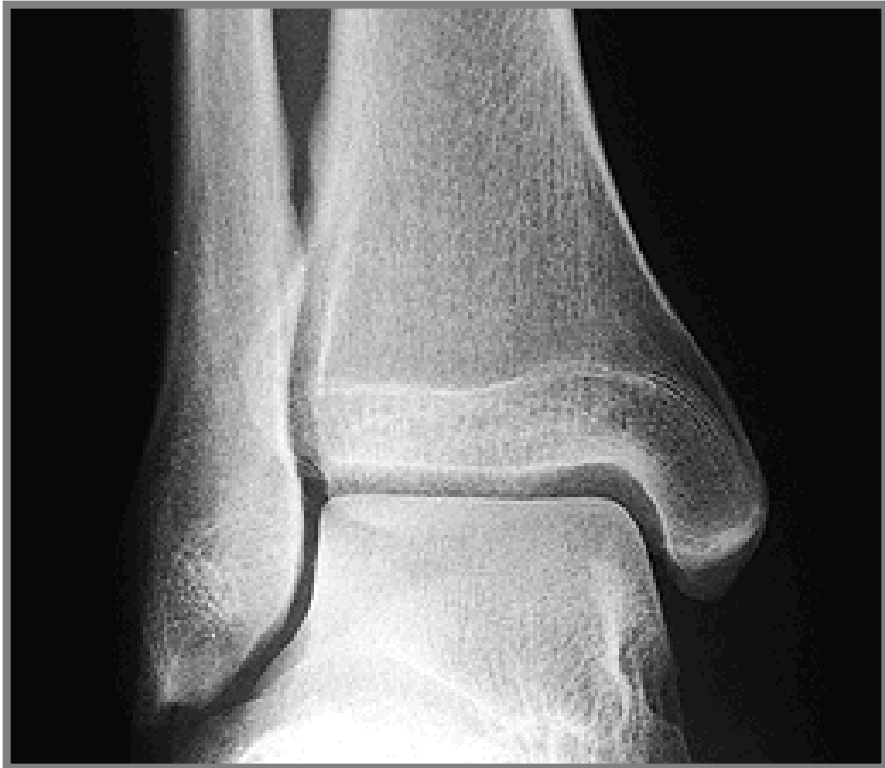- 1. Anatomy is essential for understanding radiology.**
- 2. You will see anatomical structures this way much more frequently than during operation or autopsy.**
- 3. Familiarity with normal radiographs allows you to recognize abnormalities (e.g. tumors, fractures).**
- 4. You must be able to visualize the diseased organ and its associated structures.**

X-ray (K. Roentgen 1895 – awarded by Nobel price in physics)

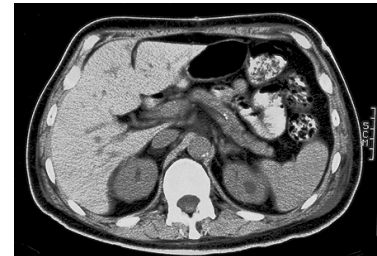
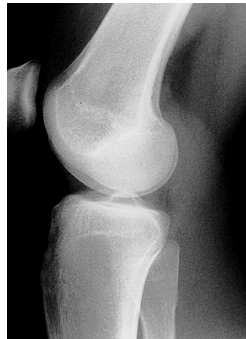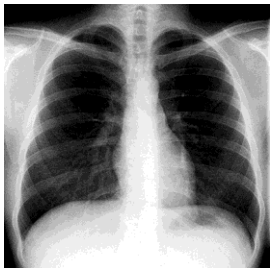
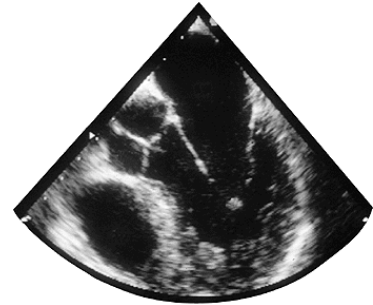
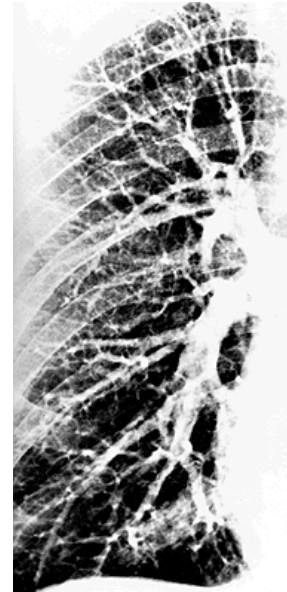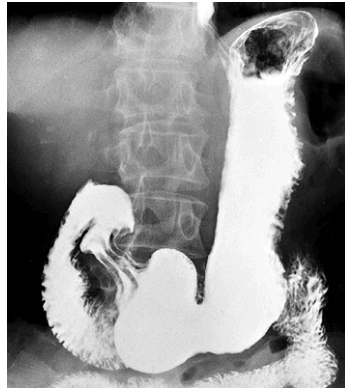
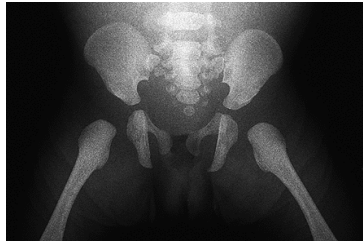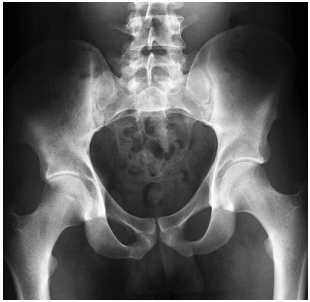A highly penetrating beam of x-rays „transluminates“ the patient, showing tissues of differing densities on x-ray film.

A tissue or organ that is relatively dense absorbs (stops) more x-rays than a less dense tissue. Relatively fewer x-rays reach the silver emulsion in the film therefore only fewer grains of silver are developed at this area when the film is processed – „white area of bones“.

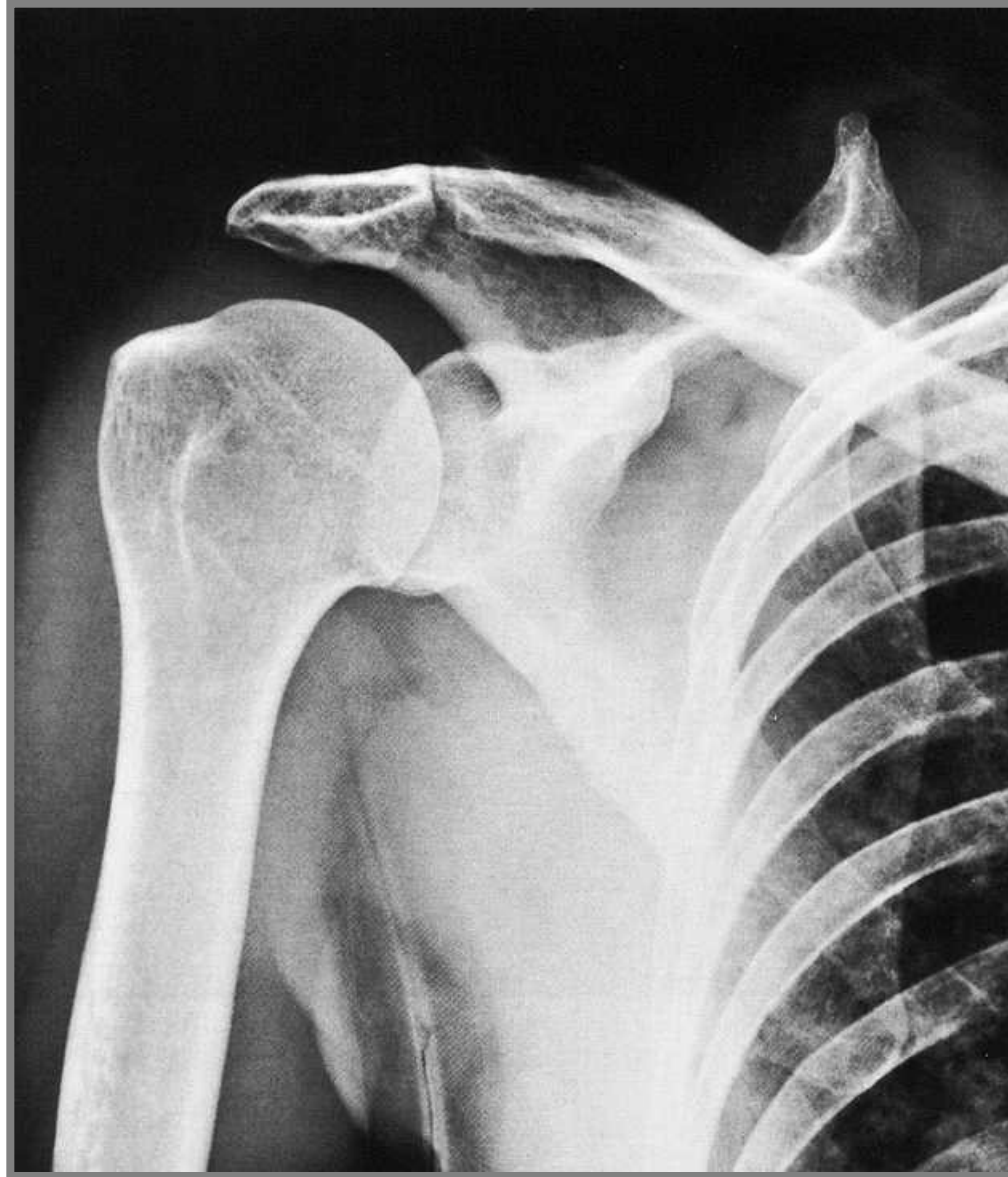



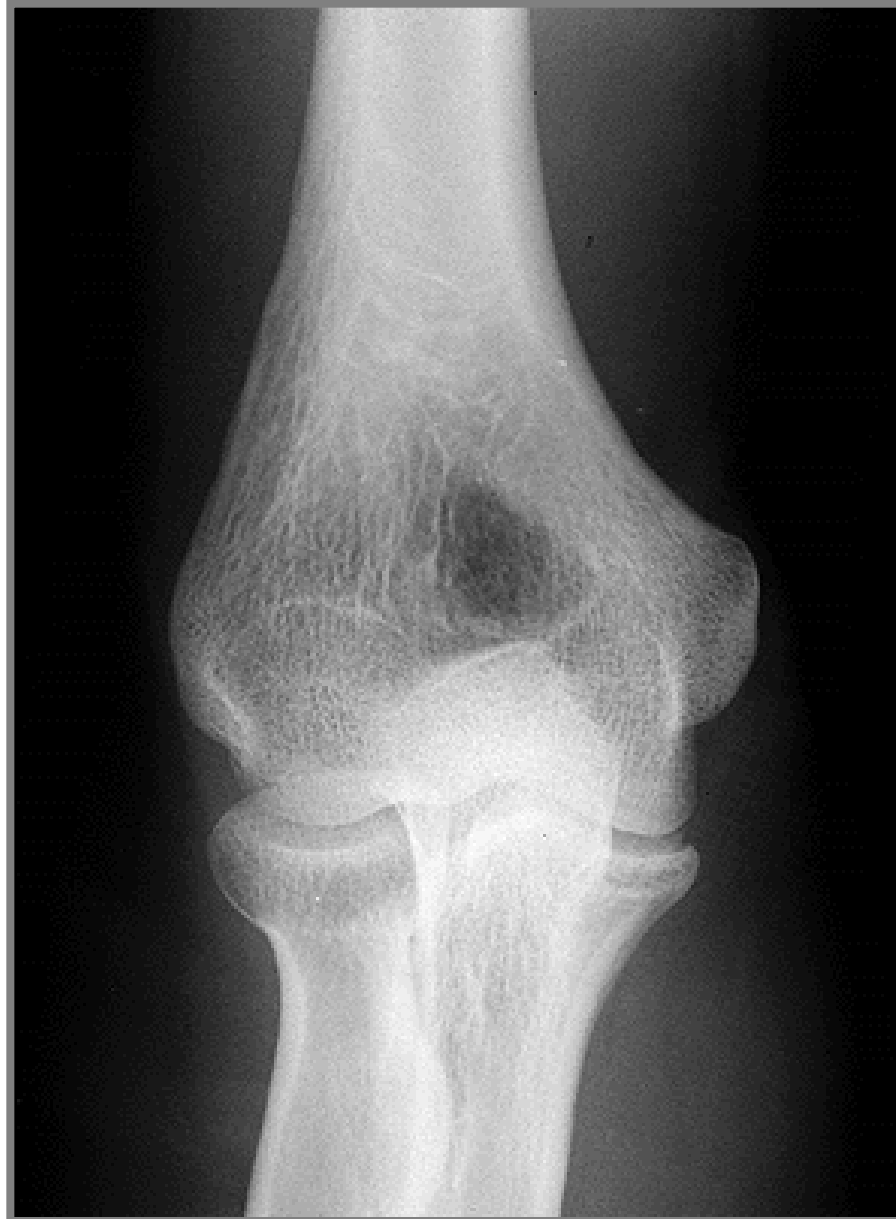1. Simple X – ray
2. X– ray with contrast materials
 - a) **positive** (iodide preparations, barium meal)
 - b) **negative** (air, gases)
4. Projection according to the course of x-ray (anteroposterior, lateral)
5. New methods (sonography, CT (computerized tomography – using CT scanners, shows sections of the body – a small beam of x-rays is passed through a plane of the body while the x-ray tube moves in an arc or a circle around the body), MRI)



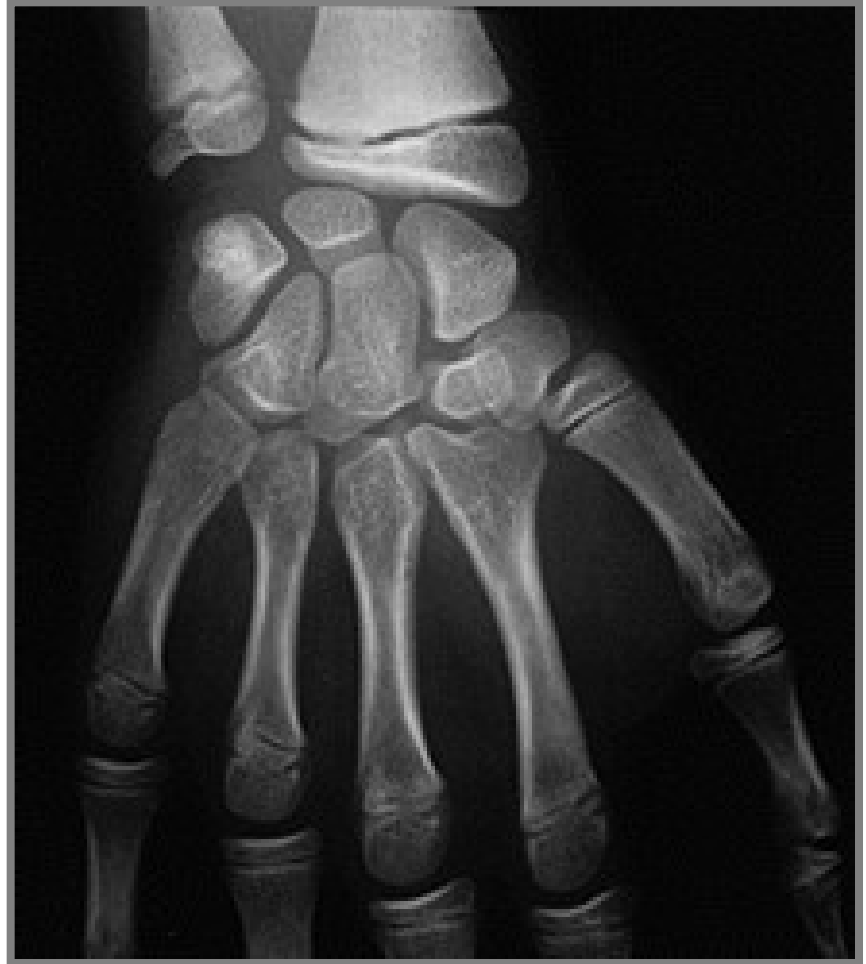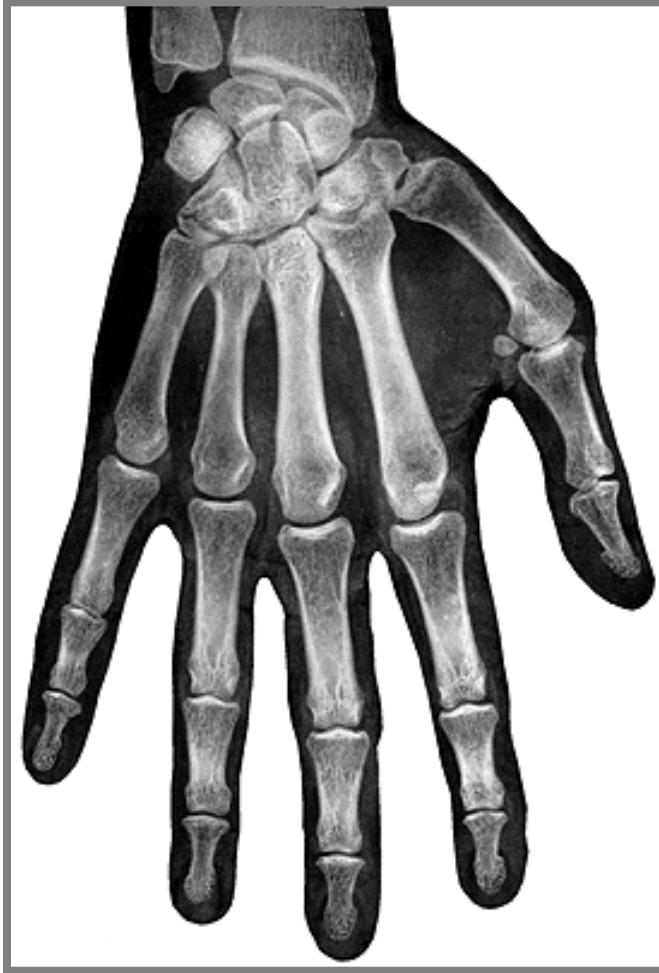X-ray of articulatio humeri (shoulder joint)

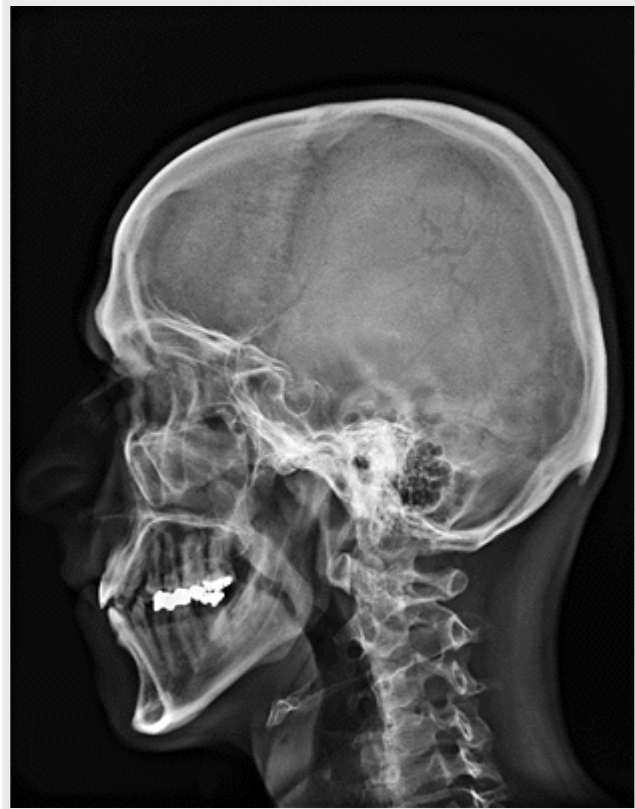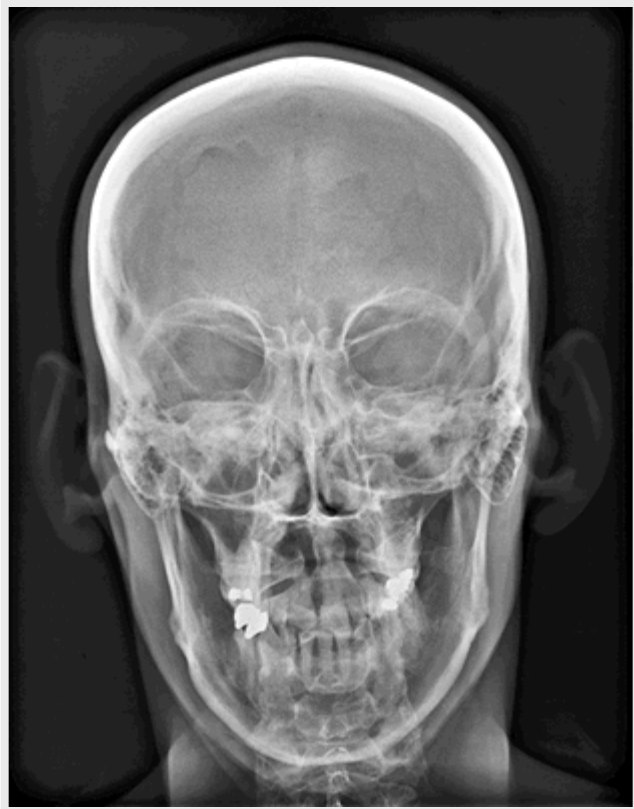


X-ray of articulatio cubiti (elbow joint)

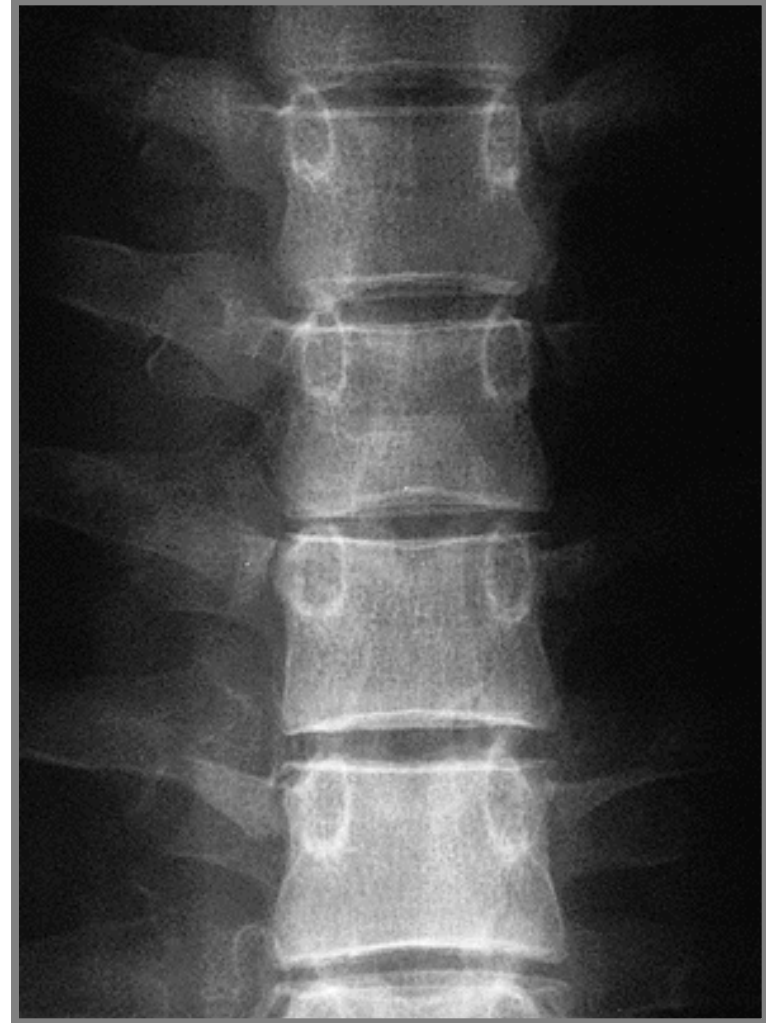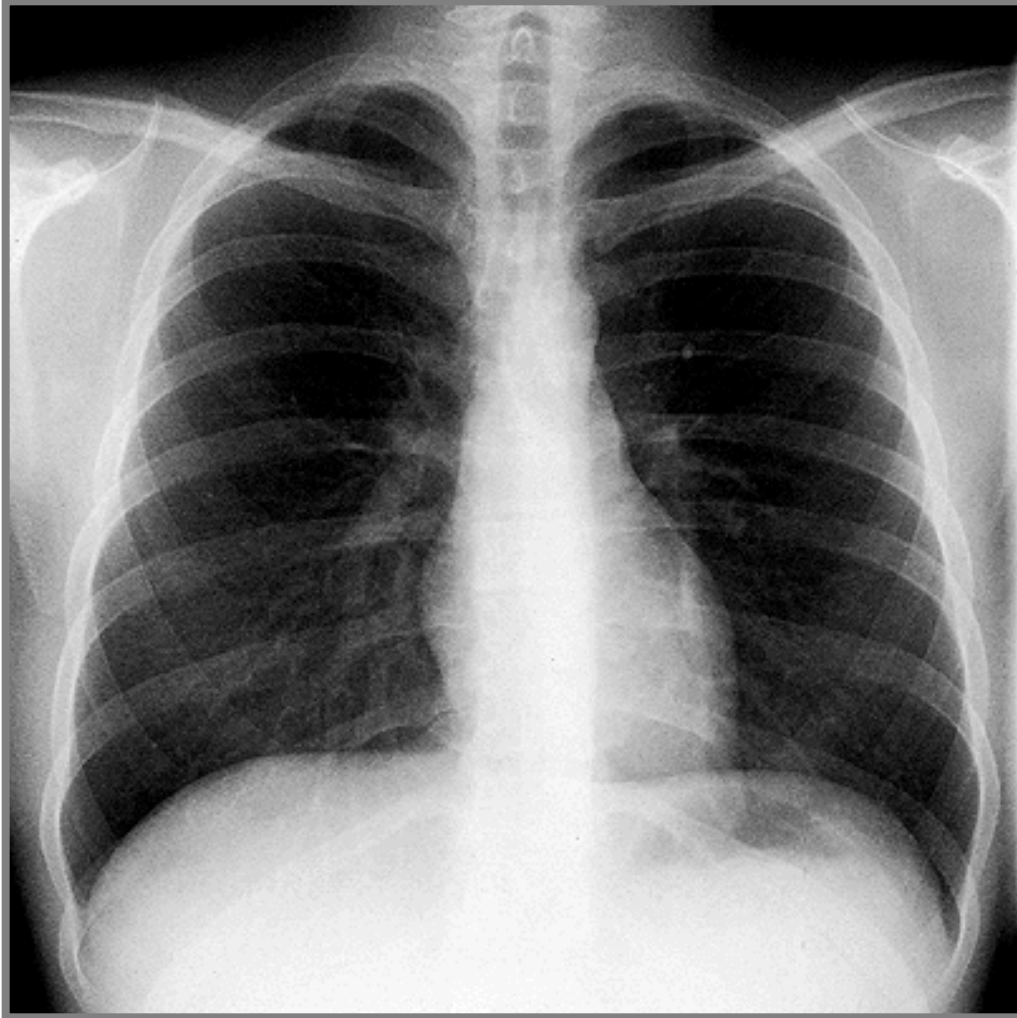


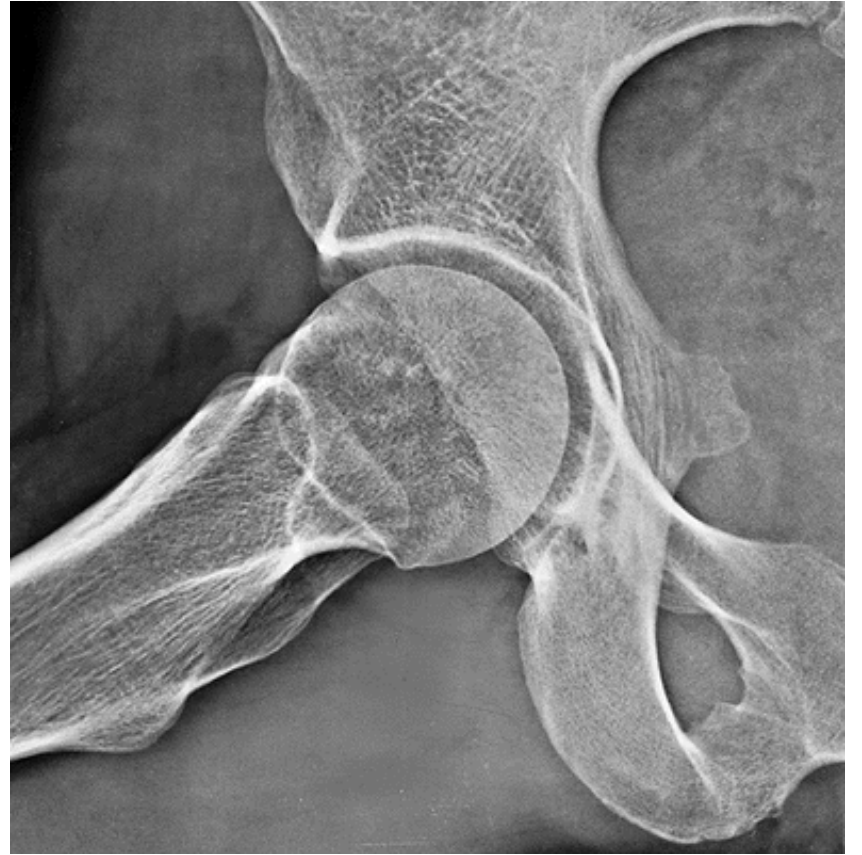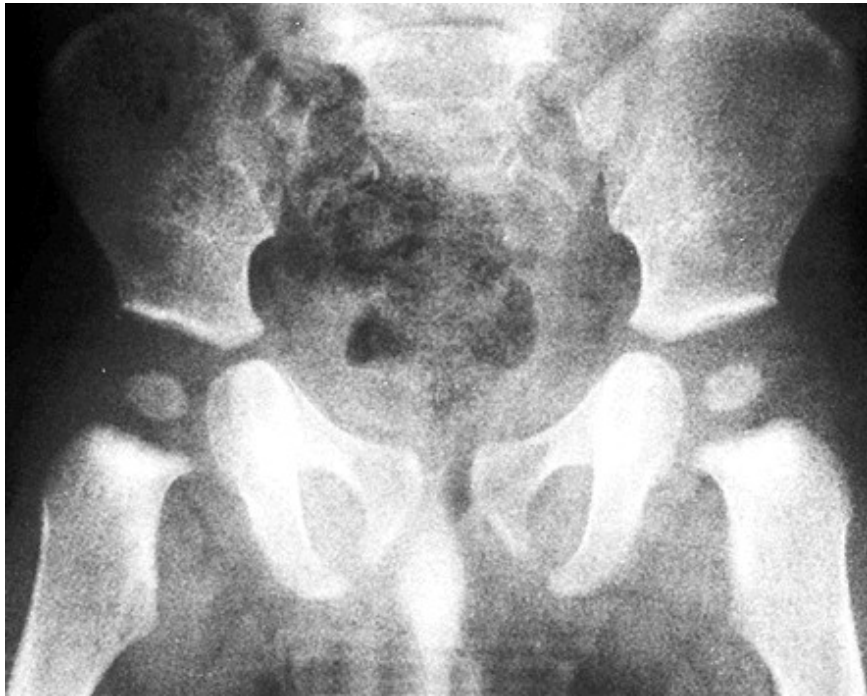X-ray of the hand

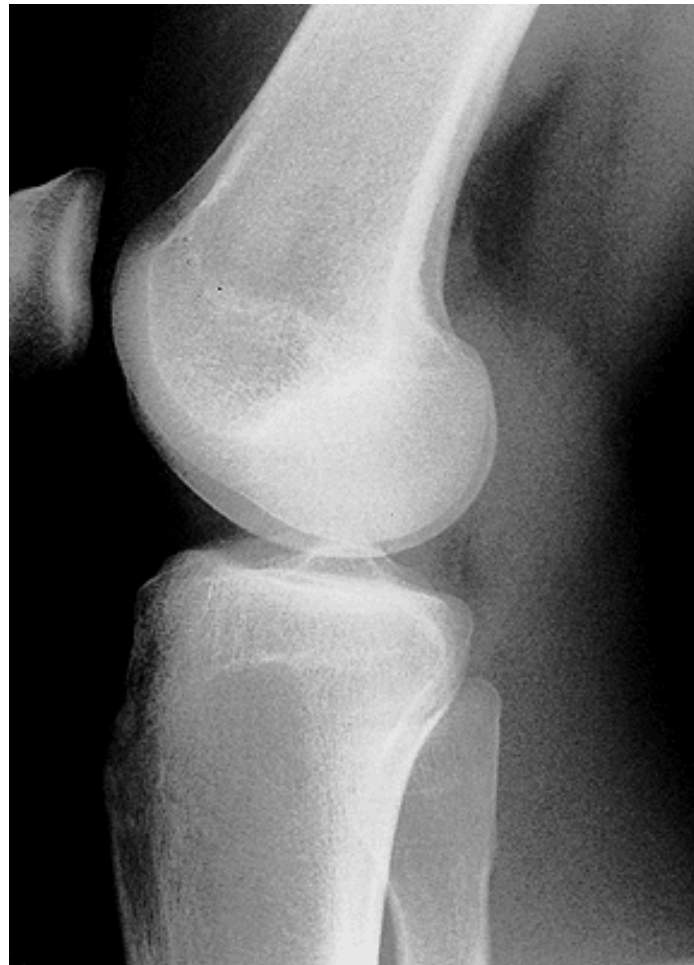
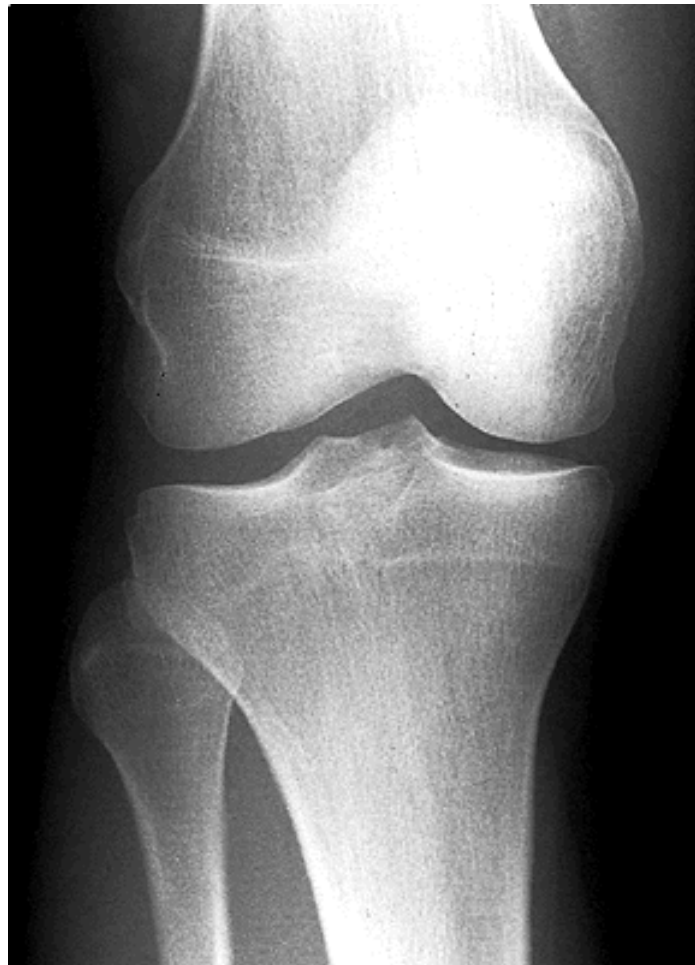


X-ray of the thorax







Used pictures come from:

Moore, K. L. (1992): Clinical oriented anatomy. Third edition.
Williams&Wilkins, A Waverly Company.

Gilroy, A. M. et all. (2009): Atlas of Anatomy. Thieme New York, Stuttgart.

Putz, R. (2008):
Atlas of Human Anatomy Sobotta. Elsevier Books.

Platzer, W., Kahle, W., Leonhardt H. (1992):
Locomotor system. Georg Thieme Verlag, Stuttgart,
New York, 4th edition.

Čihák, R. (1987): Anatomie 1. Avicenum, Zdravotnické nakladatelství.

Sexual differences of pelvis

Male pelvis is higher and narrower.

Female pelvis is lower and wider than in the male.

ala ossis ilii (*ala of iliac bone*)

tubera ischiadica (*sciatic tuberosity*)

symphysis pubis

angulus x arcus subpubicus (*subpubic angle x arch*)

shape of aditus pelvis (*shape of pelvic inlet*)

incisura ischiadica major (*greater sciatic notch*)

length of superior ramus of pubic bone – prominence of mons pubis

foramen obturatum

os sacrum

