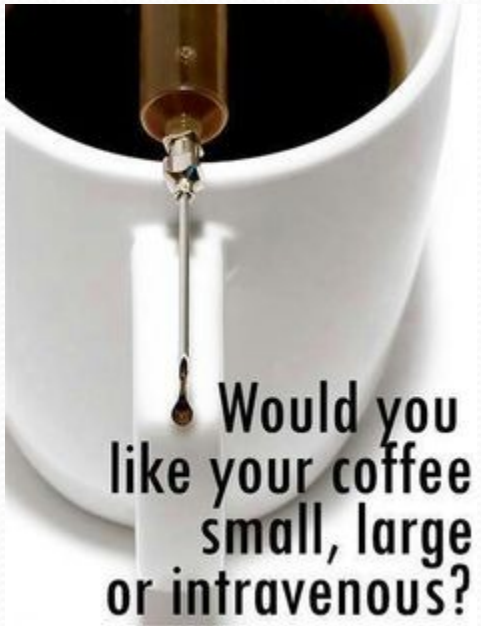

# Intravenous Access



**Martin Helán MD, PhD**

**29.2.2016**

# What possibilities do we have?

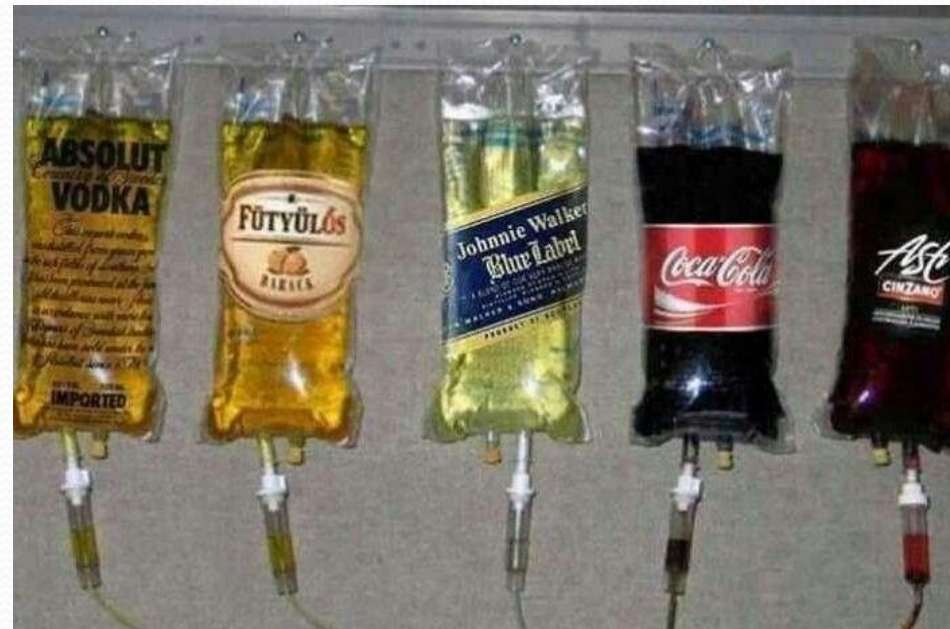- Peripheral i.v. cannula
- Central venous catheter
  - Dialyzation catheter
  - Peripherally inserted central venous catheter PICC
  - Central venous Port
- Intraosseal i.v. access



# Peripheral venous access

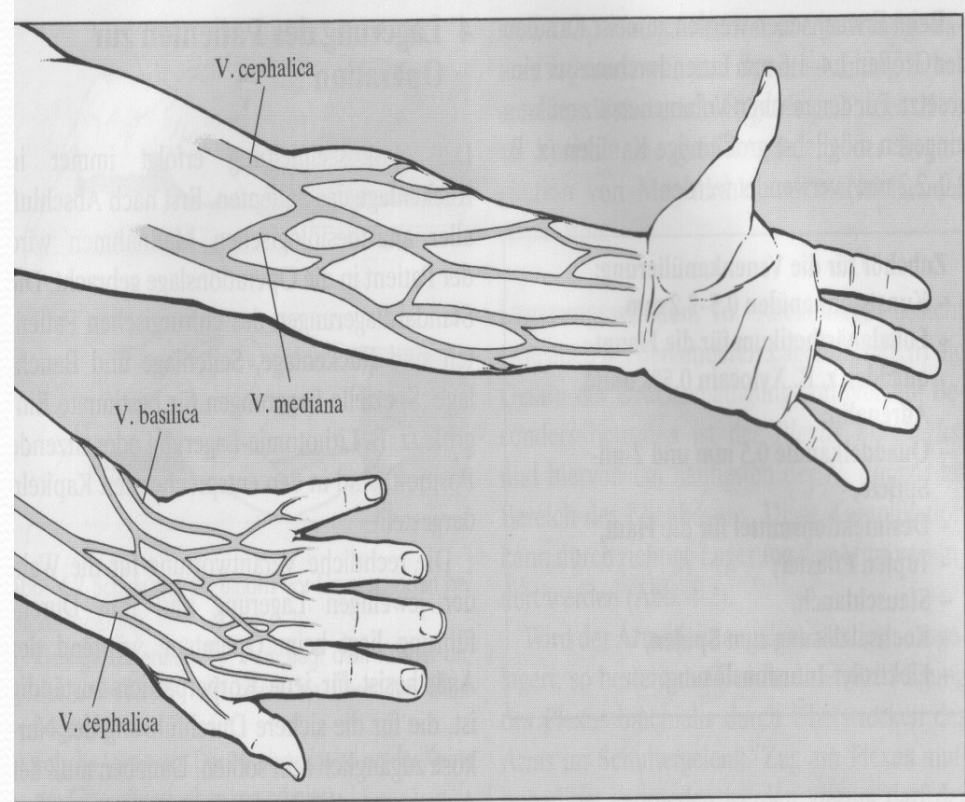
## - Indication – WHY?

- acute **drugs**
- repeated **blood samples**
- **infusion** therapy (crystalloid, colloid, blood, parenteral nutrition, ...)
- **anesthesia**



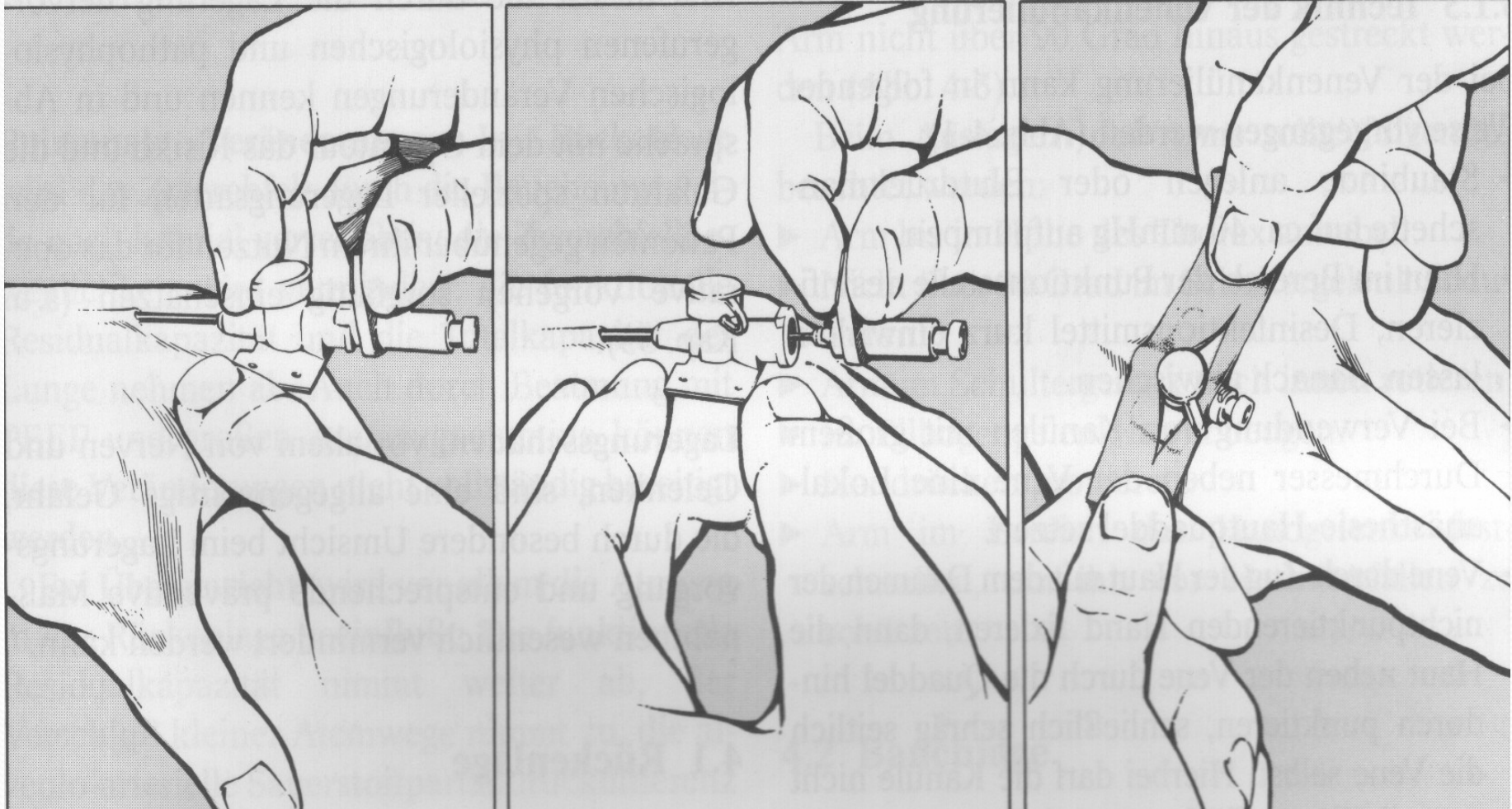
# Peripheral venous access – WHERE?

- back of the hand (wide, well filled veins)
- forearm
- cubital fossa
- wrist
- external jugular vein
- head (12M)



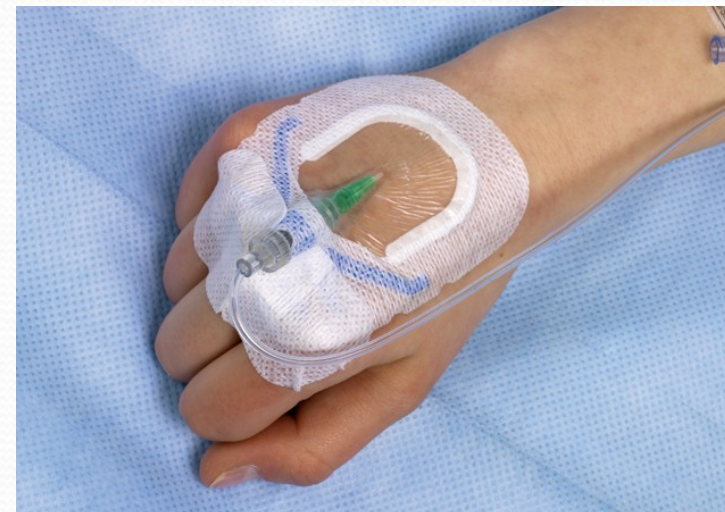

# Peripheral venous access – HOW?

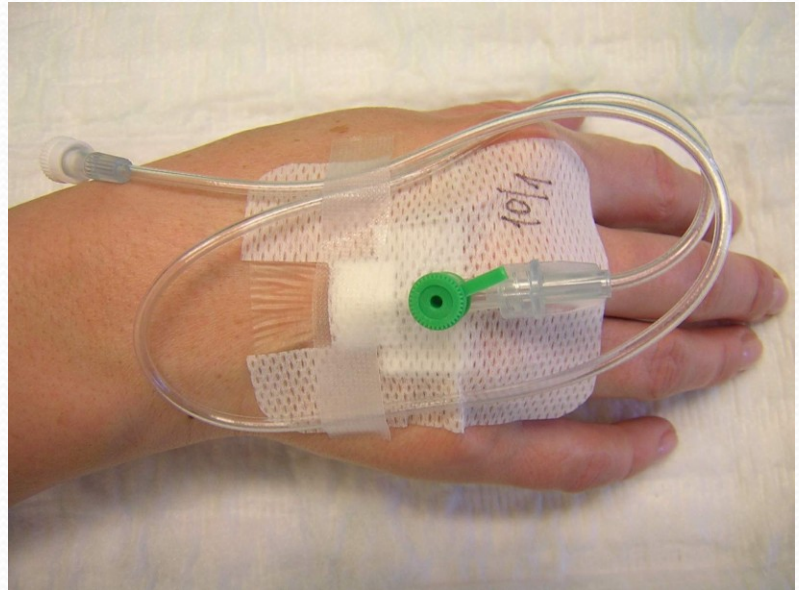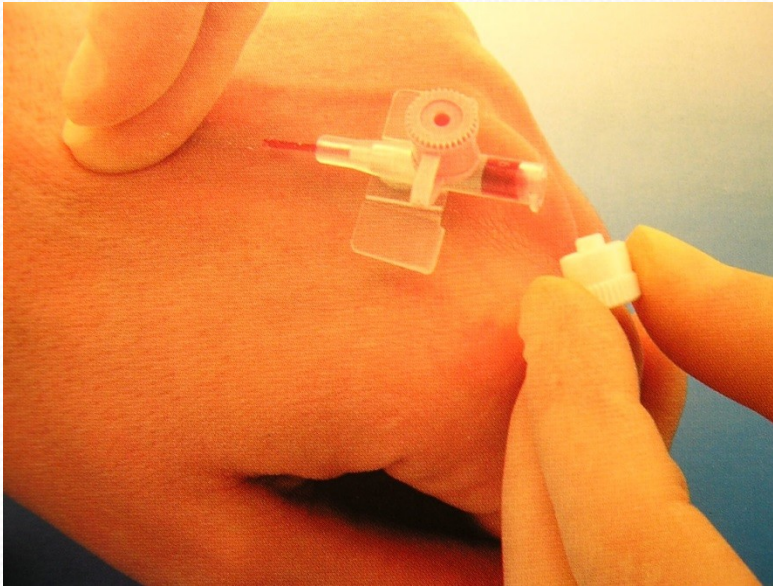
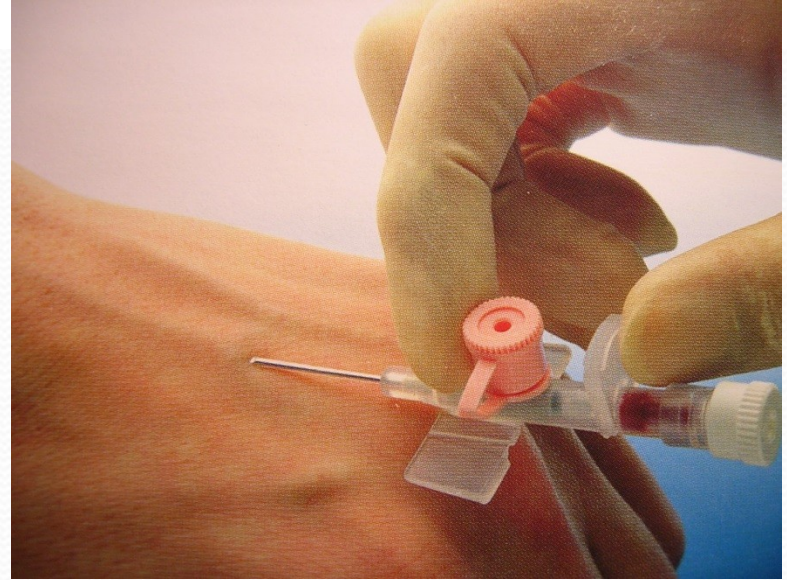


# Peripheral venous access – HOW?

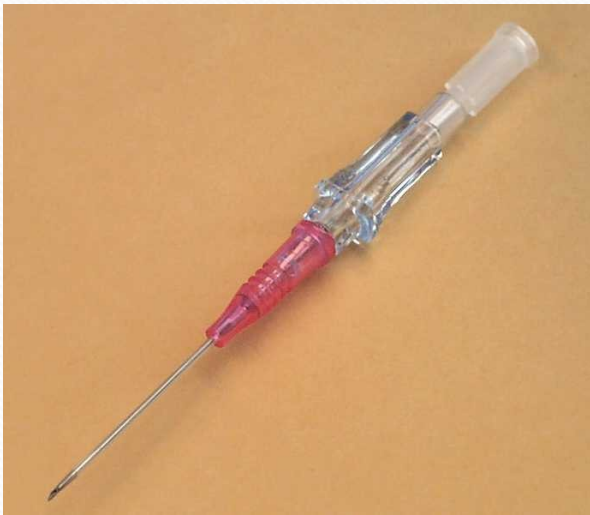
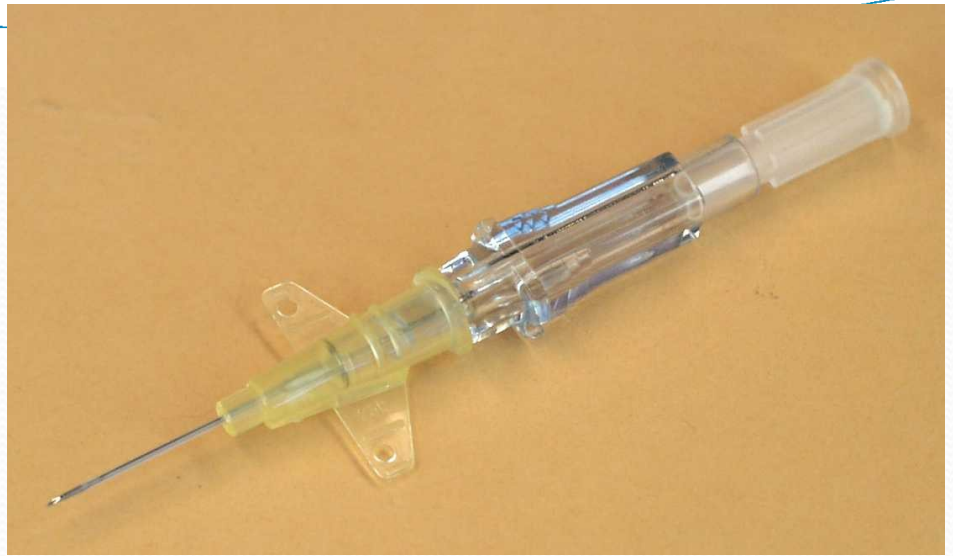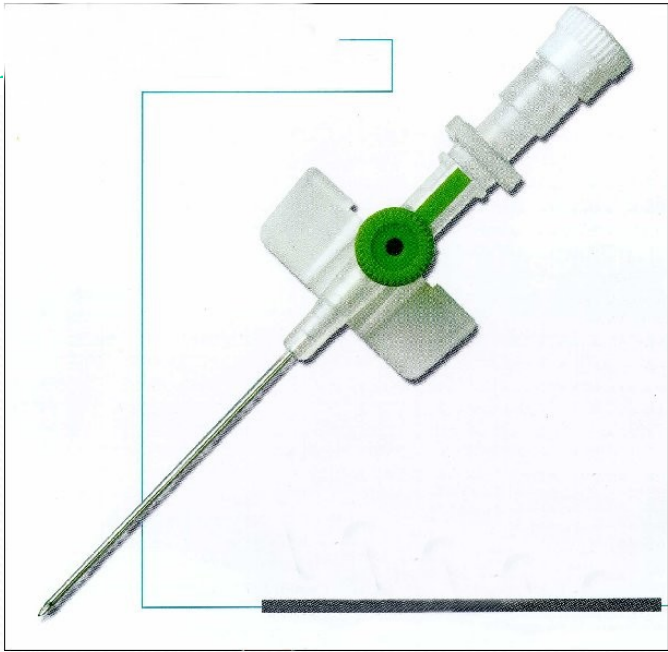
- place turniket
- use disinfection of the skin
- fix skin and vein by fingers
- puncture of the vein
- pull **out** metal needle, pull **in** flexible part
- displace turniket
- fixation by a plaster
- next attempt proximally













# Complications of peripheral vein canylation

## During puncture

- accidental puncture of brachial **artery** or median **nerve**
- hematoma

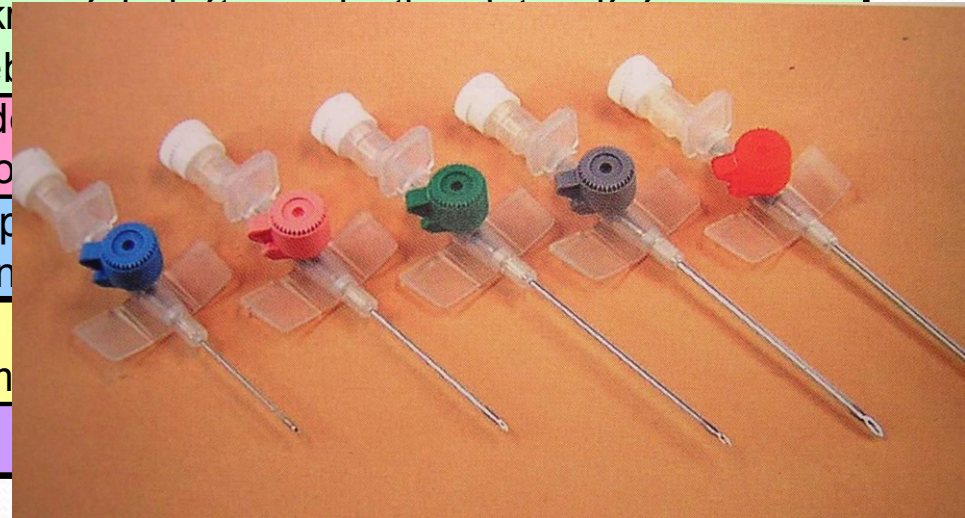## Late complications

- thrombosis
- insufficient blood filling
- infection – phlebitis

# Cannula diameter


## – Why it is important?

Oranžová	14G	Rychlá transfuze krve
Šedá	16G	Rychlá transfuze krve nebo krevních derivátů
Bílá	17G	Rychlá infuze velkého objemu tekutiny
Zelená	18G	Pacienti přijímající krevní transfuze, chirurgický výkon nebo pacienty s kardiálními onemocněními
Růžová	20G	Pacienti přijímající dlouhodobou léčbu, pacienti na dlouhodobou léčbu
Modrá	22G	Dlouhodobě léčeni pacienti, děti, dospělí s drobnými žilami
Žlutá	24G	Děti, novorozenci, starší pacienti s mimickými žilami
Fialová	26G	Děti a novorozenci






**MALÁ KANYLA**




**DOBŘE ŘEDĚNÍ**

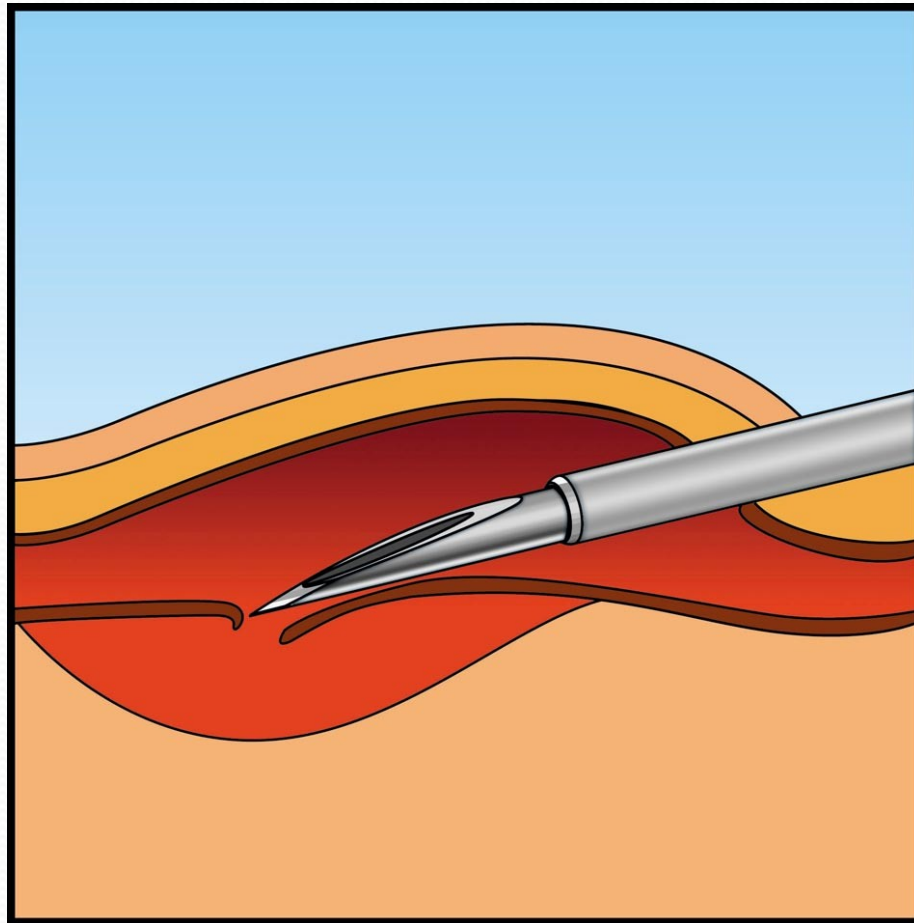
**VELKÁ KANYLA**



**Insufficient dilution of the drug**

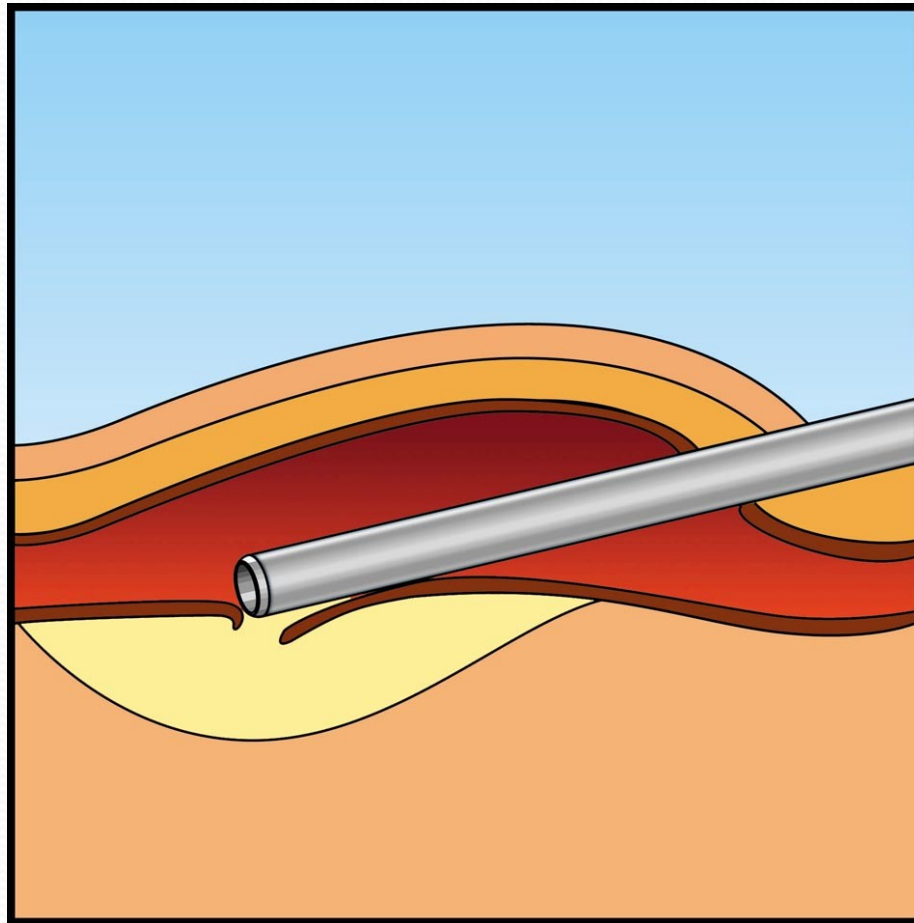


# HEMATOMA

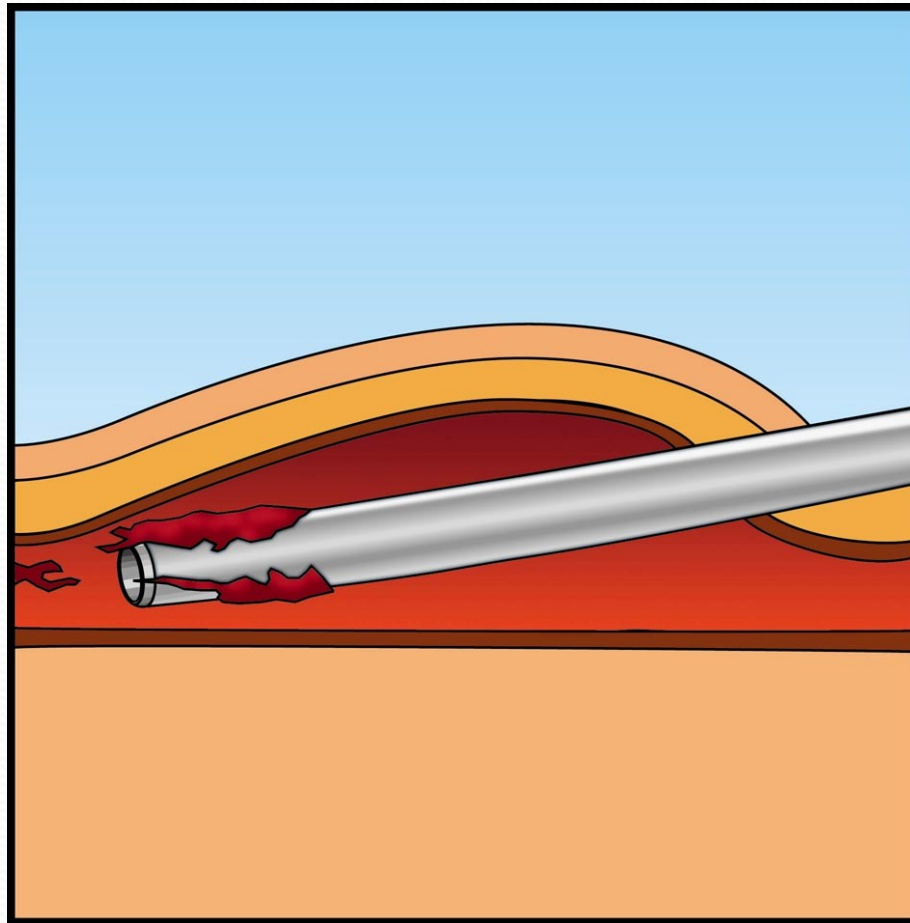




# Infiltration / Extravazace

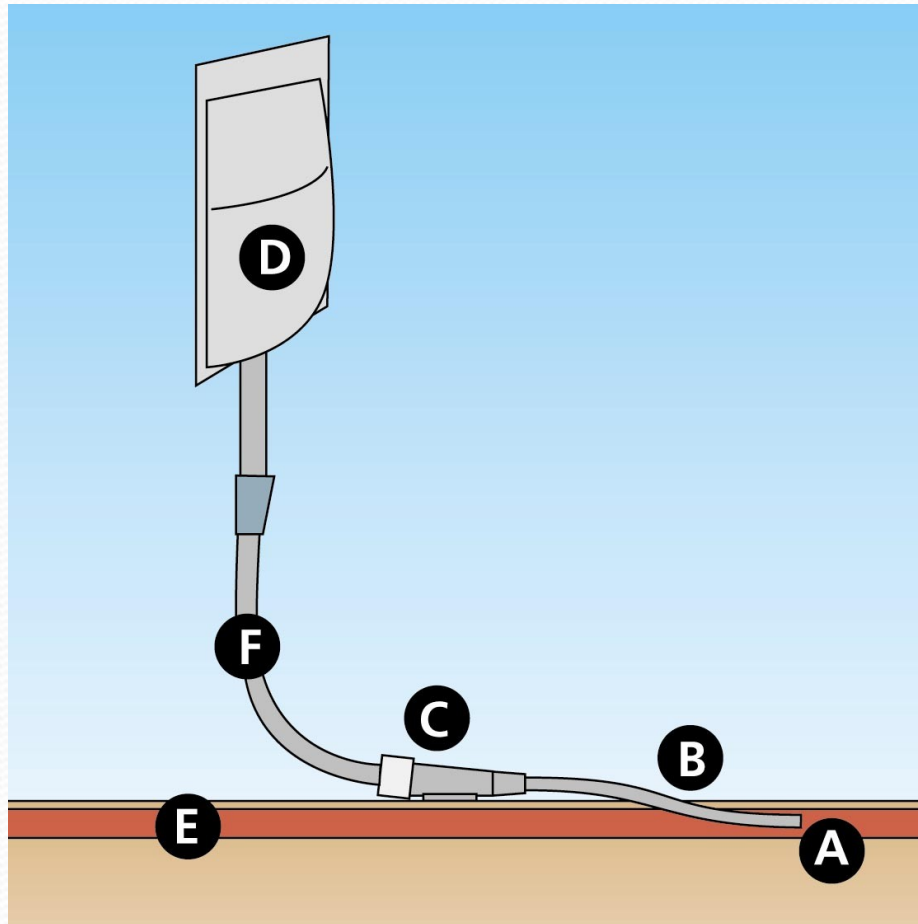


# Tromboembolie





# Infection



# Central venous catheter – Why?

- Administration of concentrated fluid, catecholamins, chemotherapy
- Measurement of Central Venous Pressure
- Parenteral nutrition
- Dialysis and Continual elimination
- Temporary cardiostimulation
- Unable maintain other (peripheral) vein access



# Central venous catheter – Contraindications

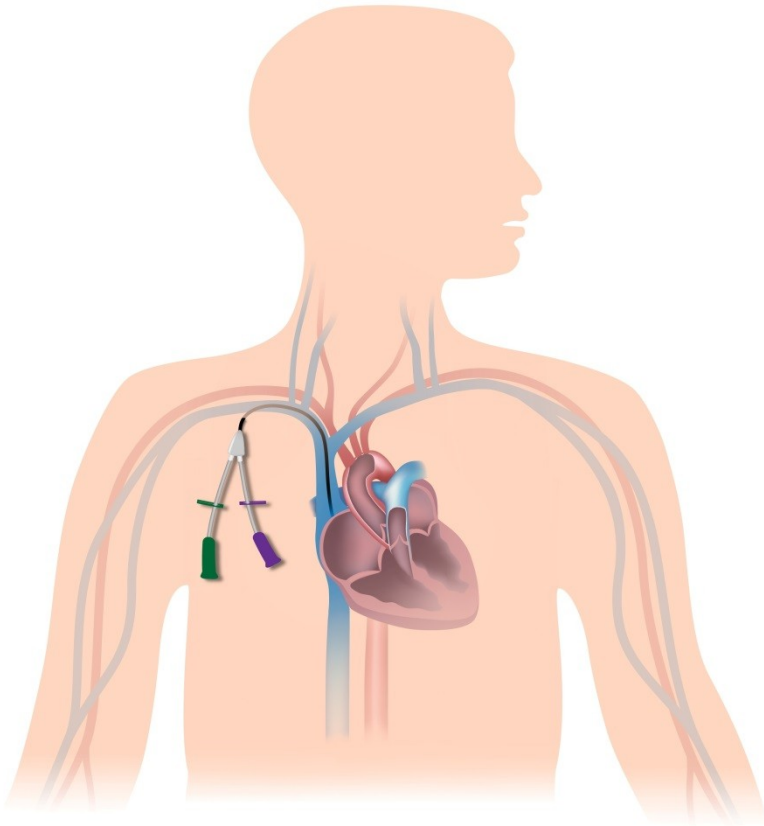
- impaired coagulation
- thrombocytopenia
- tumor nearby or infection, trauma in place of puncture
- Pneumothorax or lung pathology contralaterally
- troubles with placing head

# Central venous catheter – Where?

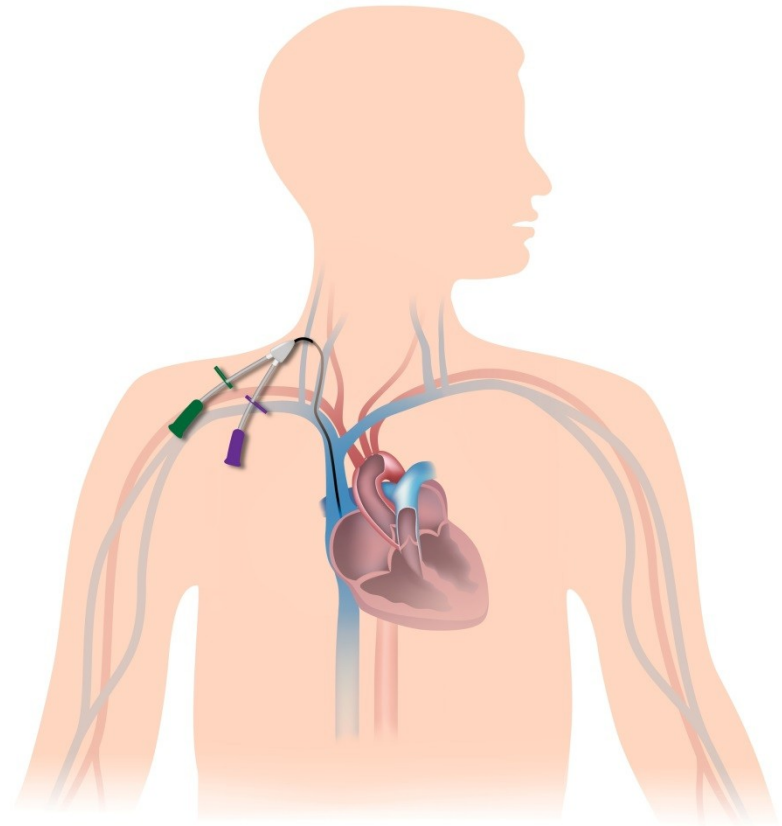
- v. jugularis interna
- v. subclavia
- v. femoralis
- (v. brachiocephalica)



# Central Venous Catheter

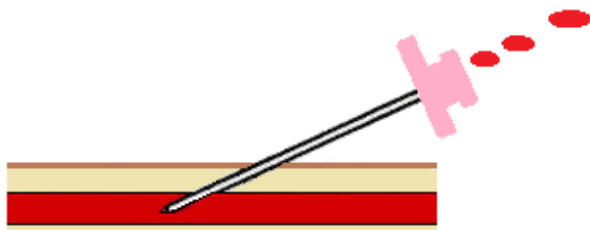


Subclavian vein insertion

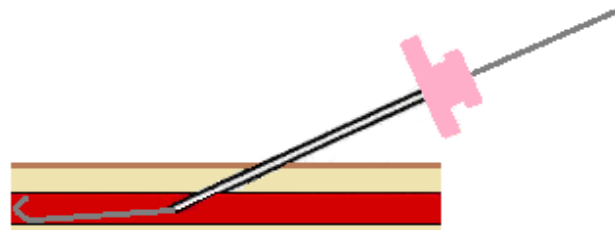


Internal jugular vein insertion

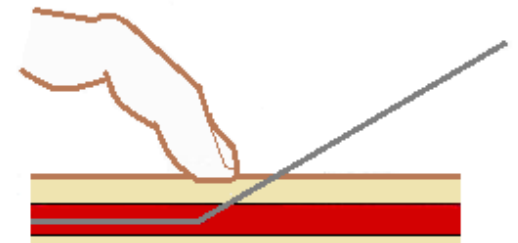
# Seldinger technique



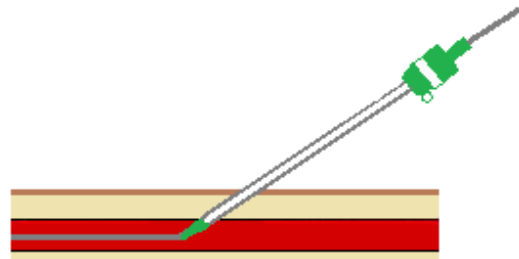
A. Pulsatile blood flow upon entry.



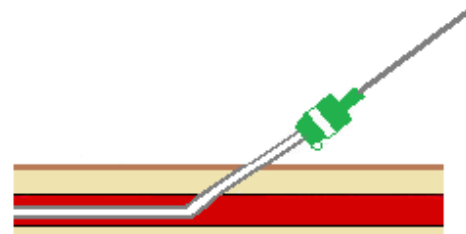
B. J-tip guidewire is advanced



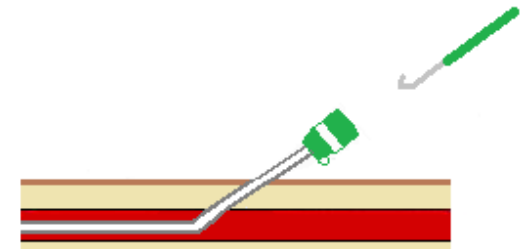
C. Needle is removed leaving guidewire inside of the vessel



D. Sheath is advanced over guidewire

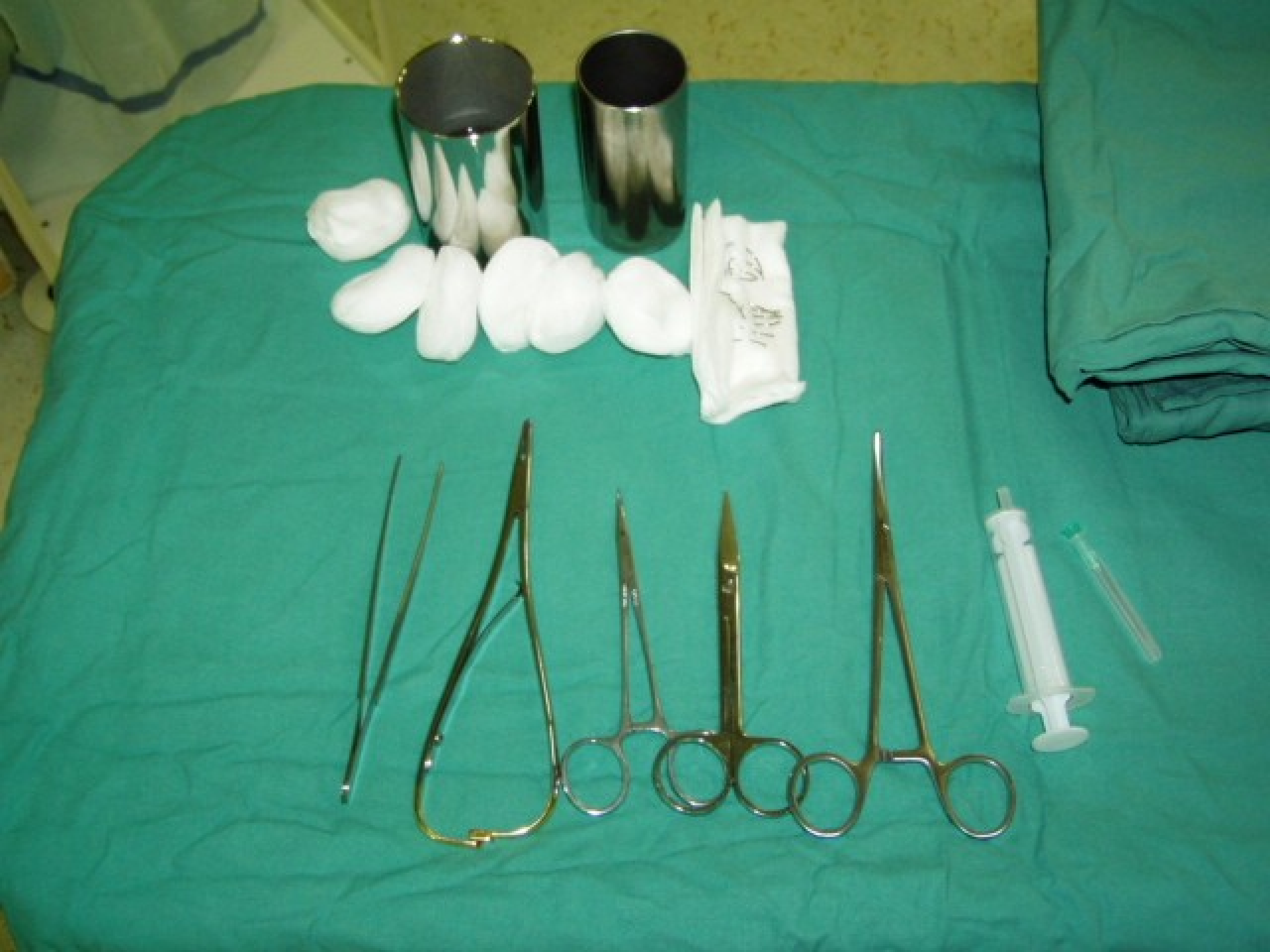

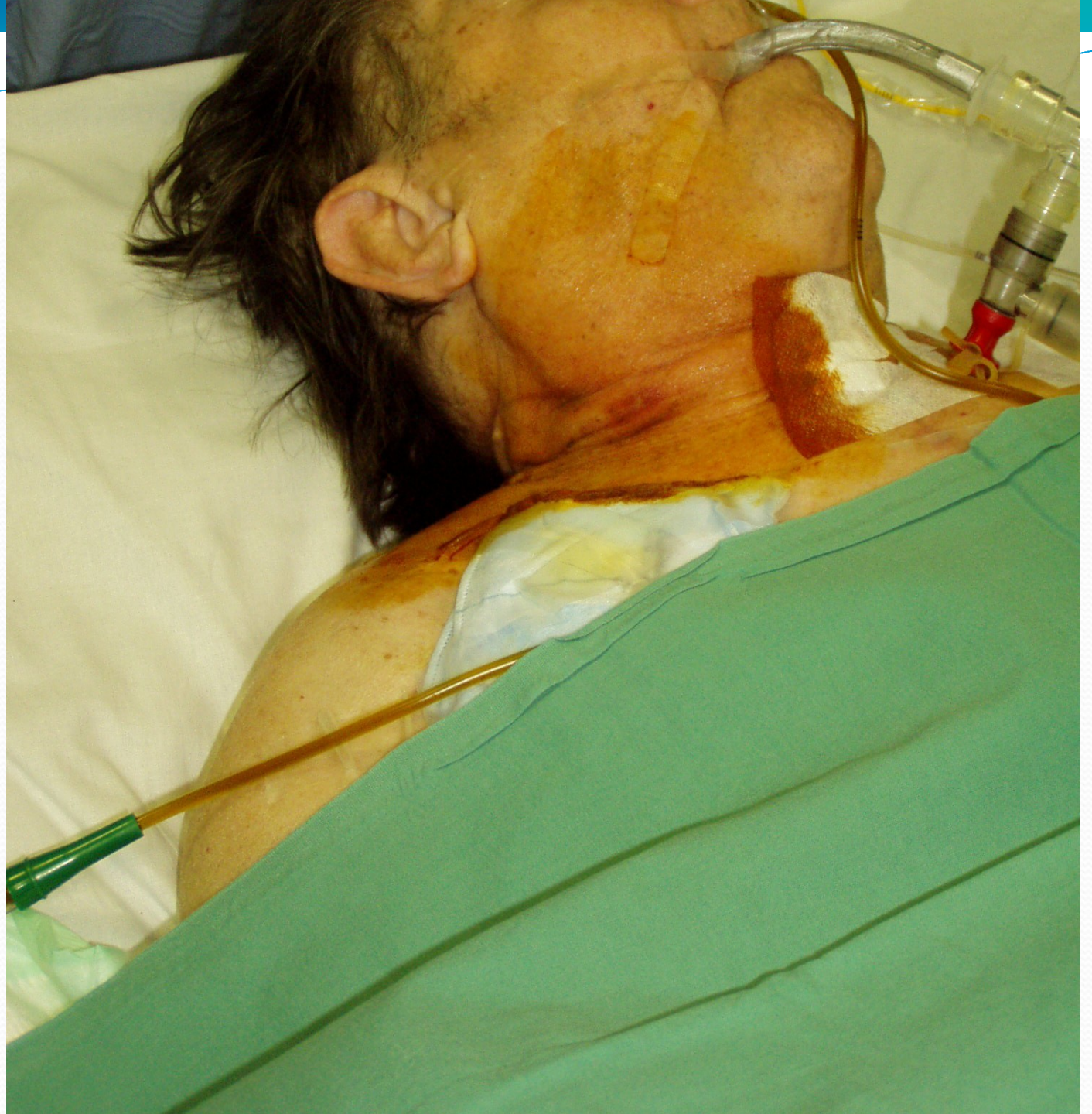E. Sheath advanced to skin entry



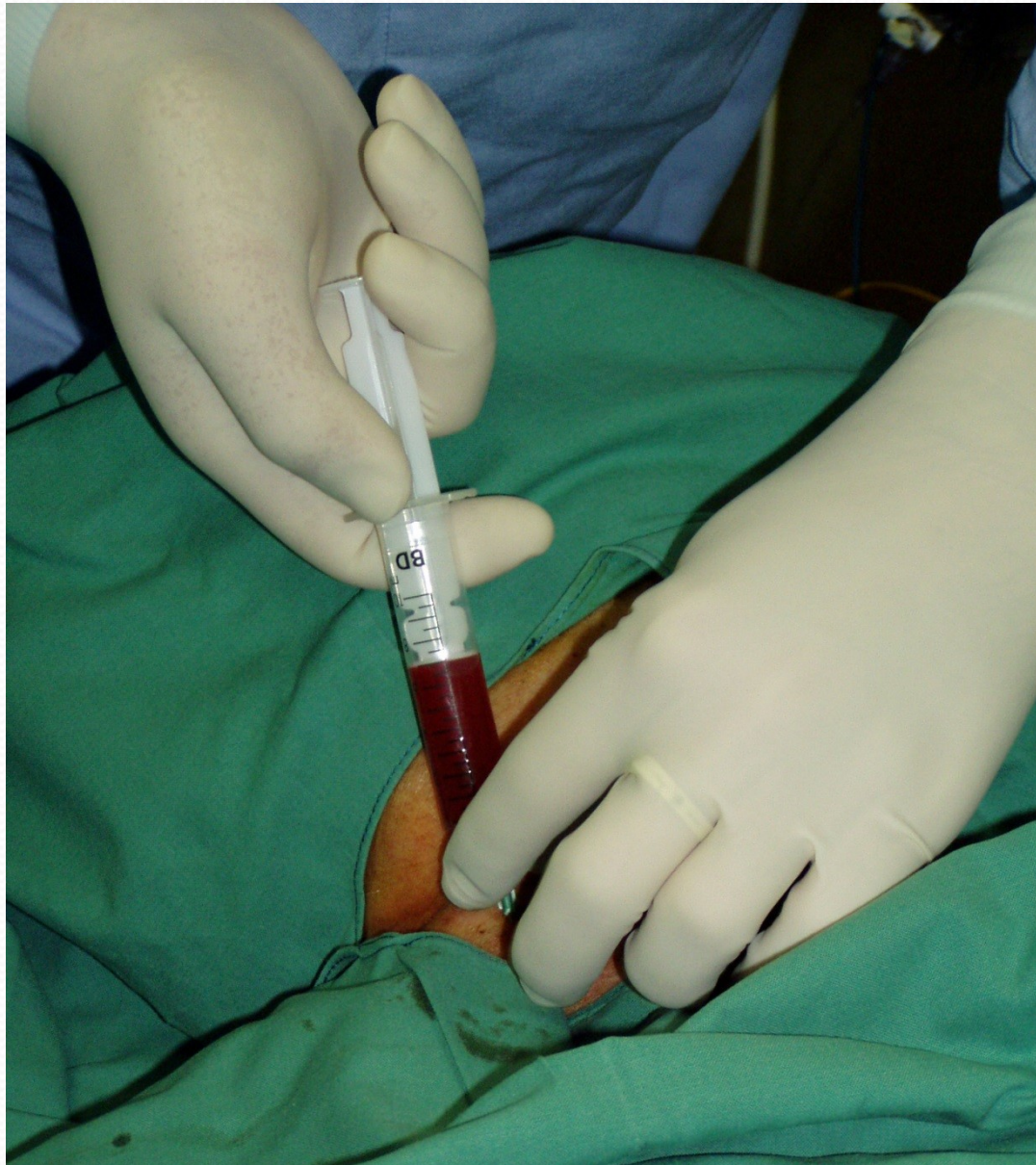F. Guidewire and dilator removed.



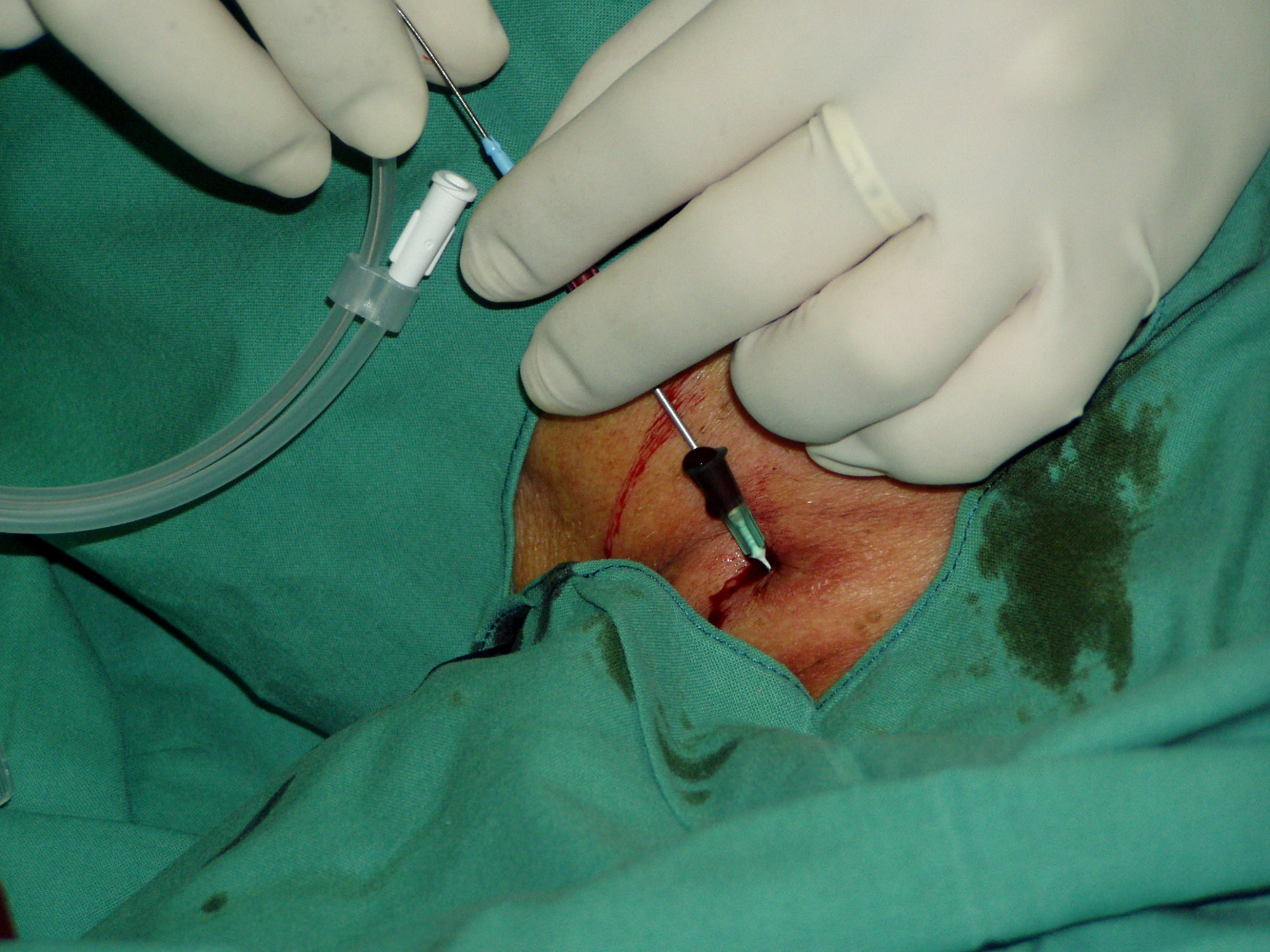




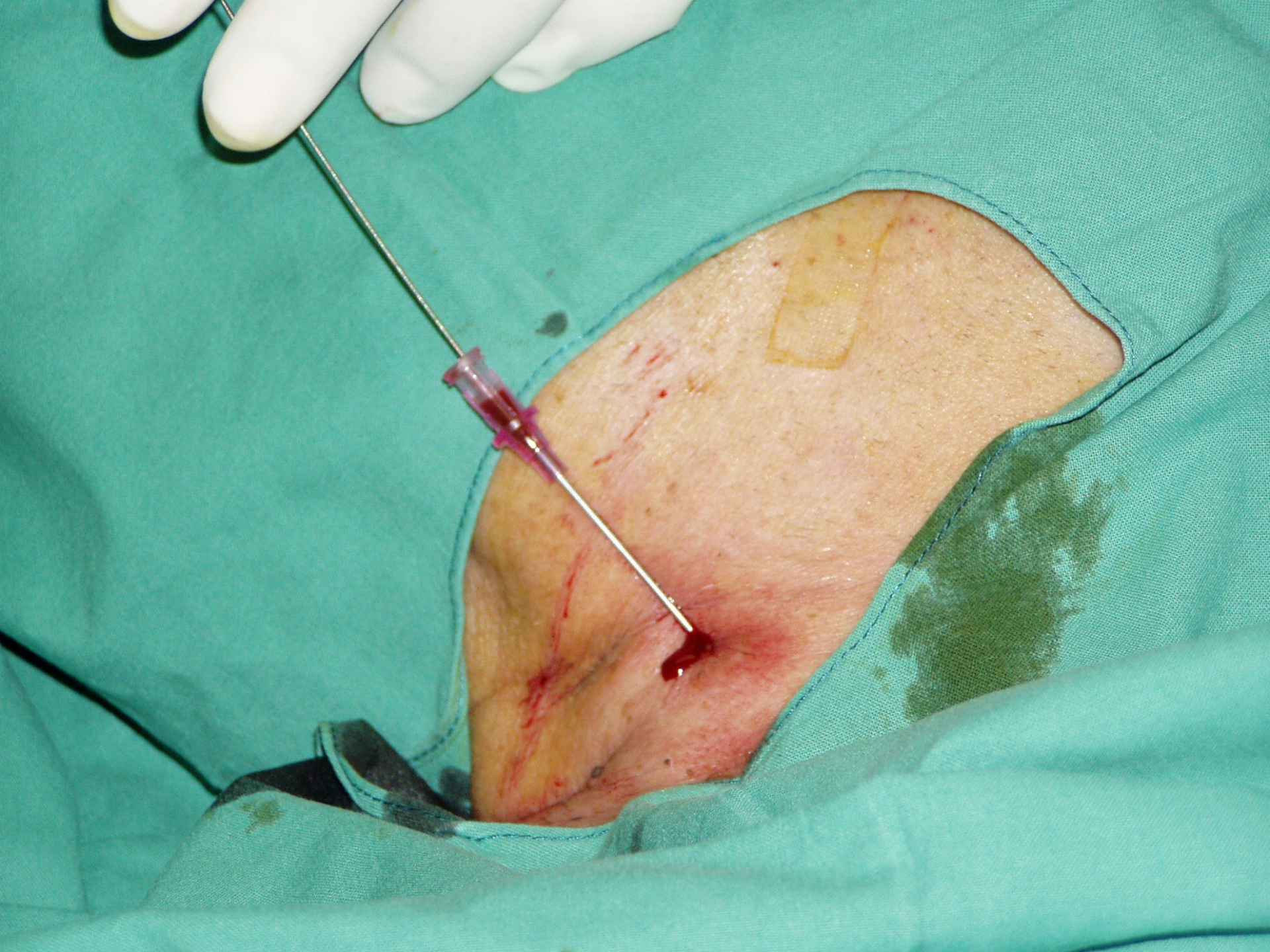




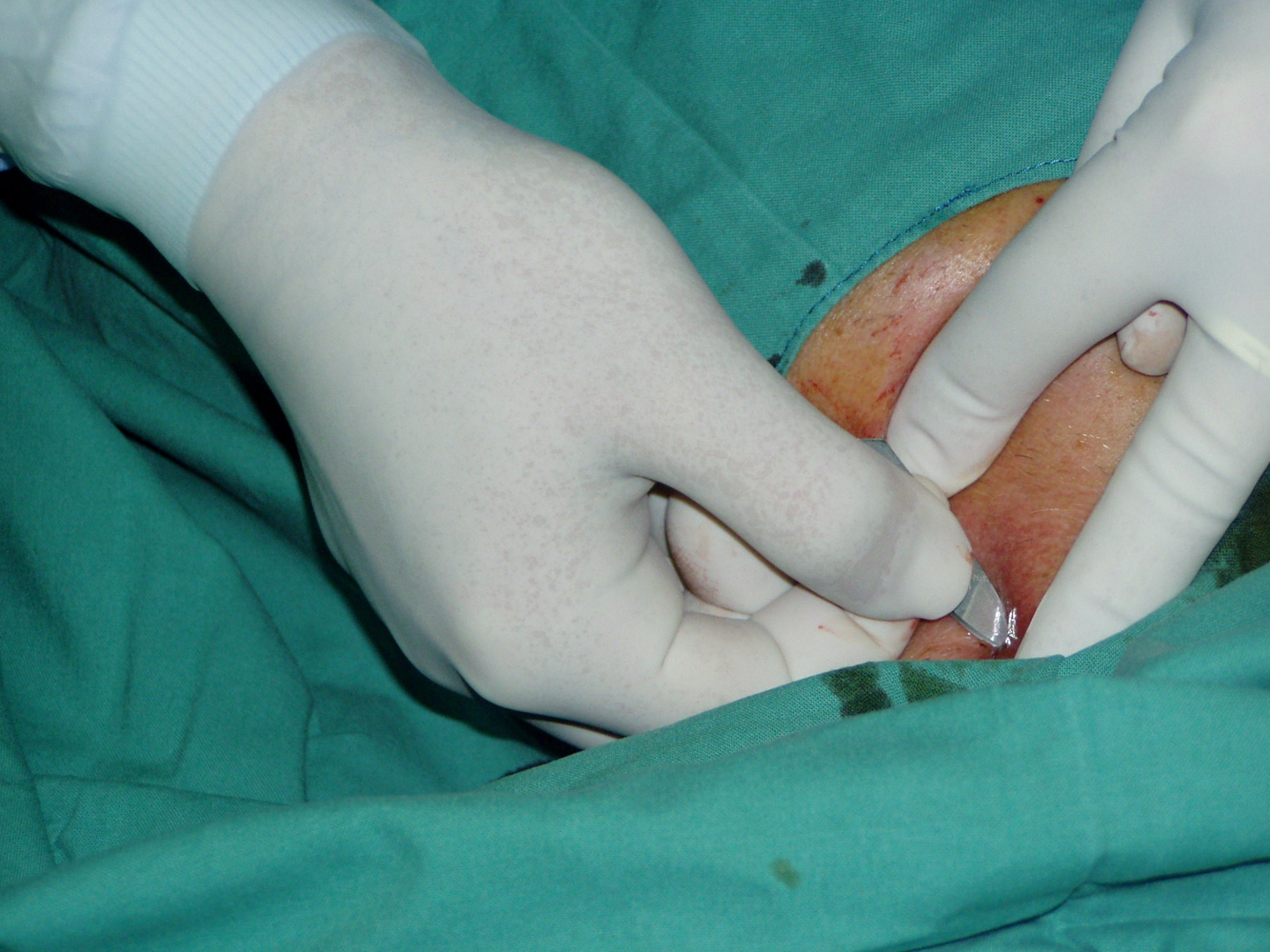




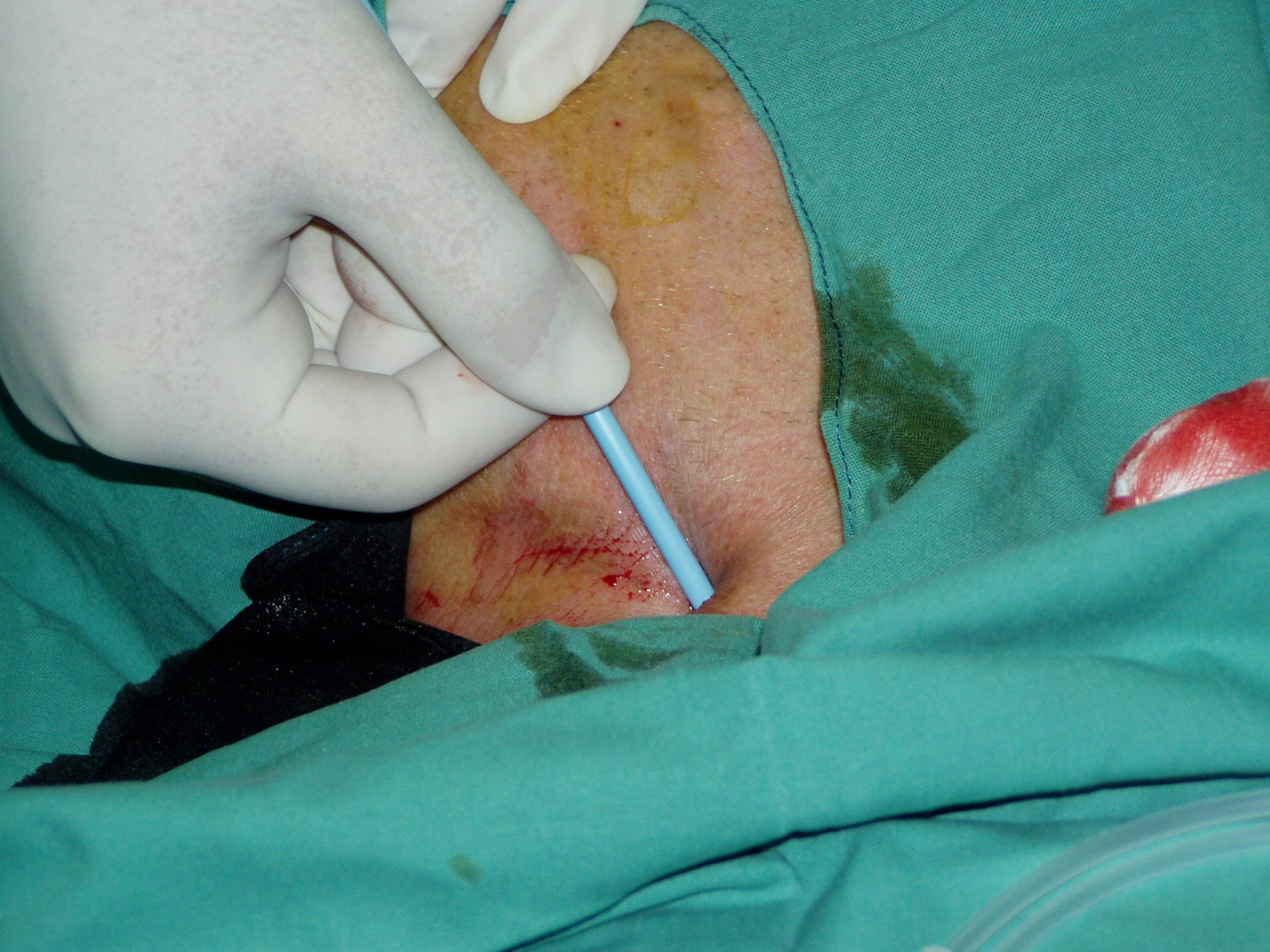


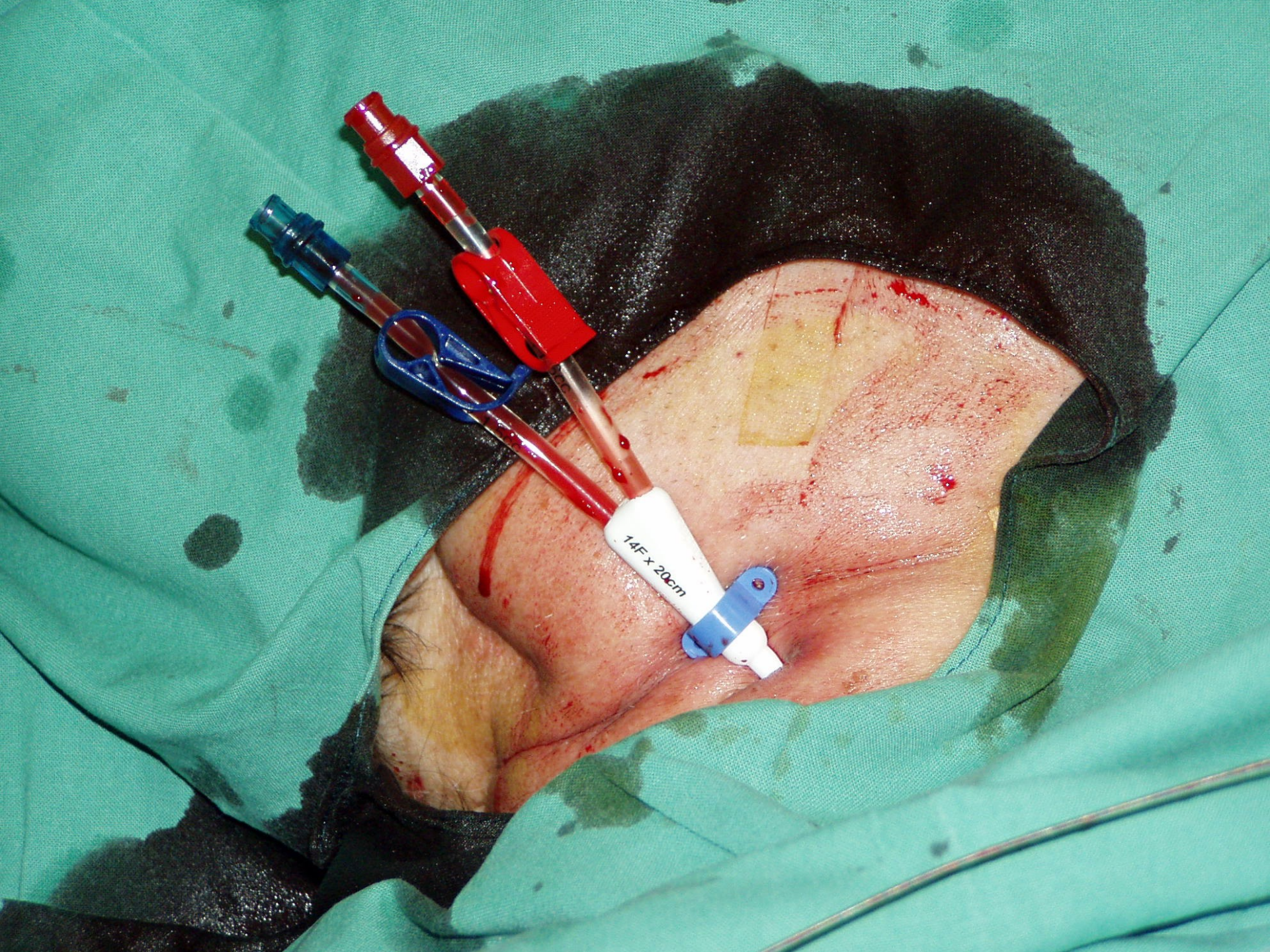




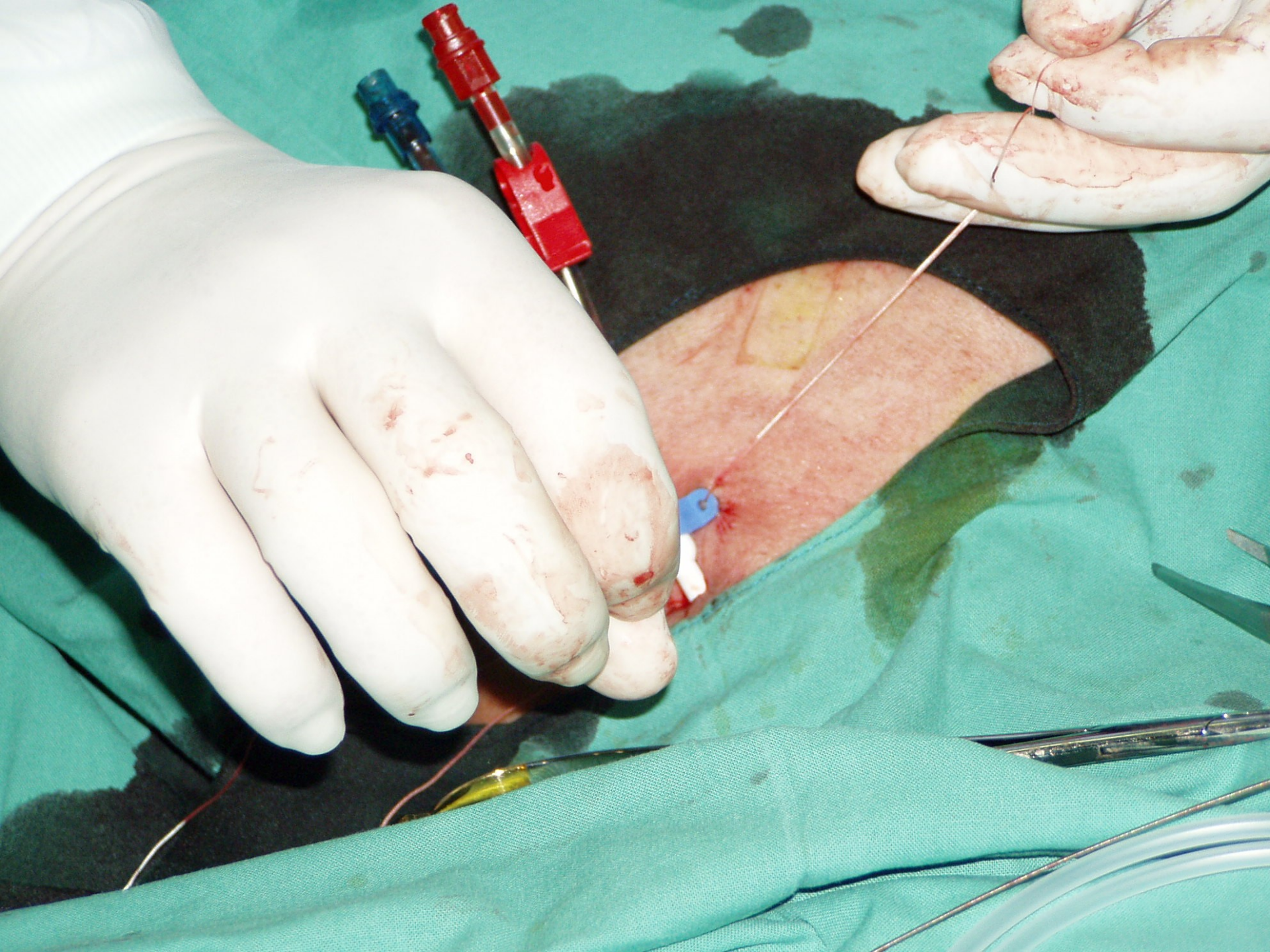














# Central venous catheter

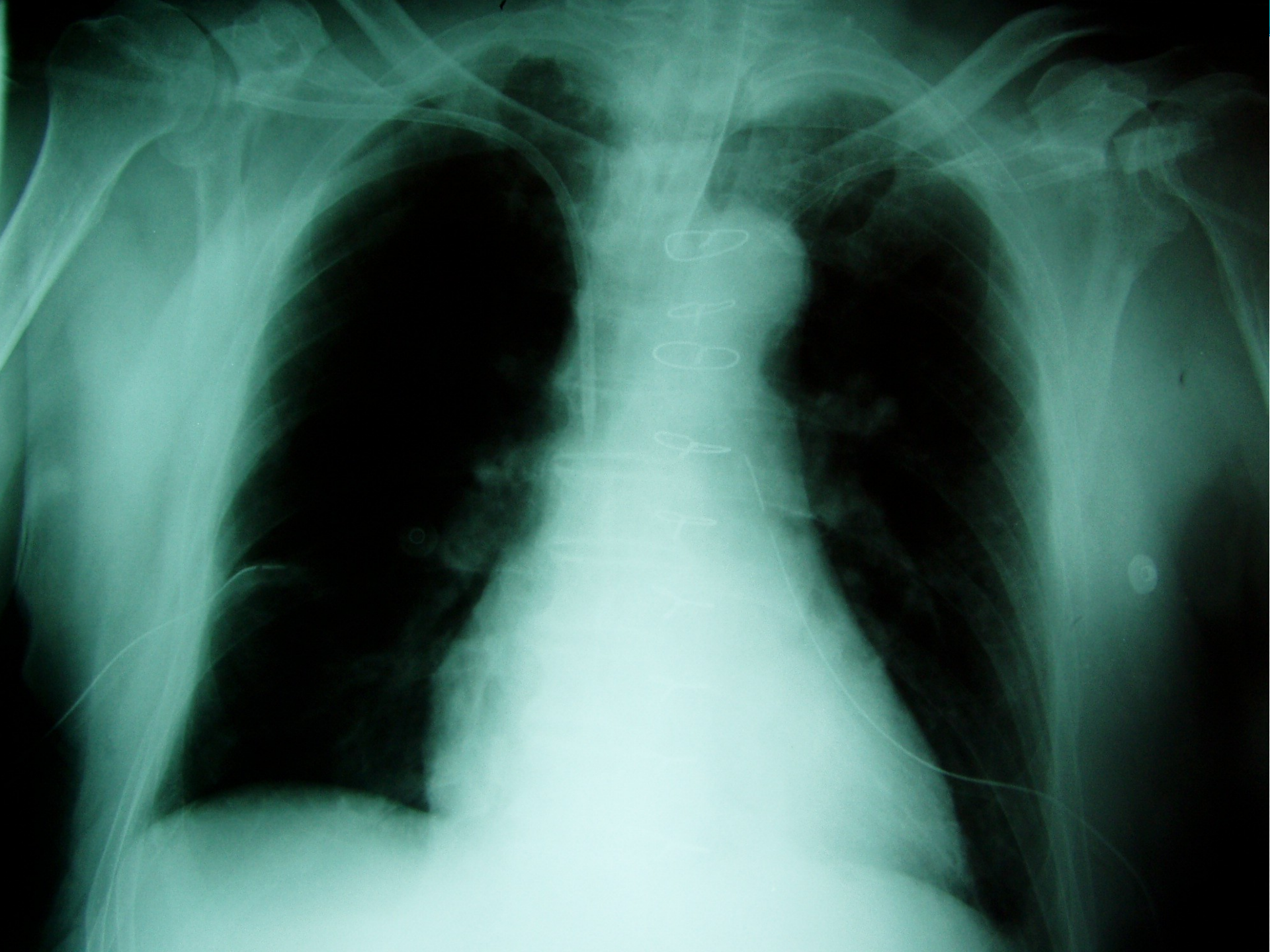## - What to do after cannulation

- sterile cover
- control chest X-ray
  - exclude PNO
  - check position of catheter

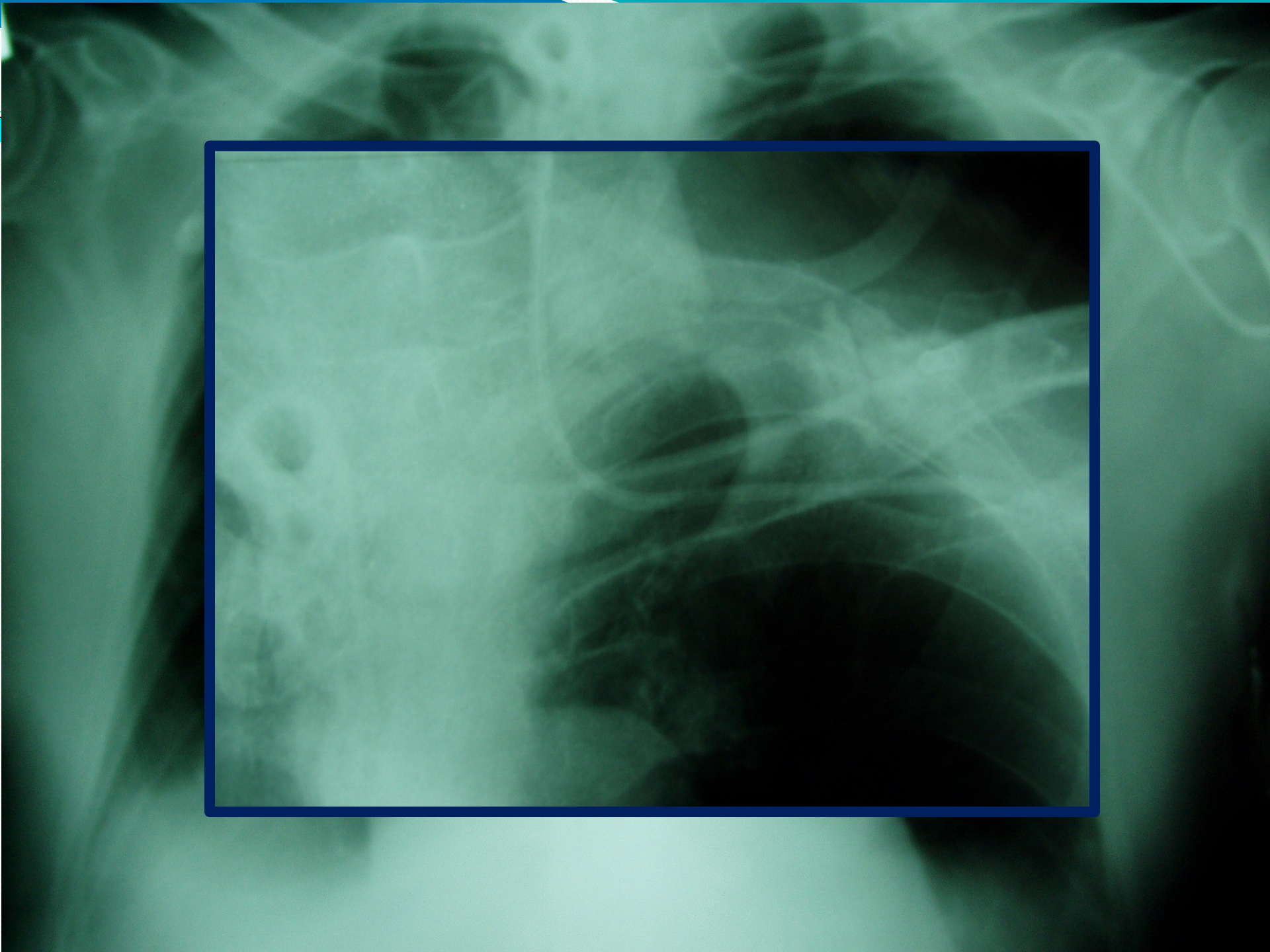


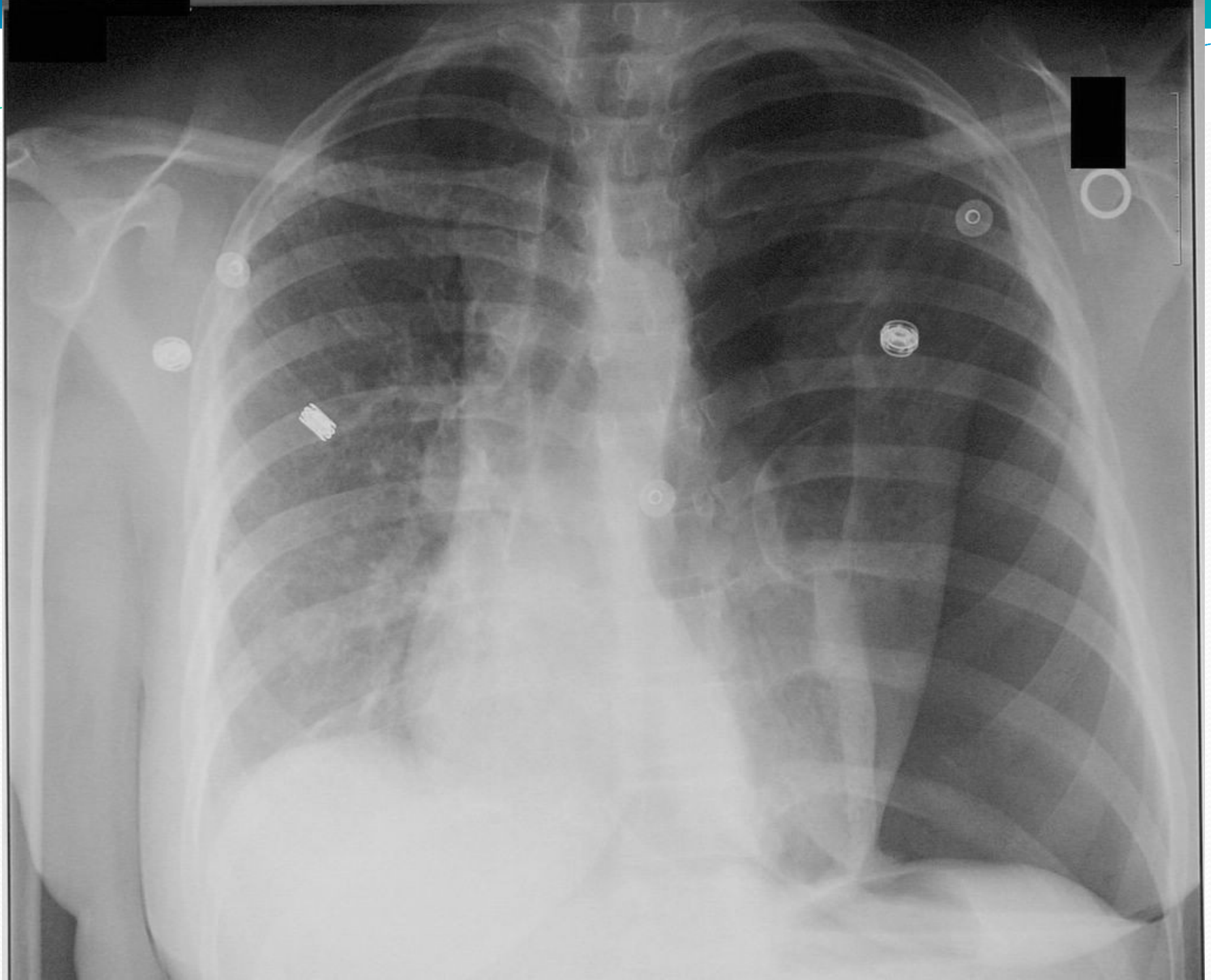
# Central venous catheter - Complications

- arrhythmias
- PNO
- bleeding
- puncture of arteria
- damage of plexus brachialis
- air emboly
- thrombosis (v.femoralis)
- infection, sepsis





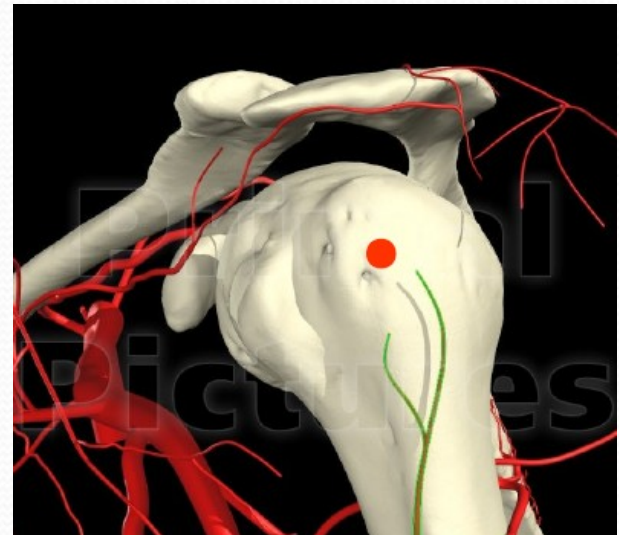




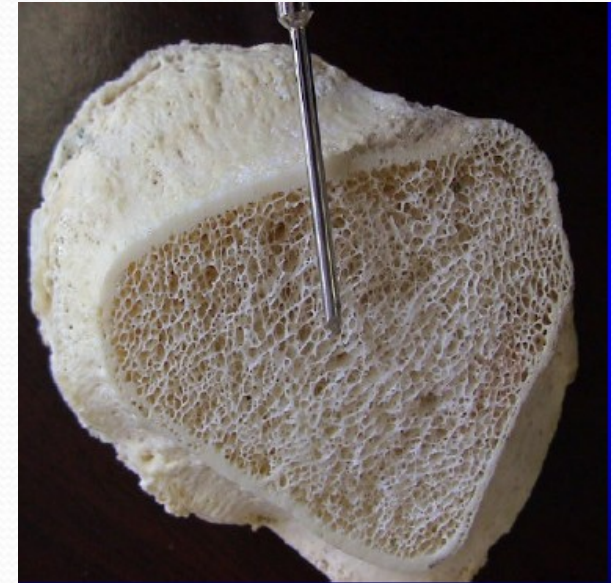
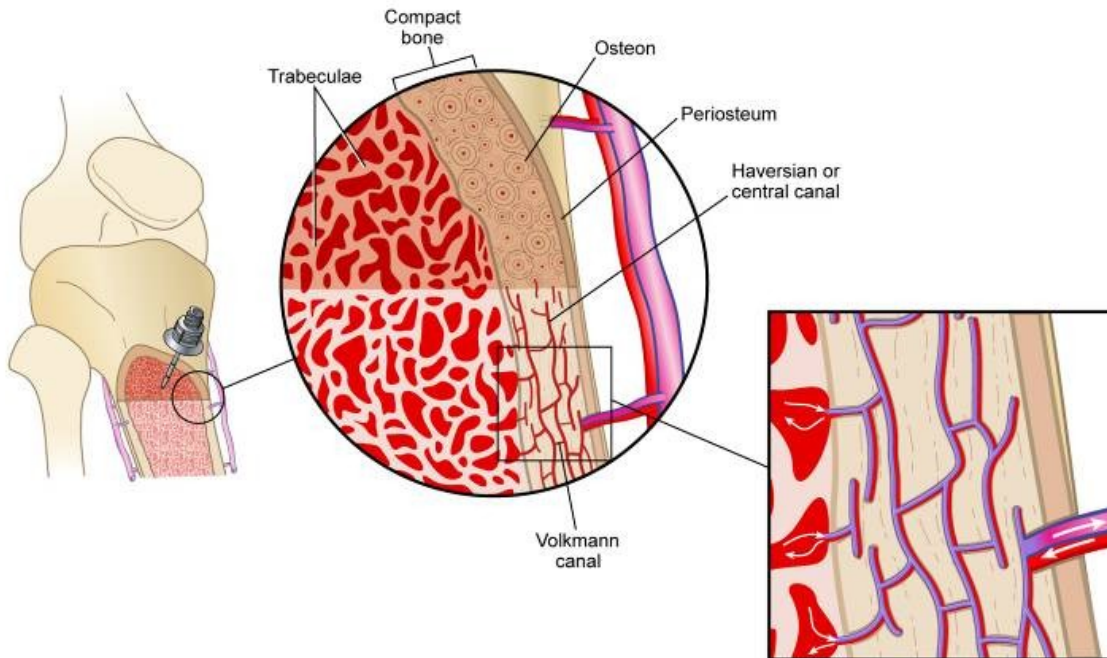


# Intraosseal access

- children
  - tuberositas tibiae
- adult
  - tuberositas tibiae
  - maleolus medialis
  - caput humeri

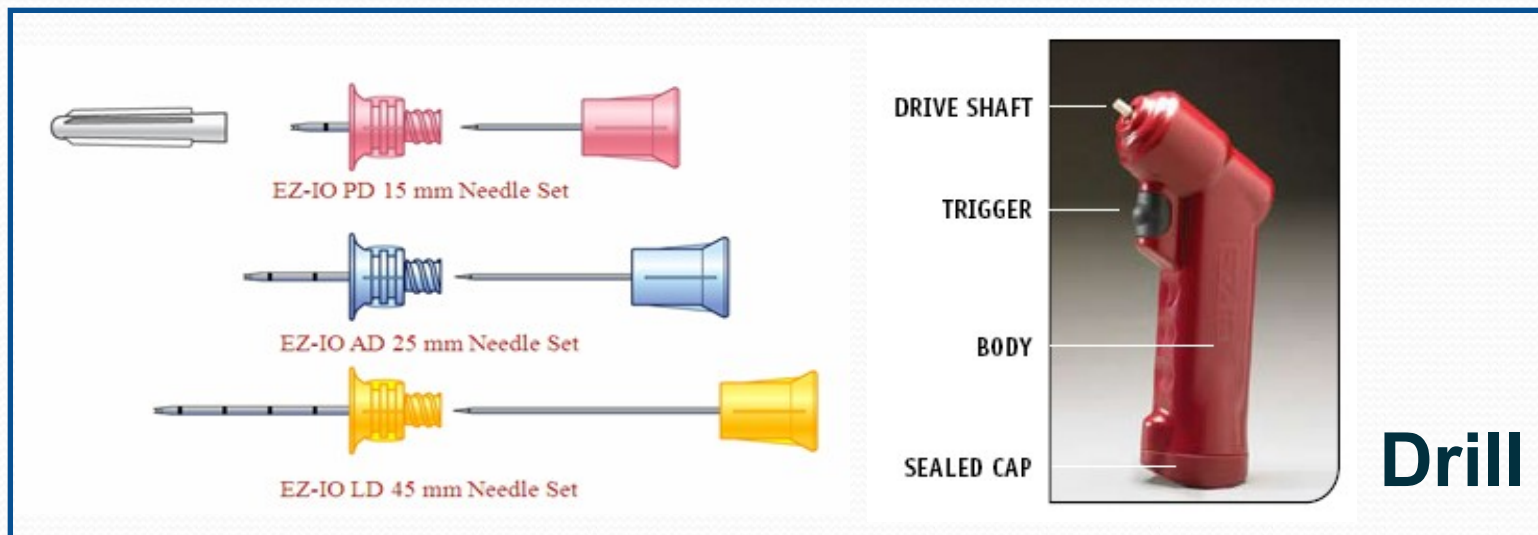
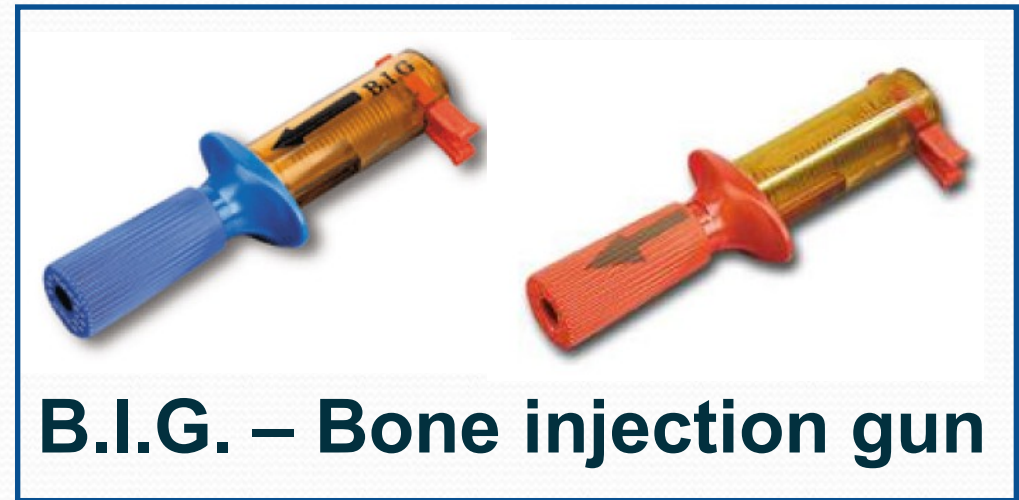

# Intraosseal access

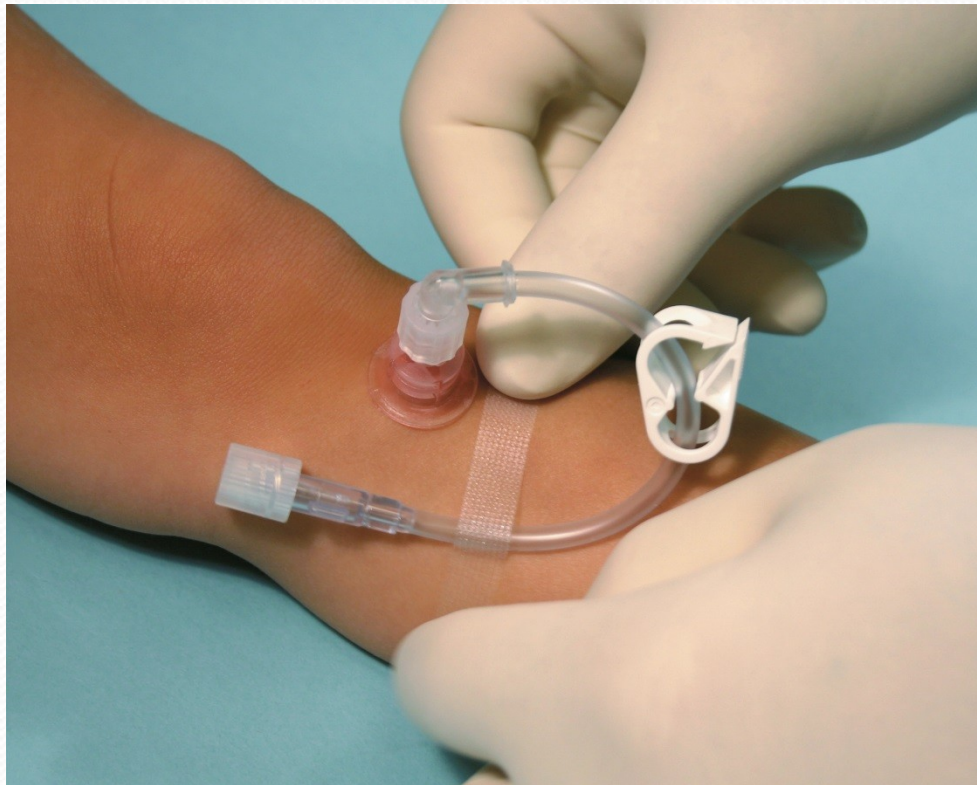




# Intraosseal access – how?



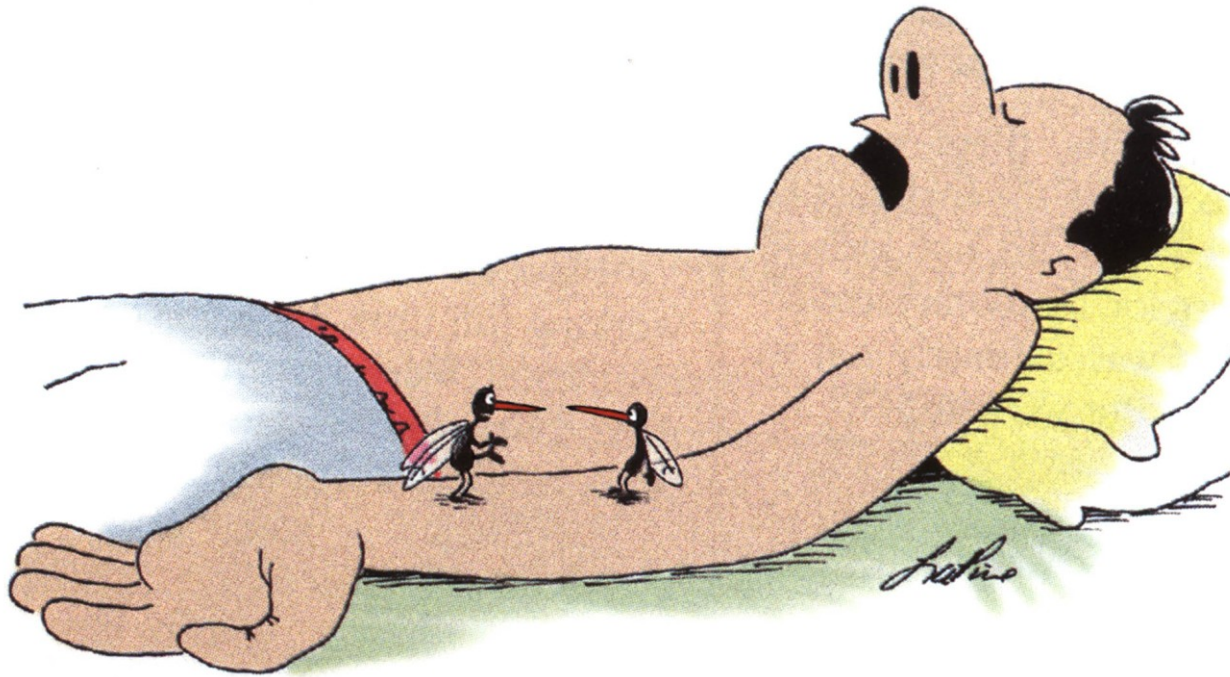
# Intraosseal access





# Thank you for your attention

## Questions?



"Sometimes I can't find a vein,  
even when my life depends on it"