

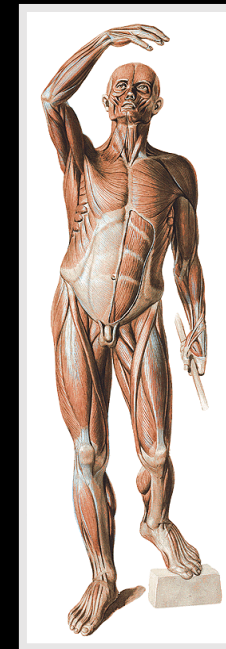
GENERAL MYOLOGY

(Muscles - an active part of the locomotor system)



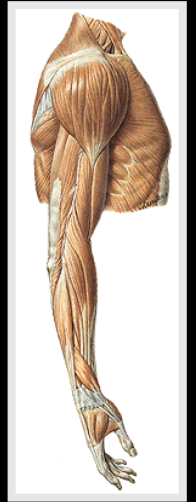
General function of muscle

- *produces **movement** in sites of skeletal junctions
- ***changes shapes** and **dimensions** of various body cavities and openings
- *gives important information about the **body position** in three-dimensional space
- *important role during **thermoregulation**
- *helps to **blood and lymph circulation**
- * **verbal and non verbal communication**
- * **about 600 muscles** (♂ 35%, ♀ 32%)
- * **logistic system (supports respiration, digestion...)**

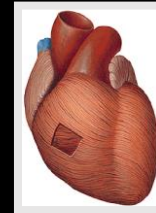


On the basis of **structure and physiological characteristics** we distinguish:

- 1) **Striated (skeleton) muscles** – muscoli sceleti (form muscles of limbs, work under control of our will, easy fatigued, spend a lot of energy, produce heat) + **skin muscles** (*musculi cutanei*)

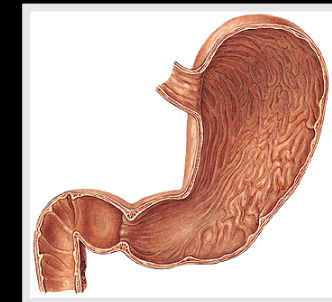


- 2) **Cardiac muscles (myocardium)**



Non-striated:

- 3) **Visceral (smooth) muscles** – forming an integral part of some hollow organs and cavities - work without our will, without fatigue).

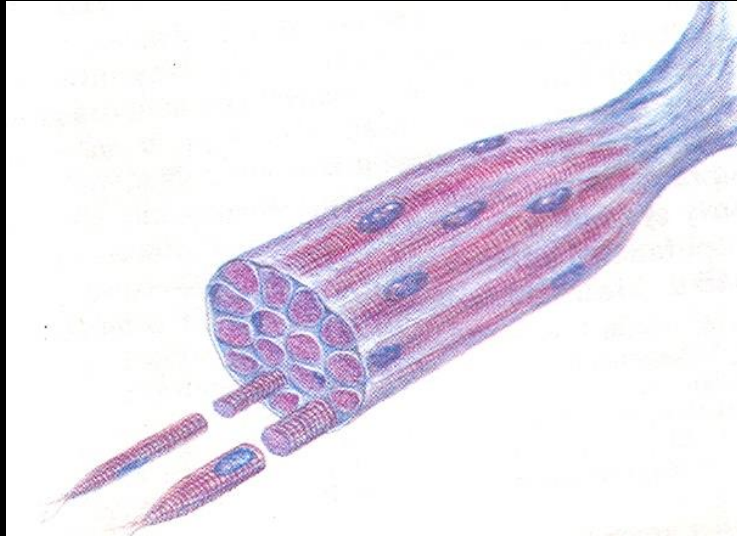


Muscle tissue

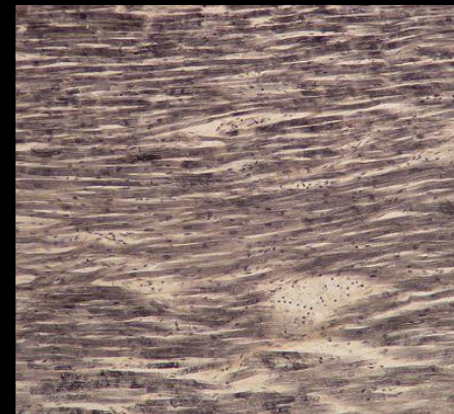
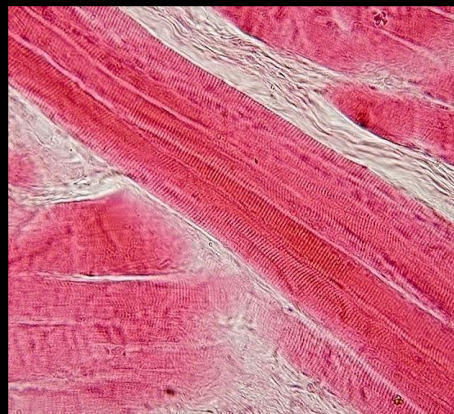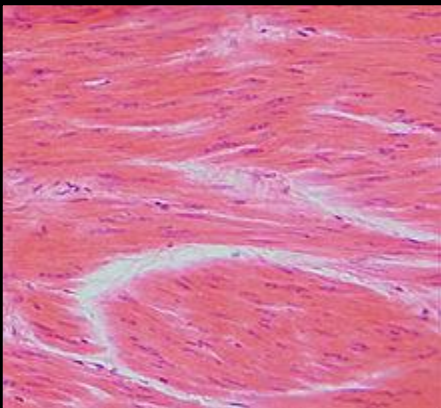
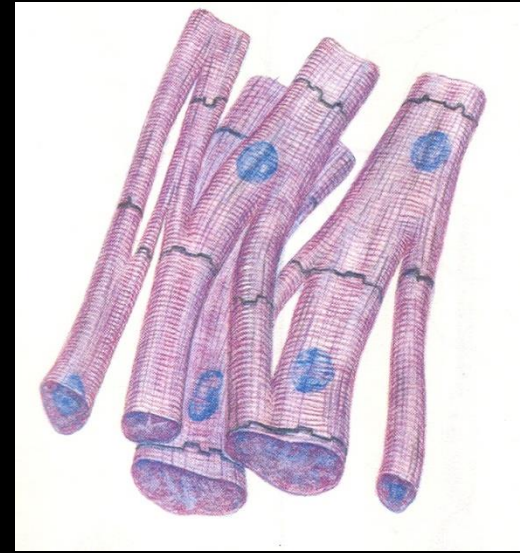Smooth muscle tissue

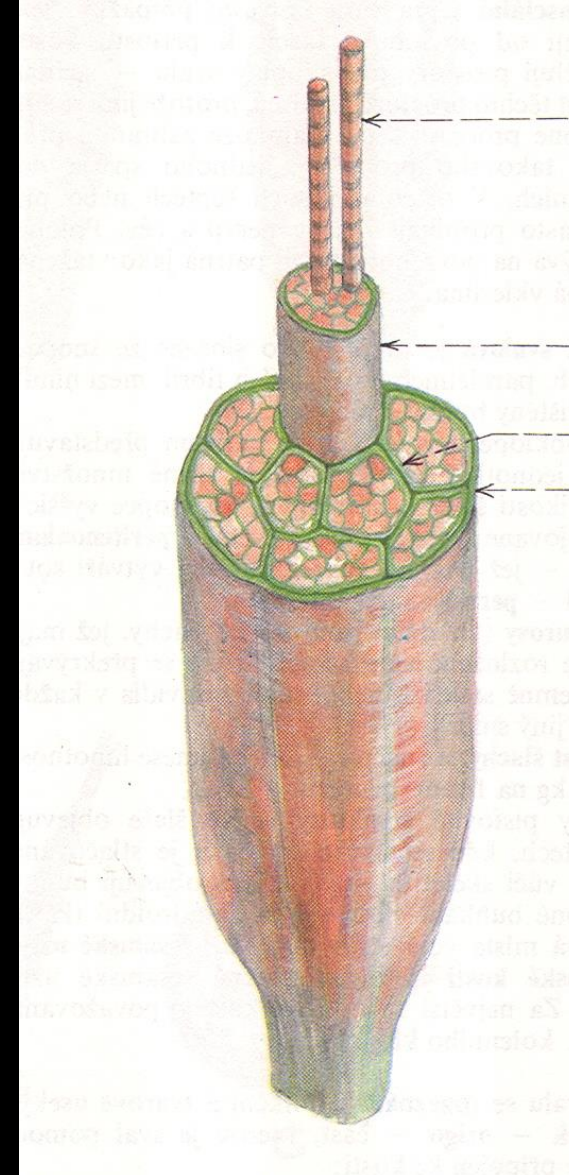
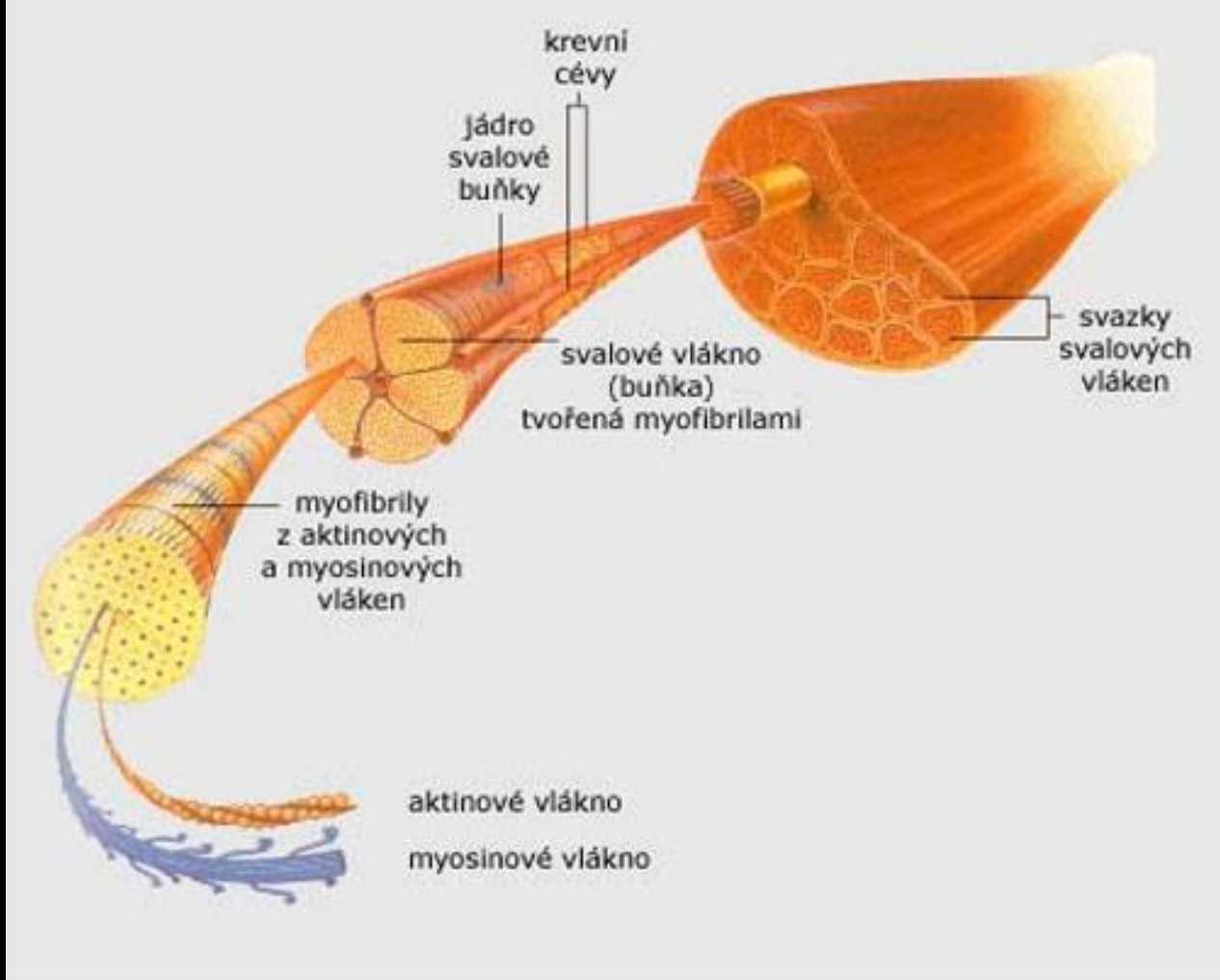


Striated muscle tissue



Heart muscle tissue





Striated fibres – endomysium

Primary and secondary muscle bundles – **perimysium internum**

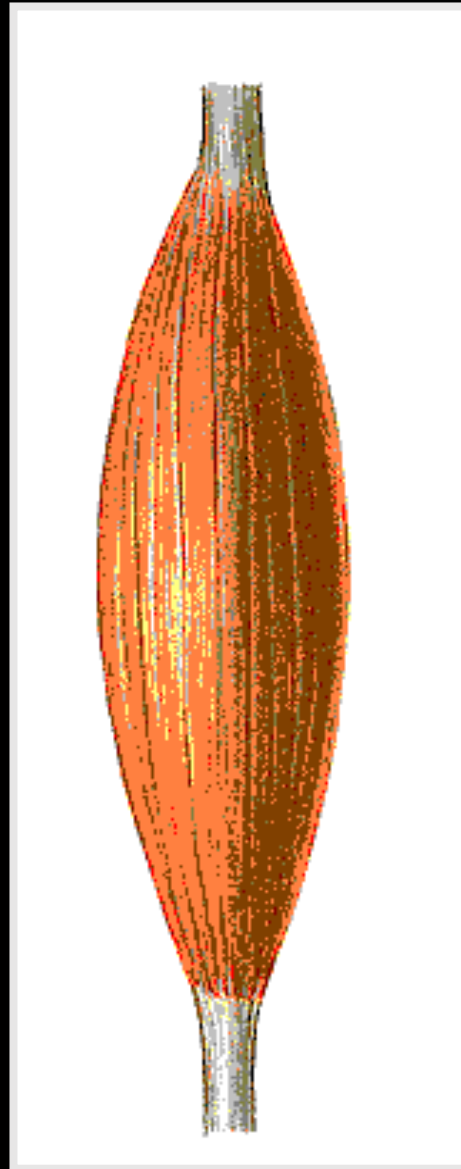
Surface of muscle **perimysium externum** – **fascia propria musculi**

Common structure of muscle

Origo (origin)

Fascia

**Tendo, aponeurosis
Insertio (insertion)**

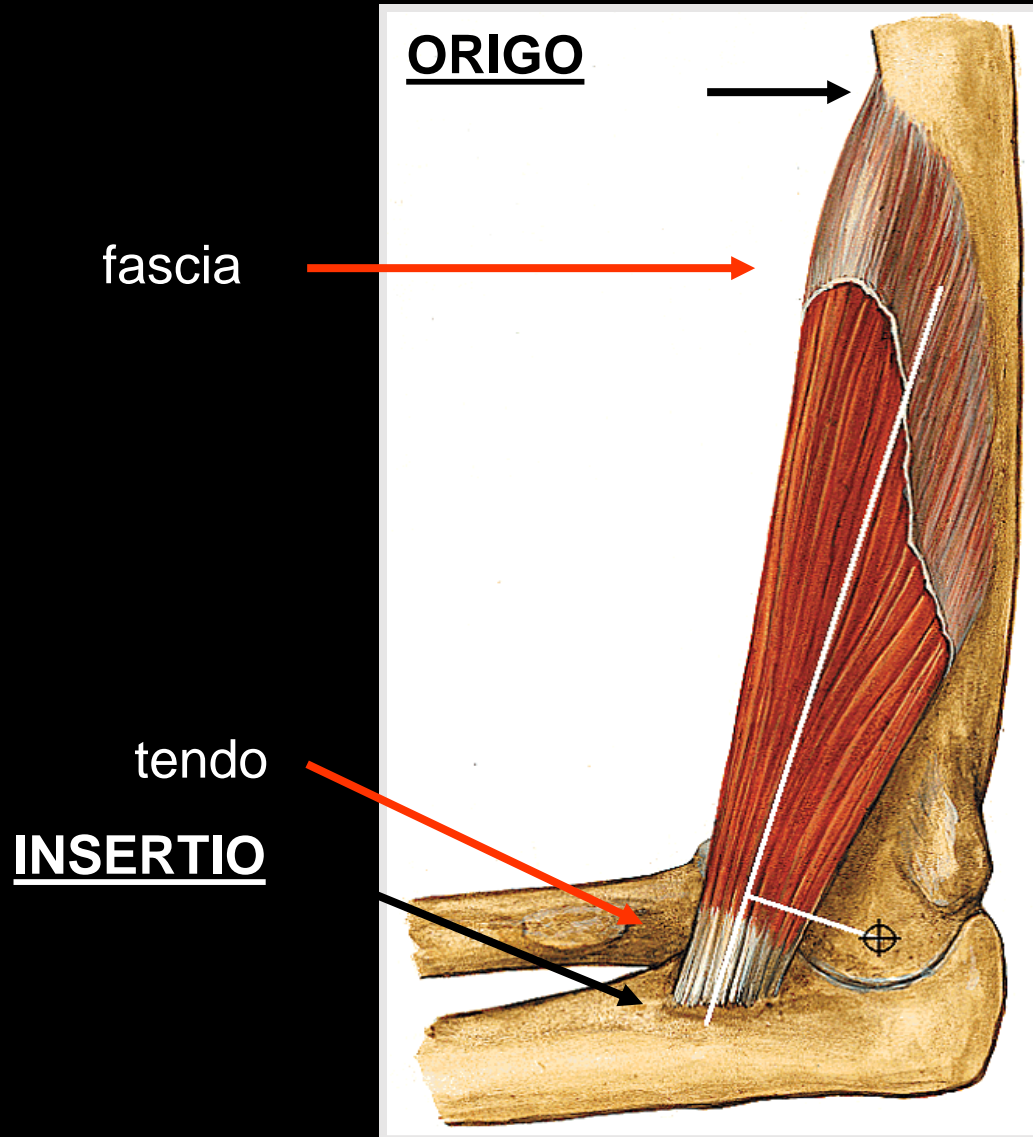


Caput (head)

Venter (belly)

Cauda (tail)

Structure of muscle



fibrous membrane – *fascia* – separates the muscles (or groups) from adjacent structures.

Vessels and nerves enter into muscle by its hilus (rich ramification)

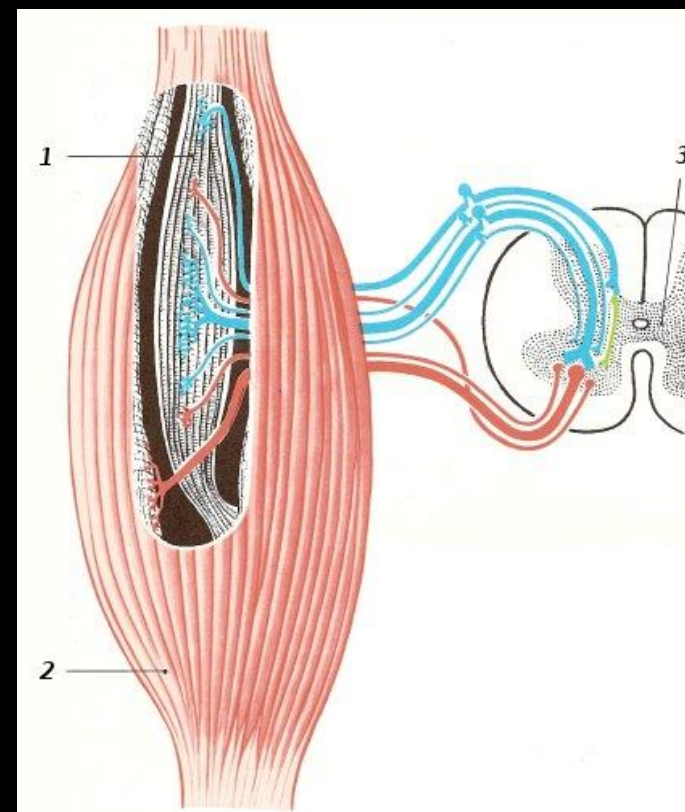
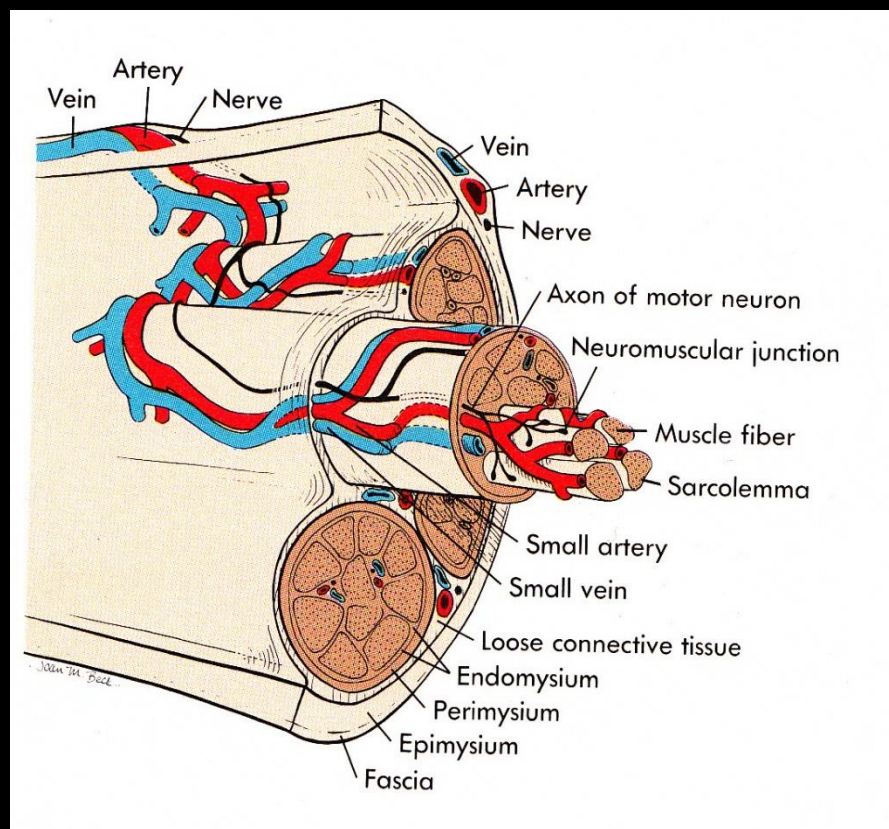
Tendons are attached to the bones by Sharpey's fibres

Vessels and nerves of the muscles

Hilus – vessels and nerves

Sensory innervation – muscle and tendon
spindles

Motor innervation – motor plate



Auxiliary facilities of muscles

Fascias – allow to move one muscle against the other

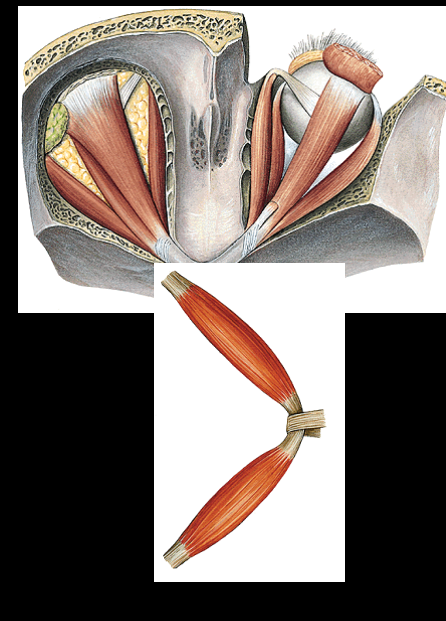
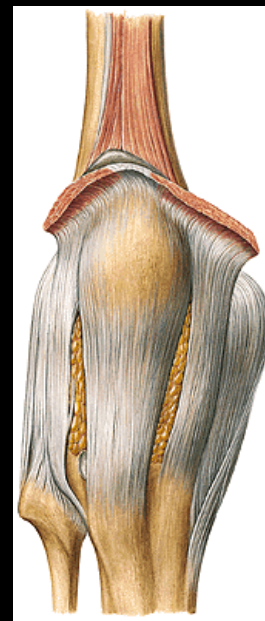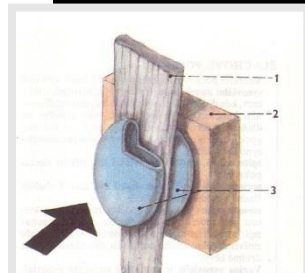
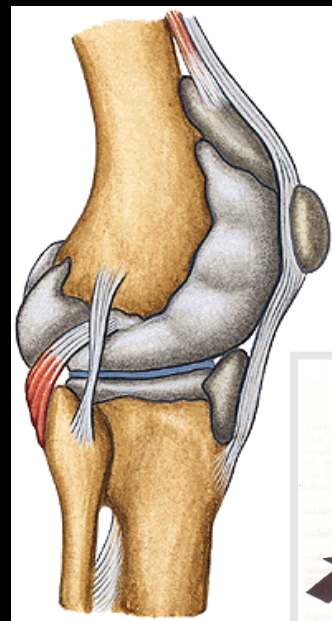
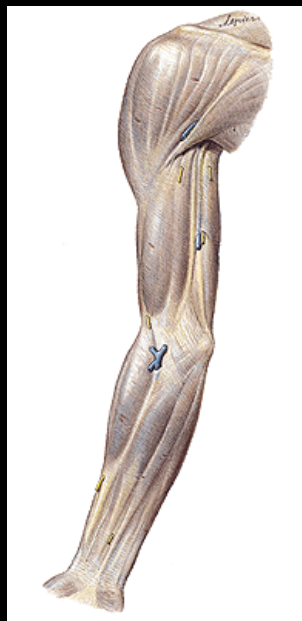Synovial bursae – protect muscle tendons against friction

Tendons, aponeurosis

Muscular trochleae – fibrous loops keeping tendon to bone, permit change of direction of muscle pulling

Sesamoid bones – at the places of pressure

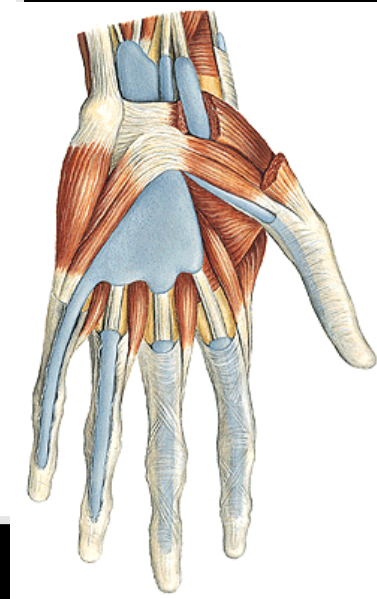
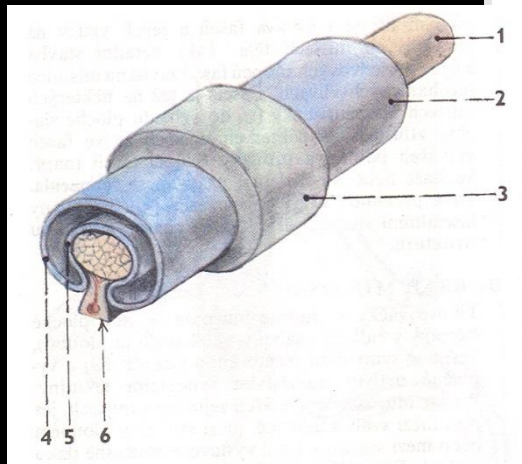
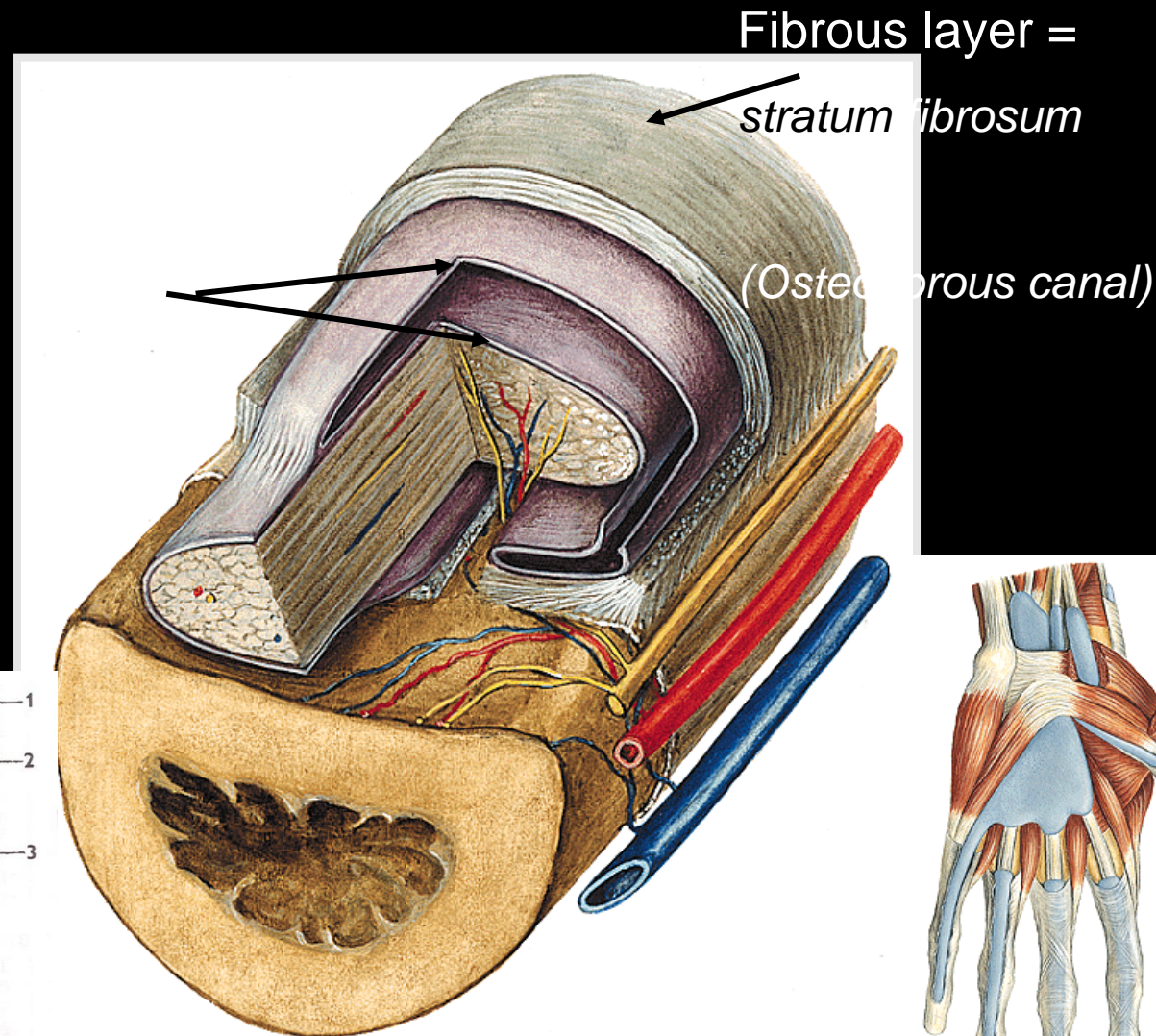
Tendon sheaths – vaginae tendinum



Auxiliary facilities – tendon sheaths = vaginae tendinum

Along the tendons, closed, increasing sliding capacity of tendons

Synovial layer = *stratum synoviale* (ext. and int. layer with **mesotenonium** for penetration of vessels into tendon)



Division of muscles according to the shape



- **long type** (predominantly limb muscles)

- **flat type of muscles** (abdominal wall muscles)

- **short type of muscles** (circumarticular muscles)

- **Composed:**

- **biceps**, begins with two heads (triceps, quadriceps)

- **digastric muscle** – *musculus digastricus* (multi-bellied muscle)

- **orbicular muscles**, *mm. orbiculares* (various types of sphincters)

- **unipennate muscles** or **multipennate** muscles

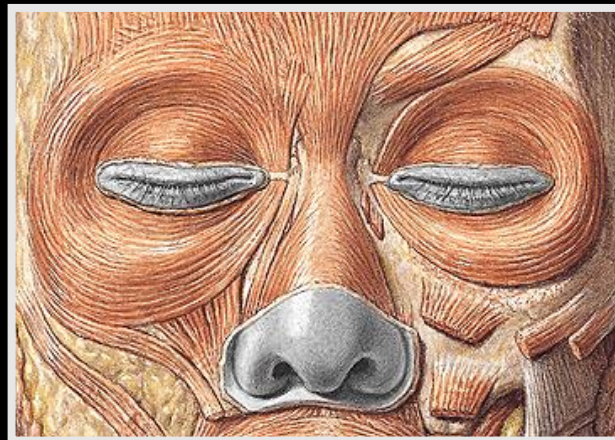
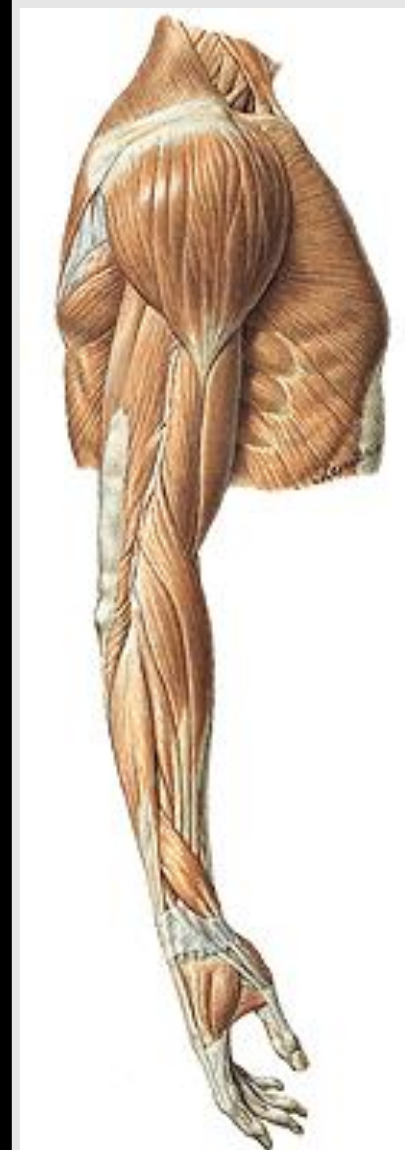
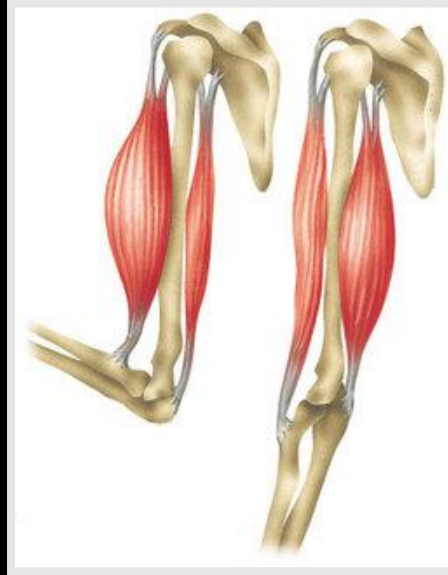Division of muscles according to the function

synergists x antagonists

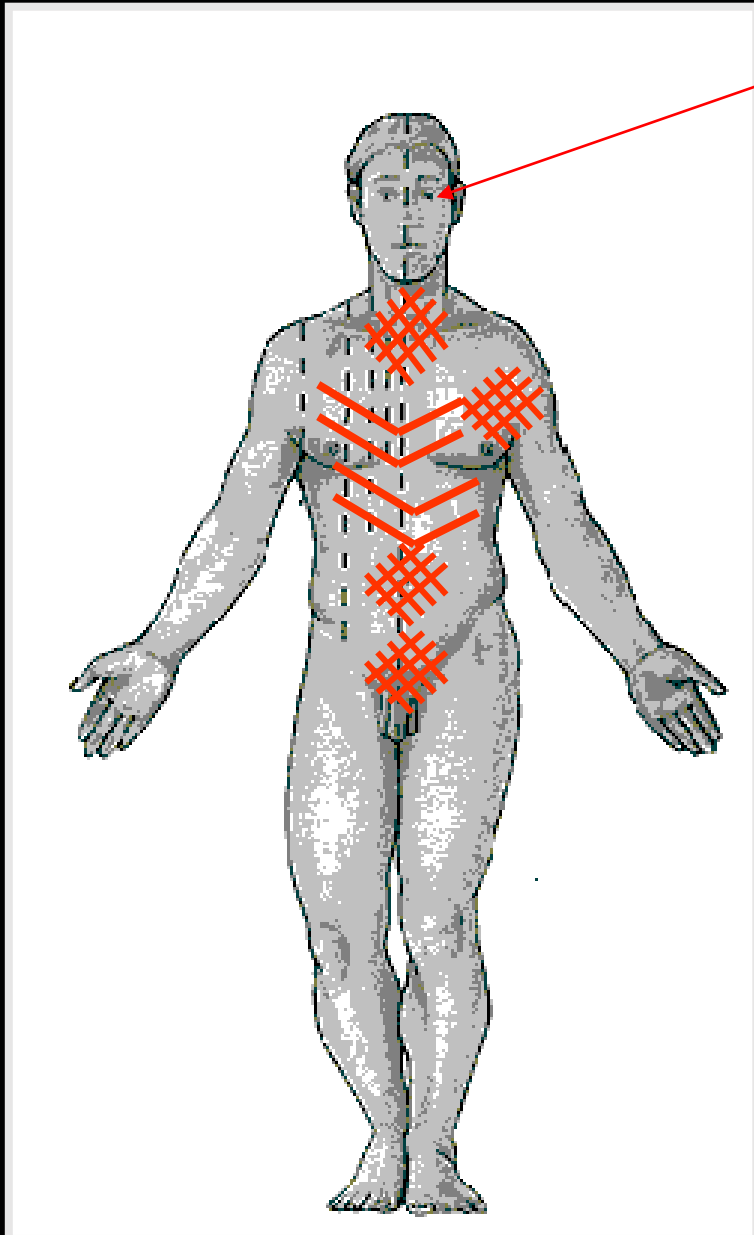
flexors x extensors f. eg.
biceps of brachium x triceps of
brachium

abductors x adductors f. eg.
abductor pollicis brevis x adductor
pollicis

dilatators x sphincters f. eg.
dilatator pupillae x sphincter
pupillae



Innervation of muscles (motor, sensory)



Cranial nerves (III. – XII.)

Spinal nerves

(31 pairs)

→ Dorsal branches

→ Ventral branches
(form plexus)

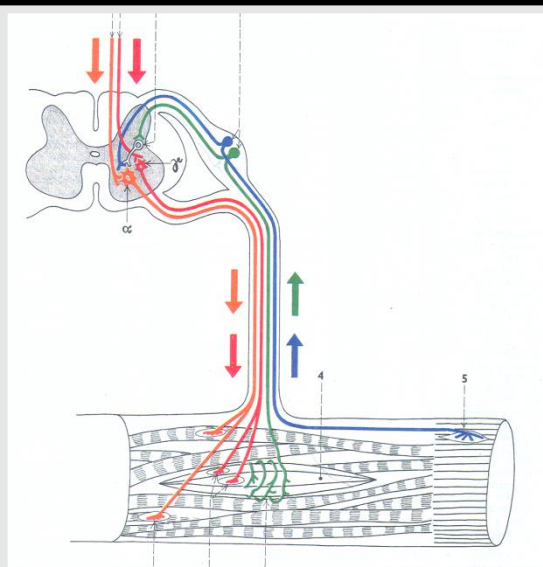
Cervical plexus

Brachial plexus

Intercostal nerves

Lumbar plexus

Sacral plexus



Division of muscles according to topography

Muscles of head

Muscles of neck

Muscles of thorax

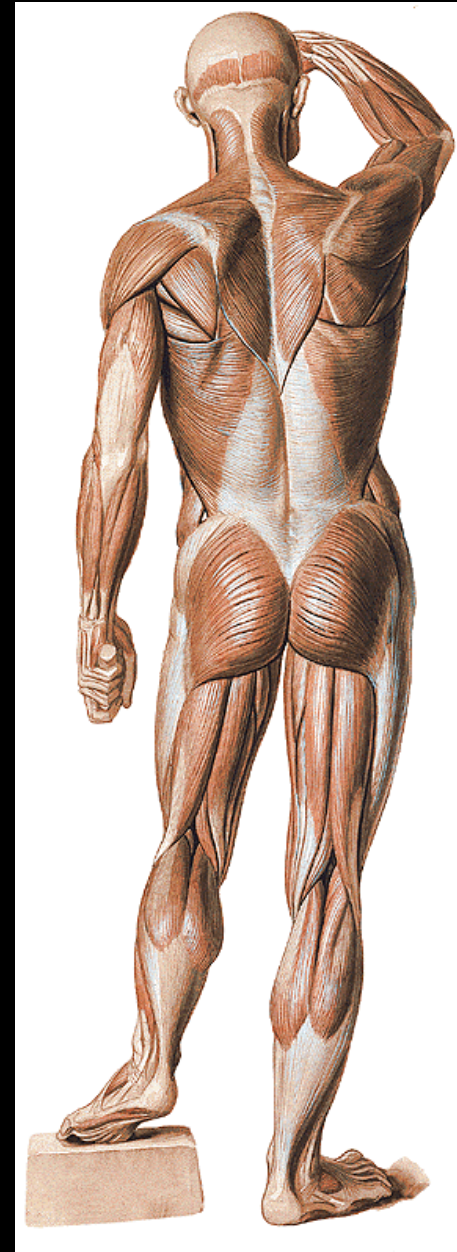
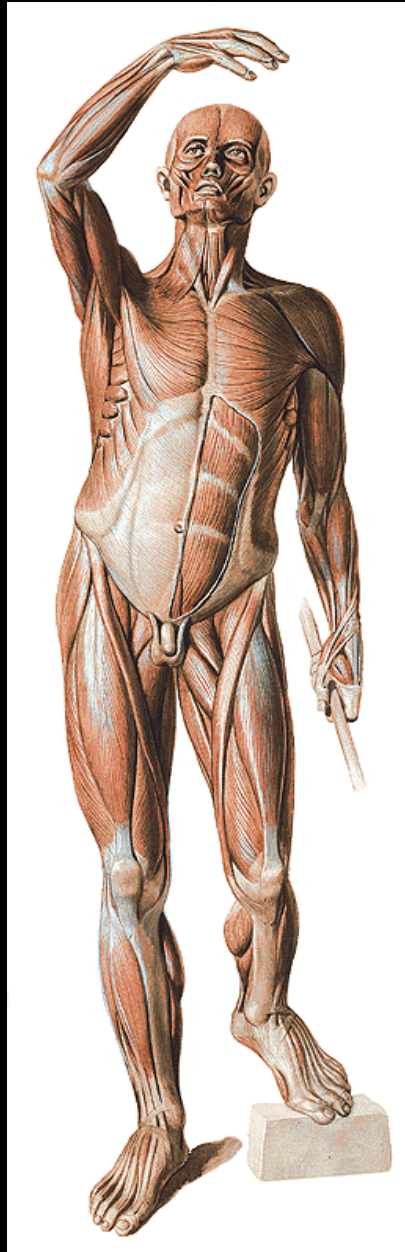
Muscles of abdomen

Muscles of diaphragm pelvis

Muscles of back

Muscles of the upper limb

Muscles of the lower limb



SPECIAL MYOLOGY

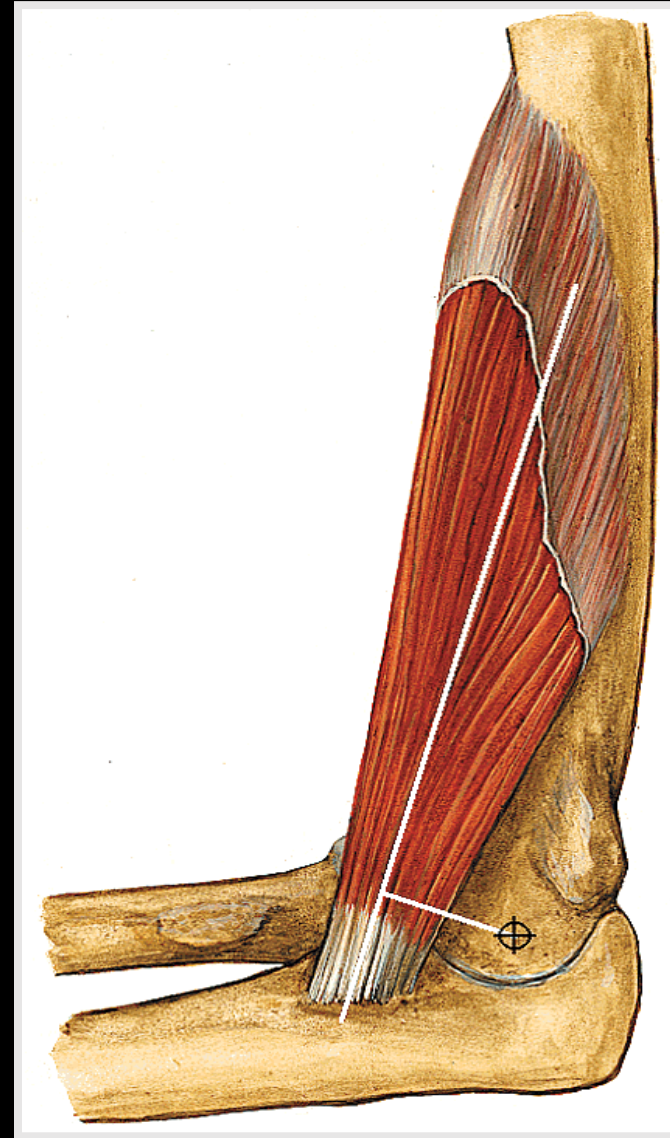
Description of the muscle:

Origo - origin

Insertio - insertion

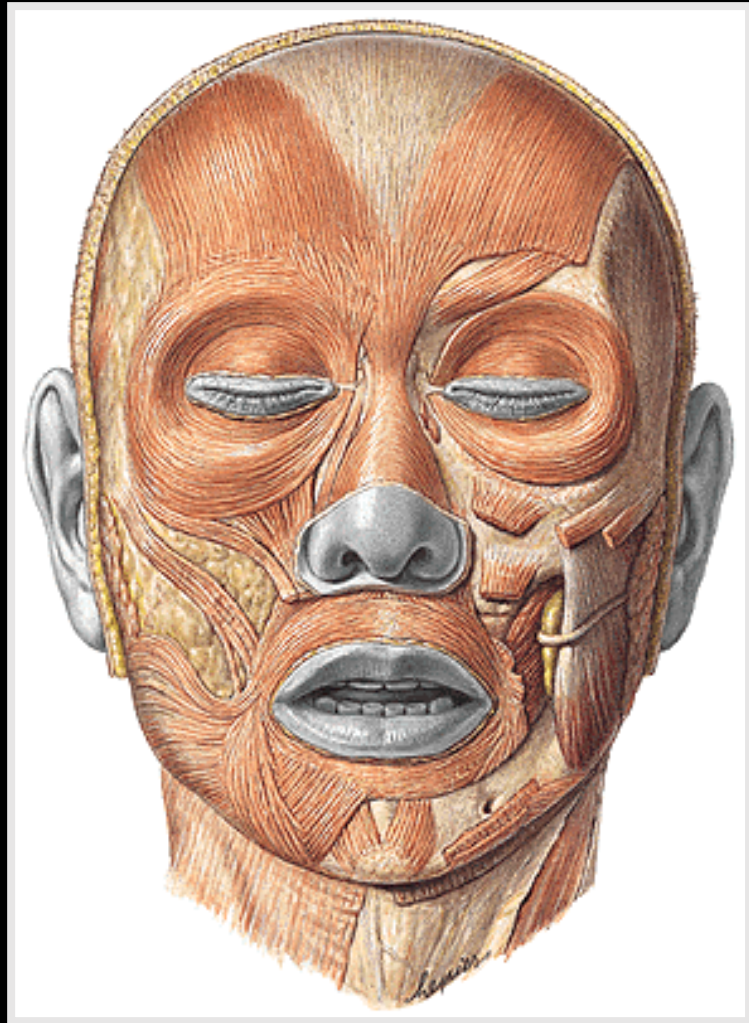
Functio – function/action

Inervatio - innervation



SPECIAL MYOLOGY

Mm. capitis (Muscles of the head)



1) MUSCULI MASTICATORII

(MASTICATORY MUSCLES)

Innervation - n. trigeminus = V. cranial nerve

2) MUSCULI FACIALES

(MUSCLES of FACIAL EXPRESION)

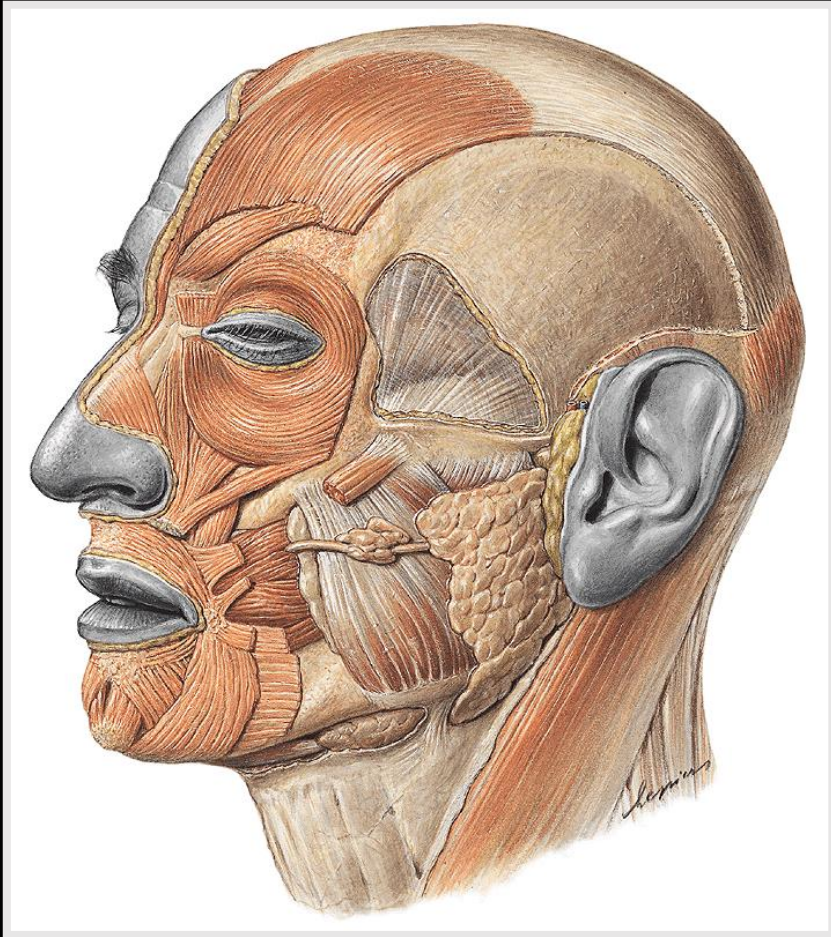
Innervation - n. facialis = VII. cranial nerve

NO FASCIA!

Musculi masticatorii

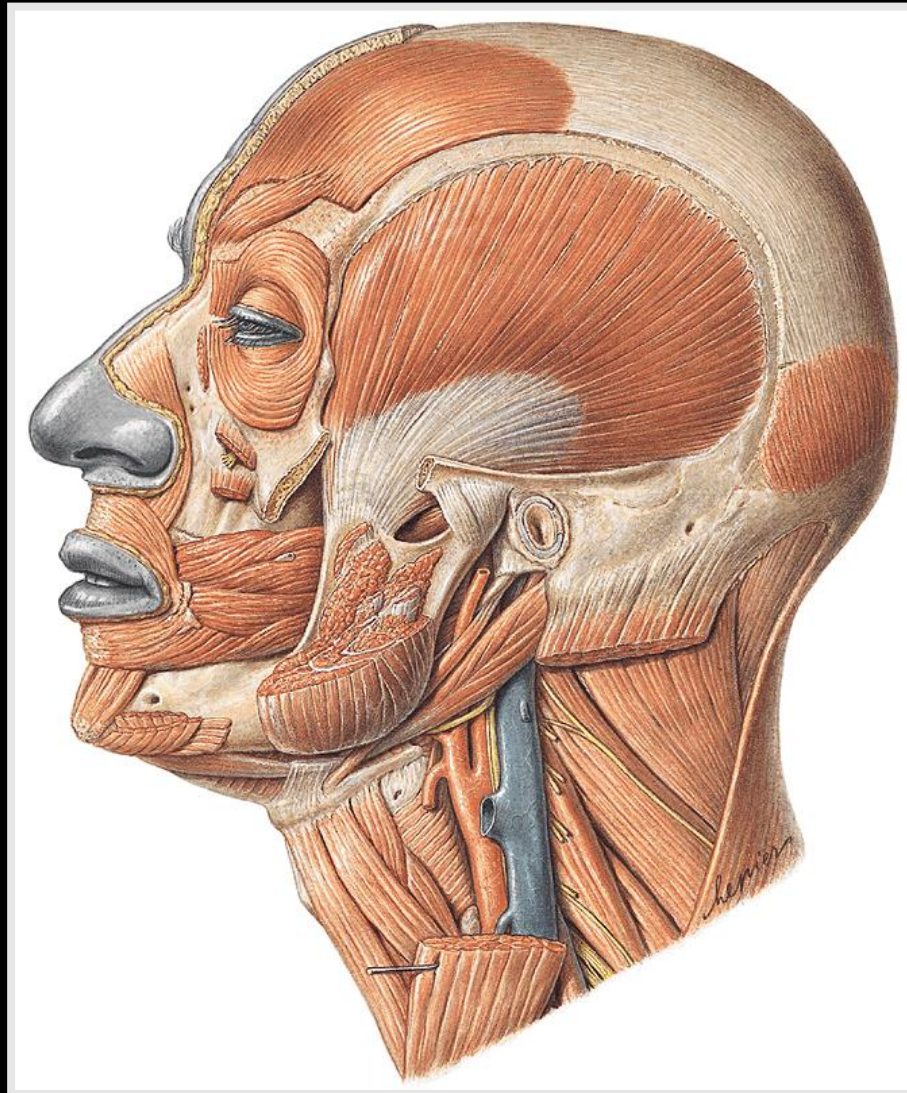
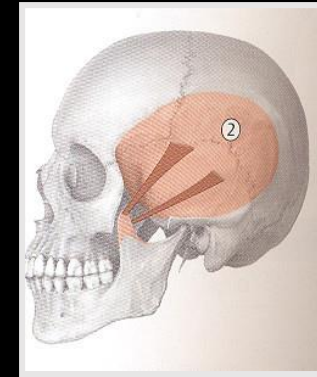
(innervation by n. trigeminus = V. cranial nerve)

(origin from the 1st branchial arch)



1. M. temporalis (temporal muscle)
2. M. masseter (masseter muscle)
3. M. pterygoideus medialis (medial pterygoid muscle)
4. M. pterygoideus lateralis (lateral pterygoid muscle)

Musculus temporalis (temporal muscle)



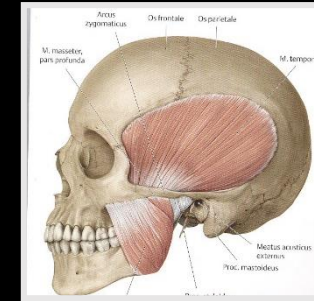
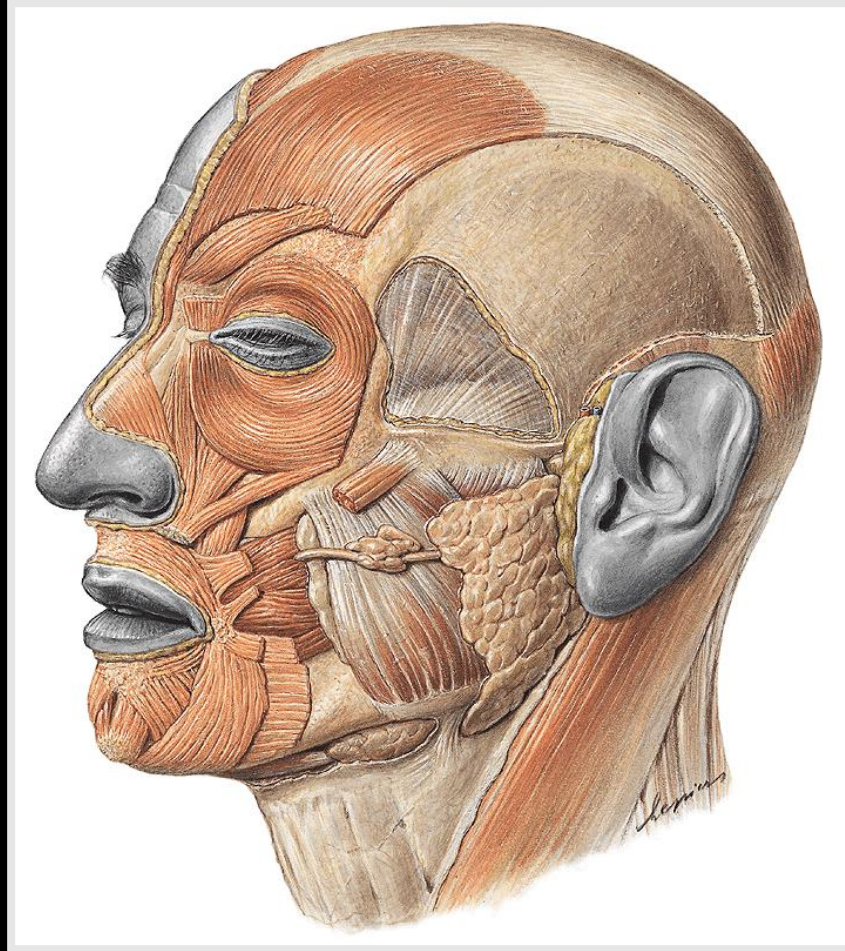
Origin: linea temporalis inferior,
fascia temporalis

Insertion: processus coronoideus of
mandible

function: elevation of mandible
(retraction)

Innervation: trigeminal nerve (n. V.)

Musculus masseter (masseter muscle)



Origin: corpus ossis zygomatici, arcus zygomaticus

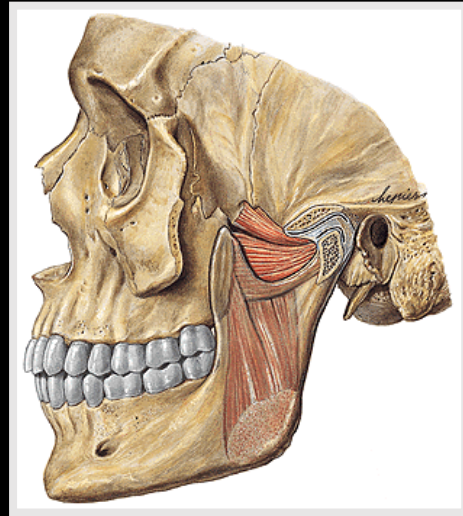
Insertion: tuberositas masseterica (angulus mandibulae)

Function: elevation and protraction of mandible

Innervation: trigeminal nerve (n. V.)

Musculus pterygoideus medialis

(medial pterygoid muscle)

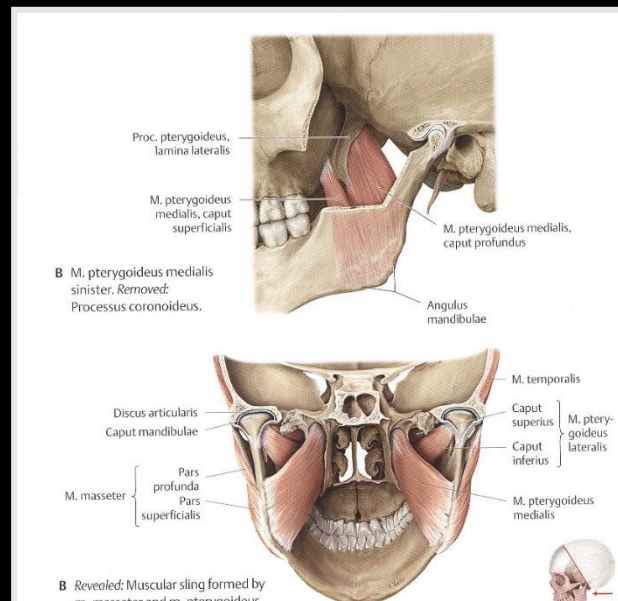


origin: fossa pterygoidea and tuber maxillae

insertion: tuberositas pterygoidea of mandible

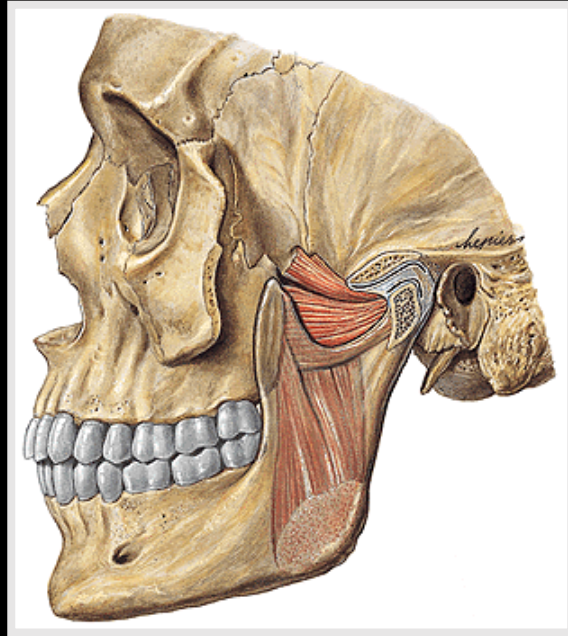
function: elevation of mandible and movements to the sides

innervation: trigeminal nerve (n.V.)



Musculus pterygoideus lateralis

(lateral pterygoid muscle)

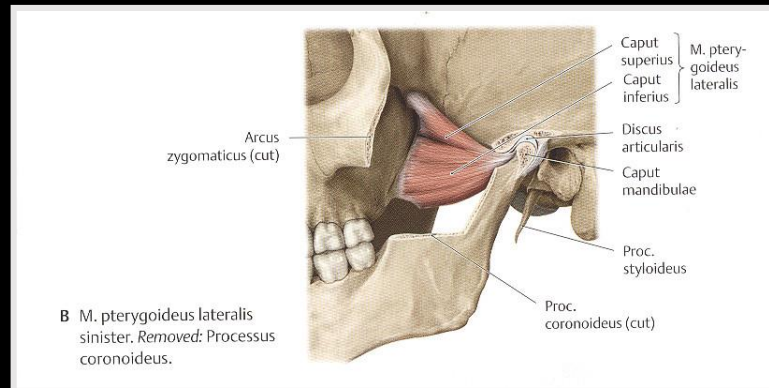


origin: facies infratemporalis alae majoris ossis sphenoidalis and lamina lateralis processus pterygoidei

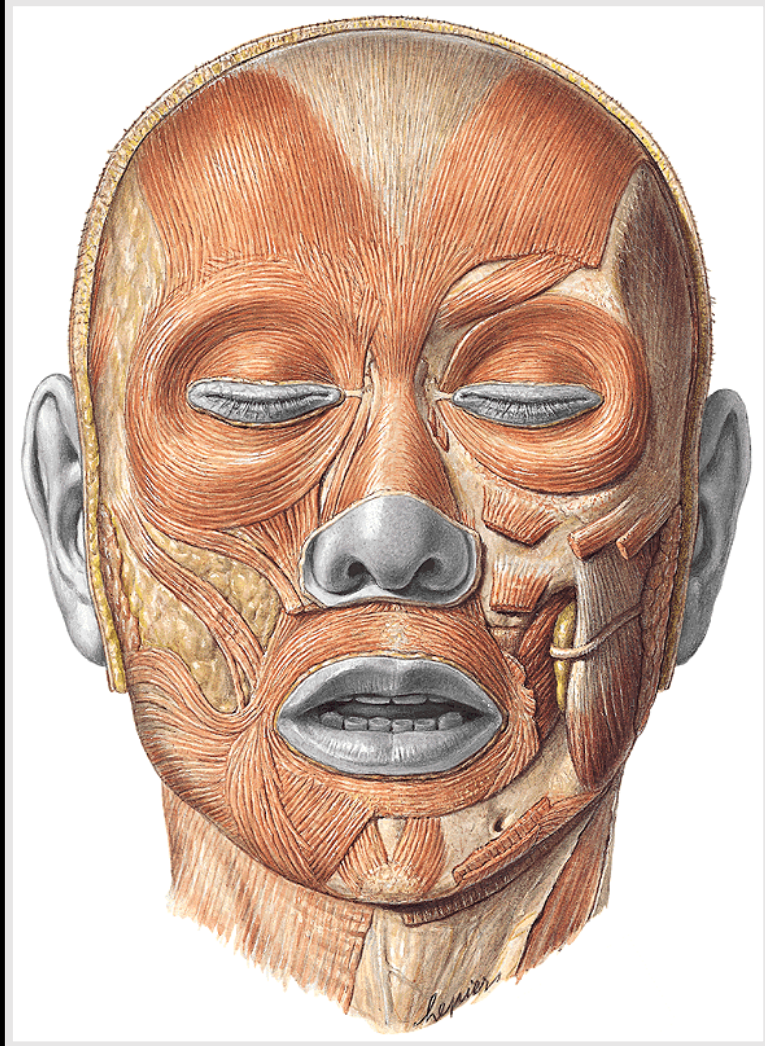
insertion: fovea pterygoidea +(discus and articular capsule of temporomandibular joint)

function: protraction of mandible, chewing movements

innervation: trigeminal nerve (n.V.)



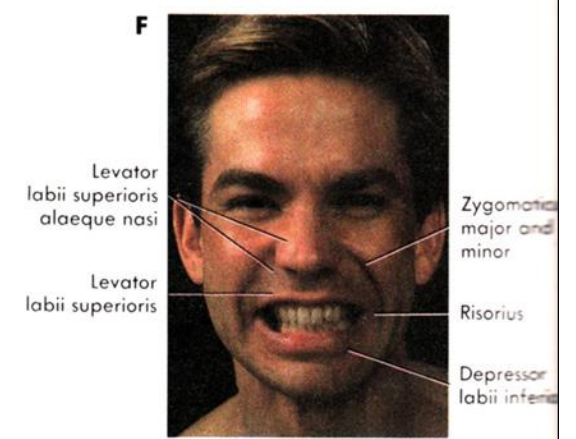
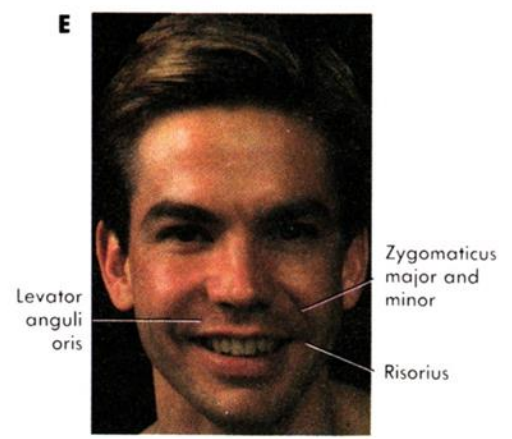
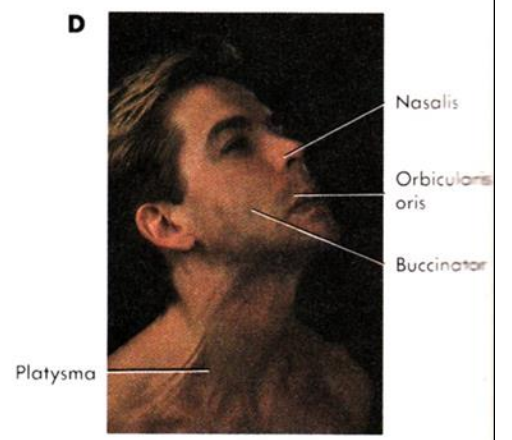
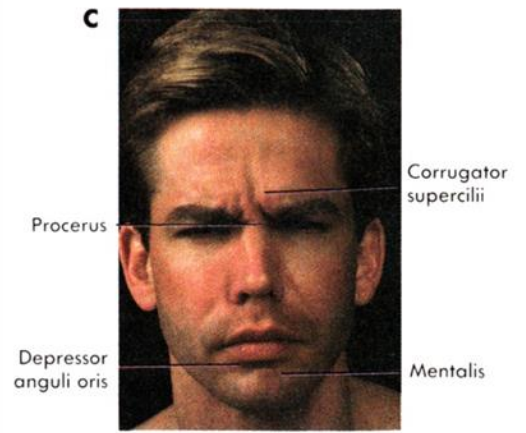
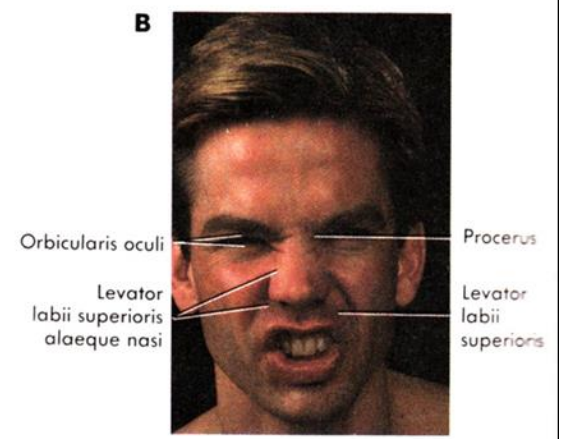
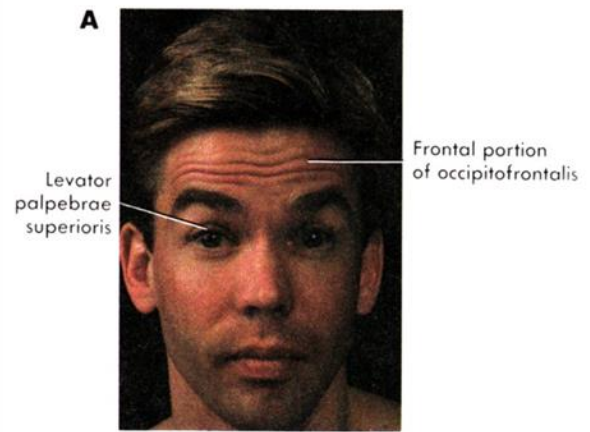
Mm. faciales (mimic muscles) (facial nerve – n.VII.)
(origin from the 2nd branchial arch)



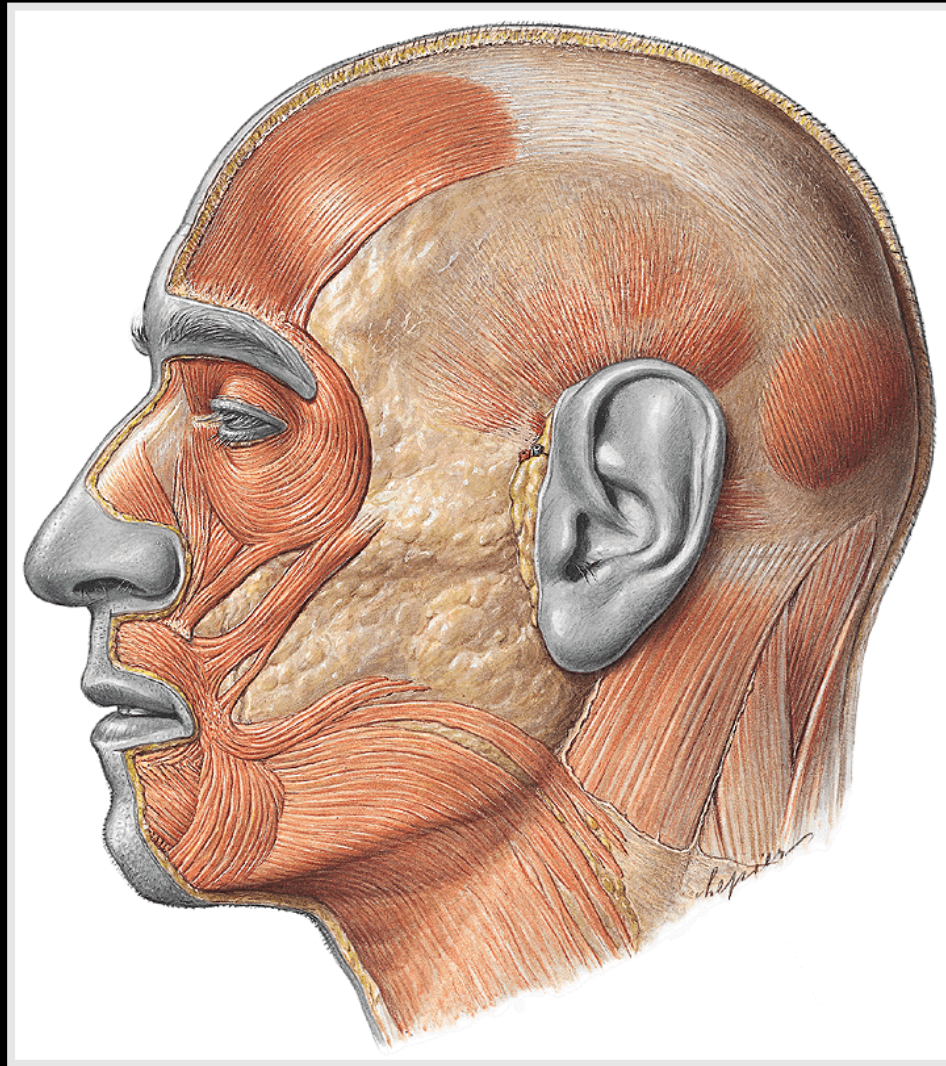
Muscles of the scalp
Muscles of the orbit region
Muscles of the nasal region
Muscles of the mouth region

Their contraction causes shift of the skin (folds or wrinkles) – it is the basis of **facial expression**.

They have **no fascias!**



Muscles of the scalp



M. epicranii

M. occipitofrontalis with frontal and occipital bellies (venter)

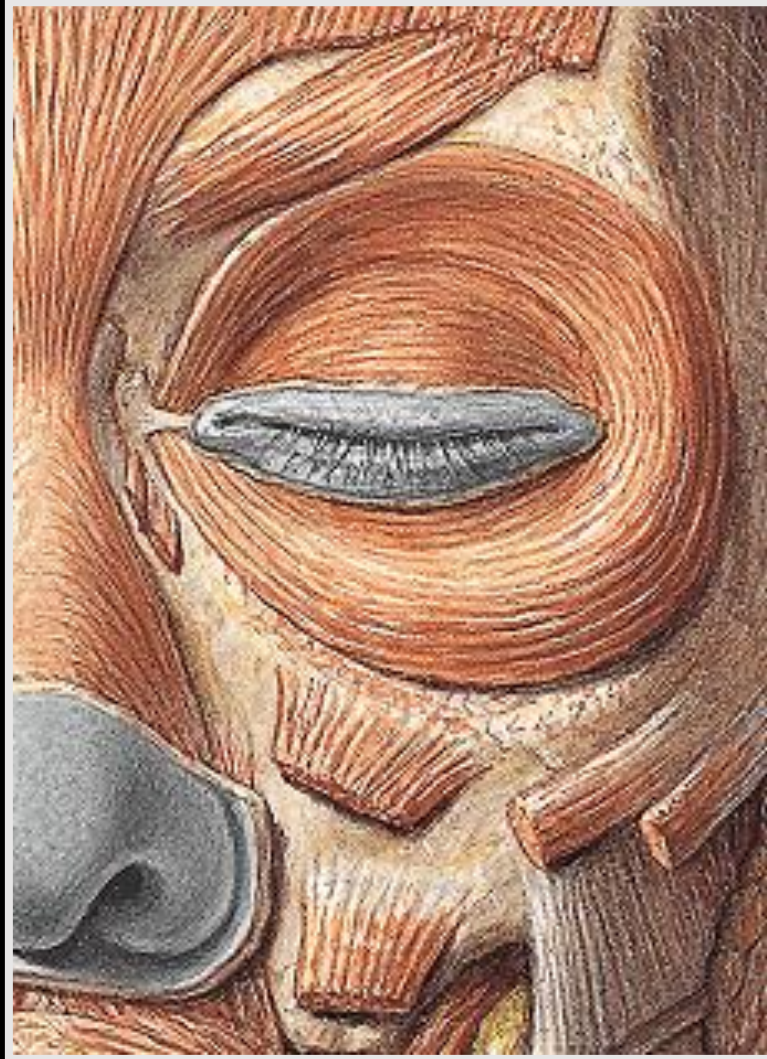
o: venter occipitalis from highest nuchal line (*linea nuchae suprema*) to the galea aponeurotica and frontal belly from here to the skin of eyebrow and glabellar region

f: wrinkles in the forehead, lift the eyebrow (**astonishment**)

M. temporoparietalis

Rudimentary muscle, from galea aponeurotica to auricular cartilage

Muscles of the orbital region



M. orbicularis oculi

Palpebral part, orbital part, lacrimal part

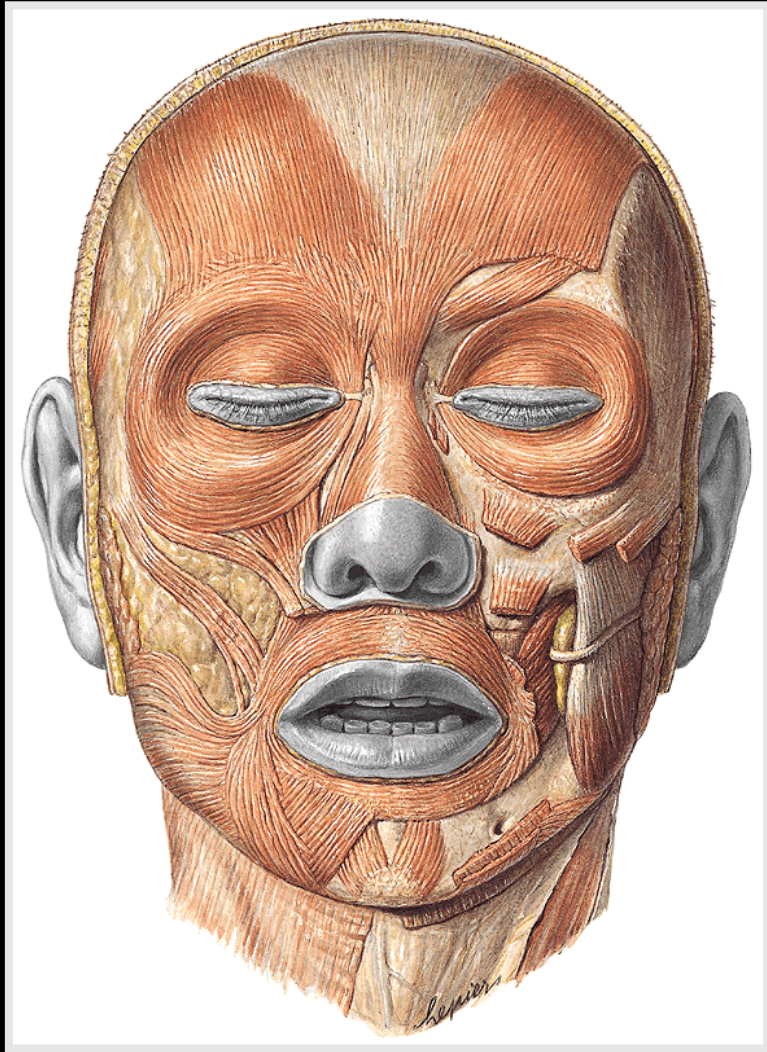
Firmly closure the eyelid, palpebral part concerned with blink reflex, radial folds in lateral angle (expression of **worry and concern**)

M. corrugator supercilii

Produces a vertical wrinkles
Expression of **attention**

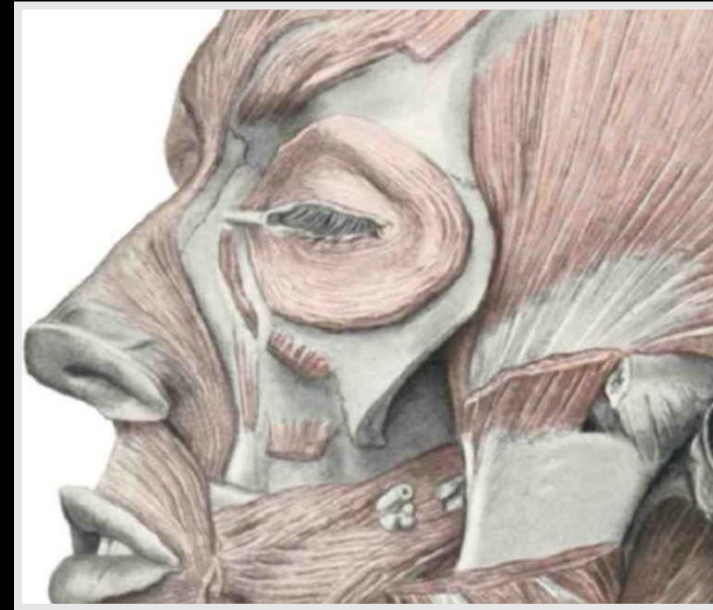M. procerus

Transverse folds across the root of nose

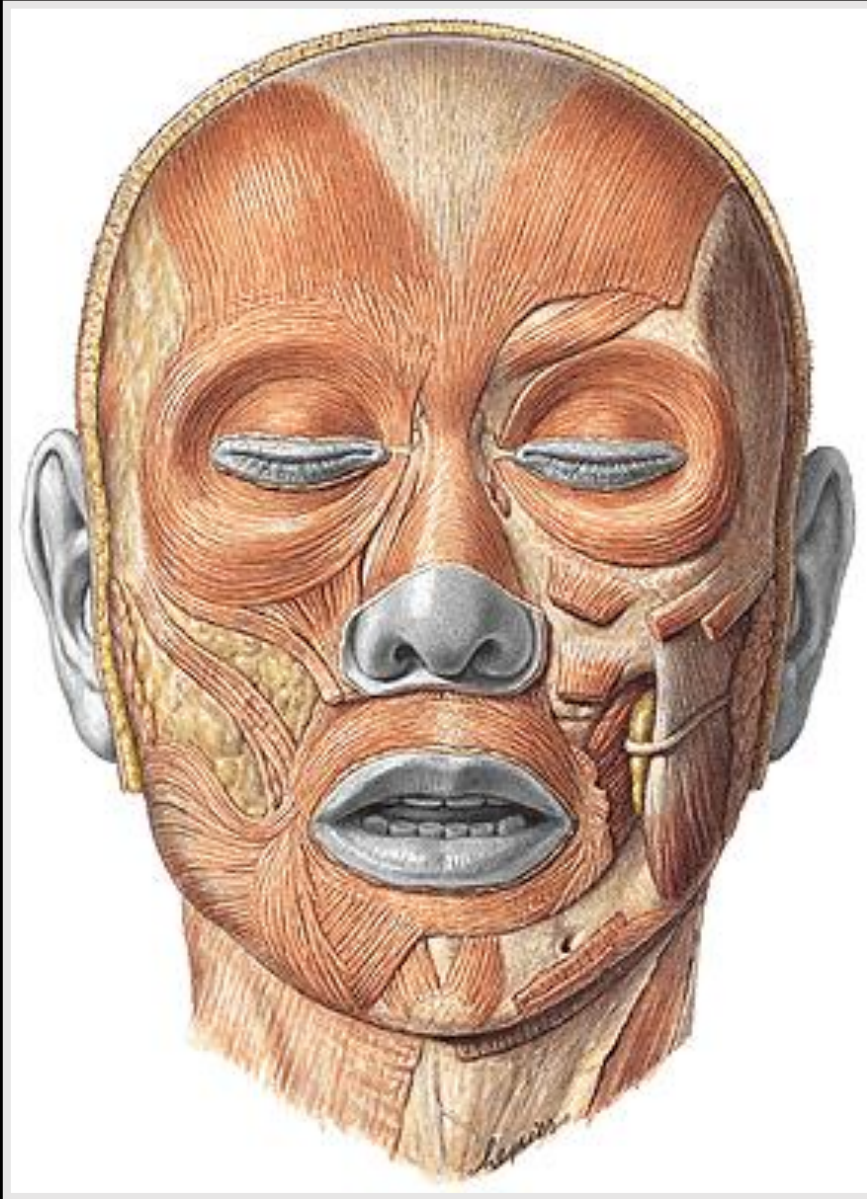


M. nasalis

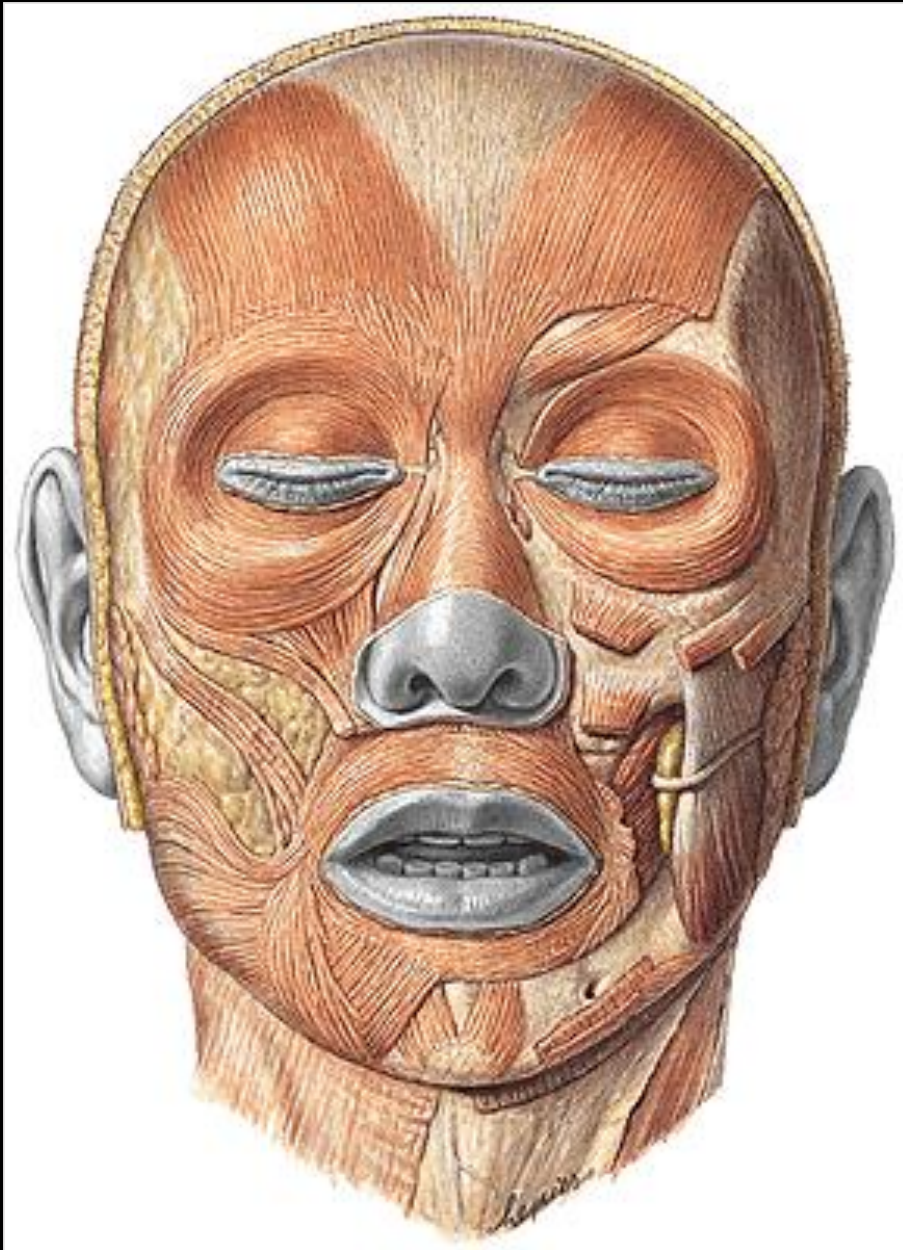
Pulls the nasal wings (nostrils) downward and backward and reduce size of nostrils. Gives impression of **desire, pleasure.**



Muscles of the mouth region



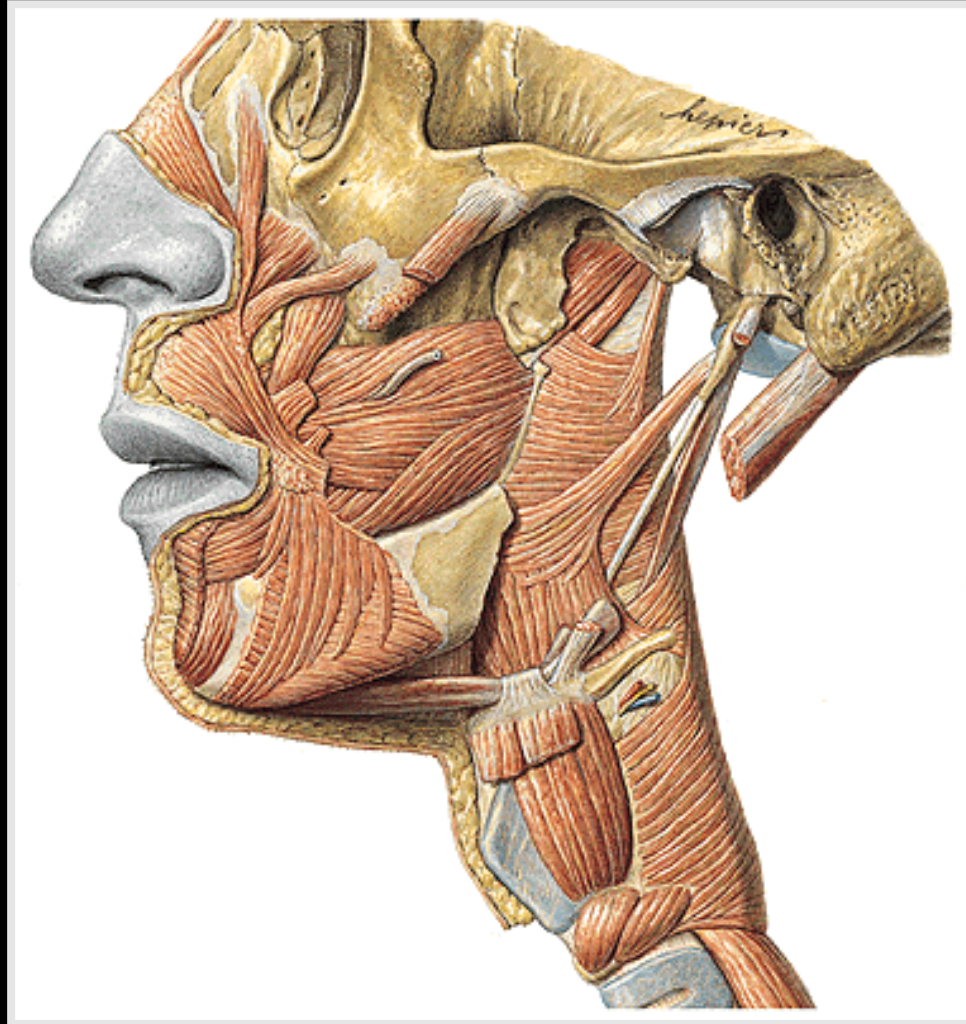
- M. orbicularis oris
- M. buccinator
- M. zygomaticus major
- M. zygomaticus minor
- M. levator labii superioris
- M. levator anguli oris
- M. risorius
- M. levator labii superioris alaeque nasi
- M. depressor anguli oris
- M. depressor labii inferioris
- M. mentalis



M. orbicularis oris

Labial and marginal parts

Closes lips, protrudes in the sucking, function during eating and drinking, speaking, purse lips.

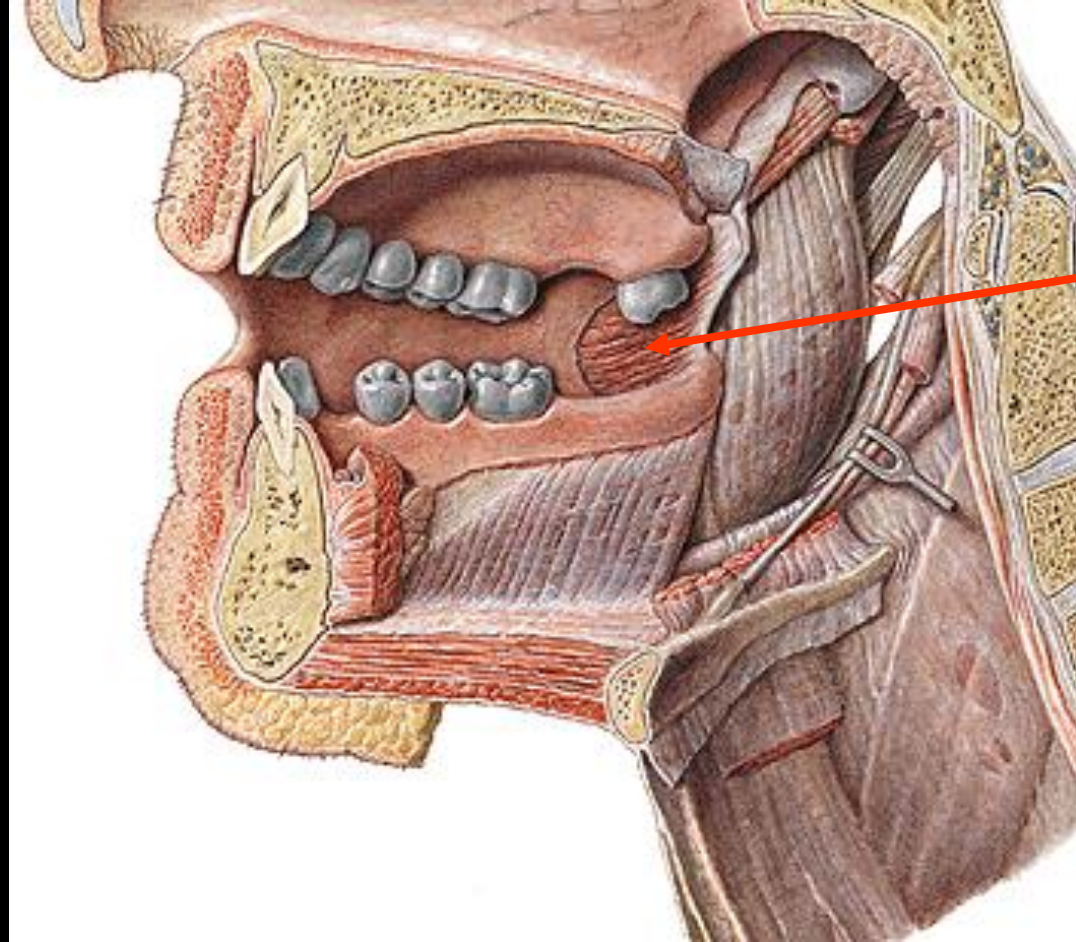


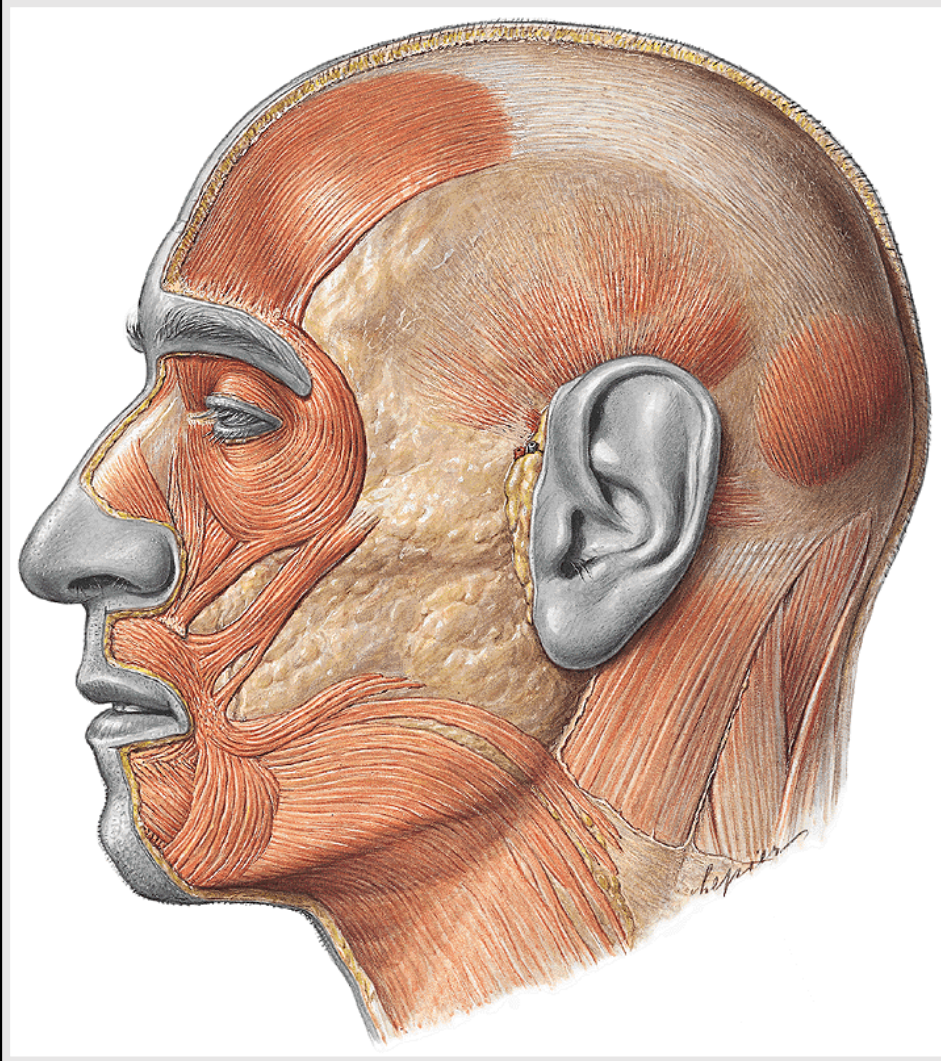
M. buccinator

Facial compression to processus alveolares, blows air out of mouth (trumpeter), pulls the angle of mouth laterally and keeps away the mucous membrane of the cheeks from the teeth

Expression of **satisfaction**

Ductus parotideus





M. zygomaticus major

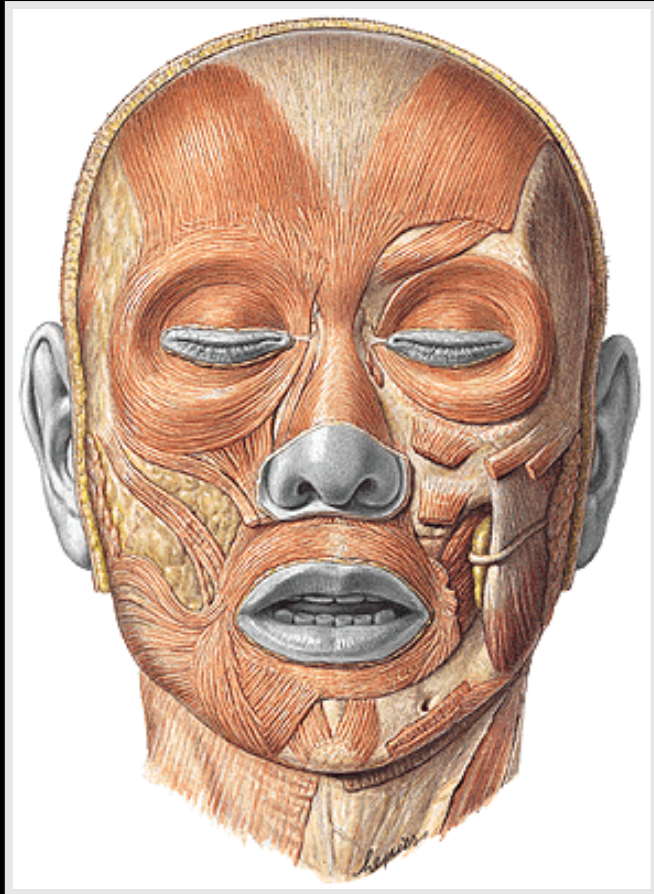
F: lifts angle of the mouth upward and laterally

Facial expression of **laugh** or **pleasure**

M. zygomaticus minor

M. risorius

„laughing muscle“

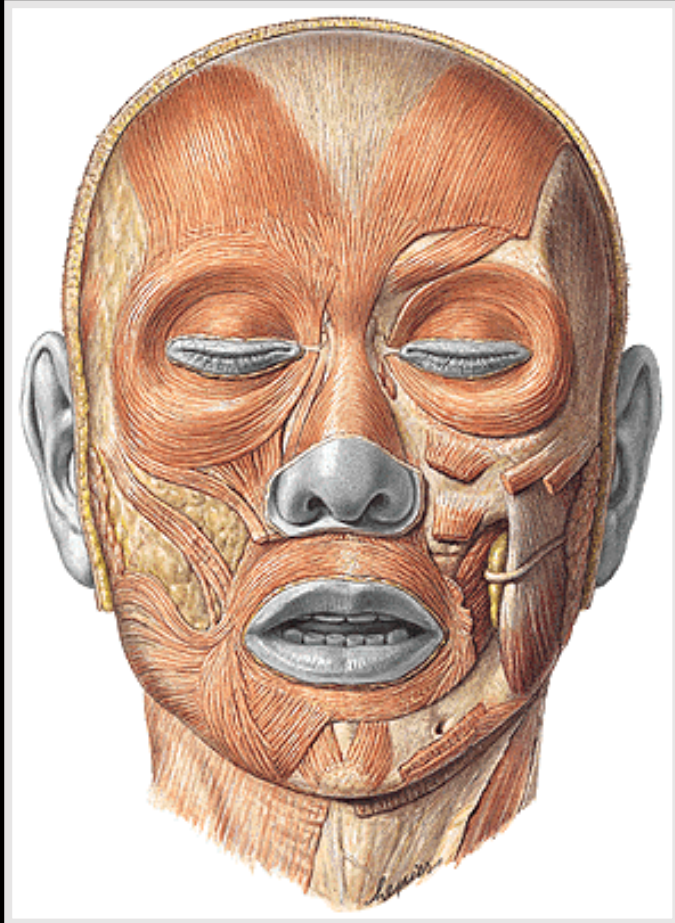


M. levator labii superioris

M. levator labii superioris alaeque nasi

M. levator anguli oris

Expression of **self-confidence**



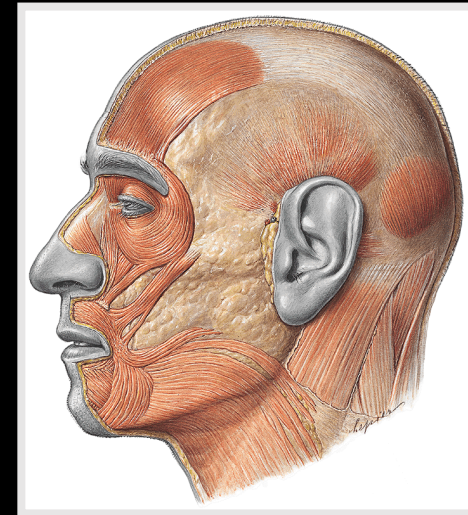
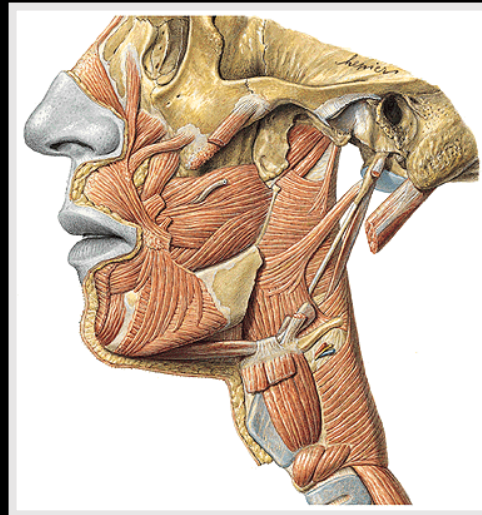
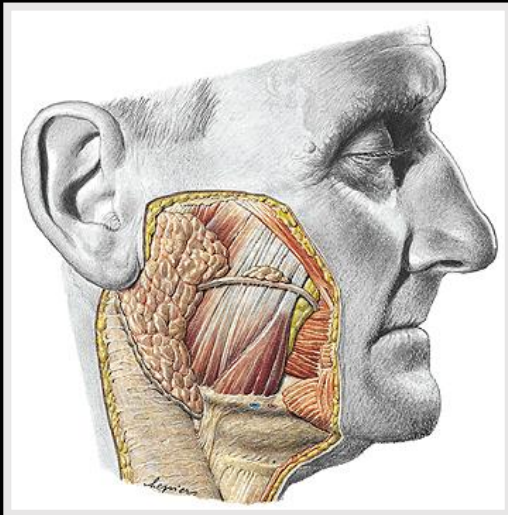
M. depressor anguli oris
Expression of sadness

M. depressor labii inferioris
Expression of perseverance

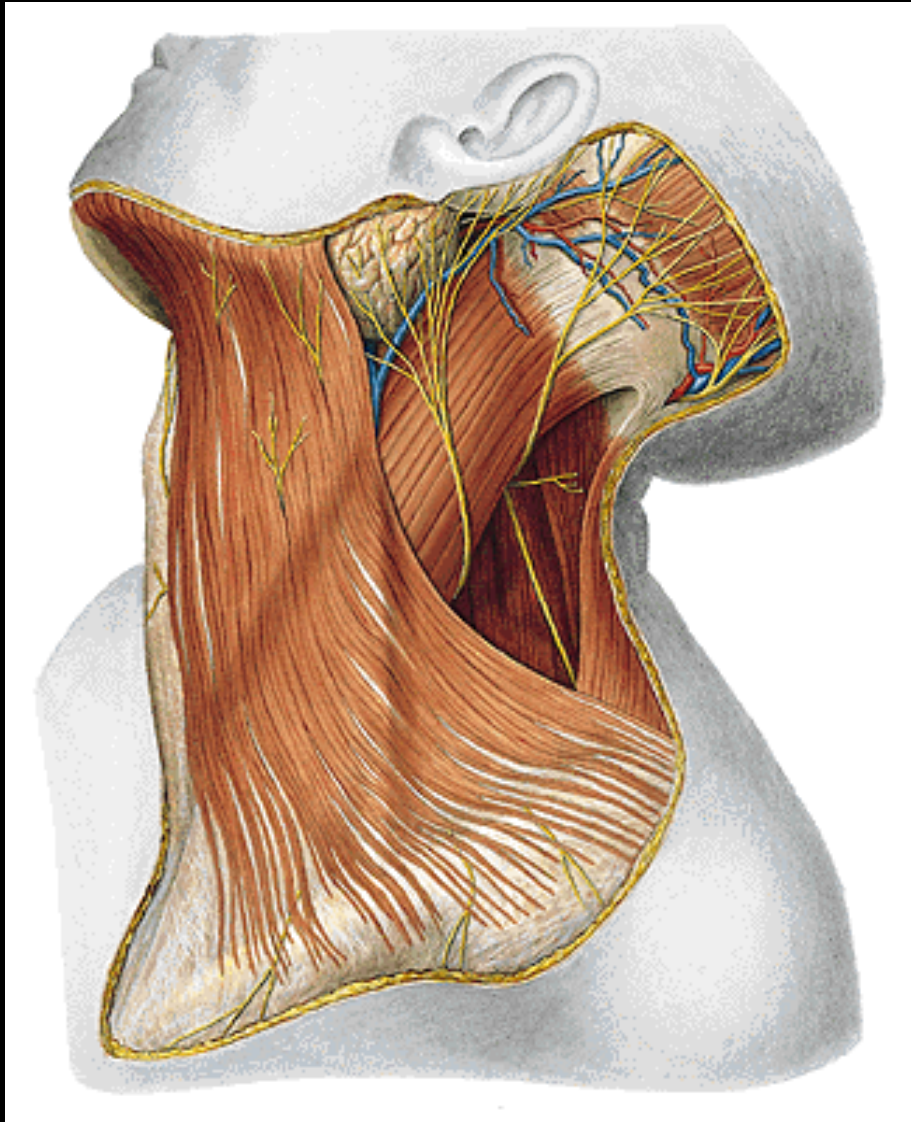
M. mentalis
Expression of scorn

Fasciae of the head

1. **Fascia temporalis** – superior temporal line to the arcus zygomaticus – superficial and deep layer
2. **Fascia masseterica** (fascia parotideomasseterica)
3. **Fascia buccopharyngea**



Muscles of the neck (mm. colli)



Superficial layer

m. platysma

m. sternocleidomastoideus

mm. suprahyoidei

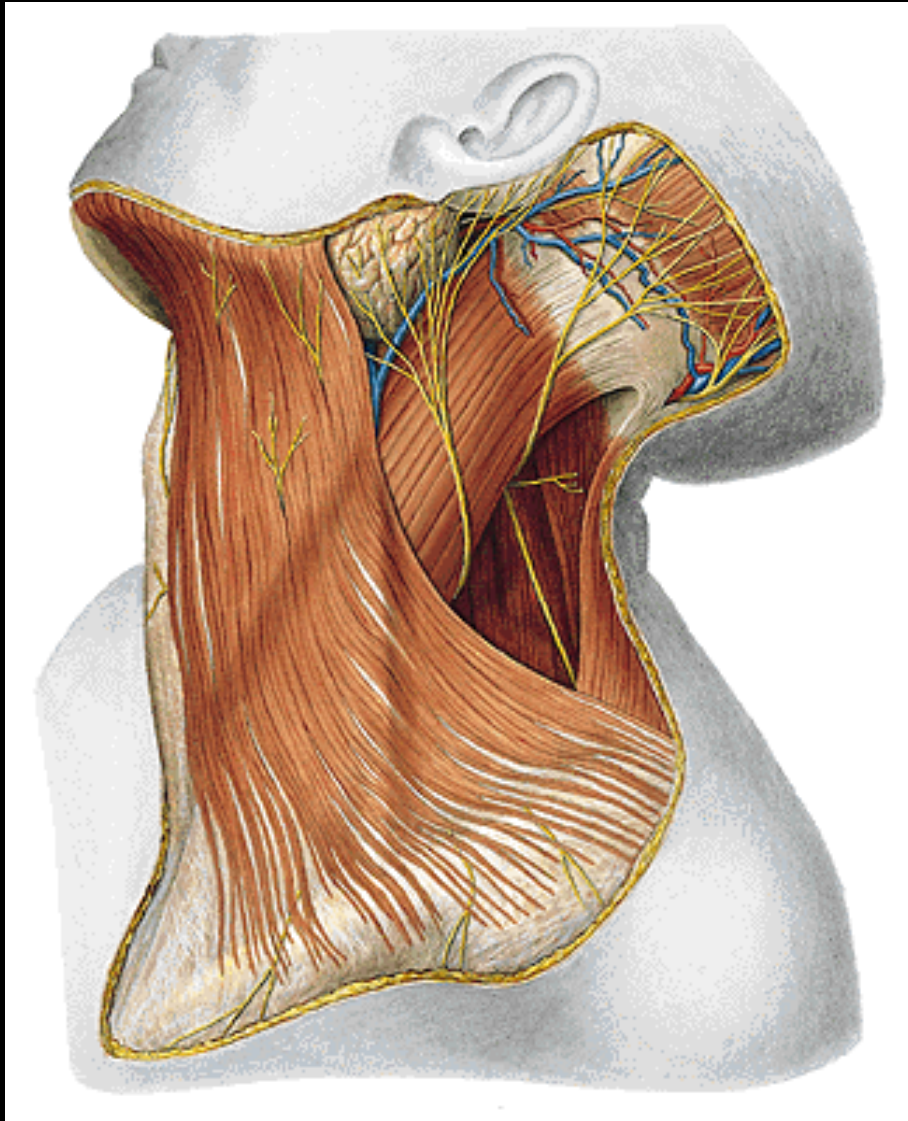
mm. infrahyoidei

mm. scaleni

Deep layer

mm. praevertebrales

Muscles of the neck (mm. colli)



Superficial layer

m. platysma

O: fascia thoracica

i: face and masseteric fascia

inn: facial nerve

F: moves by skin of neck

Without fascia!

m. sternocleidomastoideus

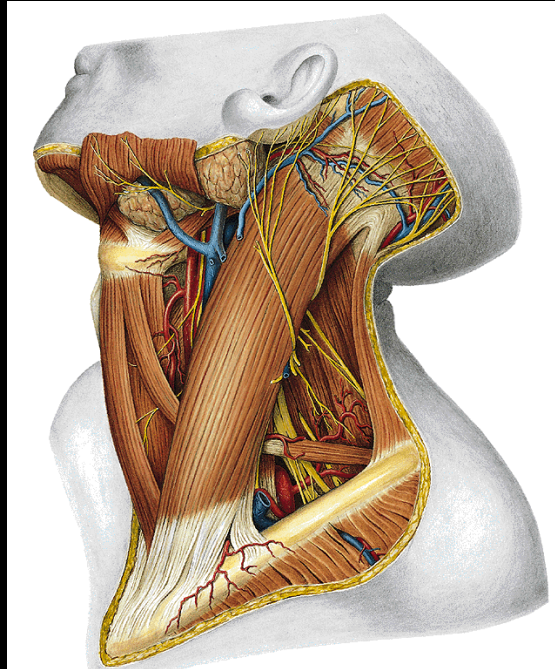
o: sternal and clavicular parts

i: processus mastoideus, superior nuchal line

inn: XI. cranial nerve, cervical plexus

f: unilateral action turns the head to the opposite side and bends, bilateral lifts head, accessory muscle of the respiration

Muscles of the neck (mm. colli)



Infrahyoid muscles

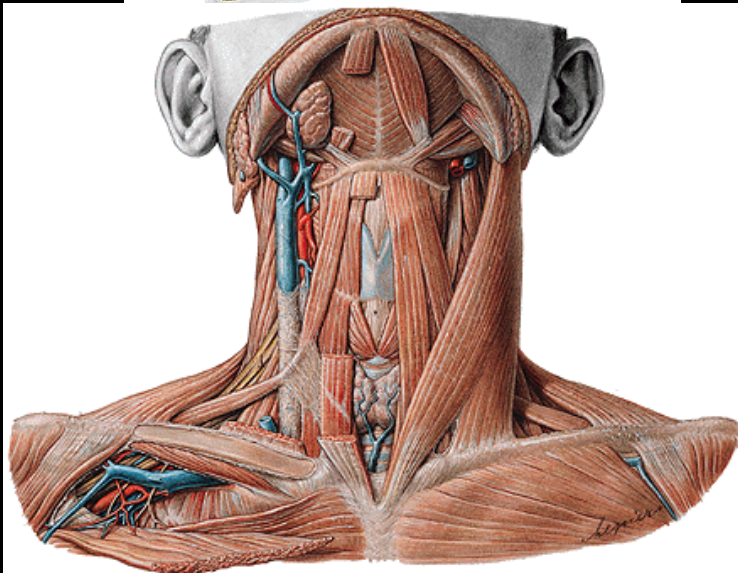
m. sternohyoideus

m. sternothyroideus

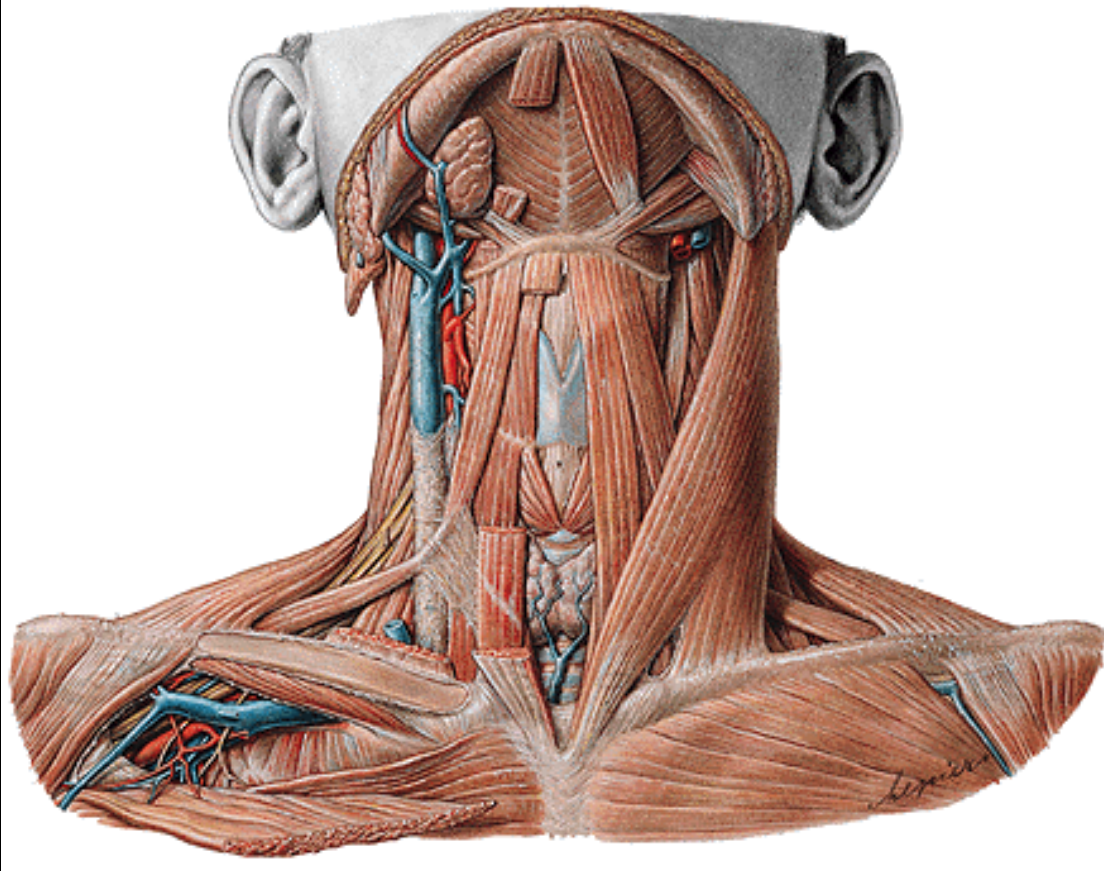
m. thyrohyoideus

m. Omohyoideus

Innervation from the ansa cervicalis profunda – cervical plexus



Muscles of the neck (mm. colli)



Suprahyoid muscles

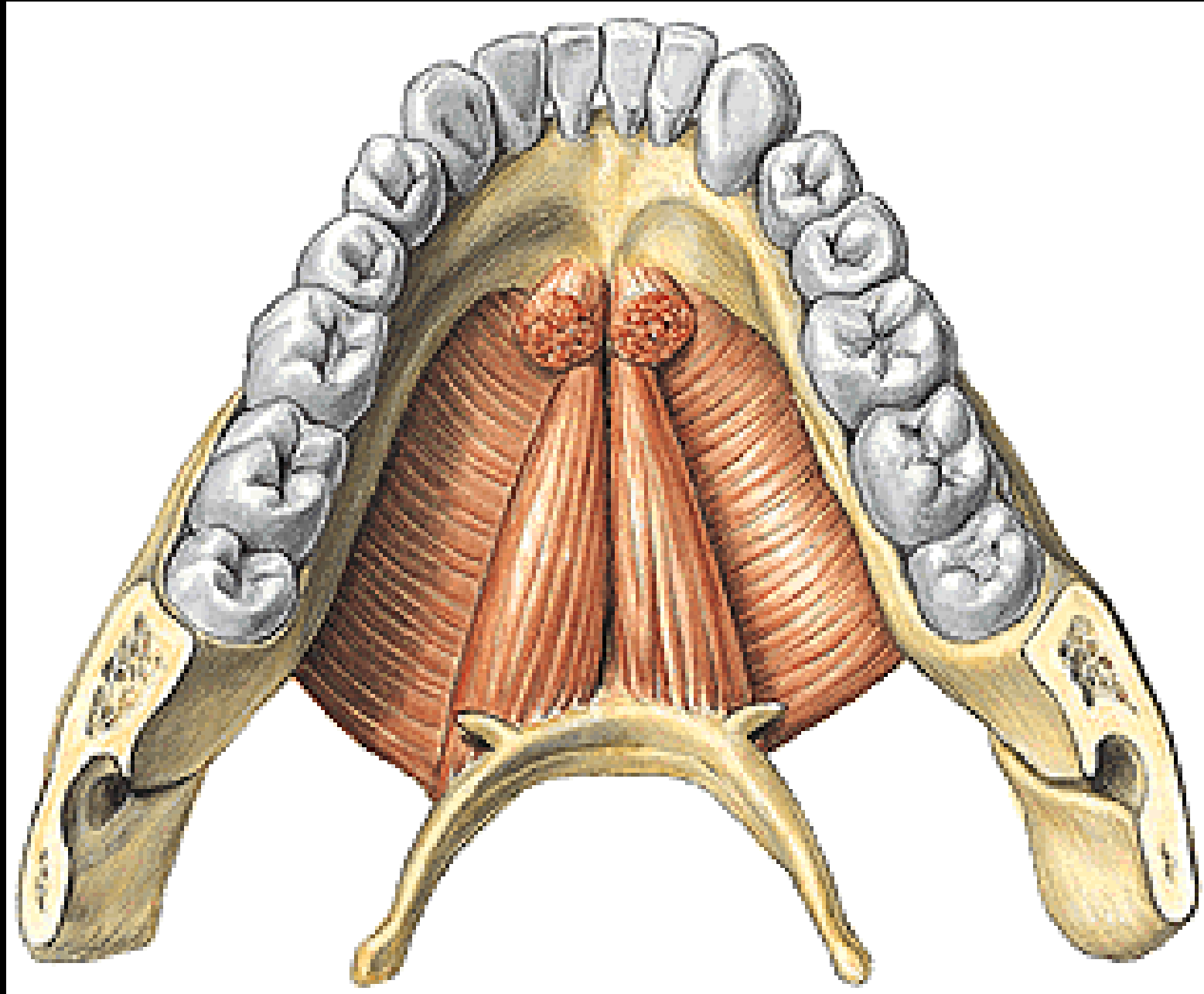
m. digastricus

m. mylohyoideus

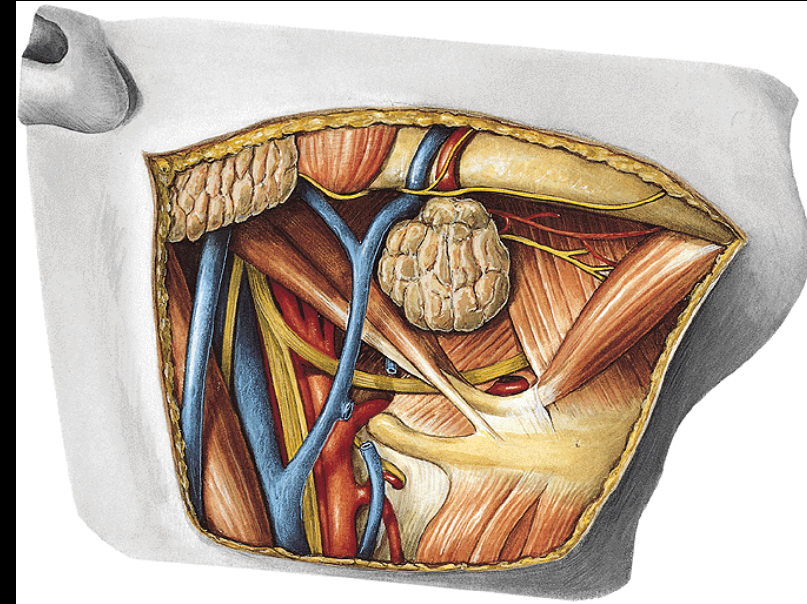
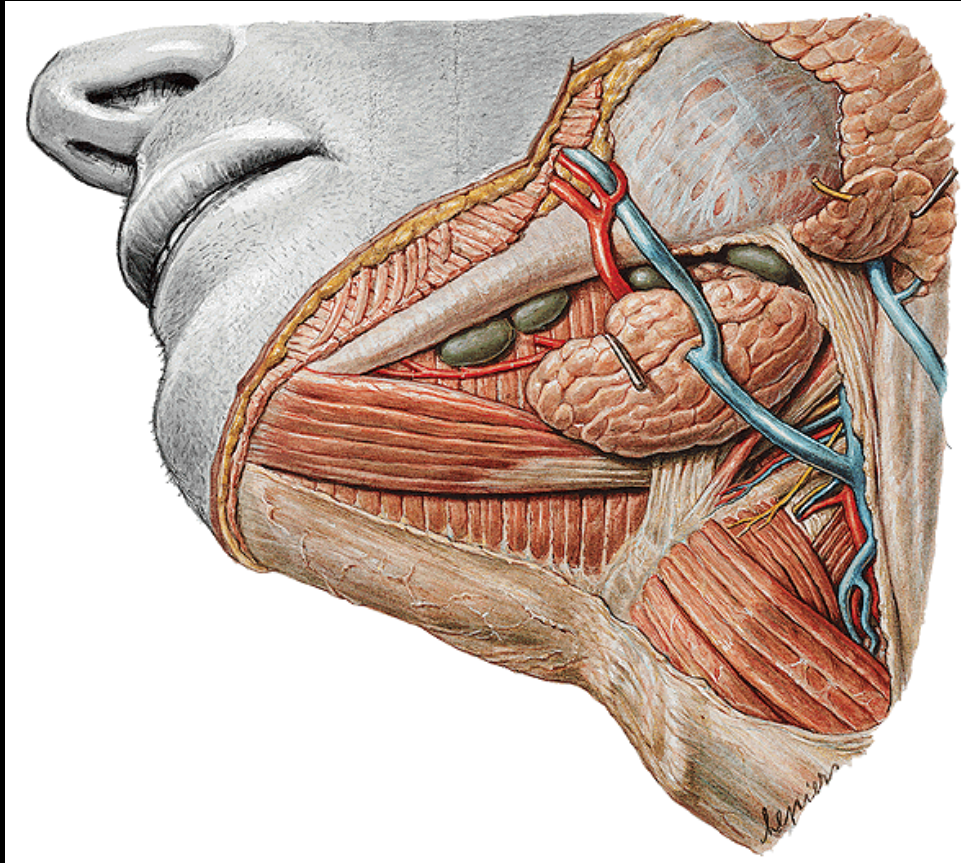
m. geniohyoideus

m. stylohyoideus

Suprahyoid muscles (m. geniohyoideus, m. mylohyoideus)

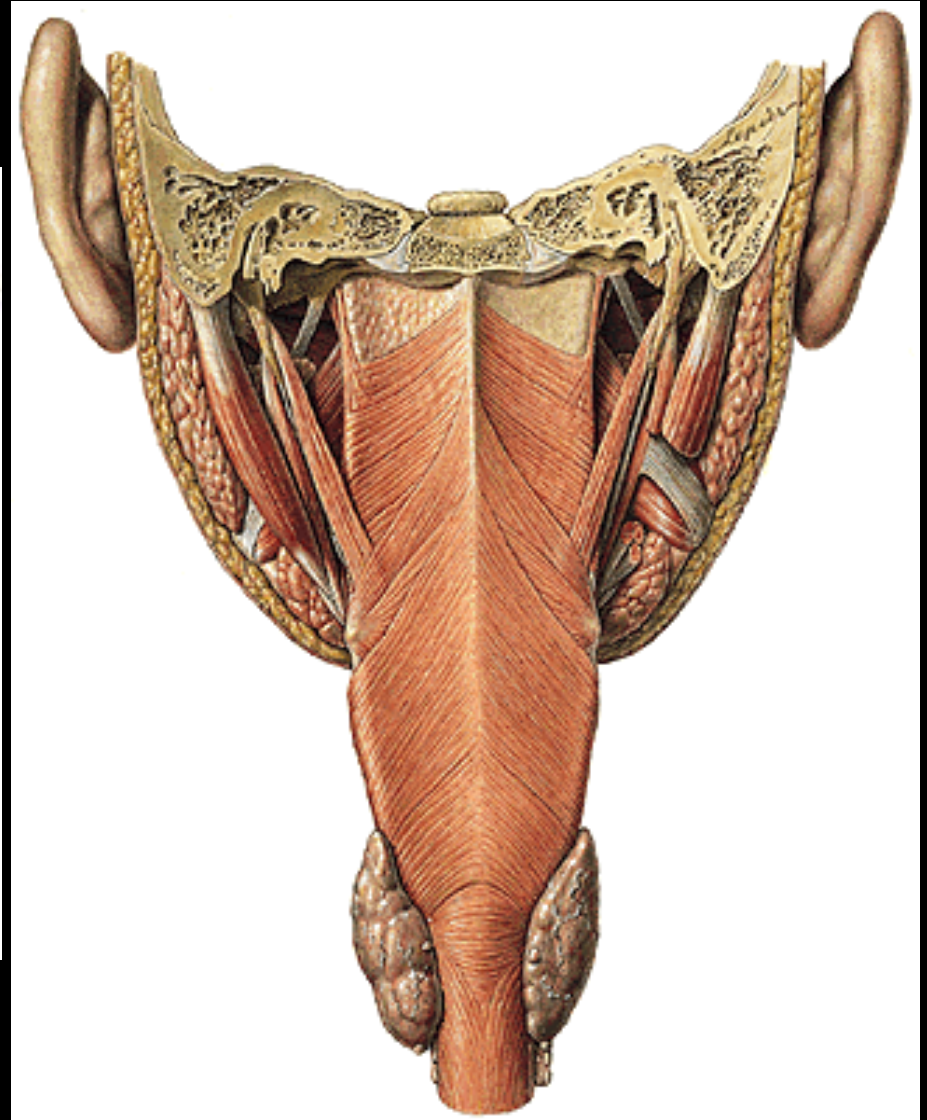
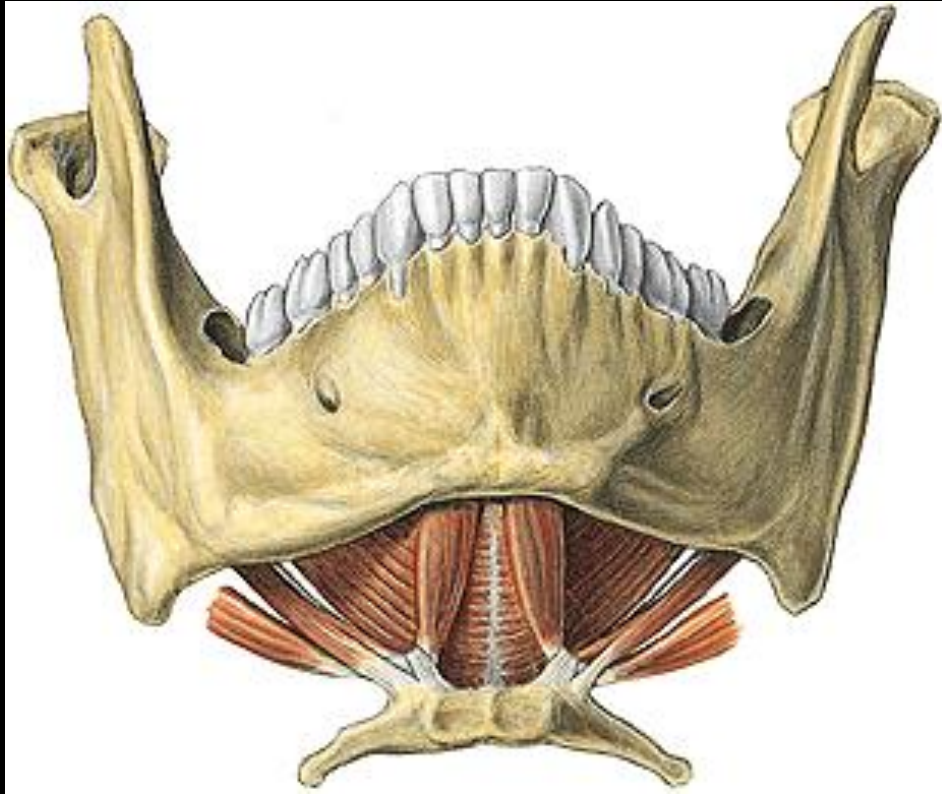


Suprahyoid muscles

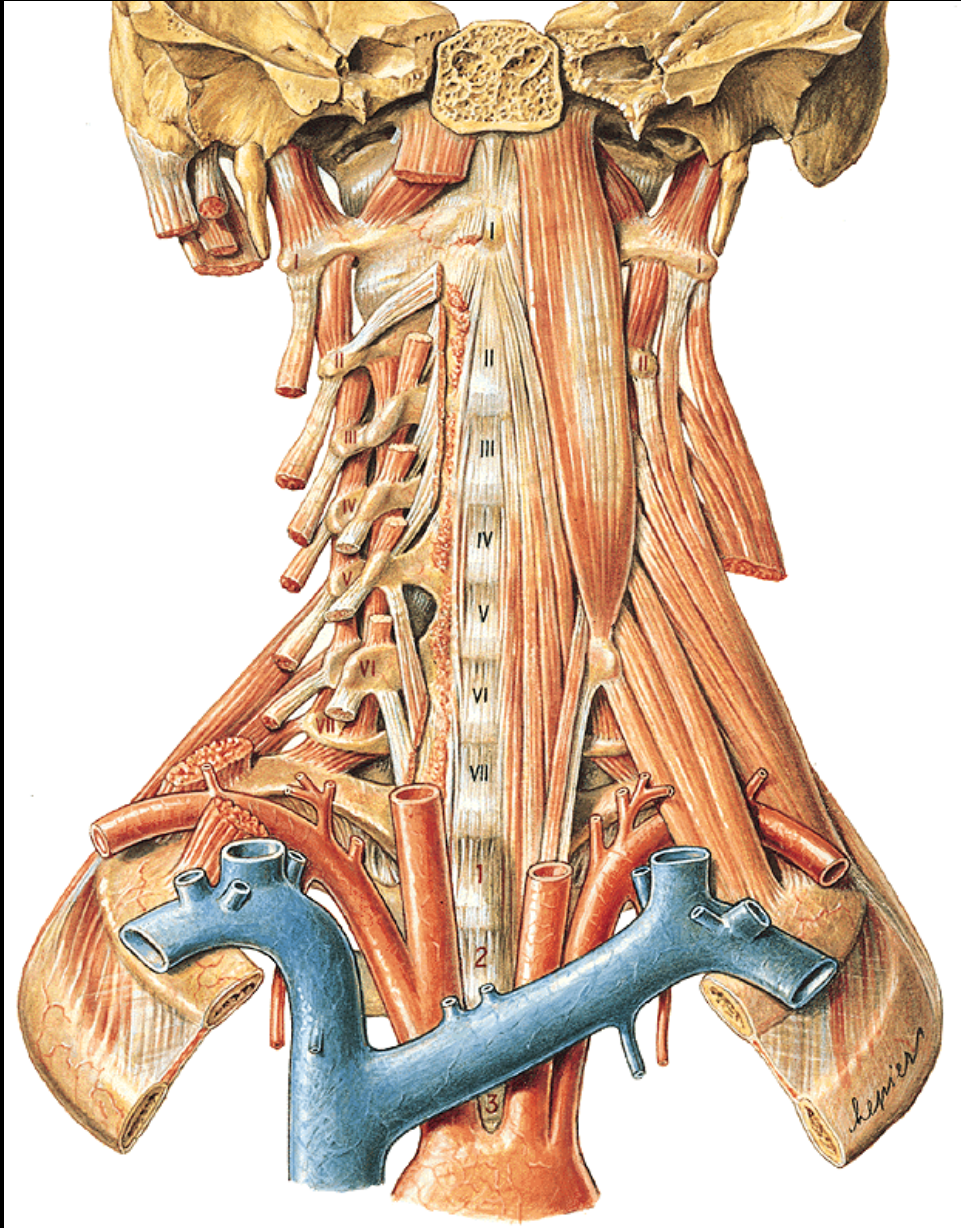


m. digastricus
m. stylohyoideus

Suprahyoid muscles



Muscles of the neck



Mm.scaleni:

m. scalenus anterior from tbc.ant.3-6C to the 1st rib

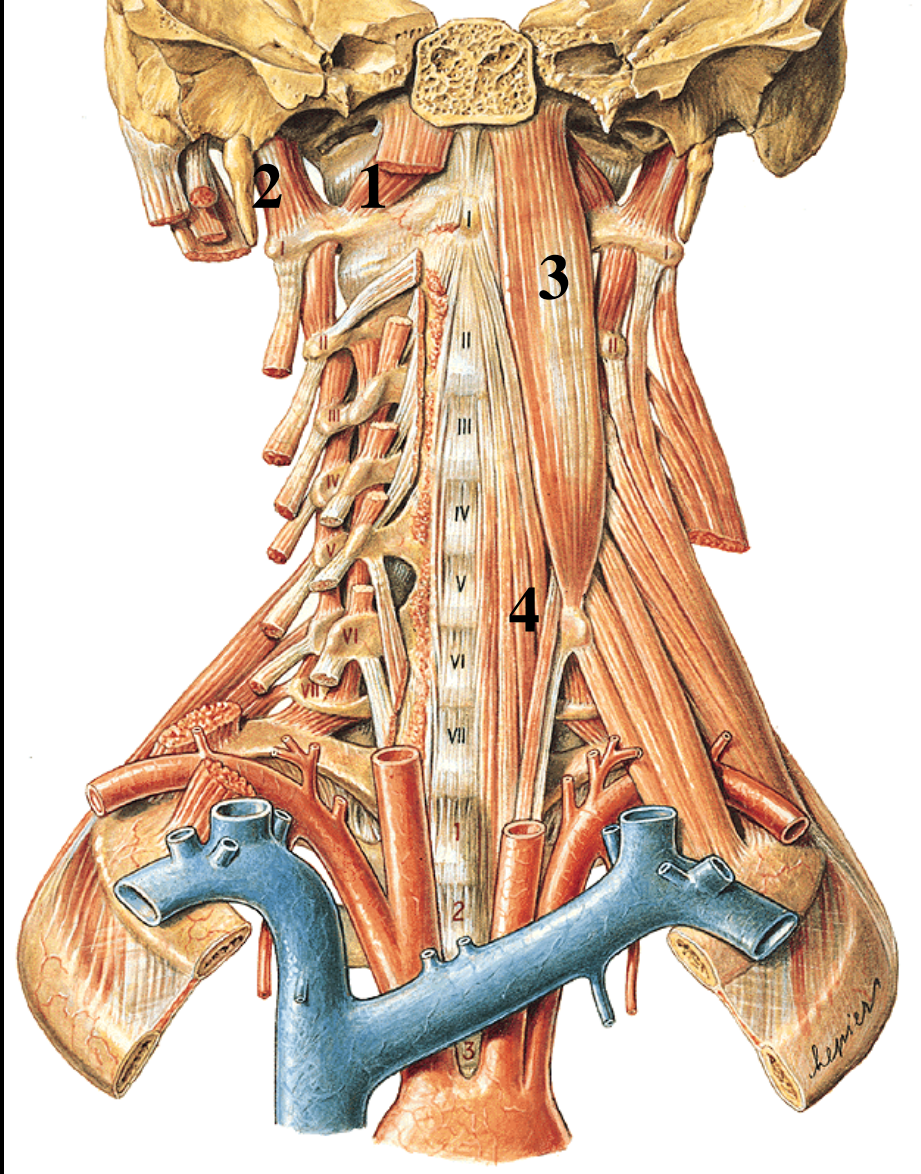
m. scalenus medius from tbc.ant.2-7C to the 1st rib

m. scalenus posterior from tbc.post.5-6C to 2nd rib

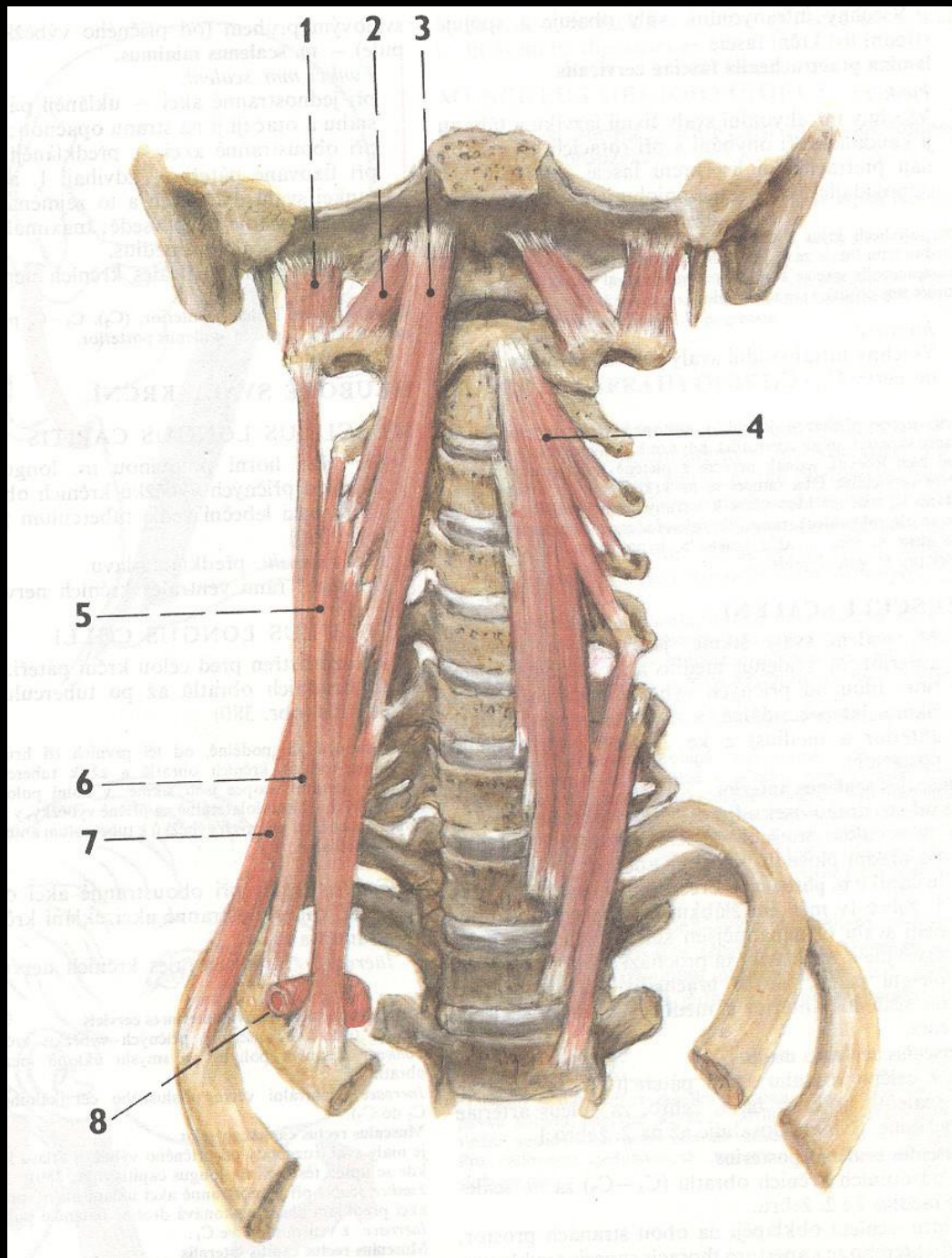
Fissura scalenorum:

course of a.subclavia and plexus brachialis

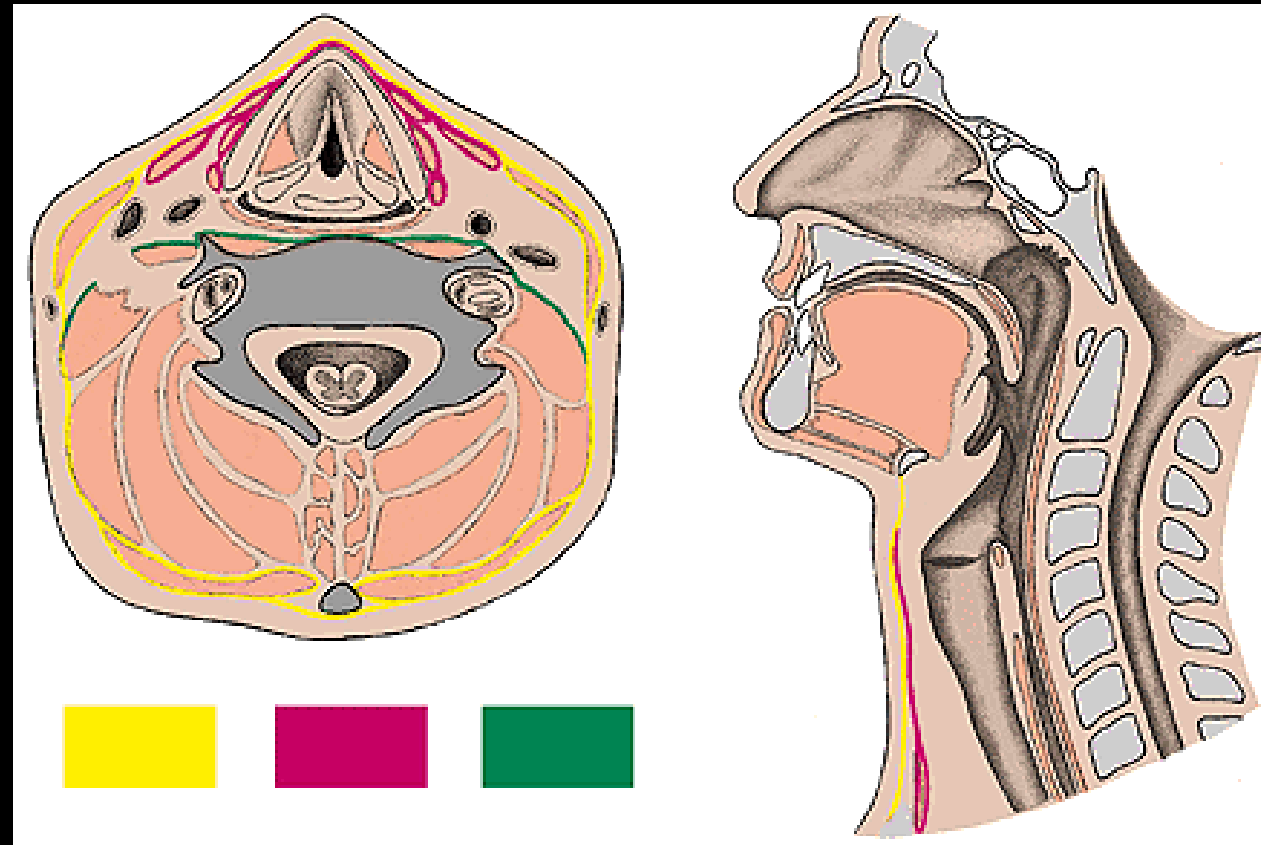
Muscles of the neck (mm. colli) deep layer



1. rectus capitis anterior
2. rectus capitis lateralis
3. longus capitis
4. longus colli
5. mm. intertransversarii anteriores cervicis



Fasciae of the neck



Fascia colli:

Lamina superficialis

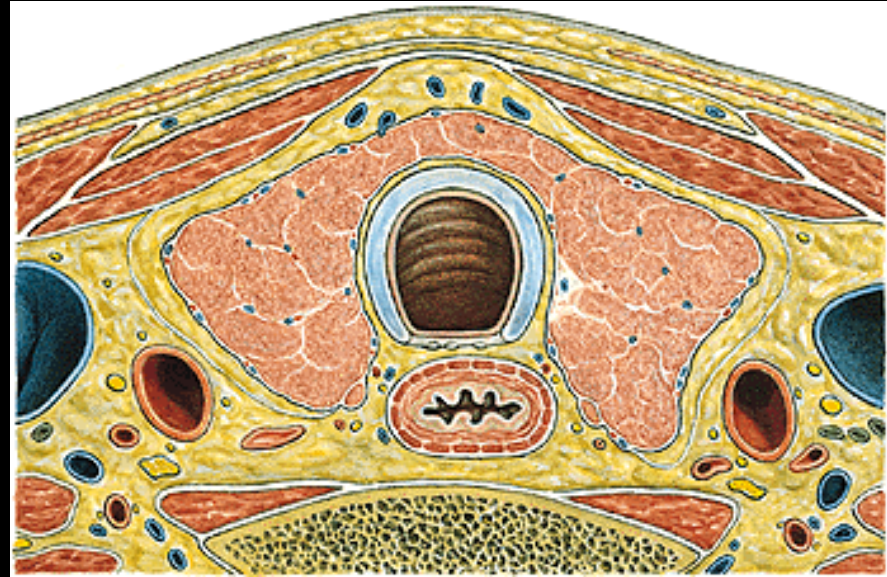
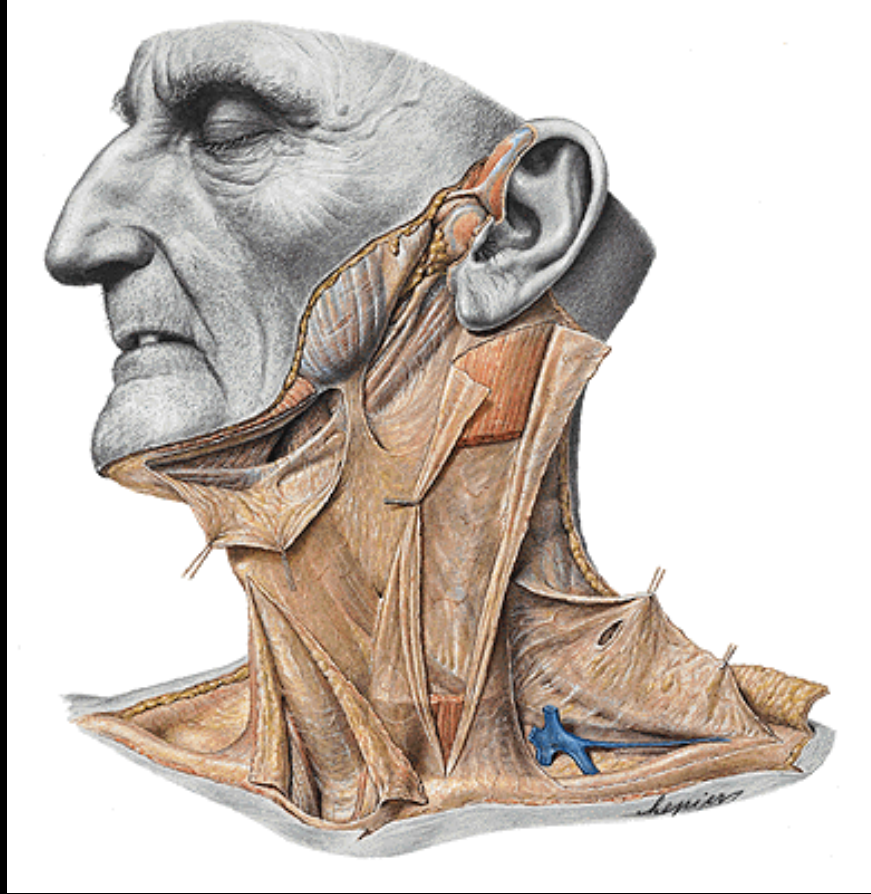
Lamina praetrachealis

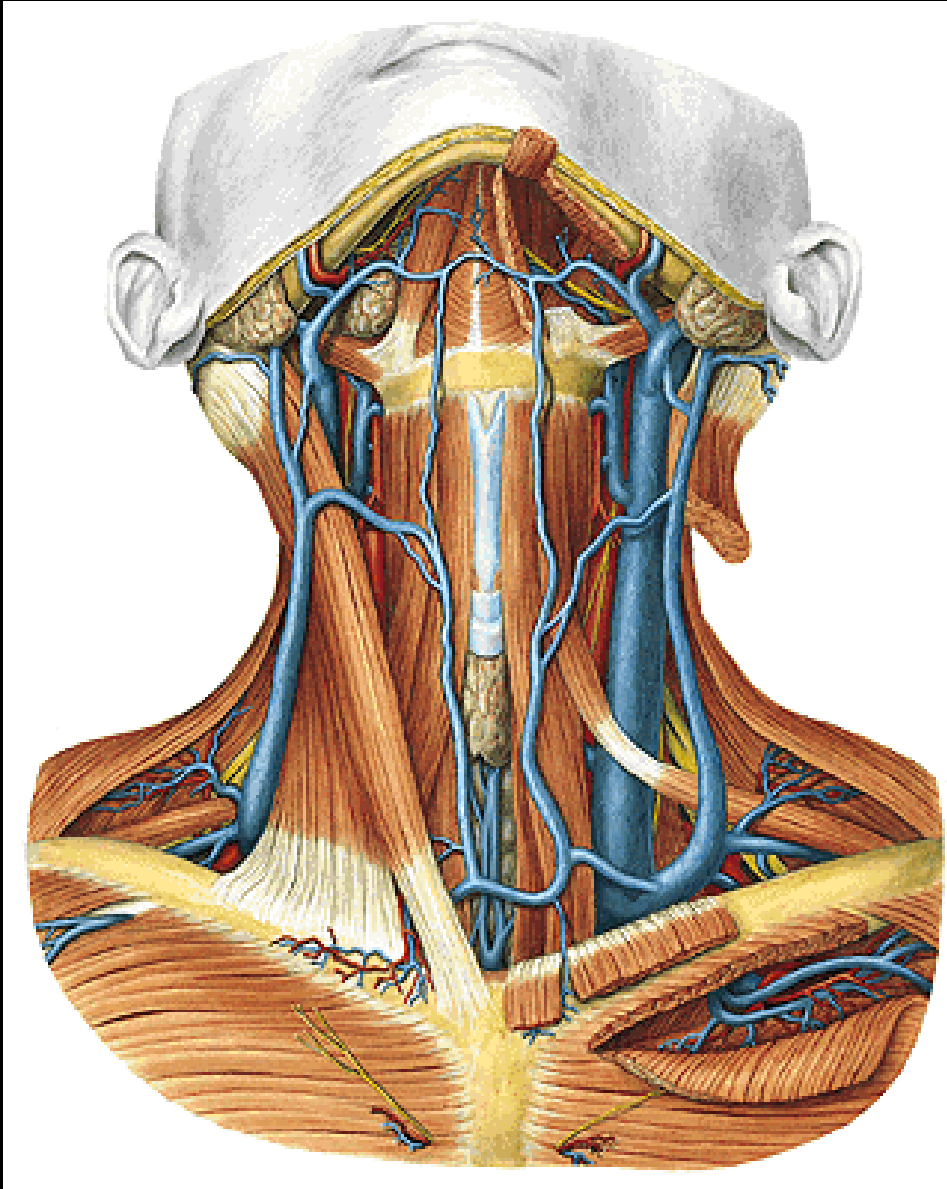
Lamina praevertebralis

Spatium suprasternale

(with arcus venosus juguli)

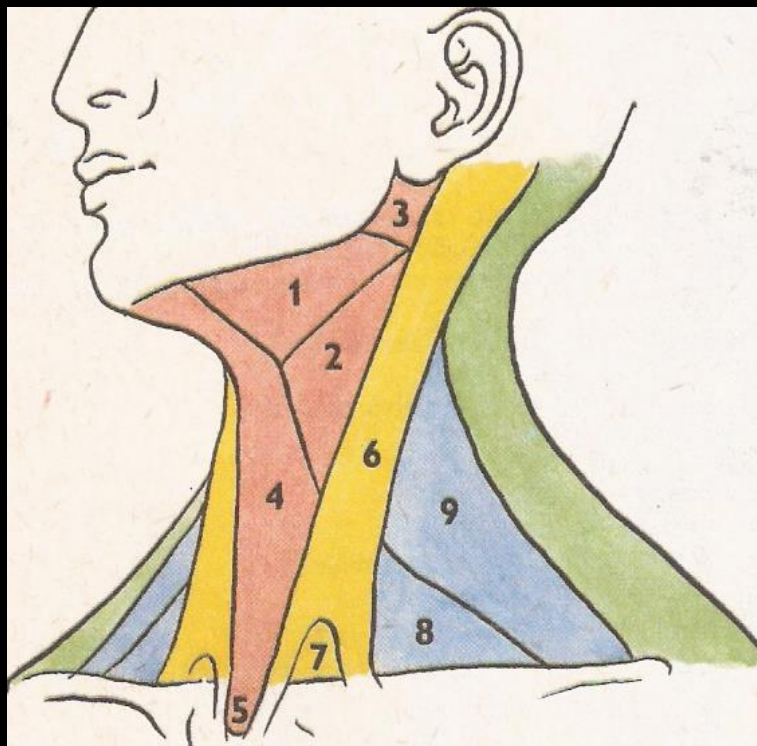
Vagina carotica



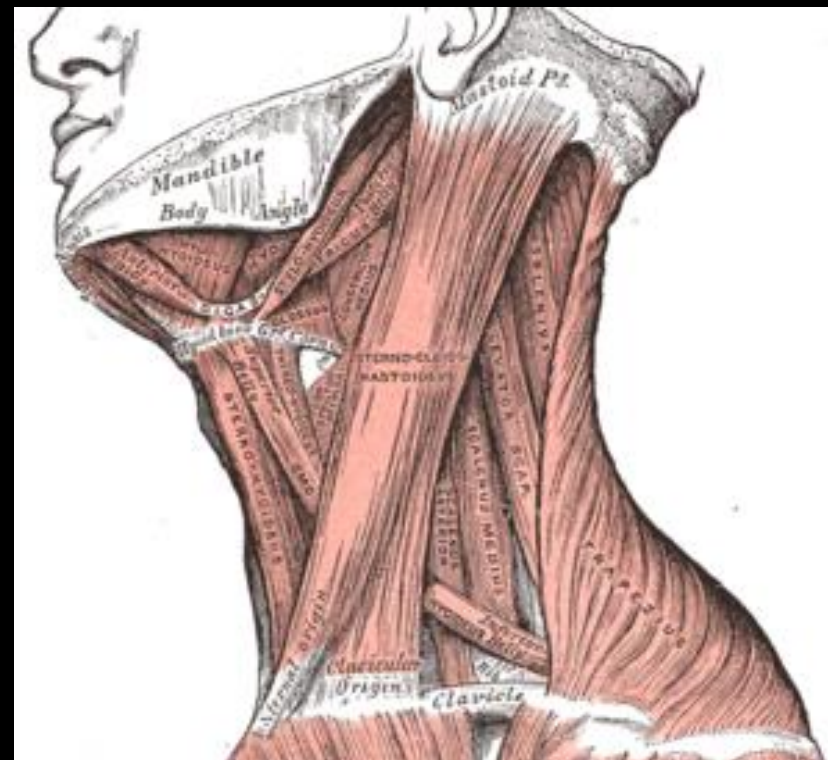


Spatium suprasternale
(with arcus venosus juguli)
Vagina carotica

Regiones colli



- 1) trigonum submandibulare
- 2) trigonum caroticum
- 3) regio retromandibularis
- 4) regio mediana colli
- 5) fossa jugularis



- 6) regio sternocleidomastoidea
- 7) fossa supraclavicularis minor
- 8) trigonum omoclaviculare
- 9) trigonum omotracheum



Used pictures come from:

Moore, K. L. (1992): Clinical oriented anatomy. Third edition.
Williams&Wilkins, A Waverly Company.

Gilroy, A. M. et al. (2009): Atlas of Anatomy. Thieme New York, Stuttgart.

Putz, R. (2008):
Atlas of Human Anatomy Sobotta. Elsevier Books.

Platzer, W., Kahle, W., Leonhardt H. (1992):
Locomotor system. Georg Thieme Verlag, Stuttgart,
New York, 4th edition.

Čihák, R. (1987): Anatomie 1. Avicenum, Zdravotnické nakladatelství.