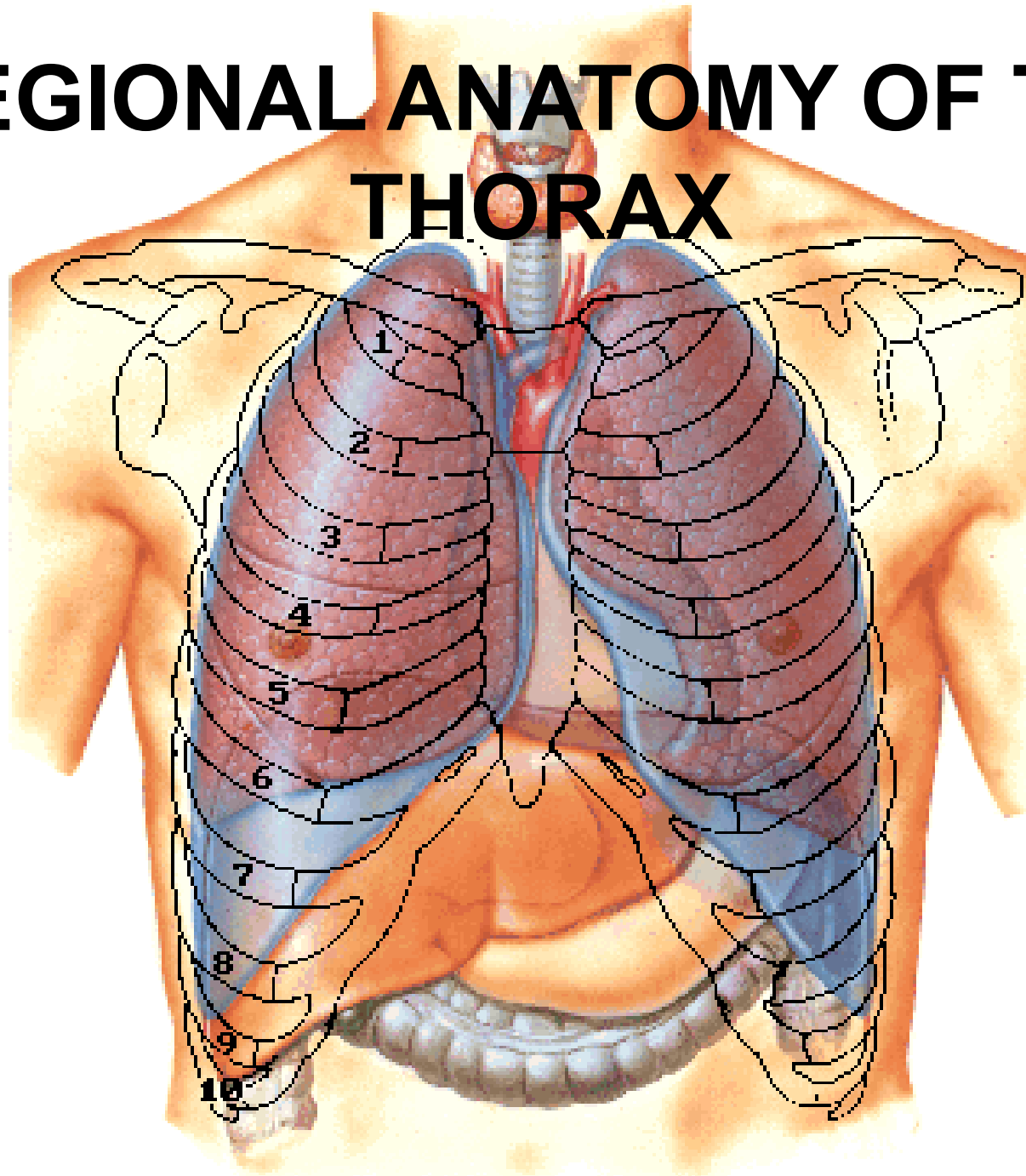
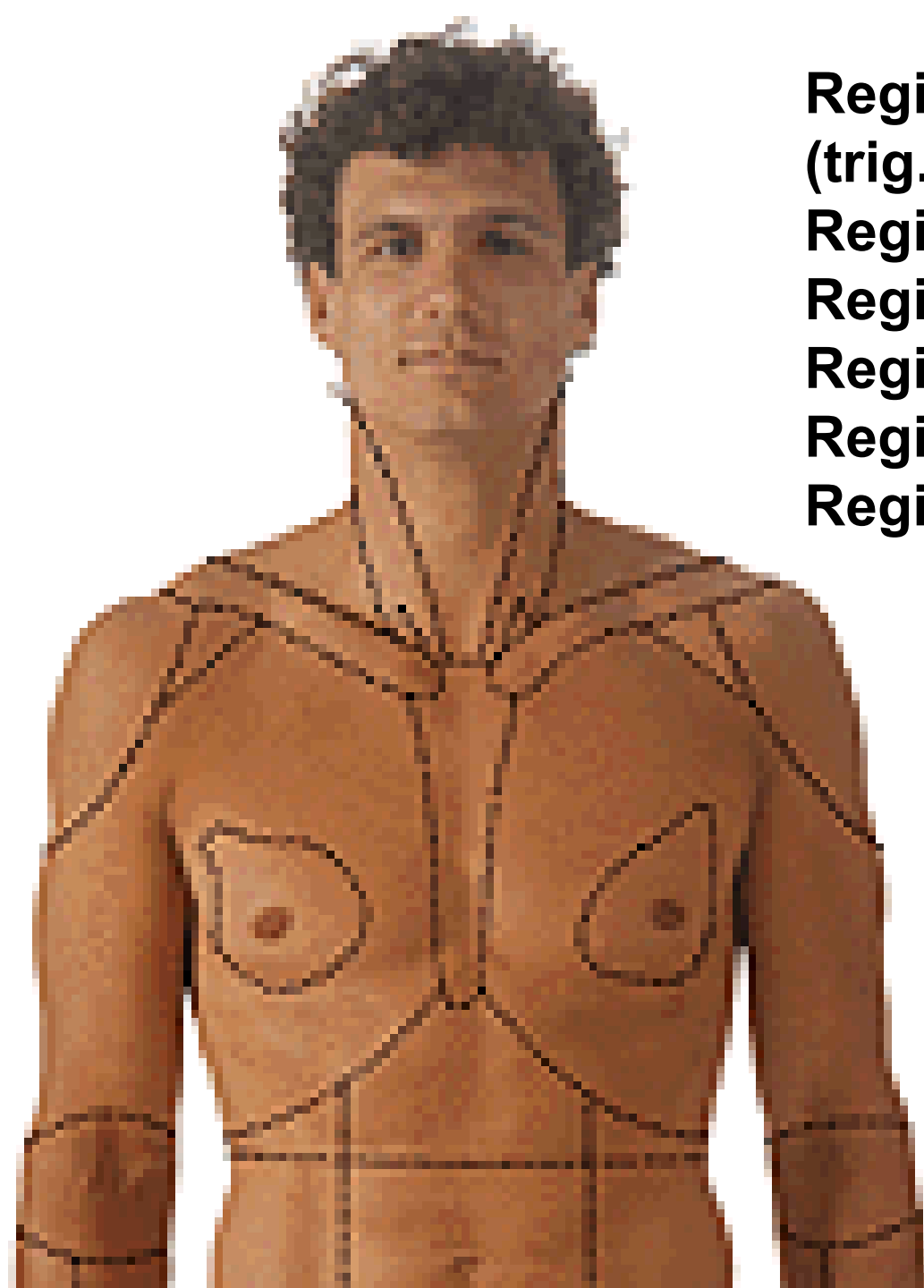


REGIONAL ANATOMY OF THE THORAX



**Regio infraclavicularis
(trig. delto-, clavipectorale)
Regio pectoralis
Regio axillaris
Regio mammaria
Regio sternalis
Regio hypochondriaca dx. et sin.**





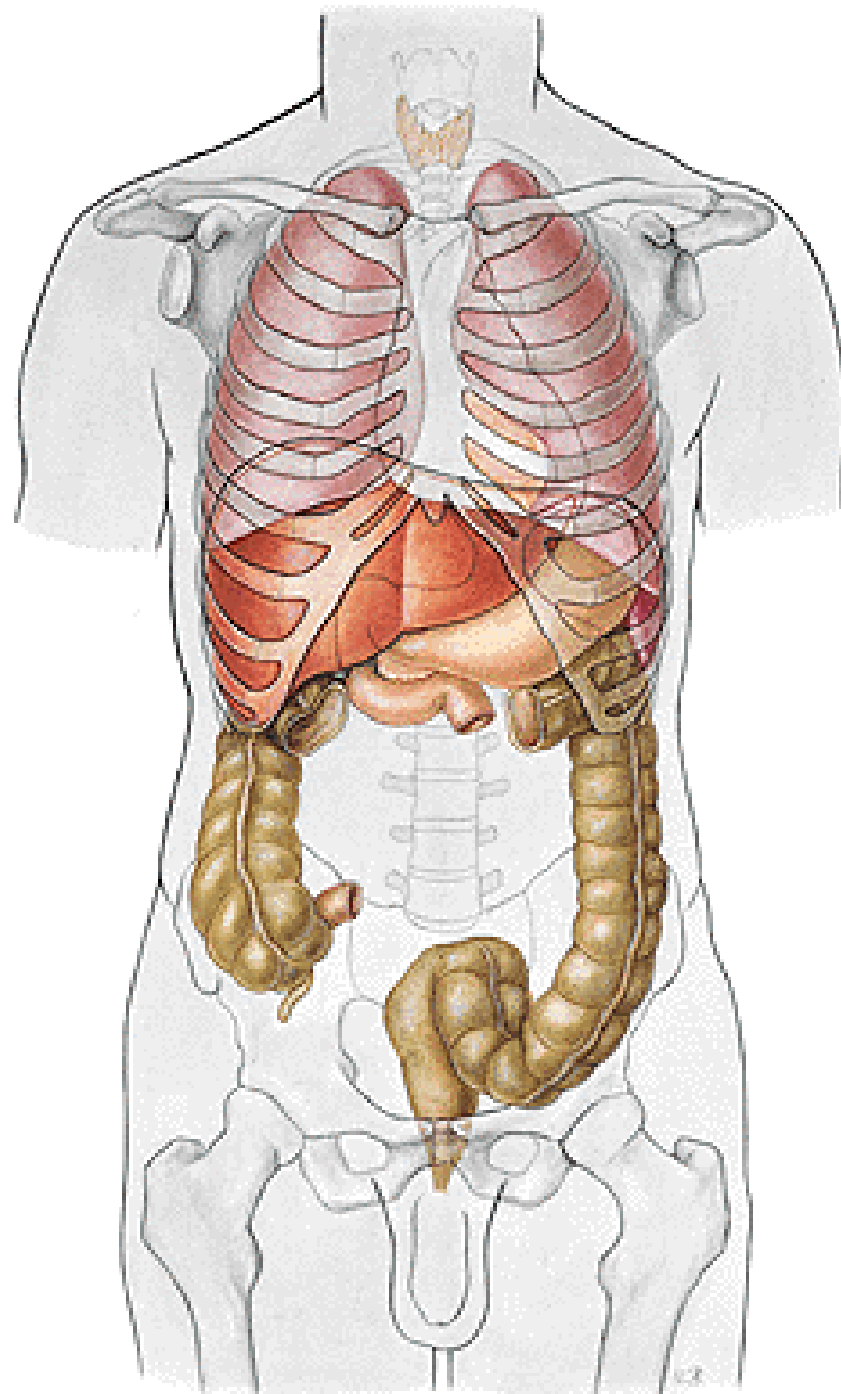
Regio vertebralis

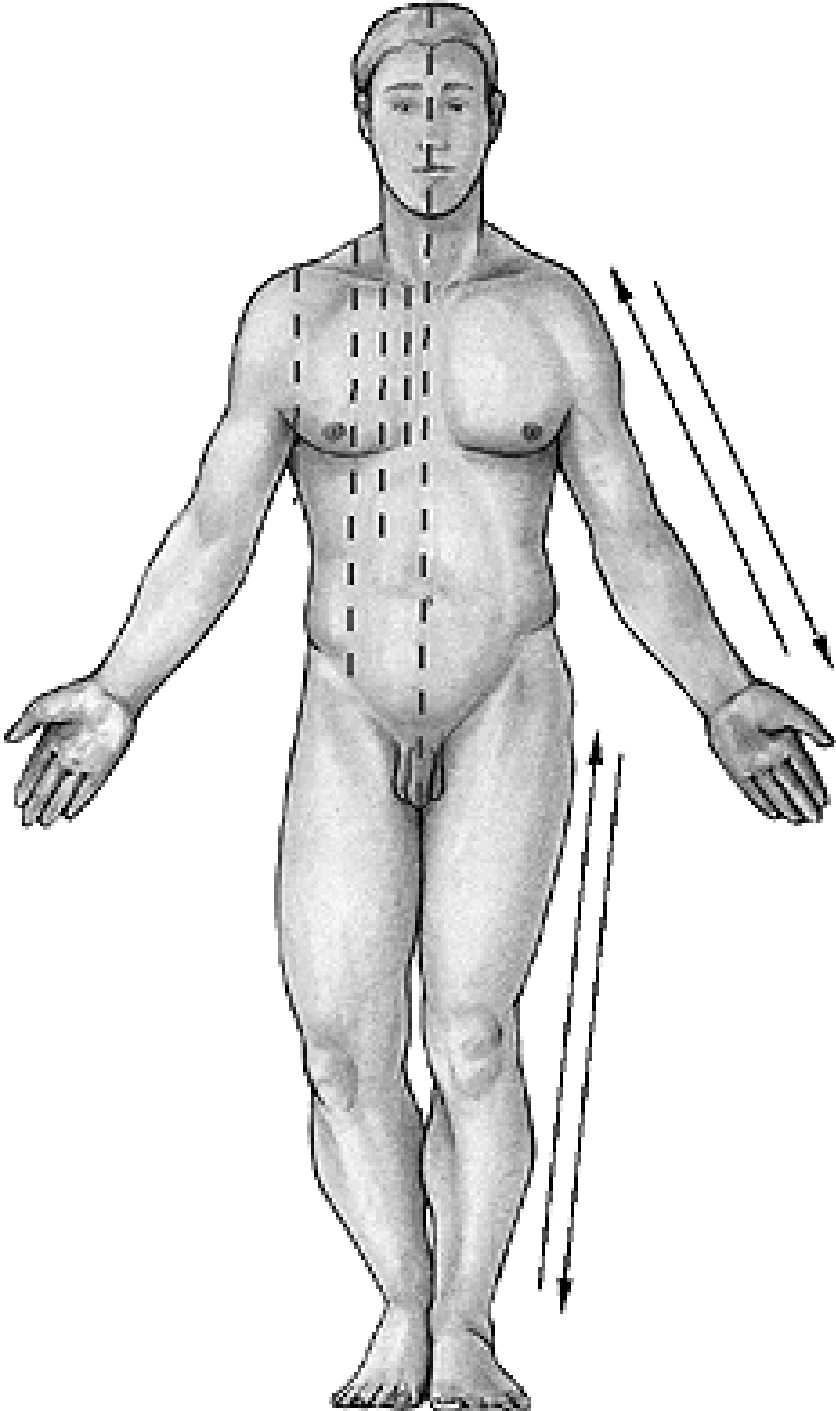
Regio suprascapularis

Regio scapularis

Regio infrascapularis

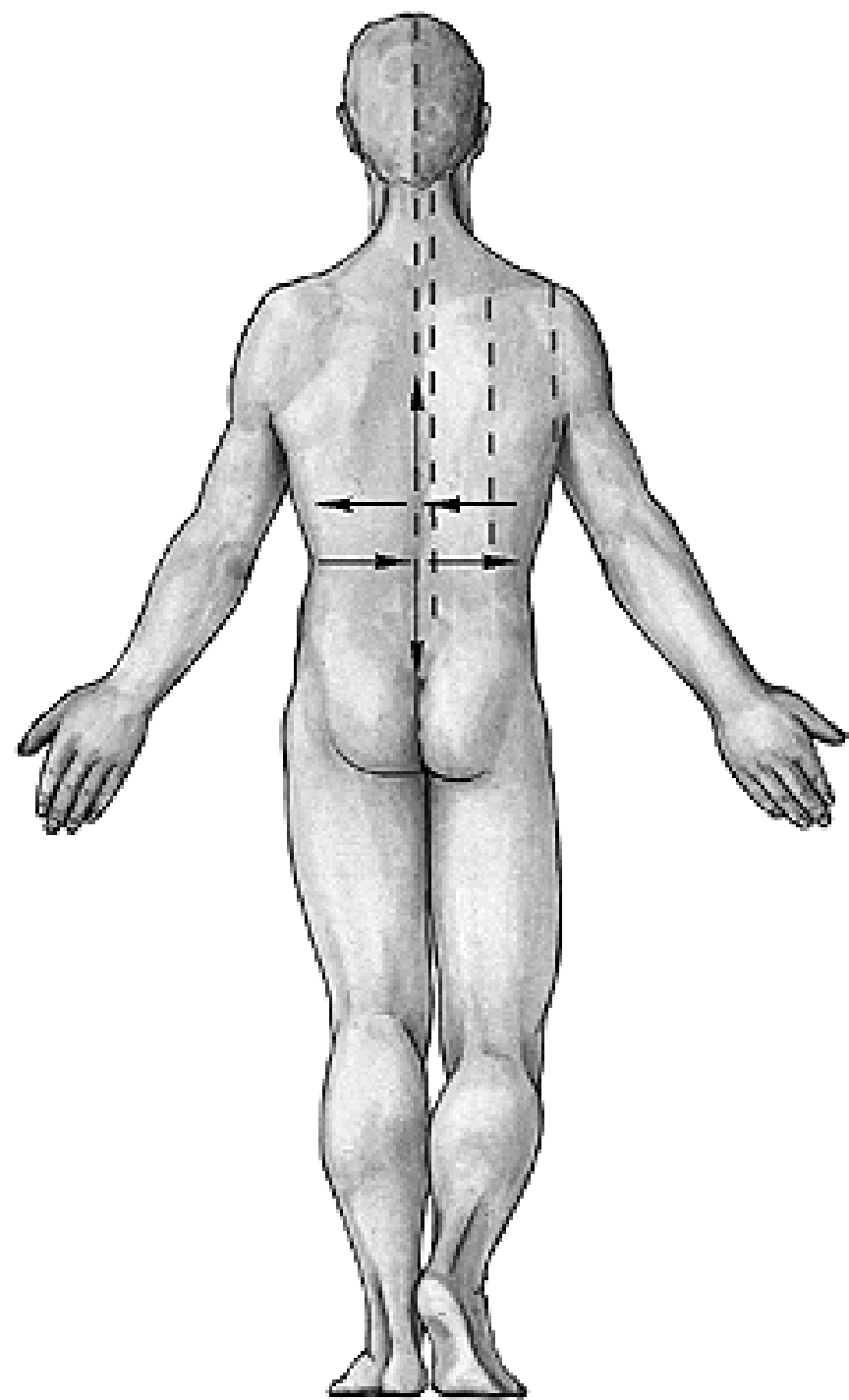
Regio axillaris





- Linea mediana anterior**
- Linea sternalis**
- Linea parasternalis**
- Linea medioclavicularis**
- Linea axillaris ant.**
- Linea axillaris media**

Linea axillaris post.
Linea scapularis
Linea paravertebralis
Linea mediana post.

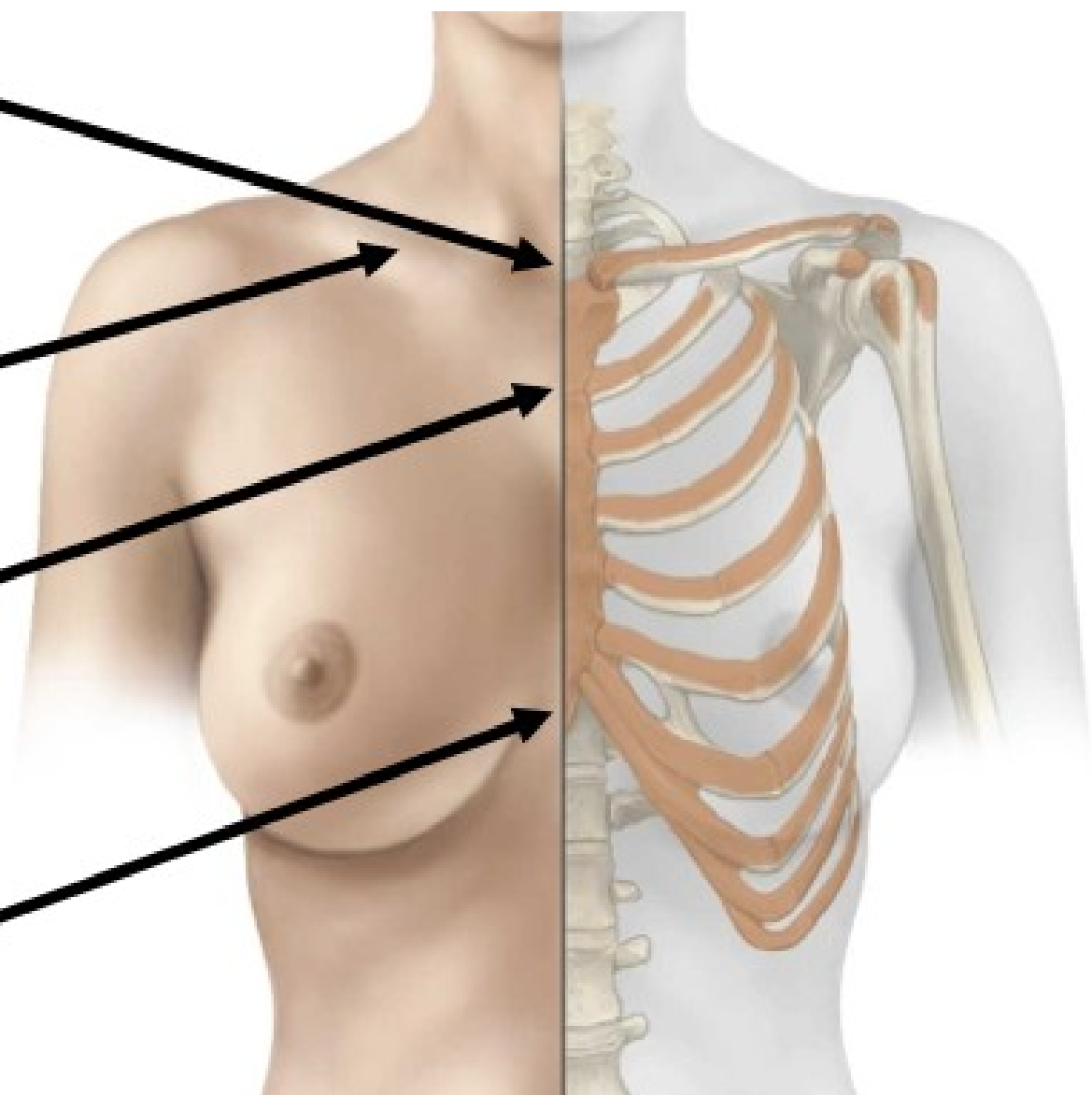


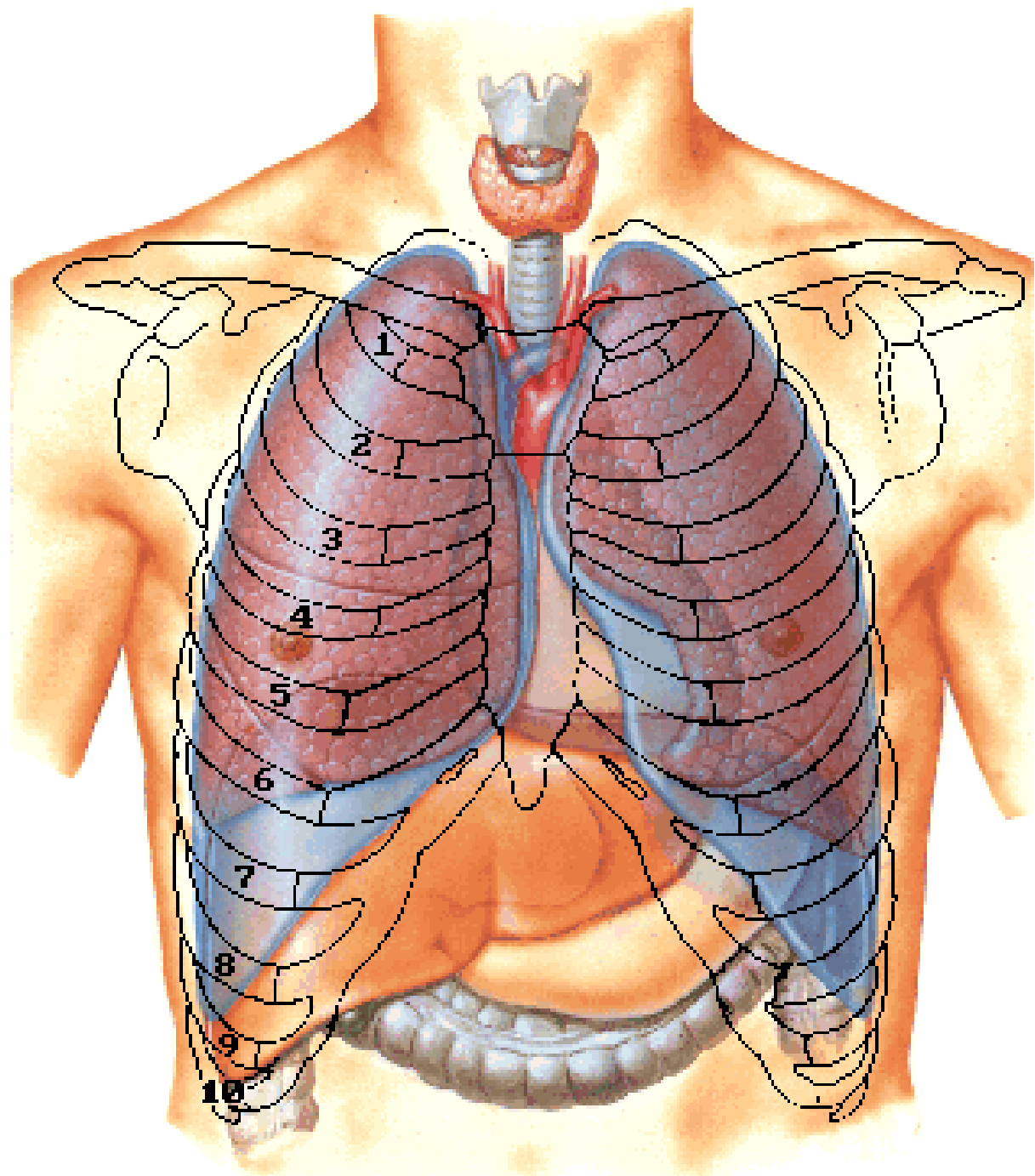
**Jugular Notch
(T2 Vertebral Level)**

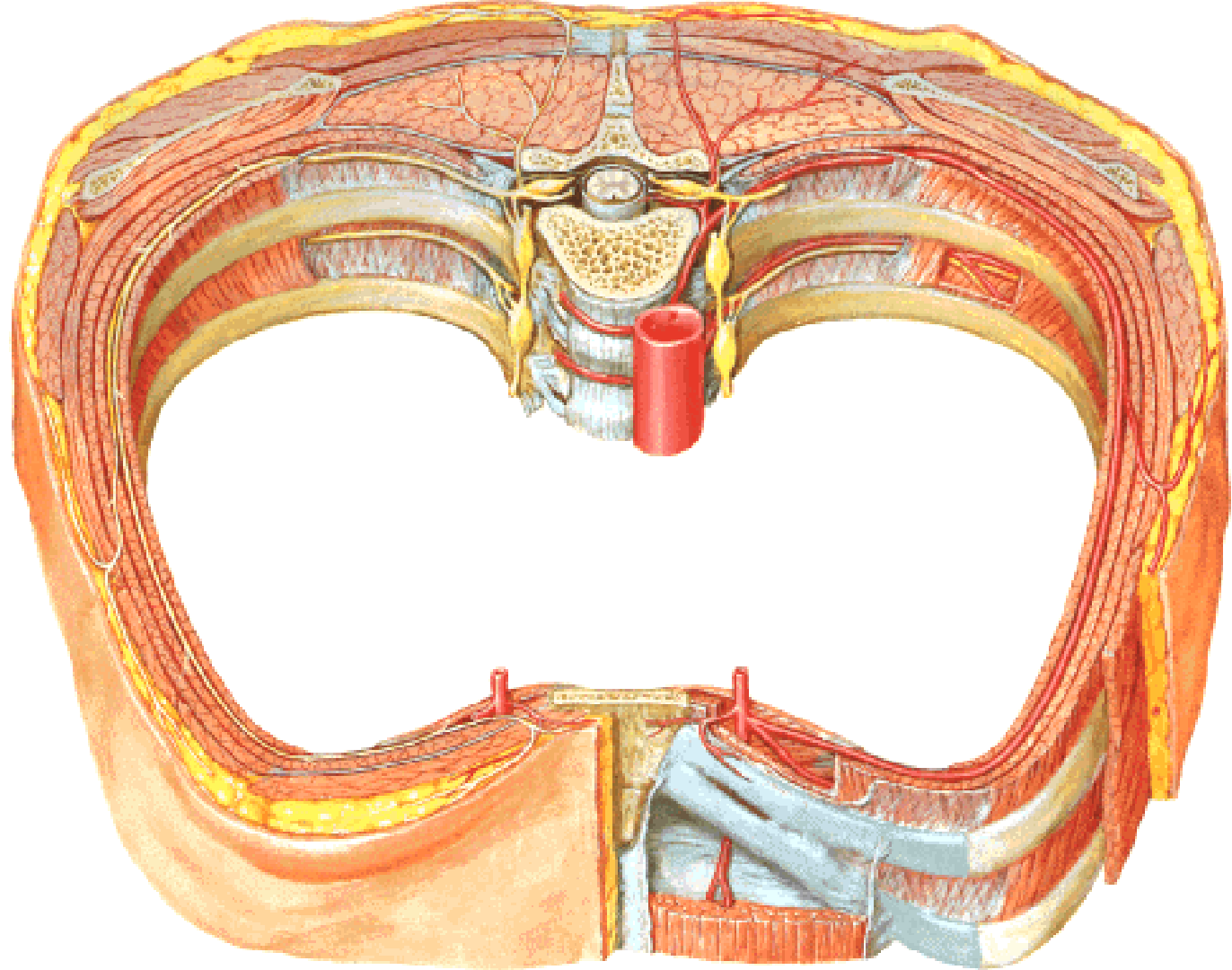
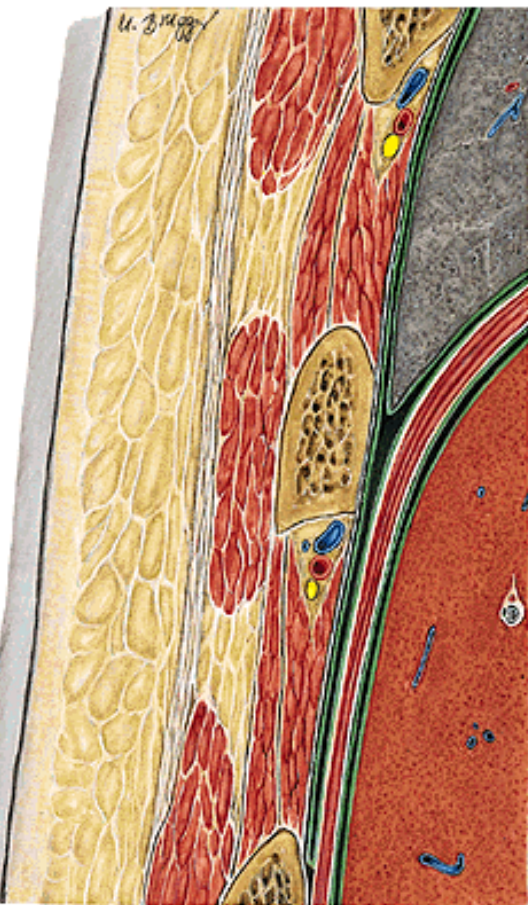
Clavicle

**Sternal Angle
(T4 Vertebral Level)**

**Xiphoid Process
(T9 Vertebral Level)**







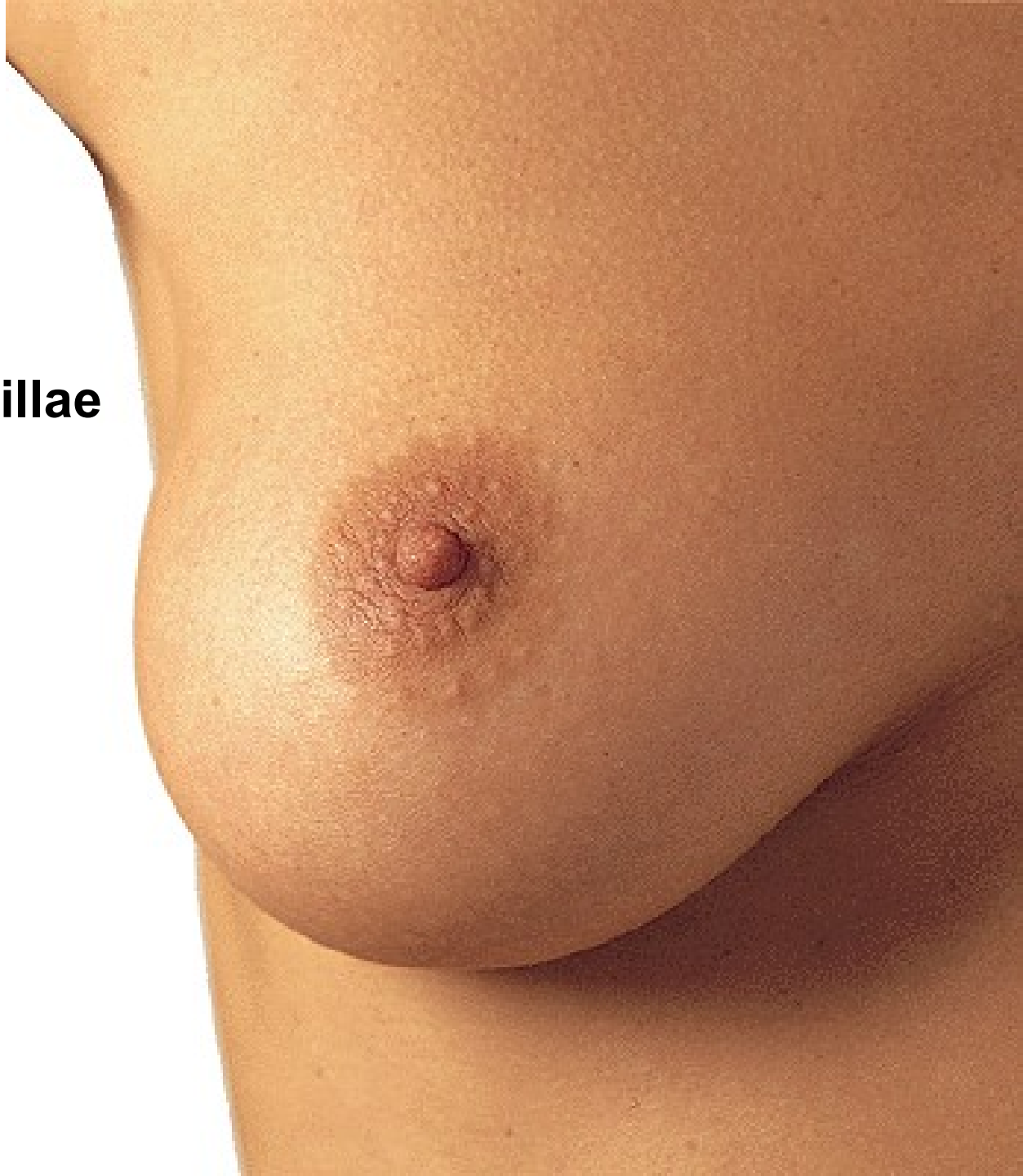MAMMA FEMININA

Areola mammae

**Glandulae areolares
(Montgomery)**

Papilla mammae

Area cribriformis papillae

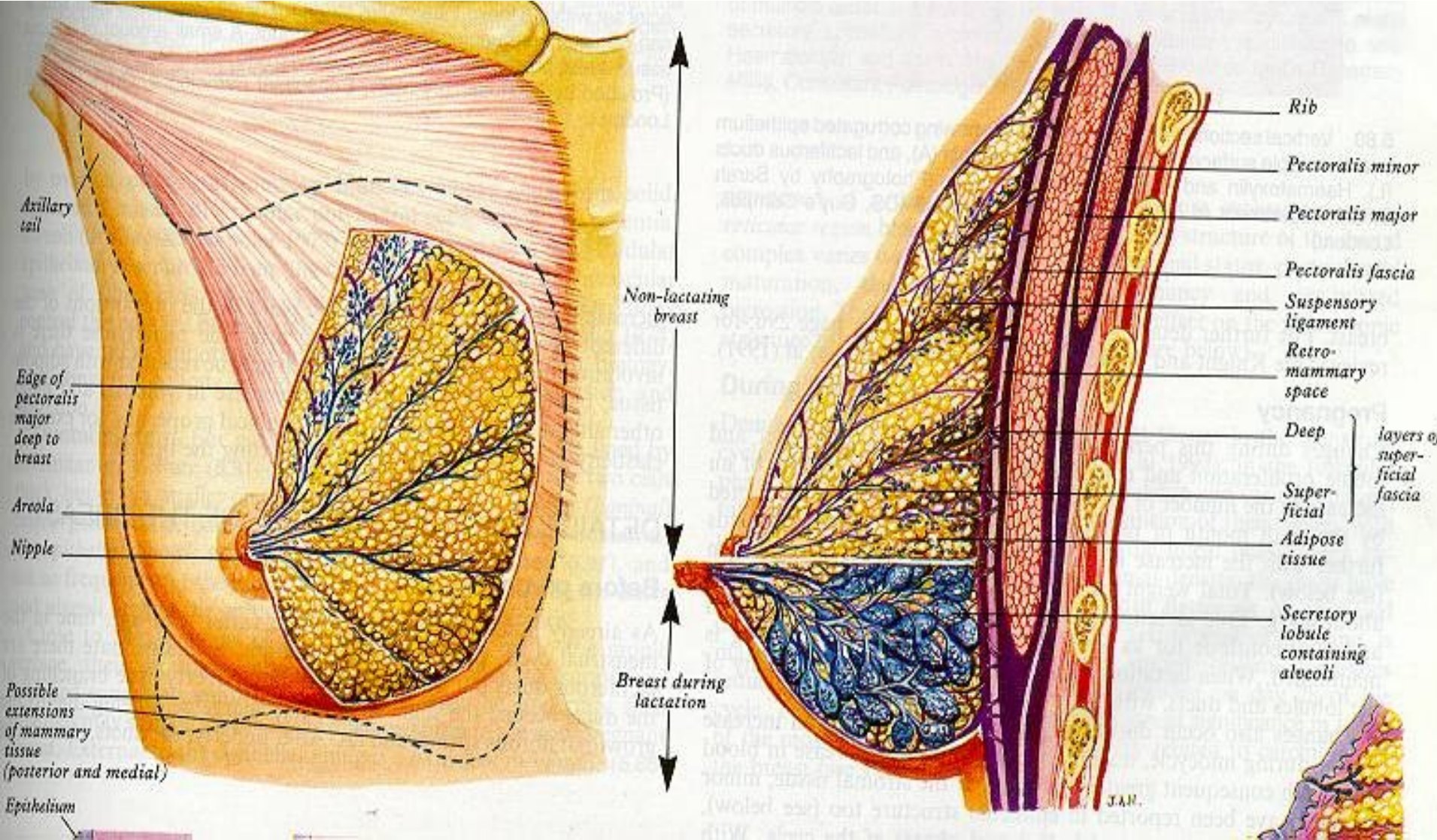


GLANDULA MAMMARIA

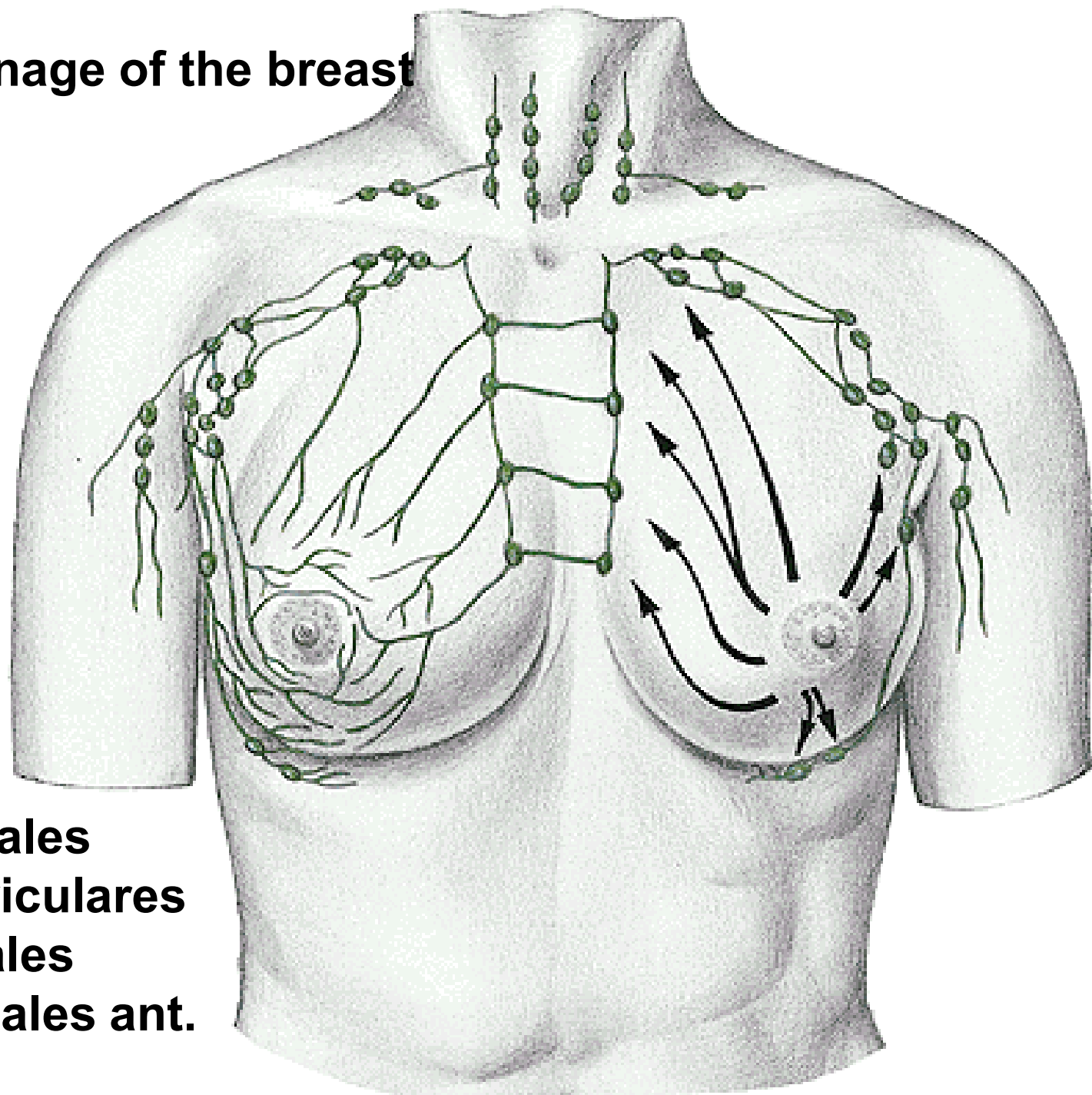
Processus axillaris

15 – 20 lobi mammae

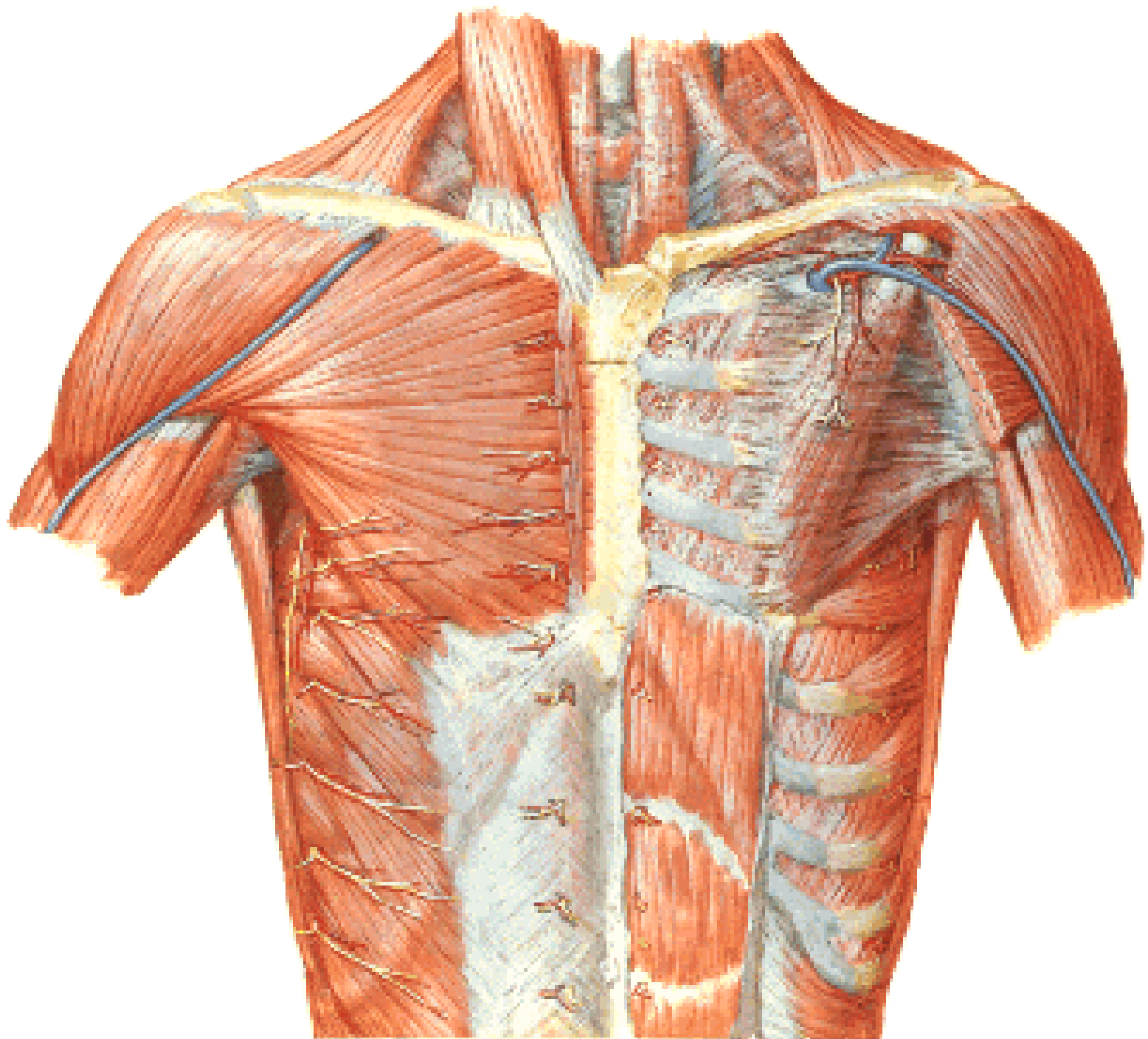
Ductus lactifer

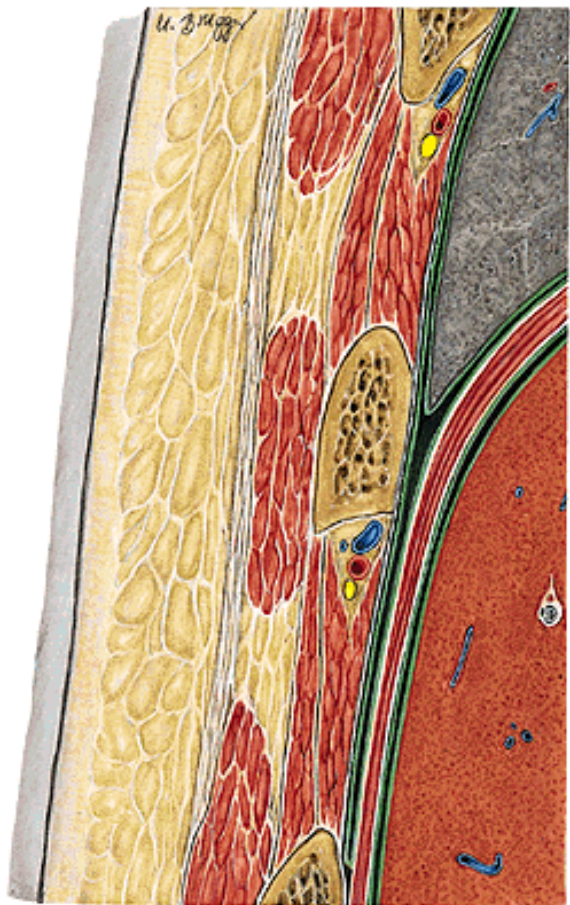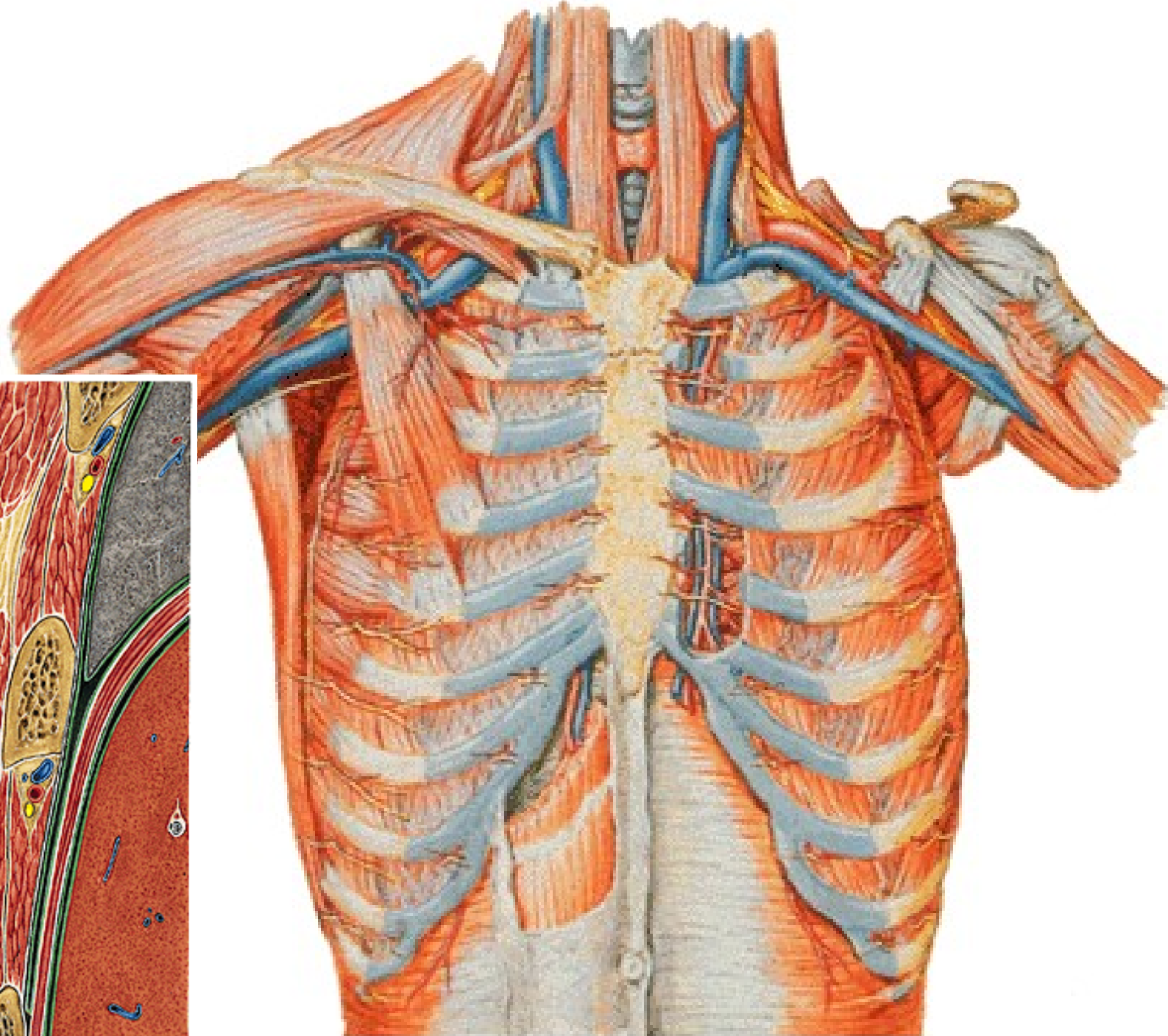


Lymphatic drainage of the breast

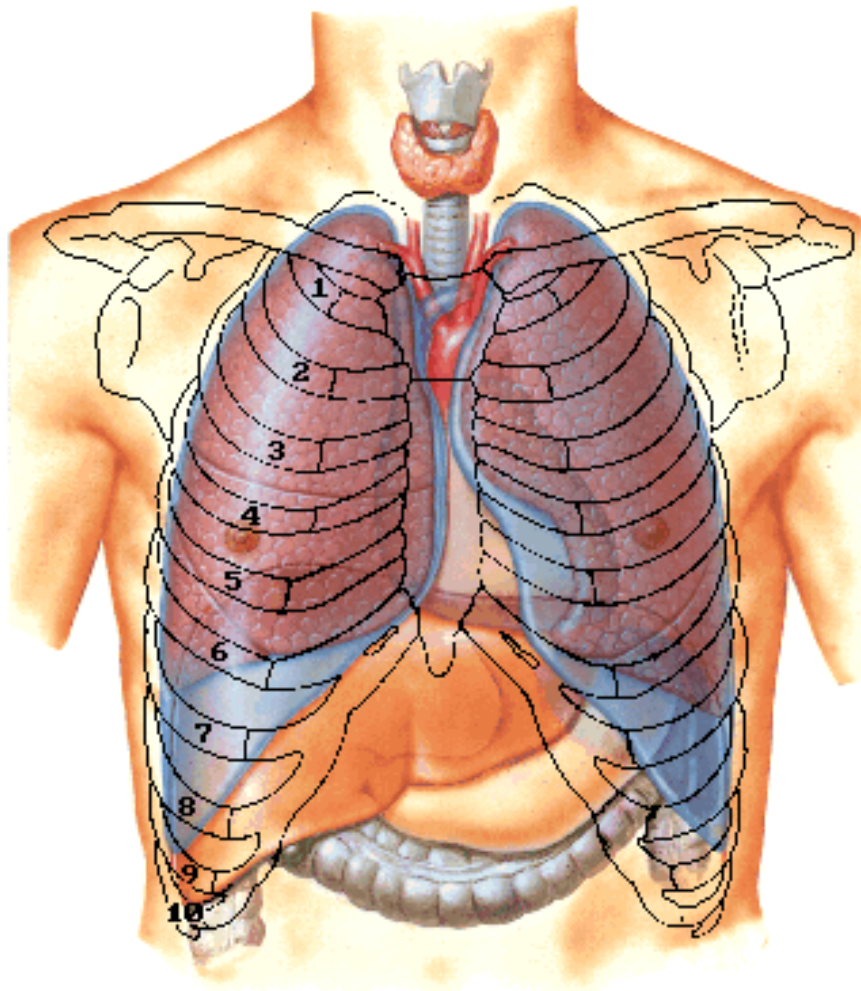


- nll. axillares
- nll. parasternales
- nll. supraclaviculares
- nll. intercostales
- nll. mediastinales ant.





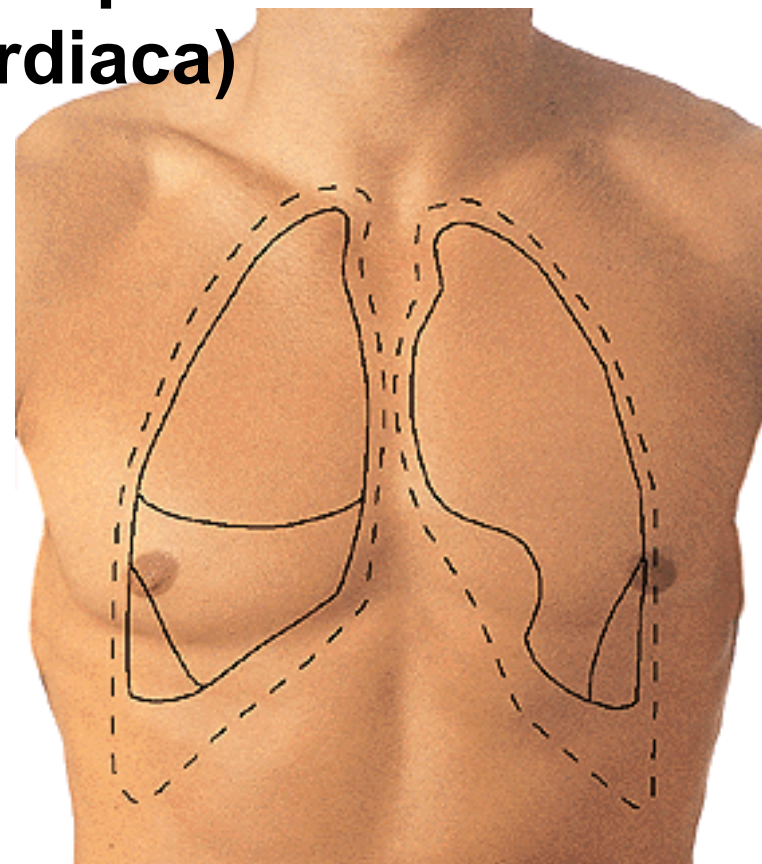
**PROJECTION OF ORGANS
ONTO THE THORACIC WALL**

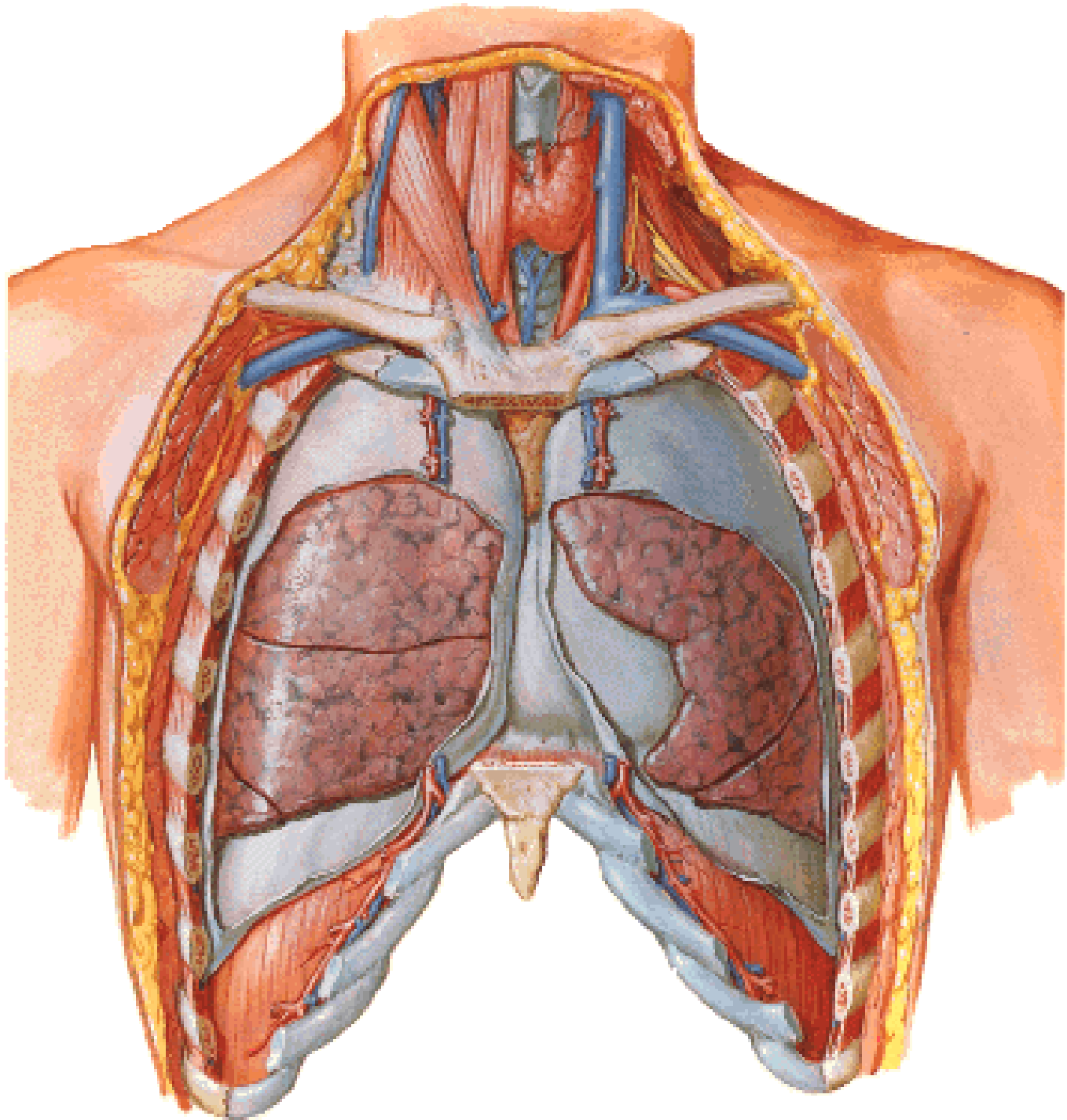


**Cupula pleurae
= Apex pulmonis**

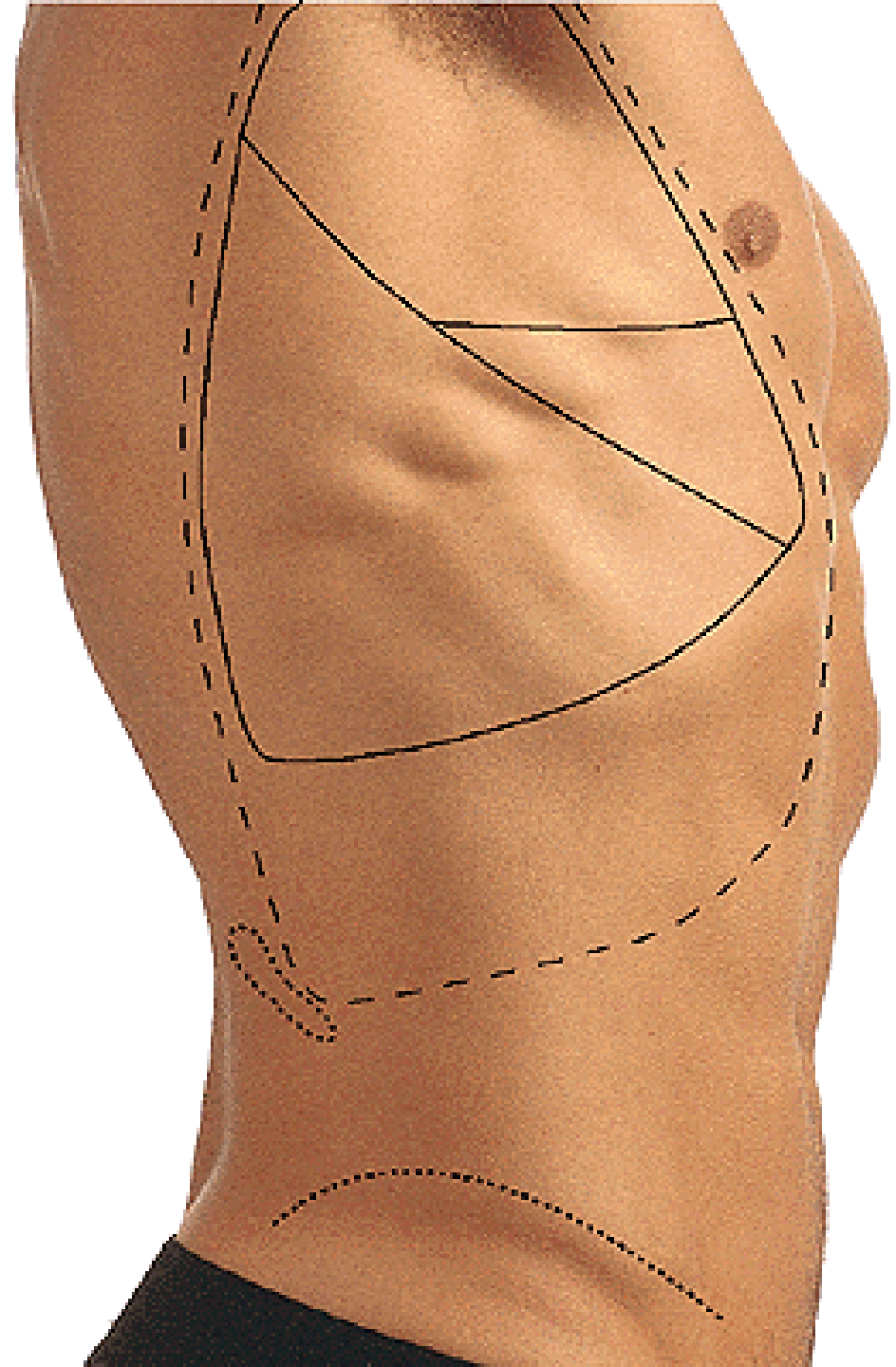
**Area interpleuralis sup.
(thymica)**

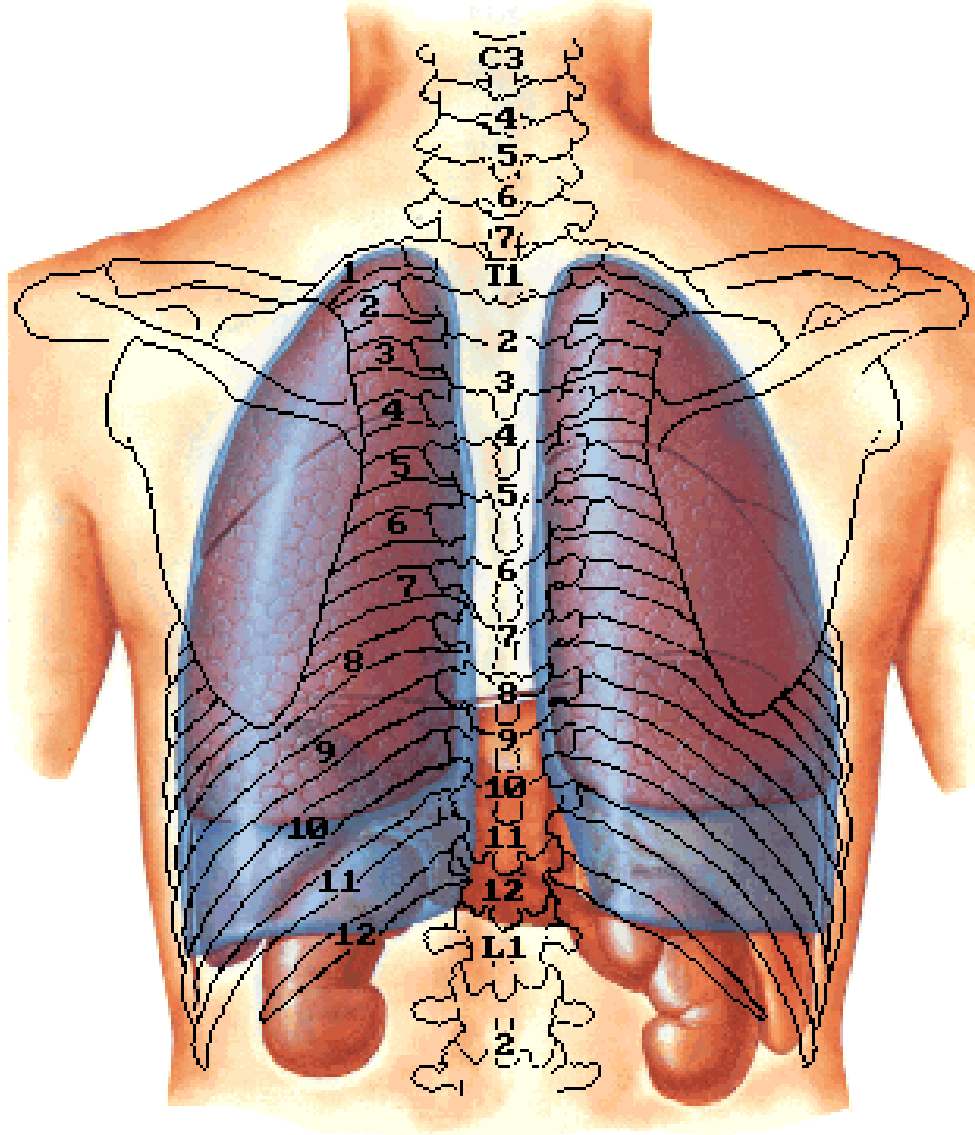
**Area interpleuralis inf.
(pericardiaca)**

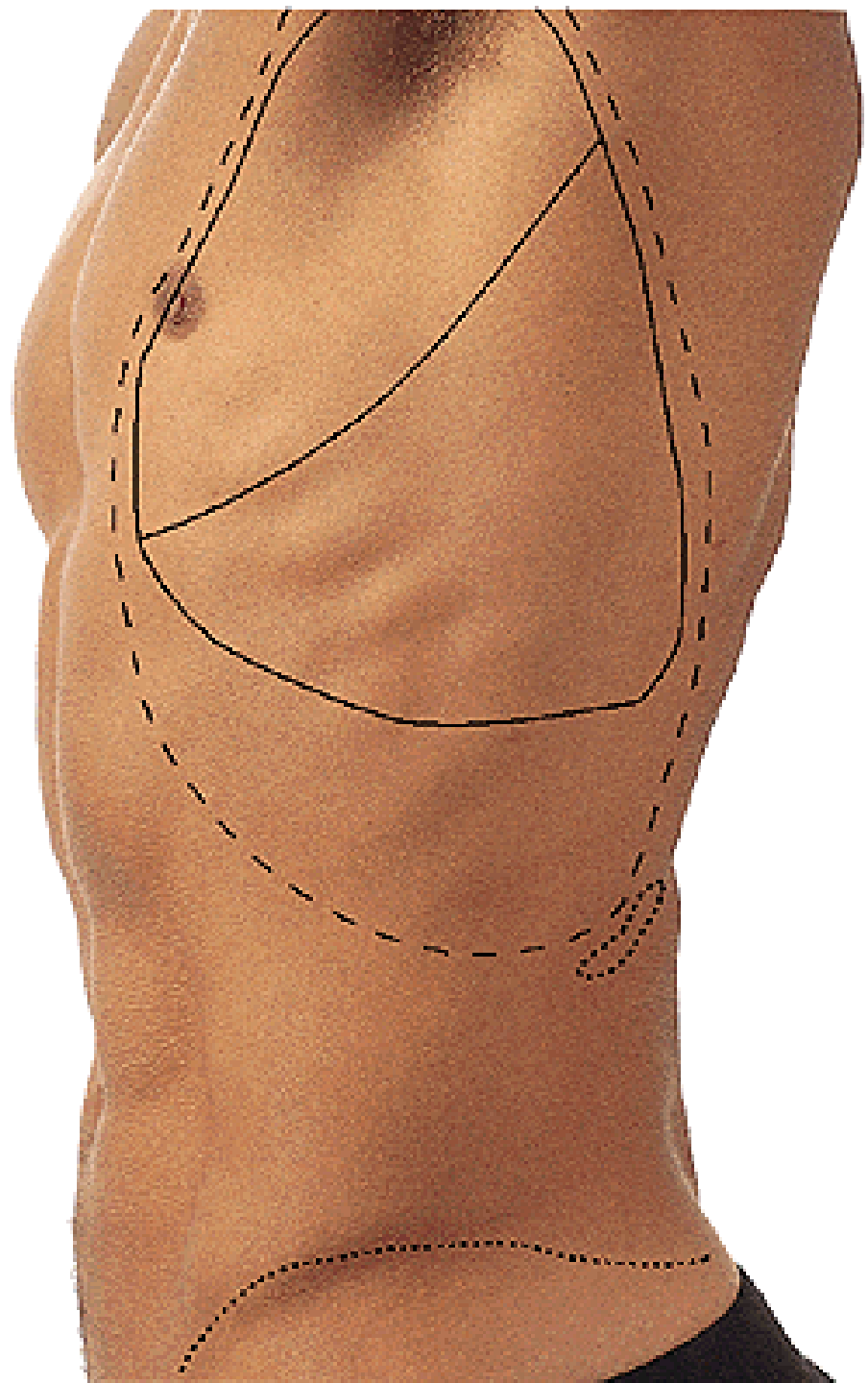




Fissura obliqua
Fissura horizontalis

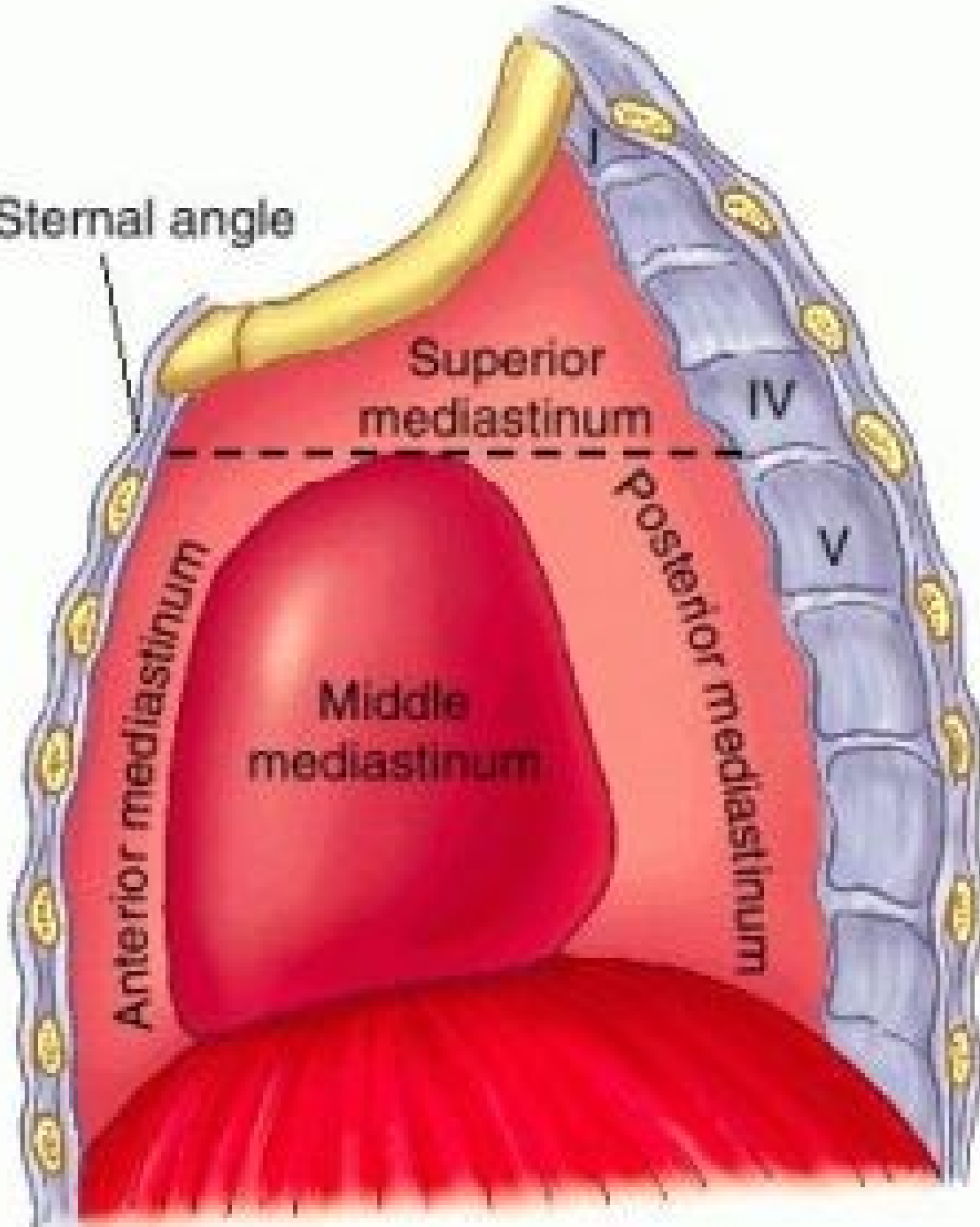


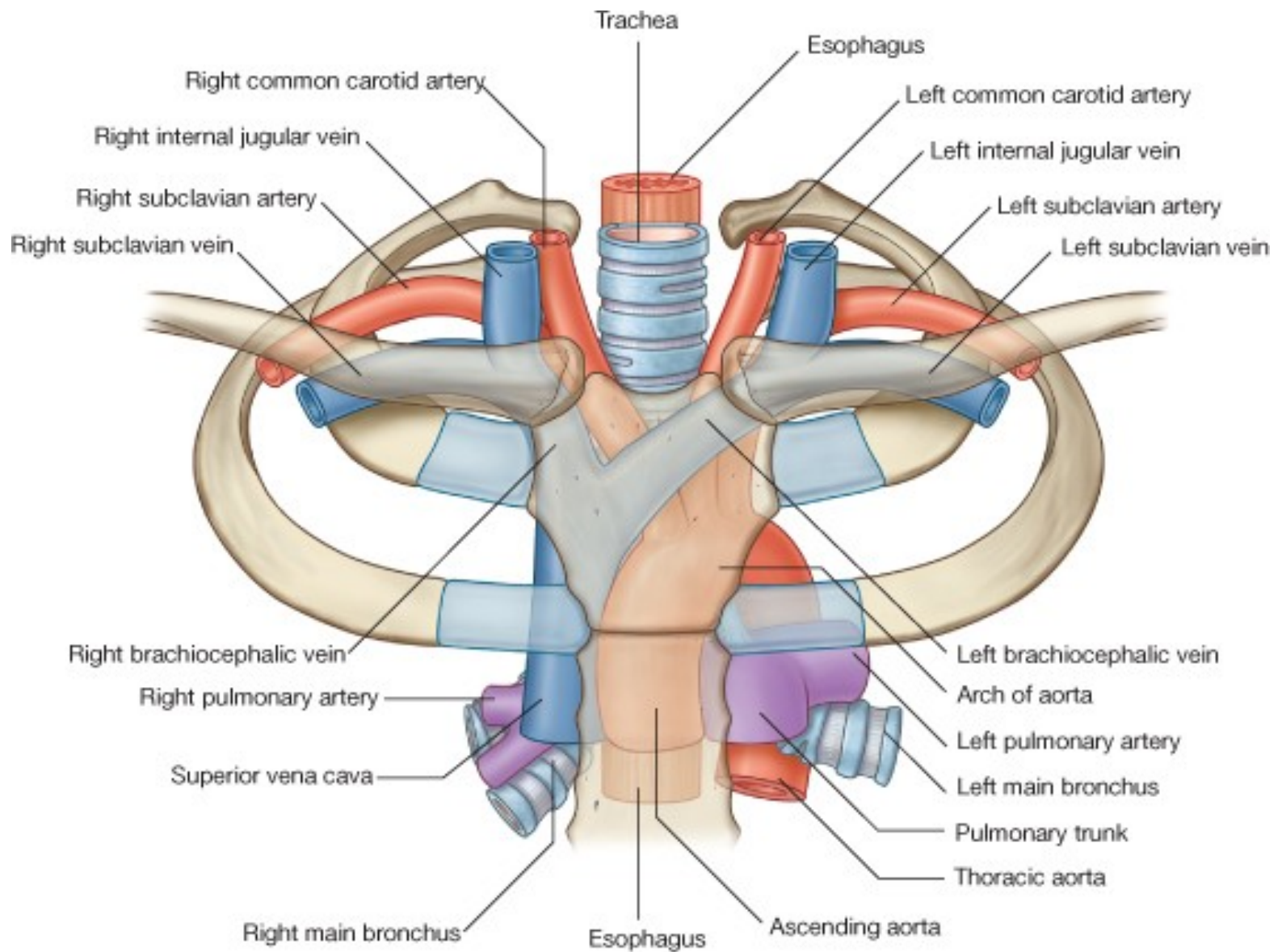


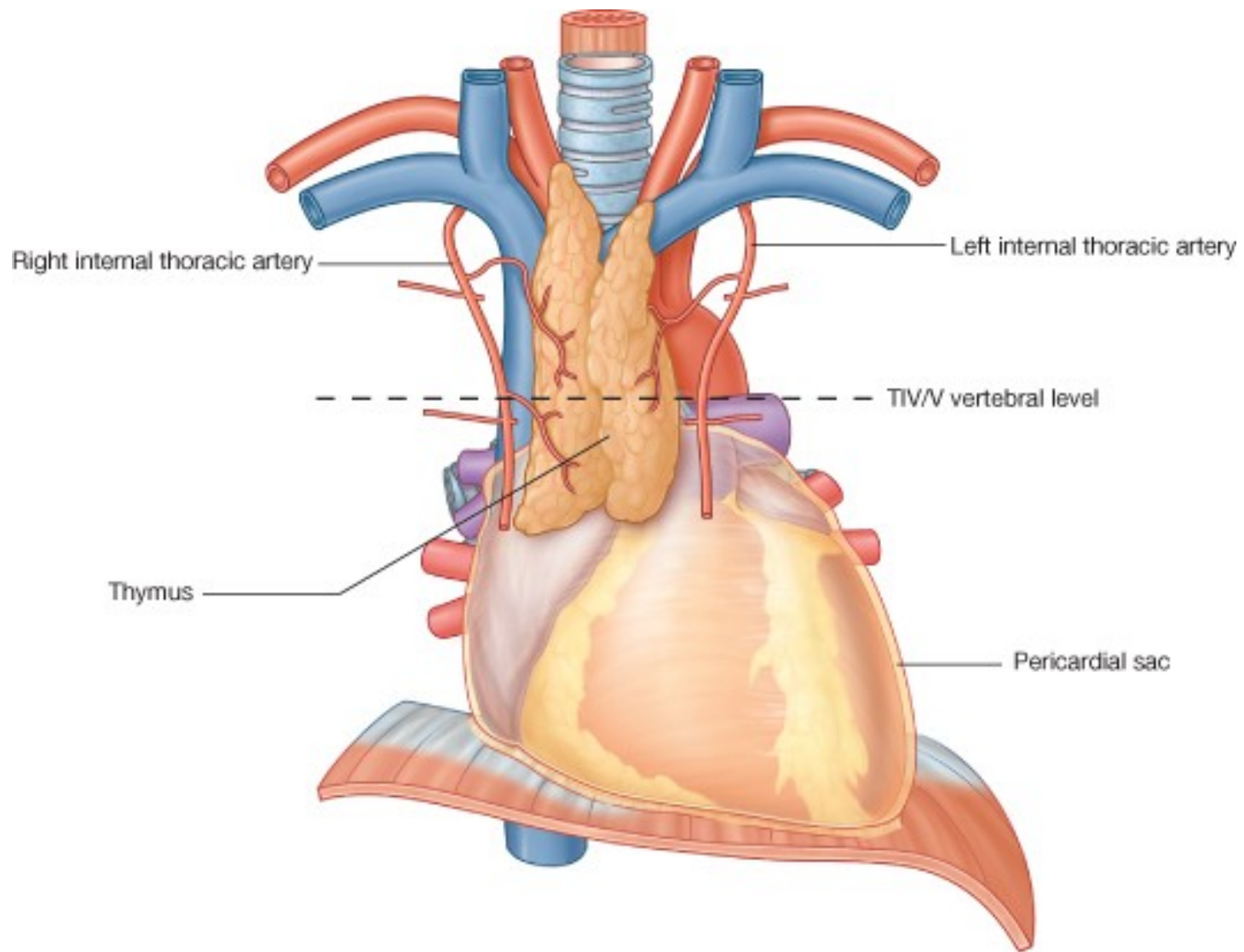


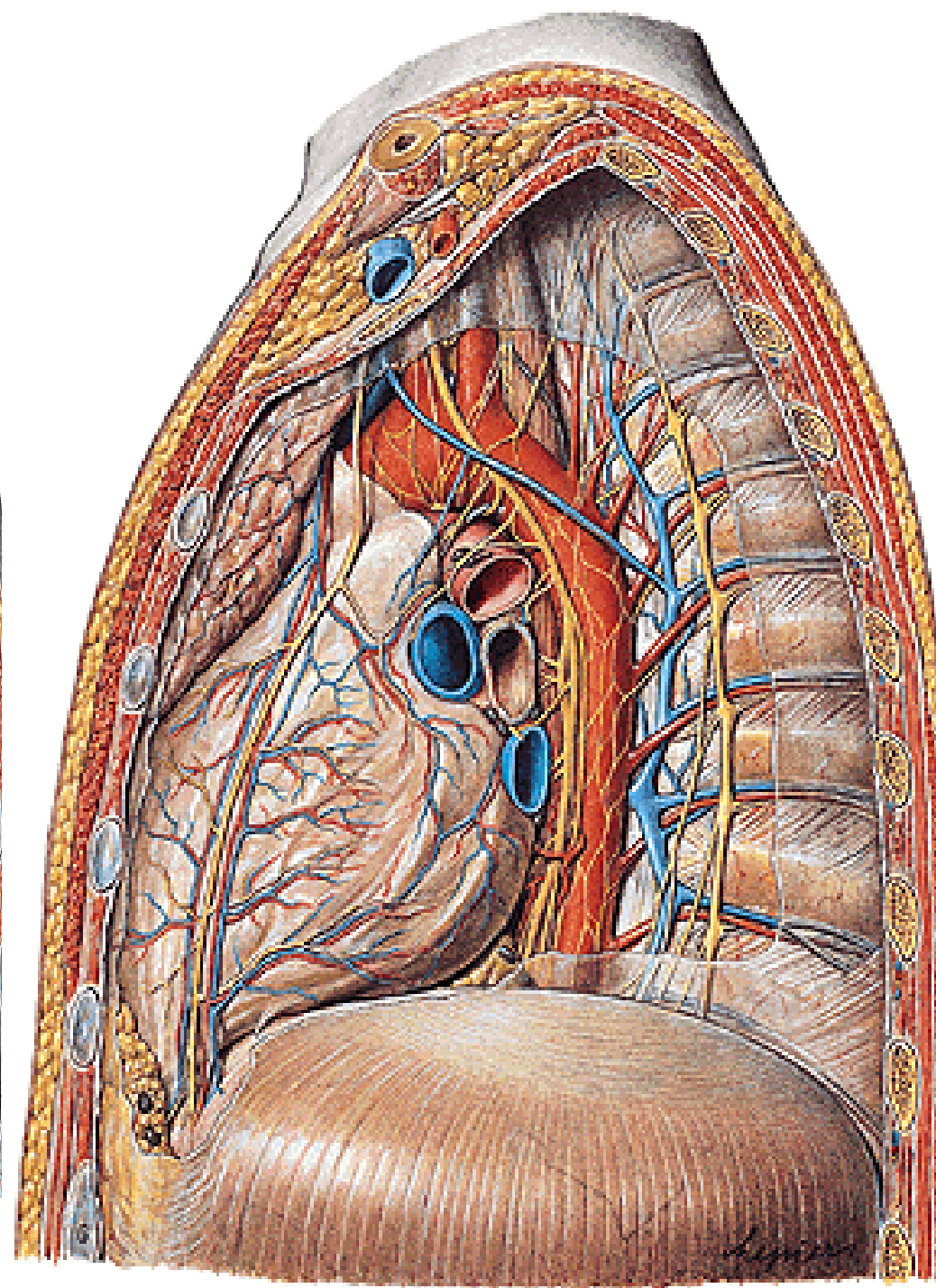
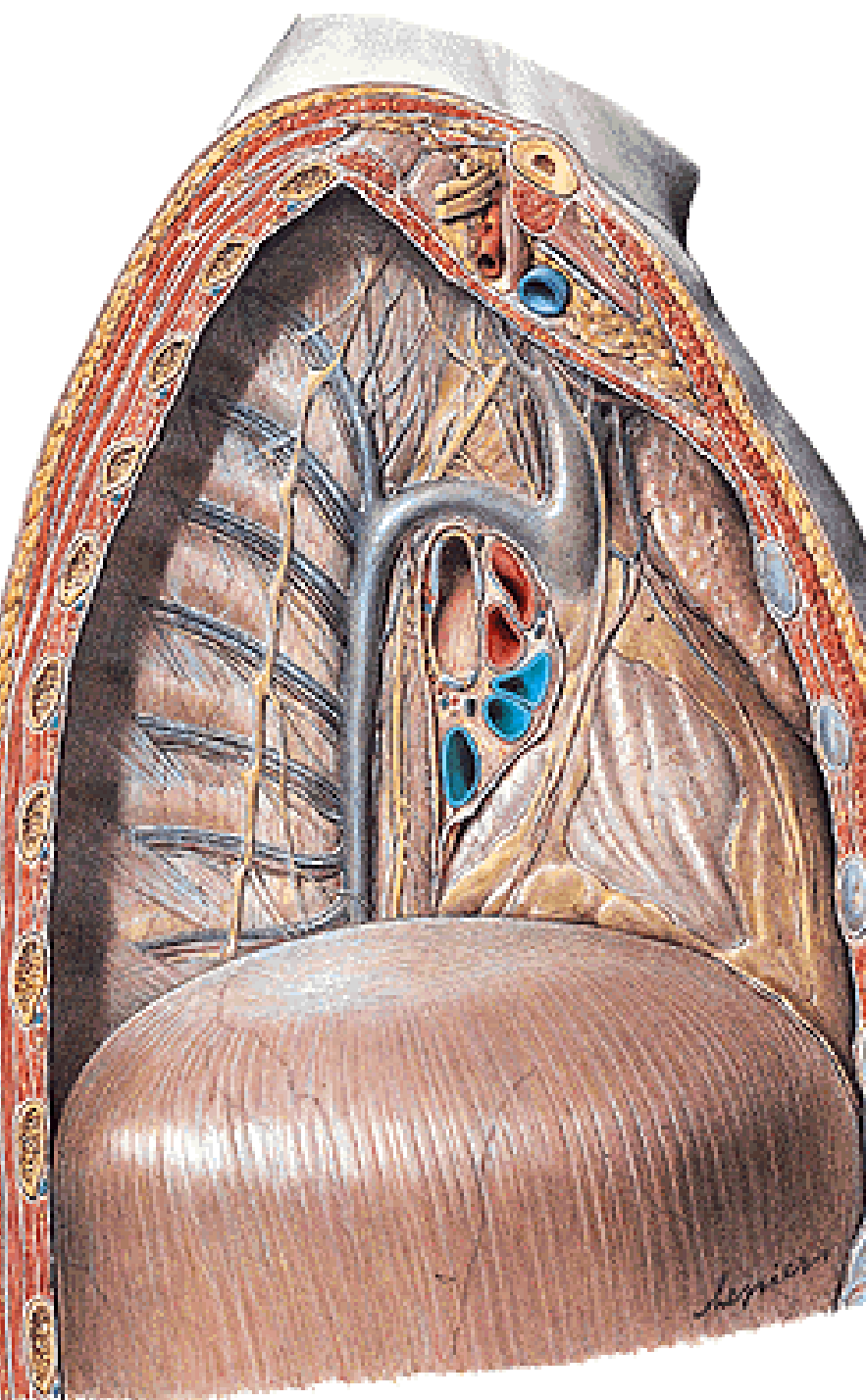
MEDIASTINUM

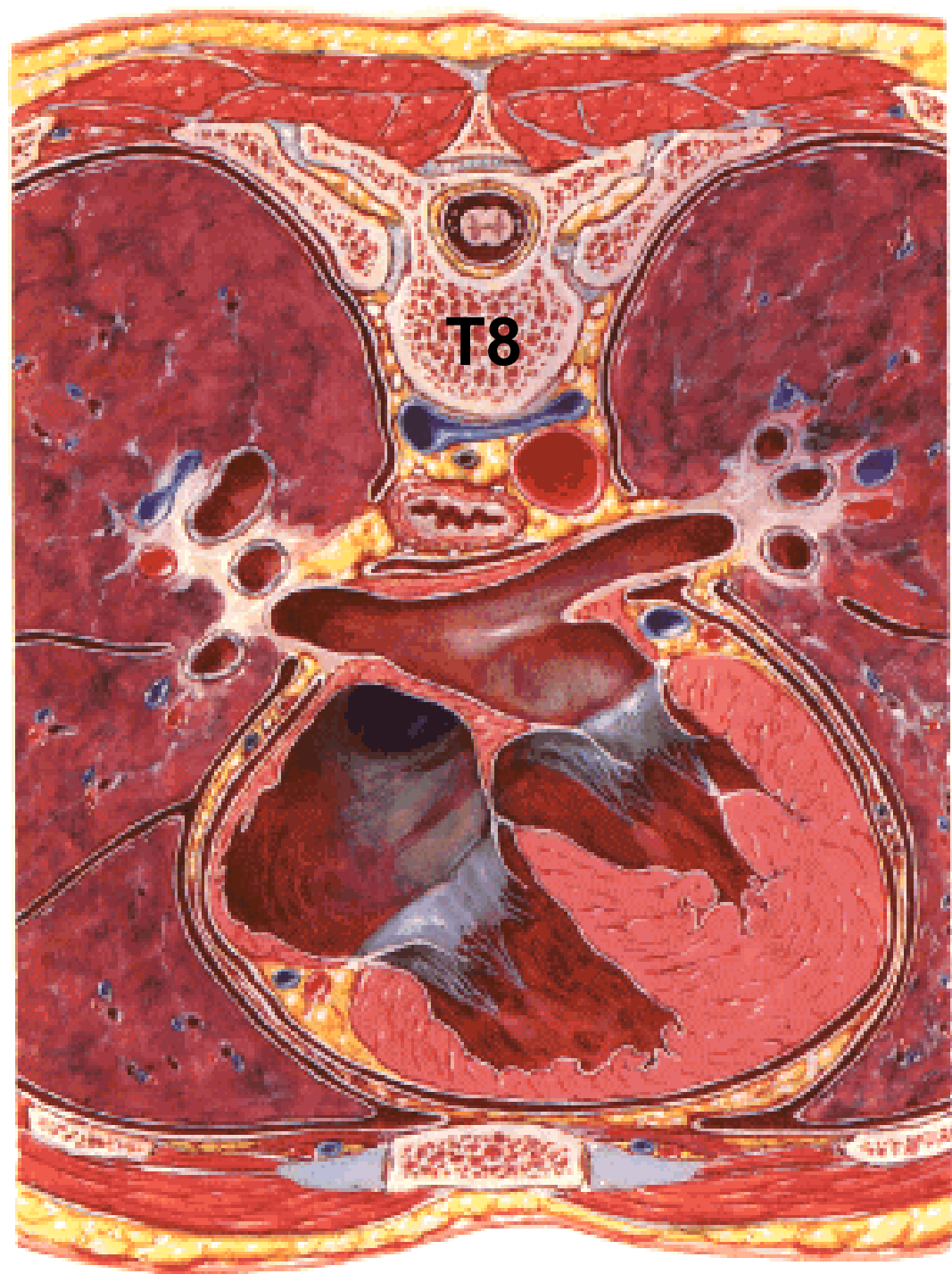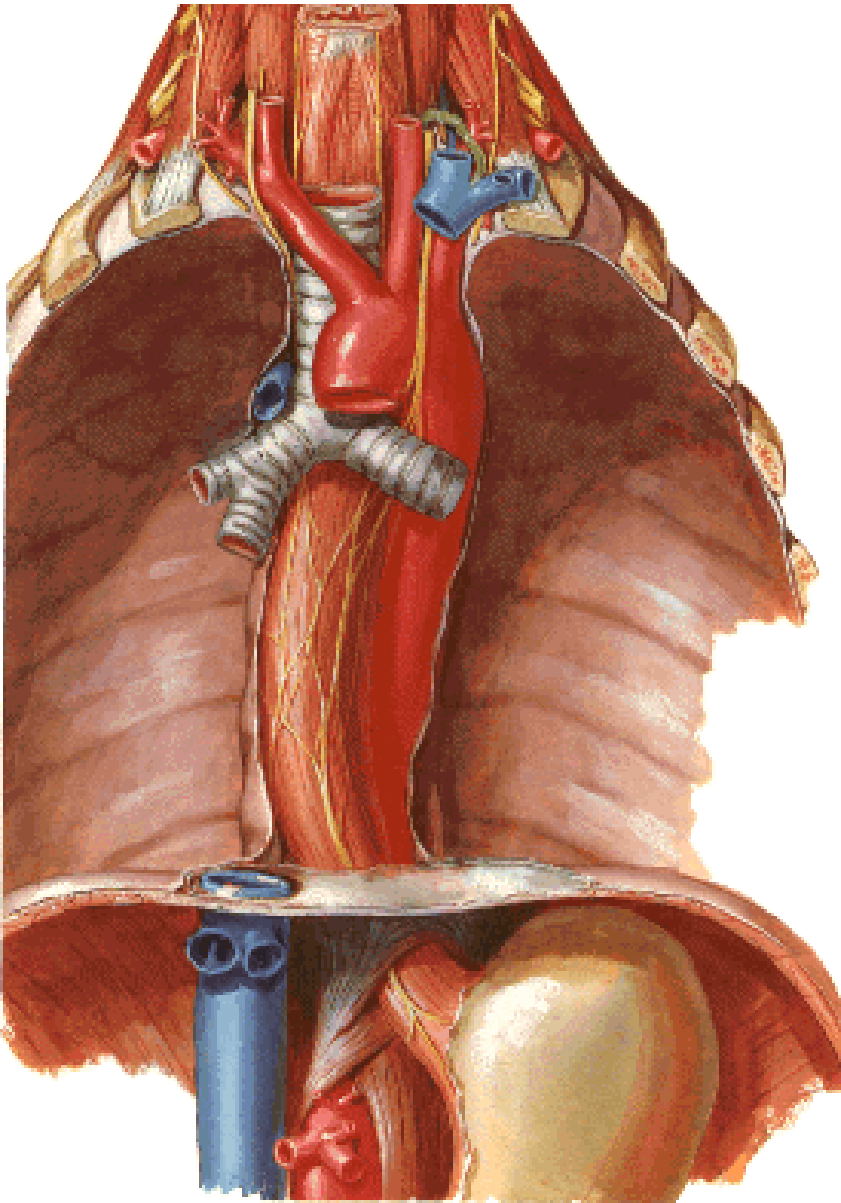
Sternal angle

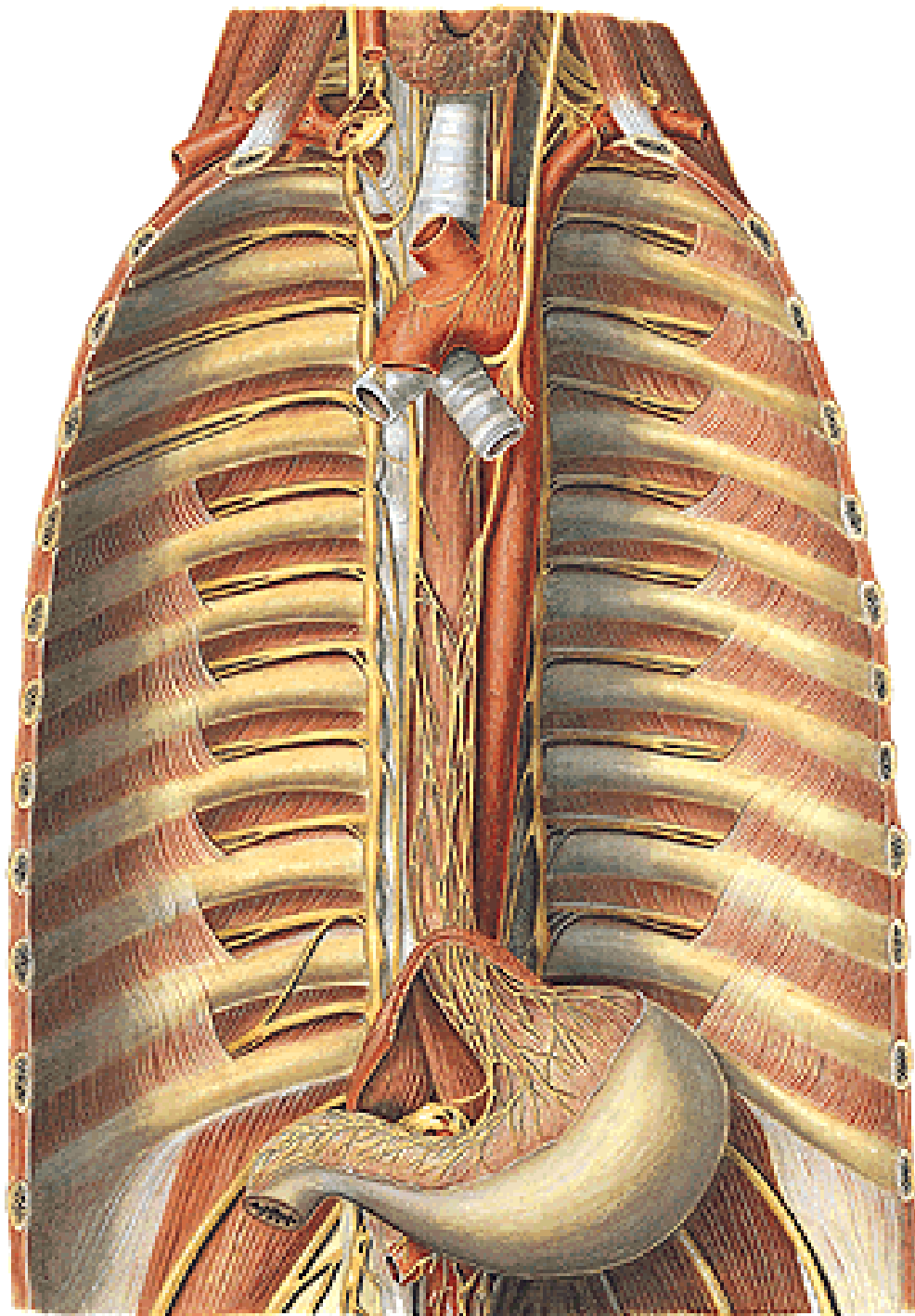


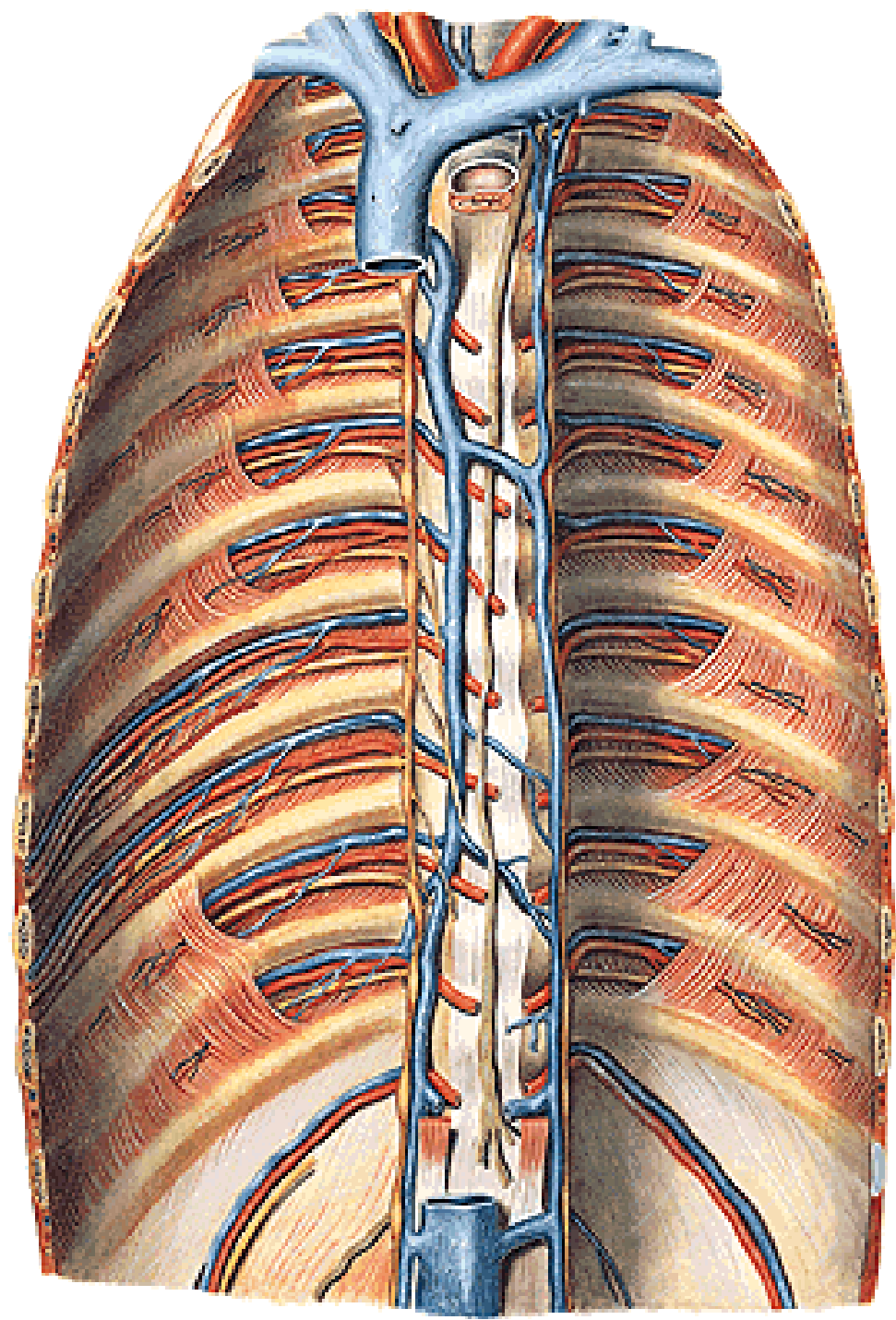
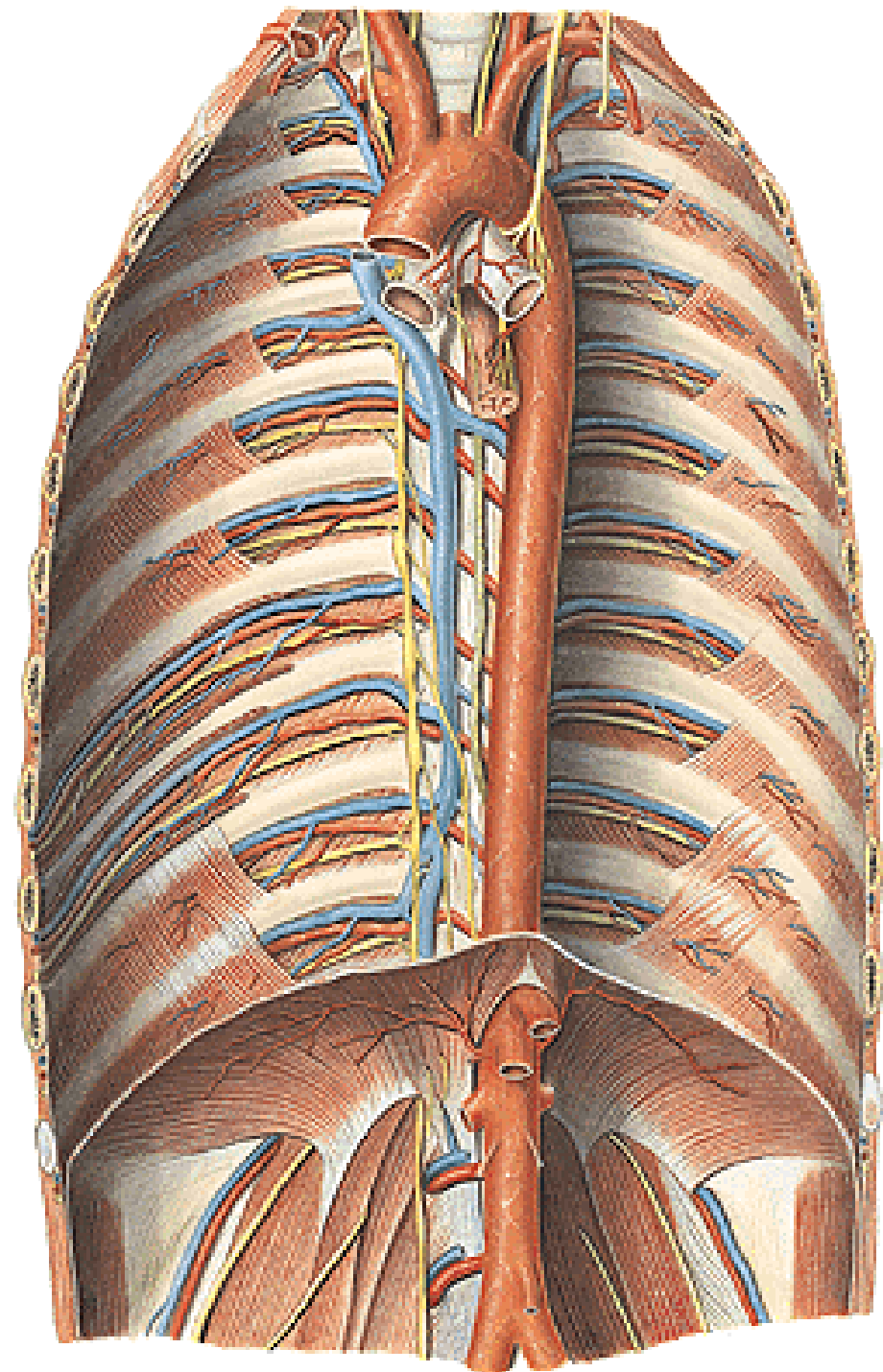


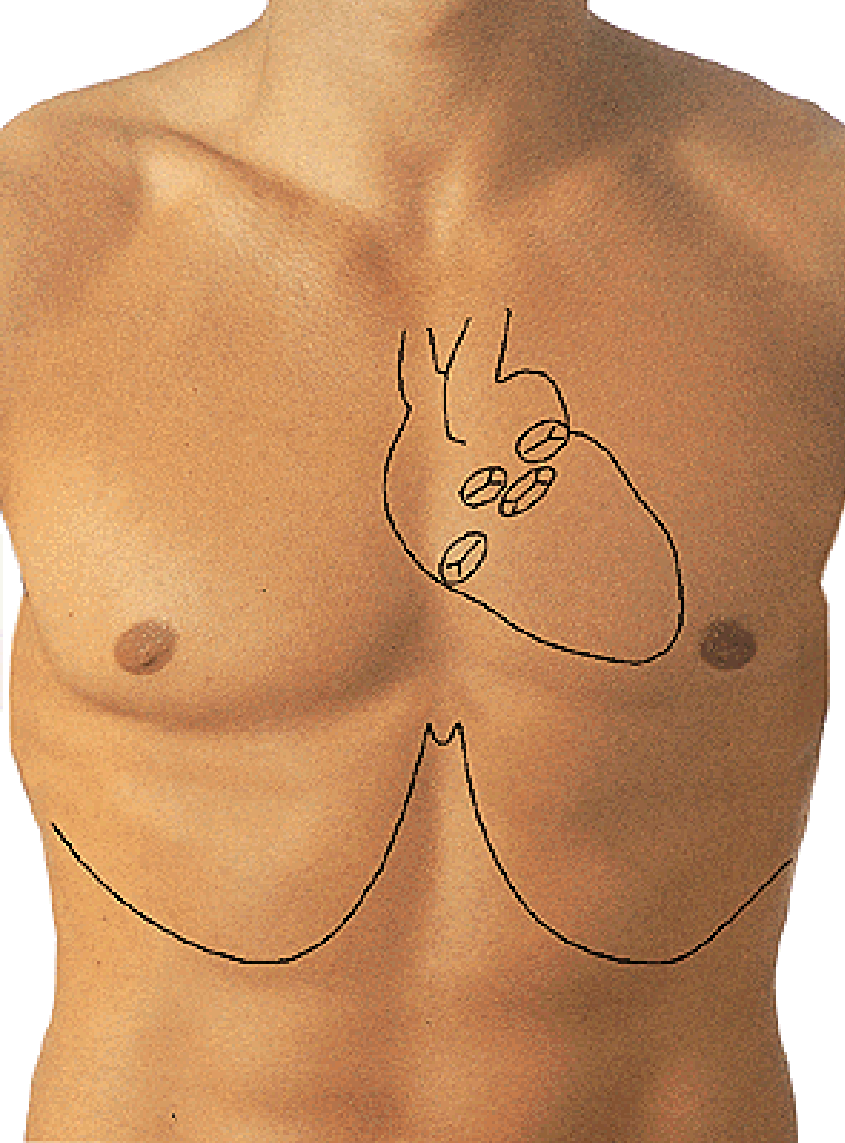










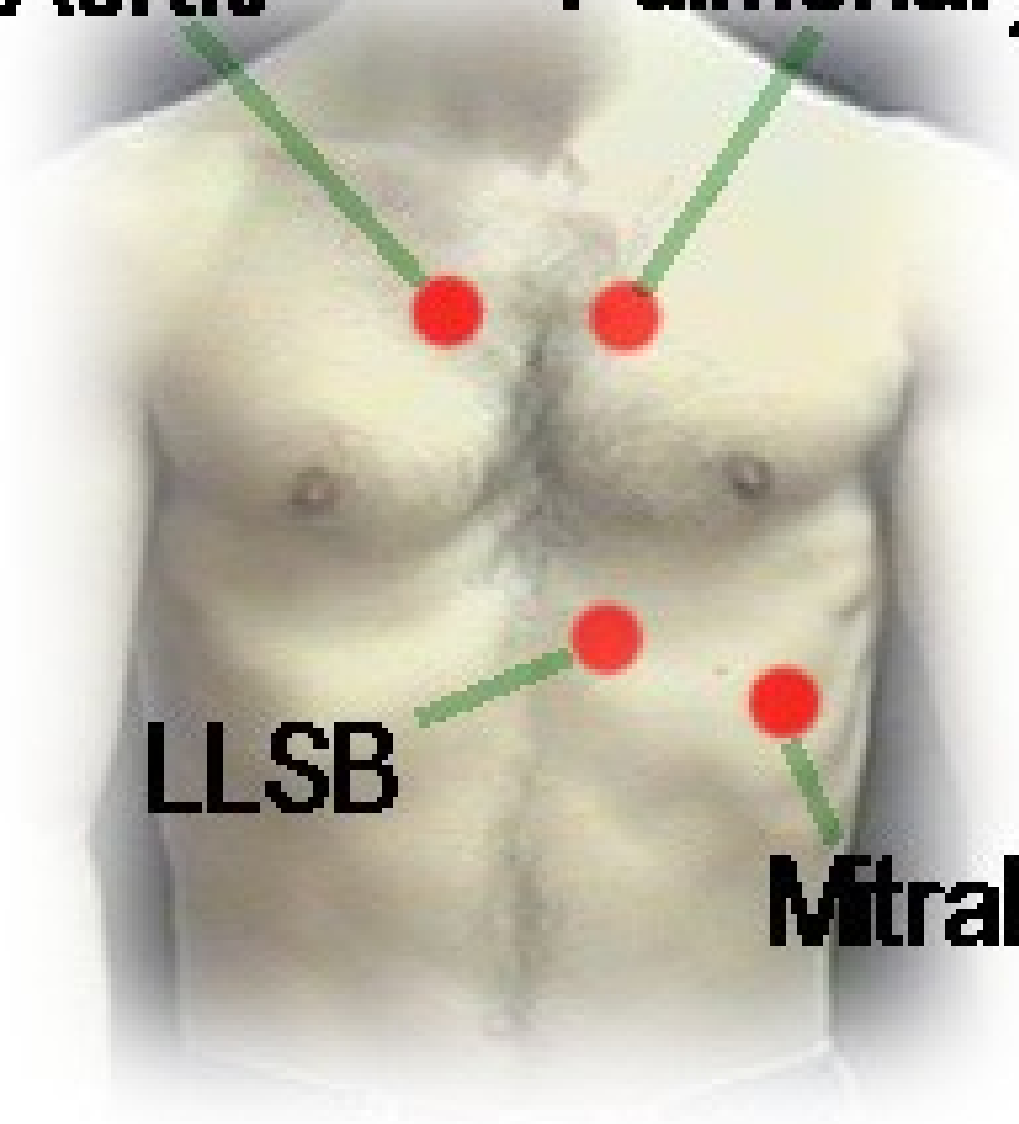


Aortic

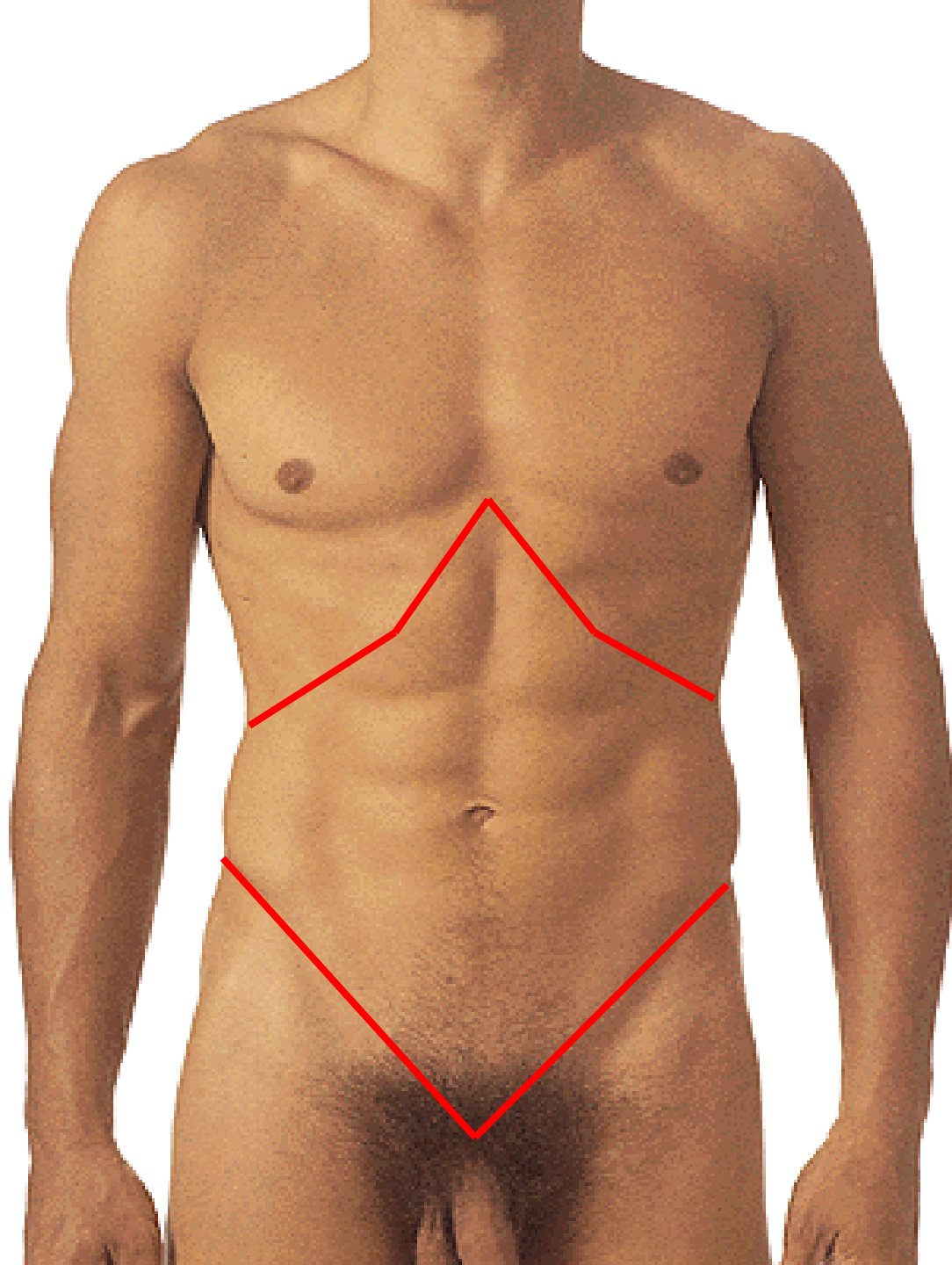
Pulmonary

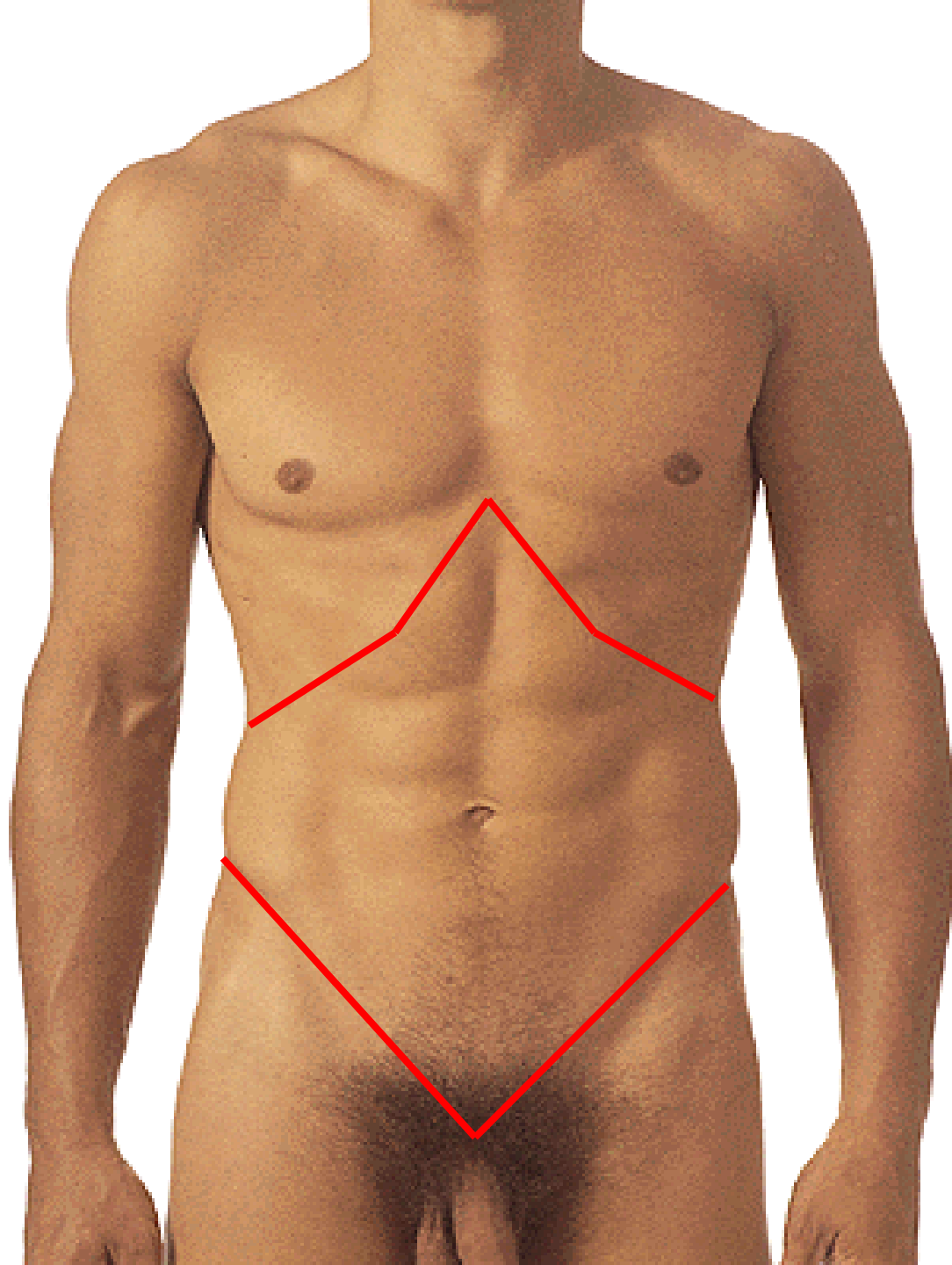
LLSB

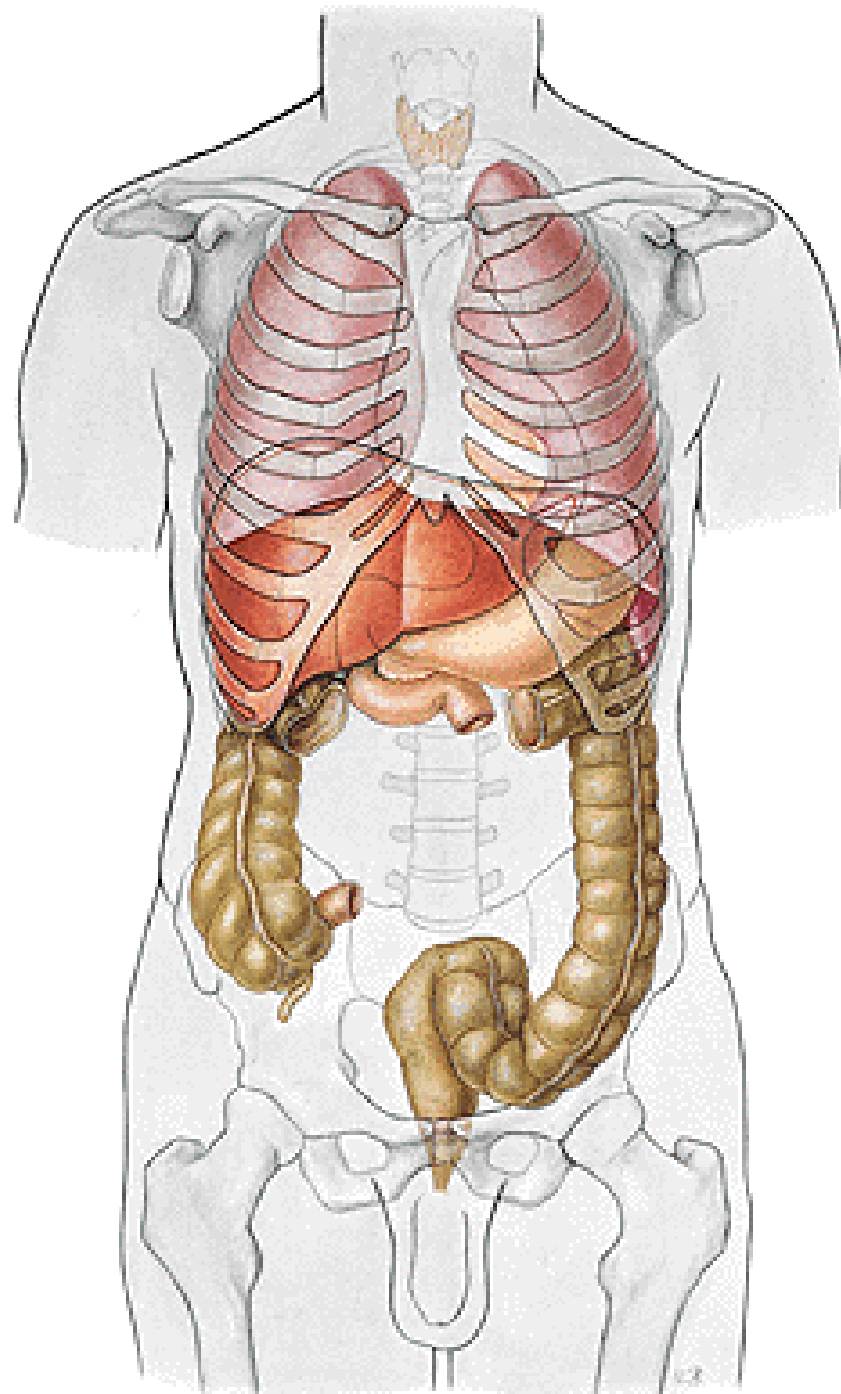
Mitral



REGIONAL ANATOMY OF THE ABDOMEN

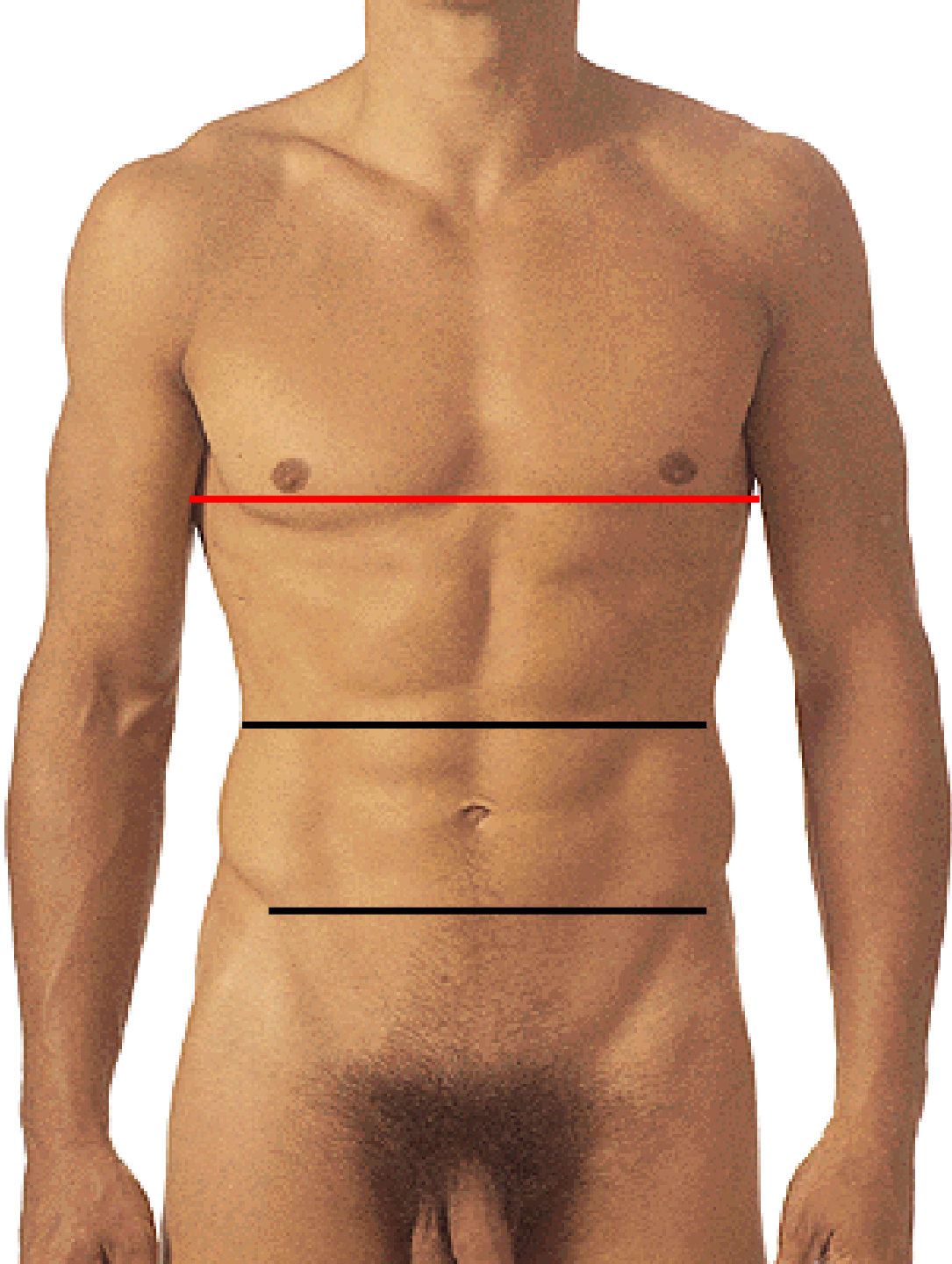




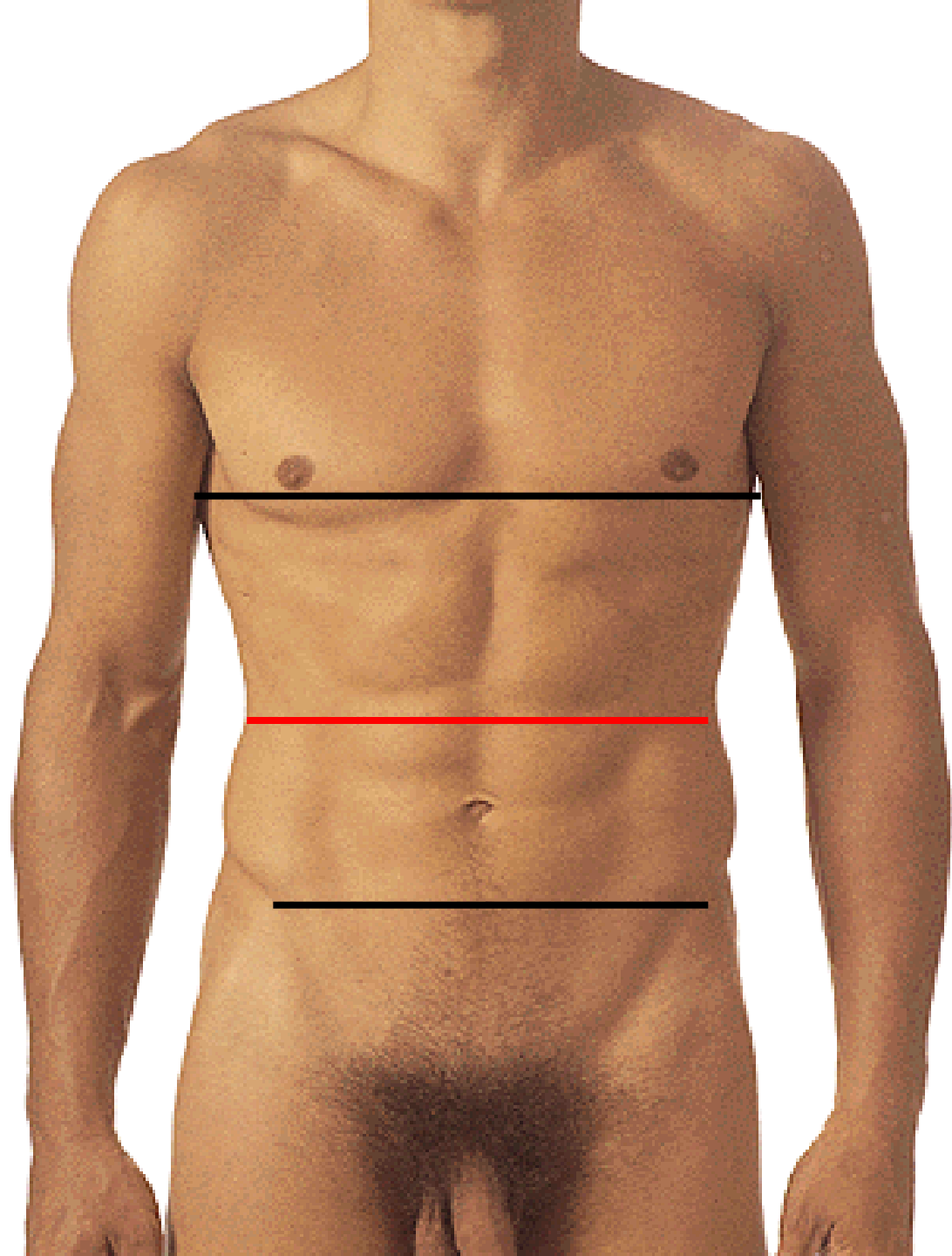




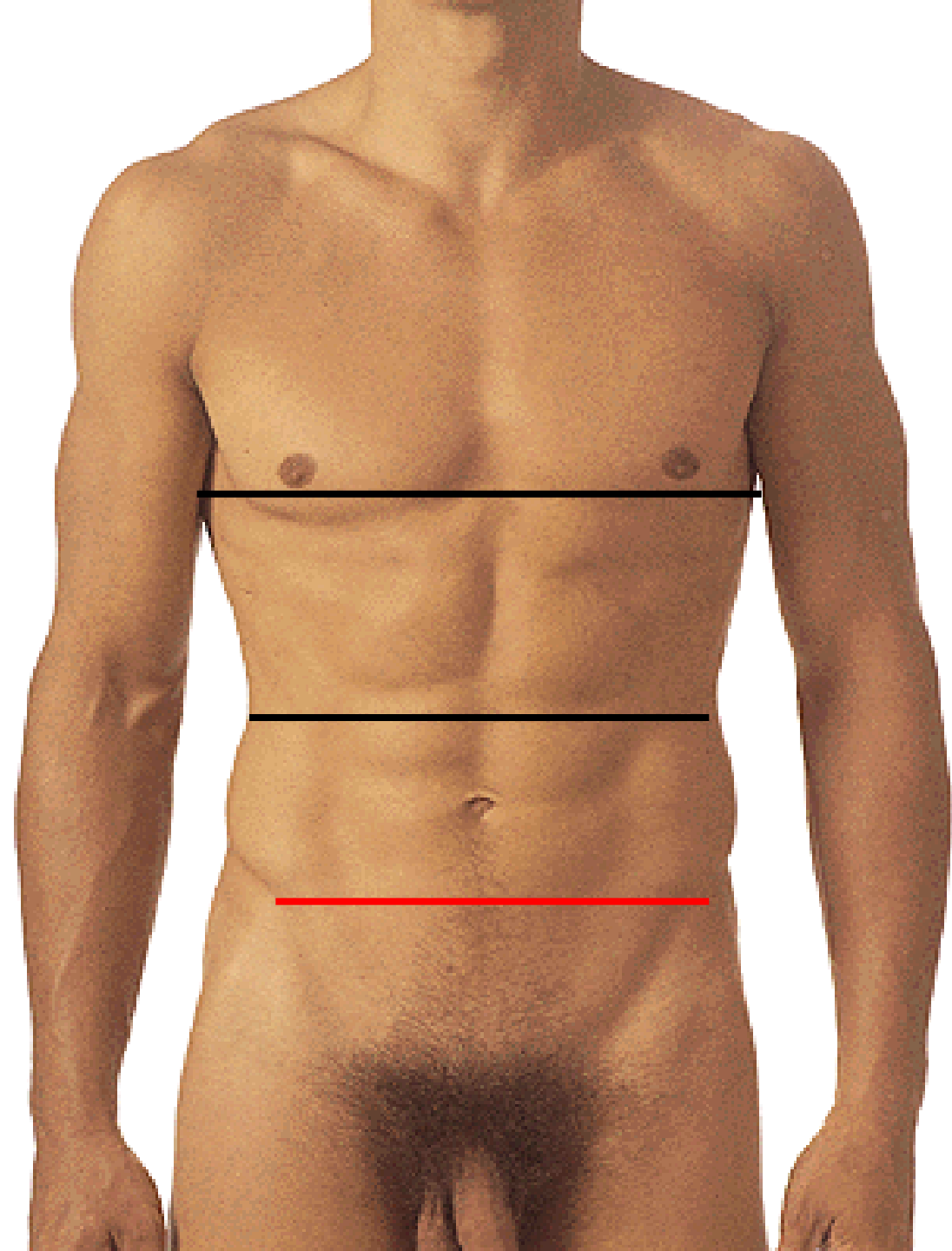
LINEA XIPHISTERNALIS



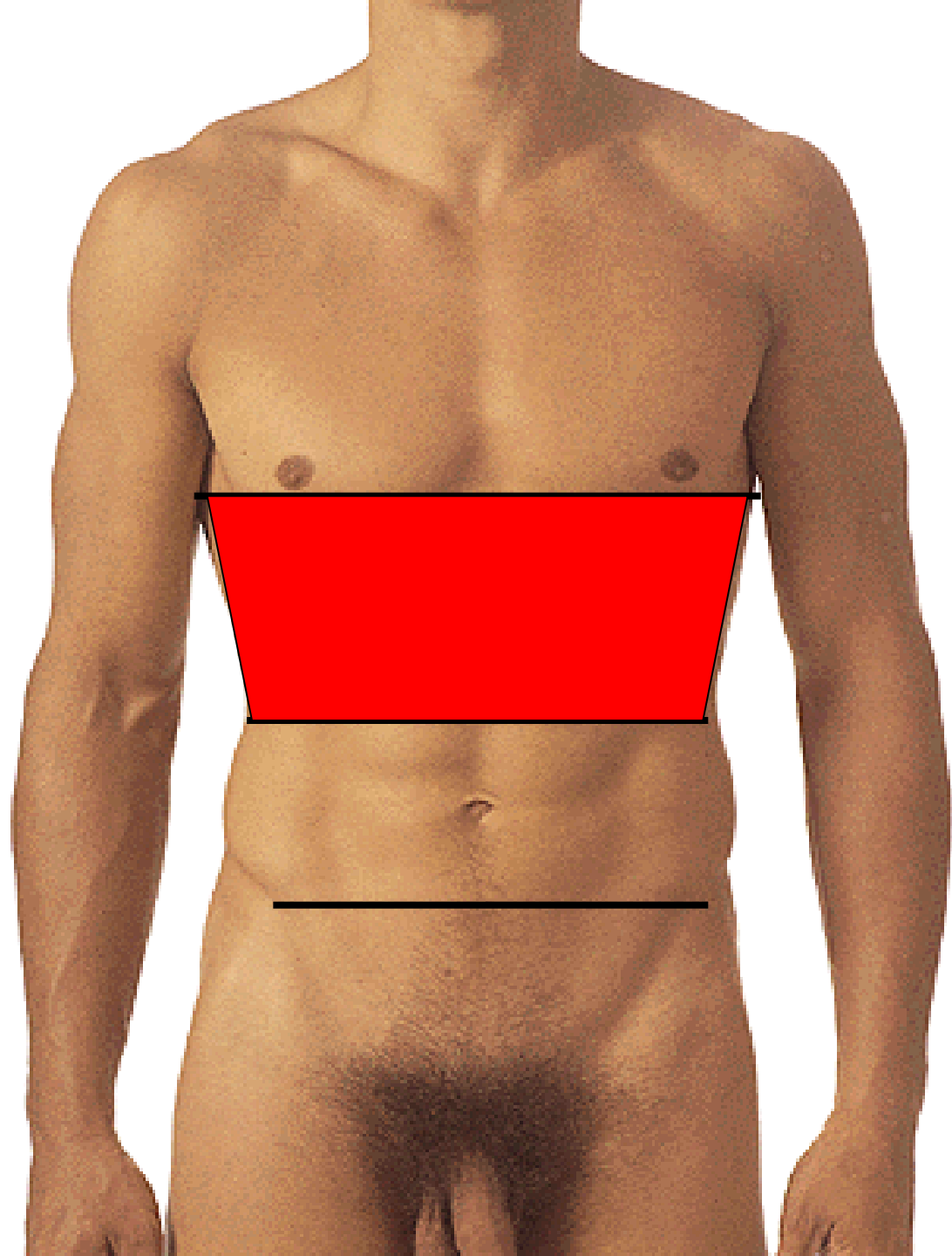
LINEA SUBCOSTALIS



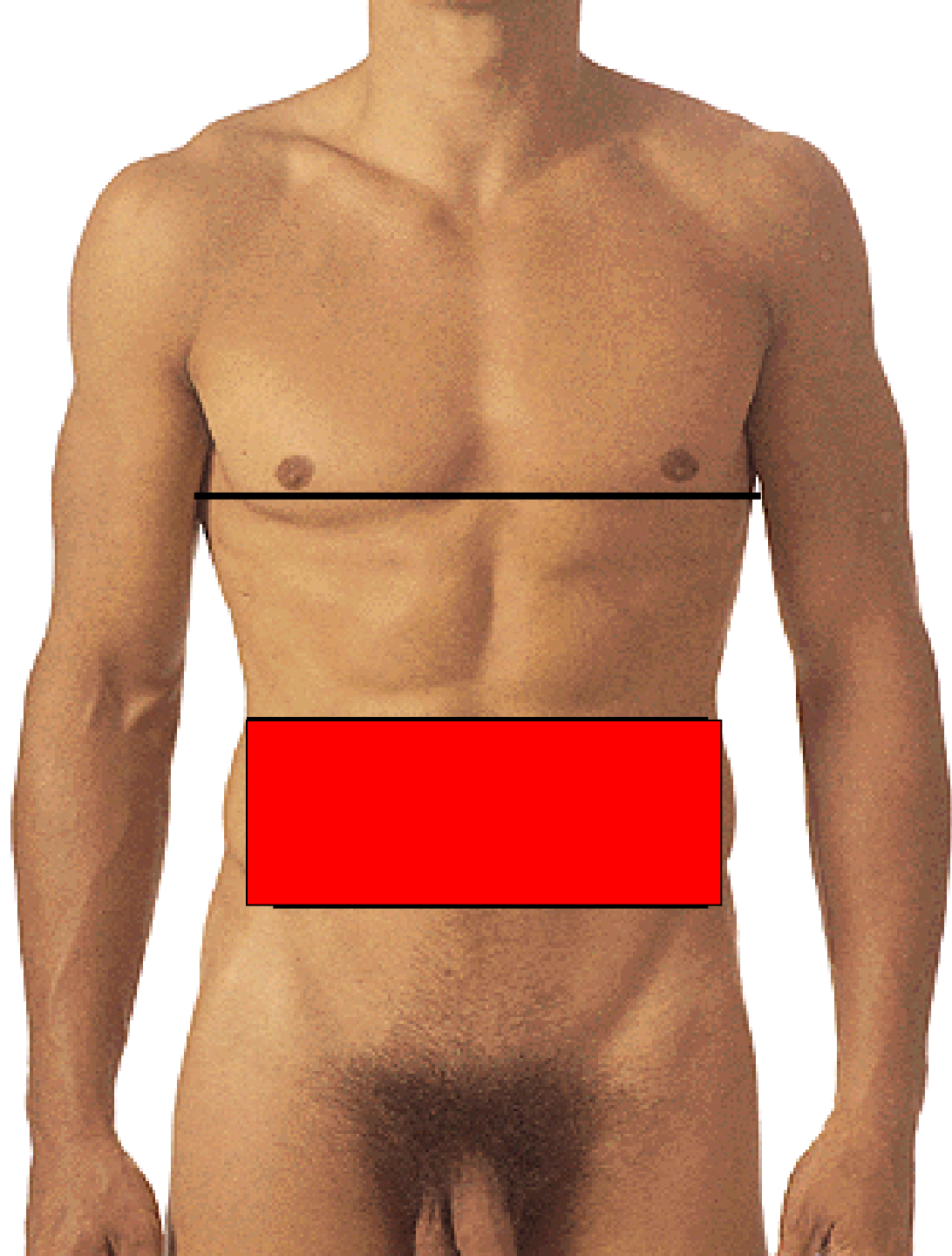
LINEA INTERSPINALIS



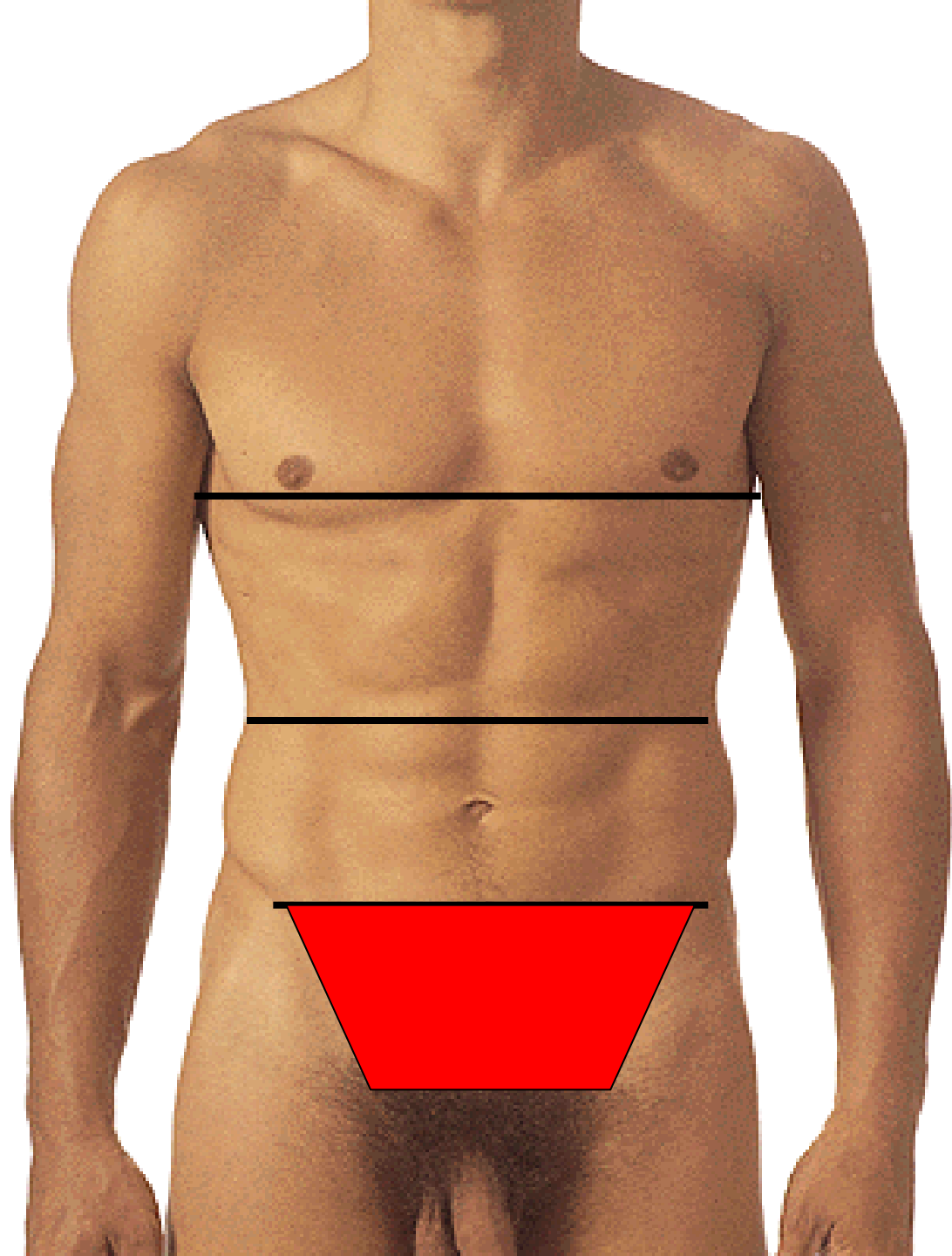
EPIGASTRIUM

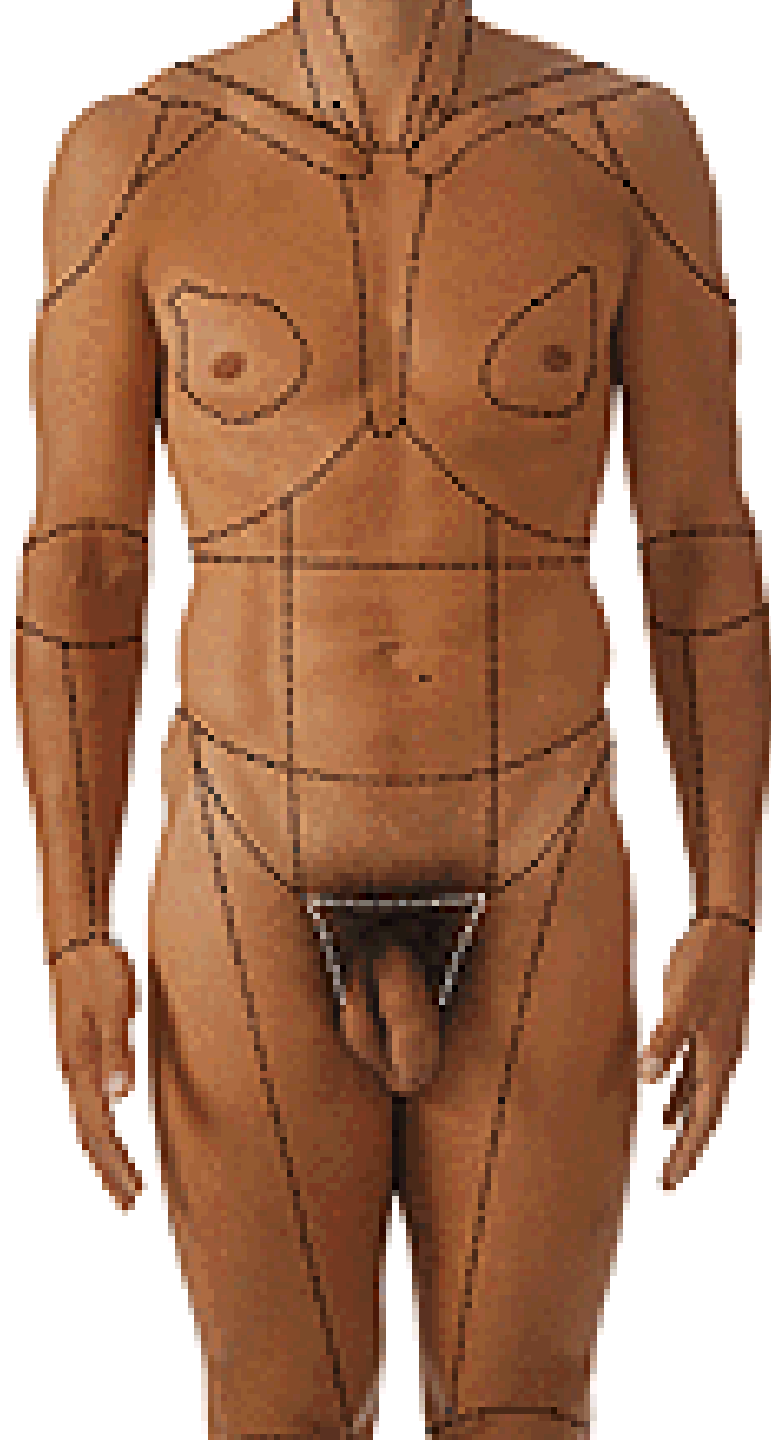


MESOGASTRIUM

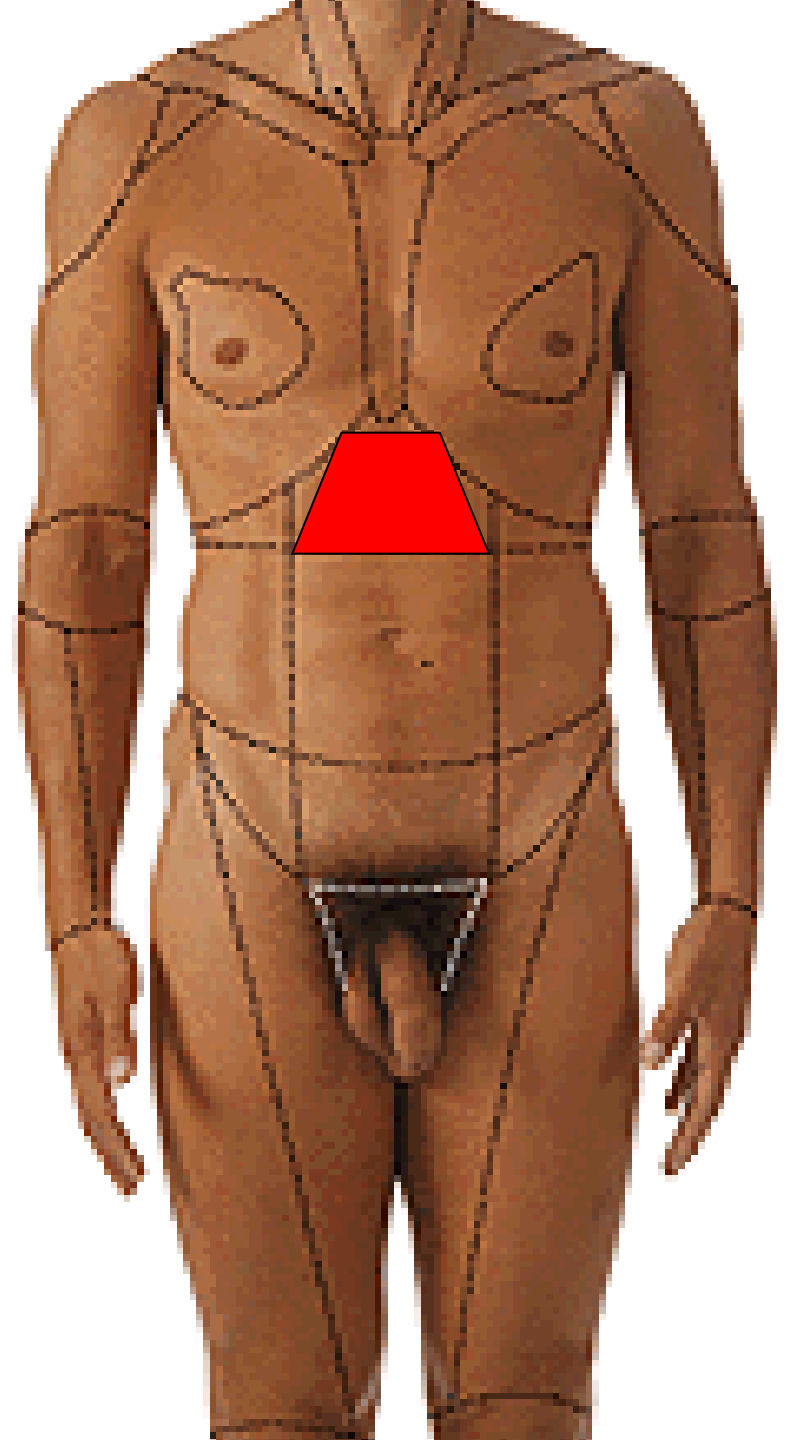


HYPOGASTRIUM

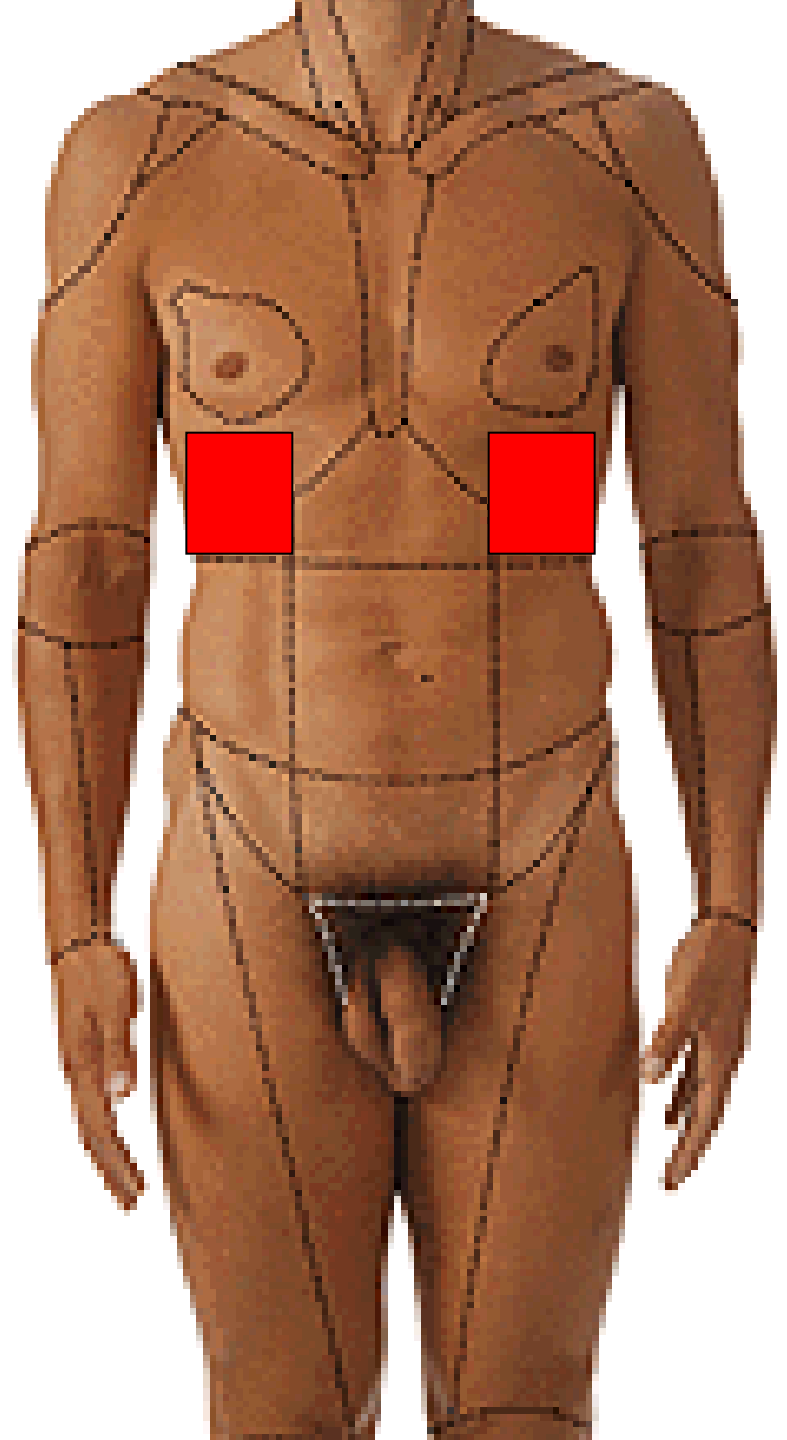




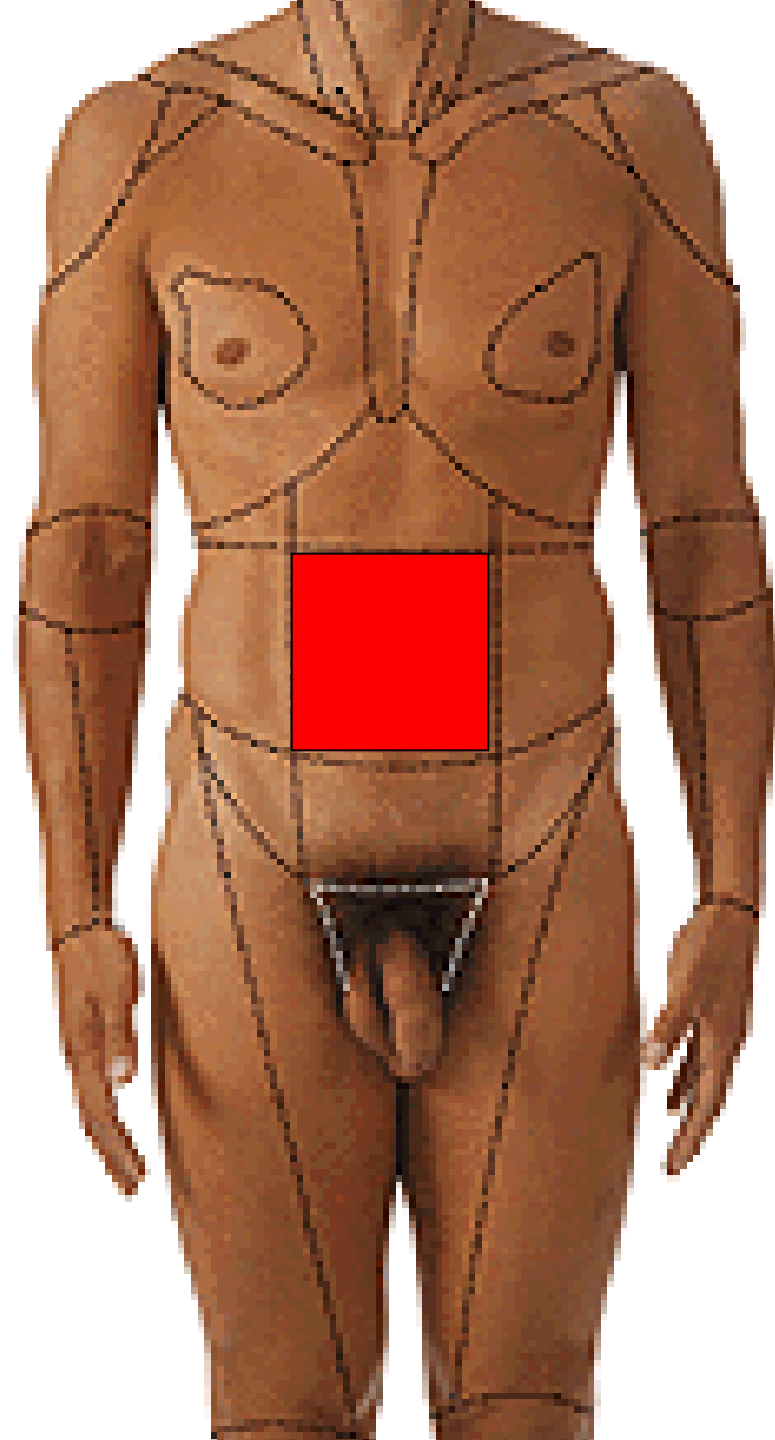
REGIO EPIGASTRICA



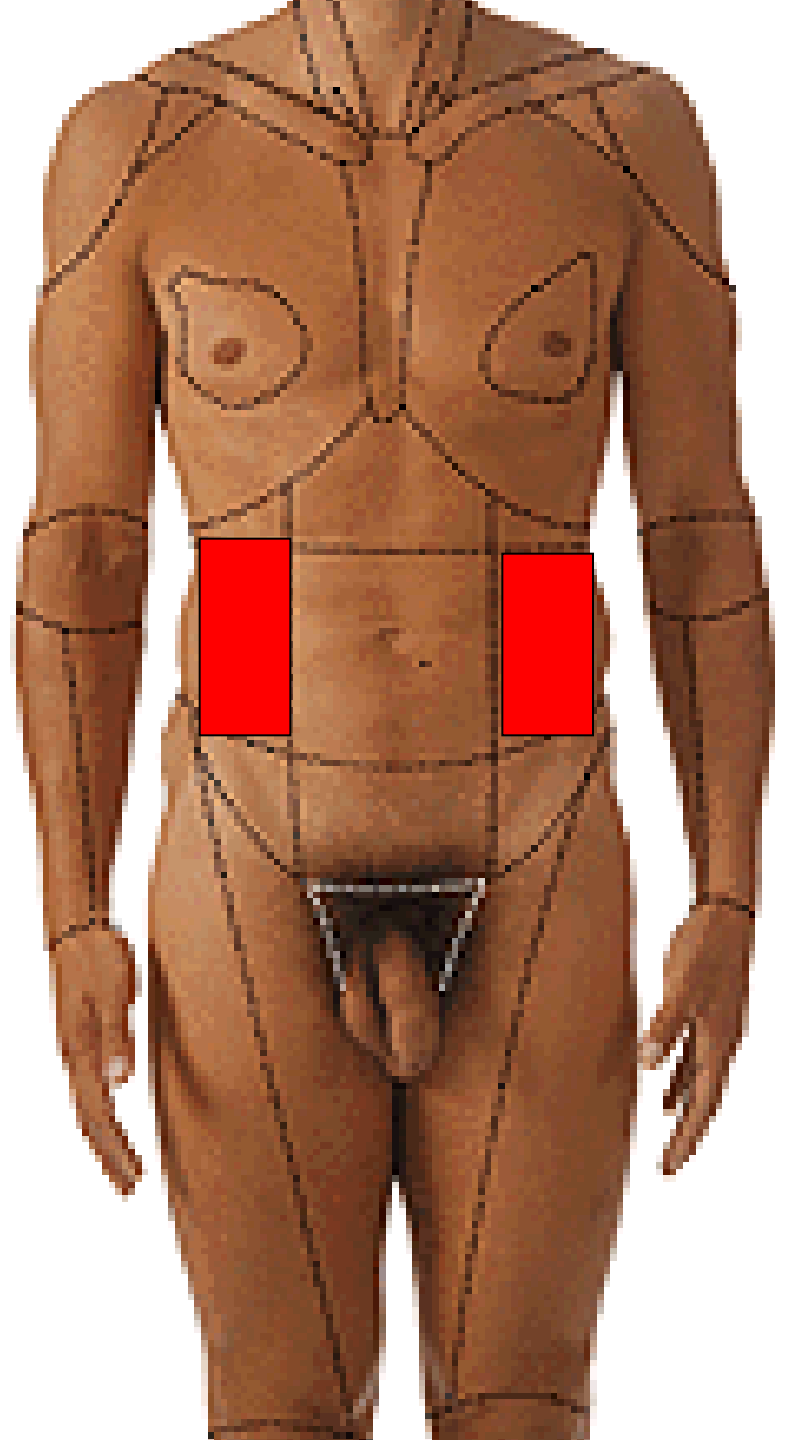
**REGIO HYPOCHONDRIACA
DEXTRA ET SINISTRA**



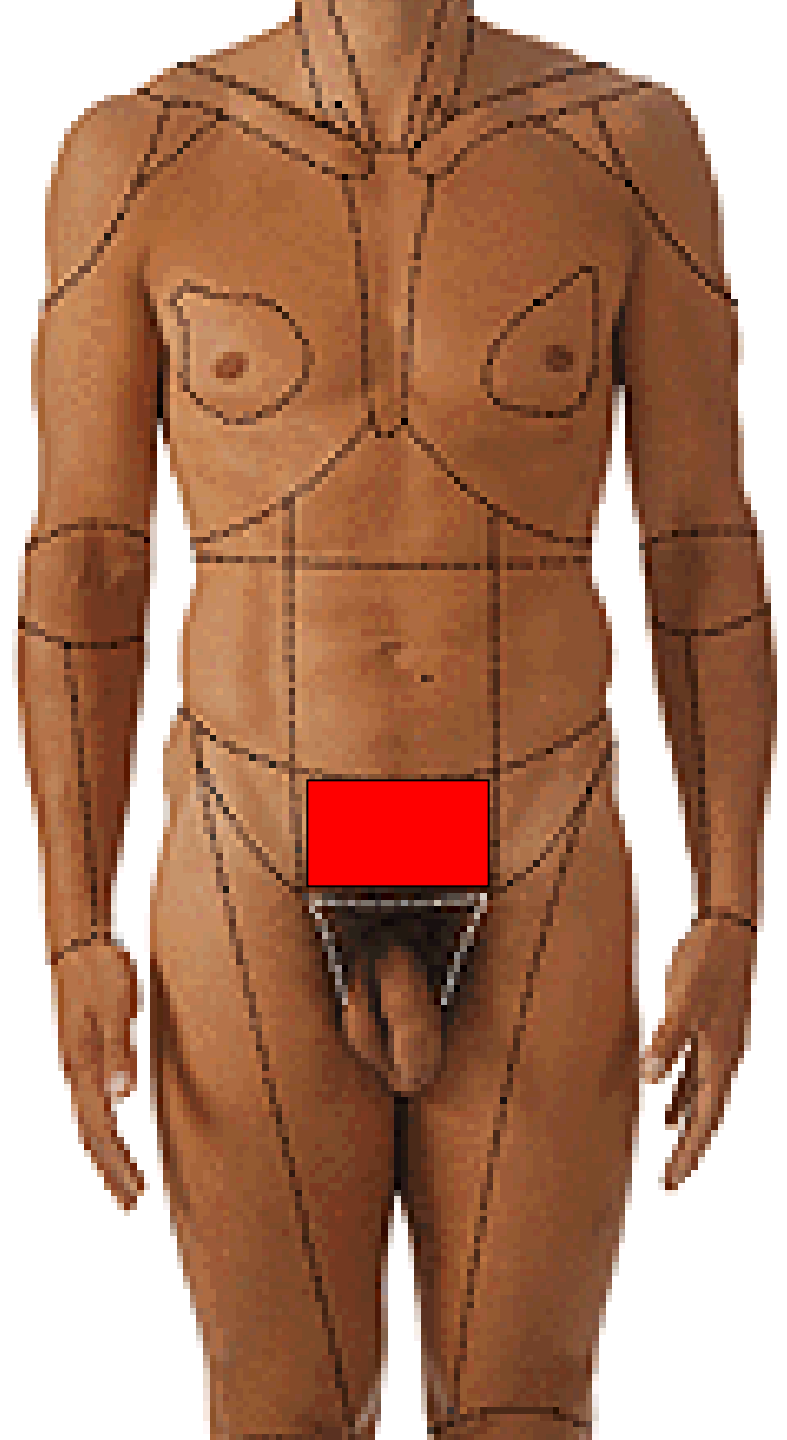
REGIO UMBILICALIS



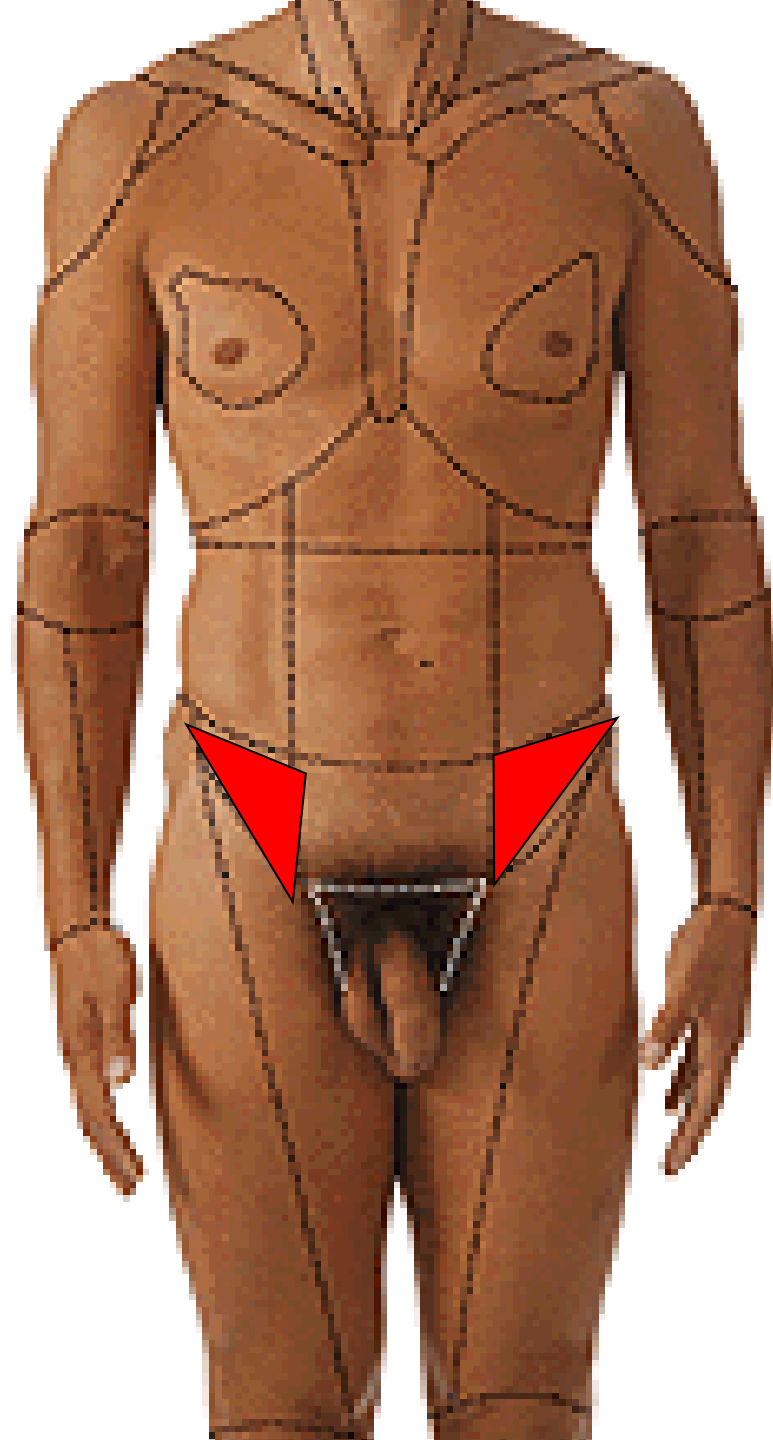
**REGIO LATERALIS
DEXTRA ET SINISTRA**



REGIO PUBICA



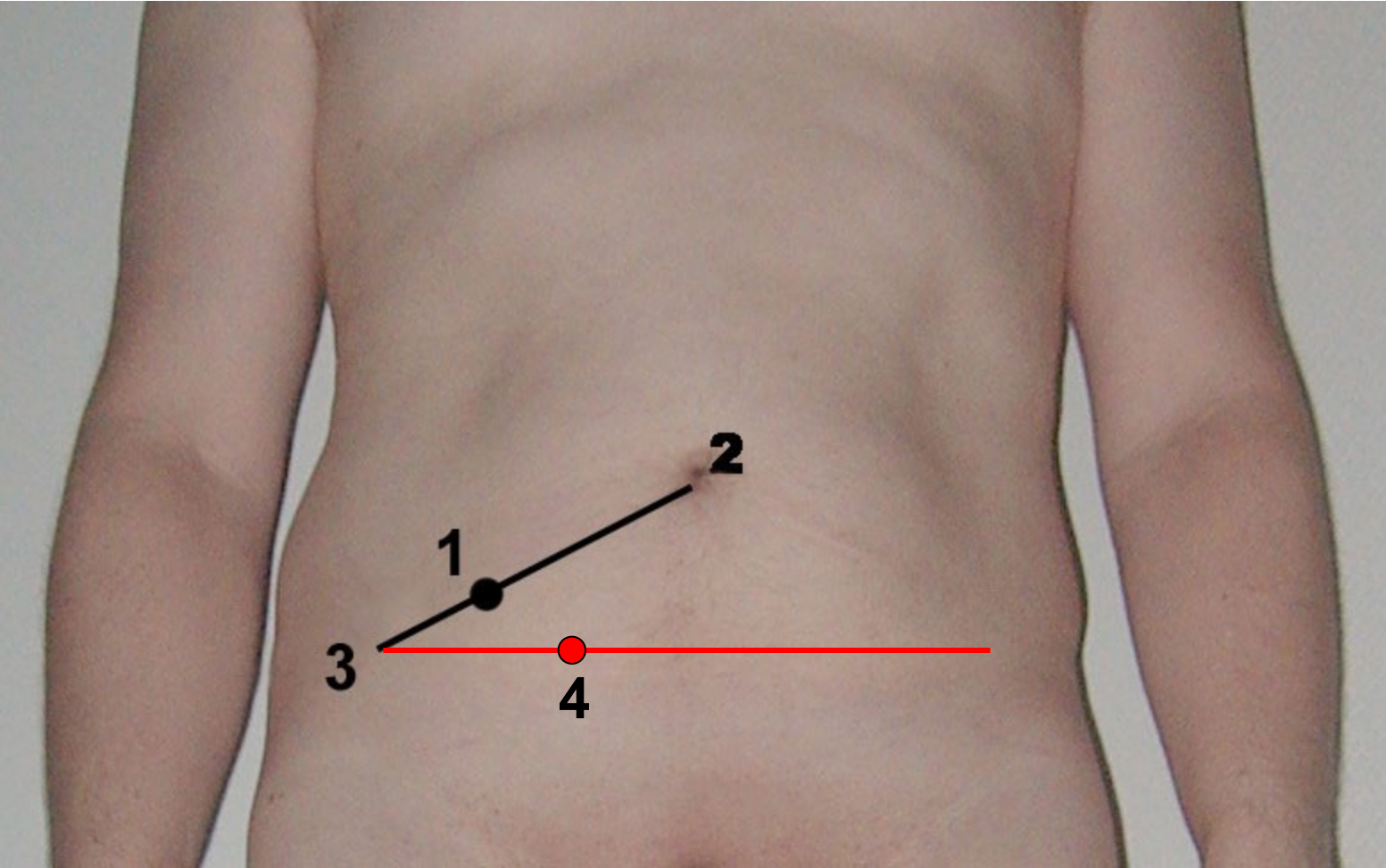
**REGIO INGUINALIS
DEXTRA ET SINISTRA**



**PROJECTION OF ORGANS
ONTO THE ABDOMINAL
WALL**

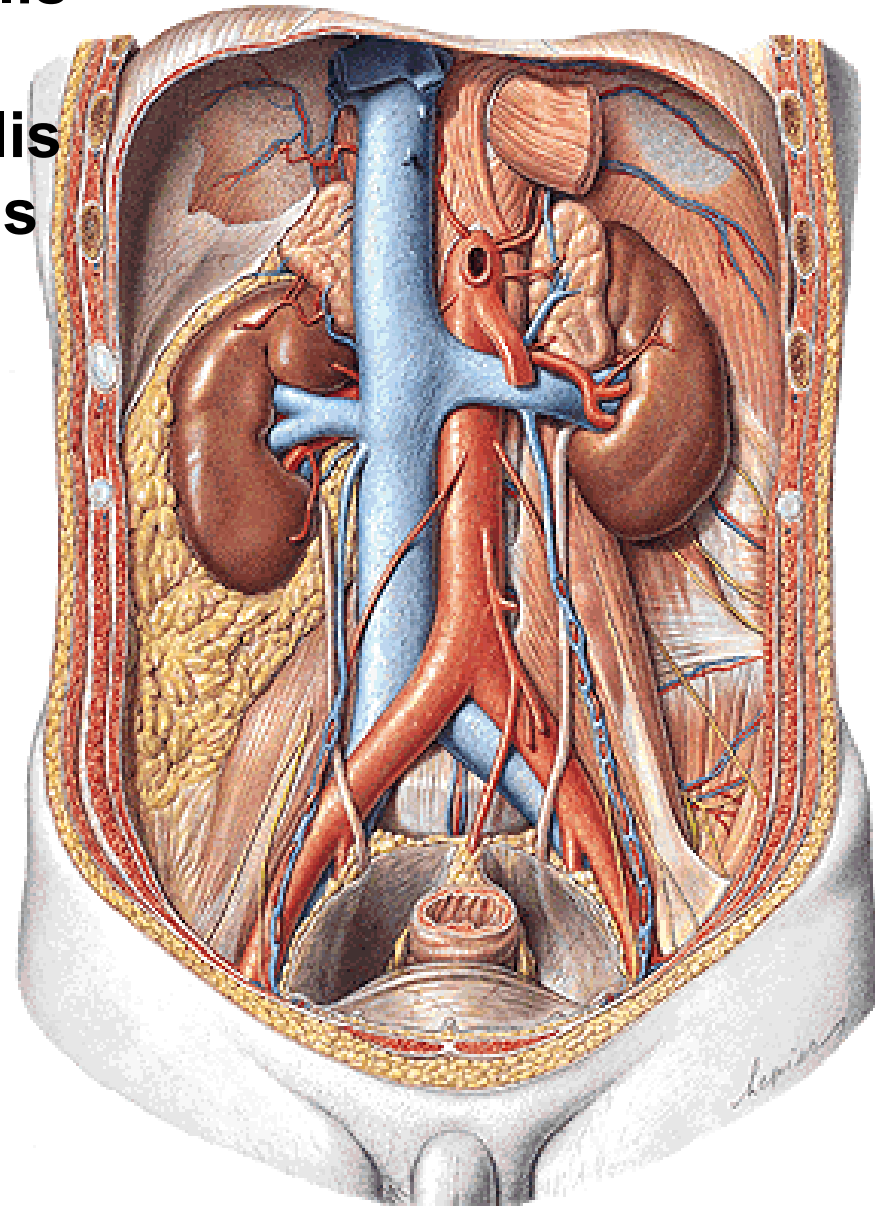
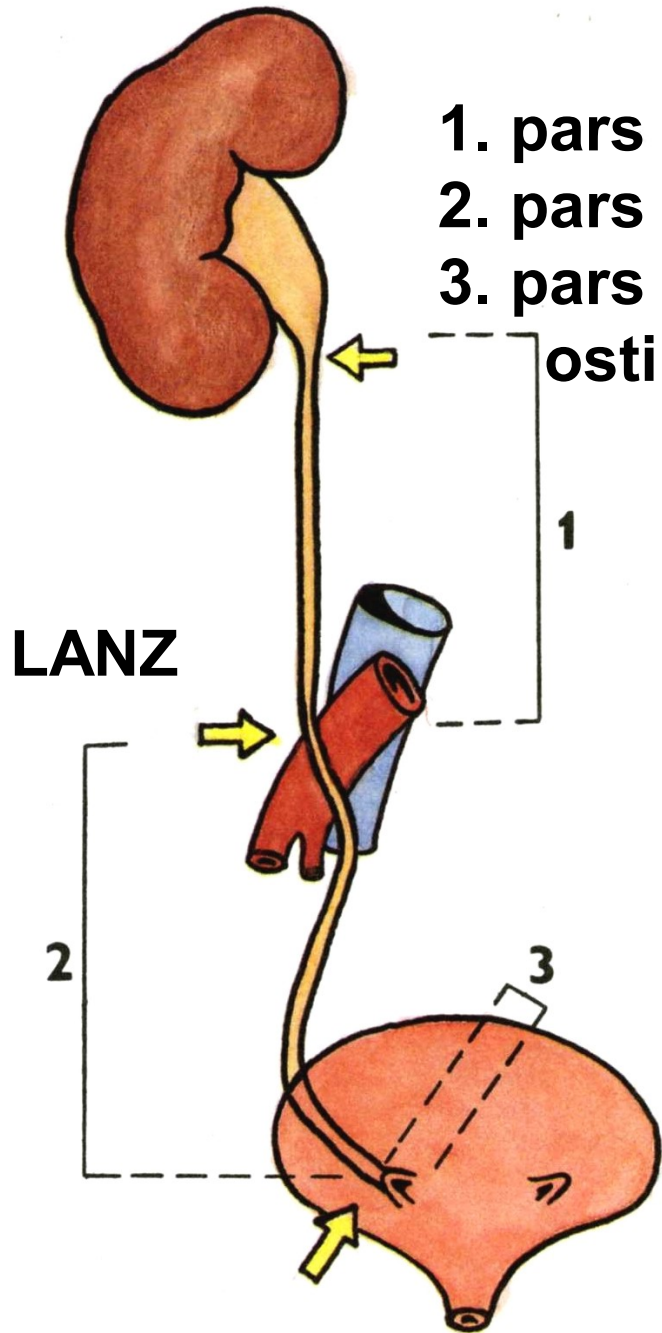
McBurney's point

Lanz's point

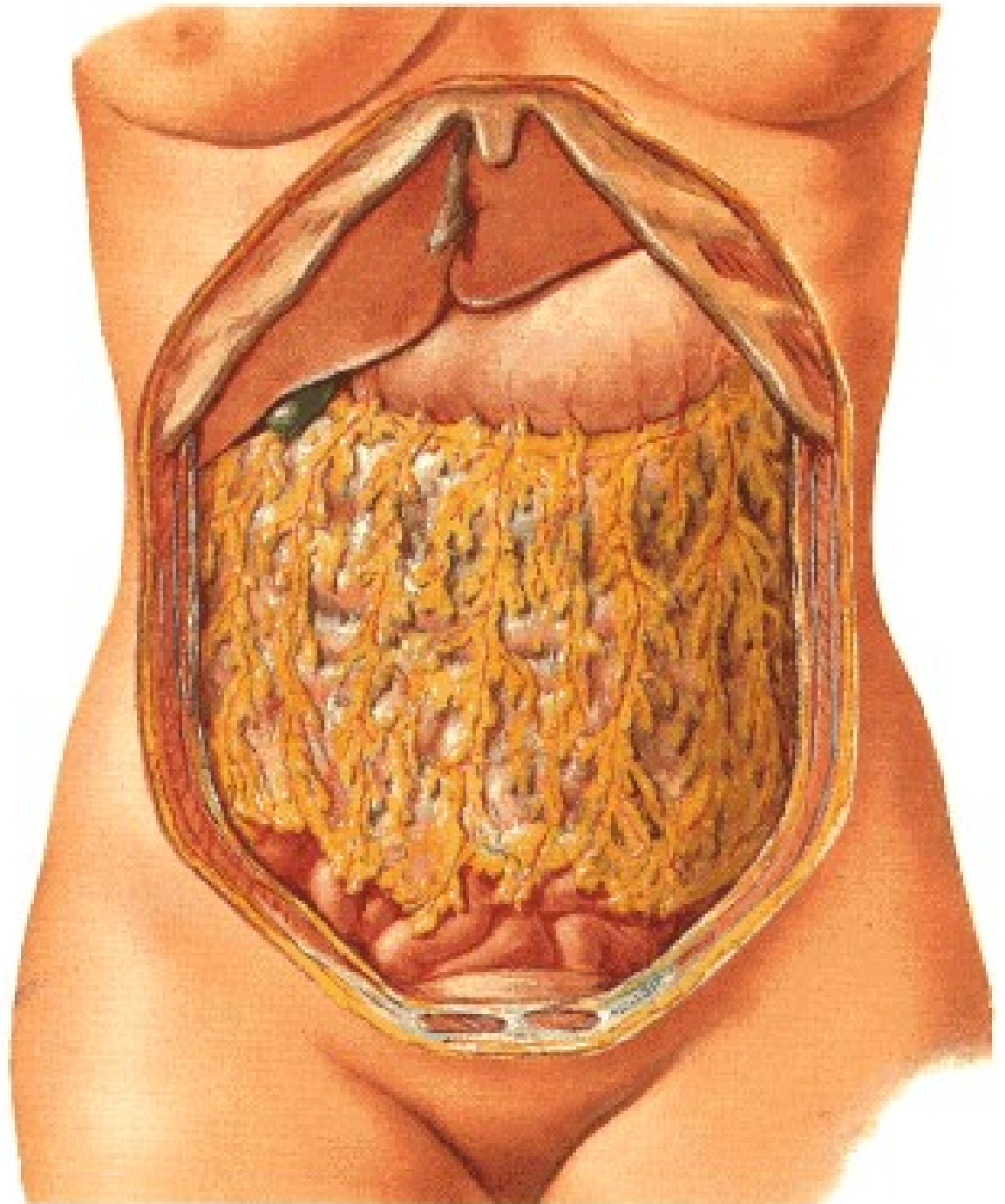


URETER

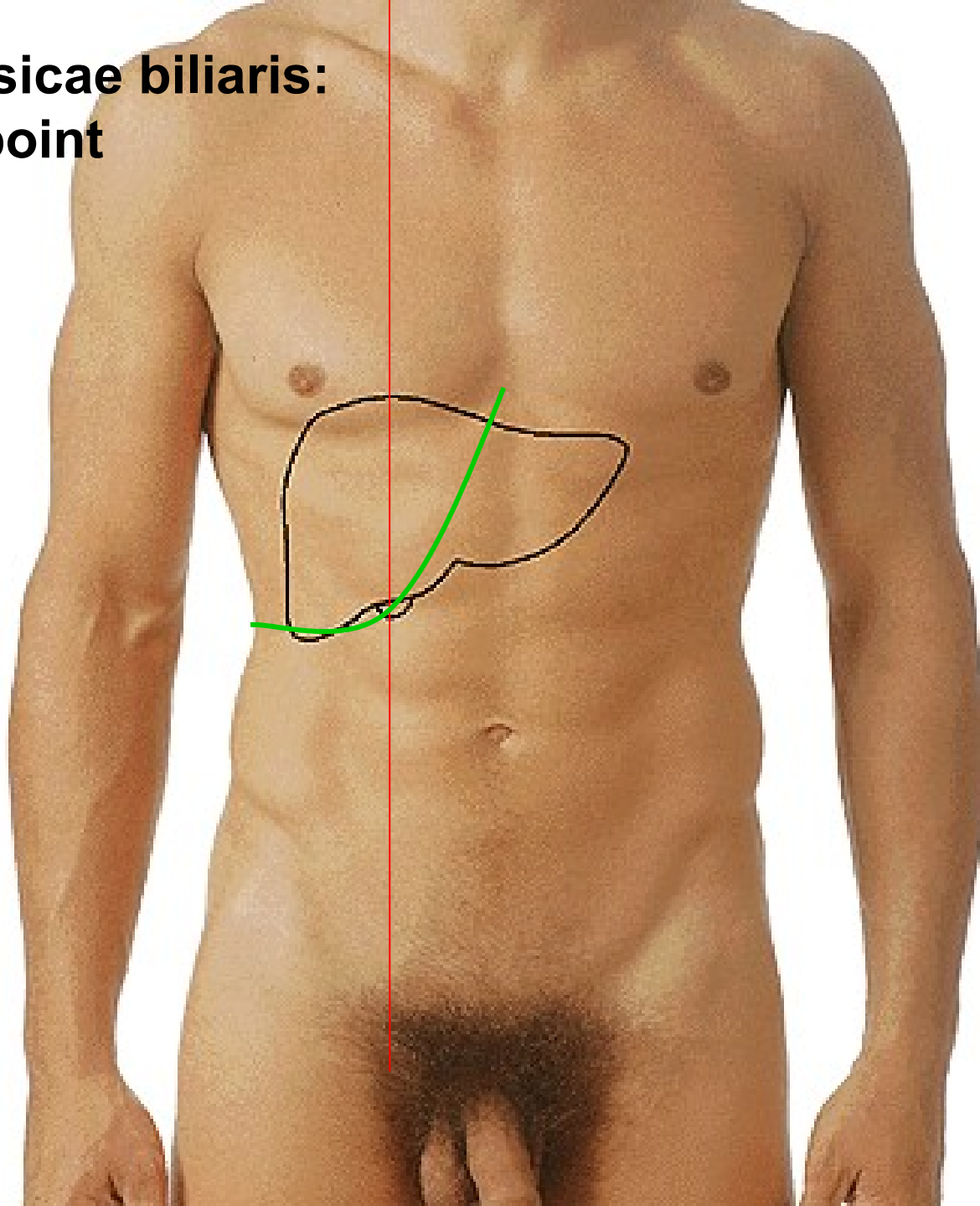
1. pars abdominalis
 2. pars pelvina
 3. pars intramuralis
- ostium ureteris



Labbe's triangle



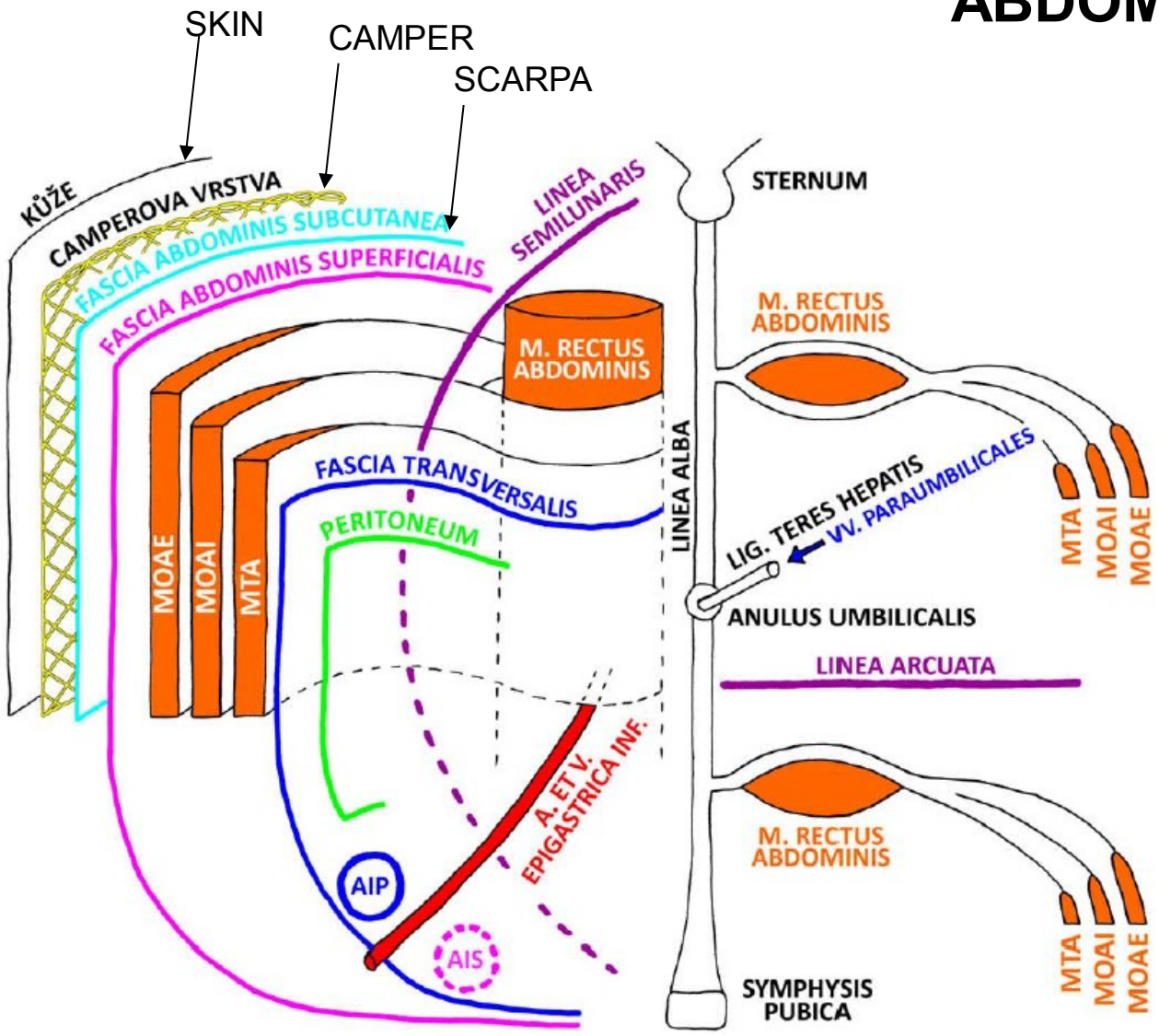
**Fundus vesicae biliaris:
Murphy's point**



ABDOMINAL WALL

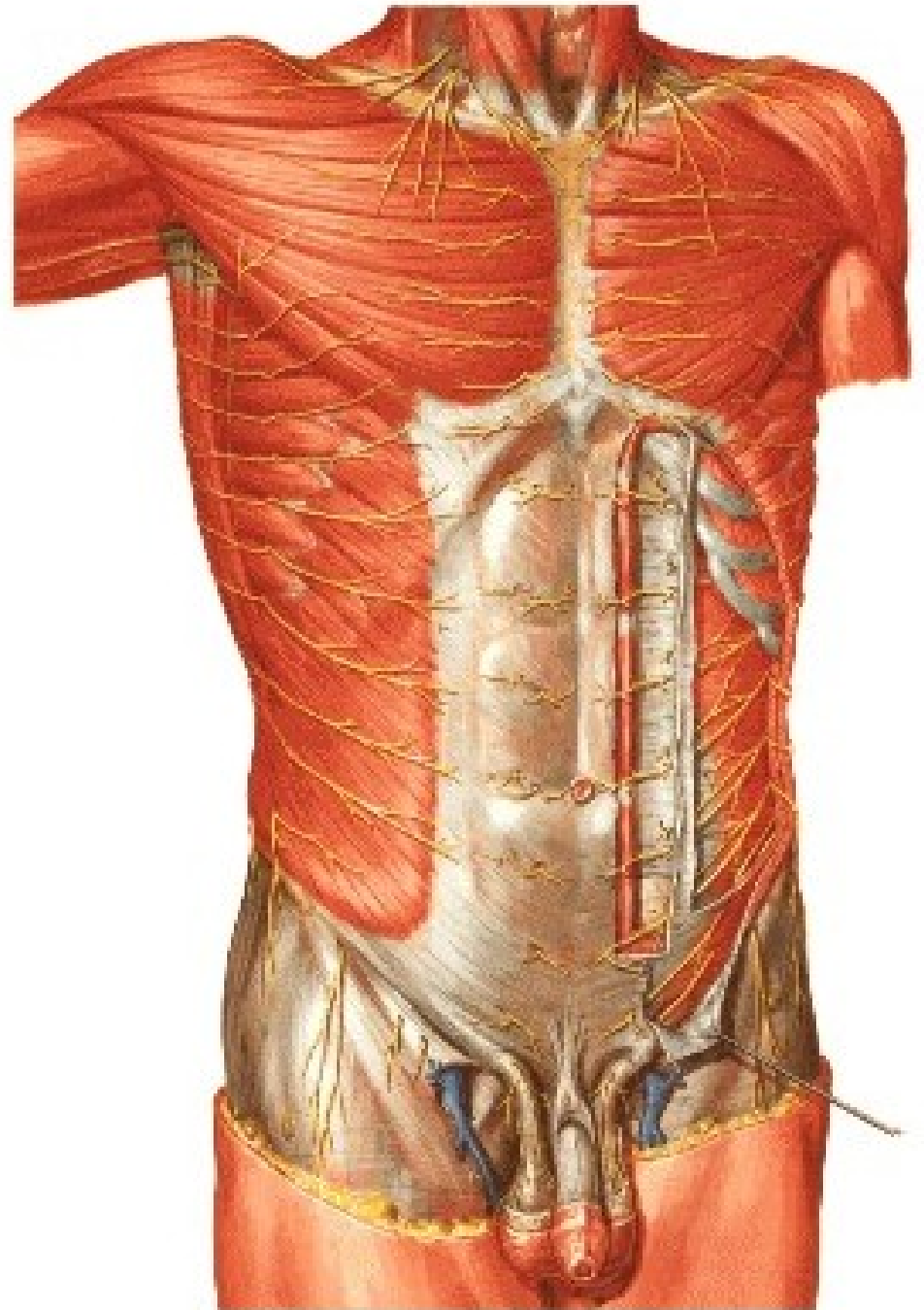


ABDOMINAL WALL

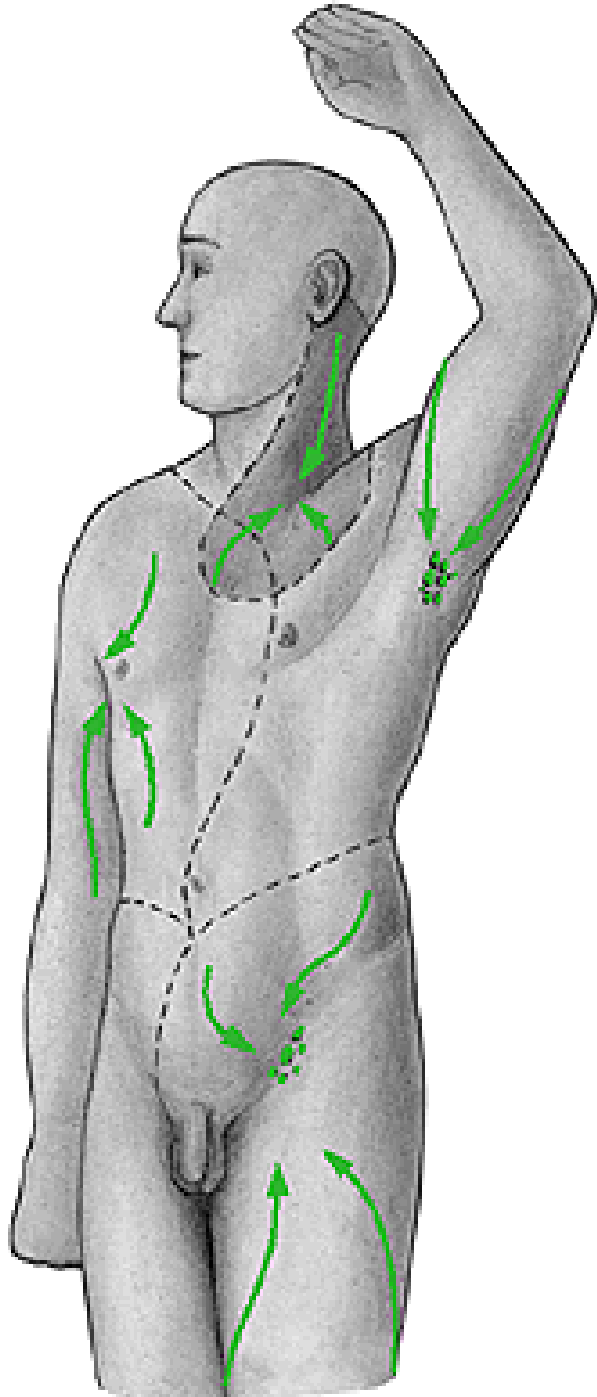


MOAE - M. OBLIQUUS ABDOMINIS EXTERNUS
MOAI - M. OBLIQUUS ABDOMINIS INTERNUS
MTA - M. TRANSVERSUS ABDOMINIS
AIP - ANULUS INGUINALIS PROFUNDUS
AIS - ANULUS INGUINALIS SUPERFICIALIS

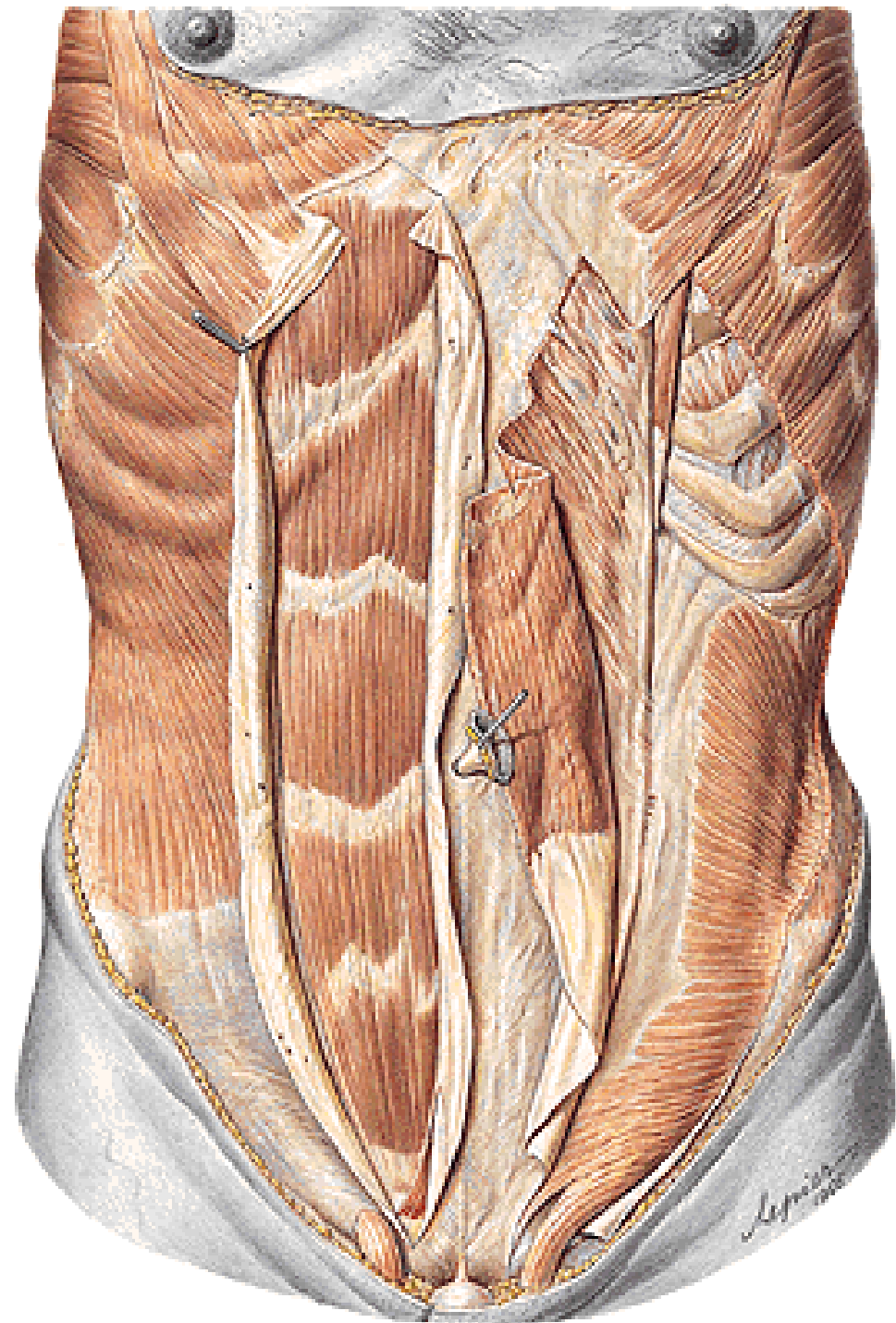
**NN. INTERCOSTALES
PLEXUS LUMBALIS
VASA INTERCOSTALIA**

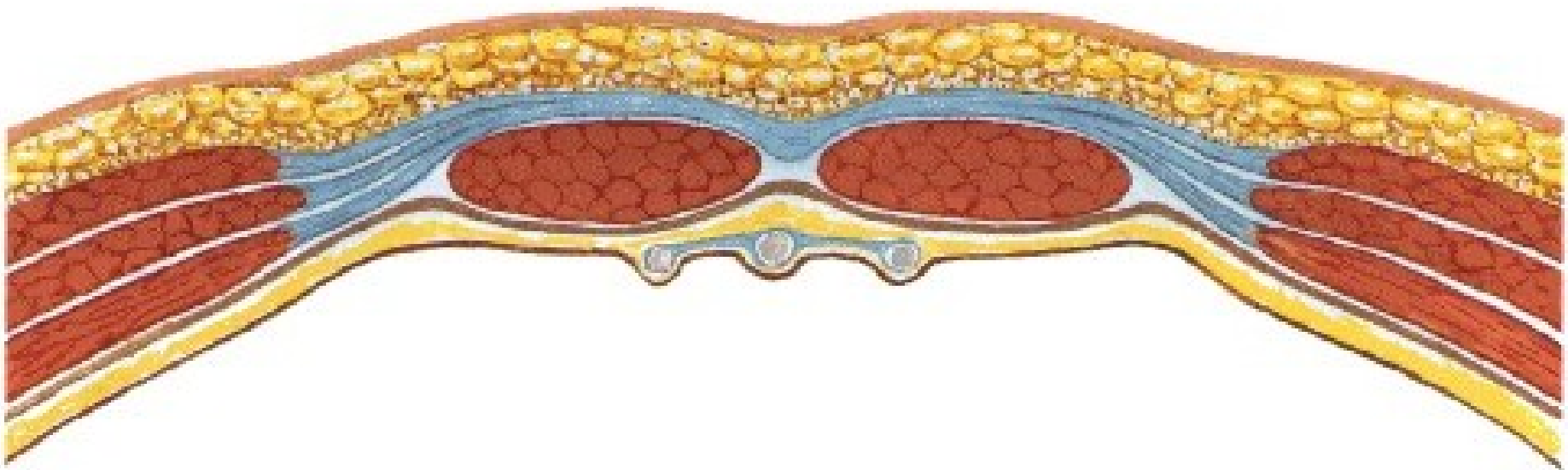
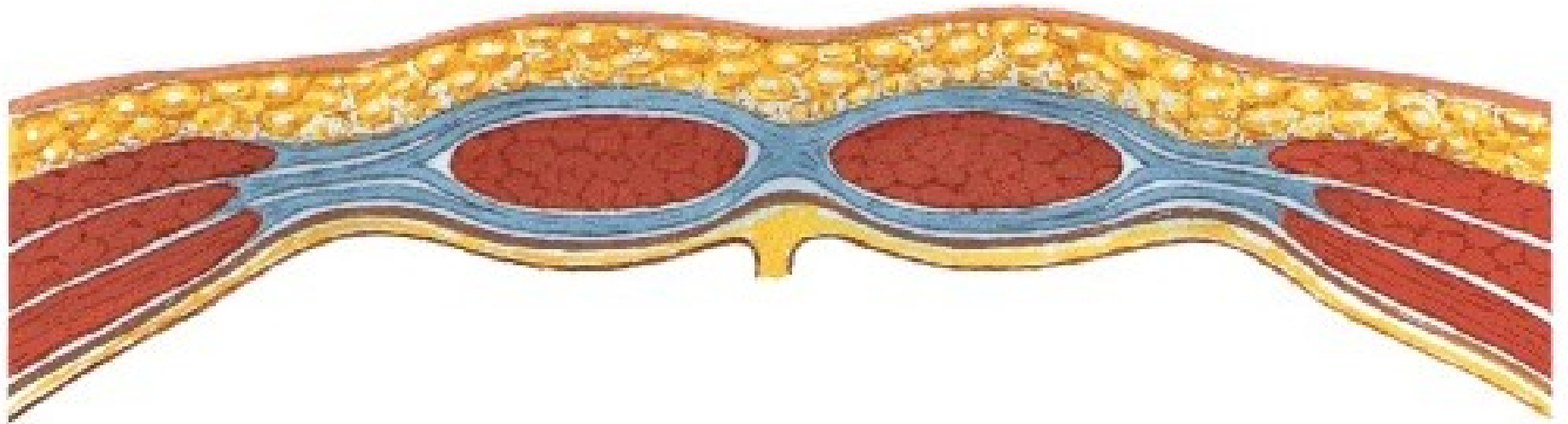


NODI LYMPHATICI AXILLARES
NODI LYMPHATICI INGUINALES SPF.

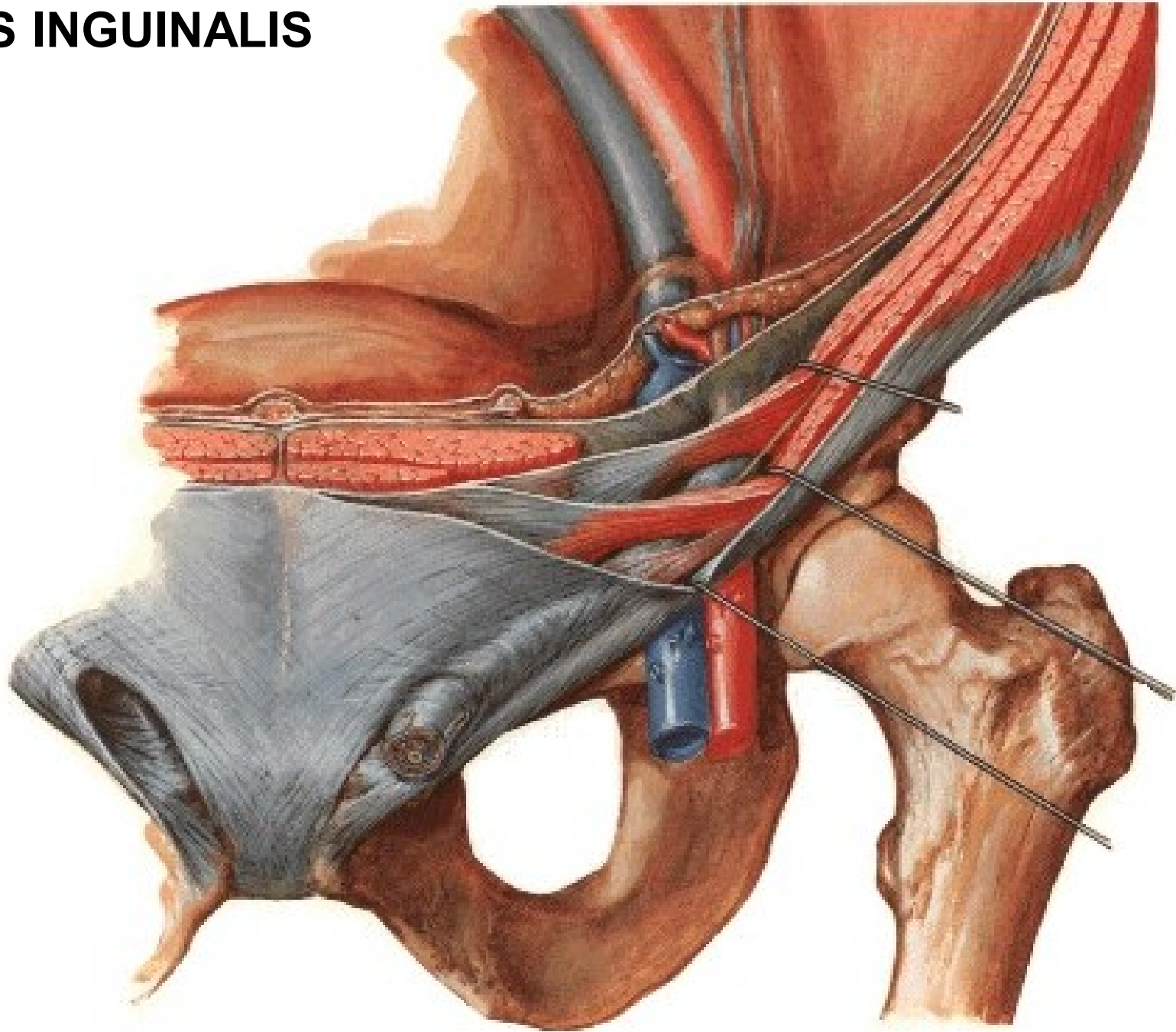


Vagina m. recti abdominis





CANALIS INGUINALIS



CANALIS INGUINALIS

Posterior wall:

Fascia transversalis

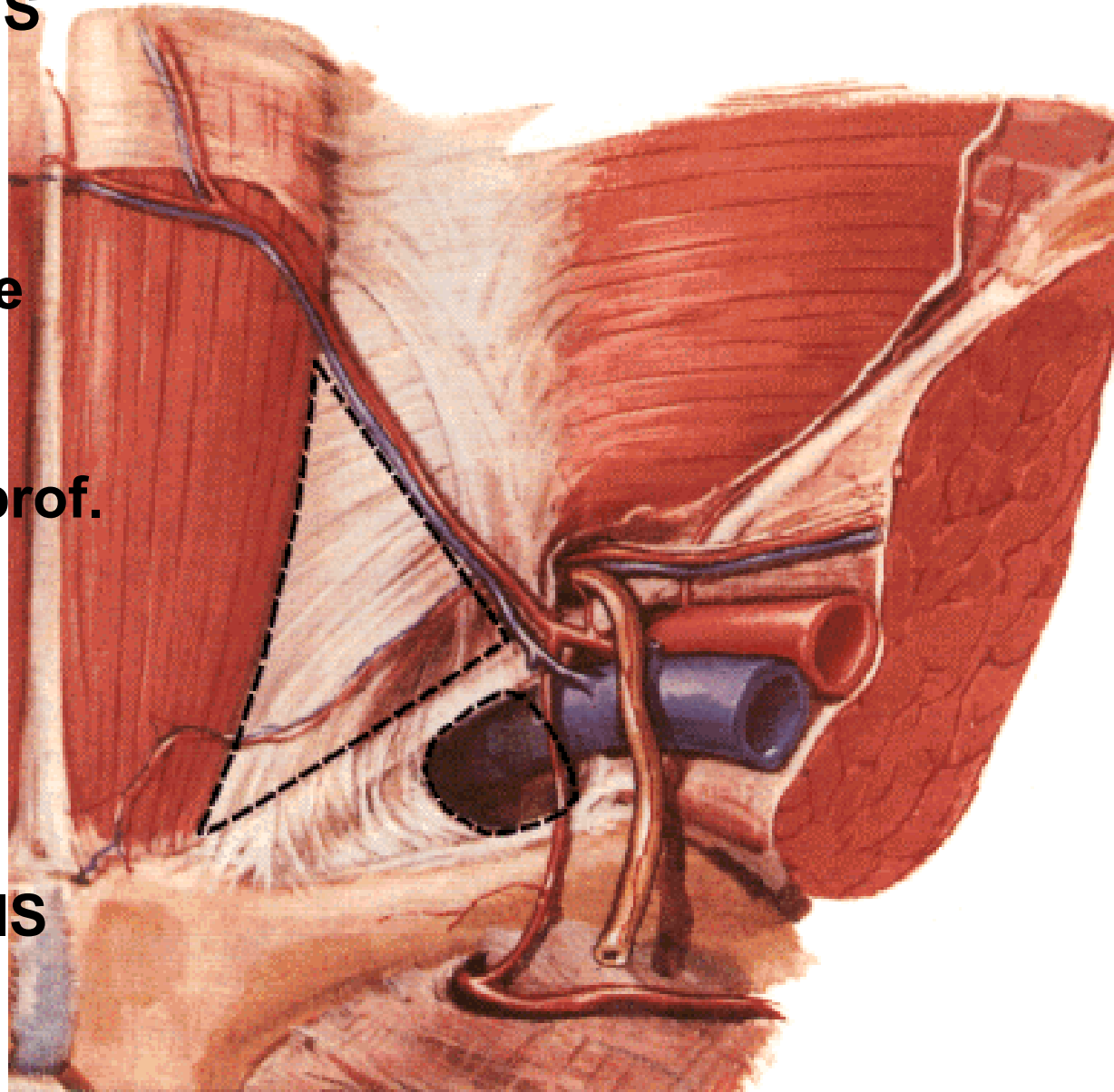
- **trigonum inguinale (Hesselbachi)**
- **lig. interfoveolare**
- **anulus inguinalis prof.**

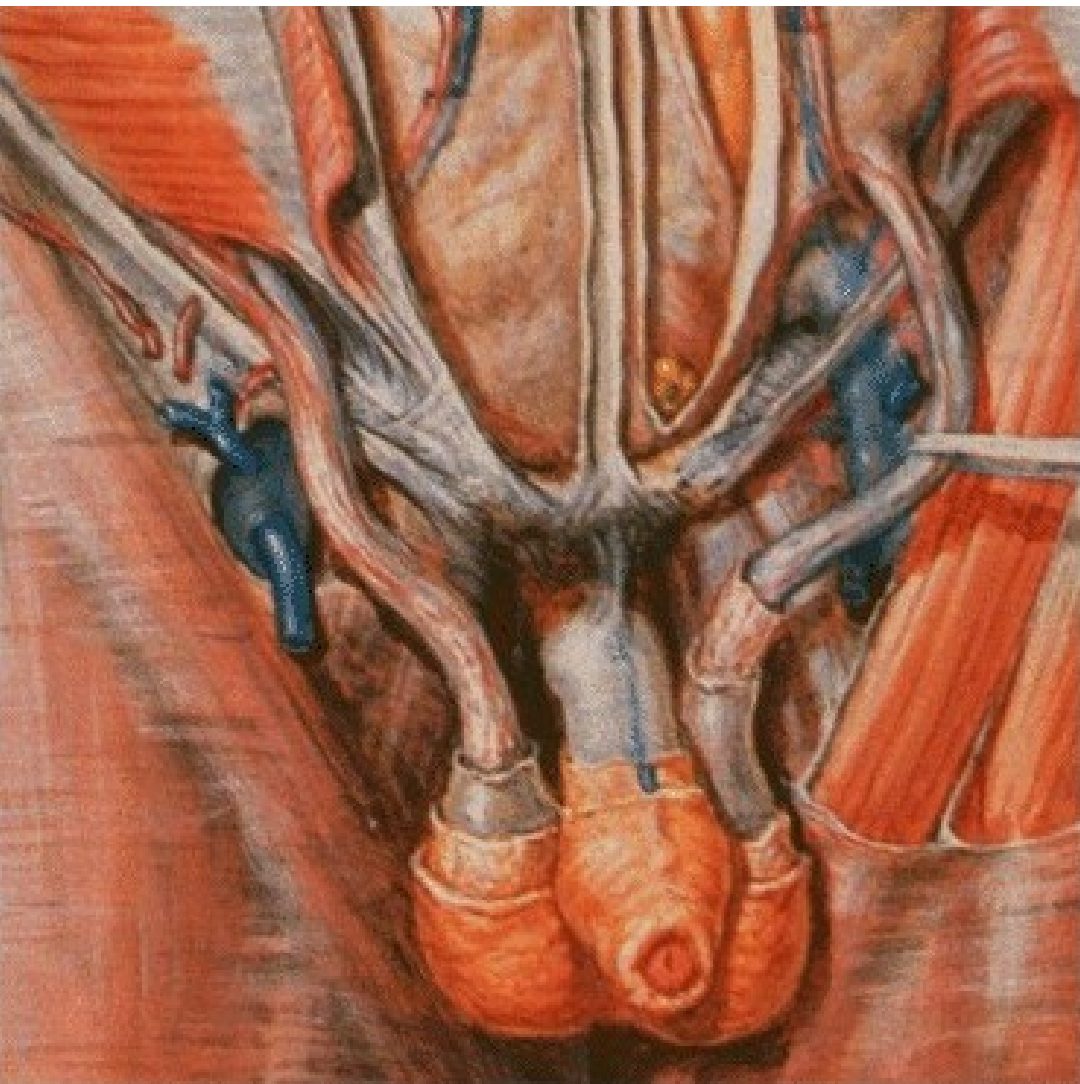
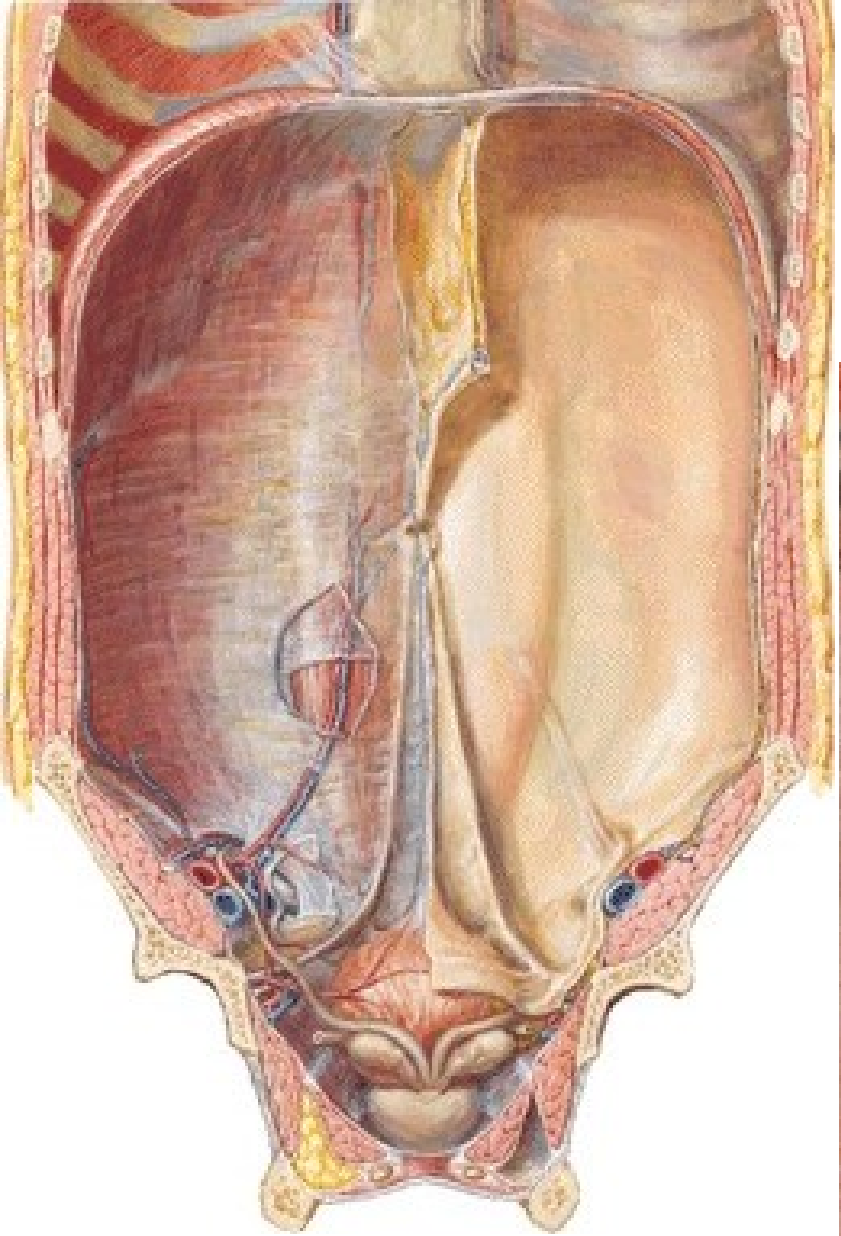
Inguinal hernia

- **direct**
- **indirect**

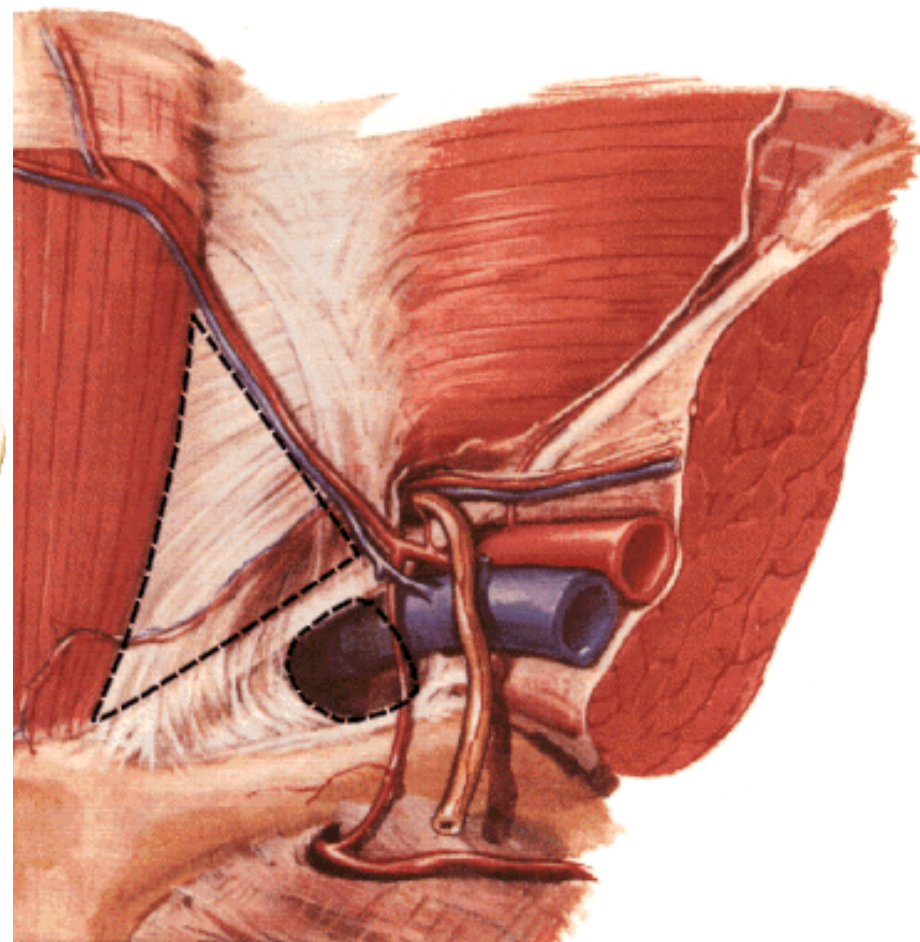
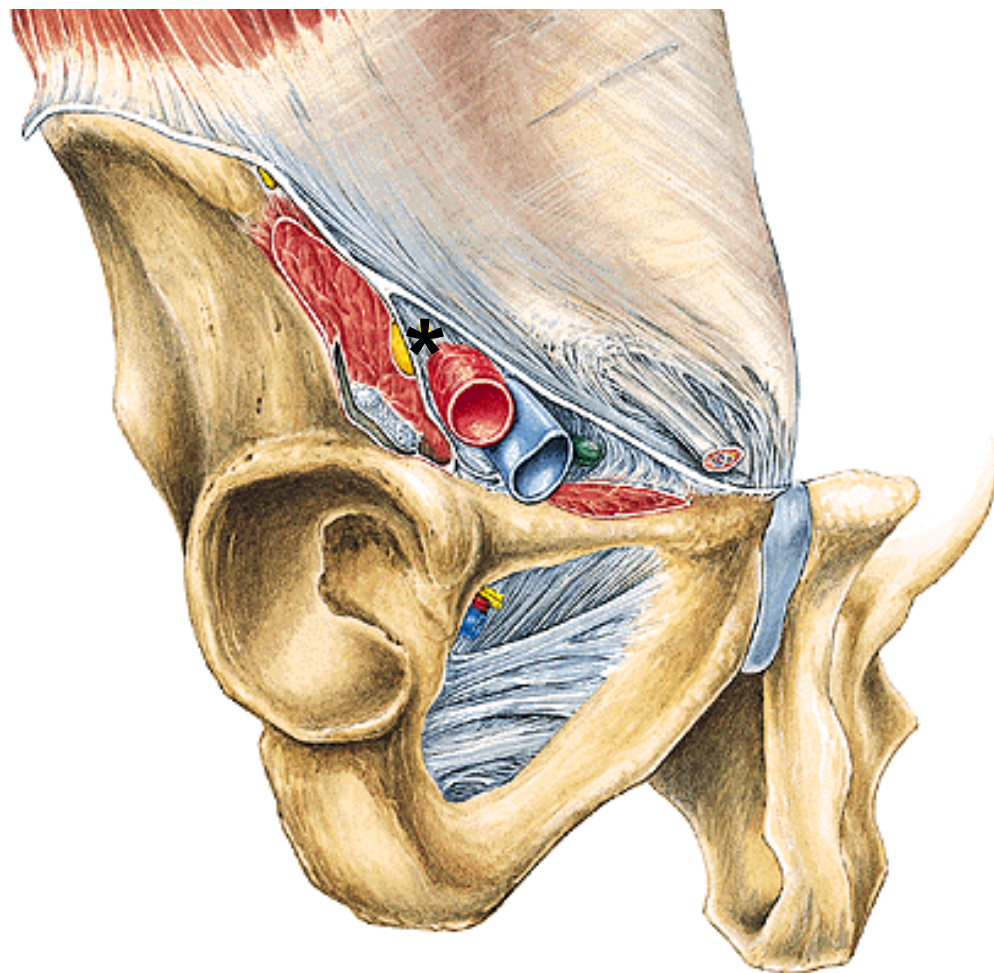
CANALIS FEMORALIS

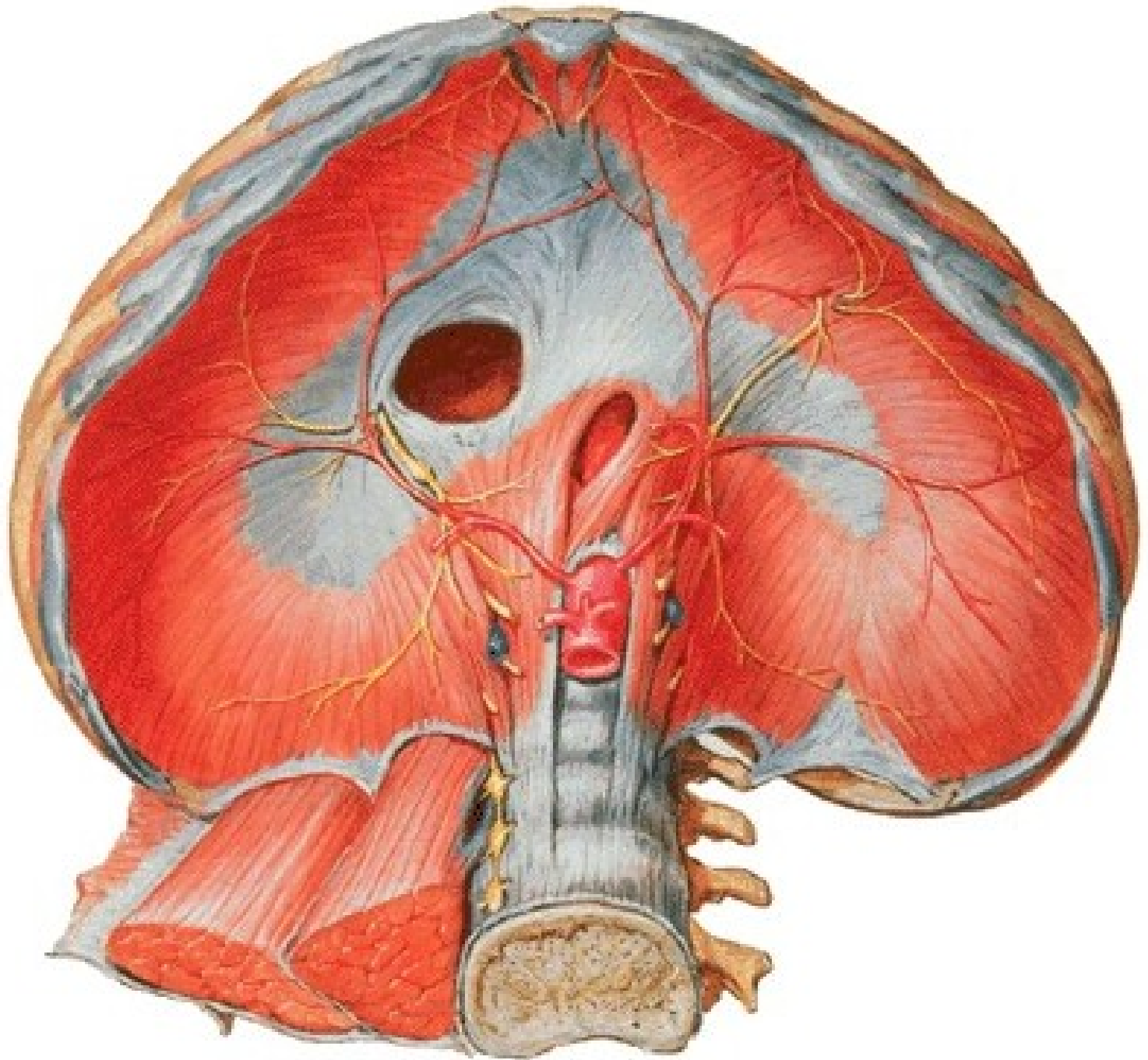
Femoral hernia





***Lacuna vasorum – anulus femoralis**
Lacuna musculorum

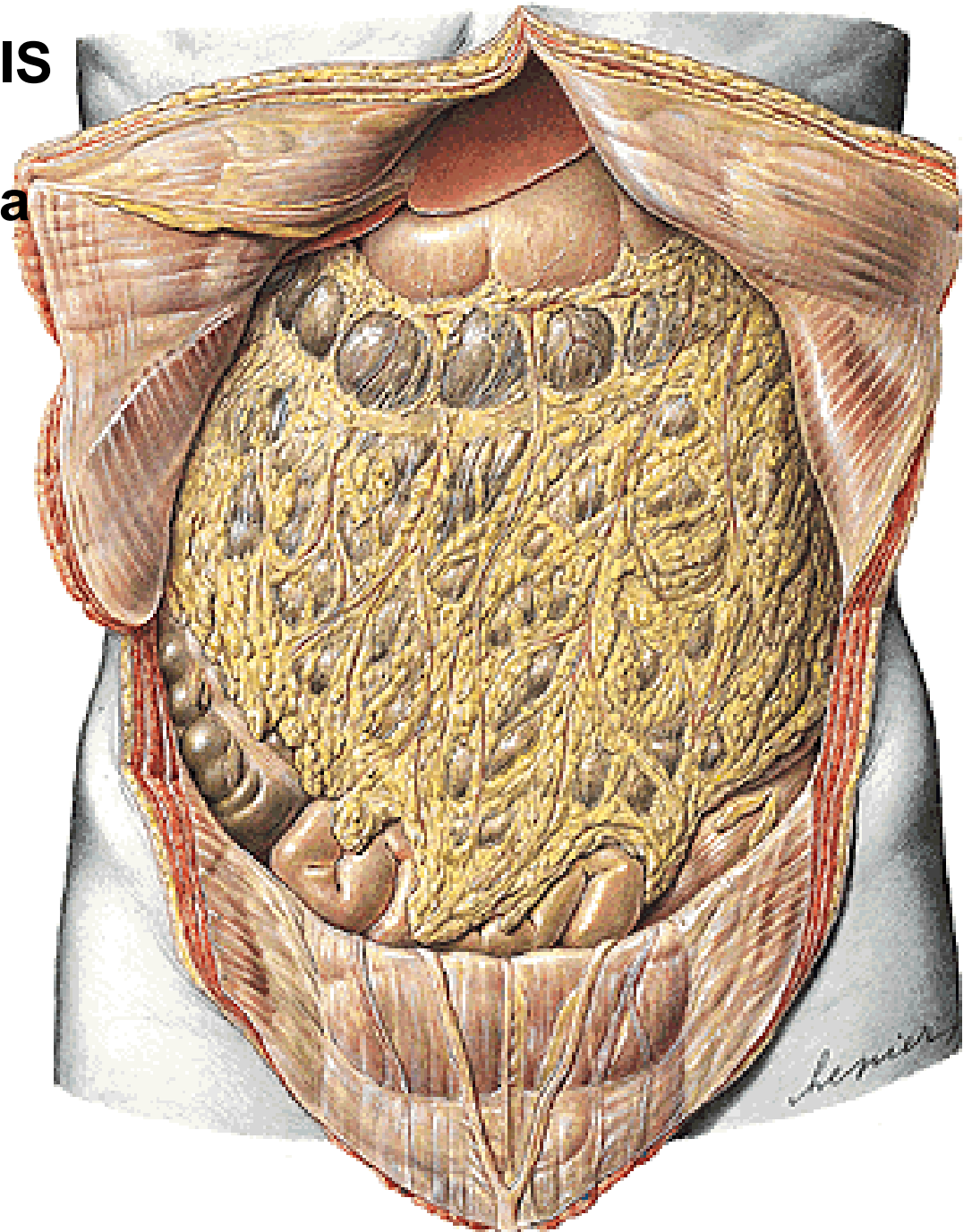




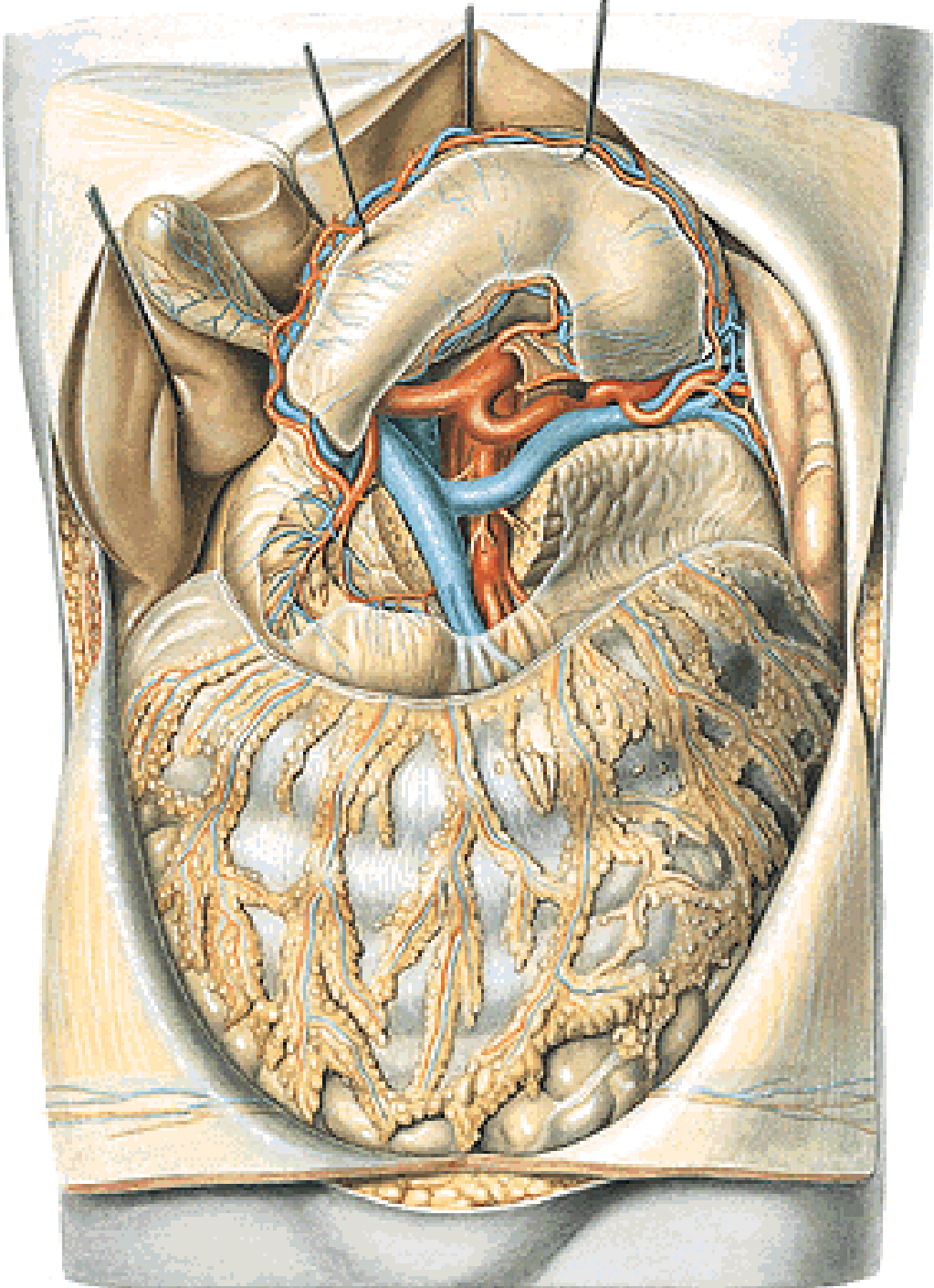
CAVITAS PERITONEALIS

CAVITAS PERITONEALIS

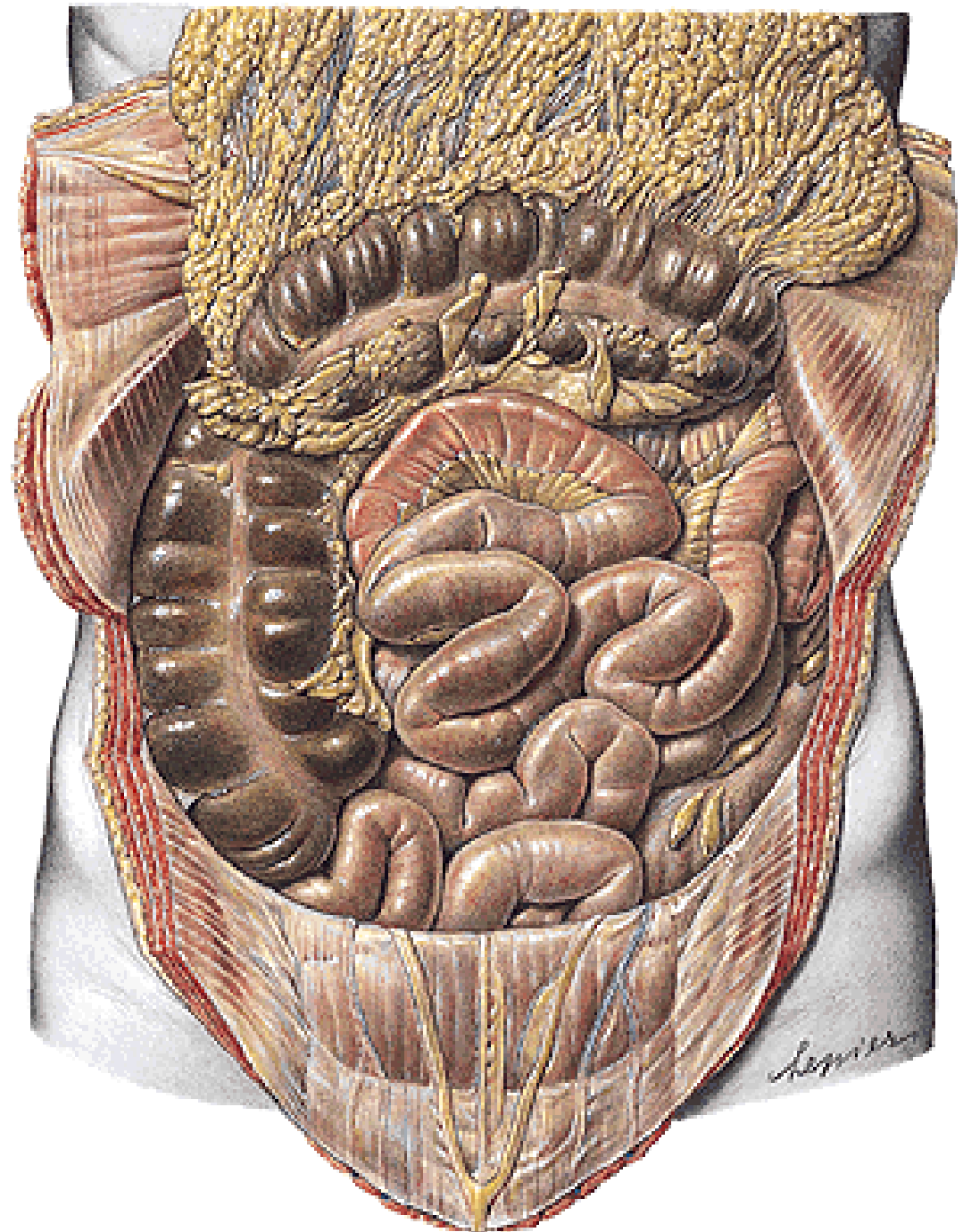
- pars supramesocolica
- pars inframesocolica

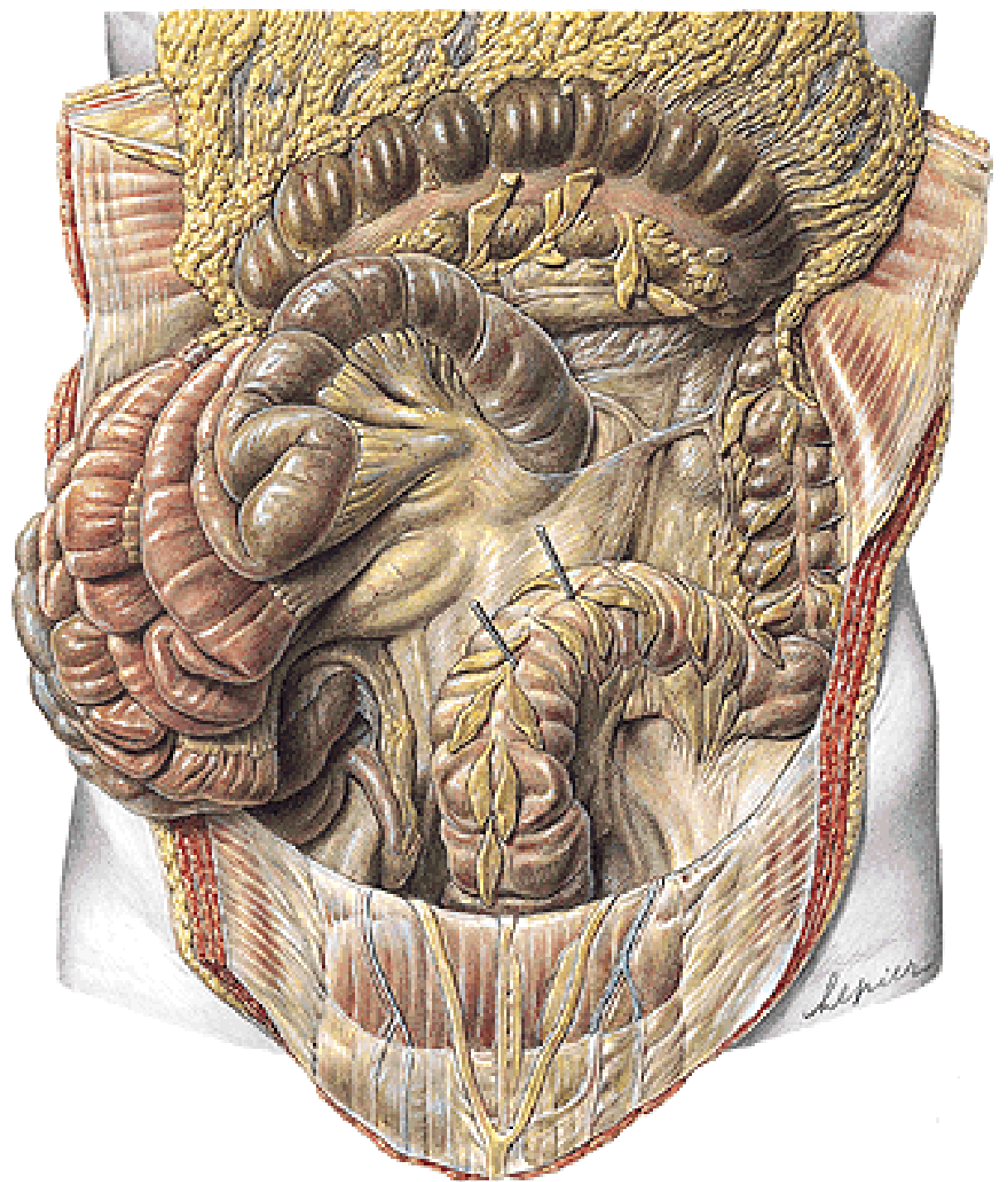


**Pars supramesocolica
(truncus coeliacus)**

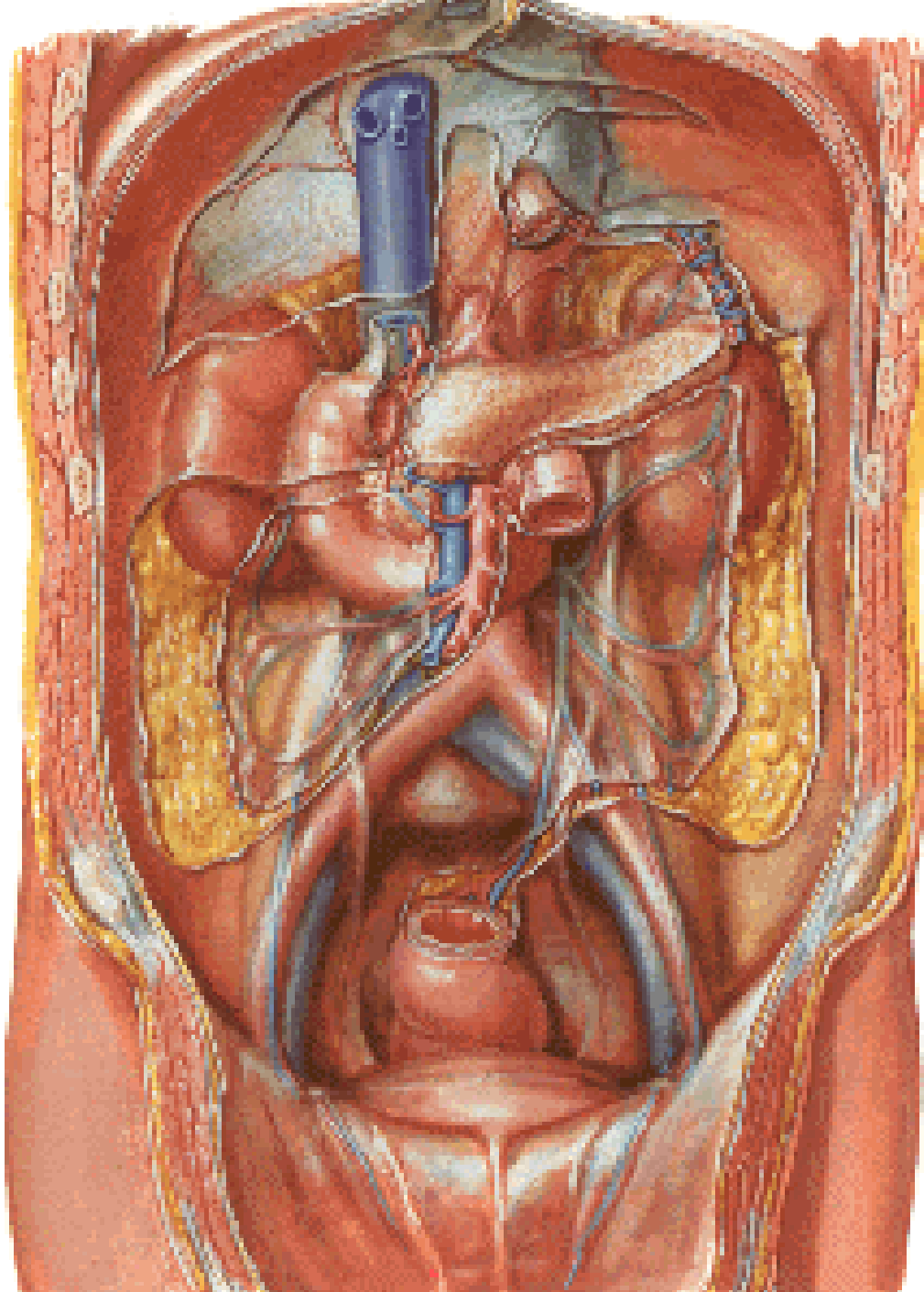


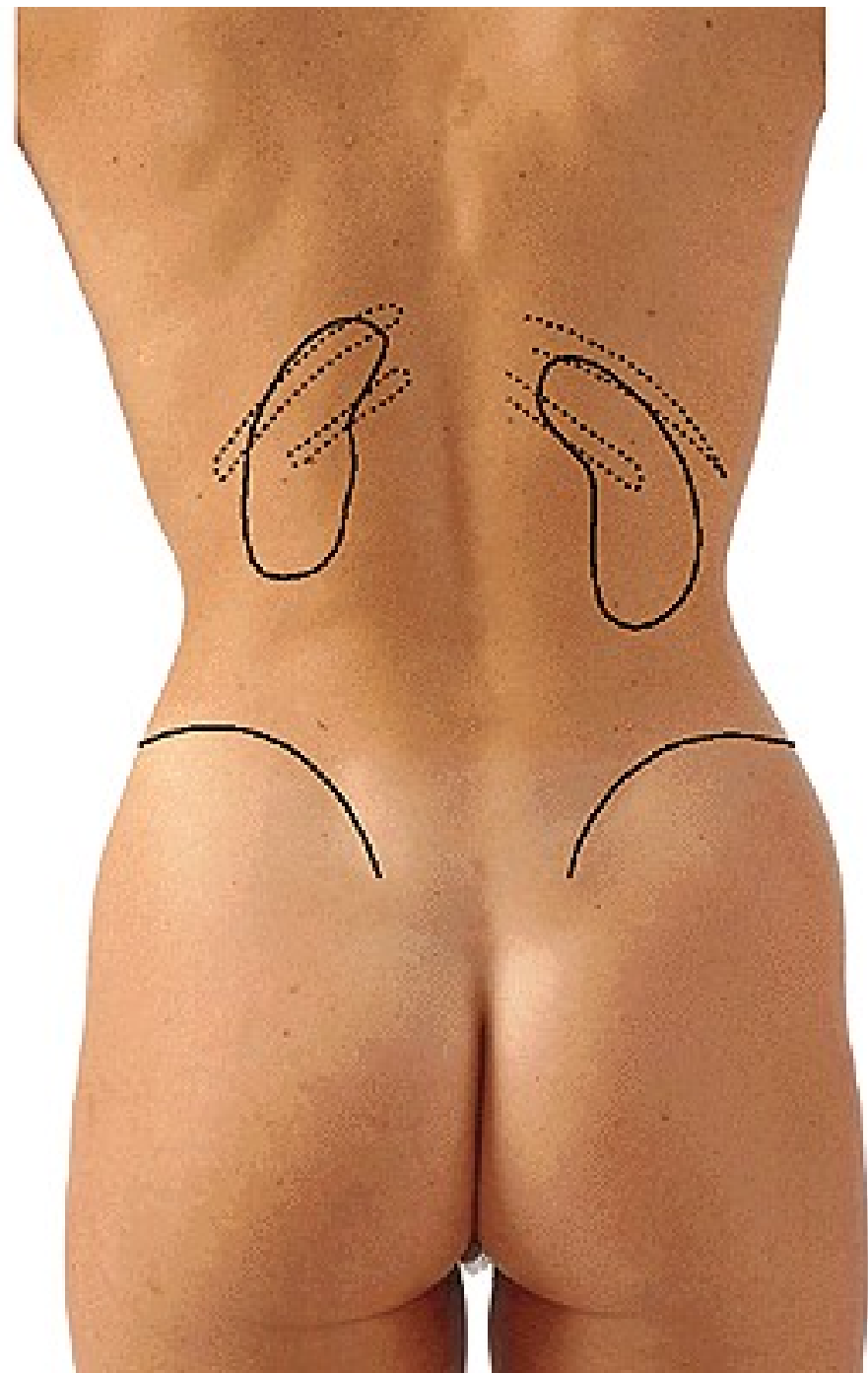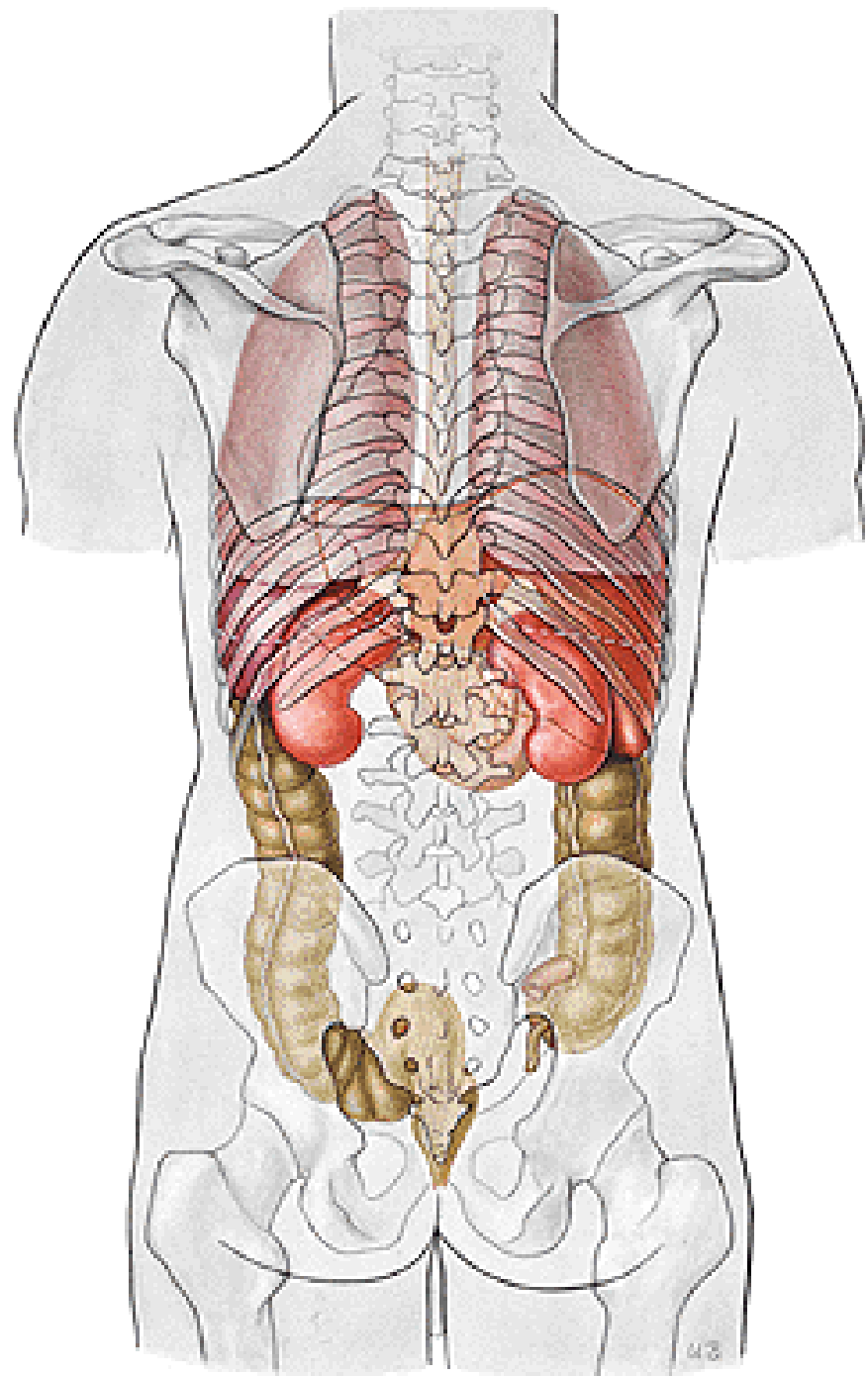
Pars inframesocolica



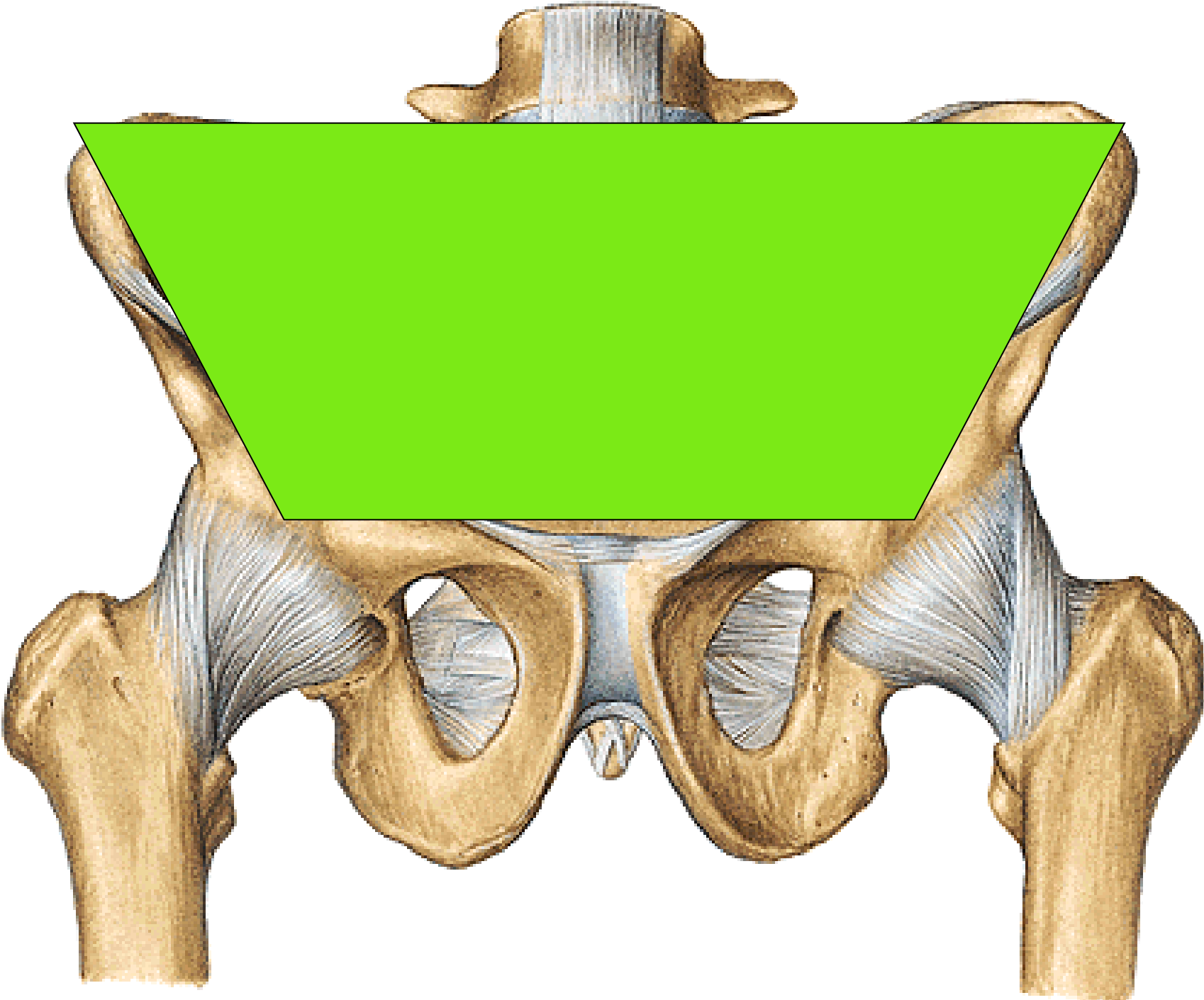


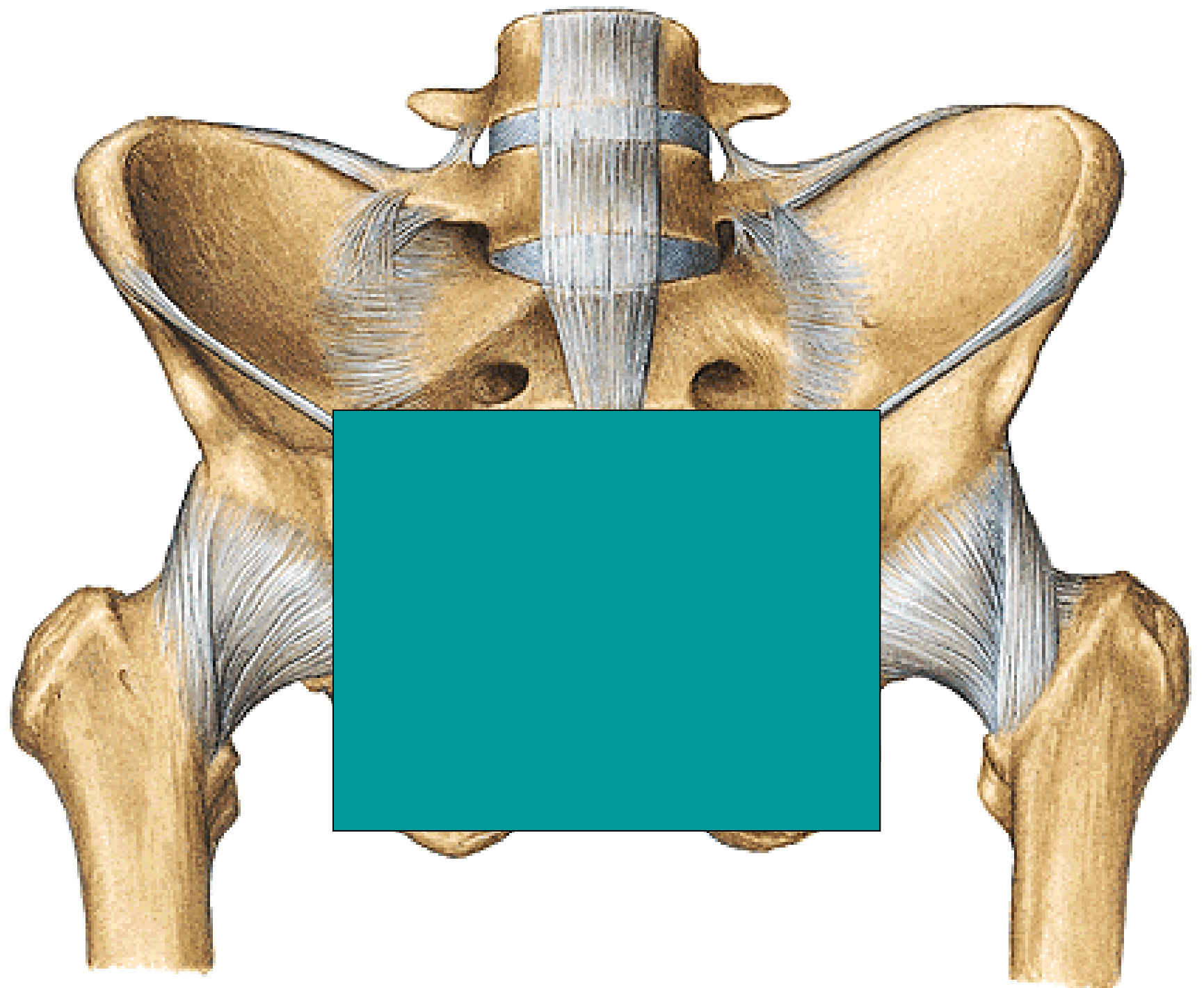
SPATIUM RETROPERITONEALE



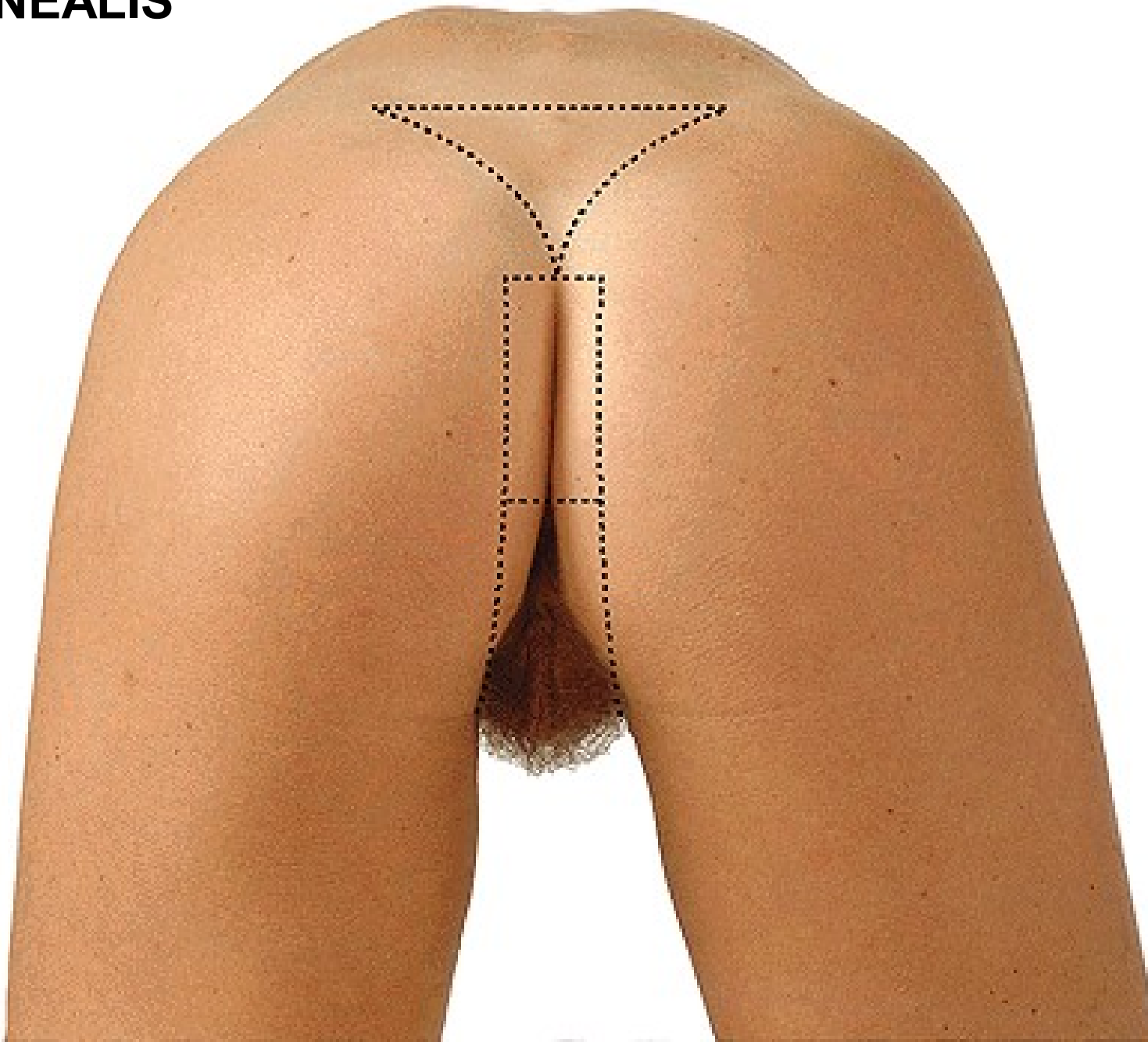


REGIONAL ANATOMY OF THE PELVIS





REGIO PERINEALIS

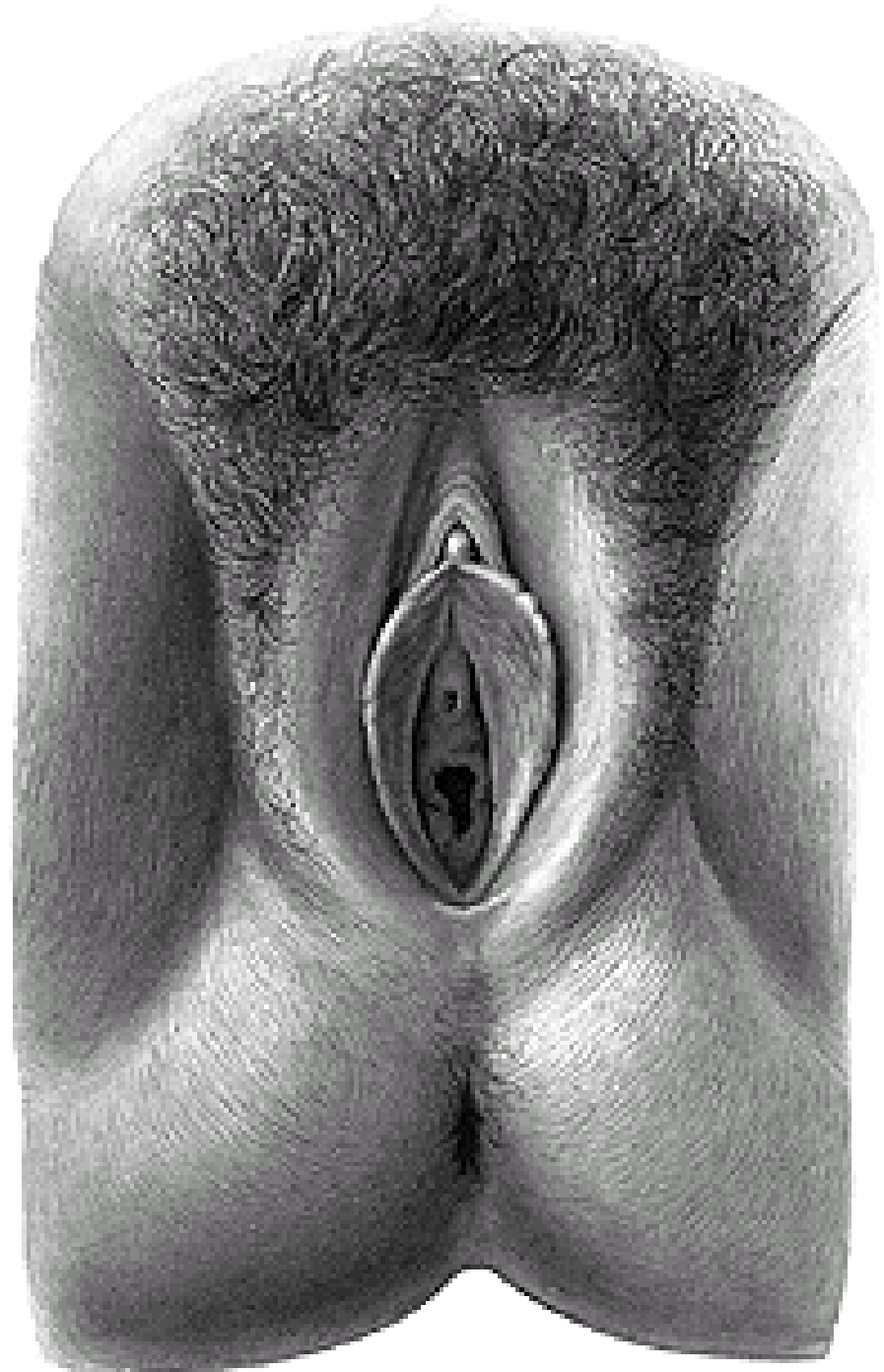

REGIO ANALIS

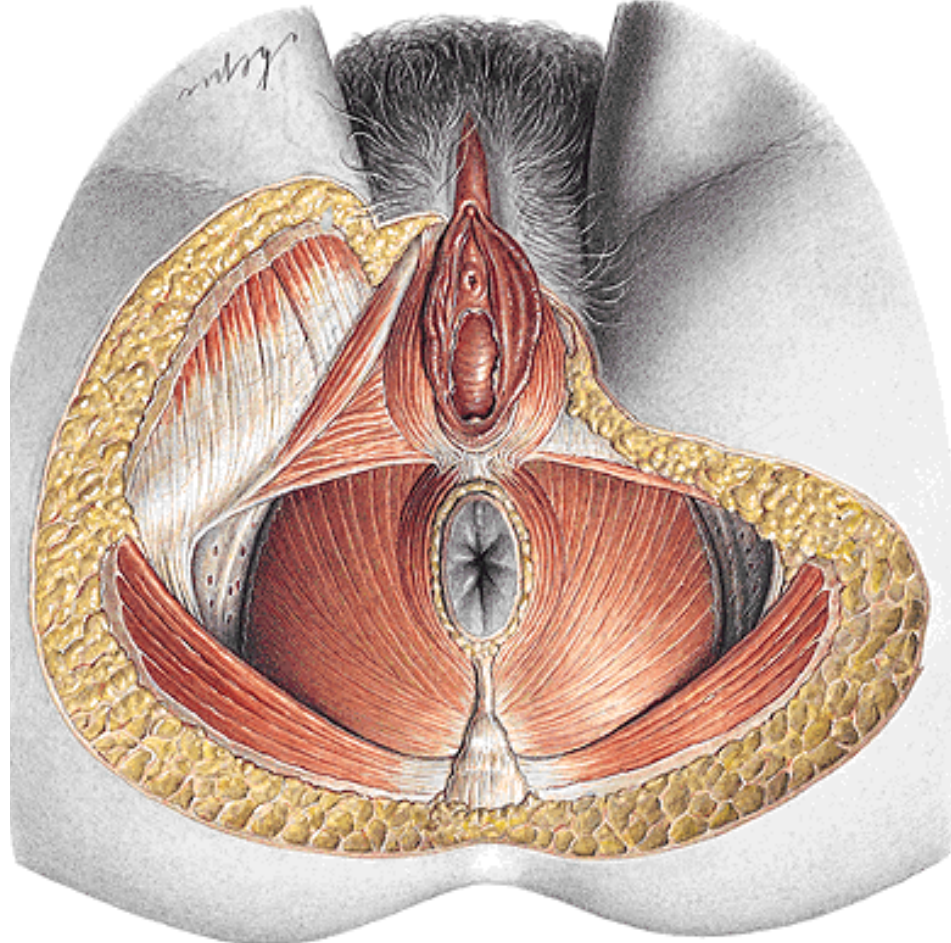
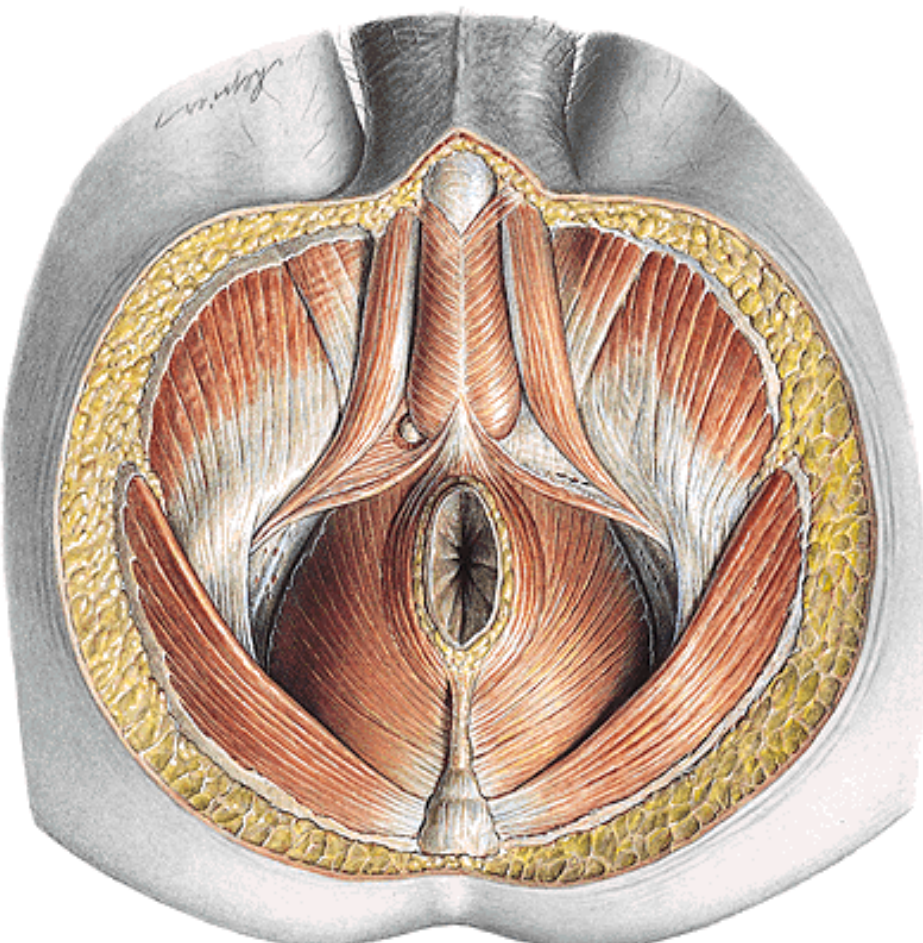
ANUS

RAPHE

GLANDULAE CIRCUMANALES



DIAPHRAGMA PELVIS
DEEP PERINEAL POUCH (DIAPHRAGMA UROGENITALE)
FOSSA ISCHIOANALIS (-RECTALIS)

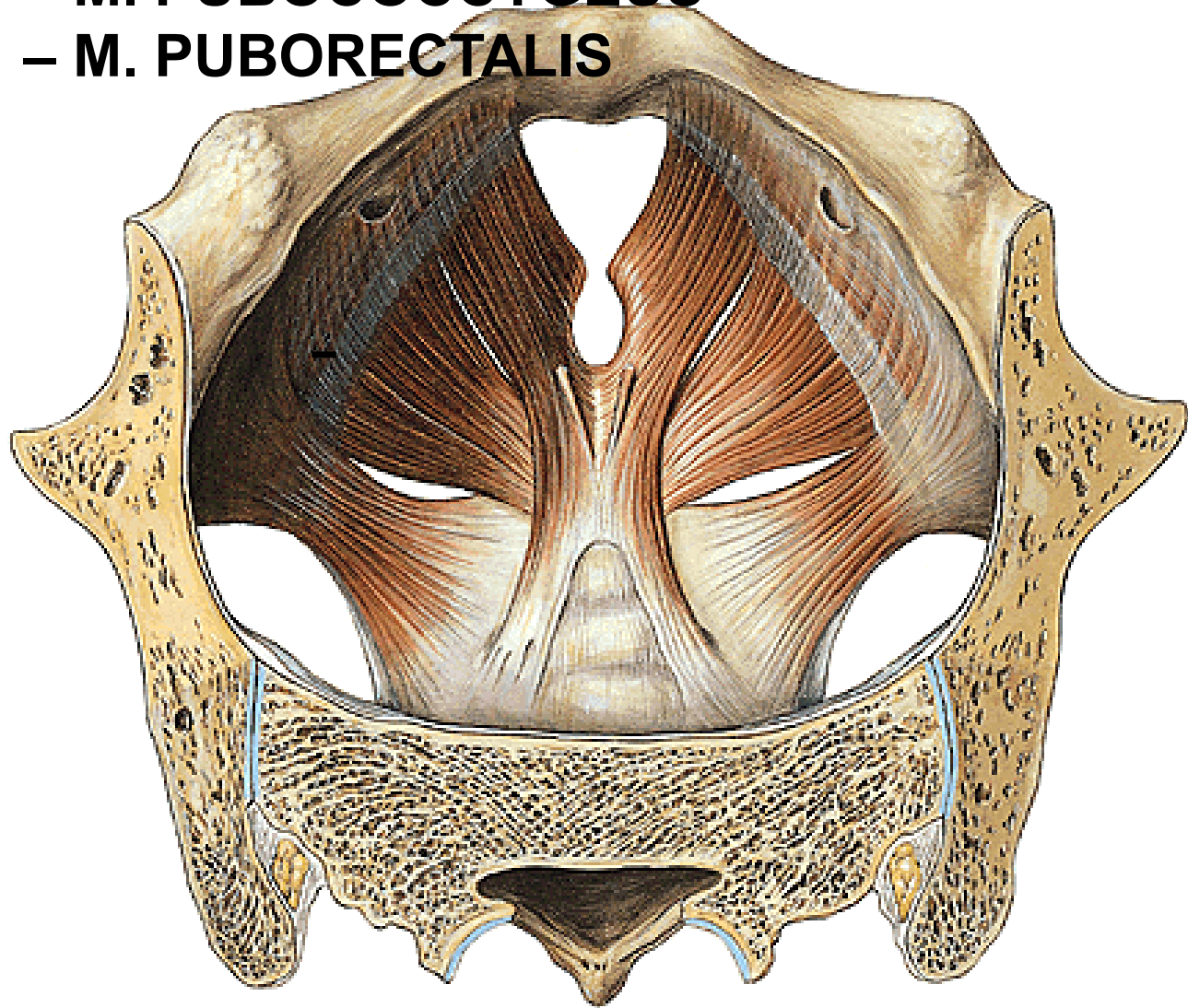


DIAPHRAGMA PELVIS

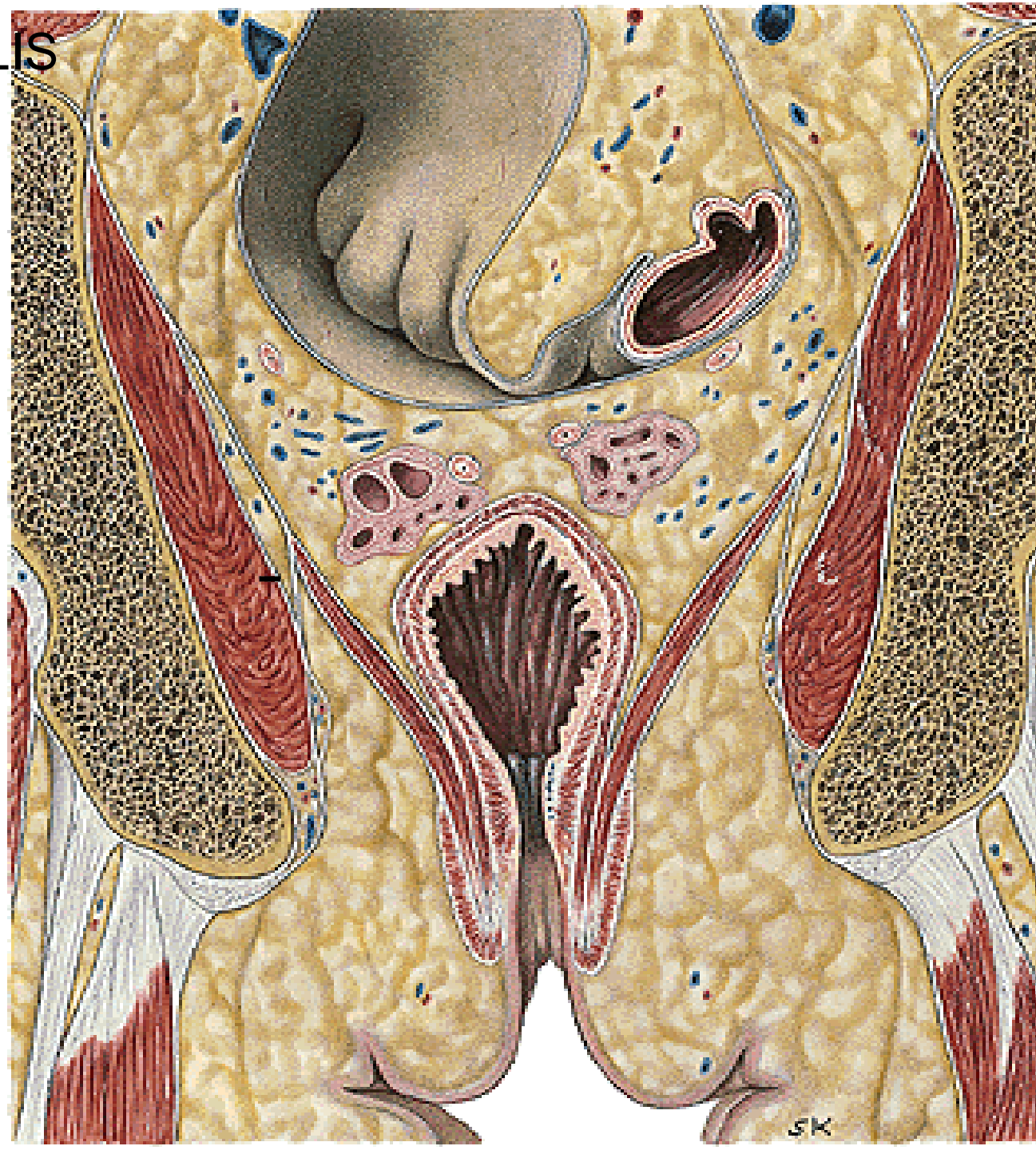- M. LEVATOR ANI – M. ILIOCOCCYGEUS
- M. PUBOCOCCYGEUS
- M. PUBORECTALIS
- M. COCCYGEUS

Arcus tendineus
m. levatoris ani

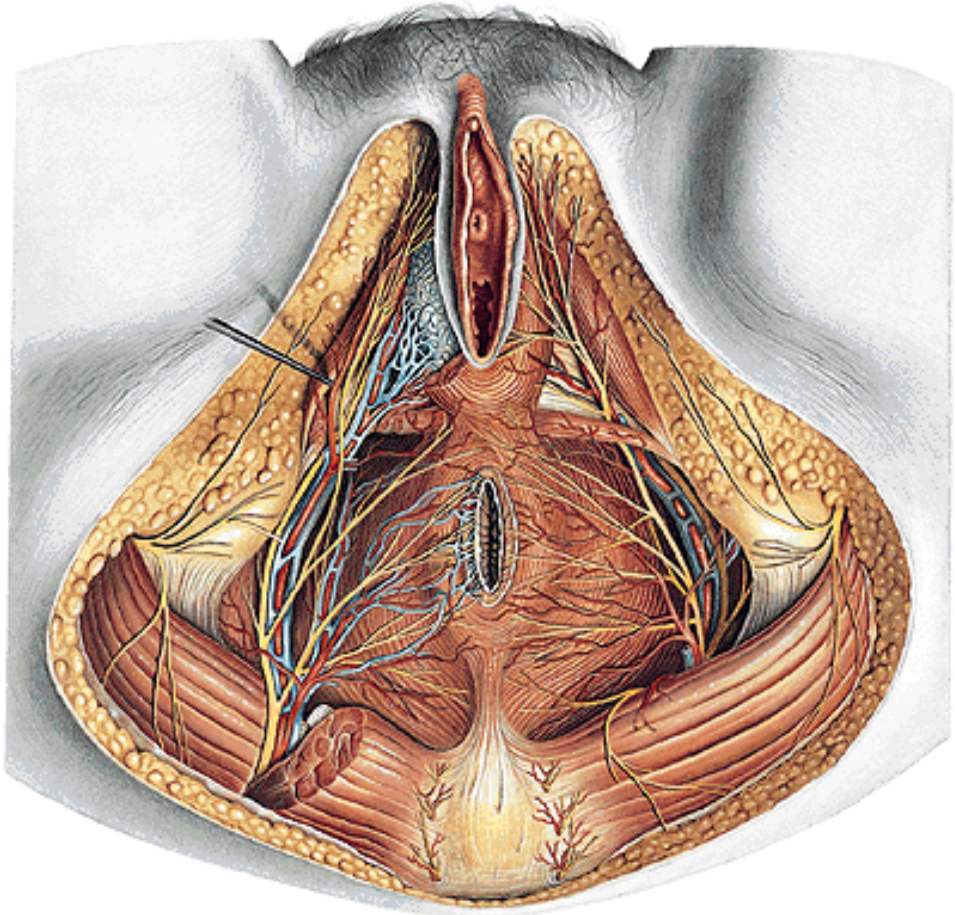
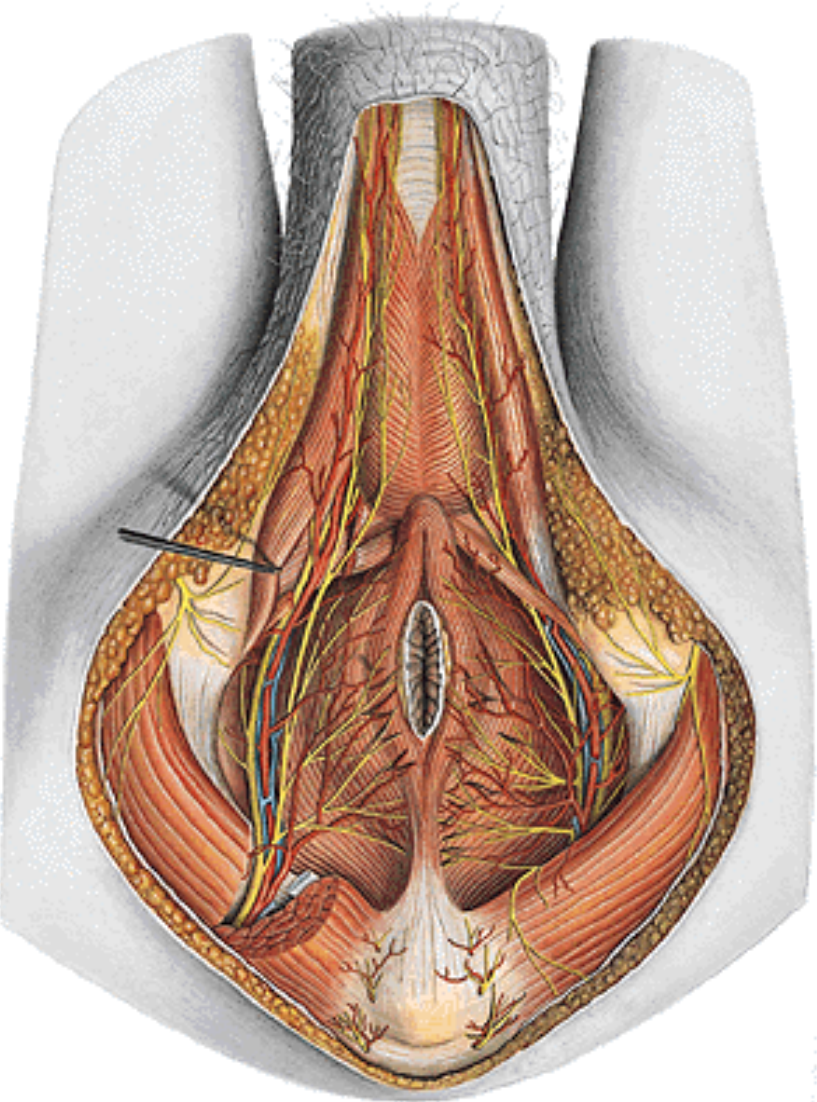
Hiatus
urogenitalis



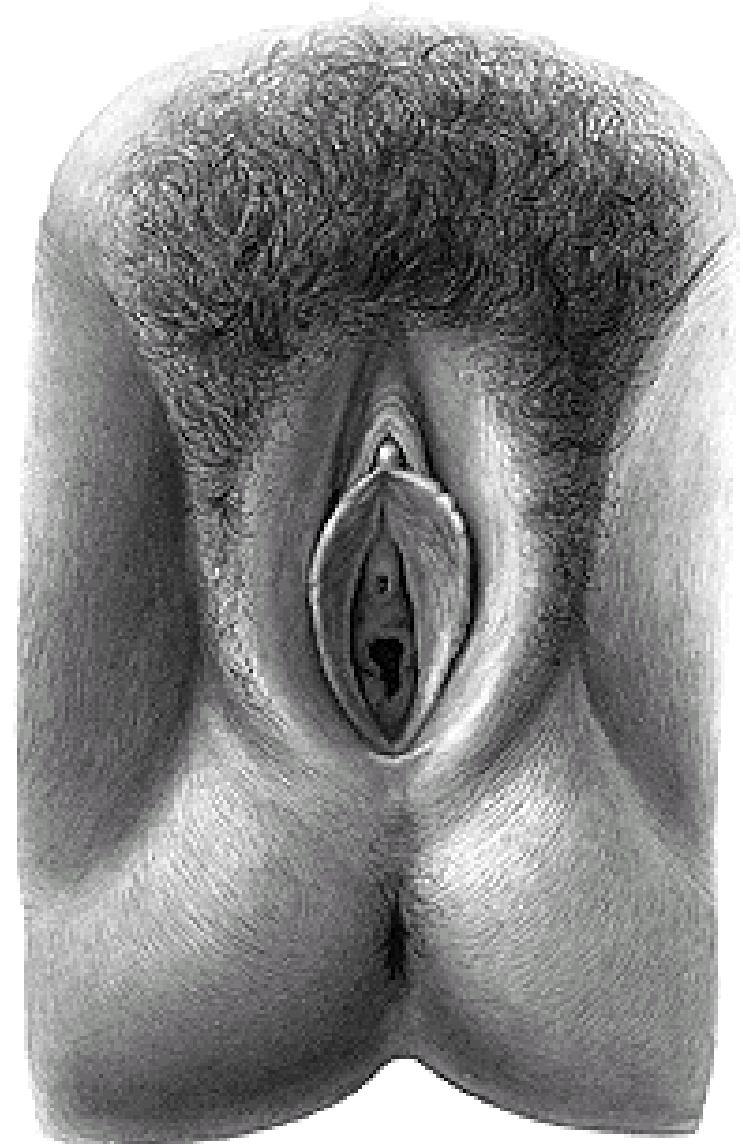FOSSA ISCHIOANALIS (ISCHIORECTALIS)



CANALIS PUDENDALIS (ALCOCK)

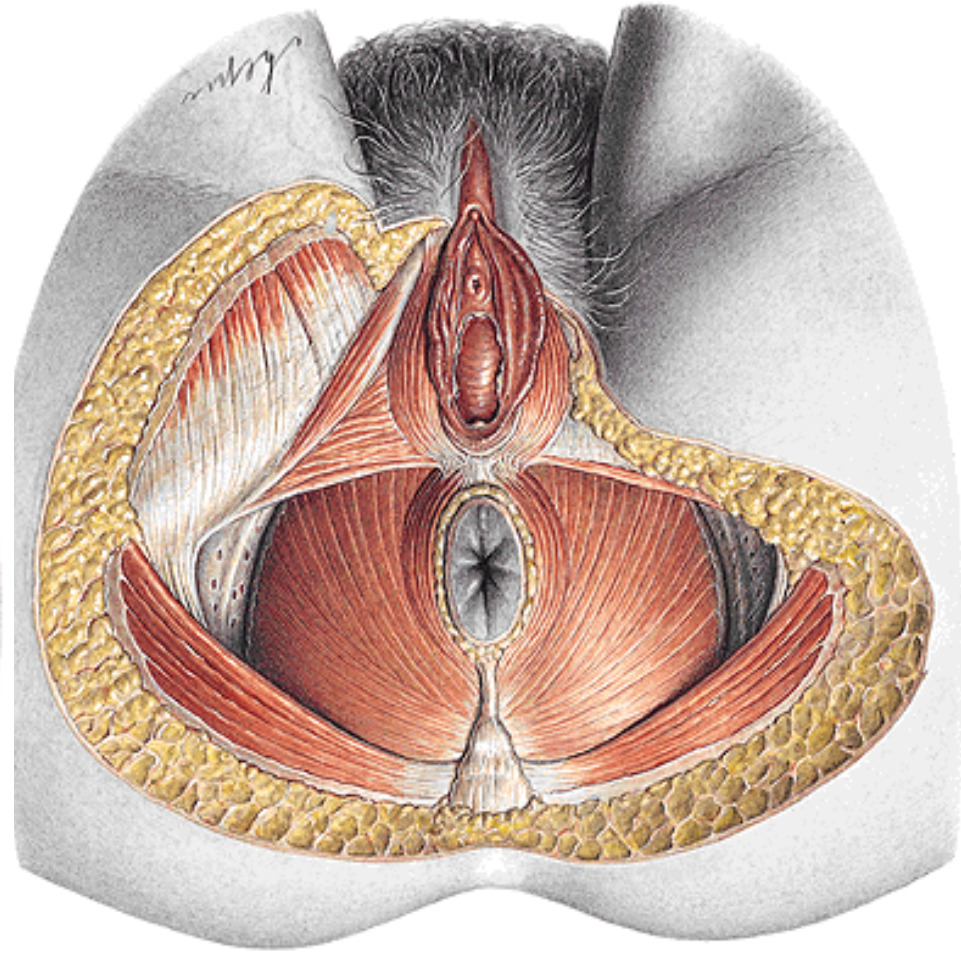
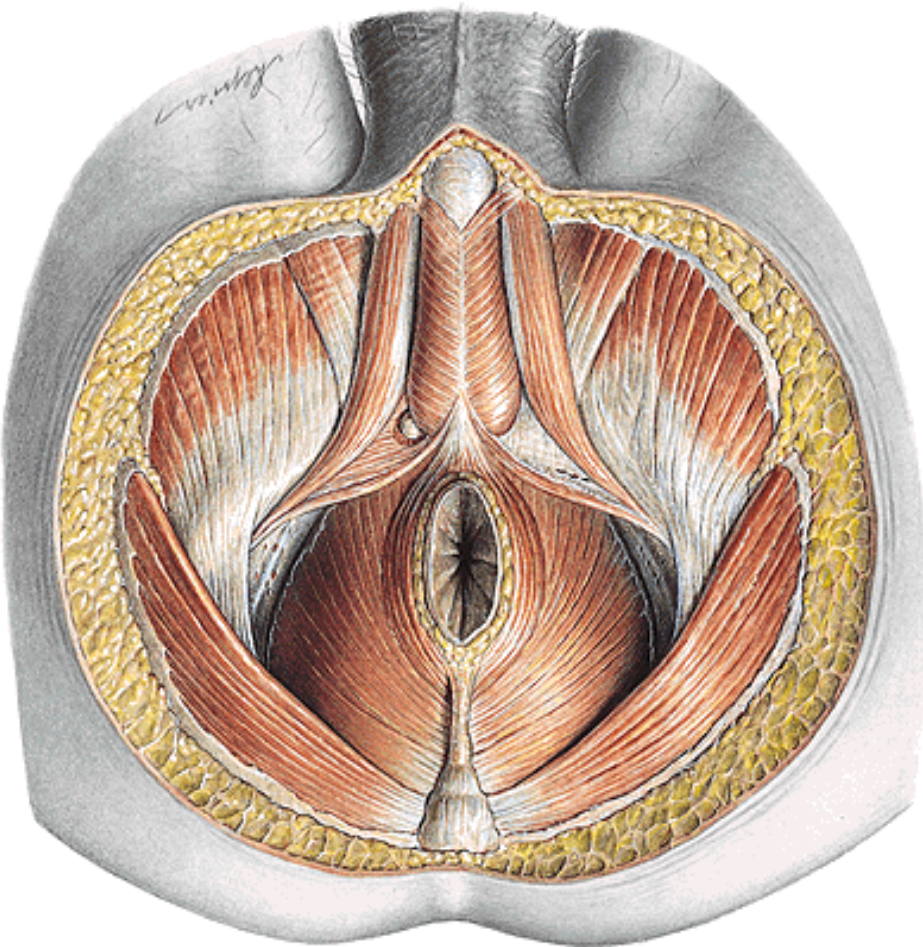


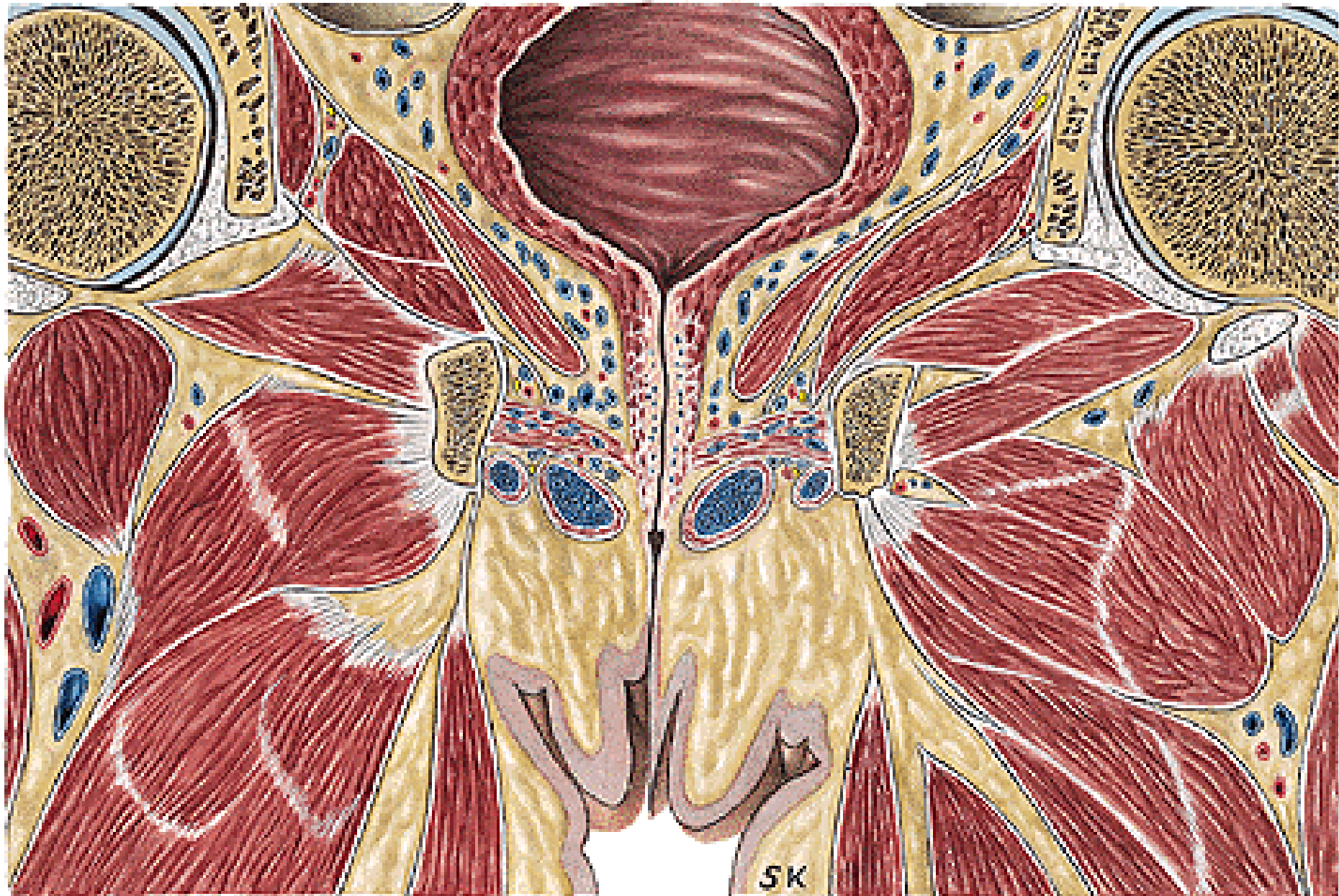REGIO UROGENITALIS

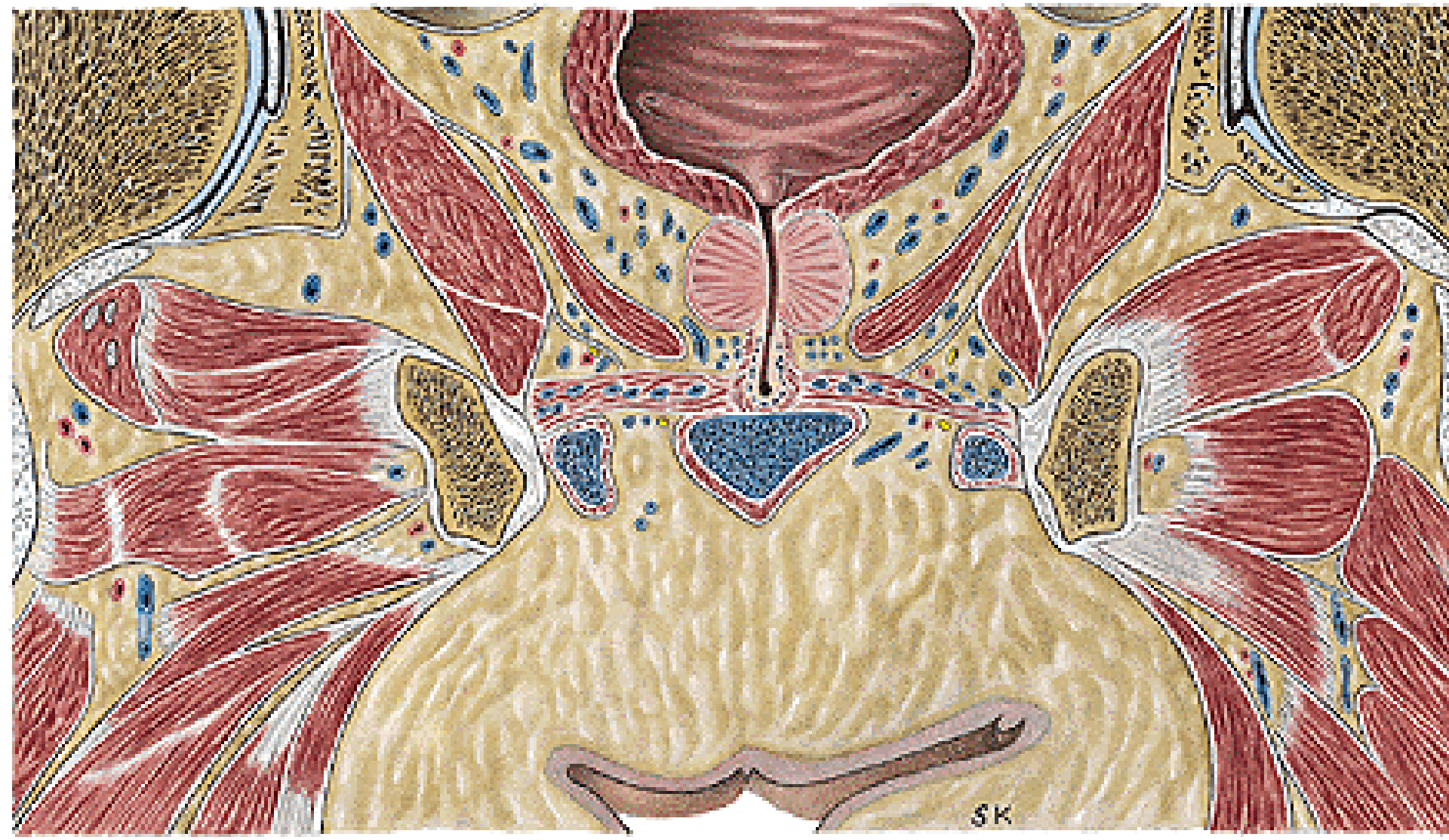

SPATIUM PERINEI SUPERFICIALE (SUPERFICIAL PERINEAL POUCH)

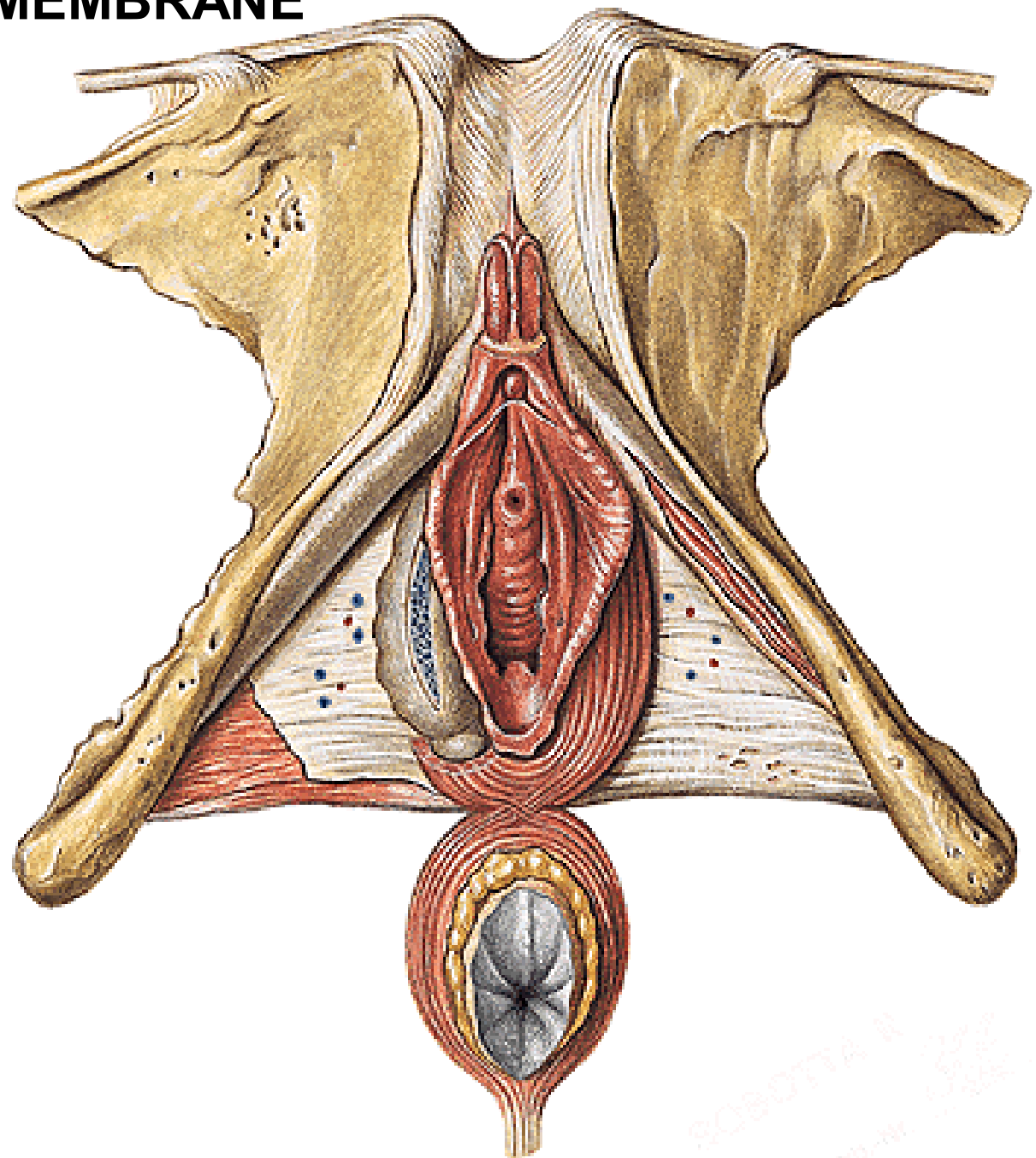
- M. ISCHIOCAVERNOSUS
- M. BULBOSPONGIOSUS
- M. SPHINCTER ANI EXTERNUS







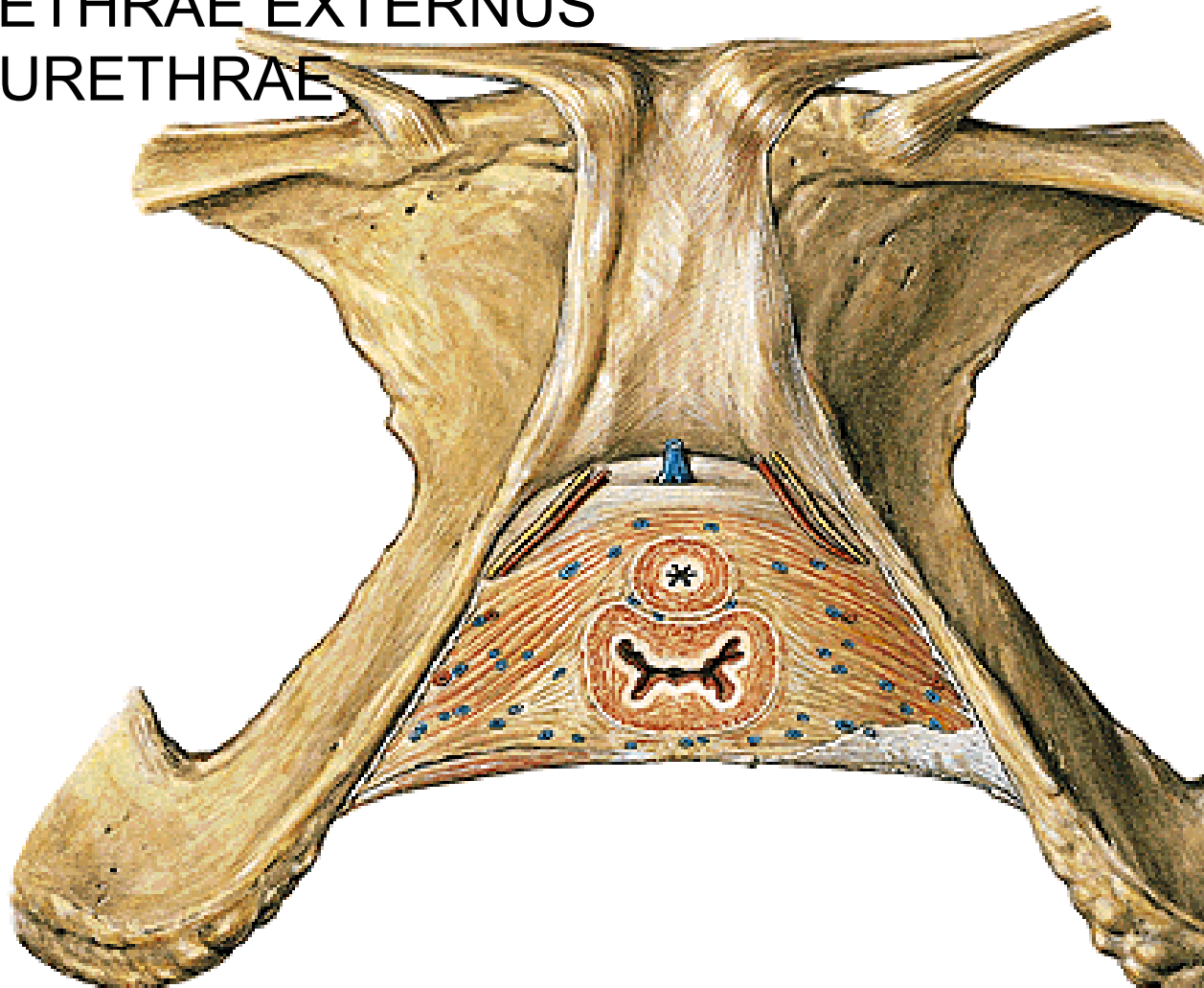
PERINEAL MEMBRANE



ROBOTA 11 2012
www.robota.com

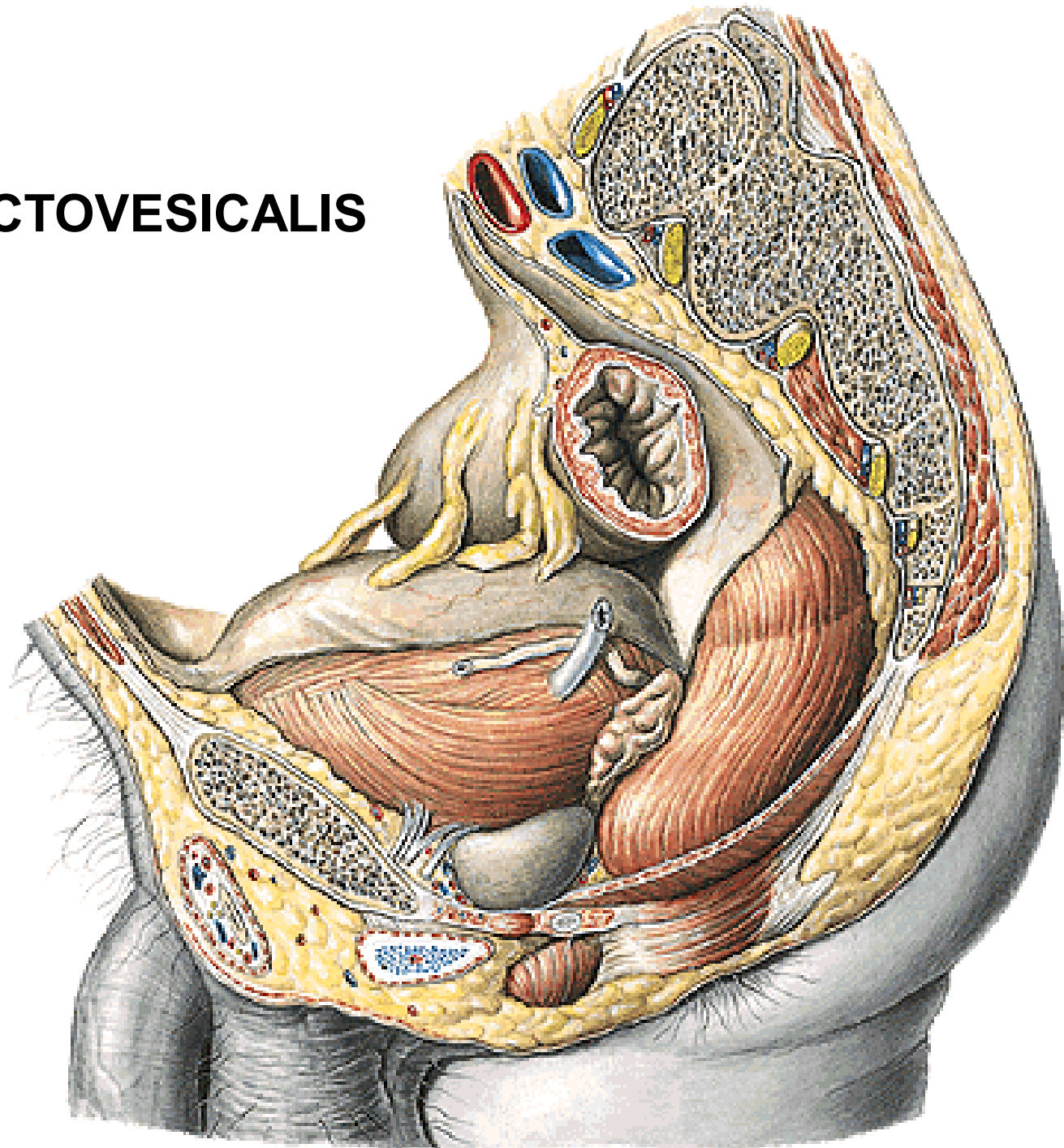
SPATIUM PERINEI PROFUNDUM (DEEP PERINEAL POUCH)

- M. TRANSVERSUS PERINEI PROF.
- (M. TRANSVERSUS PERINEI SPF.)
- M. SPHINCTER URETHRAE EXTERNUS
- M. COMPRESSOR URETHRAE

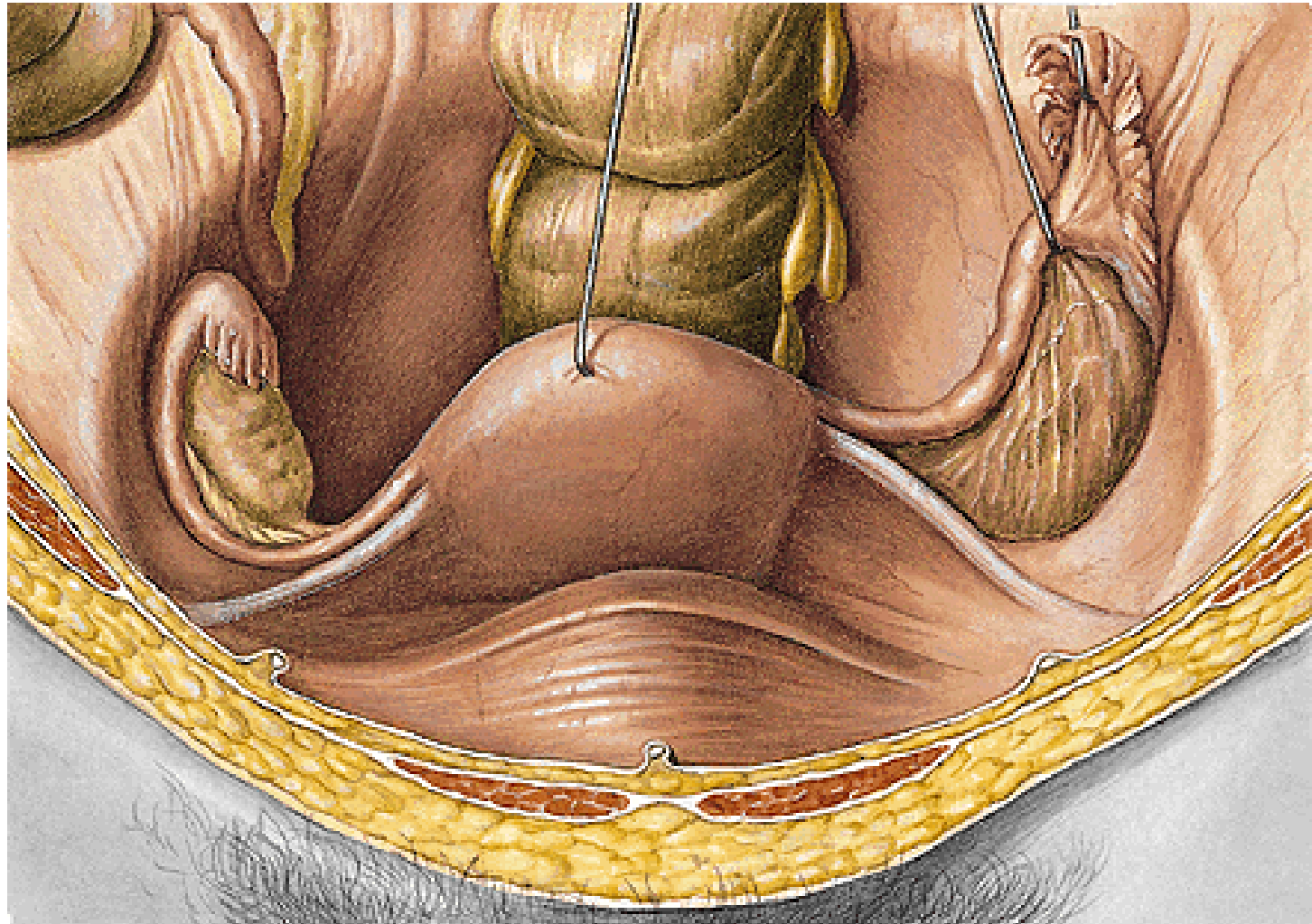


CAVUM PELVIS

EXCAVATIO RECTOVESICALIS

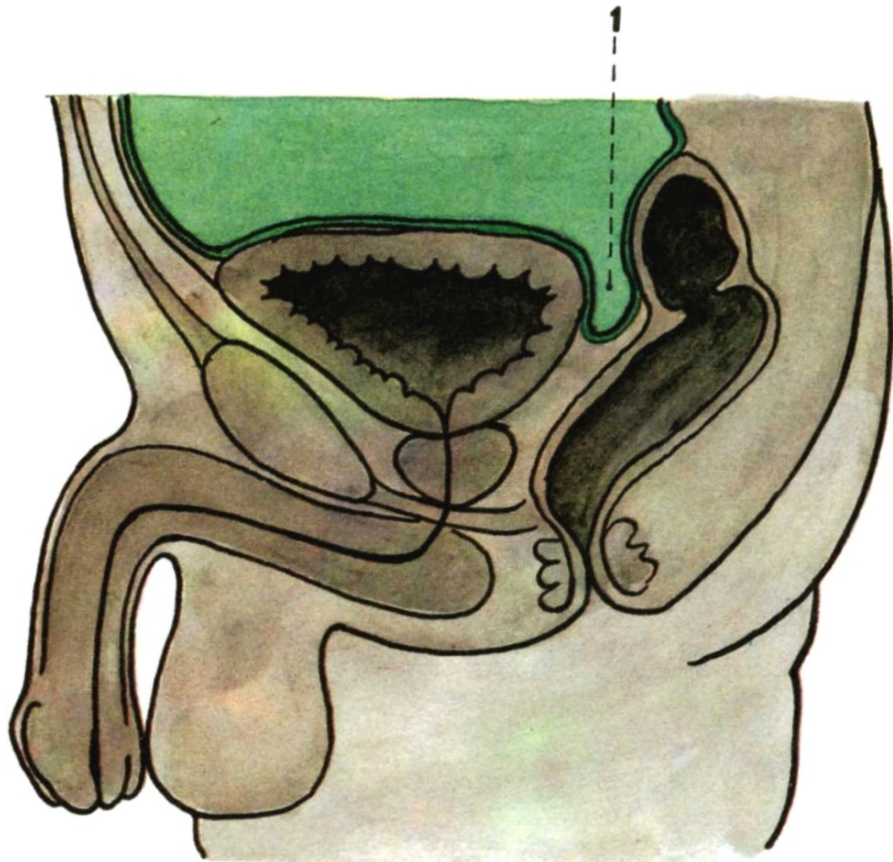


LIGAMENTUM LATUM UTERI LIGAMENTUM TERES UTERI



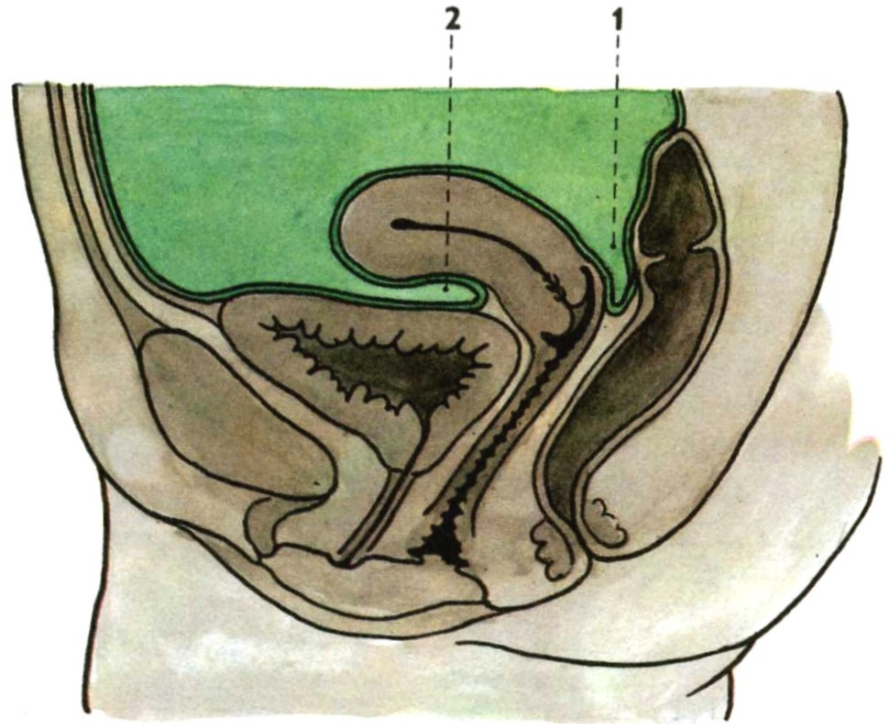
Median section through the male pelvis

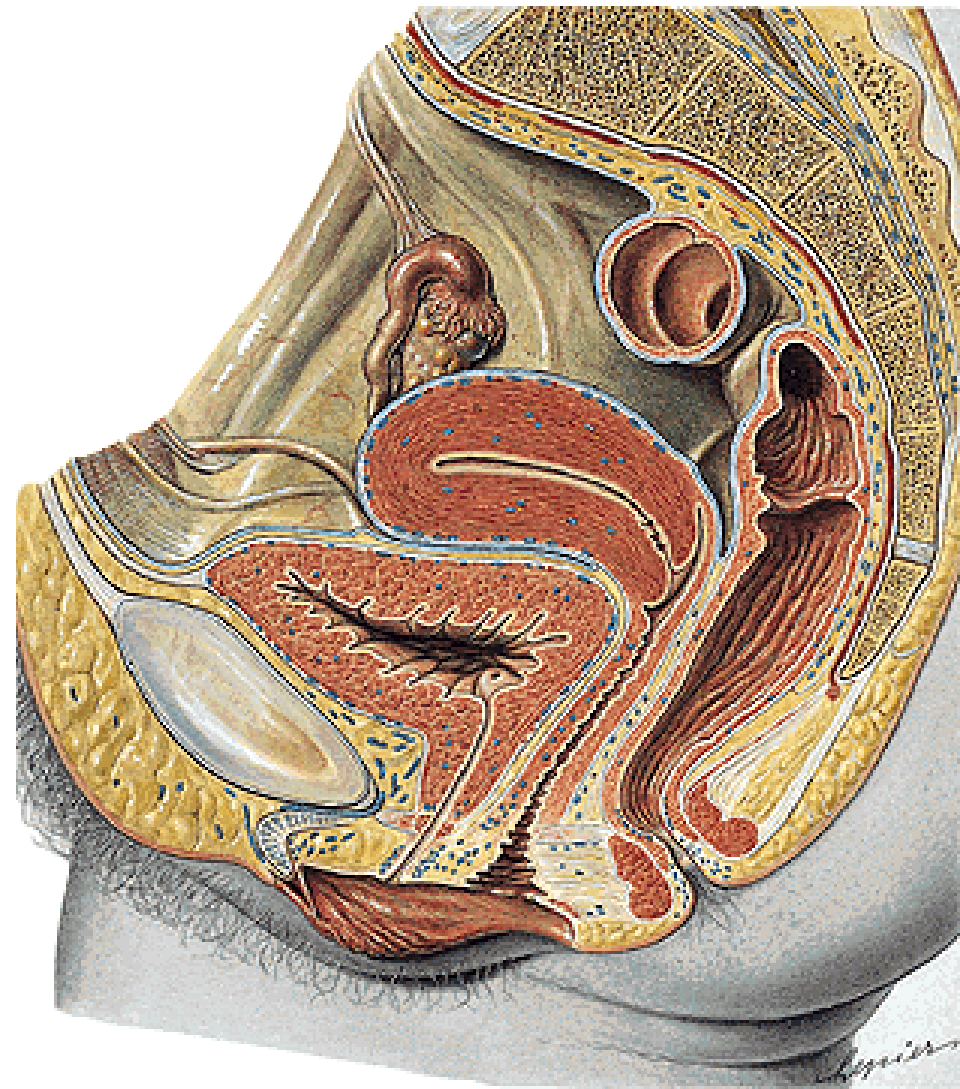
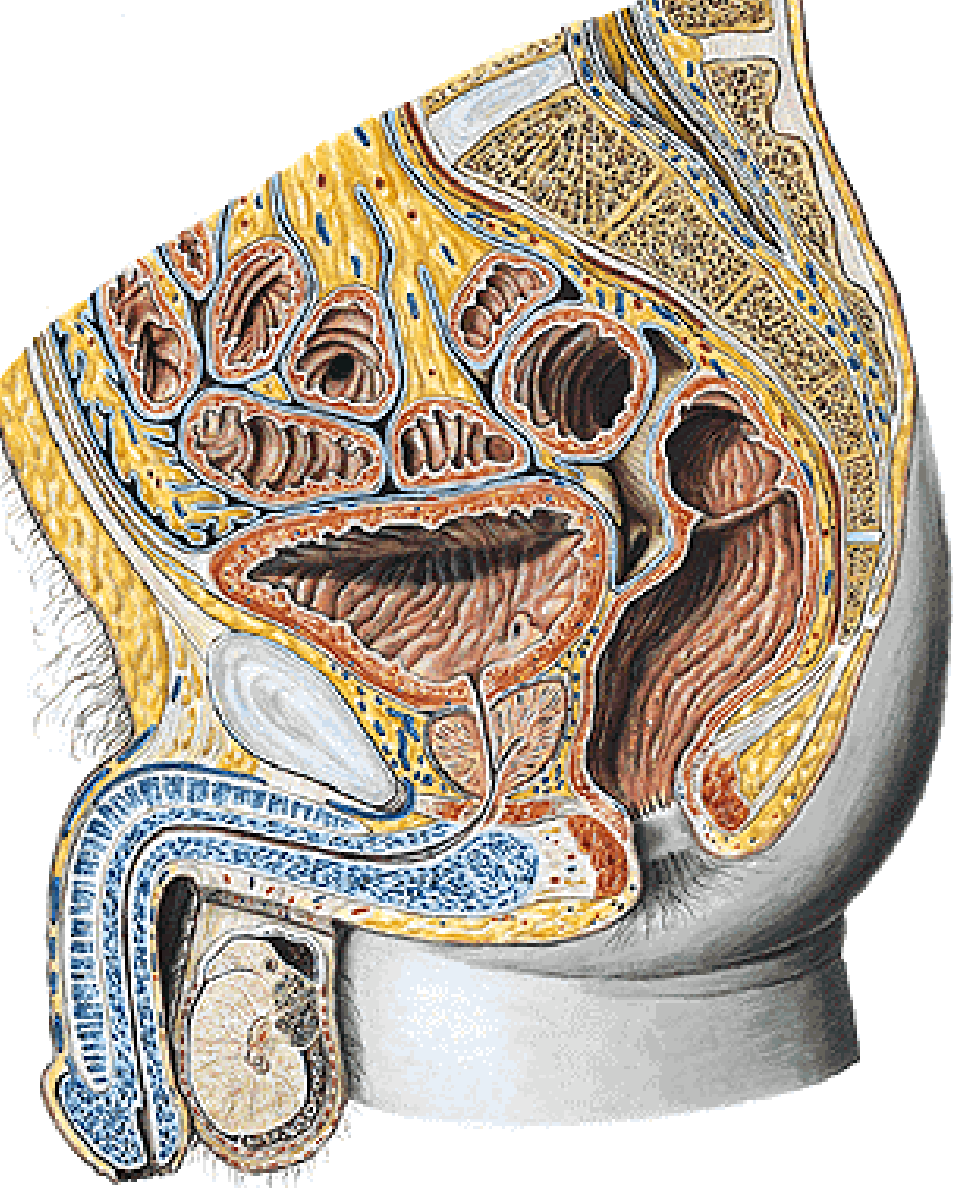
1. excavatio rectovesicalis



Median section through the female pelvis

1. excavatio rectouterina (Douglas)
2. excavatio vesicouterina





Illustrations and photographs were copied from:
Atlas der Anatomie des Menschen/Sobotta.
Putz,R., und Pabst,R. 20. Auflage. München:
Urban & Schwarzenberg, 1993
Netter: Interactive Atlas of Human Anatomy.
Windows Version 2.0
Čihák R: Anatomie 2 (Splanchnologia). Avicenum,
zdravotnické nakladatelství, Praha, 1988.