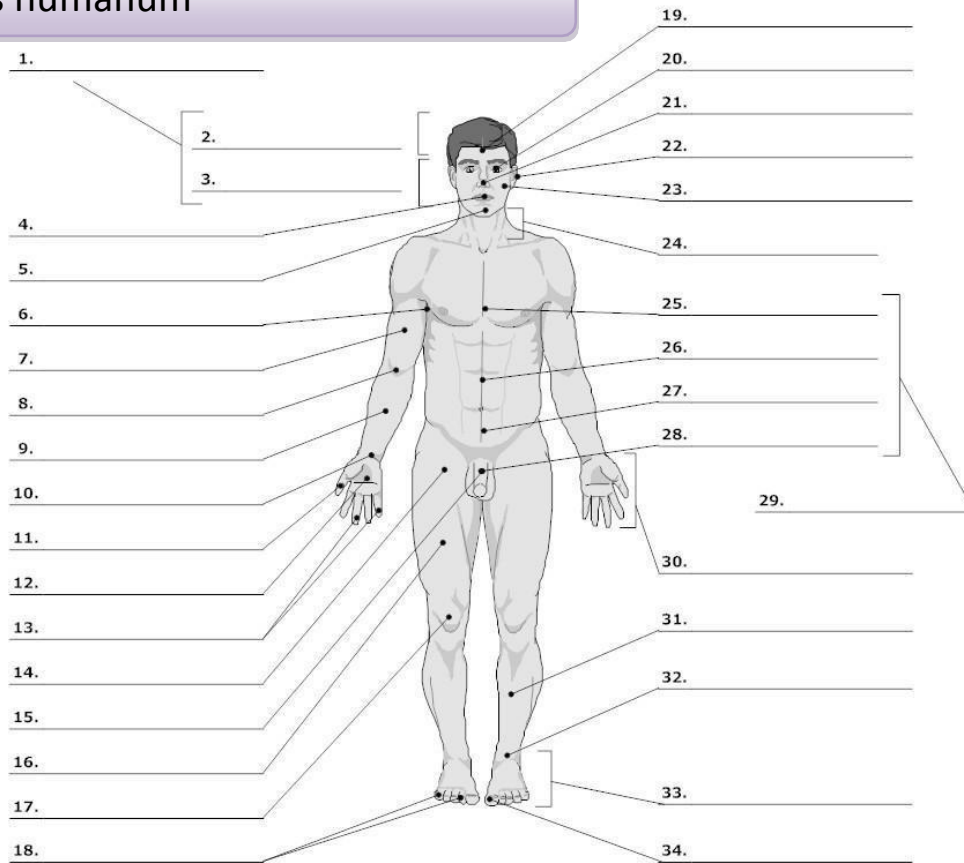


Corpus humanum

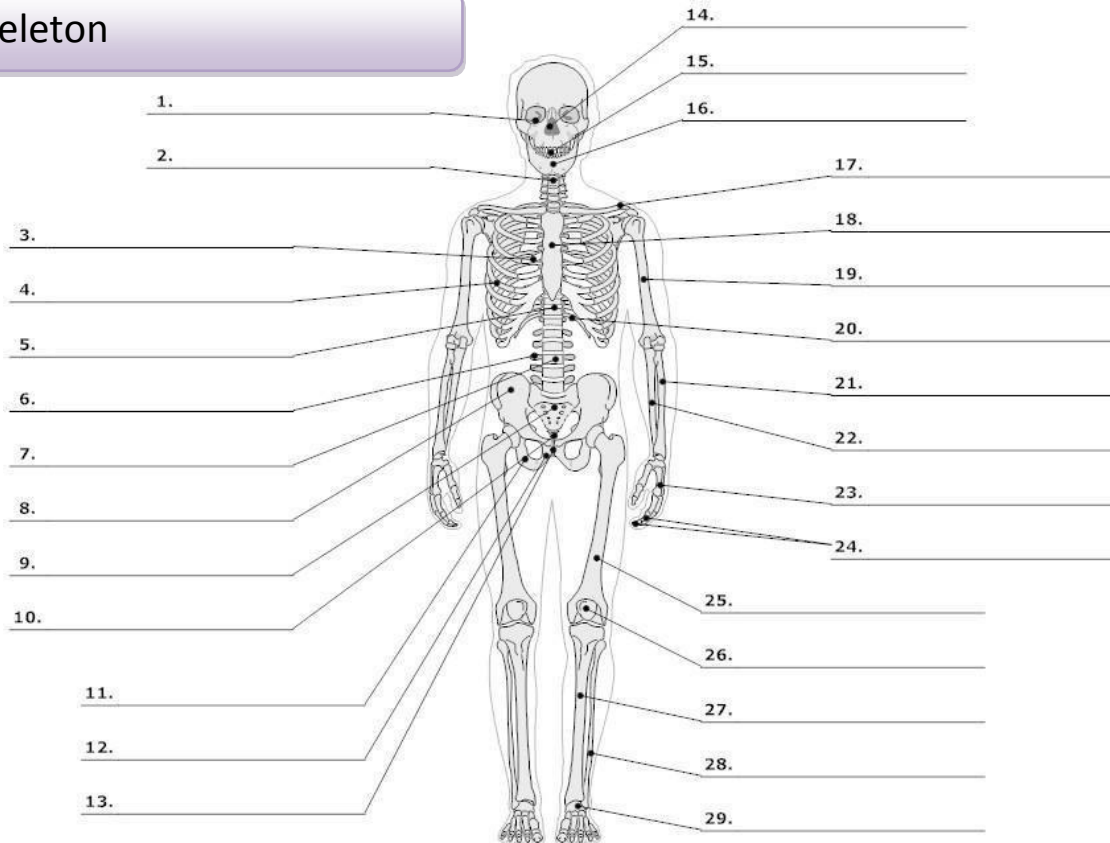


LIFEART Collection Images Copyright © 1999-2001 by Lippincott Williams & Wilkins, Baltimore, MD

0. corpus, oris, n.	body	16. femur, oris, n.	thigh, femur
cutis, is, f.	skin	17. genu, us, n.	knee
1. caput, itis, n.	head	19. frons, frontis, f.	forehead
2. capilli, orum, m.	hair	20. oculus, i, m.	eye
3. facies, ei, f.	face	21. nasus, i, m.	nose
4. os, oris, n.	mouth	22. auris, is, f.	ear
lingua, ae, f.	tongue	23. bucca, ae, f.	cheek
5. mentum, i, n.	chin	24. collum, i, n.	neck (mostly with bones)
6. axilla, ae, f.	armpit, axilla	cervix, icis, f.	neck (with soft tissues)
7. brachium, ii, n.	upper arm, brachium	25. pectus, oris, n.	chest
8. cubitus, i, m.	elbow	26. abdomen, inis, n.	belly, abdomen
9. antebrachium, ii, n.	forearm	27. hypogastrium, ii, n.	hypogastrium
10. carpus, i, m.	wrist	29. truncus, i, m.	trunk
11. pollex, icis, m.	thumb	30. manus, us, f.	hand
12. palma, ae, f.	palm (of the hand)	31. crus, cruris, n.	lower leg, shank
13., 18. digitus, i, m.	finger	32. tarsus, i, m.	tarsus
14. sulcus, i, m. ¹	fold, groove	talus, i, m.	anklebone, talus
15., 28. penis, is m.	penis	33. pes, pedis, m.	foot
		34. hallux, ucis, m.	big toe

¹ sulcus glutealis

Skeleton



LifeART Collection Images Copyright © 1989-2001 by Lippincott Williams & Wilkins, Baltimore, MD

0.	skeleton, i, n.	skeleton	scapula, ae, f.	shoulder blade
	os, ossis, n.	bone	18. sternum, i, n.	breastbone
	cranium, ii, n.	skull	19. humerus, i, m.	arm bone, humerus
1.	orbita, ae, f.	orbit	20. arcus, us, m.²	arch
2.	collum, i, n.	neck (mostly with bones)	21. radius, ii, m.	radial bone, radius
	cervix, icis, f.	neck, cervix (with soft tissues)	22. ulna, ae, f.	elbow bone
3.	thorax, acis, m.	thorax (chest with ribs)	23. metacarpus, i, m.	metacarpus
4.	costa, ae, f.	rib	24. phalanx, gis, f.	wrist
5.	discus, i, m.	(vertebral) disc	25. femur, oris, n.	finger bone
6.	processus, us, m.	process (protuberance)	26. patella, ae, f.	thighbone, femur
7.	vertebra, ae, f.	vertebra	27. tibia, ae, f.	kneecap
8.	pelvis, is, f.	pelvis	28. fibula, ae, f.	shinbone
9.	coxa, ae, f.	hip, hip joint	29. metatarsus, i, m.	calf bone
10.	ilium, ii, n.	ilium		metatarsus
11.	os sacrum*	sacral bone		
12.	coccyx, gis, f.	tailbone, coccyx		
13.	ischium, ii, n.	ischium		
14.	os pubis*	pubic bone		
15.	symphysis, is, f.	symphysis		
16.	nasus, i, m.	nose		
17.	dens, ntis, m.	tooth		
	mandibula, ae, f.	lower jaw		
	clavicula, ae, f.	collarbone, clavicle		

² arcus costalis

CLASSIFICATION OF NOUNS: *An Overview*

DECLENSION	1 st	2 nd	3 rd	4 th	5 th
GENITIVE ENDING	-ae (-es)	-i	-(?)-is	-us	-ei
GENDER <i>exceptions</i>	f <i>m</i>	m, n <i>f</i>	m, f, n	m, n <i>f</i>	f
EXAMPLE	coxa, ae, f. chole, es, f. diabetes, ae, m.	humerus, i, m. cancer, i, m. diameter, tri, f. cranium, ii, n.	coccyx, gis, f. dens, dentis, m. femur, oris, n. pelvis, is, f. cartilago, ginis, f. caput, itis, n. corpus, oris, n. pulmo, onis, m. ren, renis, m. cervix, icis, f.	arcus, us, m. manus, is, f. genu, us, n.	facies, ei, f.