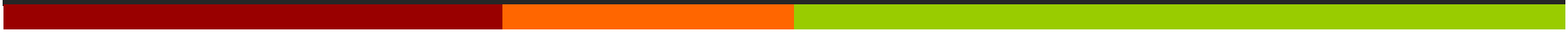



Comparison of Adjectives



1. SUPERIOR OR SUPERIUS?**MAIOR OR MAIUS?****ANTERIOR OR ANTERIUS?**

Vena cava

superior

Cornu

maius

Arteria

anterior

Membrum

superius

Ductus

maior

Ductus

anterior

Extremitas

superior

Ala

maior

Segmentum

anterius

Palpebra

superior

Musculus

maior

Margo

anterior

Labium

superius

Curvatura

maior

Bronchus

anterior

Facies

superior

Flexura

maior

Nucleus

anterior

Meatus

superior

Fossa

maior

Cornu

anterius

Arteria

superior

Foramen

maius

Nodus

anterior

Plexus

superior

Tuberculum

maius

Tuberculum

anterius

Segmentum

superius

Circulatio

maior

Radix

anterior

Regio

superior

Pelvis

maior

Crus

anterius

5. GIVE THE OPPOSITE



Meatus superior

inferior

Gradus minor

major

Phalanx proximalis

distalis

Segmentum anterius

posterius

Arteria suprema

infima/ima

Anomalia minima

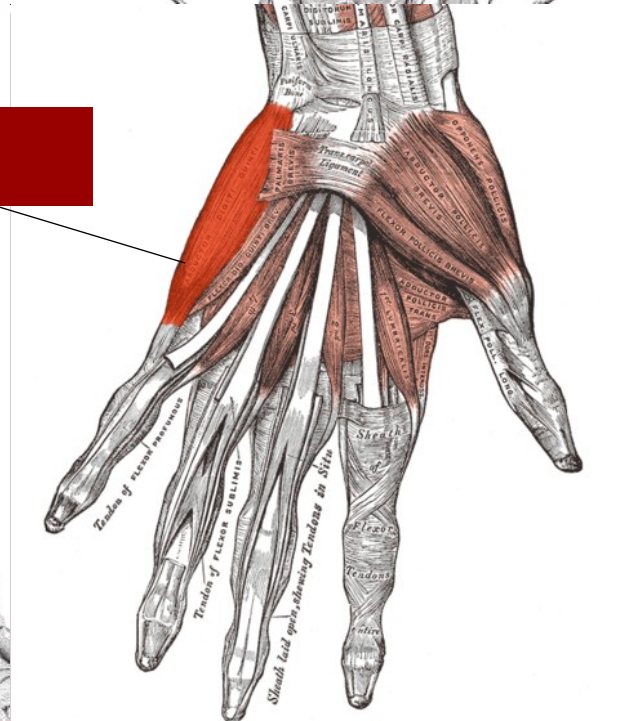
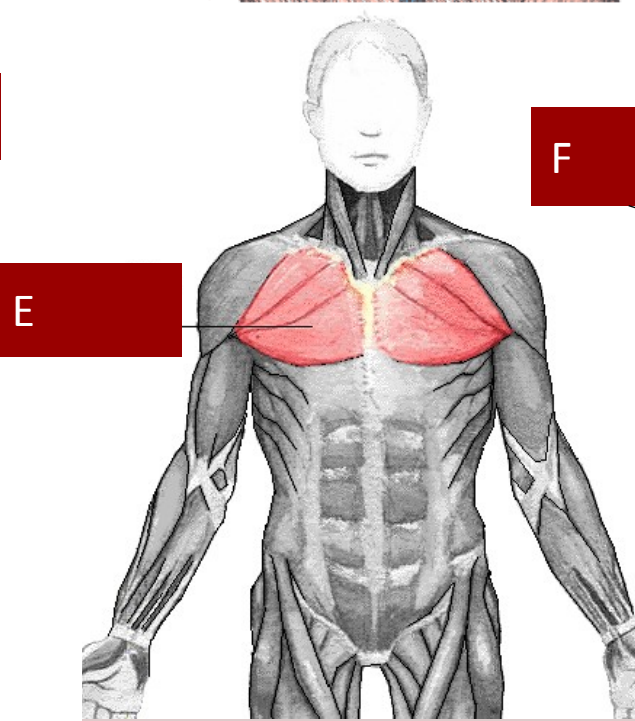
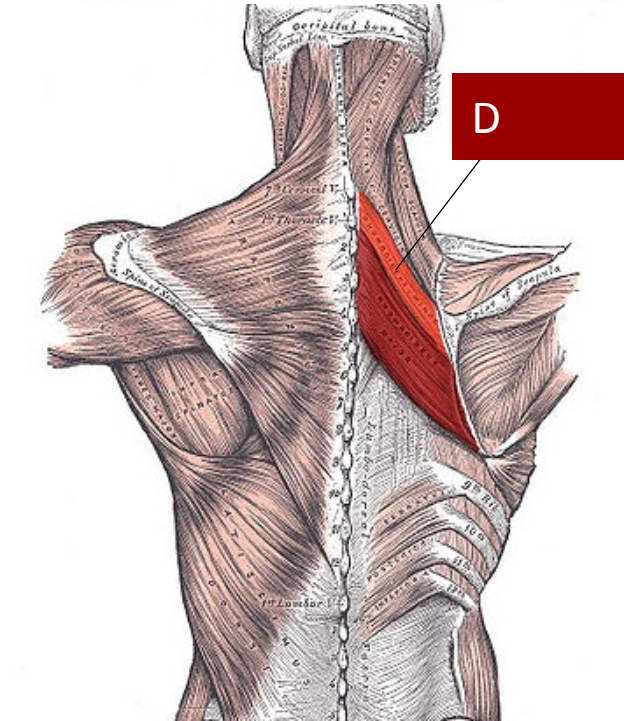
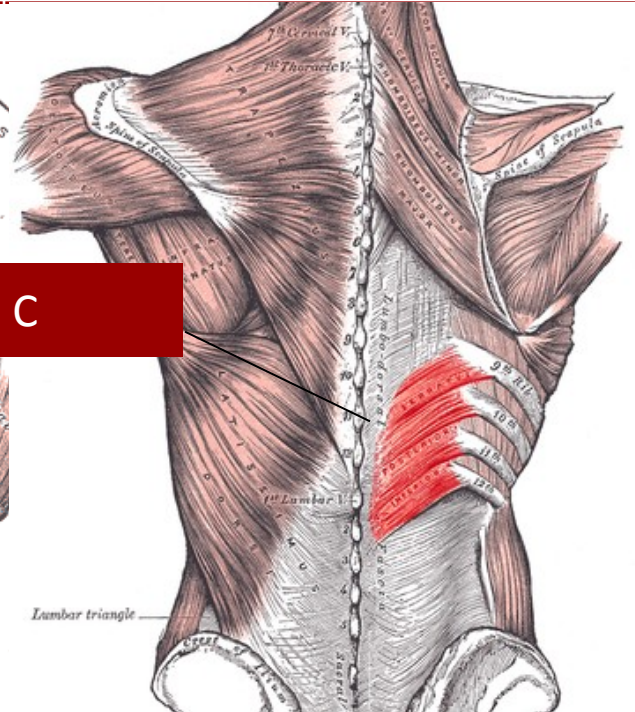
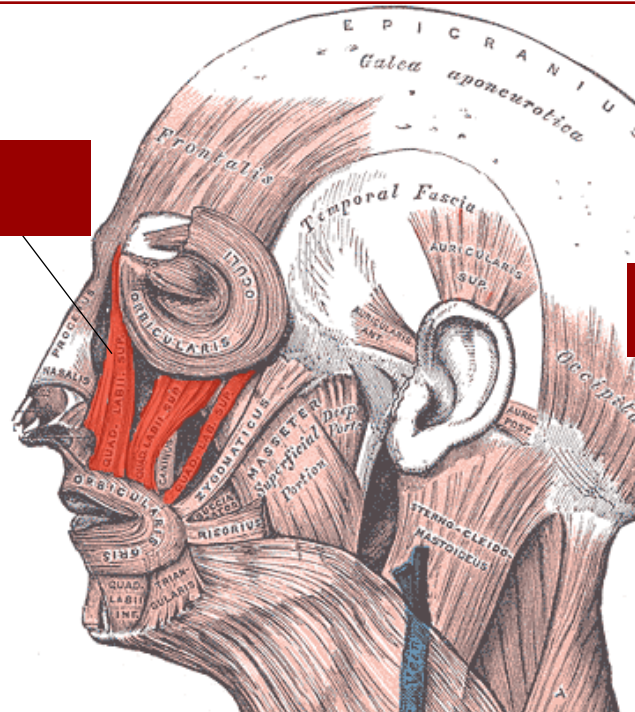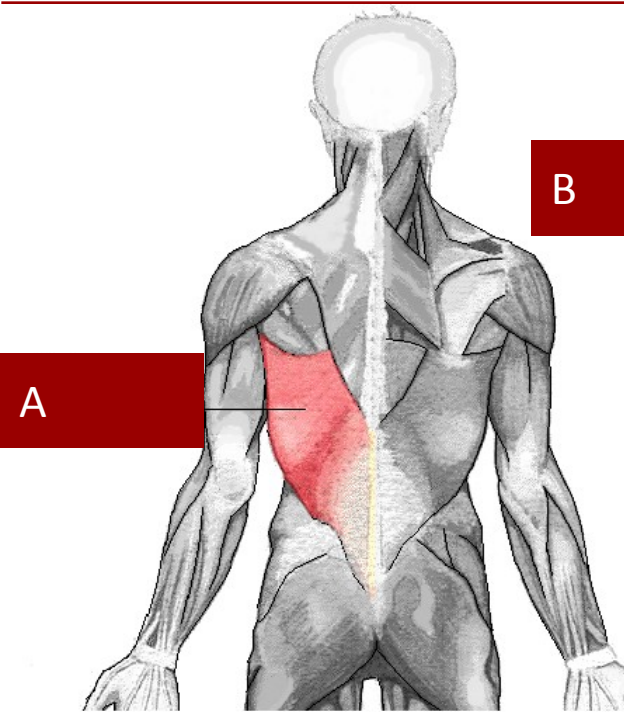
maxima

Pars externa

interna

Pulsus durus

mollis



GIVE COMPARATIVES AND SUPERLATIVES:



Laesio recens

Laesio recentior

Laesio recentissima

Musculus longus

Musculus longior

Musculus longissimus

Dosis parva

Dosis minor

Dosis minima

Os longum

Os longius

Os longissimum

Musculus magnus

Musculus major

Musculus maximus

Operatio simplex

Operatio simplicior

Operatio simplicissima

2. FORM PHRASES WITH COMPARATIVES/GIVE THE OPPOSITE

/TRANSFORM INTO ABLATIVE WITH PREPOSITION **IN**

Labium (superior)

Membra (inferior)

Tubercula (minor)

Circulatio (maior)

Dosis (maximus)

Partes (posterior)

Parietes (anterior)

Foramen (maior)

3. GIVE COMPARATIVES AND SUPERLATIVES

Cavitas parva

c. minor

c. minima

Radix lata

r. latior

r. latissima

Defectus magnus

d. major

d. maximus

Gradus parvus

g. minor

g. minimus

Operatio acuta

o. acutior

o. acutissima

Foramen parvum

f. minus

f. minimum

Pulsus frequens

p. frequentior

p. frequentissimus

Os breve

o. brevius

s. brevissimum

Pars mollis

p. mollior

p. mollissima

Therapia longa

t. longior

t. longissima

Infarctus recens

i. recentior

i. recentissimus

4. PUT COMPARATIVES AND SUPERLATIVES INTO THE PLURAL

Musculi longi

longiores

longissimi

Cavitates parvae

minores

minimae

Radices latae

latiores

latissimae

Defectus magni

majores

maximi

Gradus parvi

minores

minimi

O-tiones acutae

acutiores

acutissimae

Foramina parva

minora

minima

Infarctus recentes

recentiores

recentissimi

Ossa brevia

breviora

brevissima

Partes molles

molliores

mollissimae

Therapiae longae

longiores

longissimae

6. ADD WHAT IS MISSING



- Musculus adductor minimus _____
- Musculus auricularis posterior, _____ et superior
- Musculus constrictor pharyngis _____, medius et _____
- Musculus gluteus _____, _____ et minimus
- Musculi intercostales externi, _____ et _____
- Musculus longitudinalis inferior et _____
- Musculus rectus capitis posterior minor et _____
- Musculus teres _____ et major

FILL IN WHAT IS MISSING



Fractura membri**superioris**..... /superior/

Post contusionem labii.....**inferioris**...../inferior/

Infarctus parietis.....**anterioris**...../anterior/ ventriculi cordis

Ramus**inferior**...../inferior/ arteriae

Segmenta**posteriora**...../posterior/

Cum oedemate**maiore**...../maius/

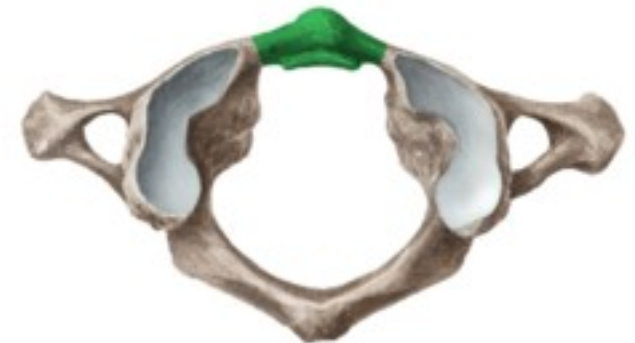
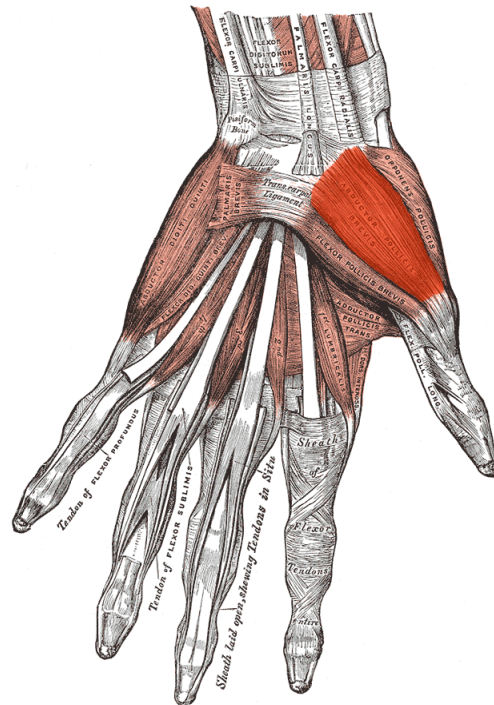
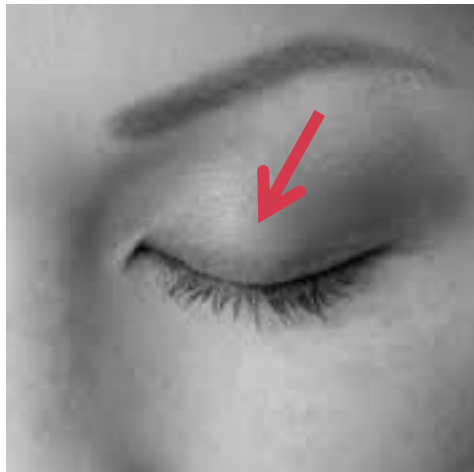
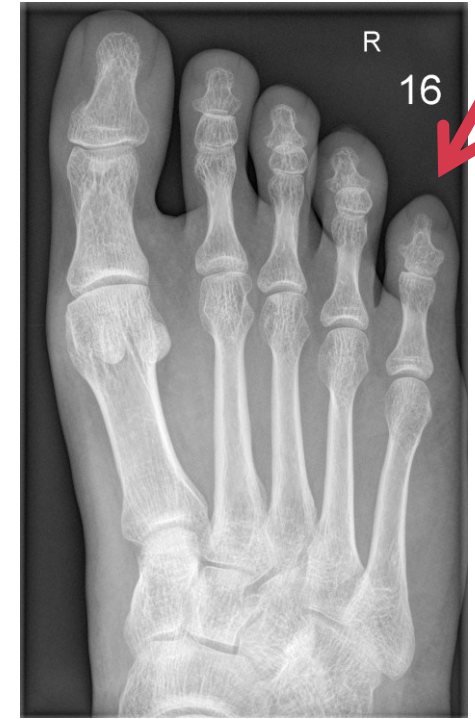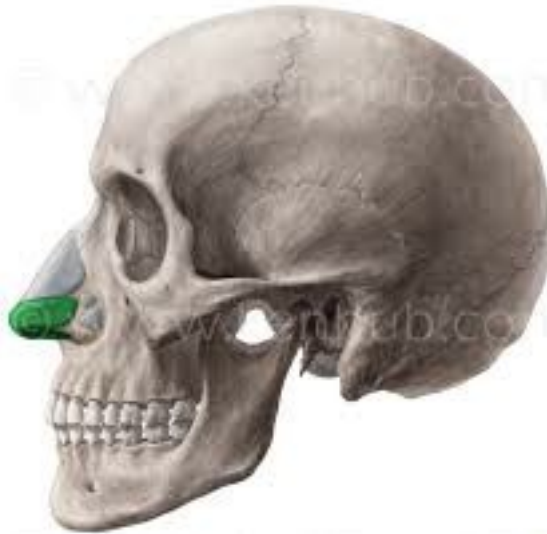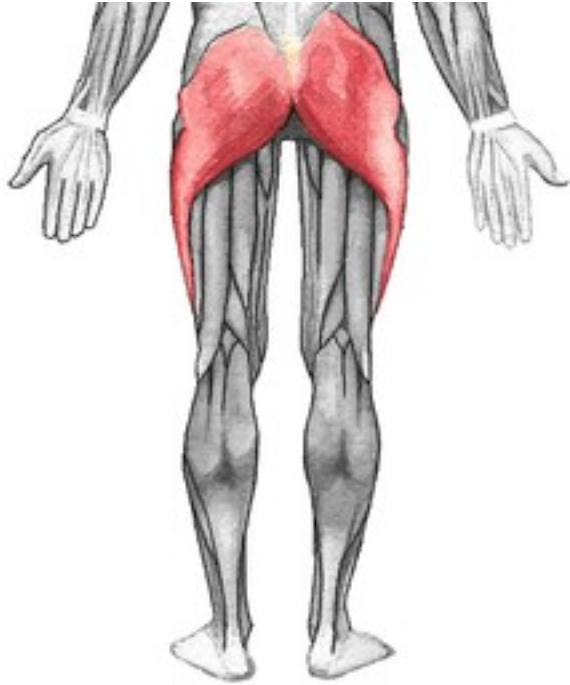
In nephritide.....**graviore**...../gravior/

Tuberculum**majus**..... /major/ et**minus**...../minor/
humeri

GIVE THE OPPOSITE TO THE UNDERLINED TERM

- | | |
|---|---------------|
| 1. muscoli membrorum <u>inferiorum</u> | superiorum |
| 2. foramen palatinum <u>majus</u> | minus |
| 3. pollex lateris <u>dextri</u> | sinistri |
| 4. musculus gluteus <u>minimus</u> | maximus |
| 5. palatum <u>molle</u> | durum |
| 6. tunica <u>externa</u> arteriae | intima |
| 7. articulatio <u>composita</u> | simplex |
| 8. arteria temporalis <u>anterior</u> | posterior |
| 9. m. transversus perinei <u>profundus</u> | superficialis |
| 10. organa genitalia <u>feminina</u> | masculina |
| 11. fascia <u>superior</u> diaphragmatis pelvis | inferior |
| 12. commissura labiorum <u>anterior</u> | posterior |
| 13. incisura ischiadica <u>minor</u> | major |
| 14. spina iliaca <u>posterior</u> superior | anterior |
| 15. pelvis <u>major</u> | minor |
| 16. pars <u>proximalis</u> urethrae masculinae | distalis |

NAME COLORED/HIGHLIGHTED STRUCTURES



READ MEDICAL RECORDS CONTAINING NUMERALS

ICD code	DIAGNOSIS
S2230	Fractura traumatica costae VI.- IX. l. dx
S2200	Fractura pathologica vertebrae Th7, Th9, Th10 et processus transversi L3
S2200	Fractura compressiva corporis vertebrae Th 5, Th9, Th11 et Th12
S6261	Fractura phalangis proximalis digiti III. manus l. sin. comminutiva aperta
S6230	Fractura ossis metacarpalis V. manus l. dx.
S9230	Fractura ossis metatarsalis II. et III. pedis l. dx. sine dislocatione
L030	Defectus chronicus cum phlegmone digiti IV. pedis l. sin.
D6919	Gangraena diabetica hallucis et digiti II. pedis l. dx.

Phlegmone, es, f. : phlegmon (purulent inflammation of the cellular or areolar tissue)

CHANGE THE WORD ORDER TO GET THE AUTHENTIC RECORD

Excoriationes pedis I. dx.
multiplices et ablatio unguis
digiti II. pedis

Luxatio digiti quinti seu
minimi manus I. sin.

Vulnus contusolacerum digiti
III. manus I. sin.

Status post amputationem
traumaticam pollicis et digiti
II. manus I. dx.

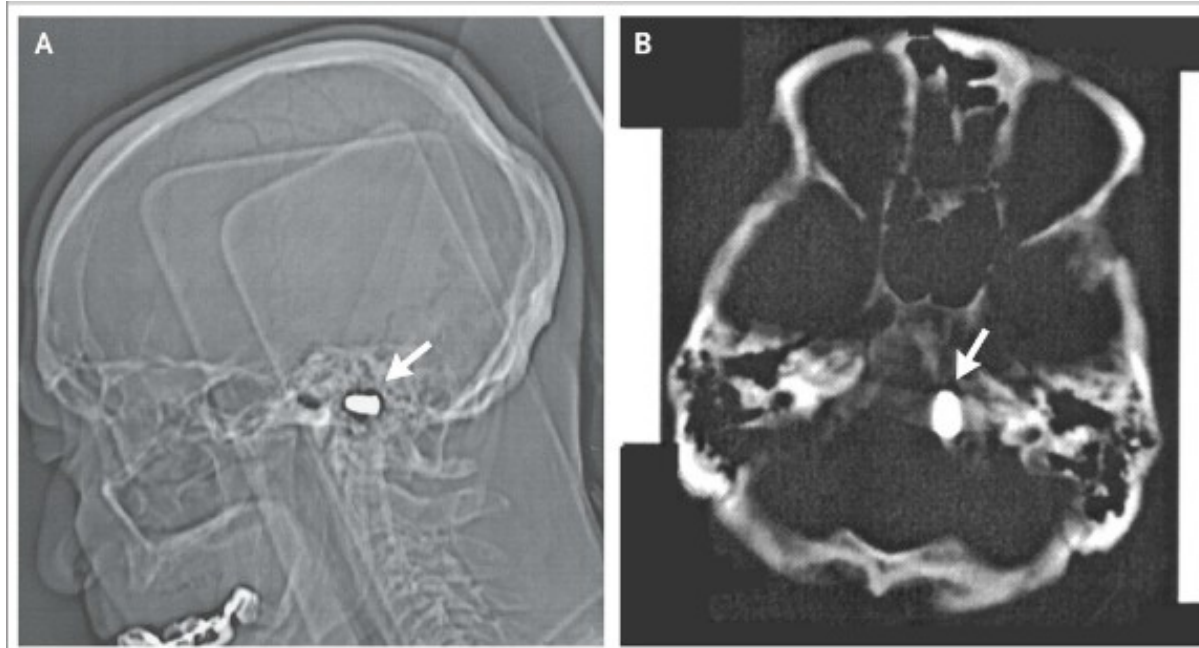
FILL IN THE MISSING ENDINGS, TRANSLATE AUTHENTIC RECORDS

1: Distorsio gen_ _ l. dx. cum excoriation_ _ _ _ multiplic_ _ _ _ et laesion_ muscul_ _ _ _ l. dx. suspect_

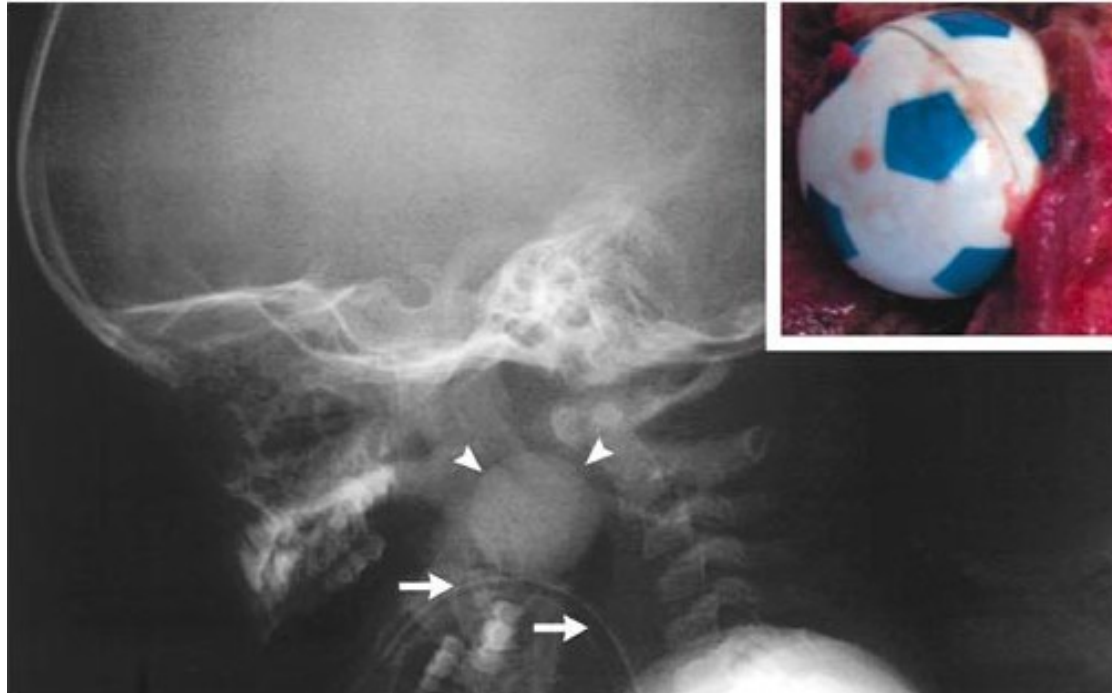
2: Laceratio lob_ superior_ _ pulmon_ _ l. sin et contusio pulmon_ _ l. dx lev_ _

3: Fractura oss_ _ _ nasal_ _ _ sine dislocation_ . Contusio faci_ _ cum haematomat_ region_ _ orbital_ _ l. sin.

4: Contusio cox_ _ l. sin. cum distension_ muscul_ _ _ _ region_ _ glute_ _ l. sin.



Cranial computed tomographic imaging revealed a *metal foreign body*, 1.2 0.7 cm, at *the left edge of the foramen magnum* in 85-year-old man. There was *no* clinical or radiographic evidence of neural *damage*. The patient revealed that at the age of 3 years he had been accidentally shot with a pistol by his older brother. The bullet had struck him just inferior to the nose, and he had lost consciousness for several hours, recovering without any specific therapy.



A three-year-old boy was playing with a plastic ball while in the backseat of a car. The father heard a gasp, saw that the child was unconscious, and suspected the child to aspirate the toy ball. Emergency personnel intubated the child, no foreign body was visualized then. The child was dead on arrival at the hospital. During the postmortem examination, a radiograph of the head and neck showed a *spherical foreign body located in the oropharynx*. The oropharynx contained a toy soccer ball 2.5 cm in diameter.