

Skeleton of the upper extremity

Marek Joukal, M.D., Ph.D.
mjoukal@med.muni.cz

Department of Anatomy, Faculty of Medicine
Masaryk University



SKELETON OF THE UPPER EXTREMITY (ossa membri superioris)

I. Bones of the shoulder girdle (cingulum membri superioris)

Clavicule

Scapula

II. Bones of the free upper extremity (ossa membri superioris liberi)

Humerus

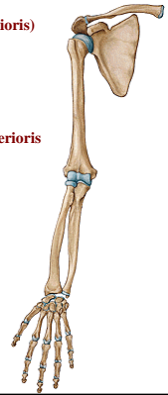
Radius

Ulna

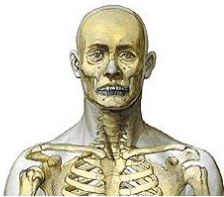Carpal bones (ossa carpi)

Metacarpal bones (ossa metacarpi)

Phalangeal bones (ossa digitorum manus)



Clavicle



Connects upper extremity with trunk

Connection with scapula

Connection with sternum

Clavicle



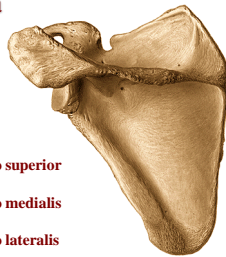
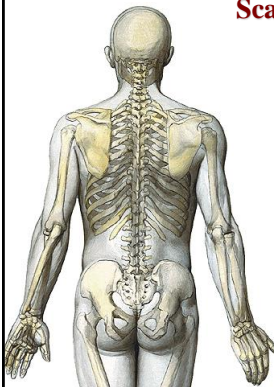
extremitas sternalis (facies articularis sternalis)

extremitas acromialis (facies articularis acromialis)

tuberositas costalis (impressio ligamenti costoclavicularis)

tuberositas coracoidea (tuberculum conoideum et linea trapezoidea)

Scapula



margo superior

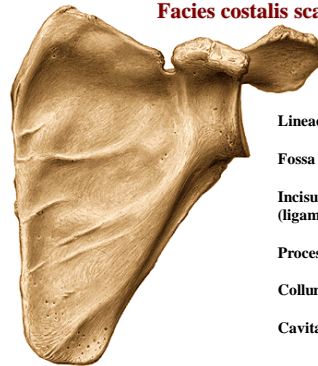
margo medialis

margo lateralis

angulus: superior, inferior, lateralis

facies: costalis, dorsalis

Facies costalis scapulae



Lineae musculares (transverae)

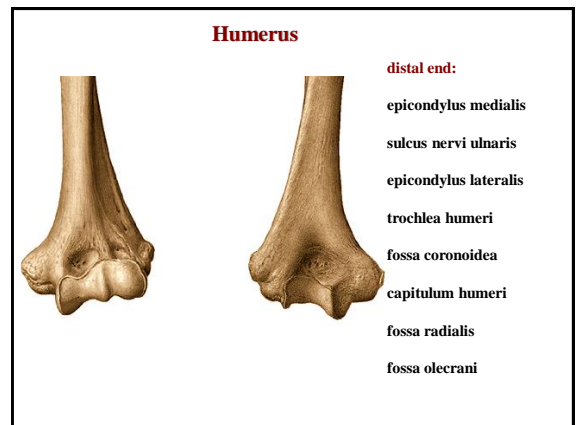
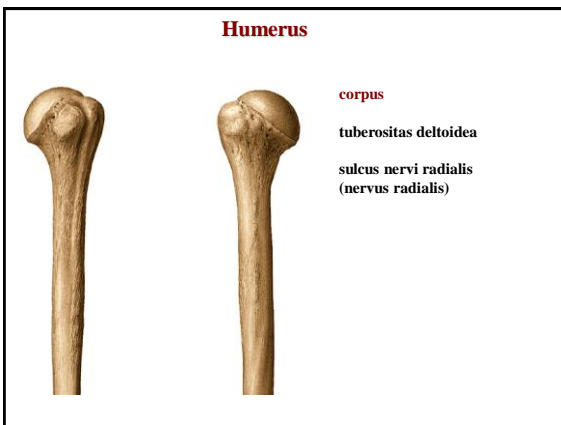
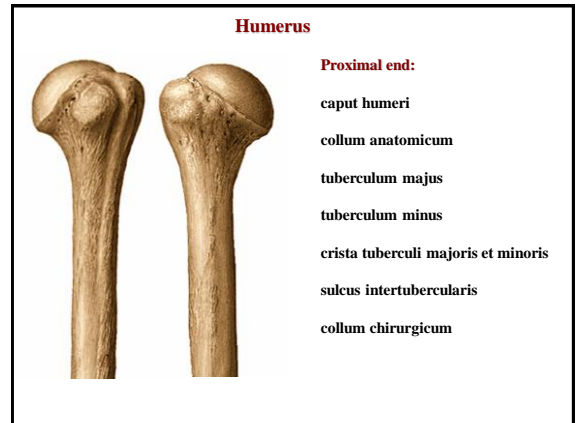
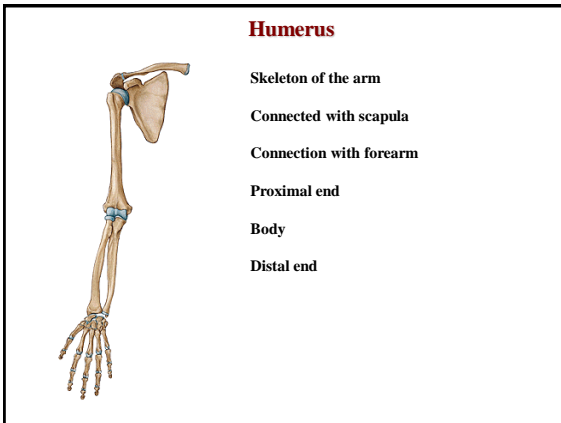
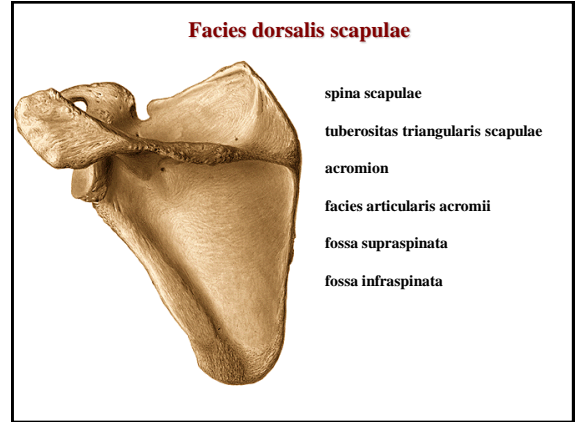
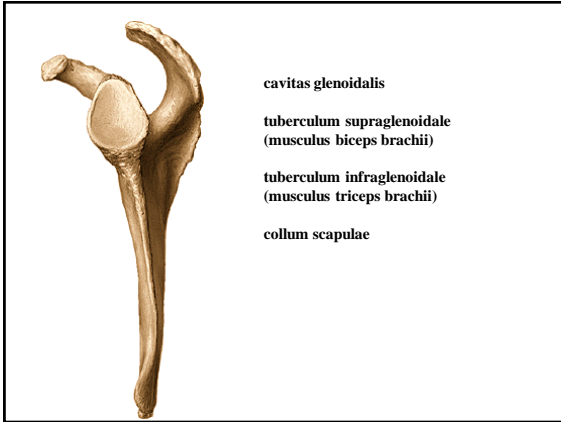Fossa subscapularis

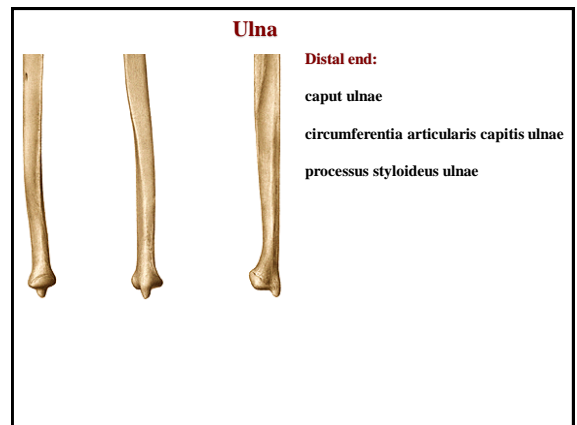
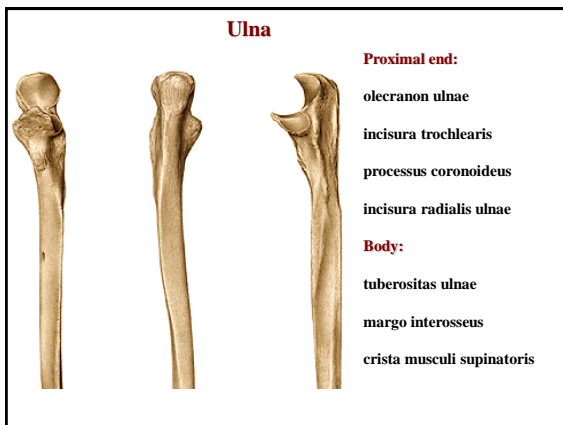
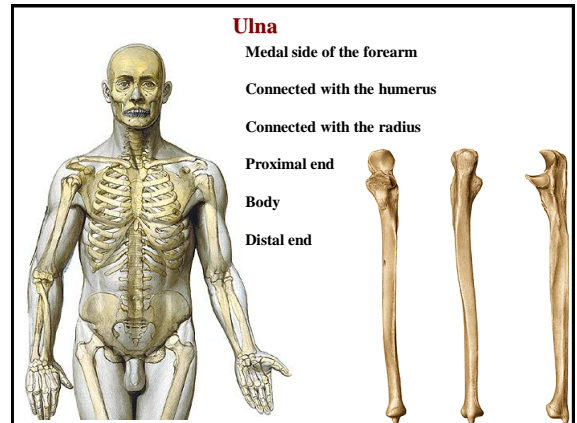
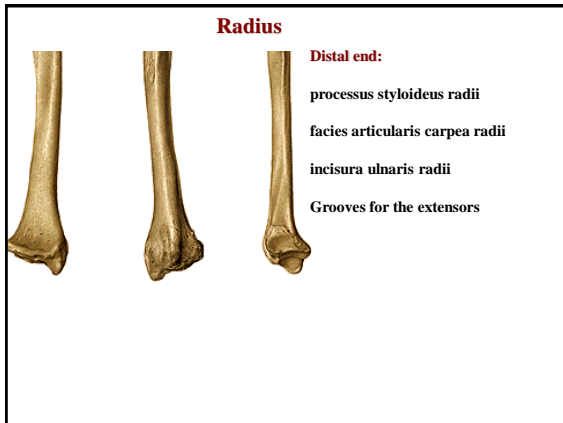
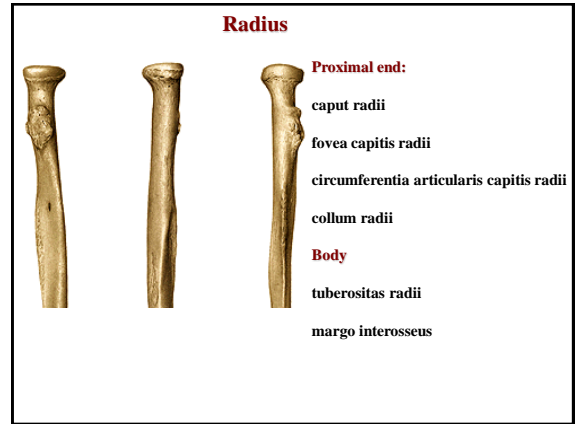
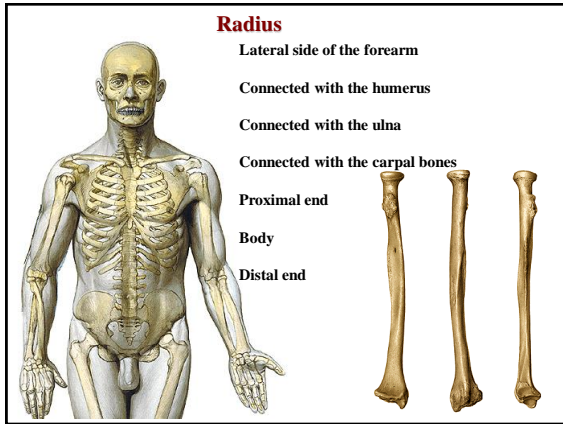
Incisura scapulae
(ligamentum transversum scapulae)

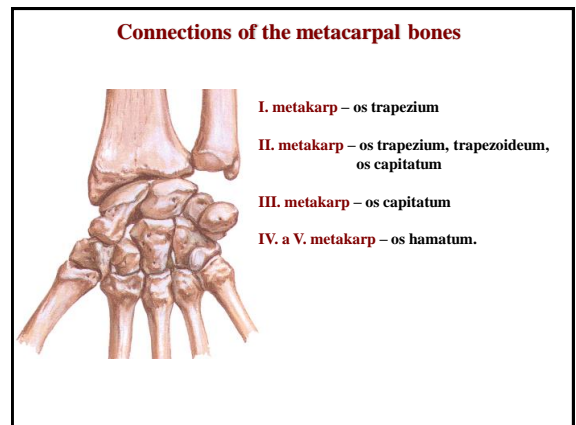
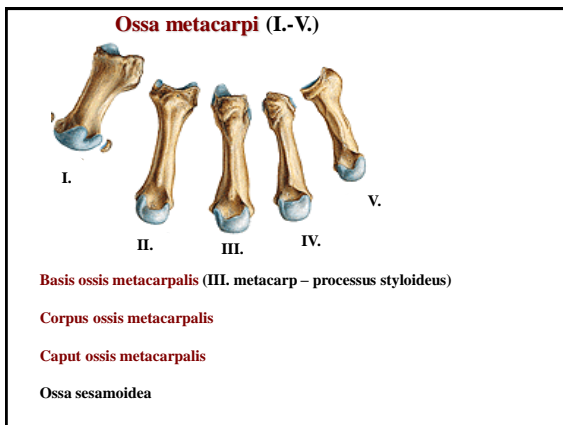
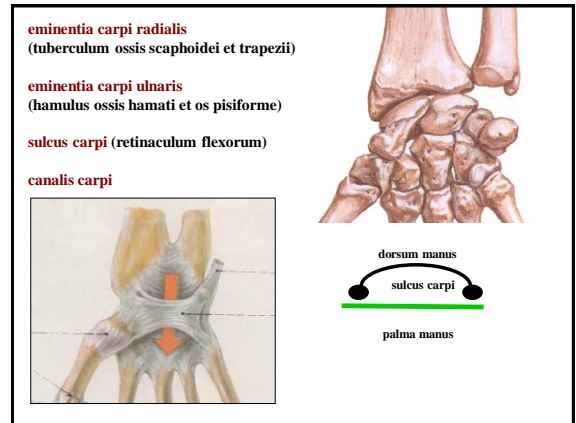
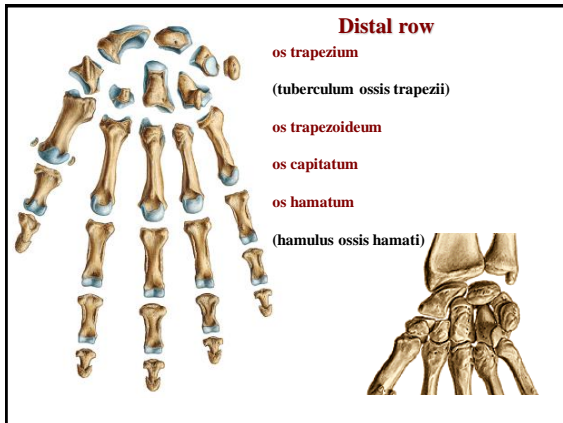
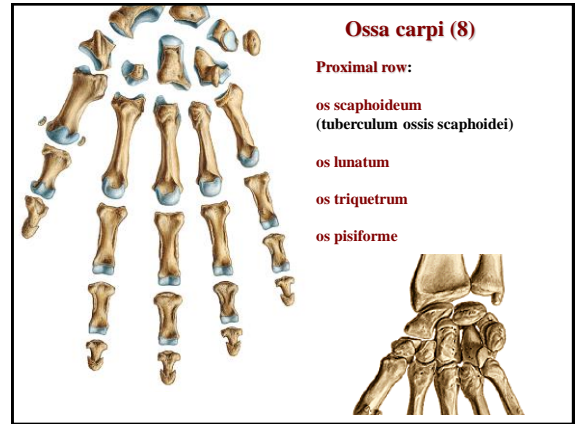
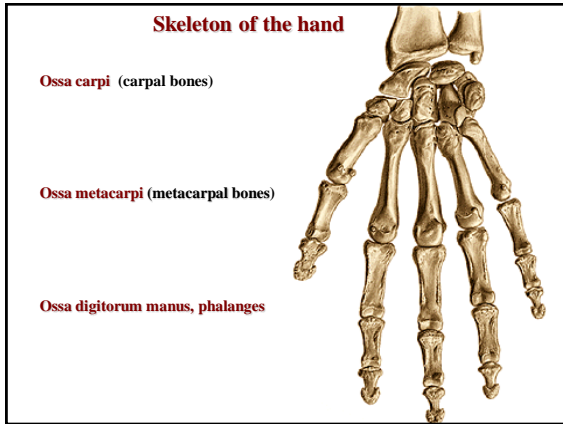
Processus coracoideus

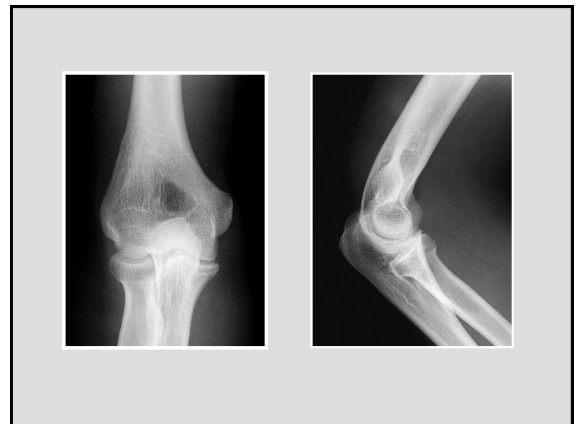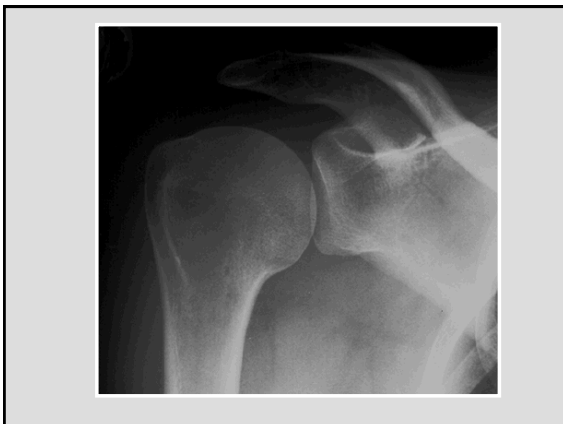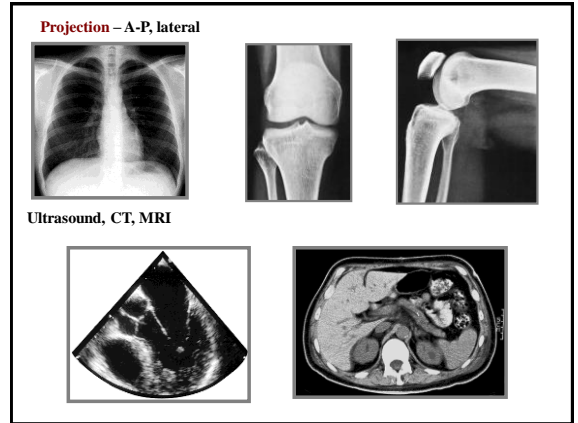
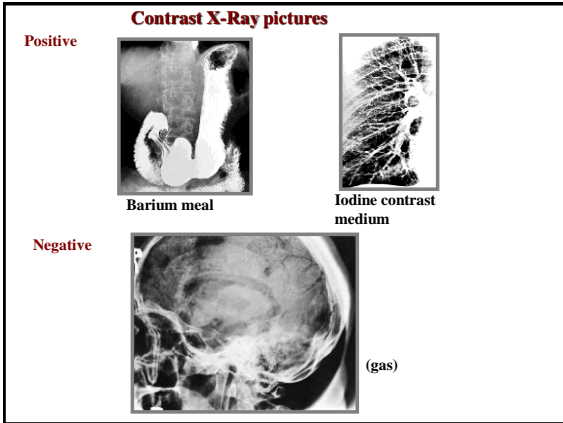
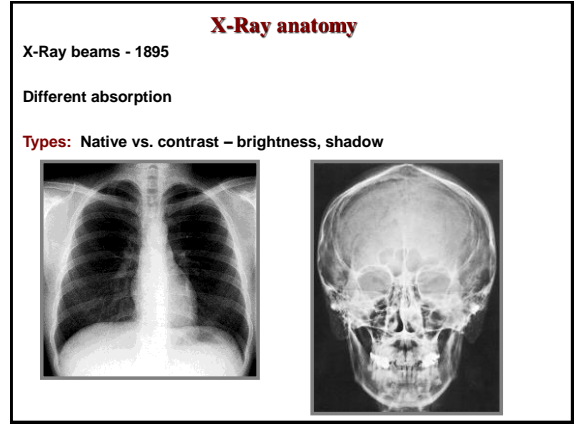
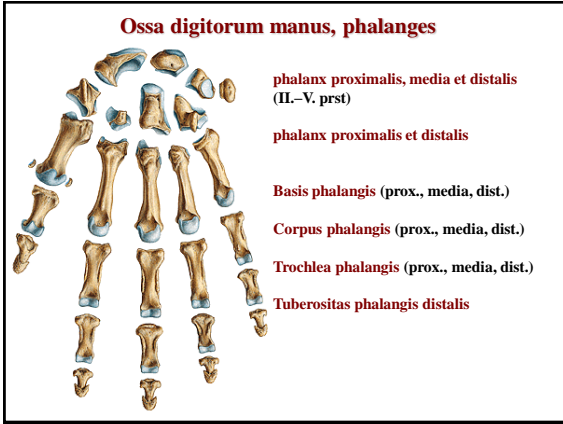
Collum scapulae

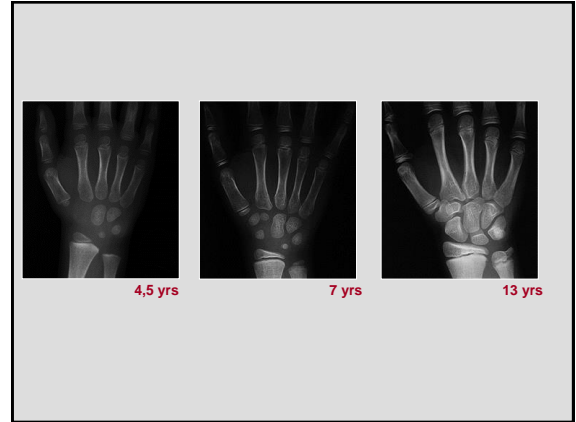
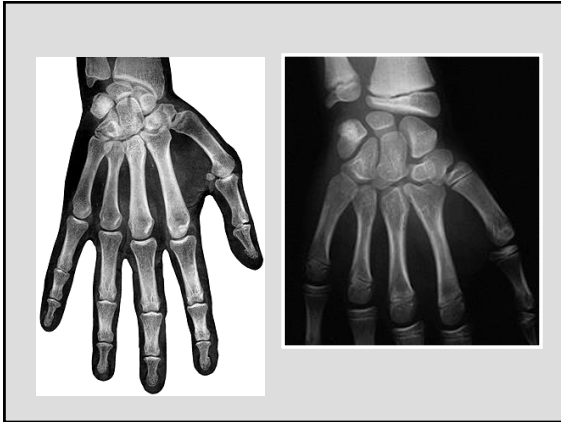
Cavitas glenoidalis











References

- Putz, R. (2008):**
Atlas of Human Anatomy Sobotta. Elsevier Books.
- Keith L. Moore, Arthur F. Dalley (2005):**
Clinically Oriented Anatomy. Williams and Wilkins.
- Platzer, W., Kahle, W., Leonhardt H. (1992):**
Locomotor system. Georg Thieme Verlag, Stuttgart, New York, 4th edition.
- Čihák, R. (1987):** Anatomie I. Avicenum, Zdravotnické nakladatelství.