


Institute for microbiology shows

# TRACING THE CULPRIT



Part nine:  
Culprits in spiral form

# Survey of topics

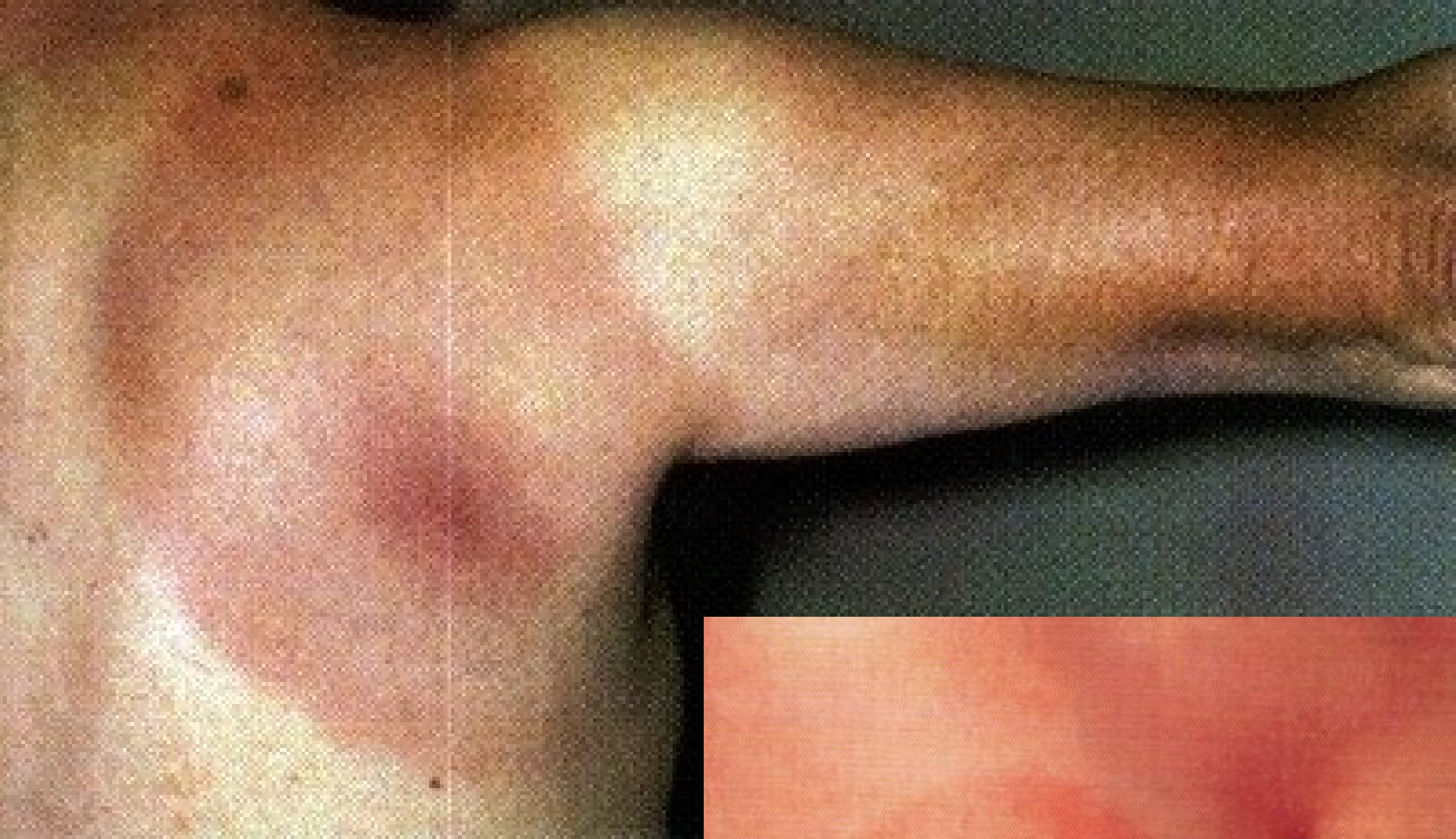Clinical characteristics of spiral bacteria

Microbiological characteristics & dg. of spirochets

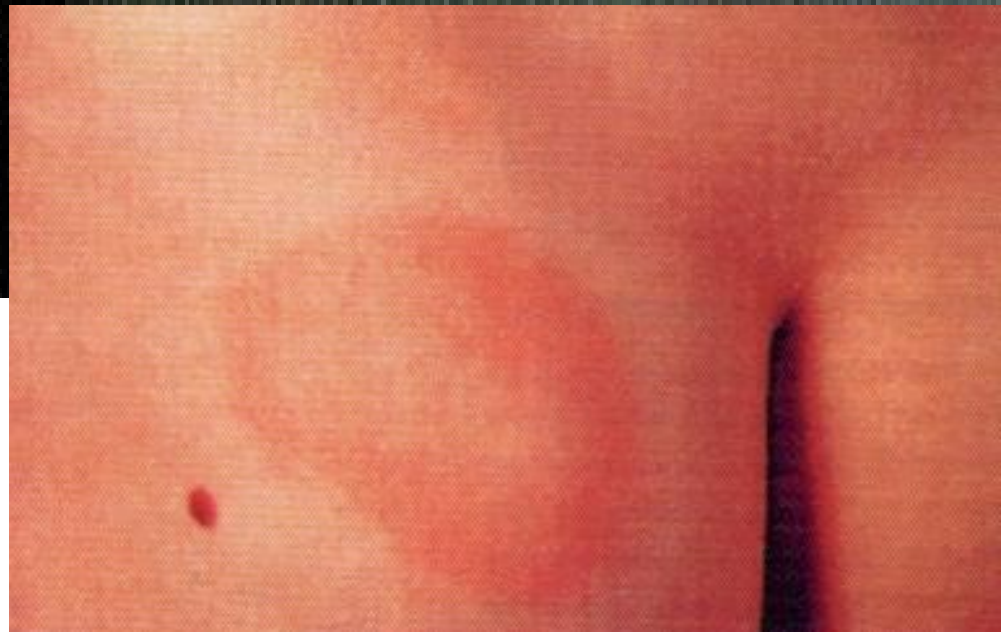# Clinical characteristics of spiral bacteria

# Story one

- Roseanne Pinkspot started to have pink spots on her body. She thought, that probably... Oh yes, several weeks ago she participated on a girl scout camp and several times during the camp she had a tick.
- Her GP sent her to children infection clinic, and experienced infection disease expert confirmed, that most likely it is the disease that Roseanne supposed. For sure, she took serum for antibody detection...



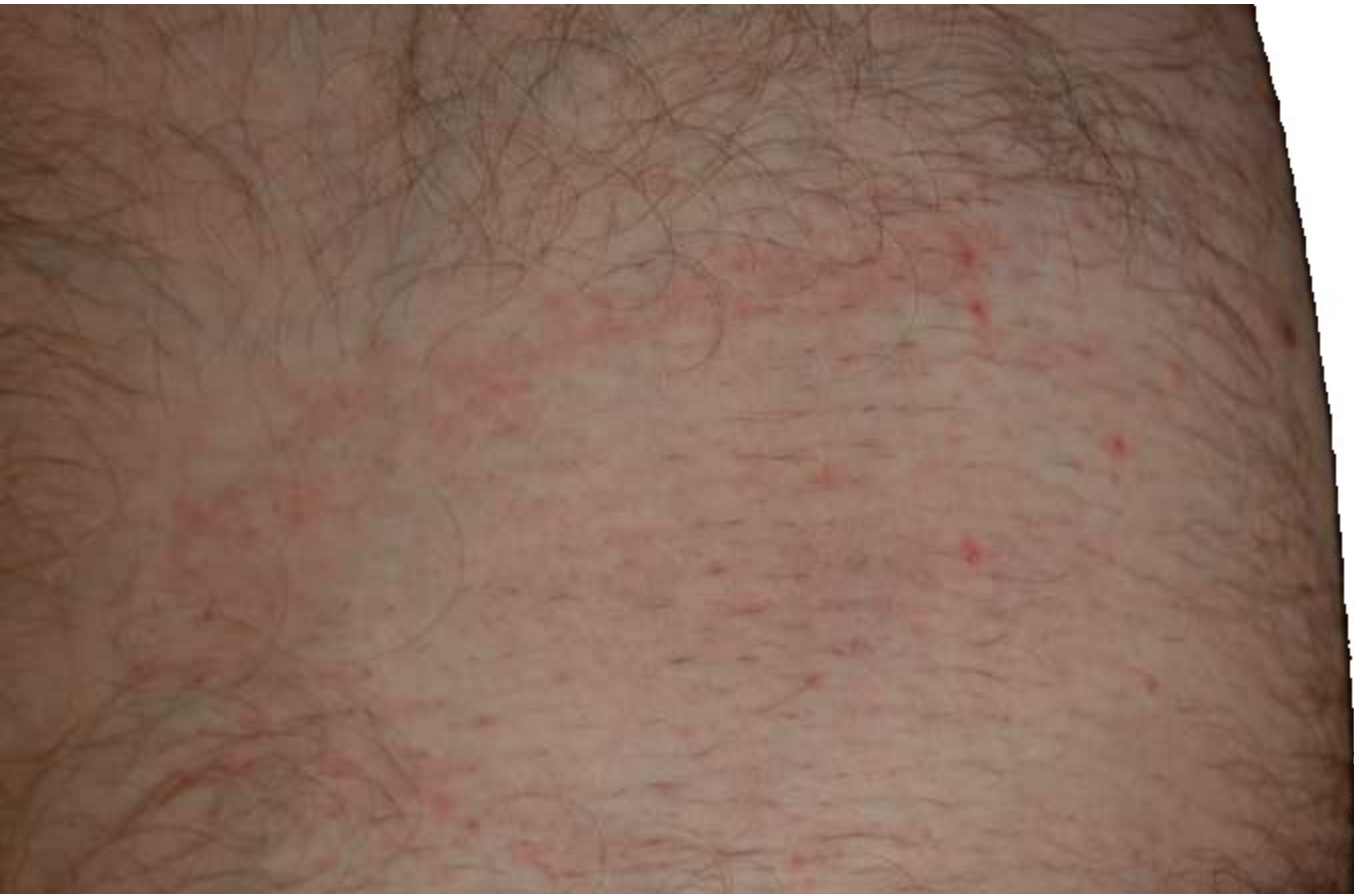[www.med.sc.edu](http://www.med.sc.edu)



[www.borreliade.de](http://www.borreliade.de)

# Erythema migrans

- This is a picture of Erythema migrans of student M. M., who kindly agreed to let it for use in education

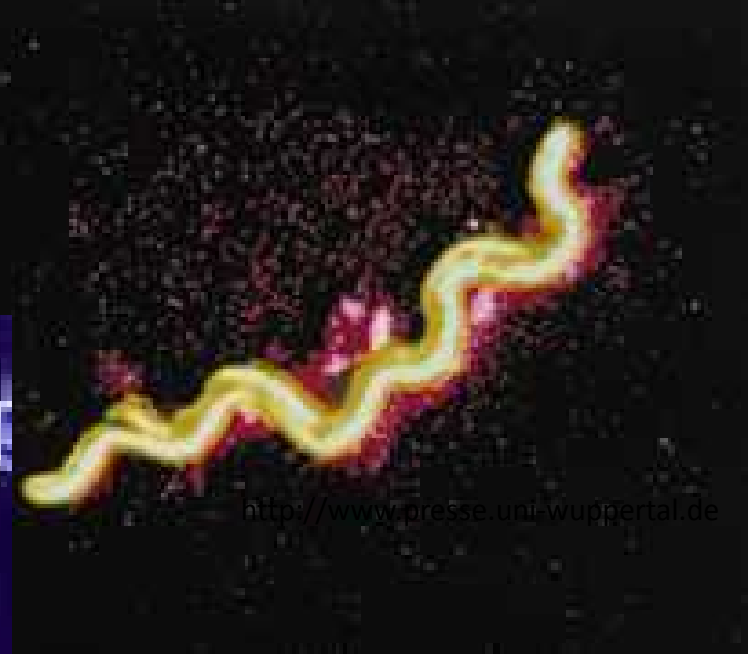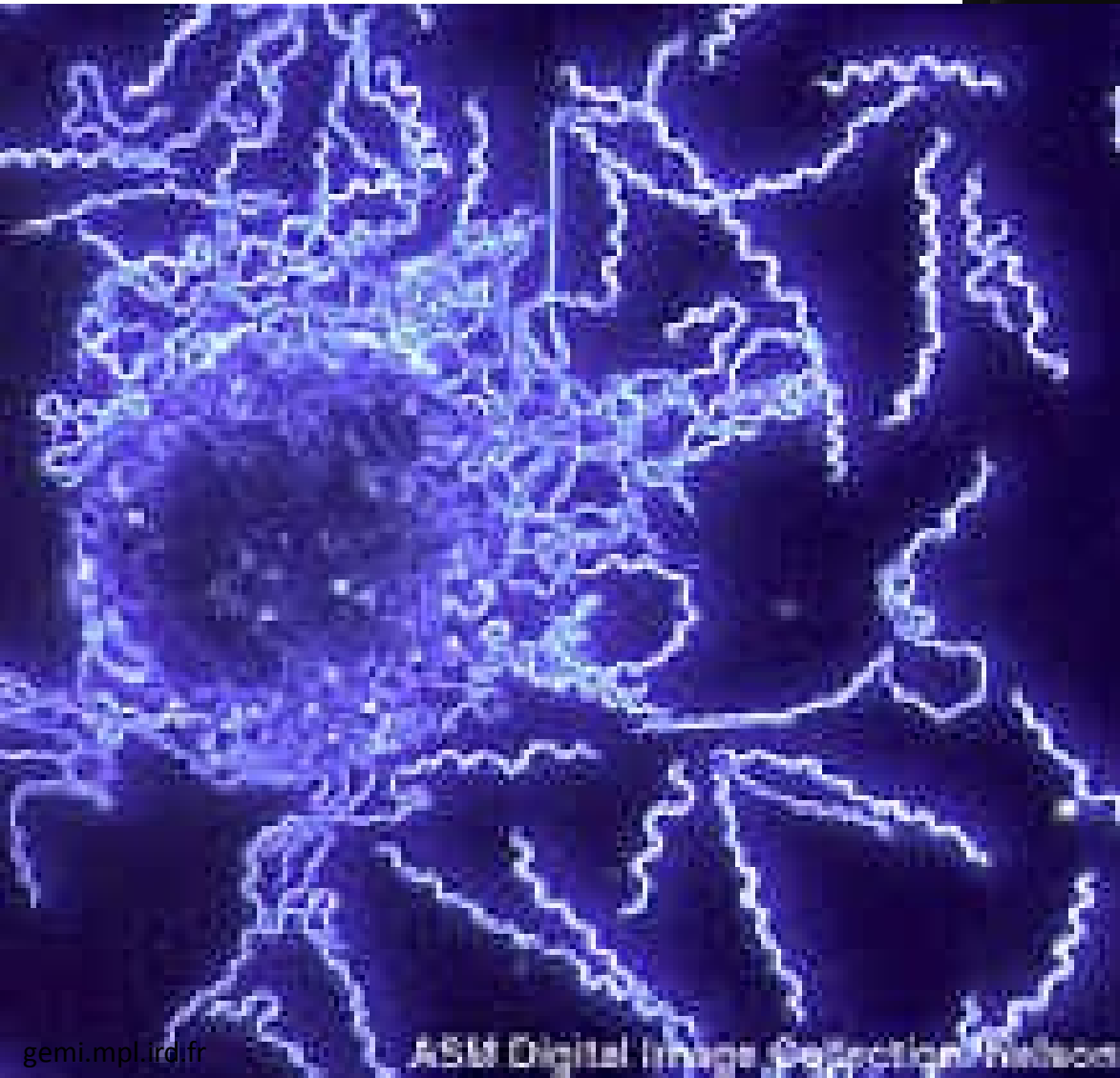




# The causative agent was


- *Borrelia afzelii*, one of borrelias, causing Lyme disease and belonging to the group *Borrelia burgdorferi sensu lato* (= „broad sense of meaning“)
- This species „in broad sense“ is divided into several genomospecies. The most important are *B. garinii*, *B. afzelii* and *B. burgdorferi sensu stricto*
- While in the USA mostly the third of them is common and joint symptomatology is common, in Europe two first borrelias are more common, and the typical disease is neuroborreliosis
- Besides Lyme diseases there exist other species causing recurrent fever (*B. duttoni*, *B. recurrentis*)

# *Borrelia burgdorferi*



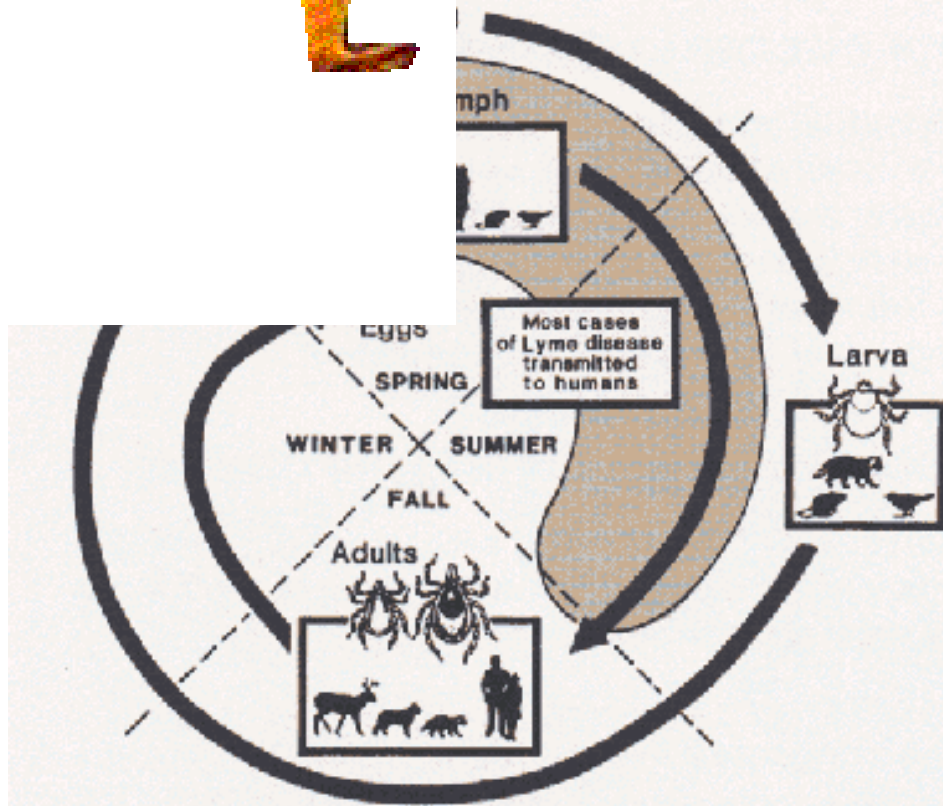
<http://www.presse.uni-wuppertal.de>



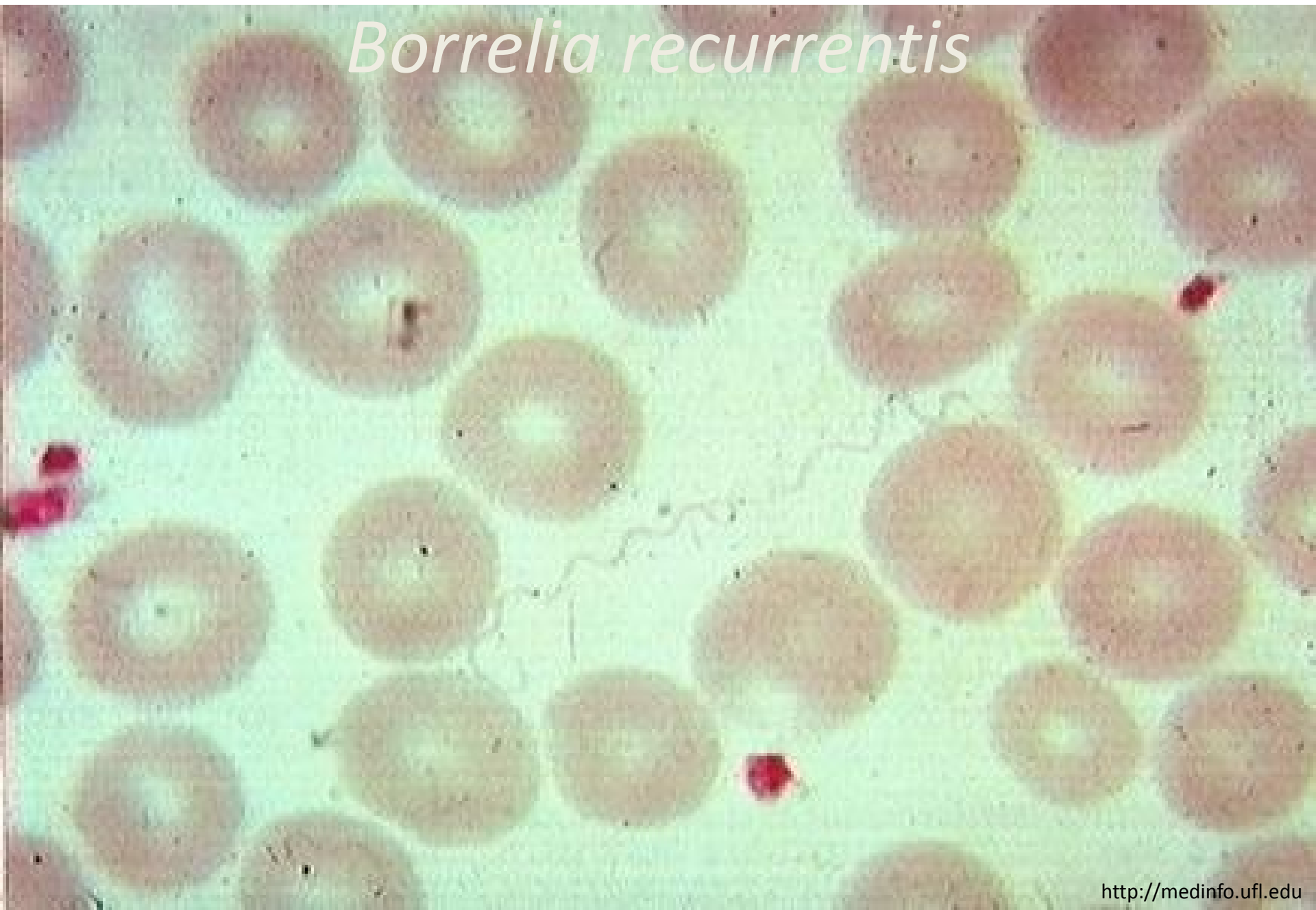


# Lyme disease – a tick borne zoonosis

## Lyme disease ticks



# *Borrelia recurrentis*



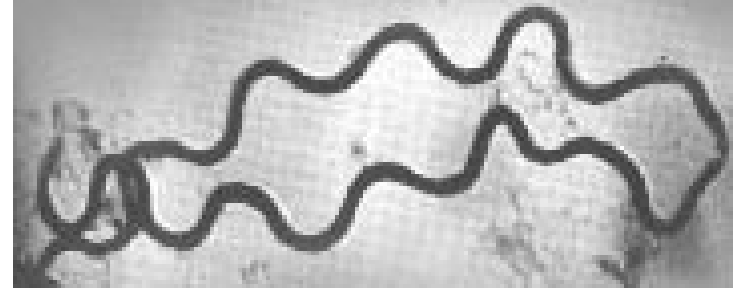
# Story two (virtual, but basis is from a real story)

- When Phyllis found, that she really needs pervitin, and more and more, she decided to earn money by her own body.
- When the client paid more, she went with him without a preservative, she used contraception and she felt more OK
- Then she fell in love and decided to have a child. She stopped the contraception and was happy. Helmut will be a good father...

# Story two – continuing

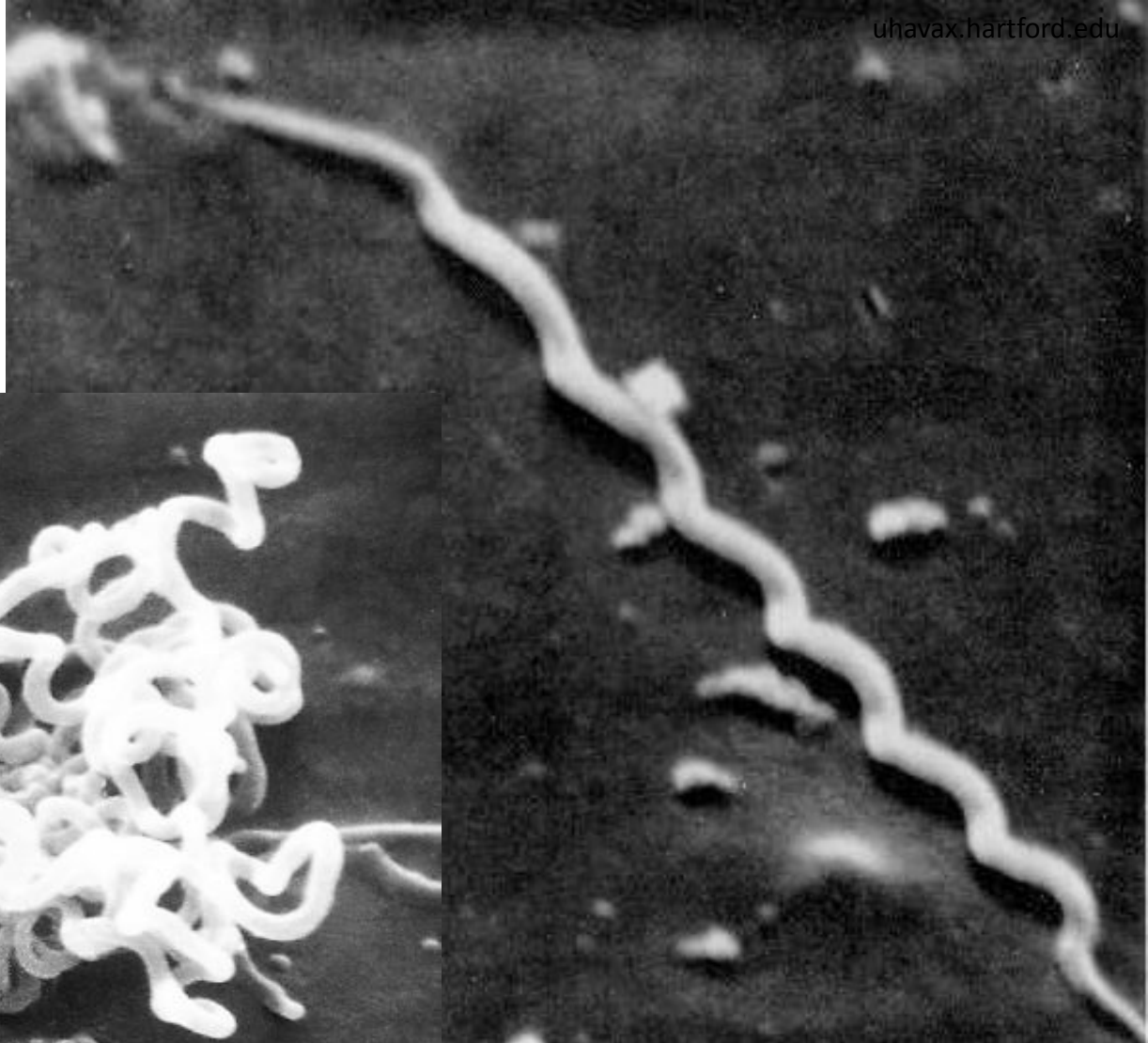
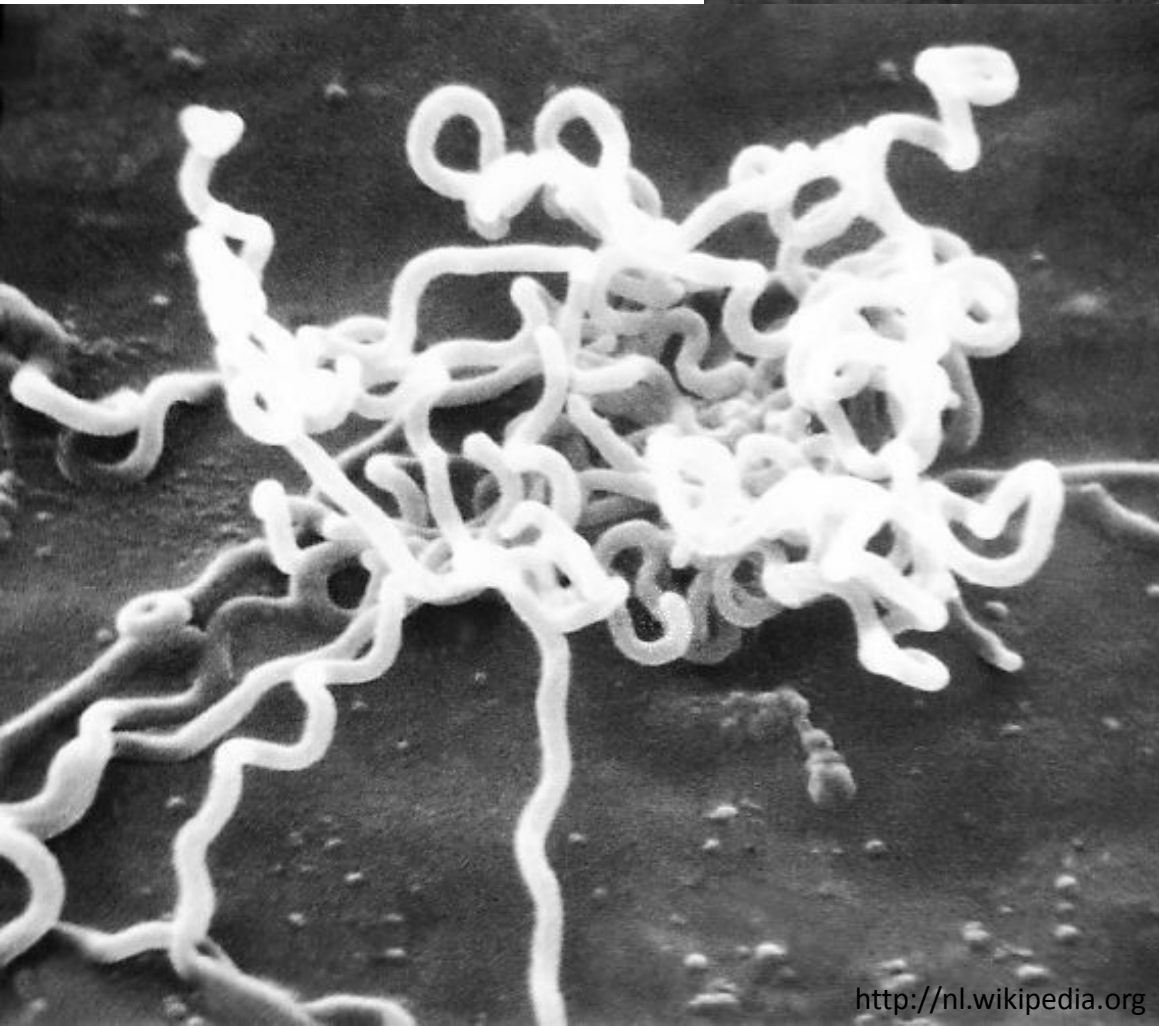
- So Phyllis was pregnant. But she found herself a genital ulcer and her gynaecologist took blood for serological examination. It was positive. Phyllis did not want interruption, it was too late and she wanted her child.
- Phyllis was treated, but the antibiotic was not chosen properly. The child was born ill and after two weeks it died because of a secondary *Klebsiella* septicaemia

# The culprit was



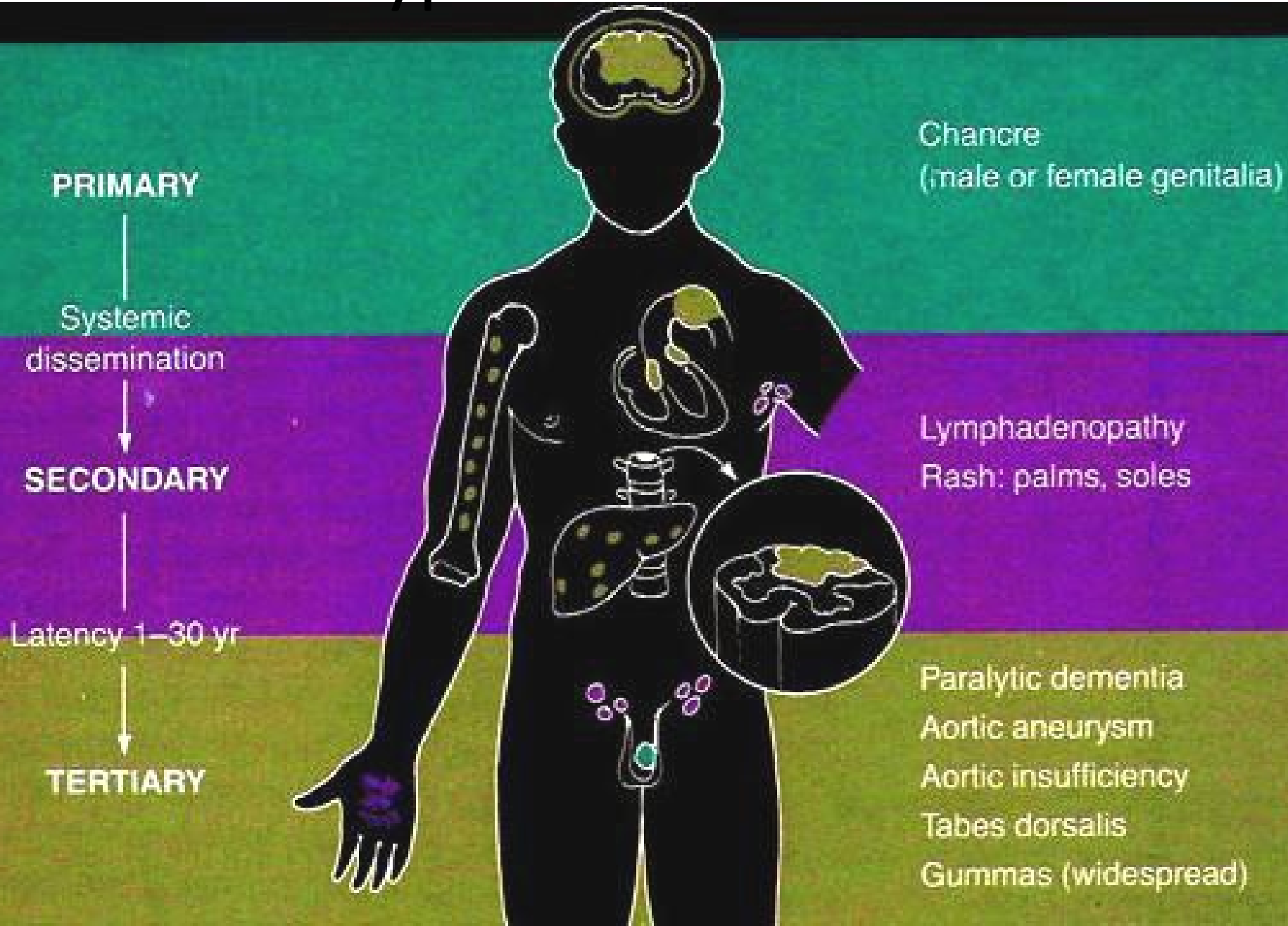
- *Treponema pallidum ssp. pallidum*, causing syphilis (lues)
- Syphilis is a classic sexual disease. It is transmitted sexually only. But it is a systemic disease – in developed stages the whole body is affected (gummas, aortal dissection, neurosyphilis, psychical symptoms)
- Some subspecies of *T. pallidum* and some other treponemas cause other, differently transmitted diseases (framboesia – yaws, *T. pertenue*)
- Some treponemas are oral pathogens (*T. denticola* – related to parodontitis), or they are non-pathogenic

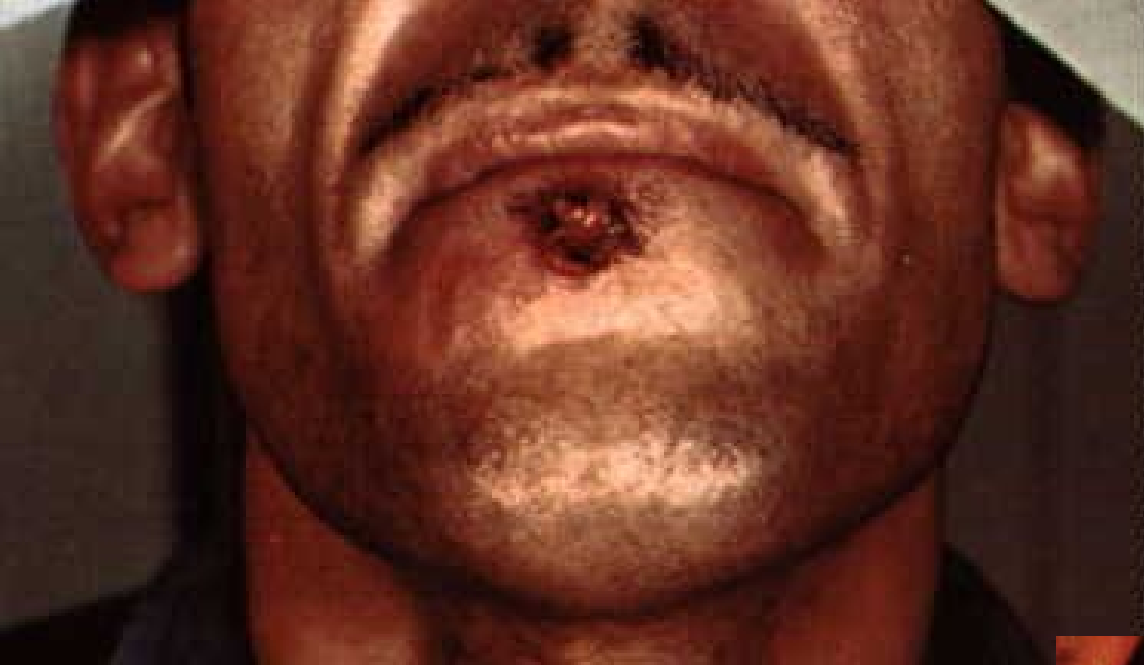# *Treponema pallidum*





# Course of syphilis



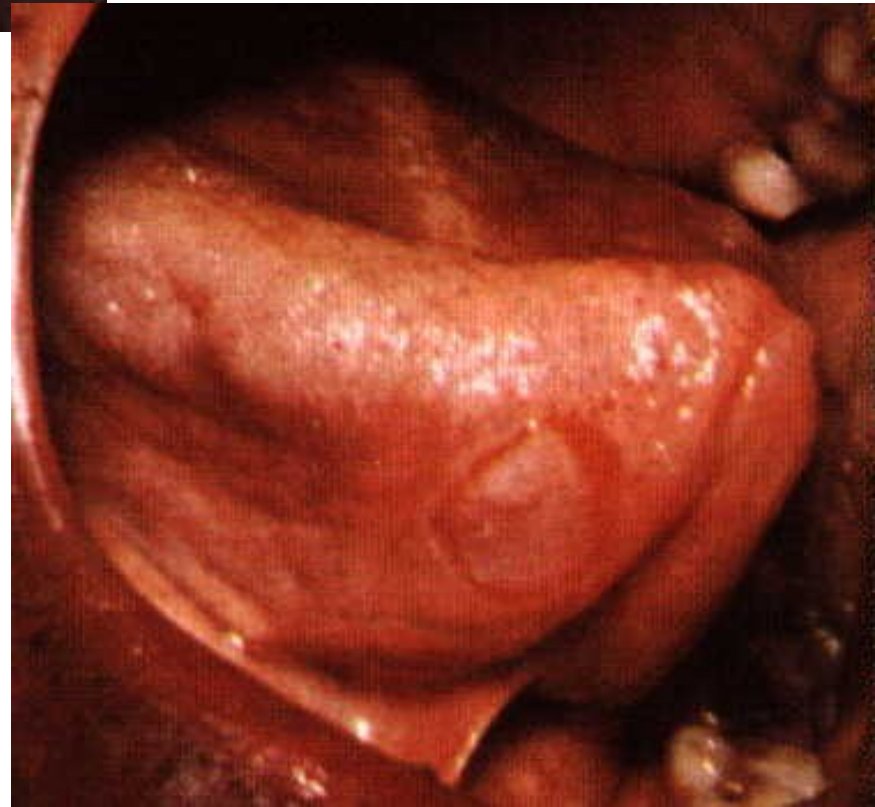

primary syphilis  
(„chancre“)

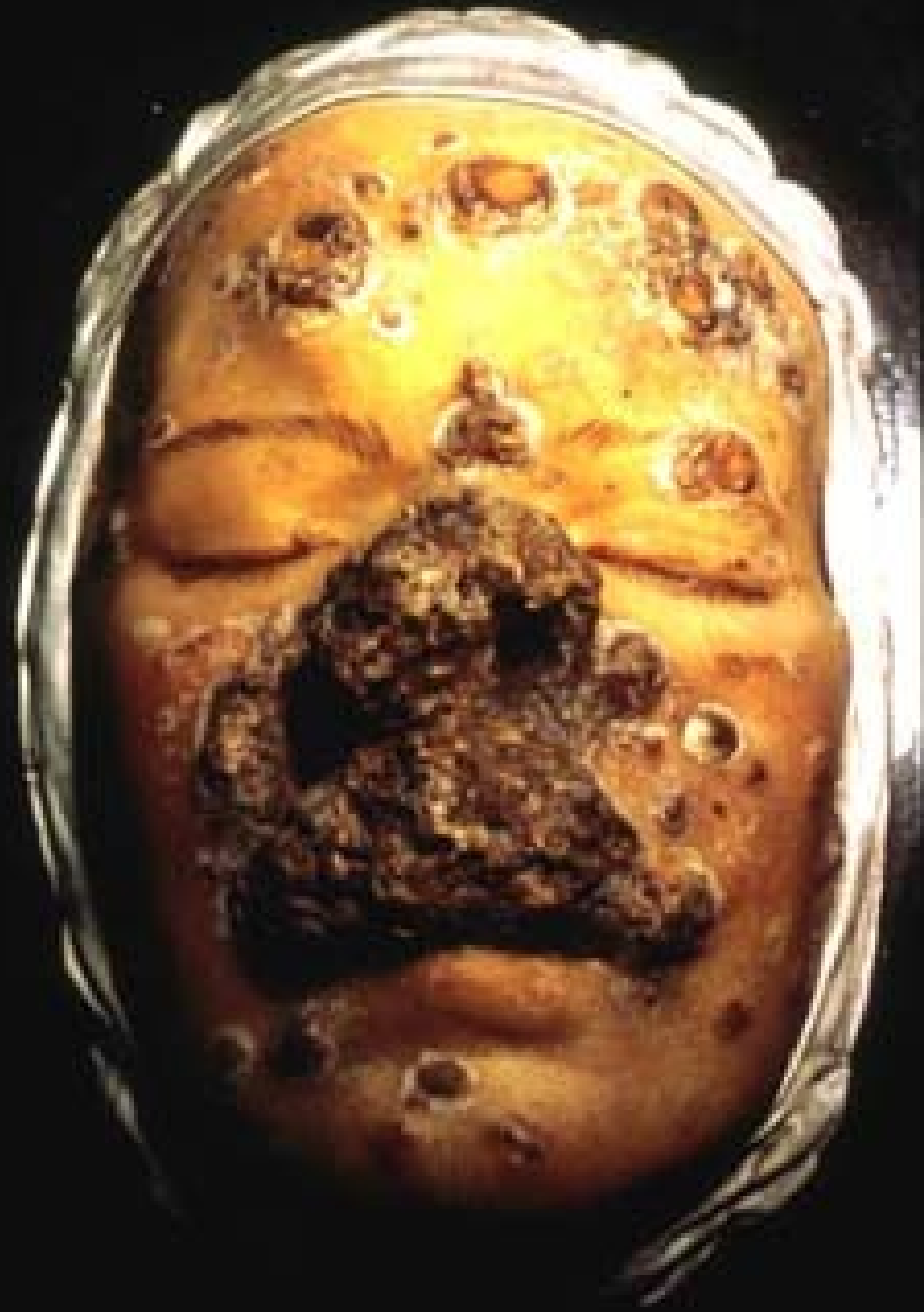uhavax.hartford.edu (2x)

## Course of syphilis

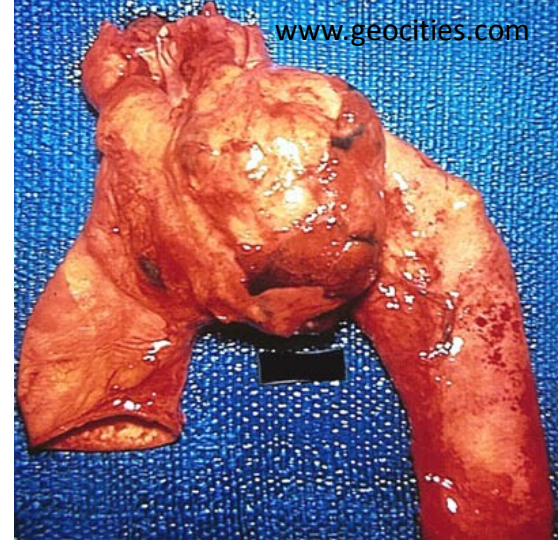secondary  
syphilis



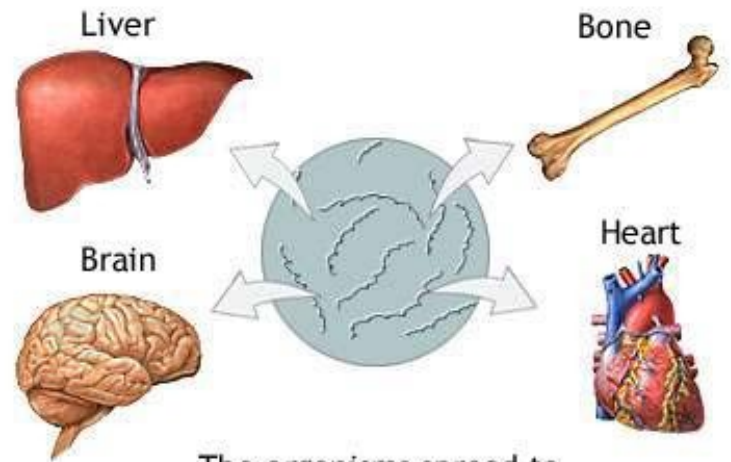




# Tertiary syphilis

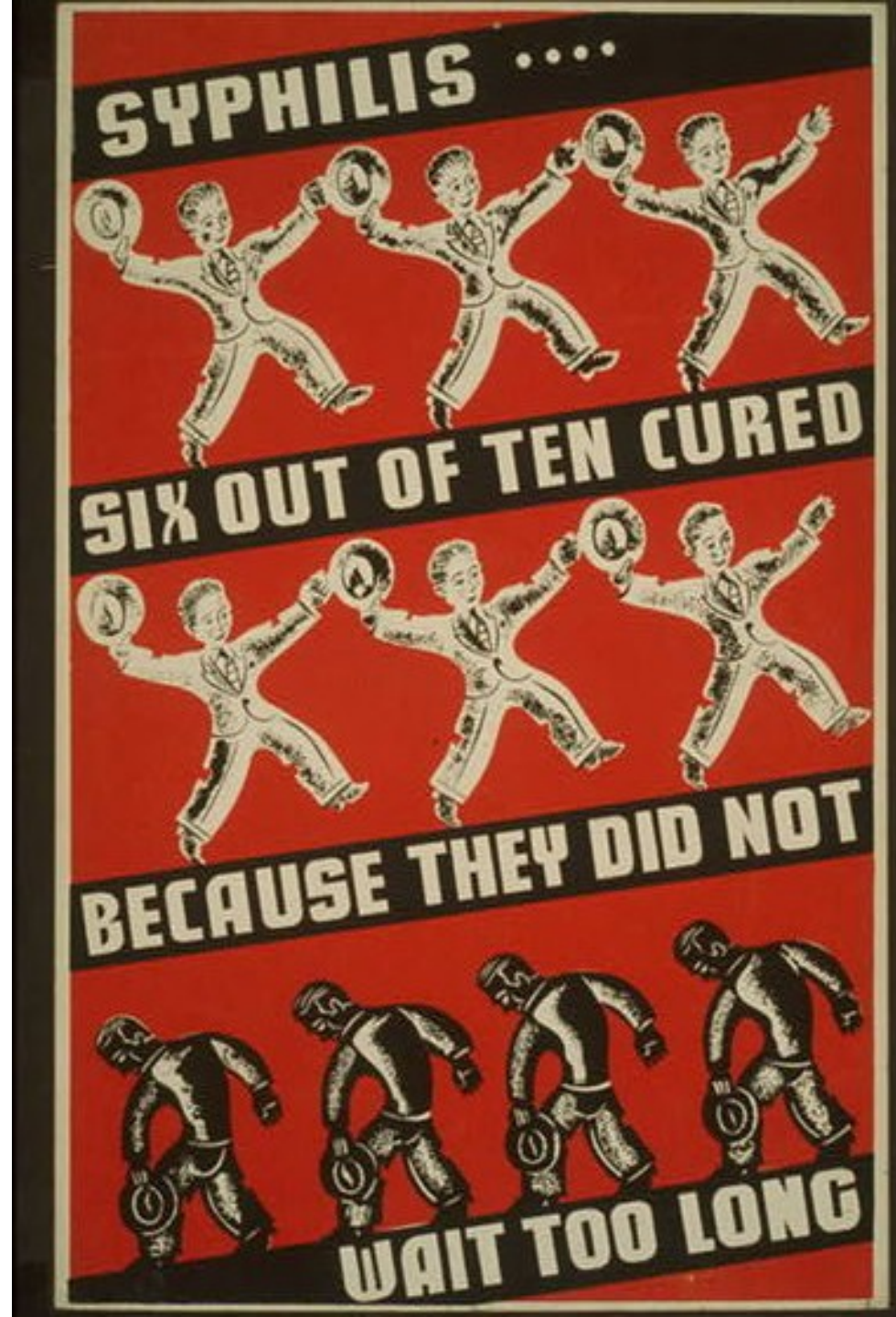
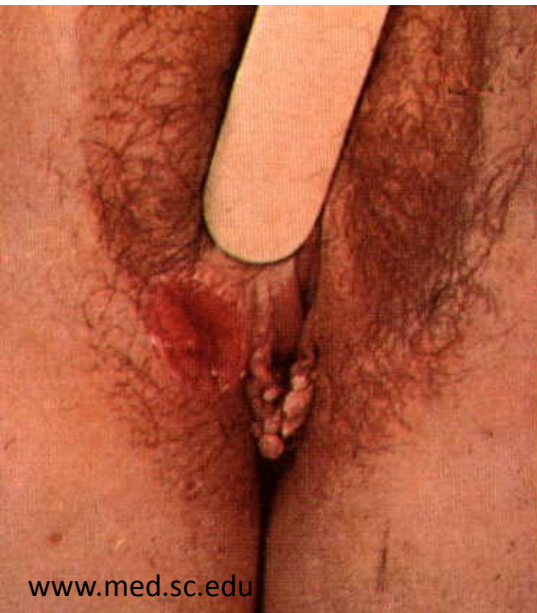

www.geocities.com



The organisms spread to various organs causing lesions or gummas

# Syphilis



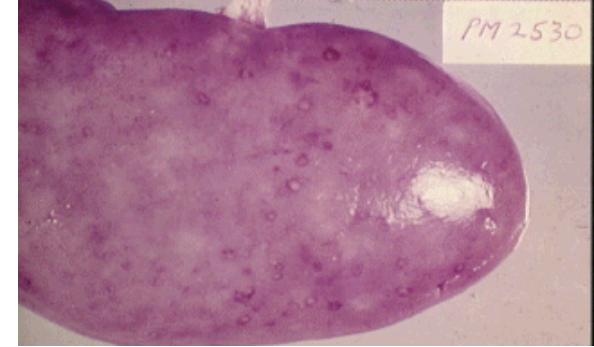
# Yaws (framboesia)



# Story three

Kidney with the  
corresponding  
disease

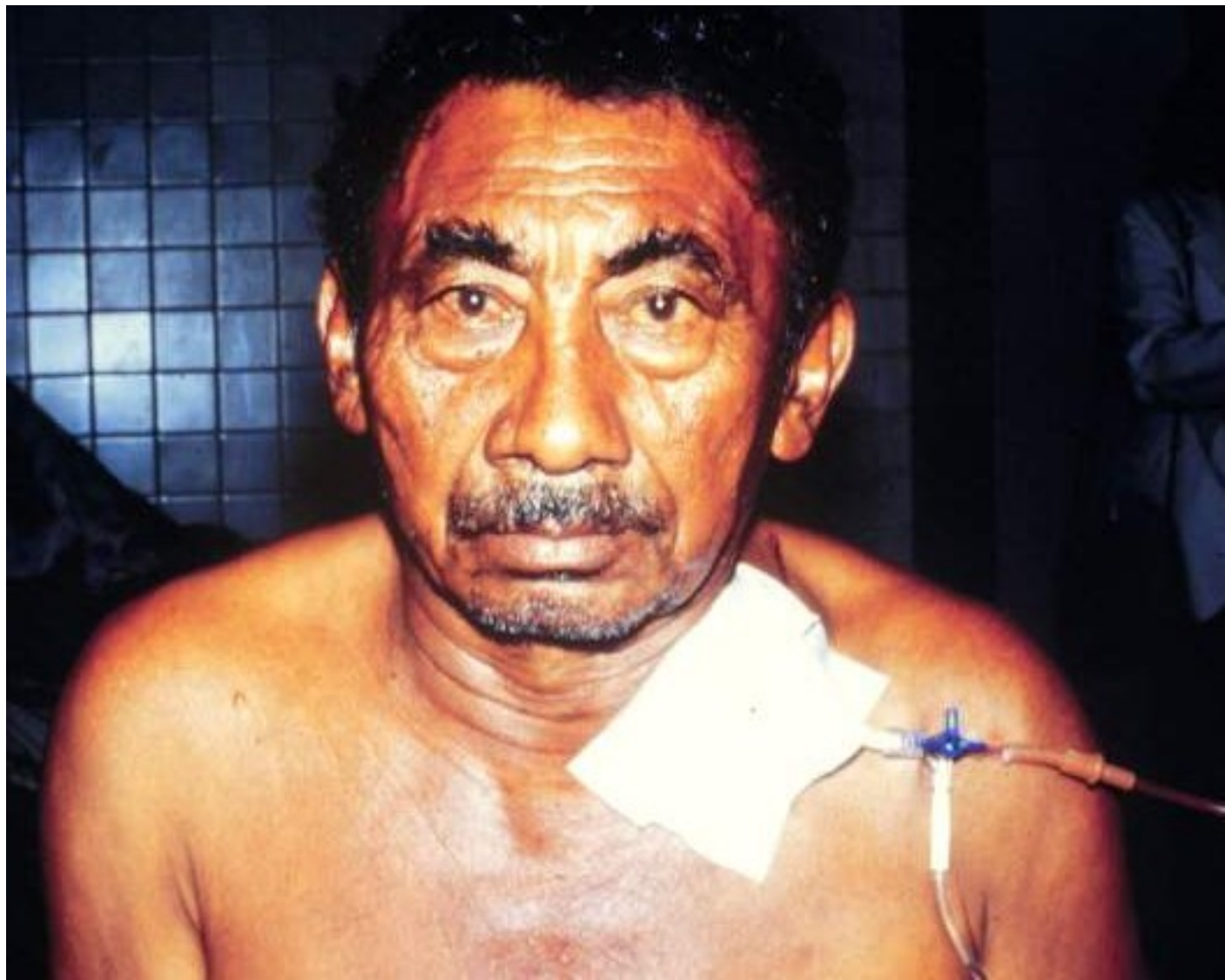www.med.sc.edu




- **Mr. Ratter** was an employee of NWPS Ltd. (Nowhere Water Pipes and Sewage)
- His job was **sewage cleaning**. He knew all sewage corridors. He also knew **rat habits**, he liked rats and he understood them.
- Nevertheless, once there was some misunderstanding between him and the leader of rat group and **Mr. Ratter was bitten to his leg**.
- Some time after this, Mr. Ratter was hospitalized with **icterus and bleeding...**



This is not Mr. Ratter, but his Venezuelan colleague with a similar fate...



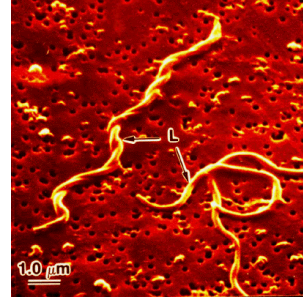
# The disease is caused by...



- *Leptospira interrogans* ser. Icterohemorrhagiae
- Formerly individual serovars of *Leptospira* were considered to be individual species, now all pathogenic ones are taken as a part of species *Leptospira interrogans* (second species *Leptospira biflexa* is non-pathogenic)
- Symptomatology varies, from „flu-typhoid“ symptoms of serovar Grippotyphosa (field fever, canefield fever) to jaundice and bleeding (Weil disease, as in Mr. Ratter) in serovar Ictero-hemorrhagiae.
- (At least these two serovars are quite simple for remembering, try to remember at least them 😊)

Microbiologic  
characteristics  
and diagnostics  
of spirochetes

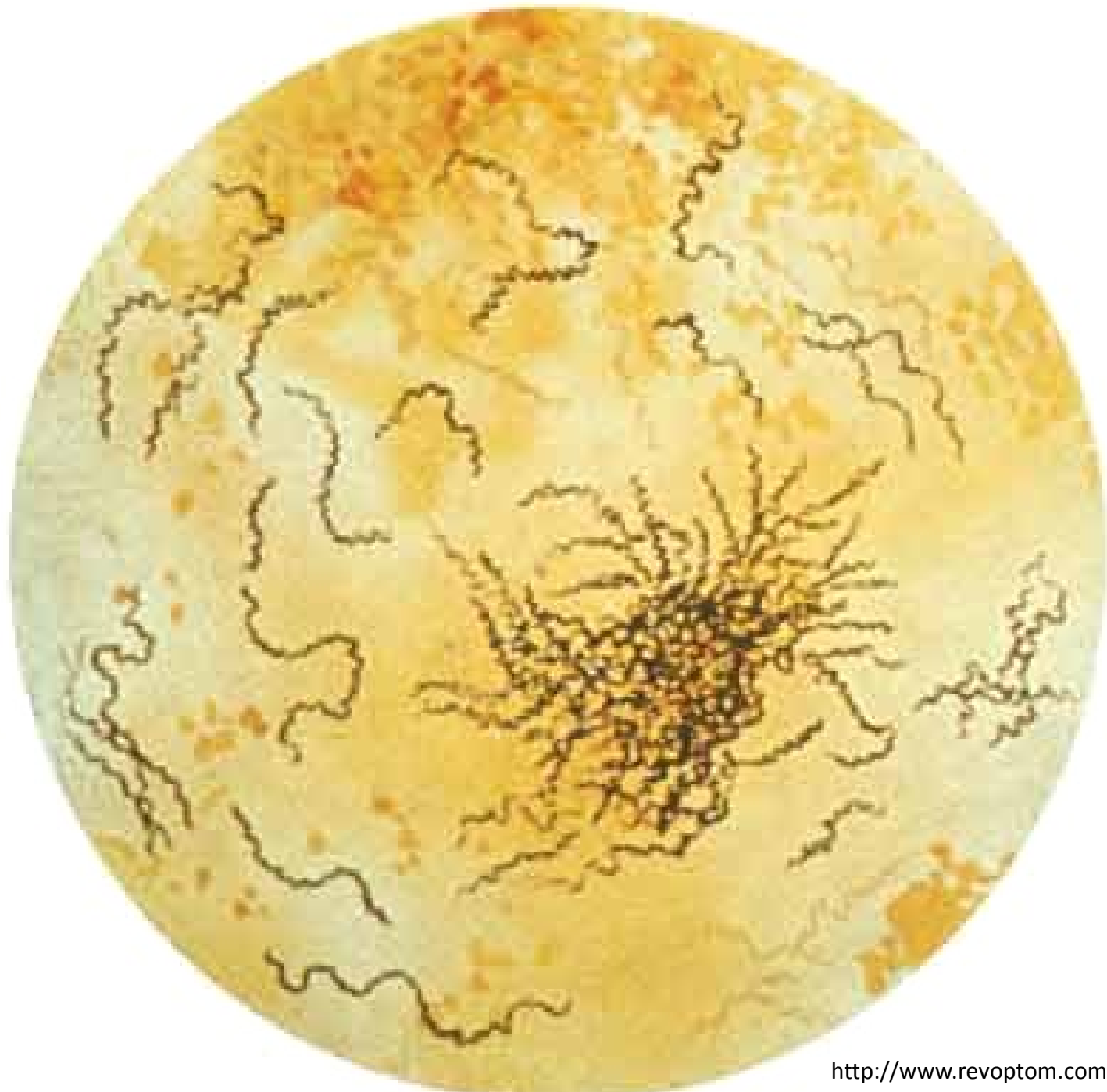
# Spirochets



- borrelias (but also treponemas and leptospiras) are spirochets, i. e. spiral rods.
- Their is close to a gram-negative one, but they do not stain by Gram's method because they cell wall is very thin.
  - So we microscopy them only using dark-field or fluorescence microscopy, or imunofluorescence ( $\neq$  fluorescence)
- The cultivation of spirochets is very difficult (we use special culture media, or we use other tests)
- *T. pallidum* cannot be cultivated in artificial media

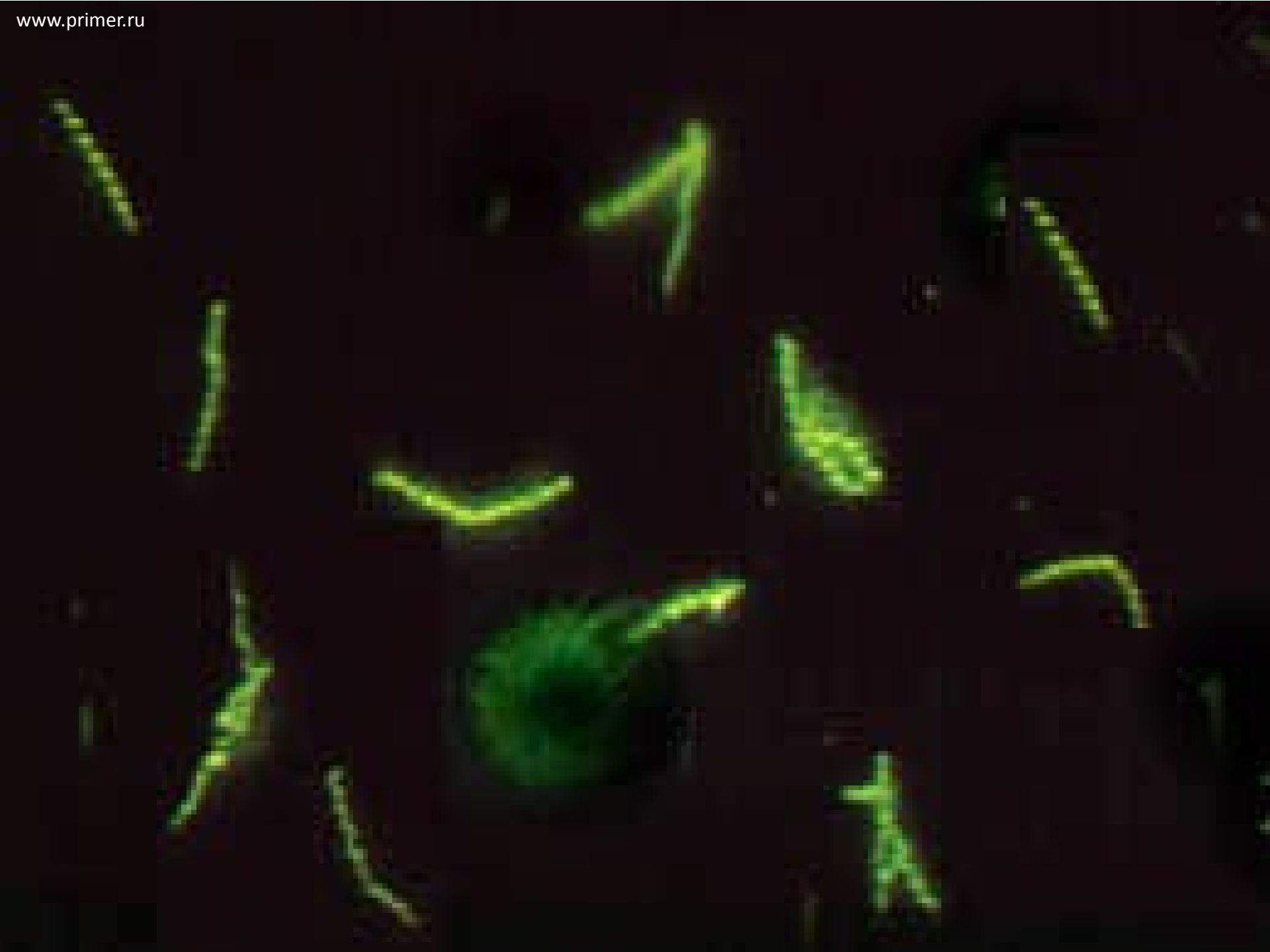


*Treponem  
pallidum*



# Treponema: direct methods

- **Direct diagnostics** is rare, also because often there is hardly something to take. Only patients with chancre are available for scrapping.
- **Microscopy**: It is possible to use **wet mount – dark field**. It is strange, that although it is a wet mount, immersion is used (treponemas are very subtle). Besides that, **fluorescence staining can be used**
- **Neither culture nor biochemical methods** are used
- **Antigen detection** can be performed by direct IMF
- **Animal experiment**: There exist so named RIT – Rabbit infectivity test
- **PCR diagnostics** is more and more important. *This is an exception – besides chancre scrapping, it is also possible to send full blood for examination.*



# Direct syphilis diagnostics – survey

- RIT – Rabbit infectivity test. For ethical reasons, but also as it is too much work, the RIT is minimized today.
- Dark field – shining *Treponema pallidum* is observed against the dark field
- Direct IMF – another direct, but difficult method
- PCR – also from blood

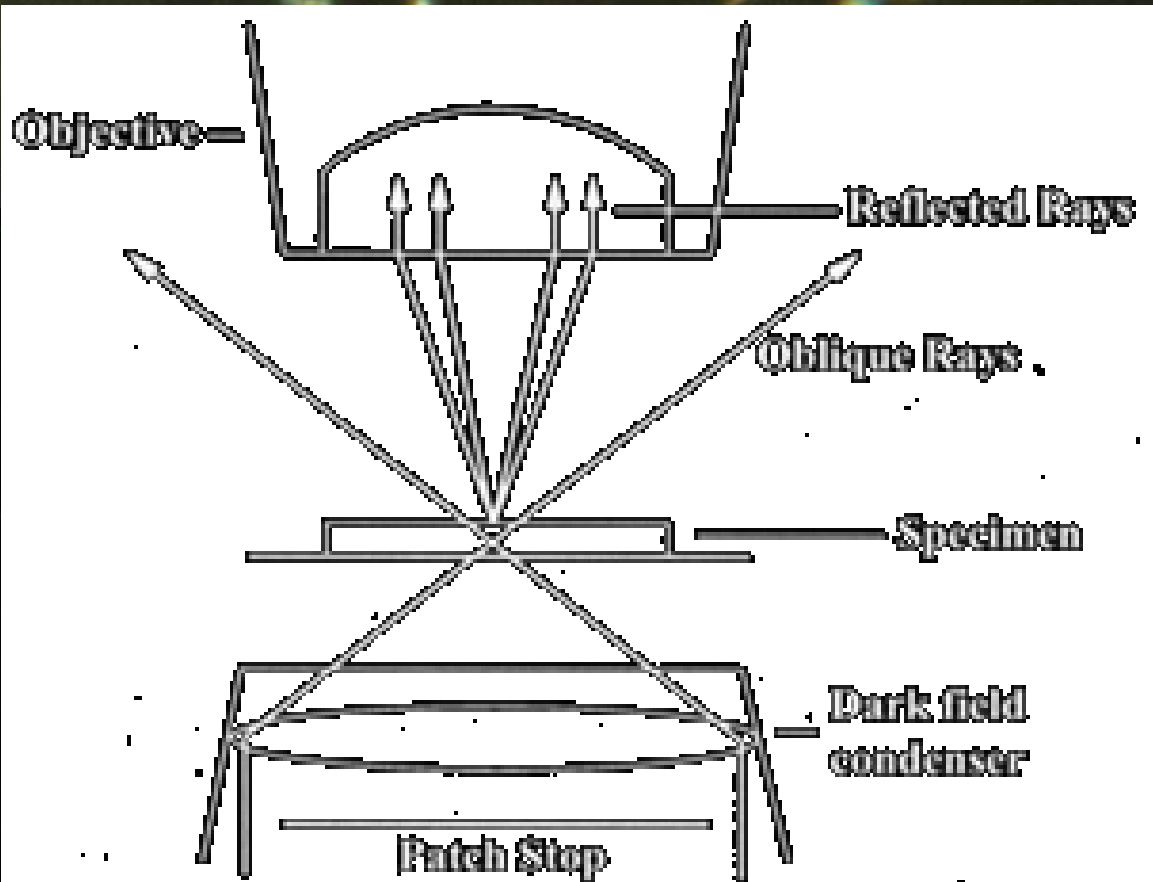
# New Zealand Rabbit used for RIT

[www.rockinjawrabbits.com](http://www.rockinjawrabbits.com)



# Dark field microscopy

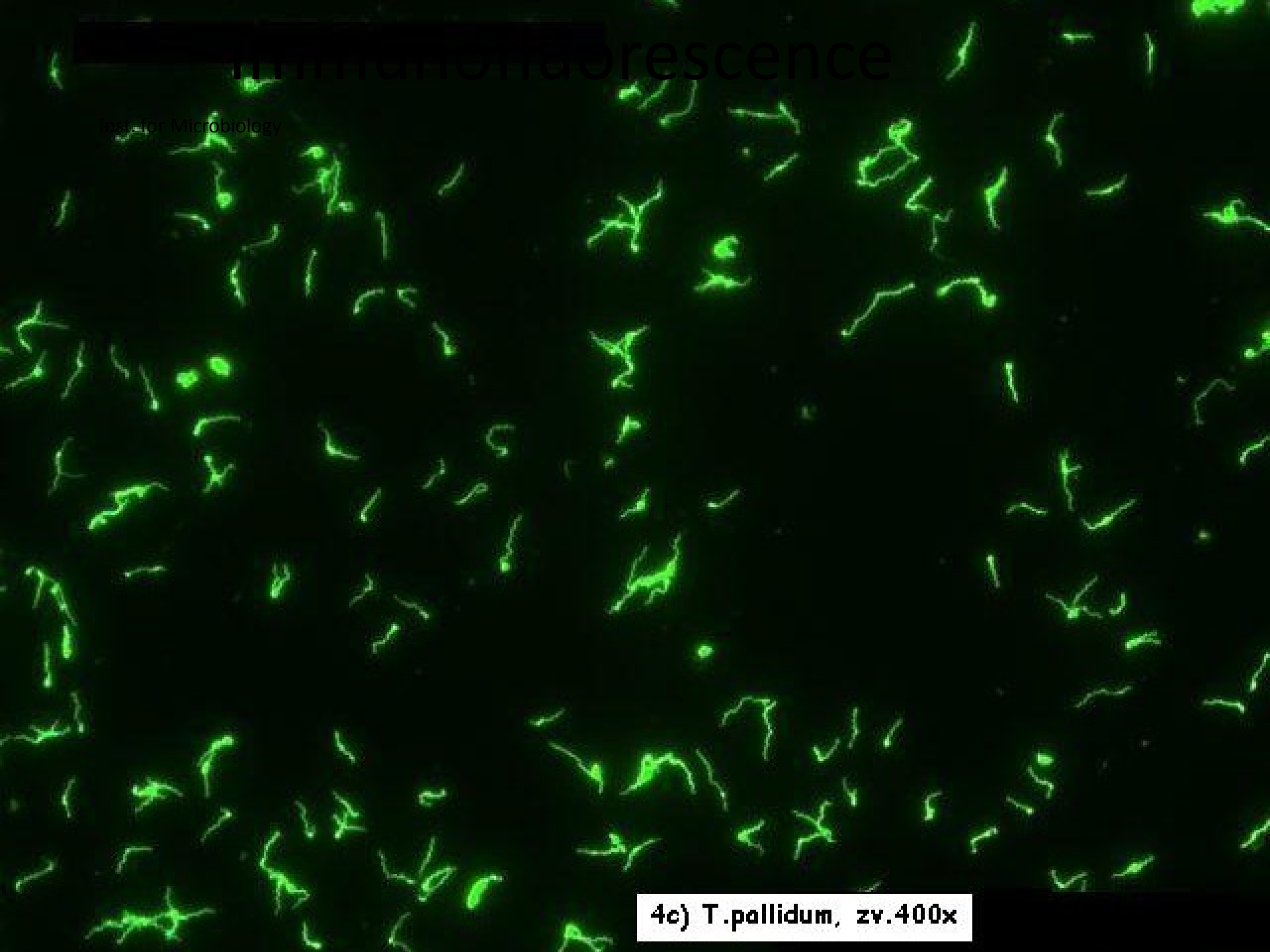
Only rays flexed at the preparation come to the observer's eye. Therefore, the observer's eye can see dark field with shining object(s)



4B) *T.pallidum* - zástin

# Immunofluorescence

Inst. for Microbiology



4c) *T.pallidum*, zv.400x

# Treponema: indirect methods

- We use **non-treponema tests**, which usually plays the role of antigen cardiolipin from bovine heart, and **treponema tests**, where we have a real antigen from *Treponema pallidum*
- **Diagnostics is composed of screening and confirmation.** We confirm everything that was positive or at least borderline at screening, in reasonable cases even negative results.
- **Screening** usually consists of a non-treponema and a treponema test
- **Confirmation** is performed by highly specific treponema tests



# The most important indirect tests for lues

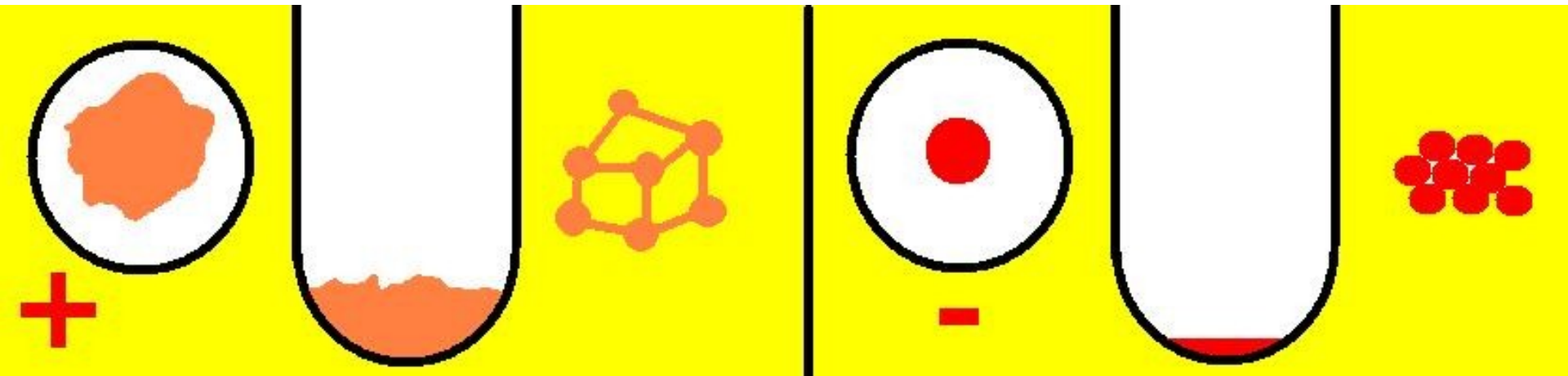
Historic	BWR – Bordet Wassermann	Nontr.
Screening	RRR – Rapid Reagin Test <i>or RPR</i> <i>or VDRL test</i>	
	MHA-TP (TPHA)*	Treponema
Confirmatory	ELISA	
	FTA-ABS (indir. imunofluor.)	
	Western Blotting	
<i>Historic, or superconfirmation</i>	<i>TPIT (Treponema Pallidum Imobilisation Test) = Nelson</i>	

\* MHA-TP – test for passive haemagglutination; now RBC use replaced by polycellulose

# RRR and TPHA

- In **RRR**, the well with turbidity is positive (it looks like the positive control). It is necessary to shake the panel, otherwise the reaction would not be visible.
- **TPHA** is an agglutination on carrier (RBC). A „potato shaped formation“ is positive, a dense dot is negative

# MHA-TP – to remember




- Positive – agglutinate formed, viewed from up as clot of irregular shape
- Negative – RBC (polycellulose particles in newer variant) fall to bottom forming a regular dense dot viewed from up

RRR – reading: turbidity = positive,  
no turbidity = negative

TPHA – reading:

Inst. for Microbiology



# Indications for confirmation


- Screening reactions are performed always, when somebody is to be tested for syphilis (including e. g. pregnant women that are not at all supposed to be positive). Screening reactions are usually performed only **qualitatively or semiquantitatively** (although it would not be a problem to do them quantitatively)
- Indication for confirmation is:
  - any **positive or at least borderline result** in RRR and/or MHA-TP reaction, OR
  - presence of **suspicious lesions on body**, or **anamnesis** of risky sexual intercourse – here even in case of negativity of both reactions

# ELISA, Western blotting and PCR in spirochetal diagnostics


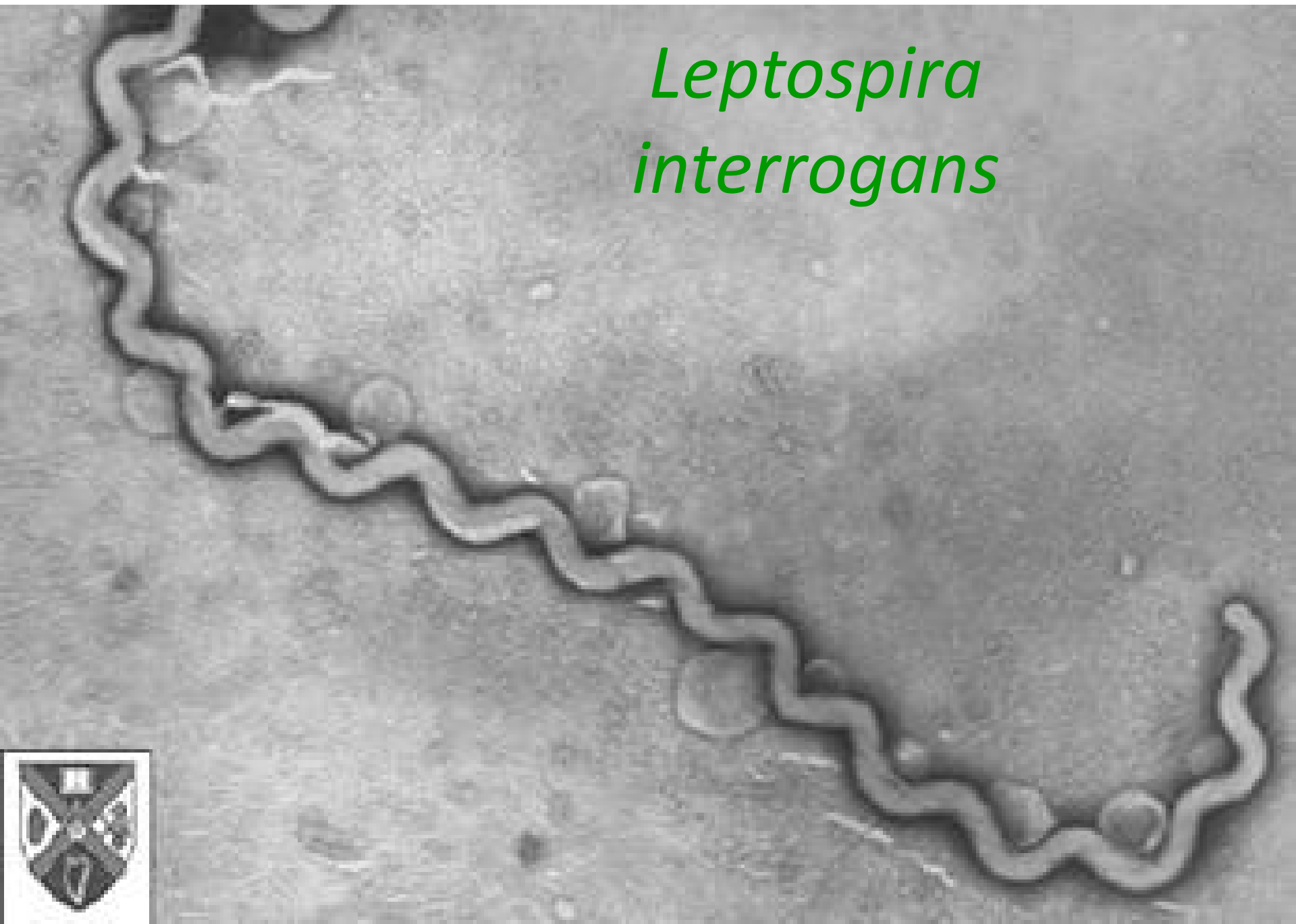
- ELISA, Western blotting and PCR – all of them are used in spirochets similarly as in other microbes – see J08 and J09 topics in spring term.
- Positive are patients with values of absorbance higher than a given value (CAL – calibration well, cut off etc.)
- Examination of IgG and IgM antibodies is important, mere IgG positiveness is just a proof of a previous infection.
- PCR is used in diagnostics of syphilis and Lyme disease. It is usually positive sooner than methods detecting antibodies.

# Borrelia and leptospira – course of investigation

- **Borrelia:** Mostly serology, event. PCR. In serology, IgM (typical for an early infection) and IgG antibodies are detected using ELISA method, positive finding is confirmed by Western blotting. Western blotting is more specific.
- **Leptospira:** Dark field microscopy and culture in special medium are used

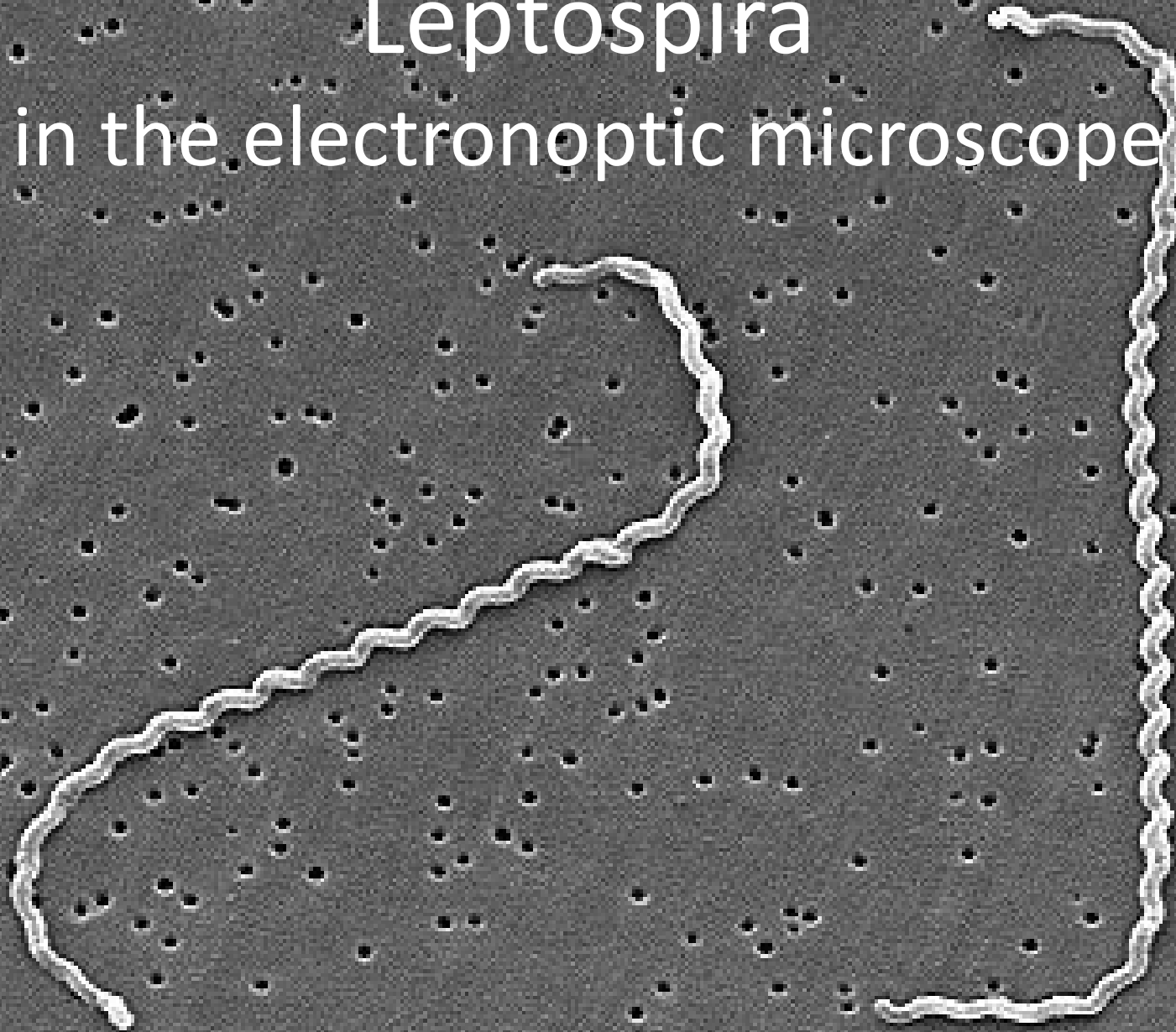

*Leptospira*  
*interrogans*



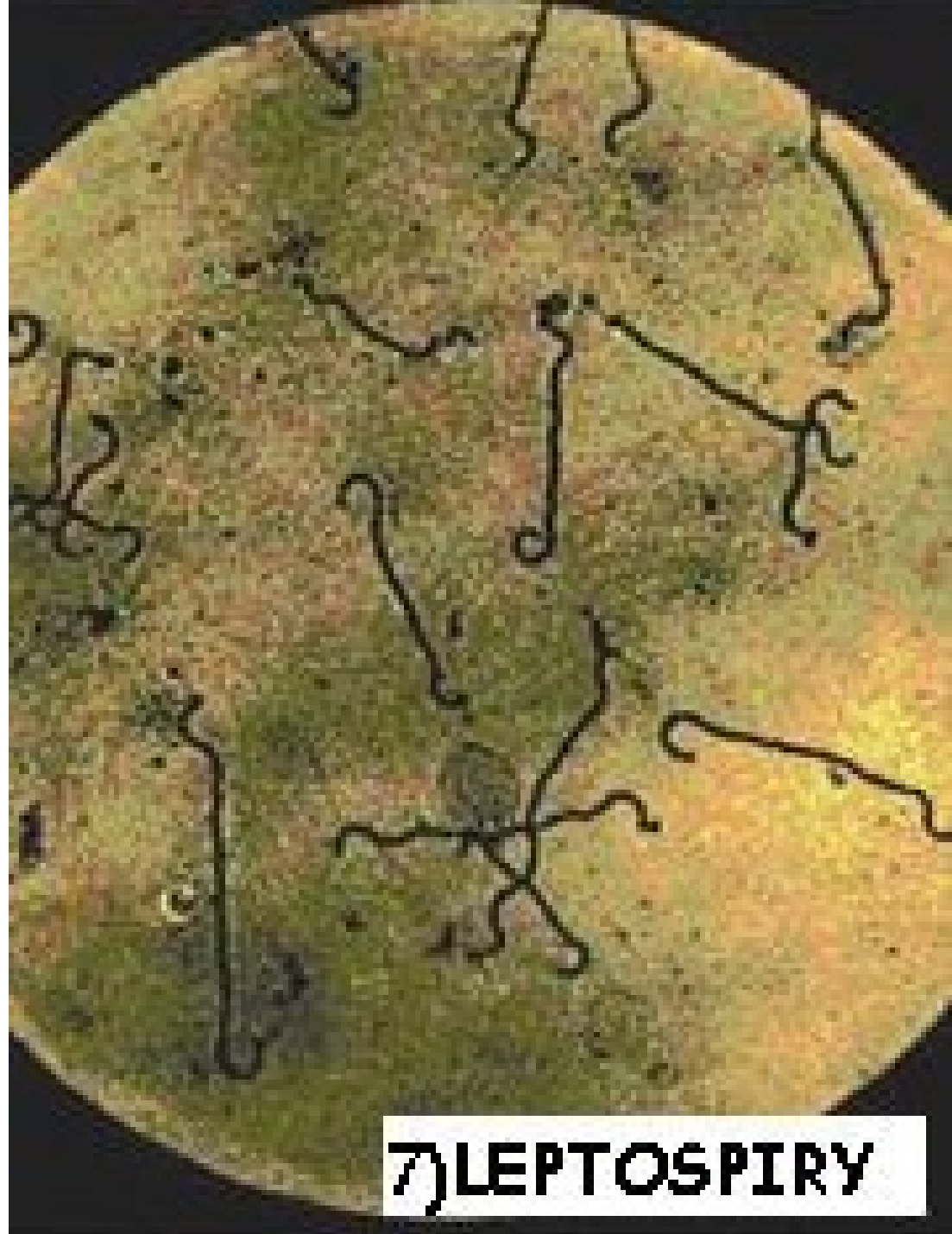

# Leptospira in the electrooptic microscope



# *Leptospira* diagnostics

- Microscopy of leptospira



7) LEPTOSPIRY

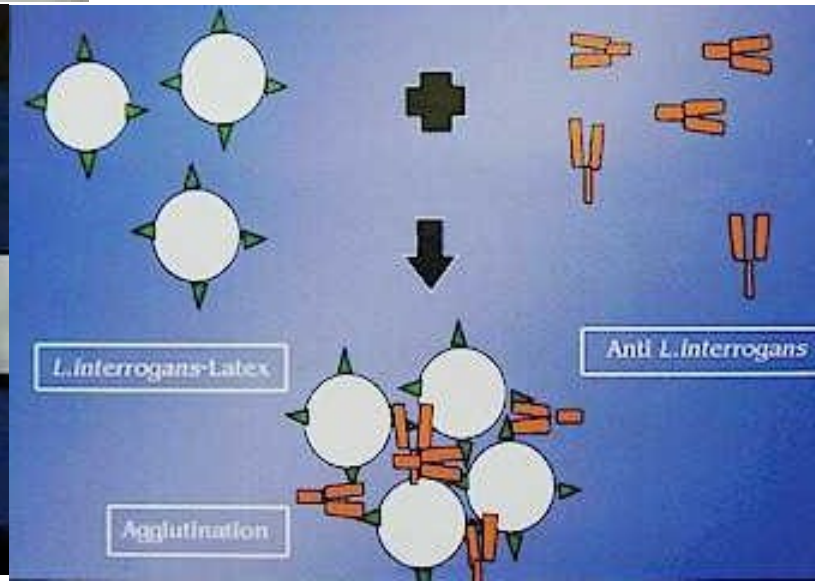
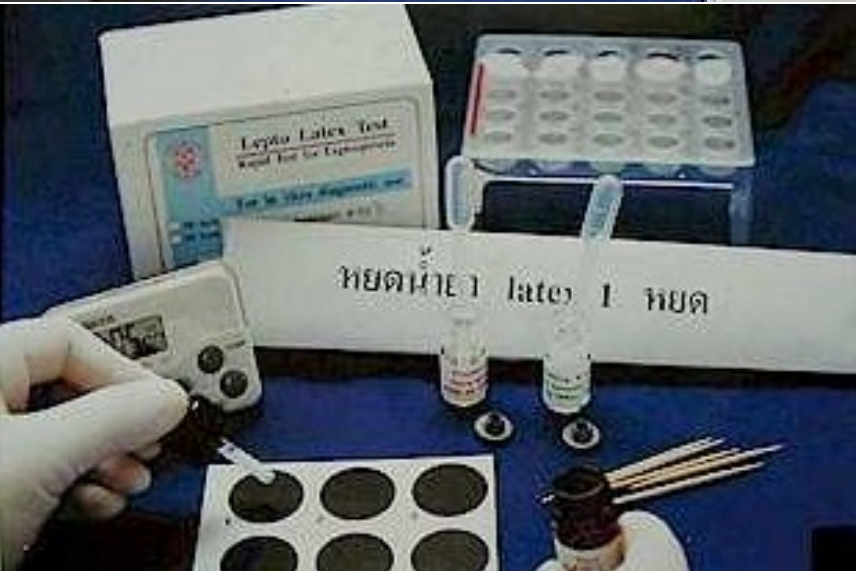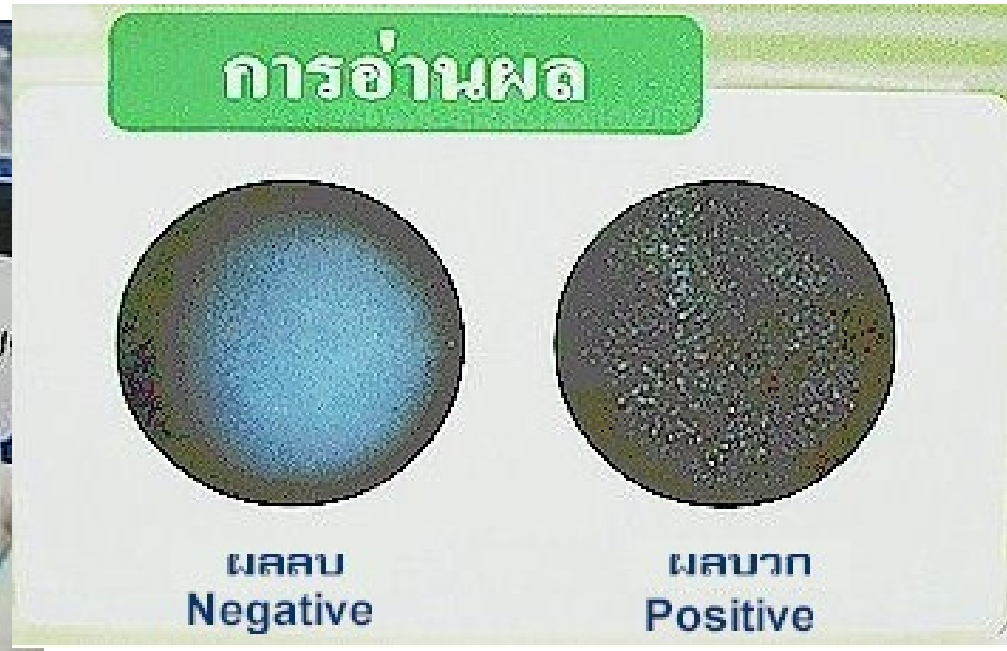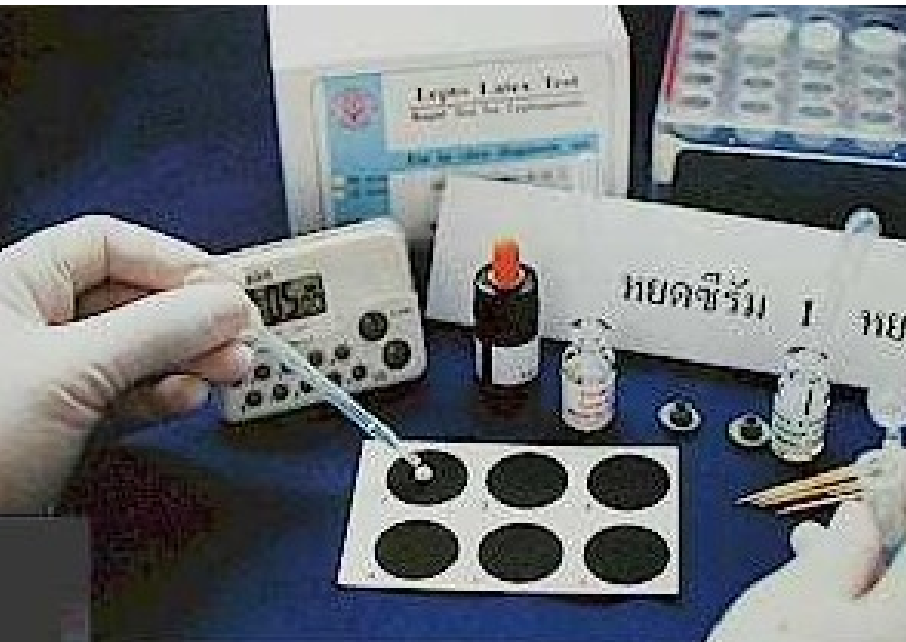# *Leptospira* diagnostics

- Leptospirosis are usually diagnosed by serology
  - Microscopic agglutination test (MAT)
    - Patient sera are reactive with live antigen suspensions of leptospiral serovars
    - After incubation the samples are examined microscopically for agglutinations
  - Other serological tests are ELISA methods


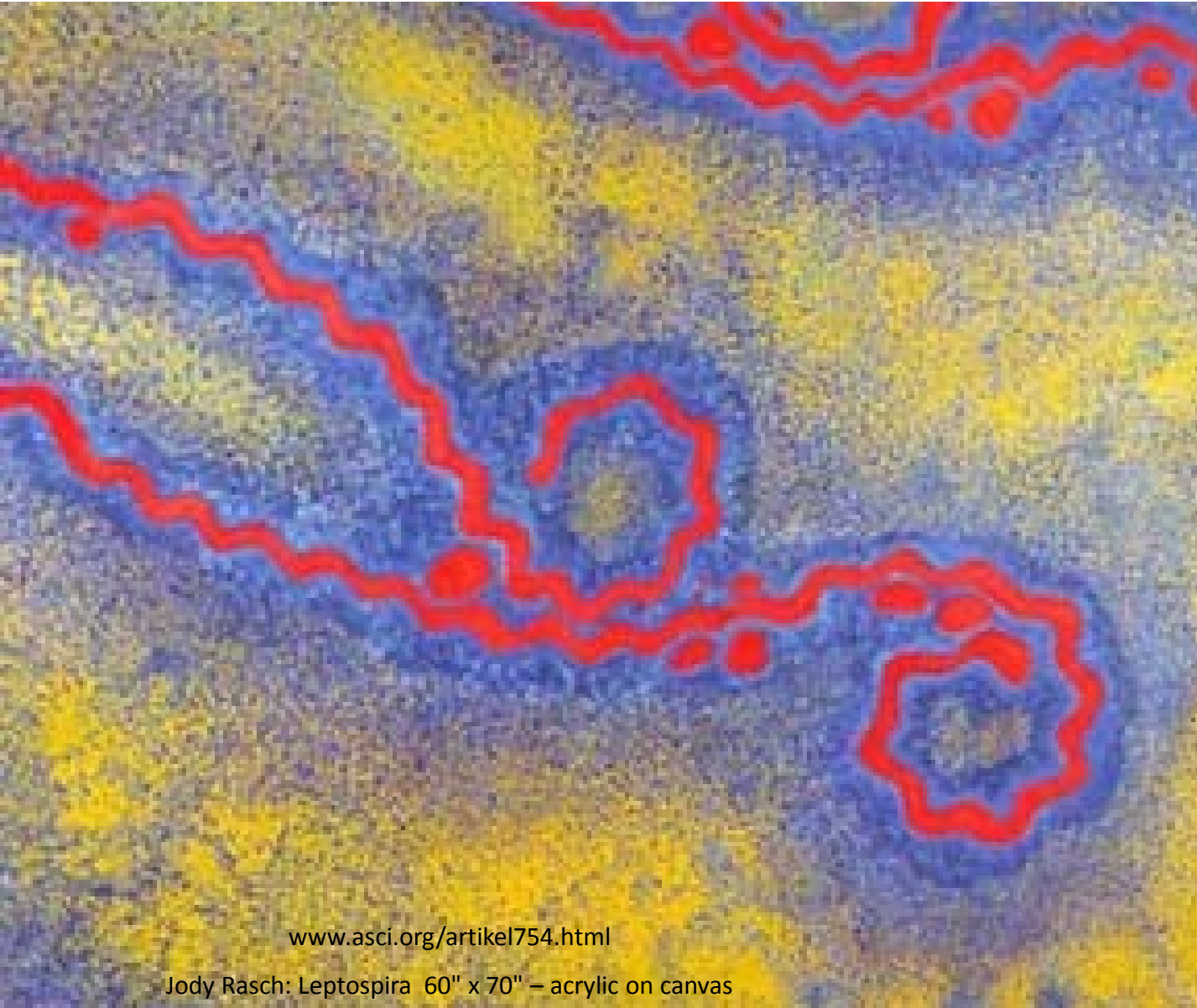
# More diagnostic opportunities in *Leptospira*

(latex agglutination)

4x www.thailabonline.com



# The End



[www.asci.org/artikel754.html](http://www.asci.org/artikel754.html)

Jody Rasch: Leptospira 60" x 70" – acrylic on canvas