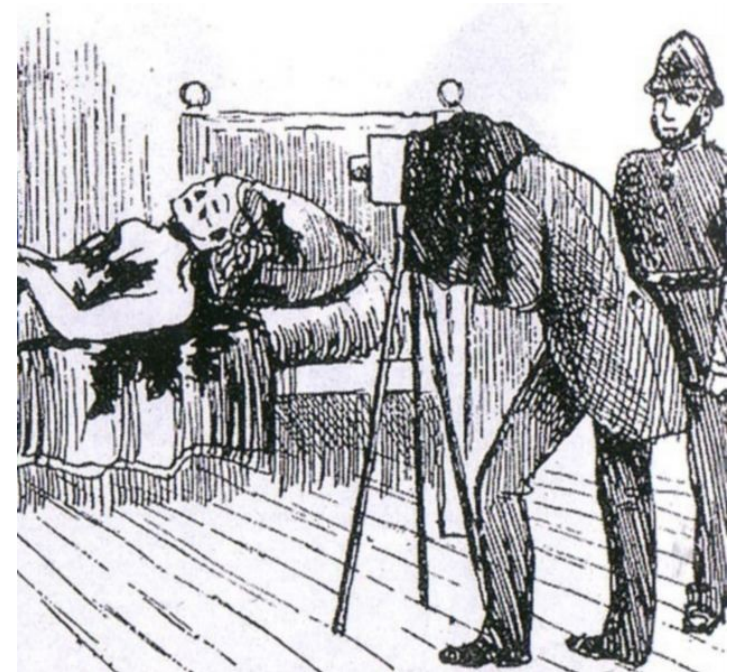




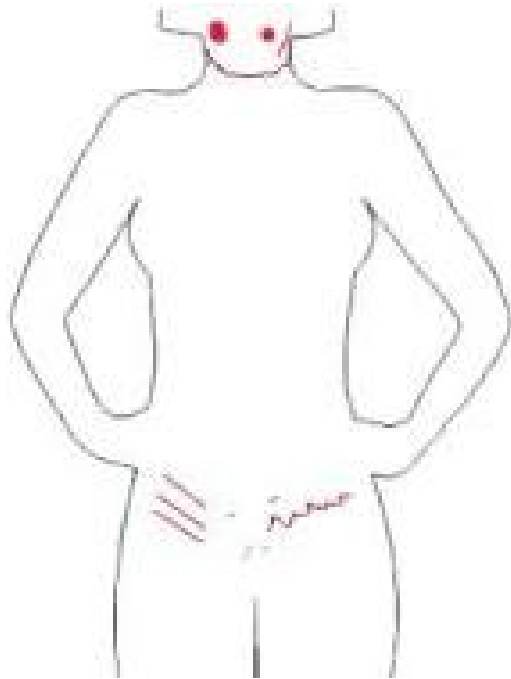
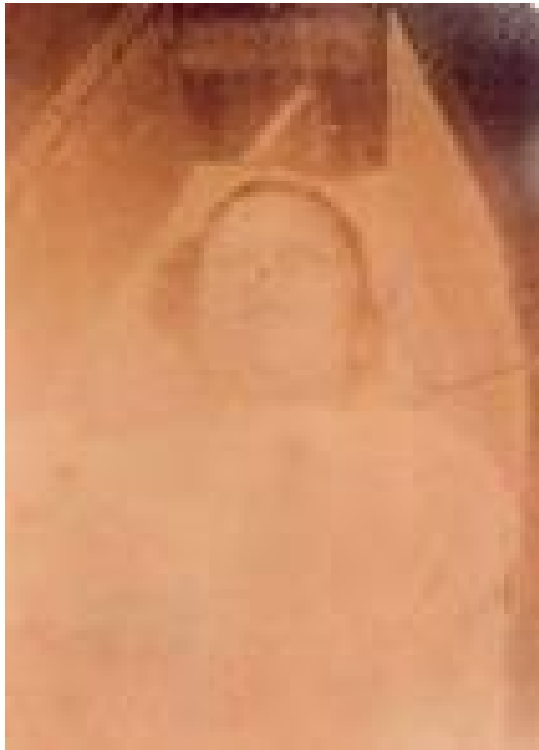# Jack the Ripper

Victim's wounds



# 1. Victim – Mary Ann Nichols

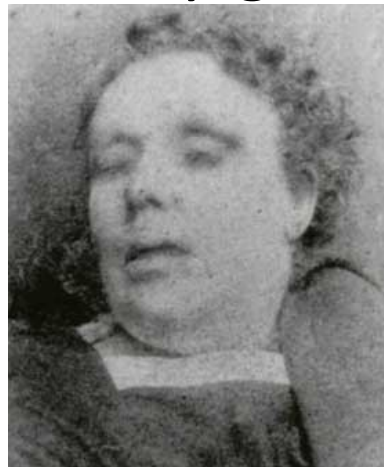- Nichols' body was discovered at about 3:40 a.m. on Friday 31 August 1888 in Buck's Row (now Durward Street), Whitechapel.

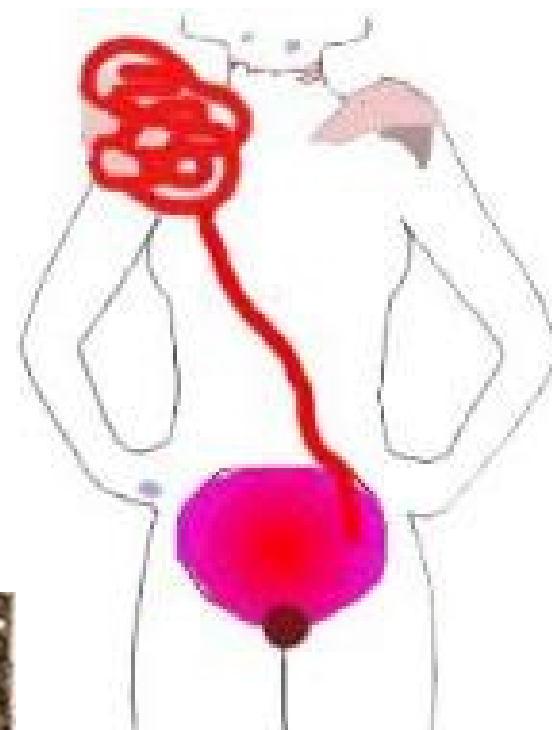

- Five teeth were missing, and there was a slight laceration of the tongue. There was a bruise running along the lower part of the jaw on the right side of the face. That might have been caused by a blow from a fist or pressure from a thumb. There was a circular bruise on the left side of the face which also might have been inflicted by the pressure of the fingers. On the left side of the neck, below the jaw, there was an incision and it ran from a point immediately below the ear. On the same side, but an inch below was a circular incision. That incision completely severed all the tissues down to the vertebrae. The large vessels of the neck on both sides were severed. The cuts must have been caused by a long-bladed knife, moderately sharp, and used with great violence. No blood was found on the breast, either of the body or the clothes. There were no injuries about the body until just about the lower part of the abdomen. Two or three inches from the left side was a wound running in a jagged manner. The wound was a very deep one, and the tissues were cut through. There were several incisions running across the abdomen. There were three or four similar cuts running downwards, on the right side, all of which had been caused by a knife which had been used violently and downwards, the injuries were from left to right and might have been done by a left handed person. All the injuries had been caused by the same instrument.

## 2. Victim – Annie Chapman

- Chapman's body was discovered at about 6 a.m. on Saturday 8 September 1888 near a doorway in the back yard of 29 Hanbury Street, Spitalfields. As in the case of Mary Ann Nichols, the throat was severed by two cuts. The abdomen was slashed entirely open, and it was later discovered that the uterus had been removed. At the inquest, one witness described seeing Chapman at about 5:30 a.m. with a dark-haired man of "shabby-genteel" appearance.

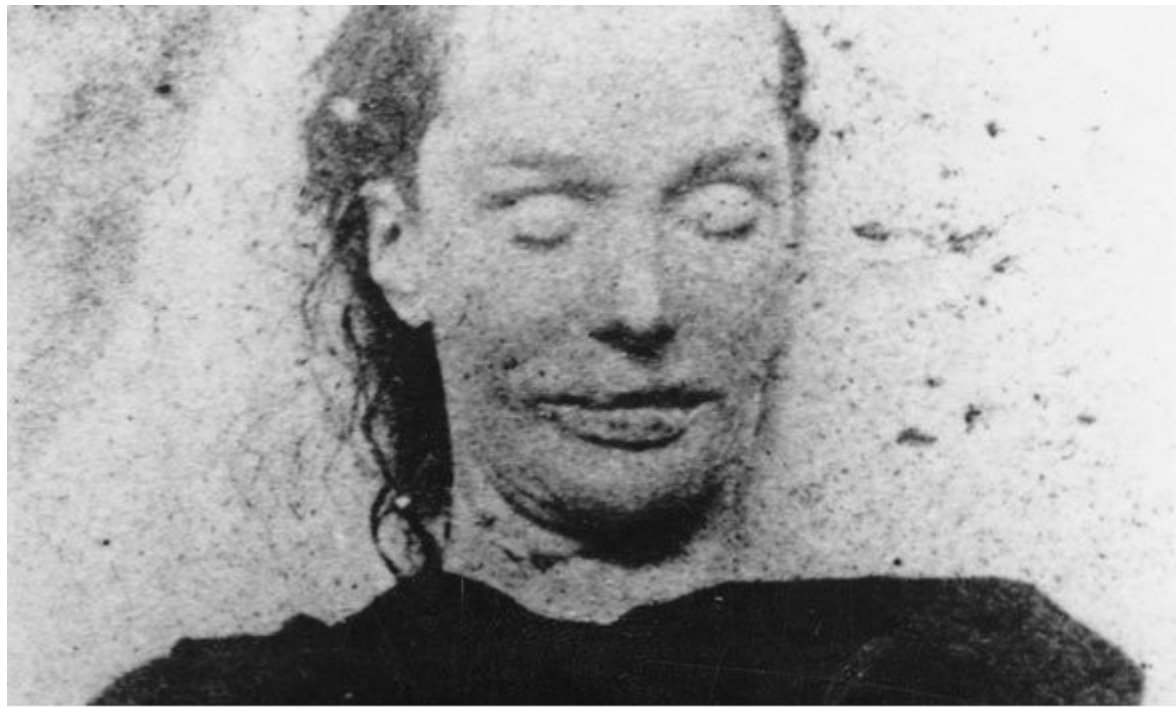
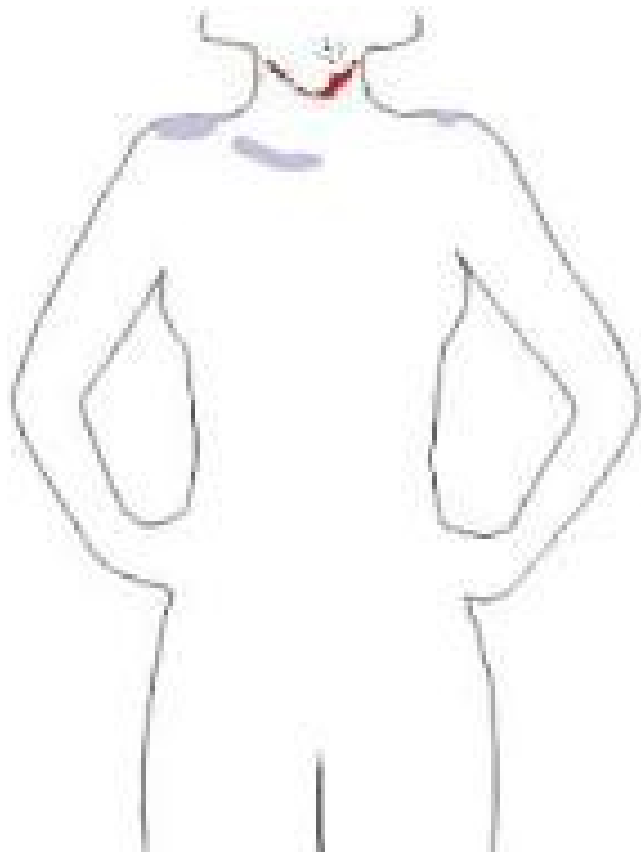



- **Bruise over the right temple** - old; 2 man's thumb-sized bruises on top forepart of chest - old; **3 scratches below the lower left jaw**, 1 1/2"-2" below left ear lobe, going in opposite direction of throat wounds - recent; **Bruise on right cheek** - recent; Bruise corresponding with the scratches - recent; **Abrasion on head of proximal phalanx of ring finger**; Marks of rings on same finger; Upper eyelid bruised; Limbs very stiff, but left side more stiff than right side; **Bruise on middle part of bone of right hand**; Scar on left of frontal bone - old; Fingers of left hand partly closed; Little food in stomach; No sign of fluid; No sign of alcohol consumption; Lungs diseased; Brain membranes diseased; Signs of deprivation; Front teeth perfect on top and bottom as far as the first molar; The shortest throat incision ran from the front of the throat and terminated on the right side between the lower jaw and the breast bone; The longest throat incision completely encircled the throat, running along the line of the jaw; The incisions ran from victim's left to right; 2 clean and distinct cuts on the left side of the spine which were parallel to each other and were 1/2" apart; Missing were the **womb, upper part of vagina, greater part of bladder, and part of the belly wall** that included the navel.

### 3. Victim - Elizabeth Stride

- Stride and Eddowes were killed in the early morning of Sunday 30 September 1888. Stride's body was discovered at about 1 a.m. in Dutfield's Yard, off Berner Street (now Henriques Street) in Whitechapel. The cause of death was one clear-cut incision which severed the **main artery on the left side of the neck**. The **absence of mutilations to the abdomen** has led to uncertainty about whether Stride's murder should be attributed to the Ripper or whether he was interrupted during the attack. Witnesses thought that they saw Stride with a man earlier that night but gave differing descriptions: some said that her companion was fair, others dark; some said that he was shabbily dressed, others well-dressed.



Elizabeth Stride (PA)

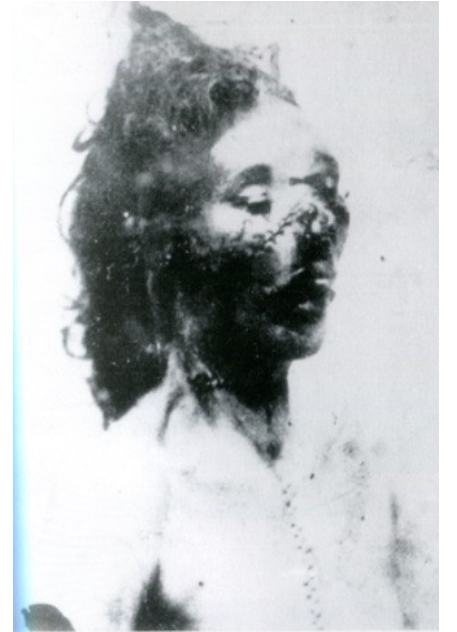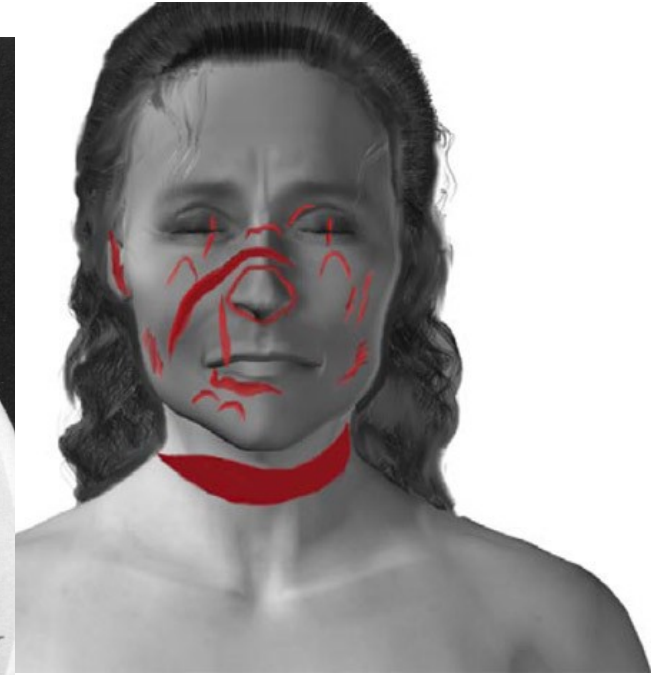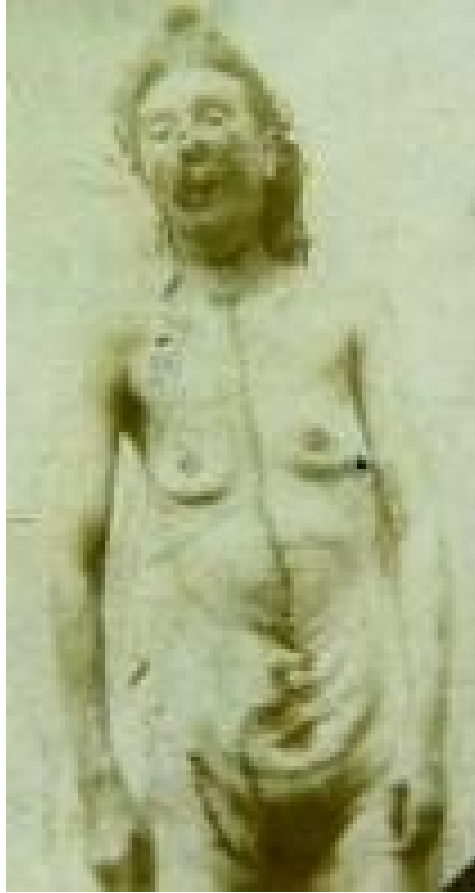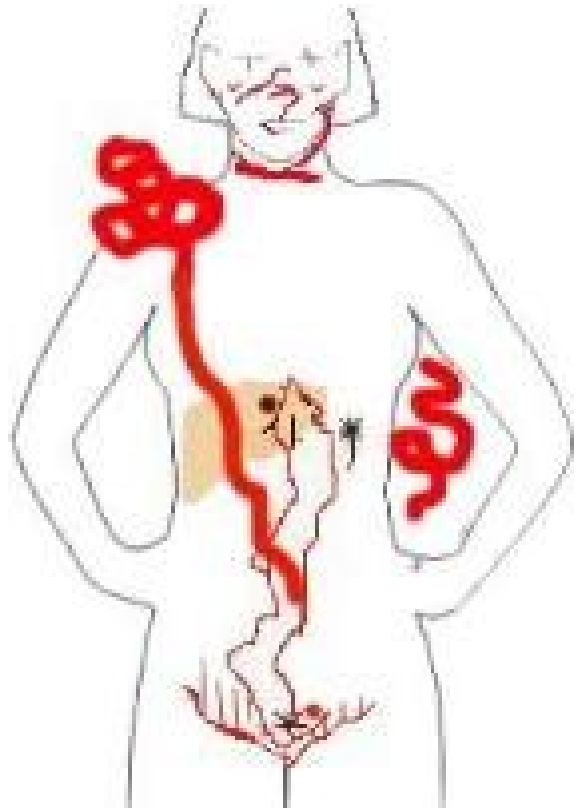




- An abrasion of the skin about an inch and a quarter diameter, apparently slightly stained with blood, was under the right clavicle. The throat was deeply gashed: in the neck was a long incision which exactly corresponded with the lower border of her scarf; the incision commenced on the left side, 2 1/2" below the angle of the jaw, and almost in a direct line with it, nearly severing the vessels on that side, cutting the windpipe completely in two, and terminating on the opposite side 1 1/2" below the angle of the right jaw, but without severing the vessels on that side.

## 4. Victim - Catherine Eddowes

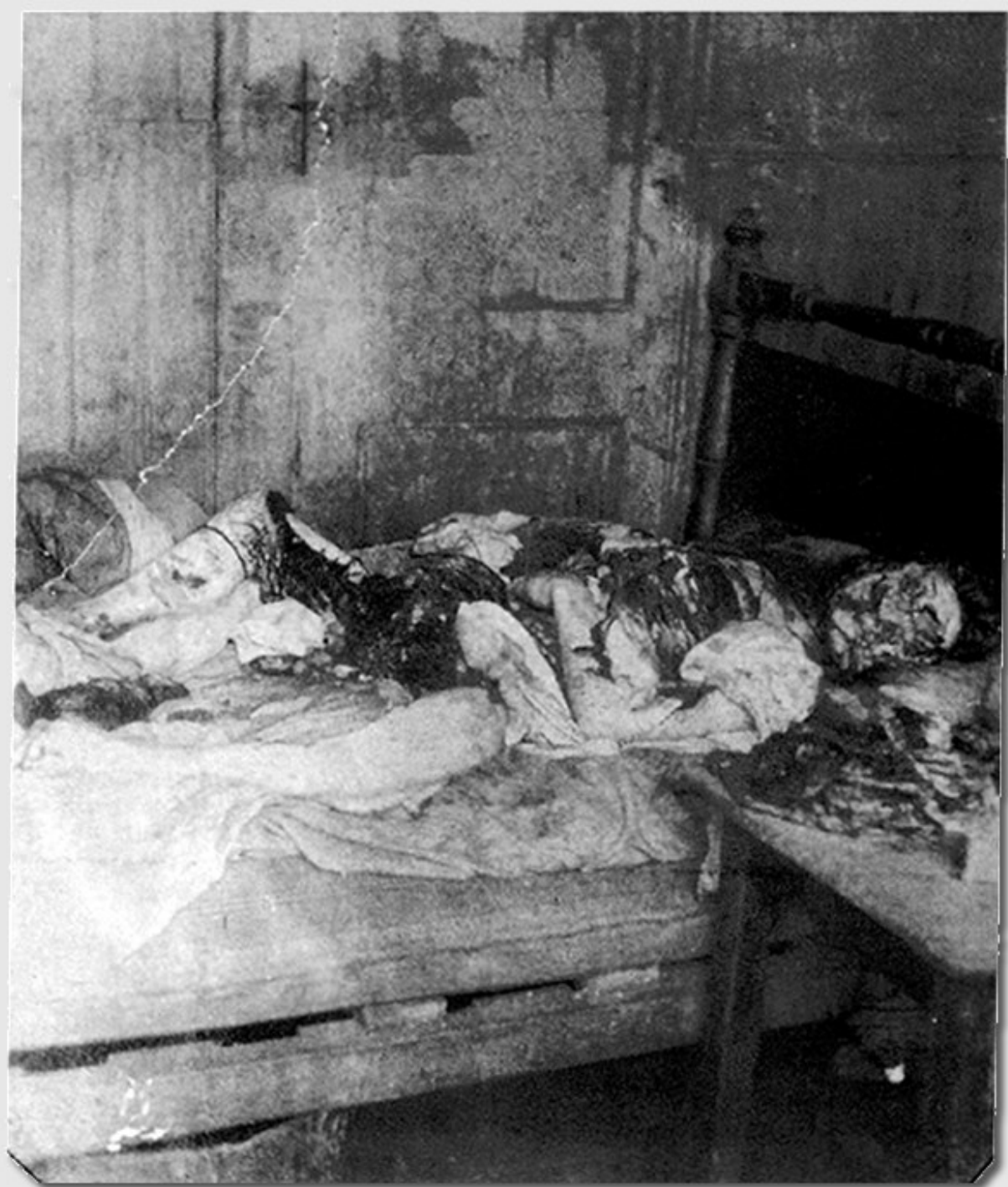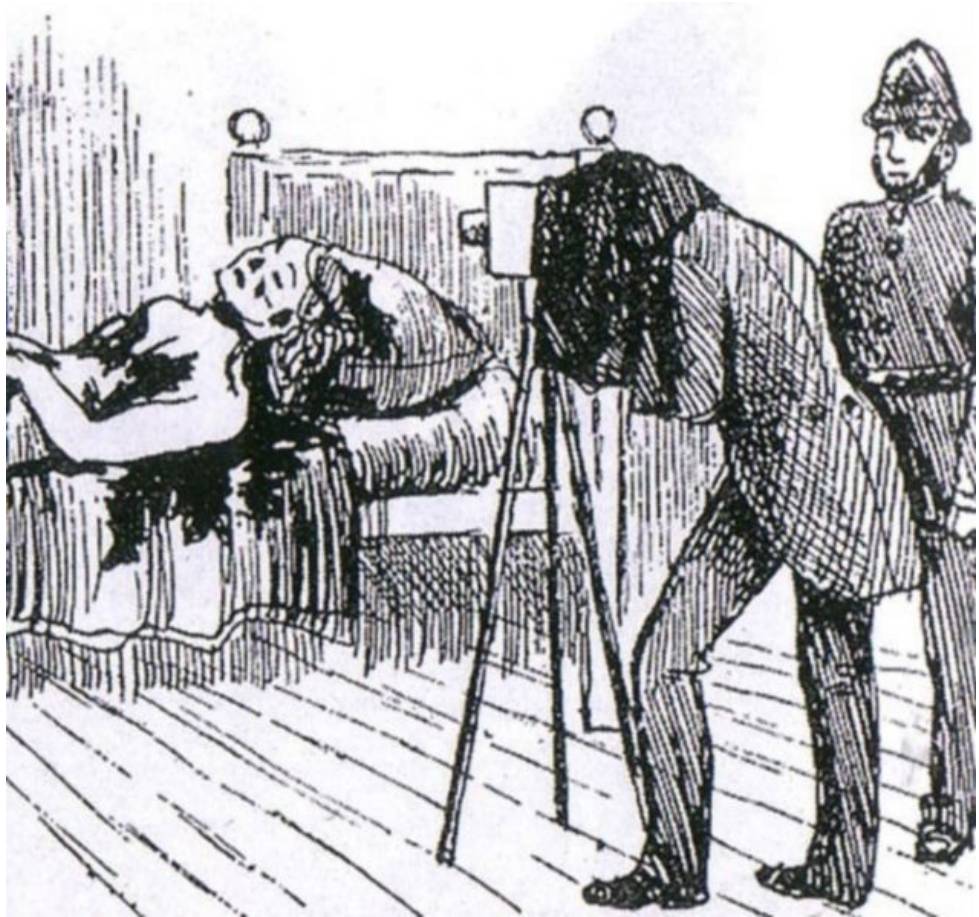
- Eddowes' body was found in Mitre Square in the City of London, three-quarters of an hour after Stride's. The throat was severed and the abdomen was ripped open by a long, deep, jagged wound. **The left kidney and the major part of the uterus** had been removed. A local man named Joseph Lawende had passed through the square with two friends shortly before the murder, and he described seeing a fair-haired man of shabby appearance with a woman who may have been Eddowes. His companions were unable to confirm his description. Eddowes' and Stride's murders were later called the "double event".

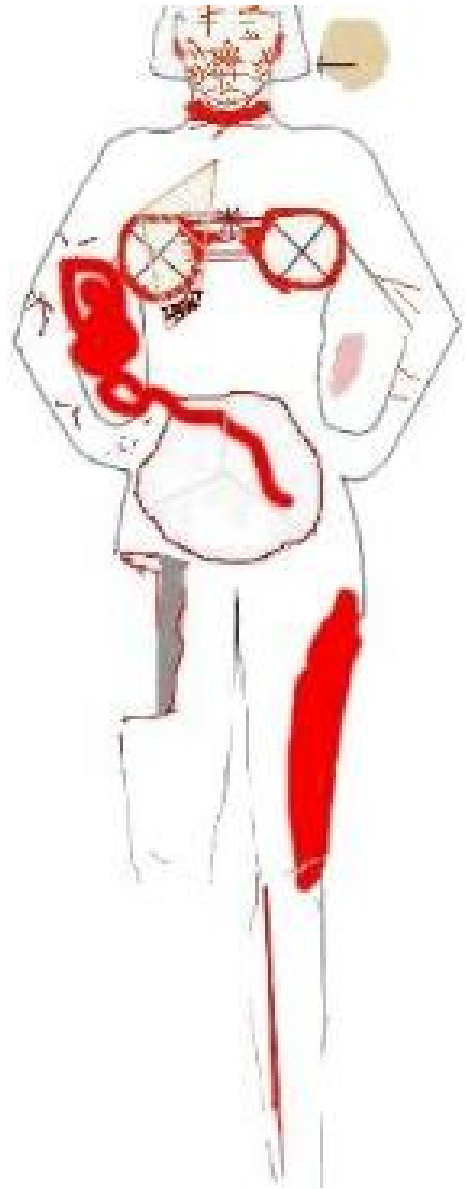


- Rigor mortis well marked; **green discoloration over abdomen**; body not quite cold; no traces of recent connection; recent bruise, size of a sixpence, on left hand between thumb and first finger; left eyelid cut; **deep cut on bridge of nose**; cut on right cheek; tip of nose detached; **2 abrasions on left cheek under left ear**; throat cut nearly ear-to-ear, dividing all tissues down to the bone; **frontal abdominal walls** cut open from the pubic area to the breast bone; liver was stabbed; left of the groin, a stab wound; **cuts made between the thighs and labium on both sides**; stomach contained very little food or fluid; intestines had been detached; **right kidney bloodless and pale**; **gall bladder had bile**; pancreas was cut; left kidney removed; **uterus lining was cut**; womb was cut through leaving 3/4" of a stump; womb was removed; **bladder was healthy**.

## 5.Victim - Mary Kelly


- Kelly's mutilated and **disembowelled body** was discovered lying on the bed in the single room where she lived at 13 Miller's Court, off Dorset Street, Spitalfields, at 10:45 a.m. on Friday 9 November 1888. The throat had been severed down to the spine, and the abdomen almost emptied of its organs. The heart was missing.





- The thighs were stripped; the abdomen was removed, abdominal cavity was empty; the breasts were cut off; arms were mutilated; Facial features were removed; the neck was severed down to the spine; left femur split from the hips downward, exposing the marrow cavity. The uterus, kidneys, and one breast were placed under the head; The other breast was by the right foot; The liver was placed between the feet; Intestines lay by the right side of the body; Flesh removed from the abdomen and thighs were placed on the table; The heart was absent from the room. Bed clothing and the right corner of the bed were saturated with blood; About two square feet of blood was below the bed; The wall by the right bedstead had several splashings of blood. The face was cut in all directions; Numerous cuts across all features; The neck was cut down to the vertebrae; The cuts showed distinct ecchymosis; The breasts were removed by quasi-circular incisions; Associated muscles attached to the breasts; Thorax visible through the cuts; Abdomen and costal arch to pubes removed; Front right thigh skinned down to the bone; Left thigh stripped of skin and muscle as far as the knee; The left calf had a long incision running from the knee to 5" above the ankle; Both arms and forearms had extensive jagged wounds; The right thumb had a 1" superficial cut, extravasation of the blood in the skin and several abrasions on the back of the hand; Lower part of the right lung was broken and torn away; Left lung intact; Pericardium was open and the heart absent; Partly digested food found in the abdominal cavity and in the stomach remains.





HERMAN WEBSTER MUDGETT *alias* H. H. HOLMES.

