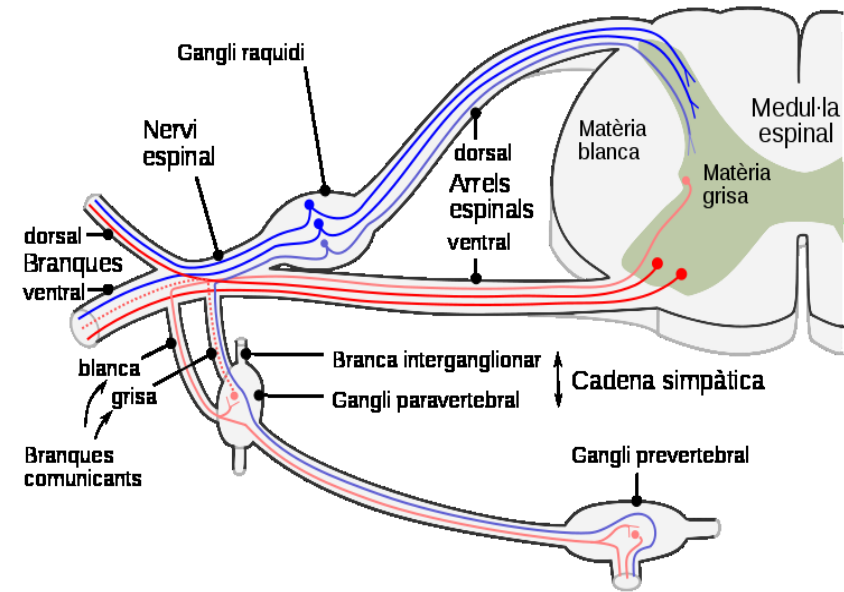
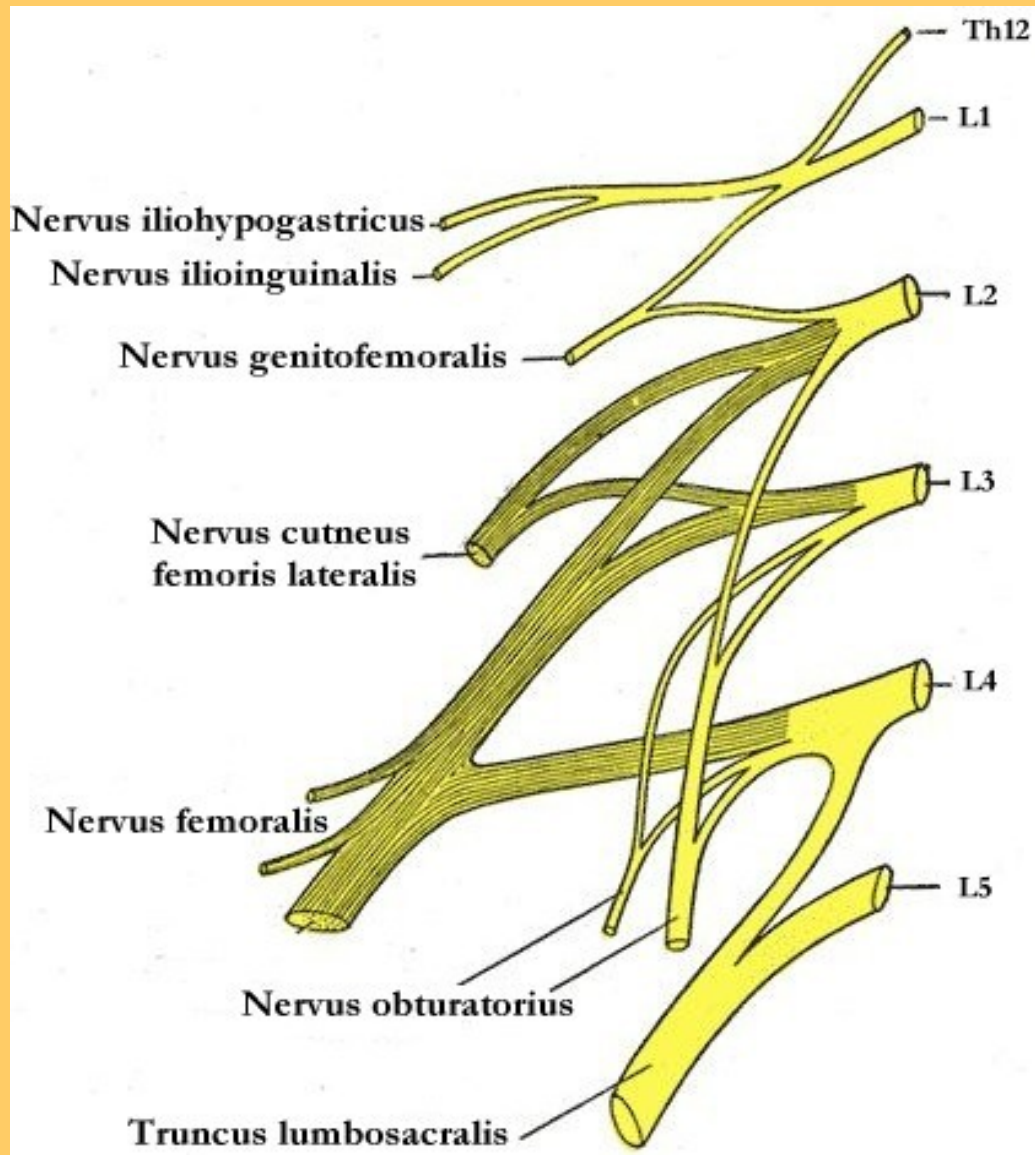
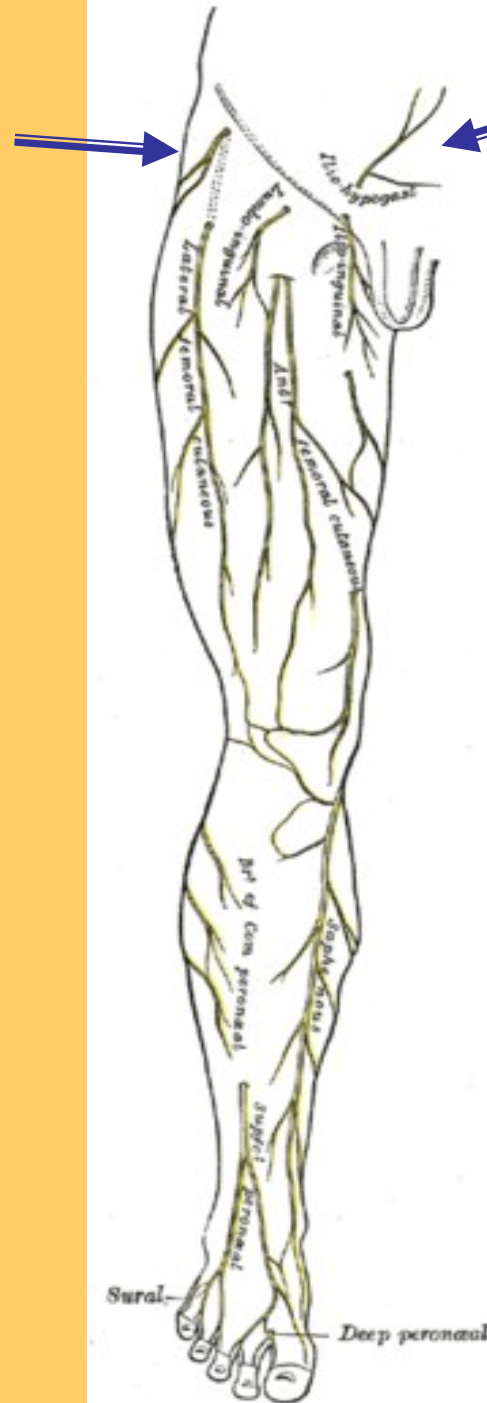


# **Nervy dolní končetiny topografie(2)**



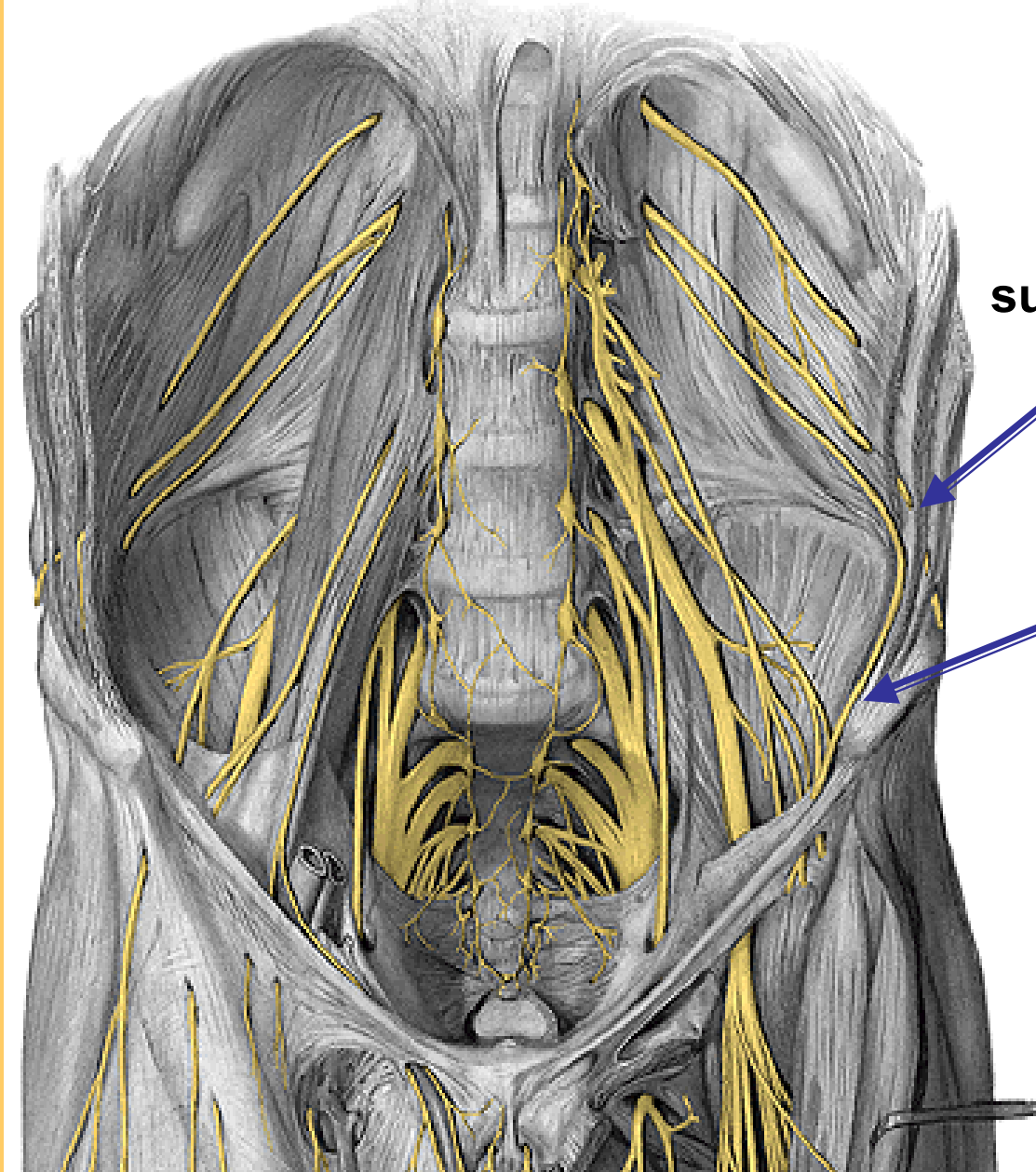
## PLEXUS LUMBALIS





= kožně u spiny a anulu

n. iliohypogastricus

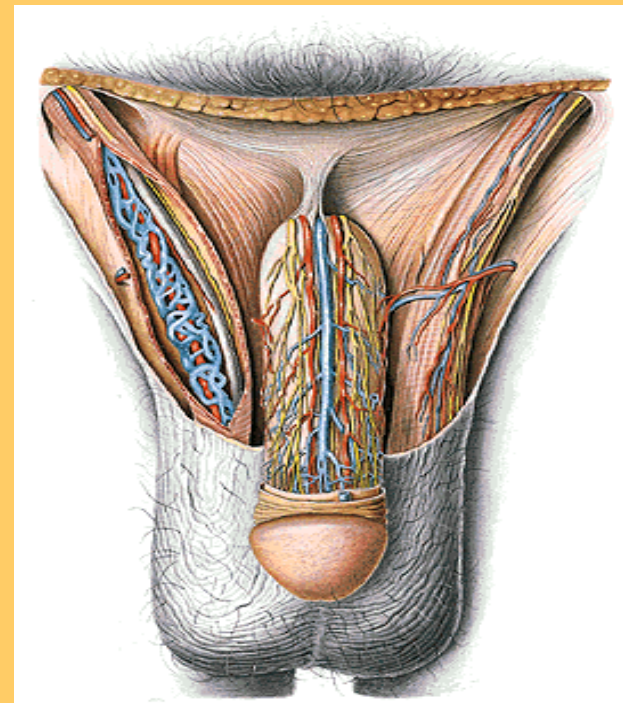


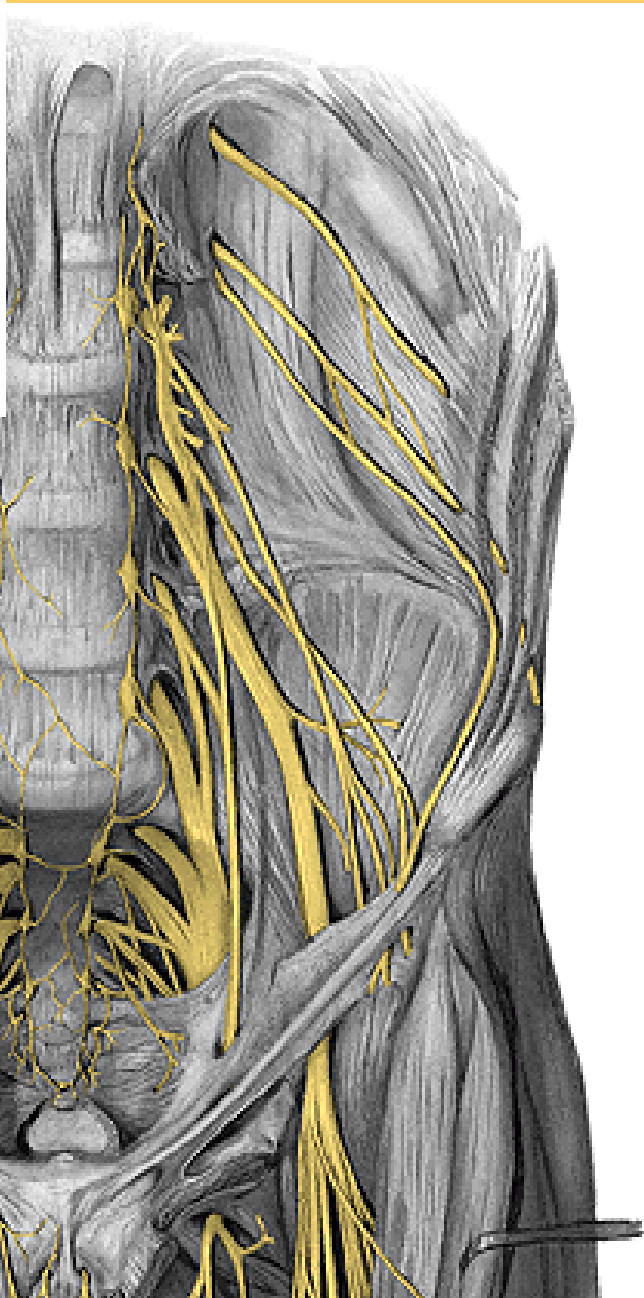
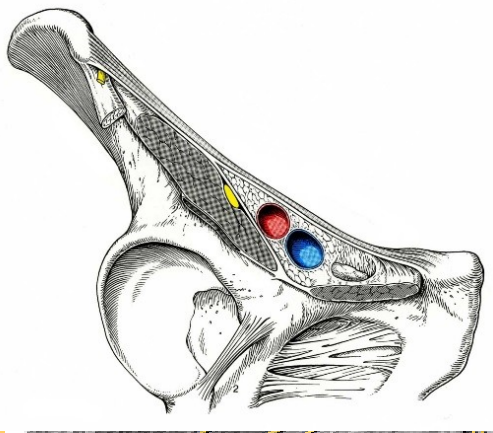
sub.cost.

iliohypogastr.

**B) n.ilioinguinalis**

do zevního anulu- lat.:  
cremaster, scrotum, labia

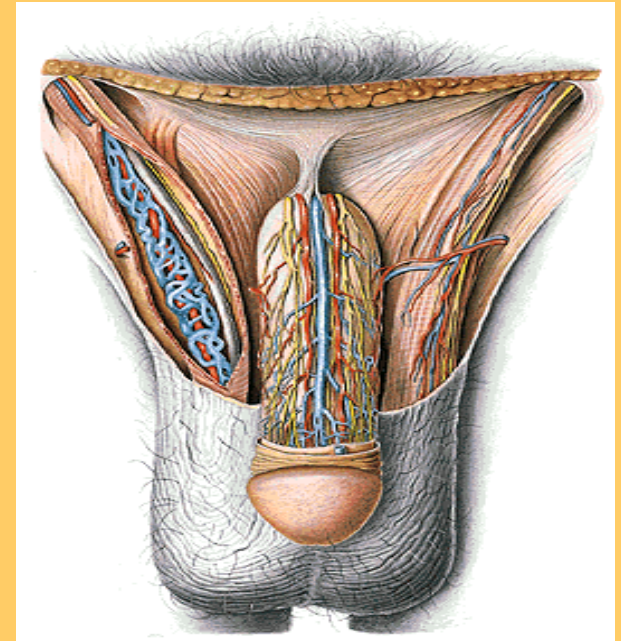




TOPO:  
psoas

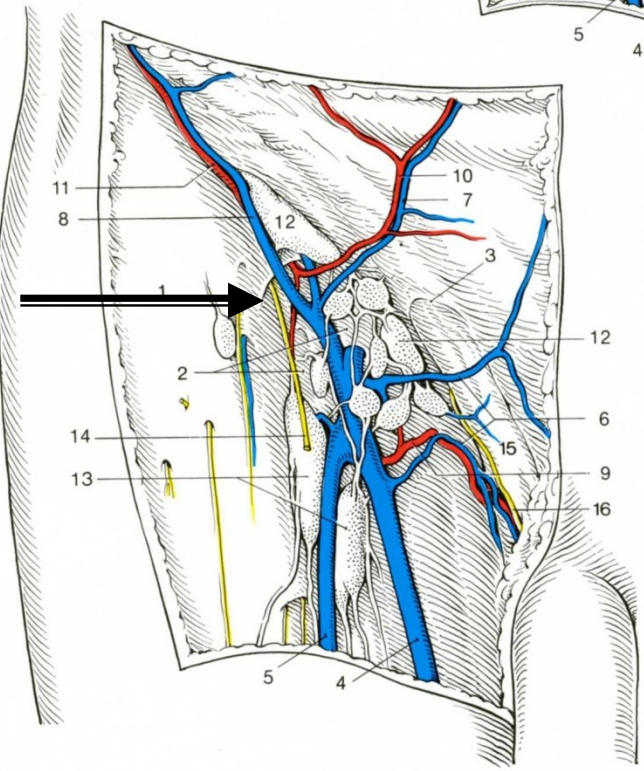
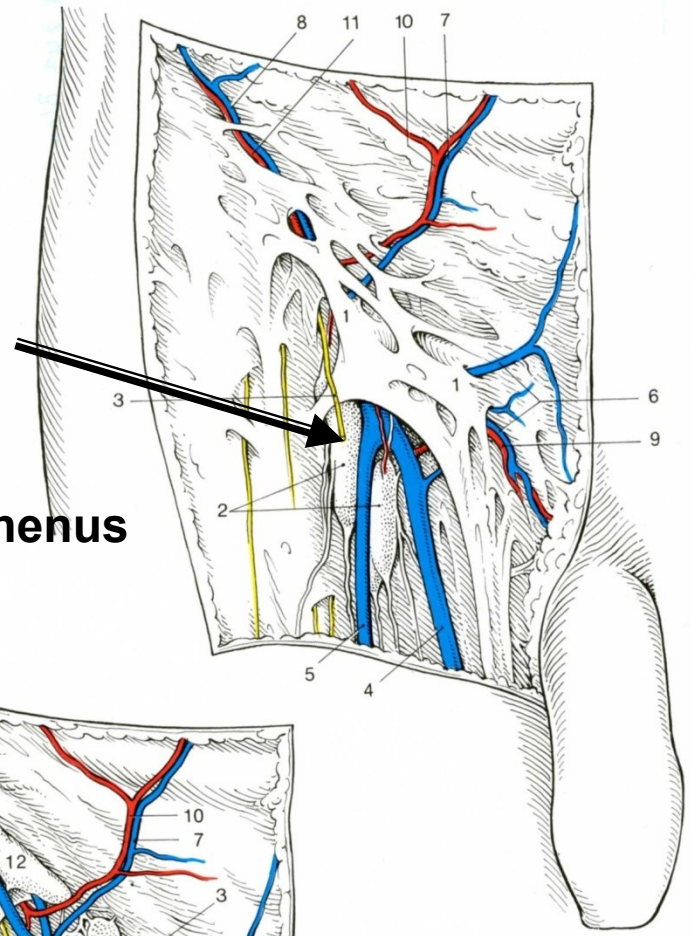
Větve :

- r. **genitalis** - med.ve funic.-  
cremaster, dartos,scrotum
- r. **femoralis** – v lacun. vasor.-  
k hiatus saph.

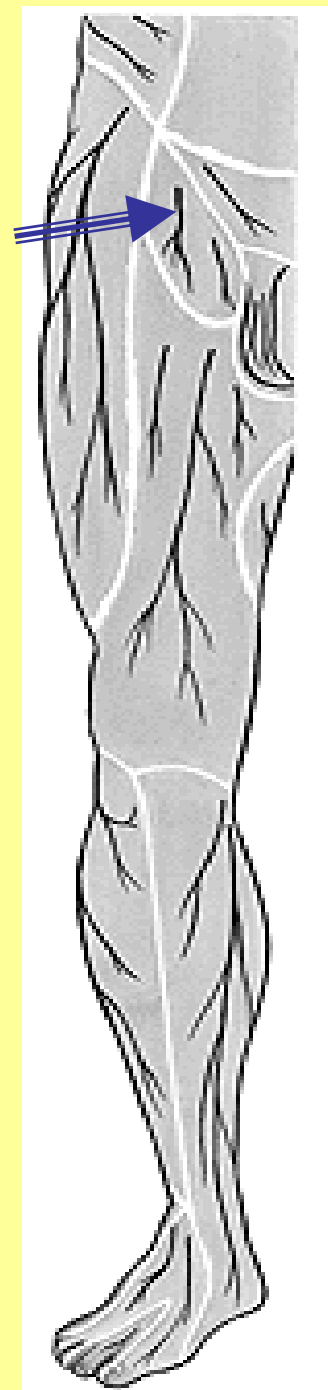


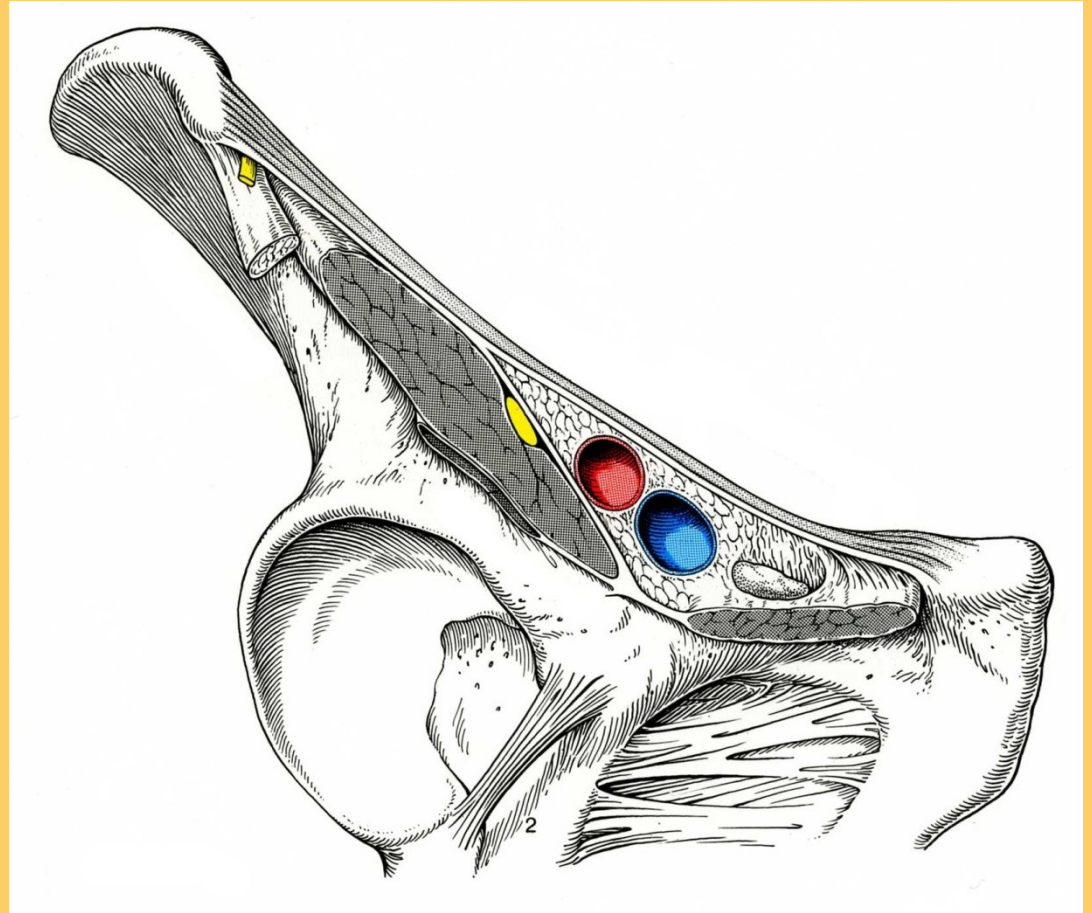
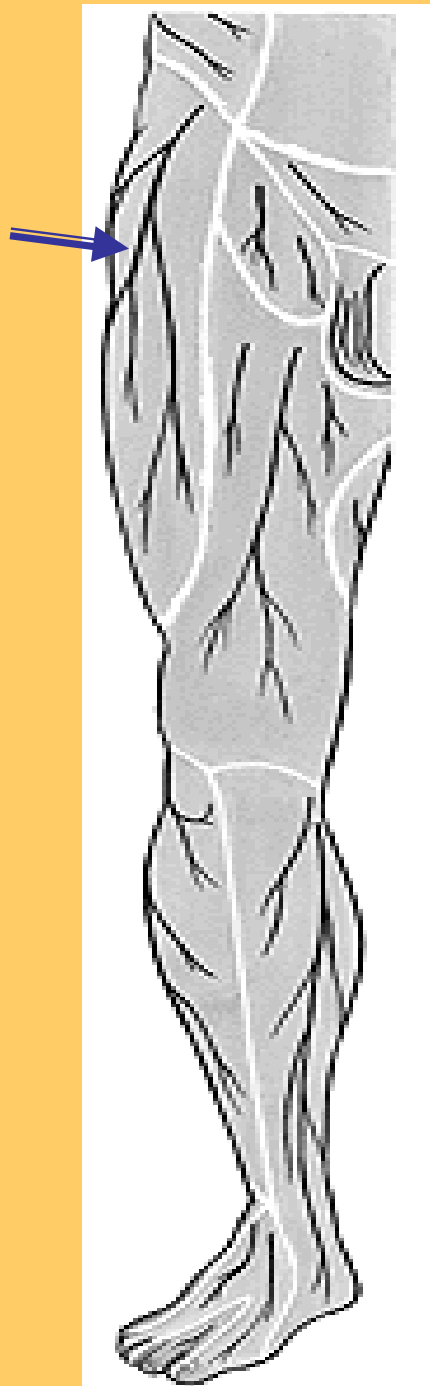
C) n. genitofemoralis

**Hiatus saphenus**



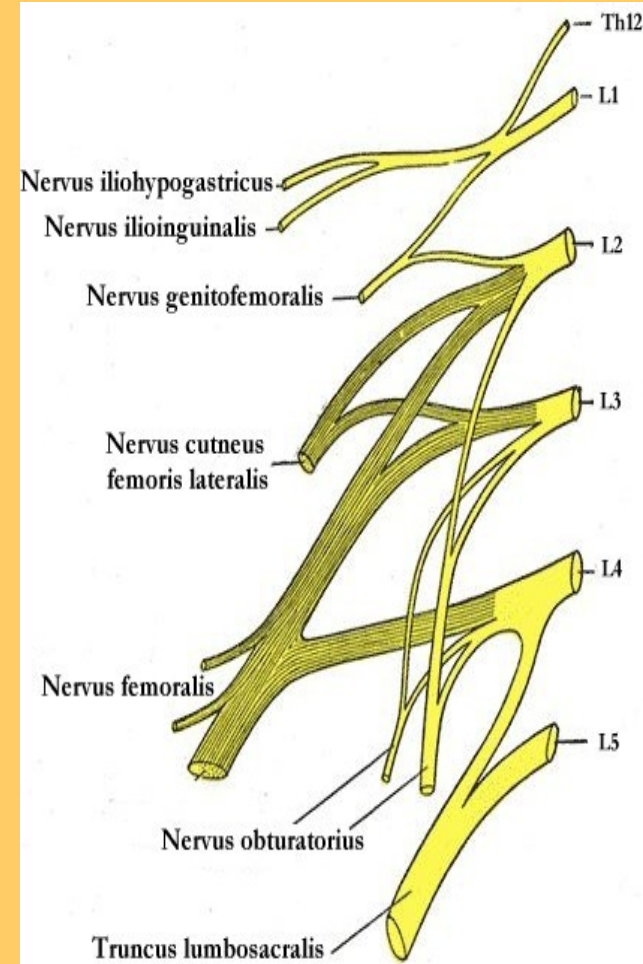
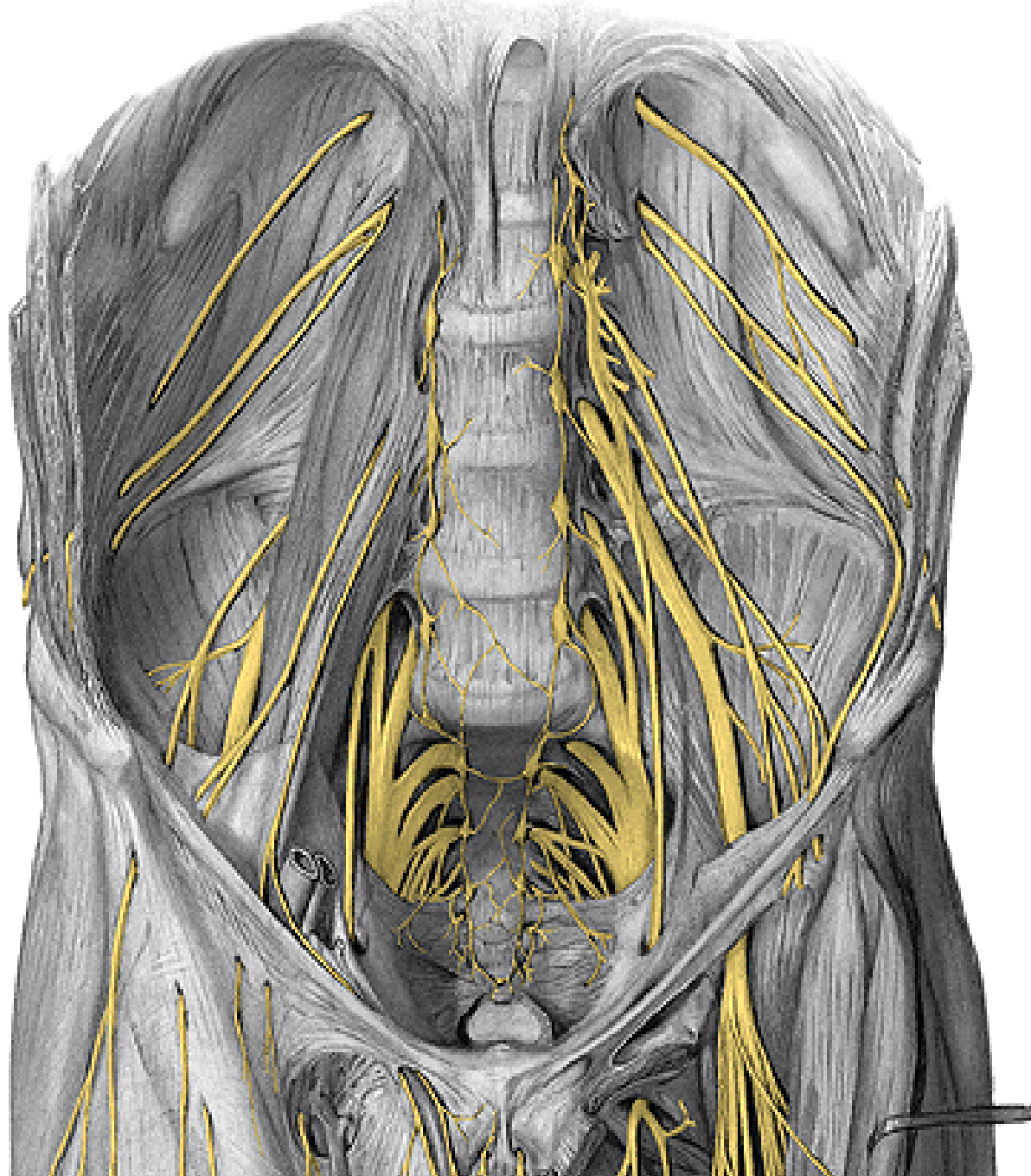
**r. femoralis**





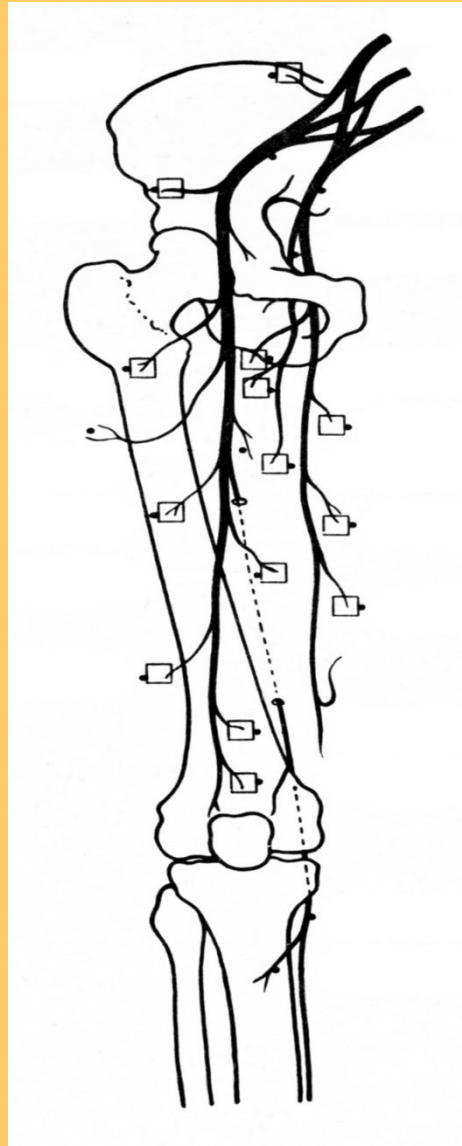
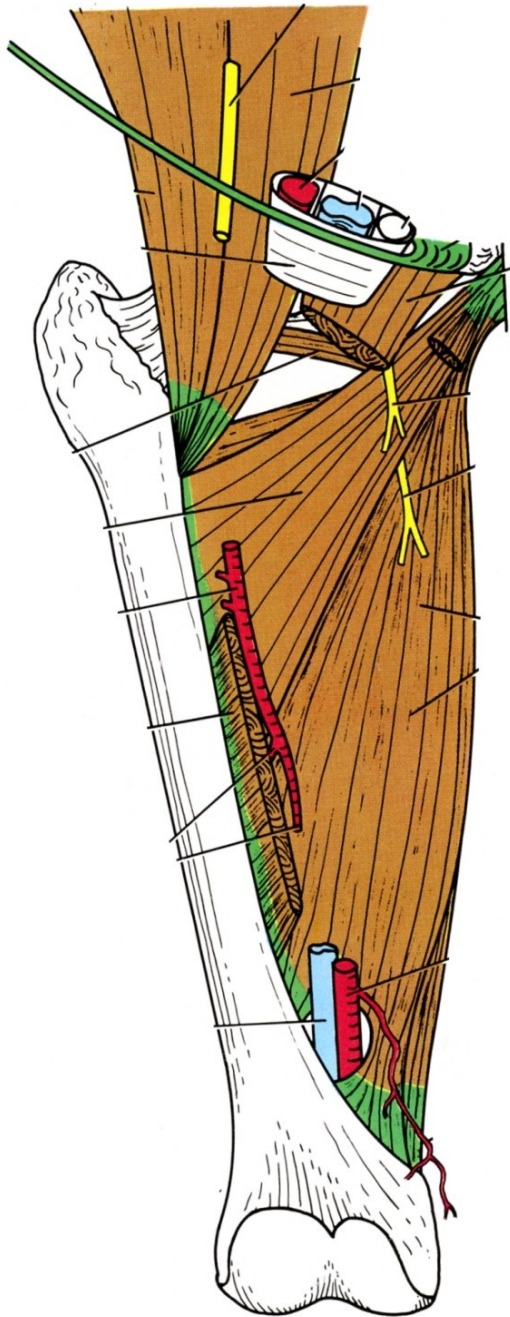
d) n. cutaneus femoris lat.





**TOPO:**

**e) n. obturatorius**

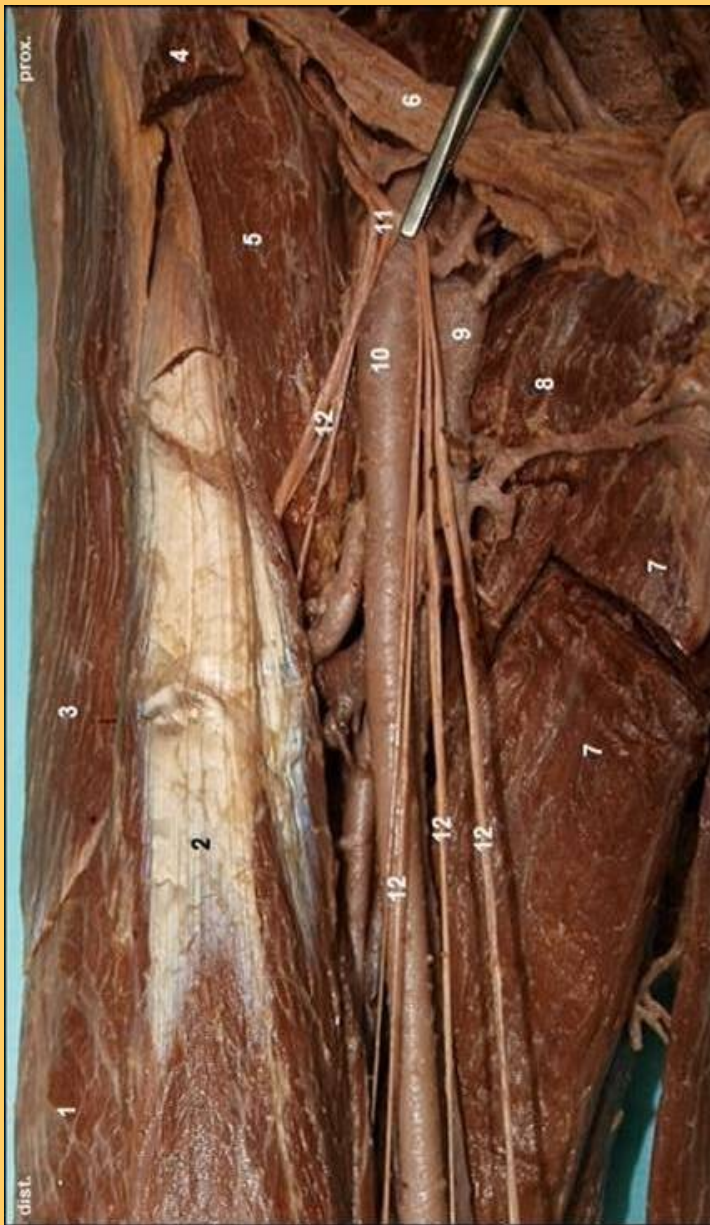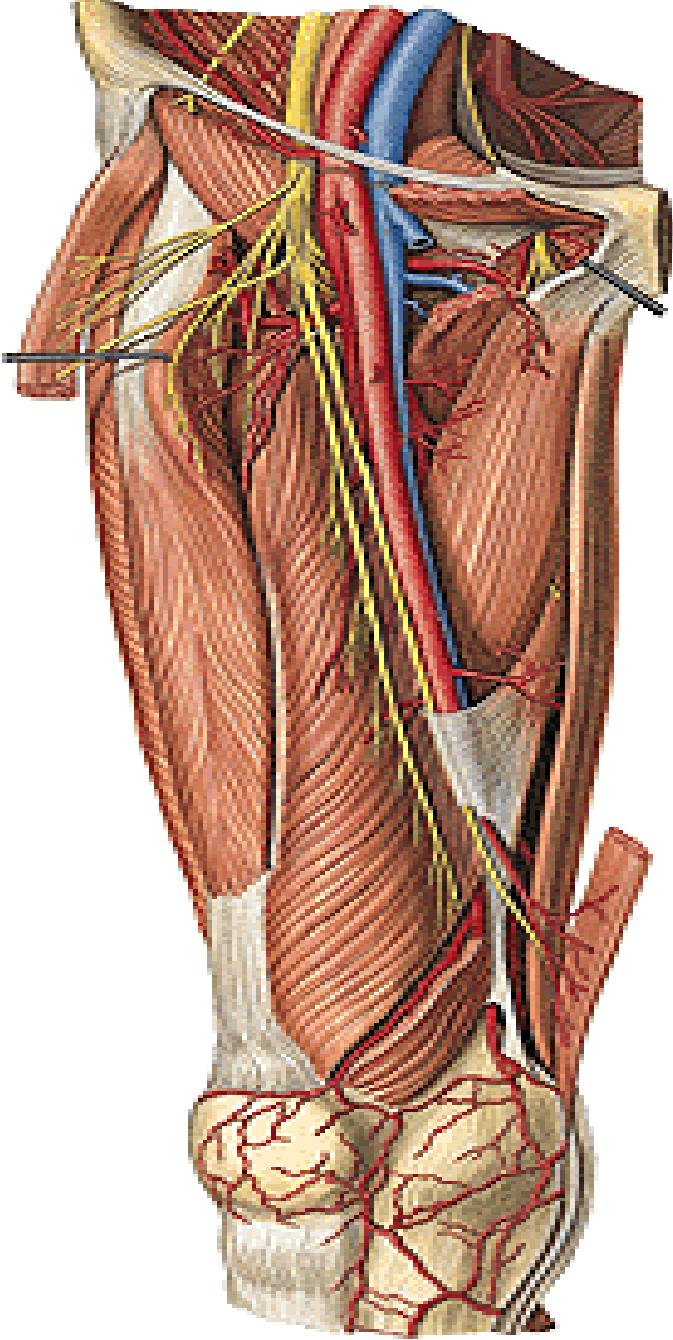


**n. obturatorius**

**a) r. anterior – mezi adduktory  
long., brev., pect.**

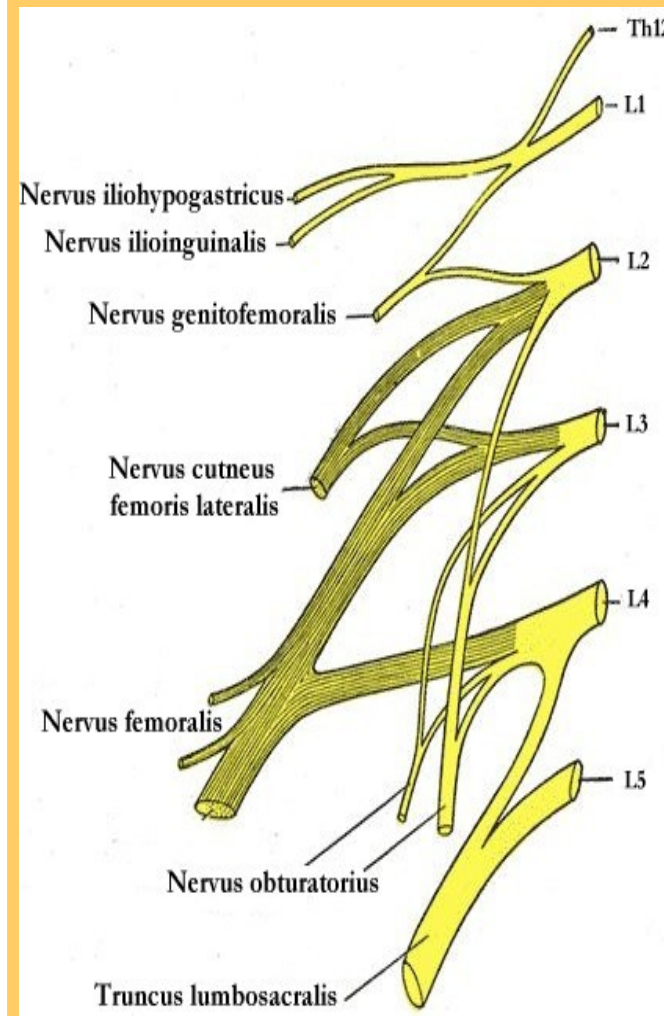
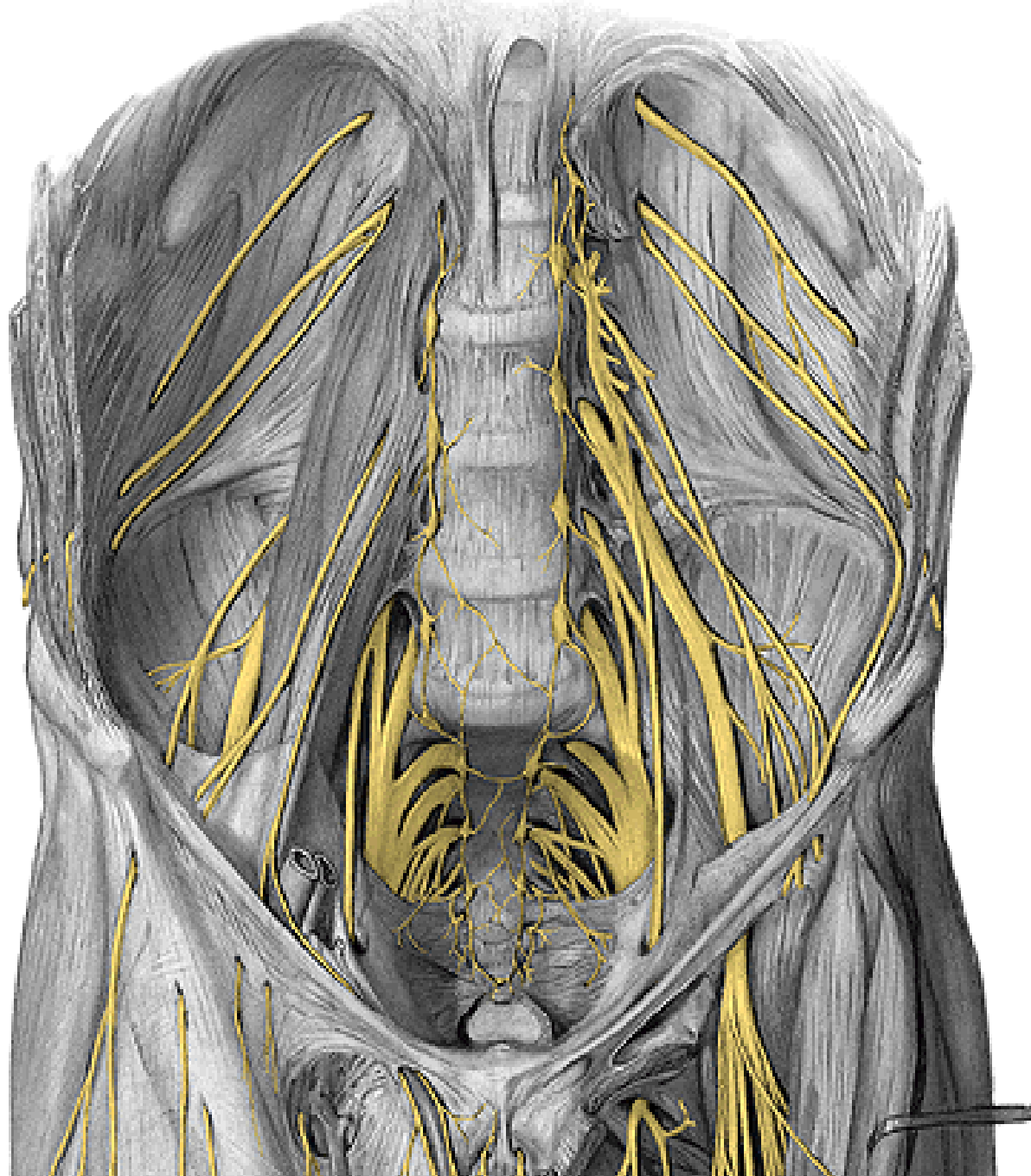
**b) r. posterior – add. magnus**



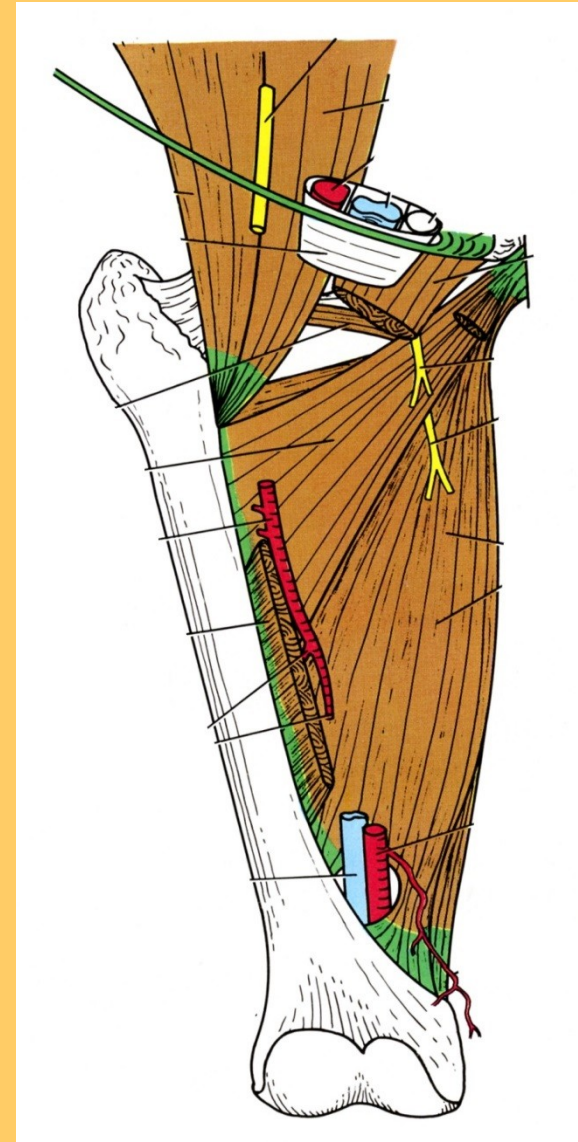
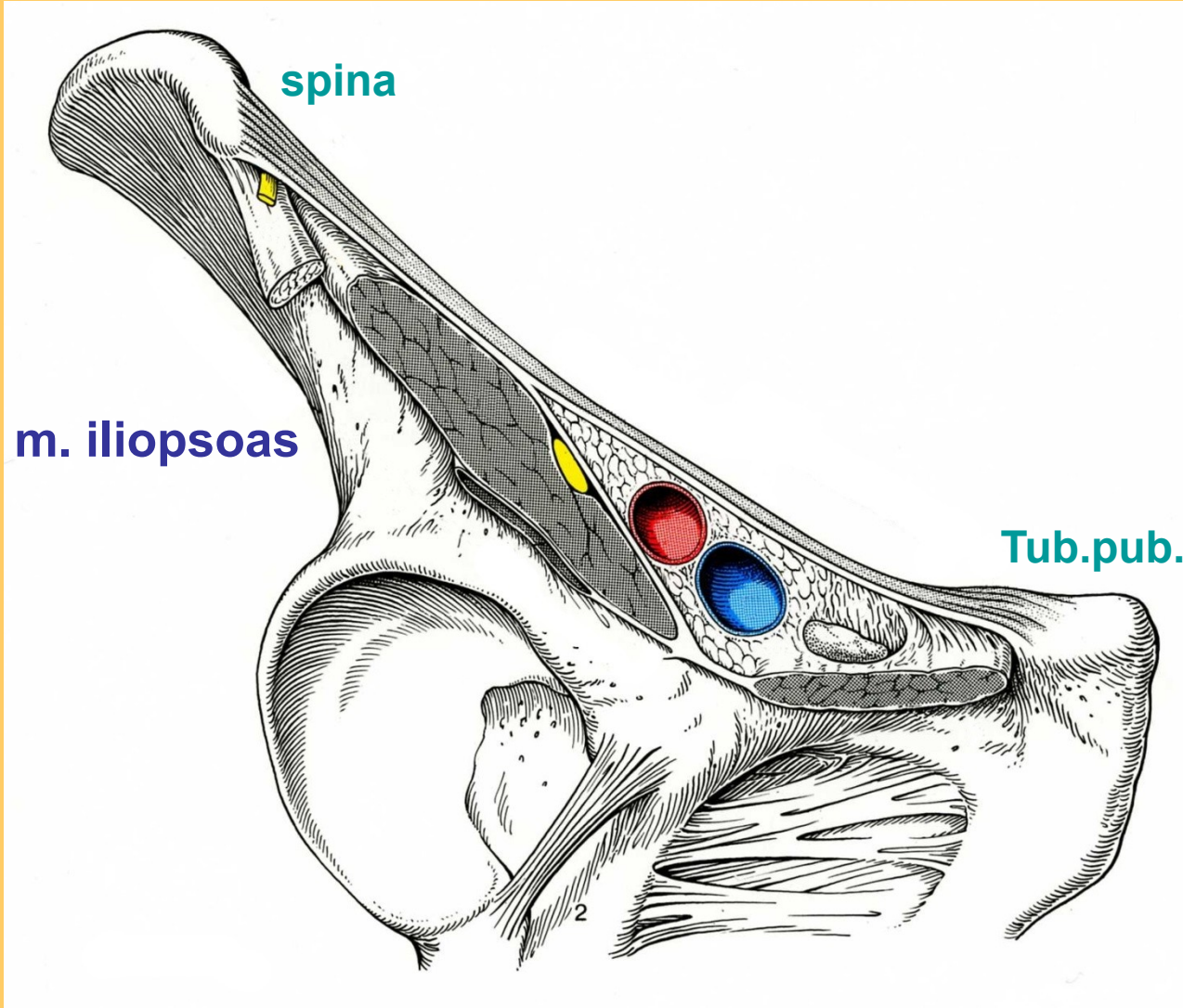


**r. anterior**

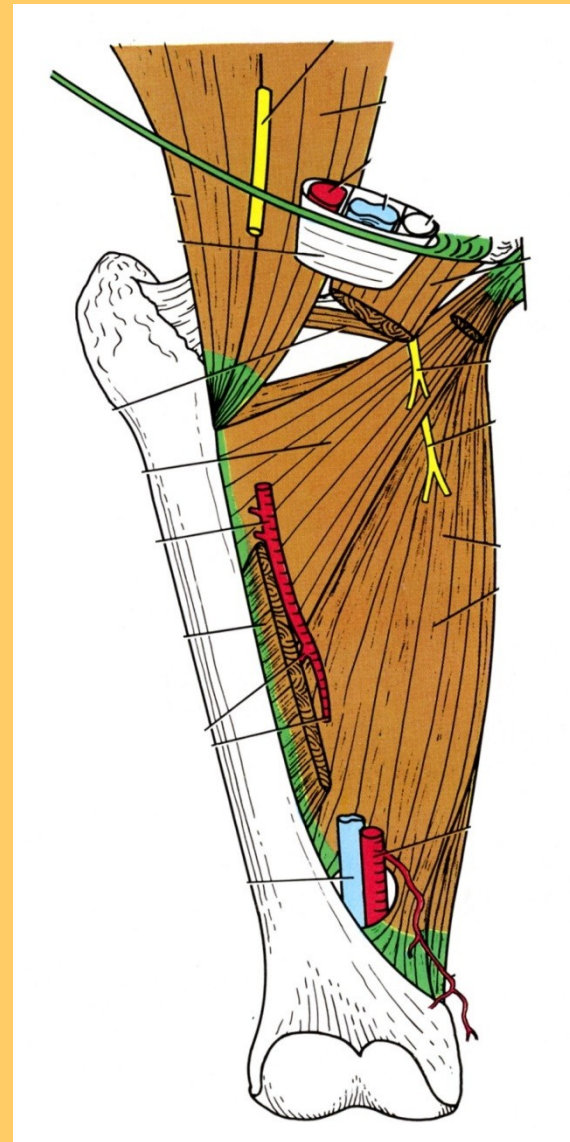
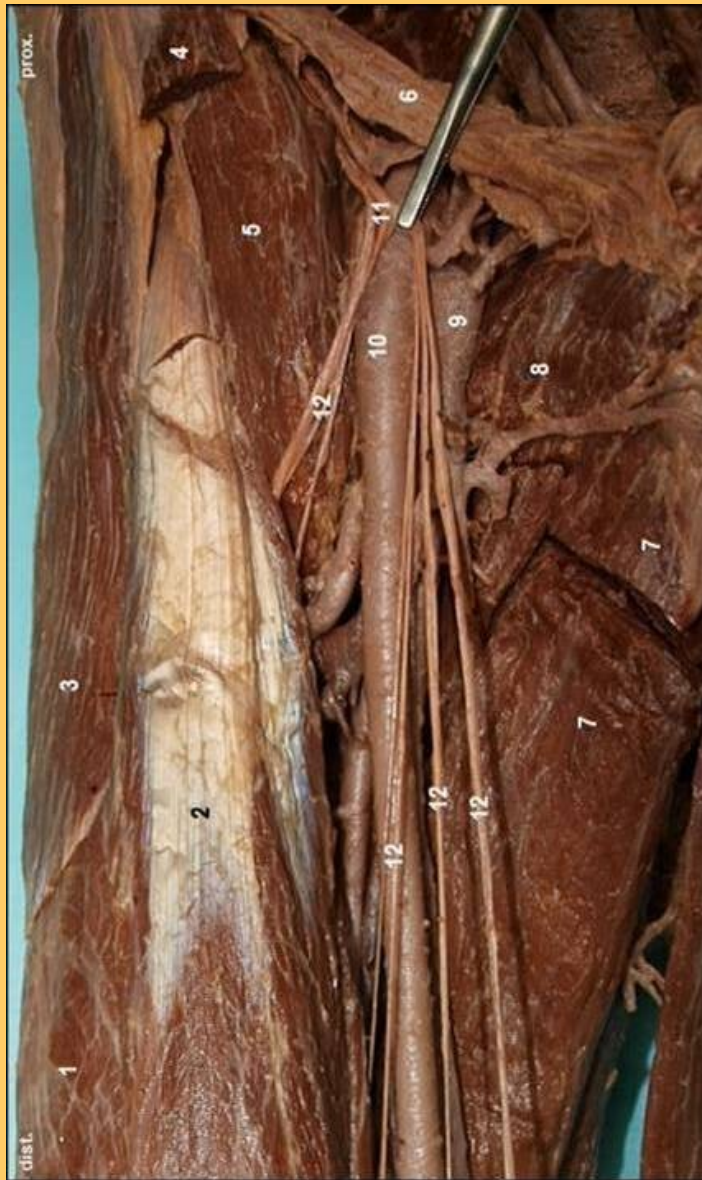**n. obturatorius**



**f) n. femoralis**

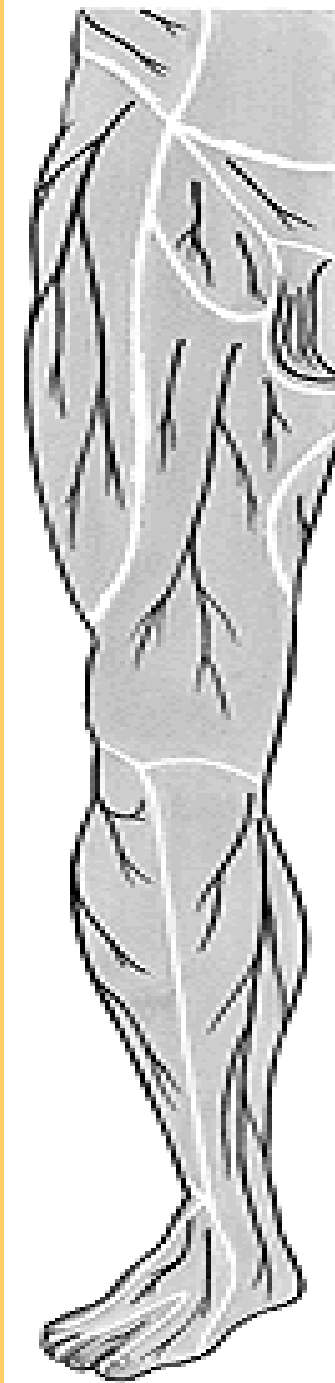
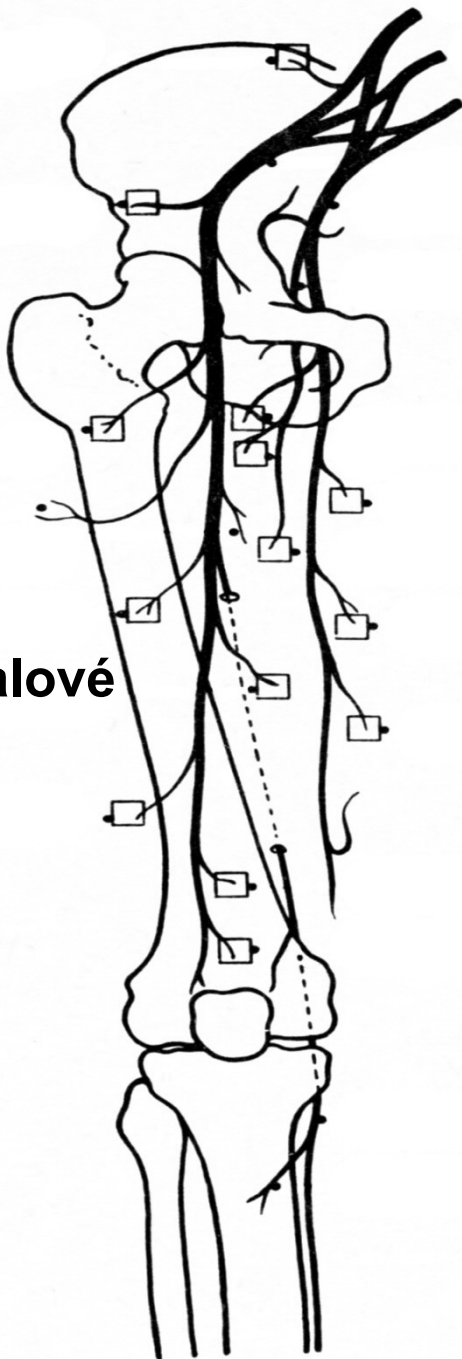


LACUNA musculorum – N. FEMORALIS



**n. femoralis :** 5 – m. iliopsoas, 7- adductor longus., 8 - pectineus

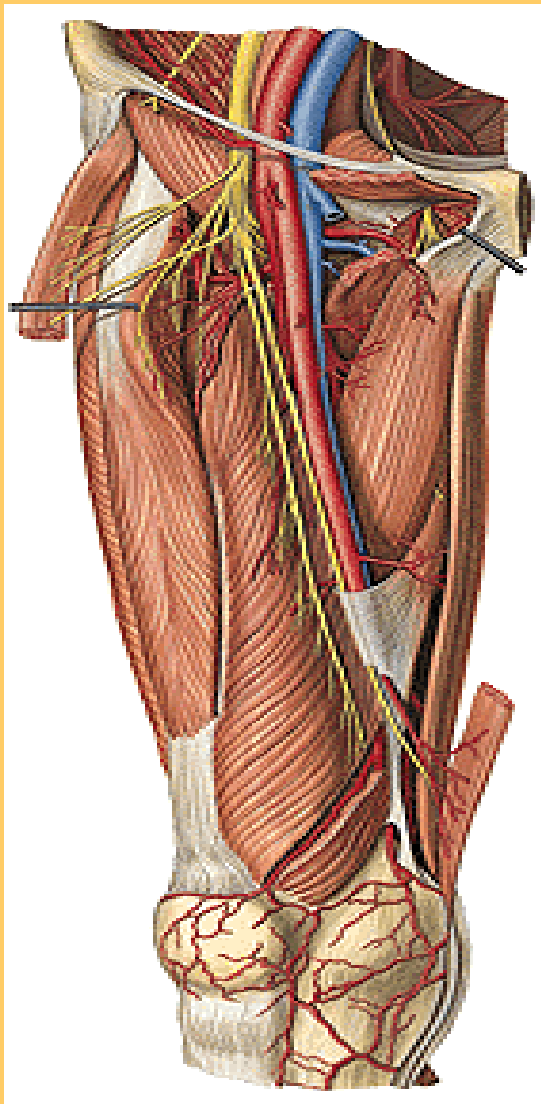
**svalové**



**rr. cutanei ant.**

**n. cutaneus cruris med.**  
při **v. saphena**,  
(**štěpy na by pass**)

**n. femoralis**



**1 – nervus femoralis 2 – n. saphenus  
3 - rr. musculares**





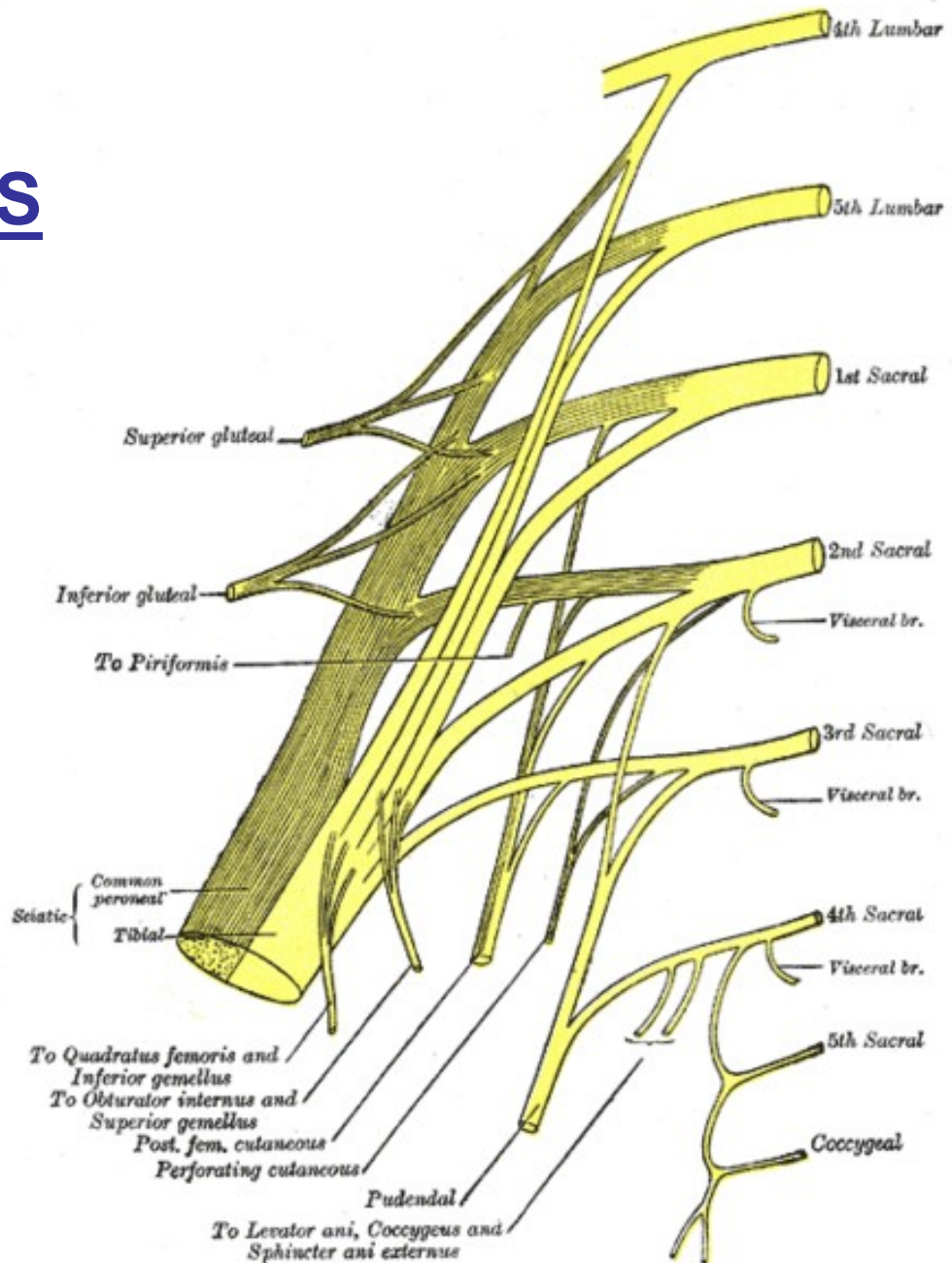
# PLEXUS SACRALIS

n. gluteus sup.

- inf.

n. ischiadicus

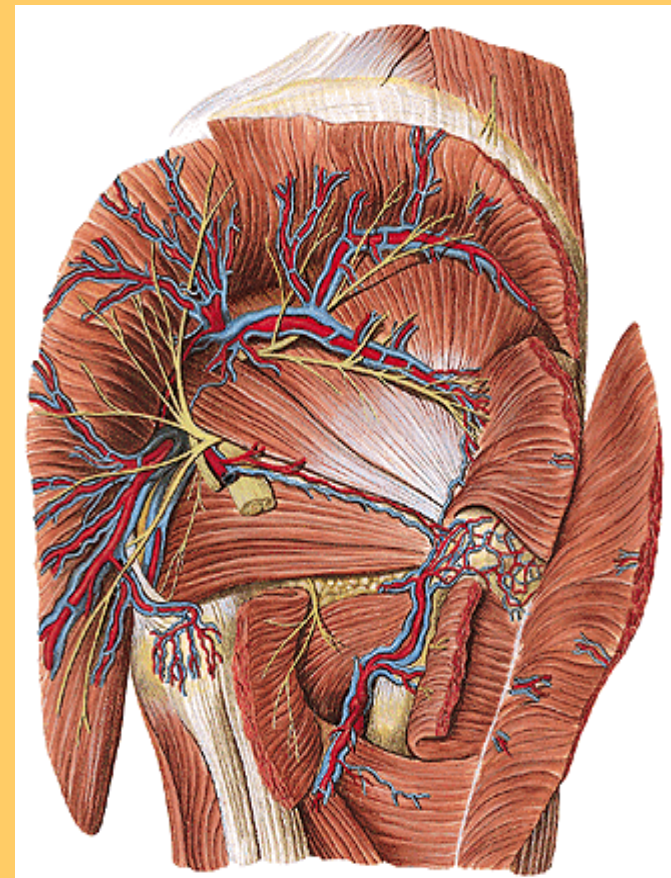
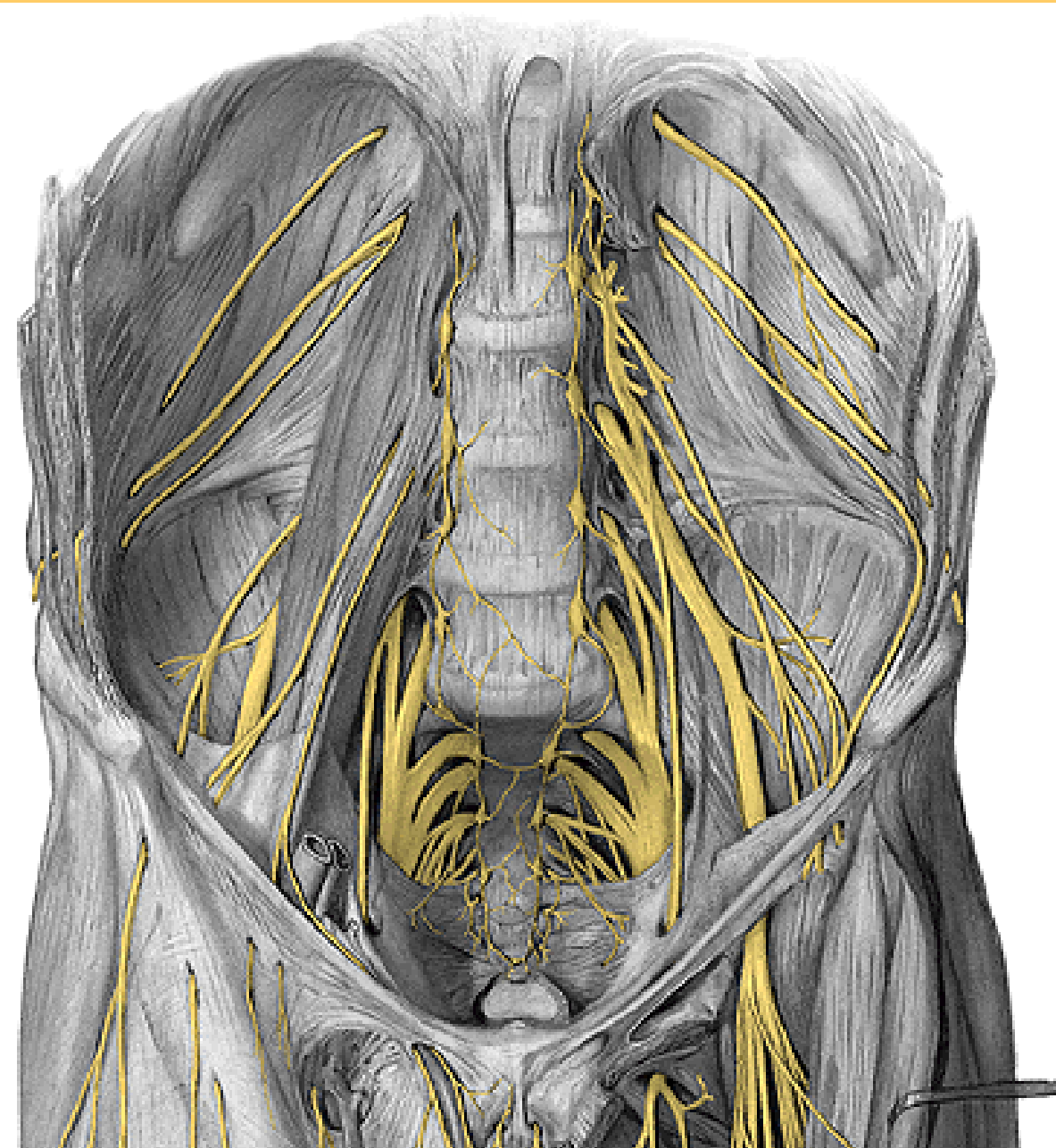
rr. muscul.  
cutan. fem. post.  
pudendus  
coccygeus



L4  
L5  
S1  
S2  
S3  
S4  
S5  
Co

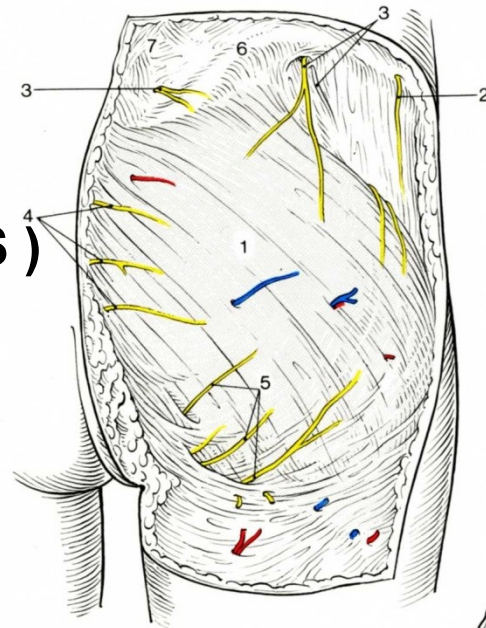
TOPO: sacrum, piriform.

a) **N. GLUTEUS**



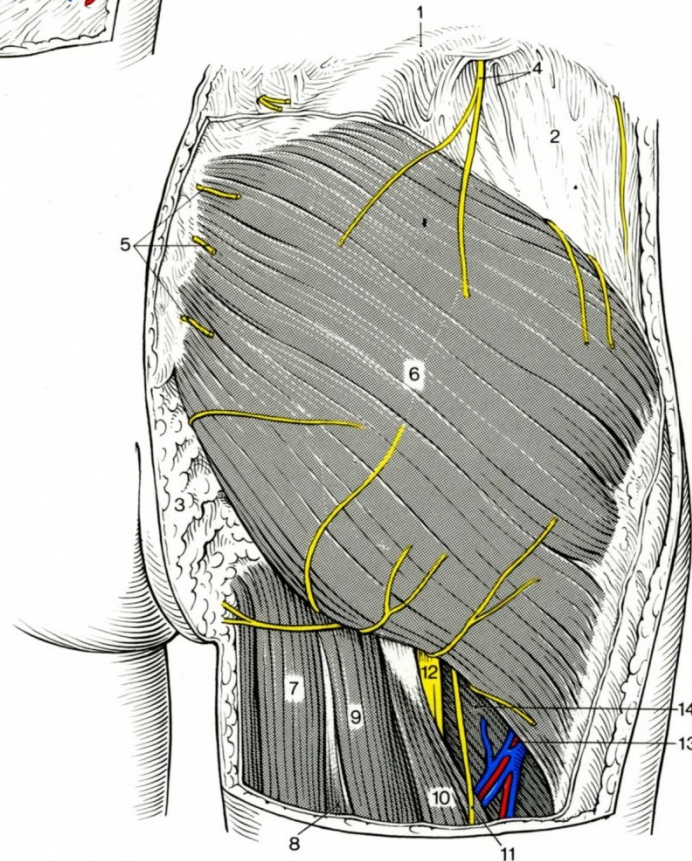
nn. clunium  
( clunii )

med.( S )

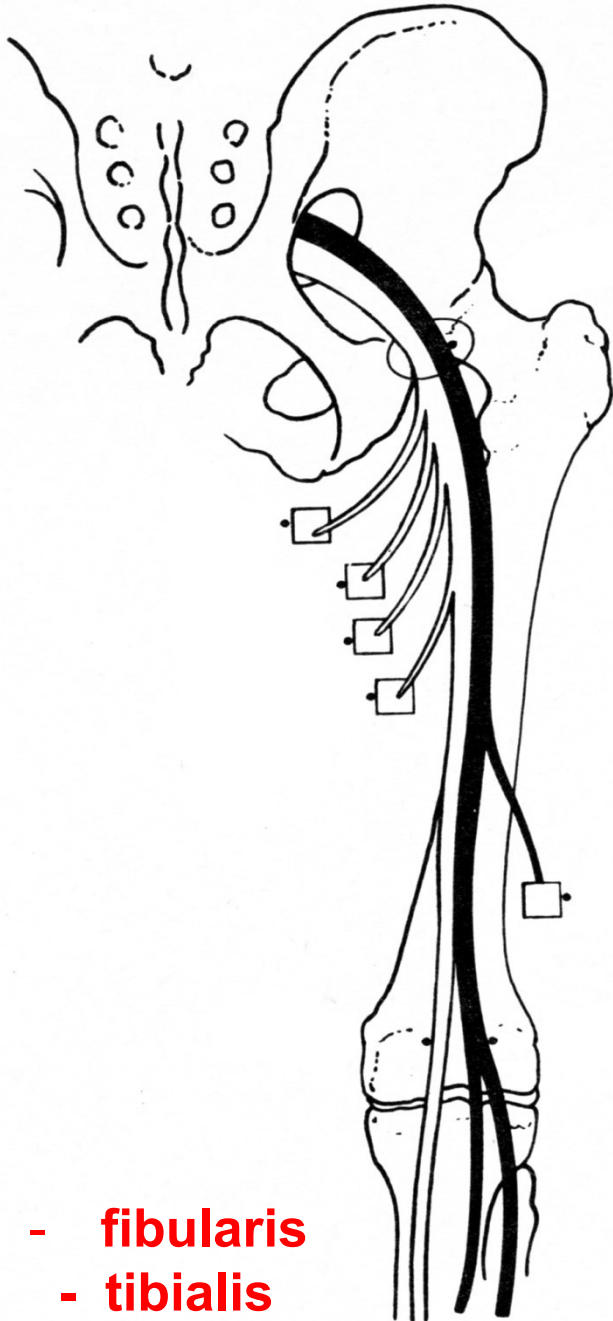


sup. ( L )

inf.

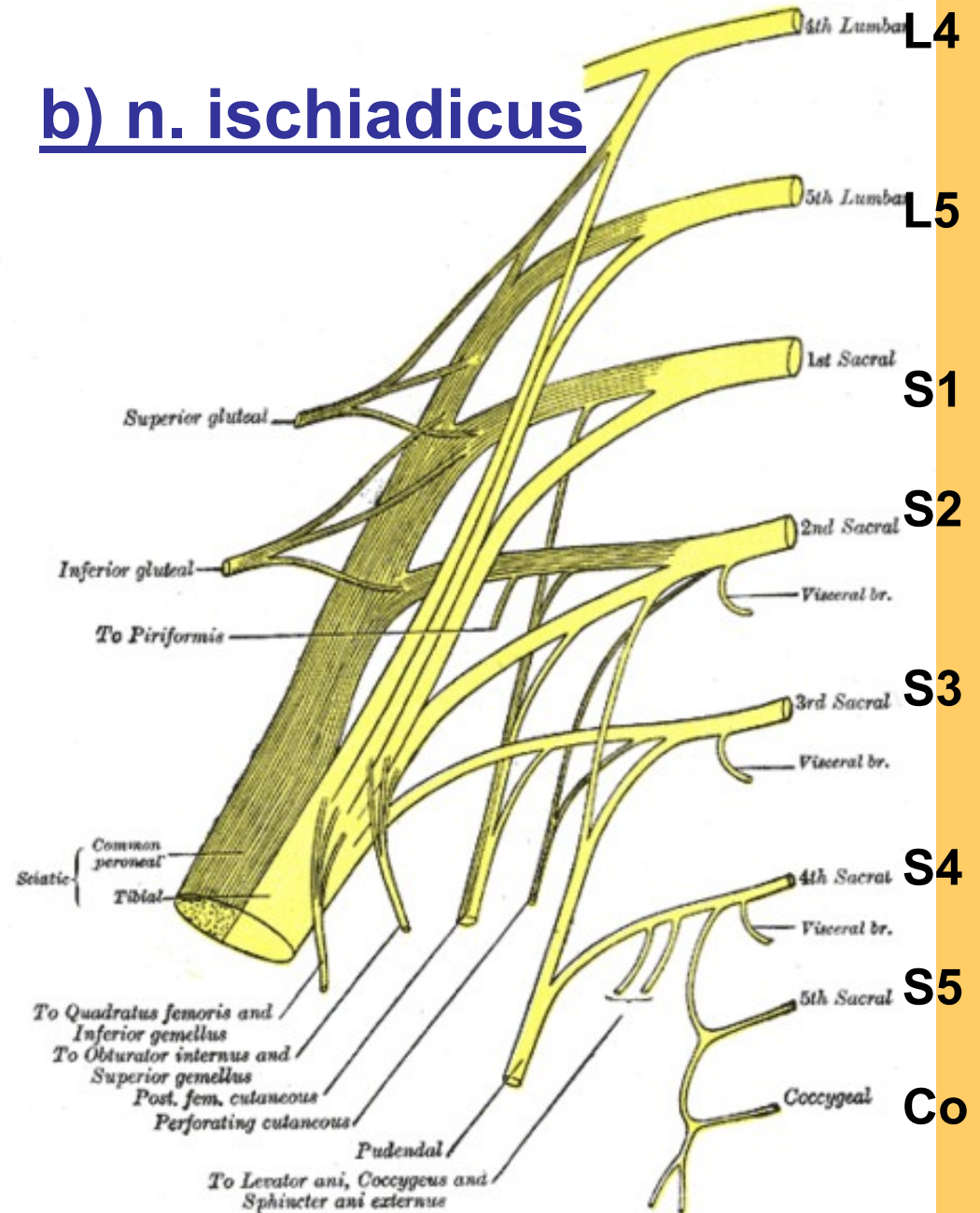


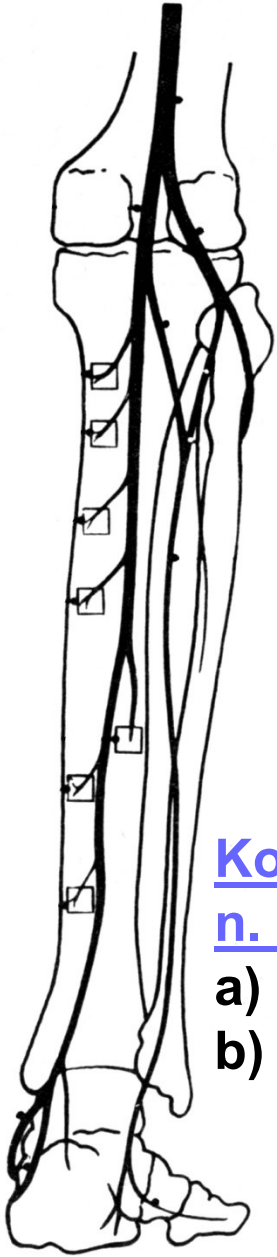
r. perinealis  
= cut. fem.



- fibularis
- tibialis

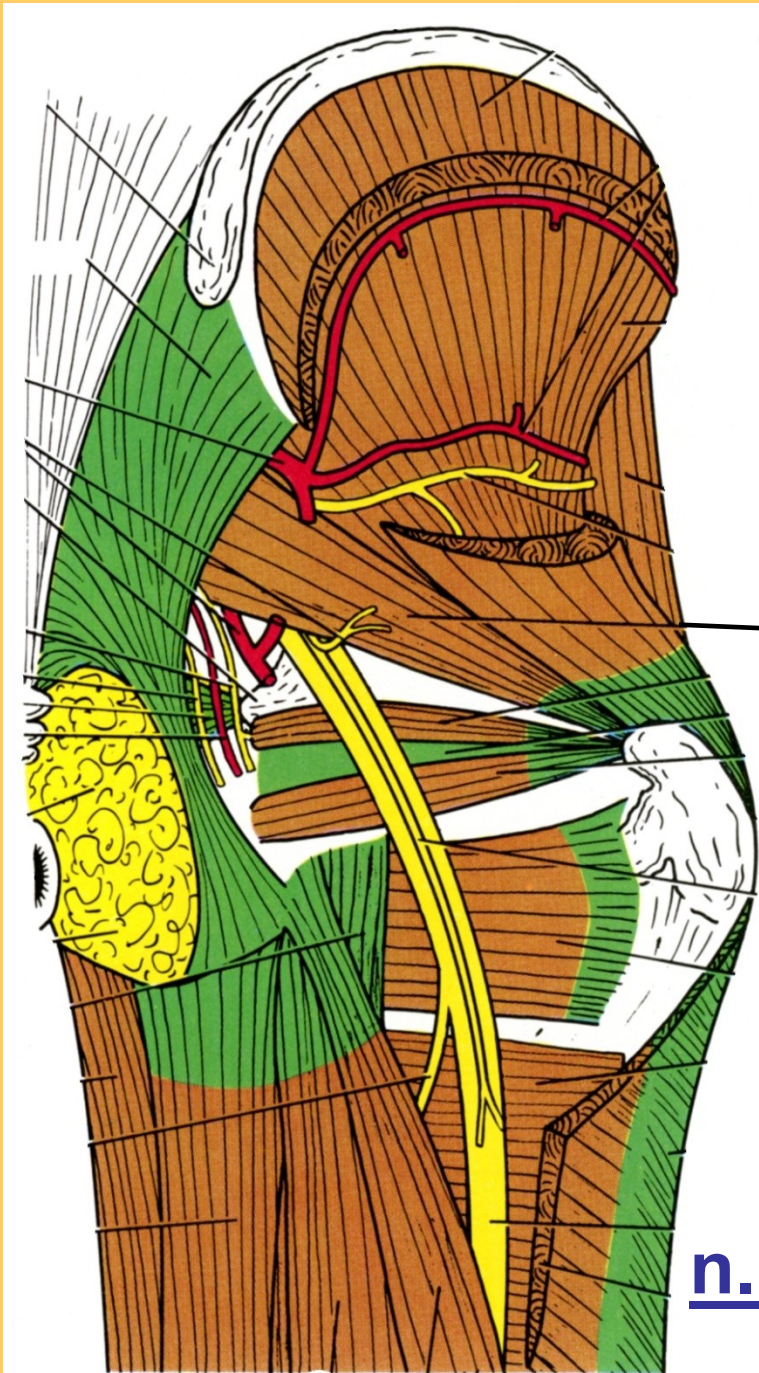
## b) n. ischiadicus





Konečné větve  
n. ischiadicus:

- a) n.fibularis
- b) n. tibialis



glut.med.

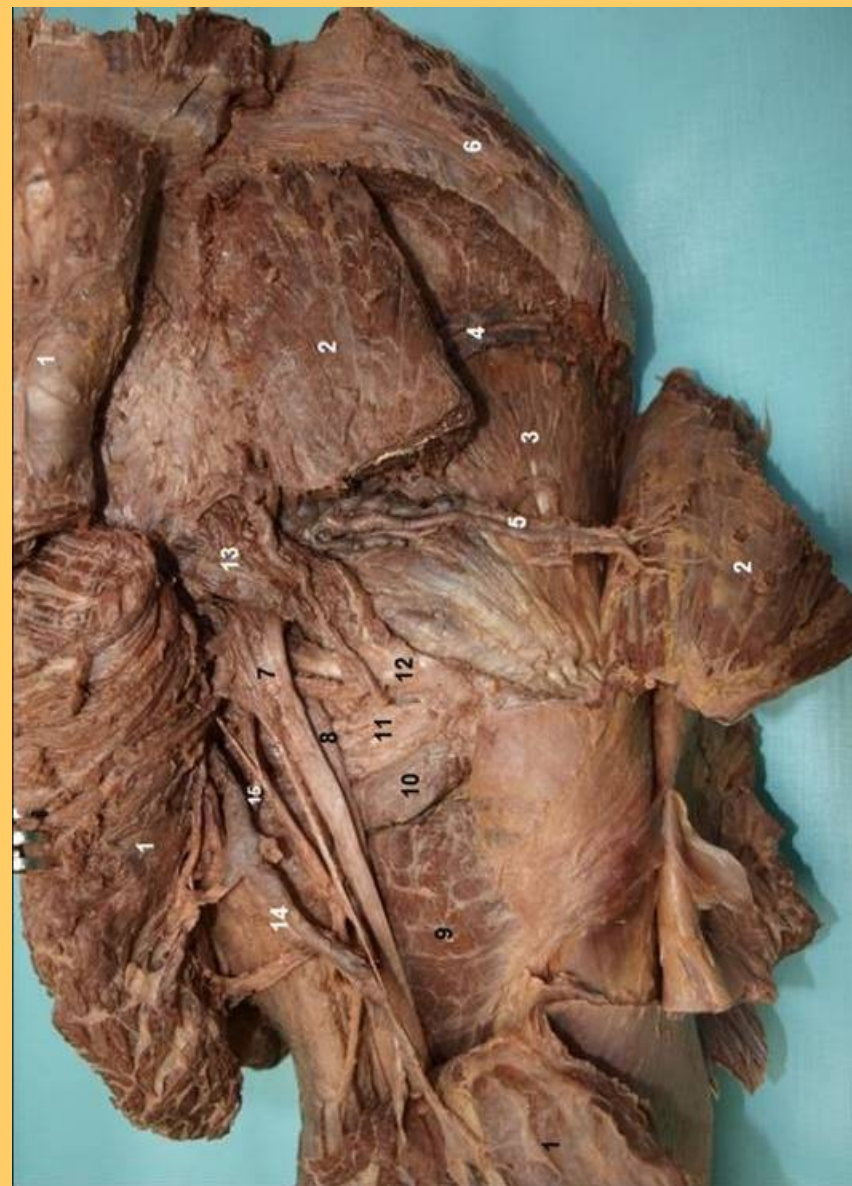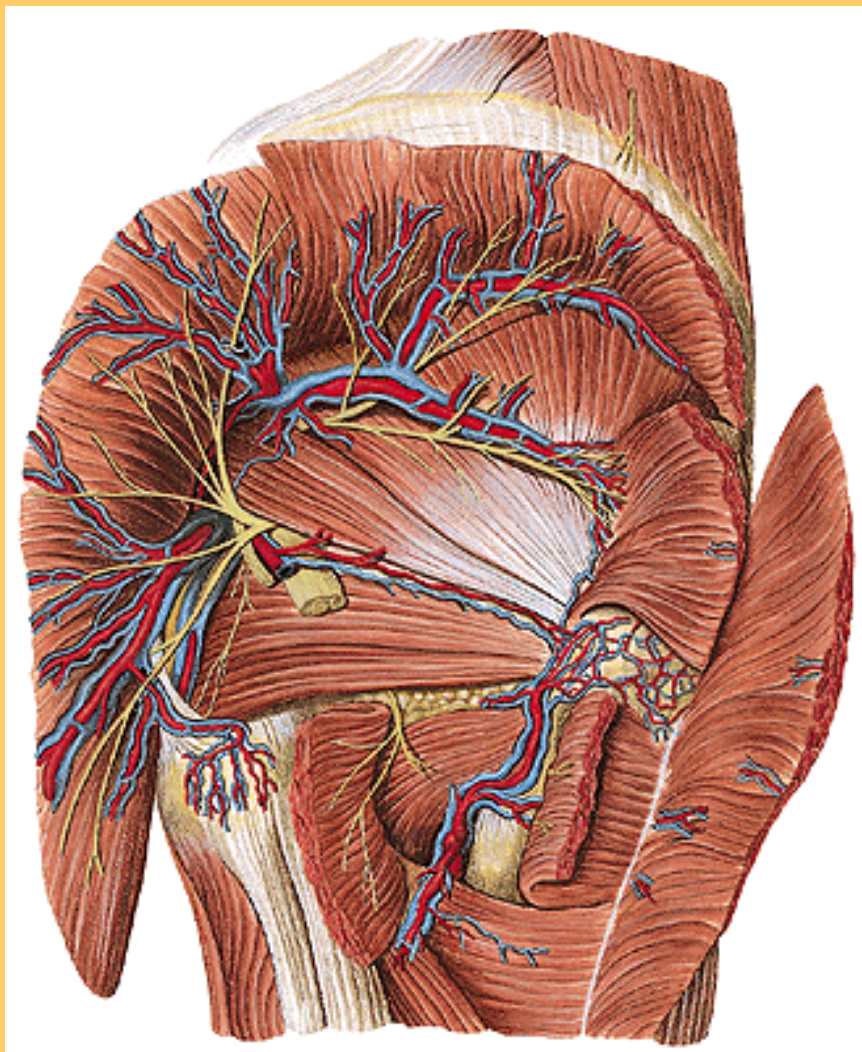
minim.

pirif.

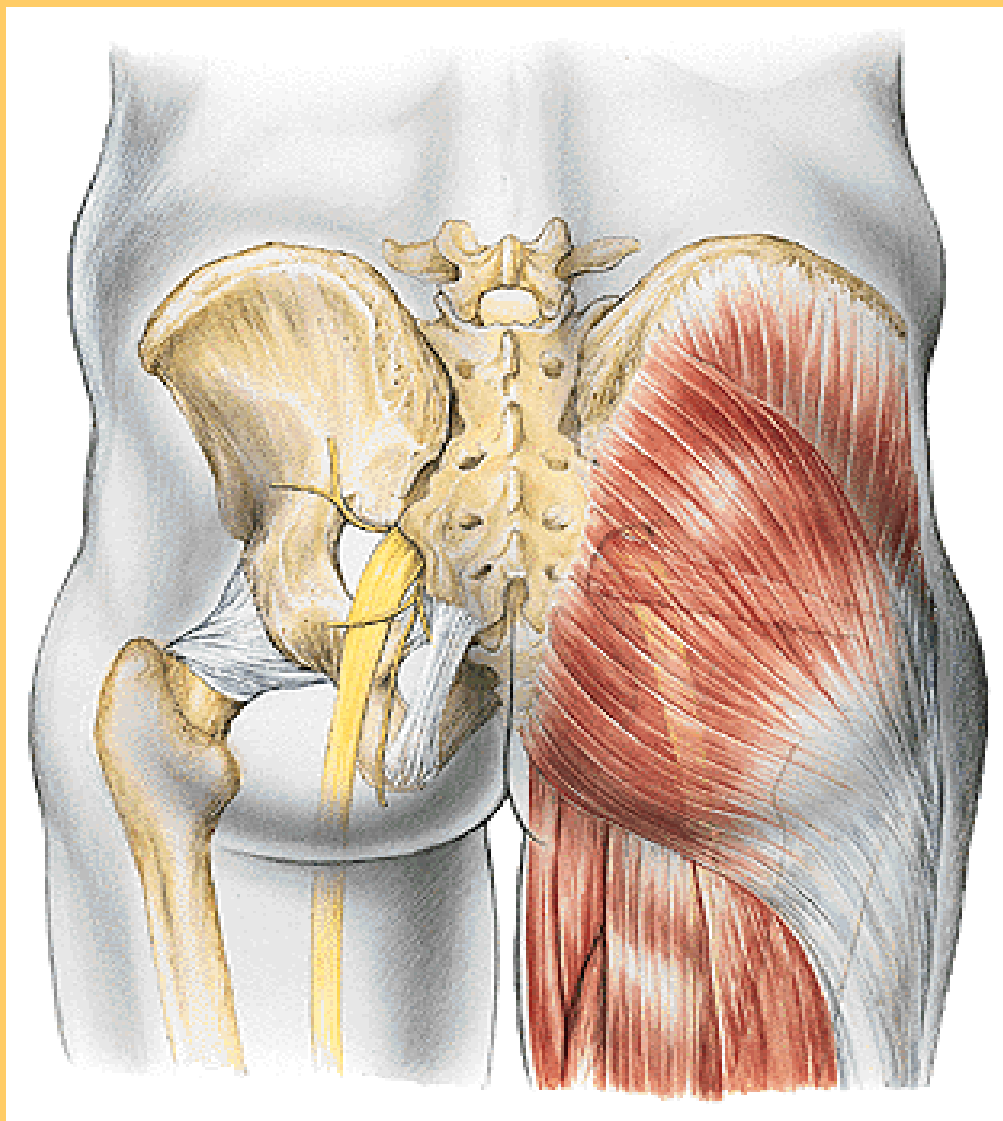
gemelli, obtur.

quadr.fem.

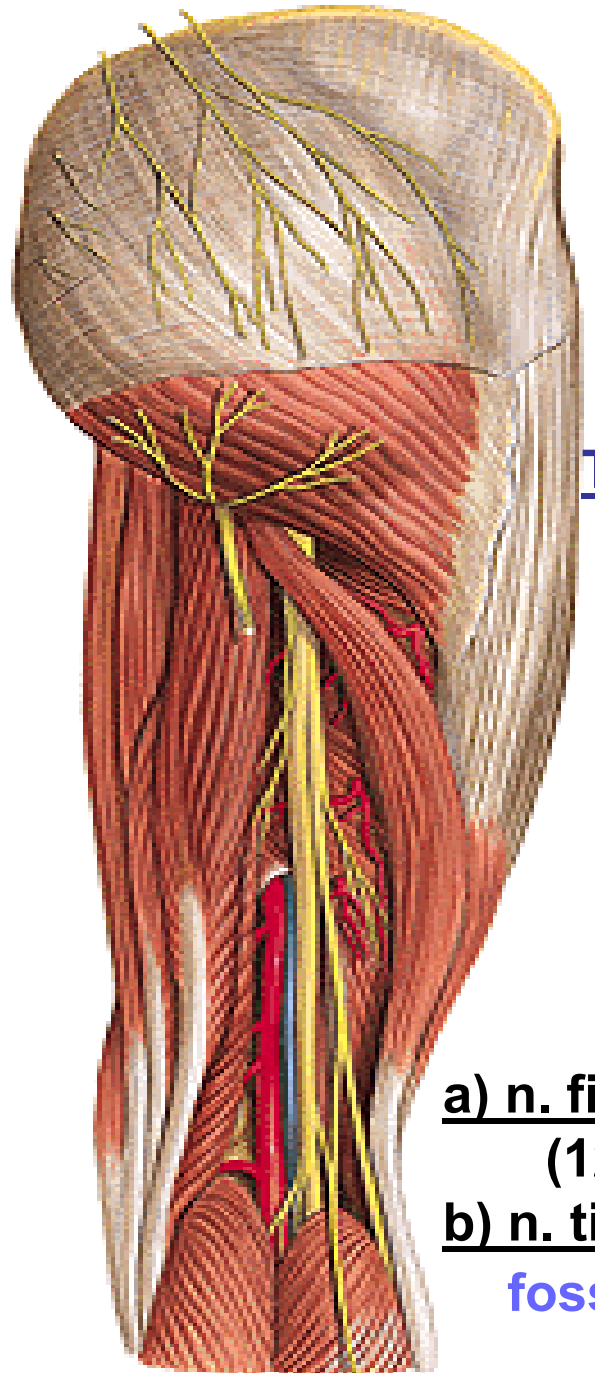
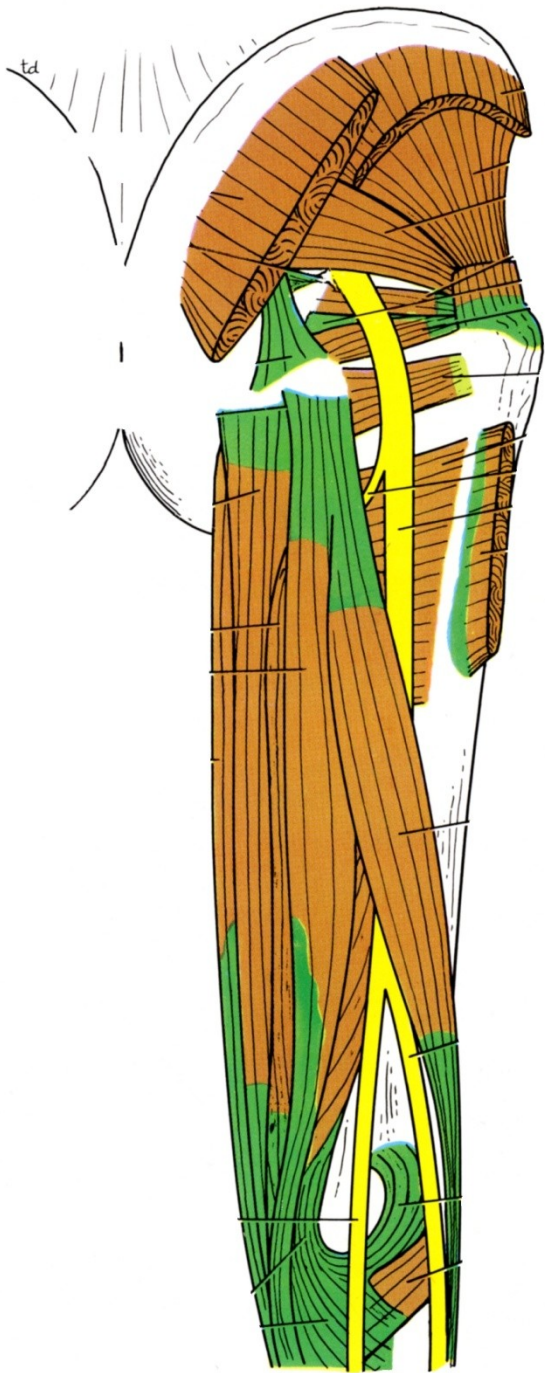
n.ischiadicus



1 – m. gluteus max., 2- medius 3- minimus, 13- m. pirif., 7- n. ischiad.  
 5 - vasa glutea. 4- m. gemelli, obtur., quadratus



**Projekce na povrch – i.m. aplikace**

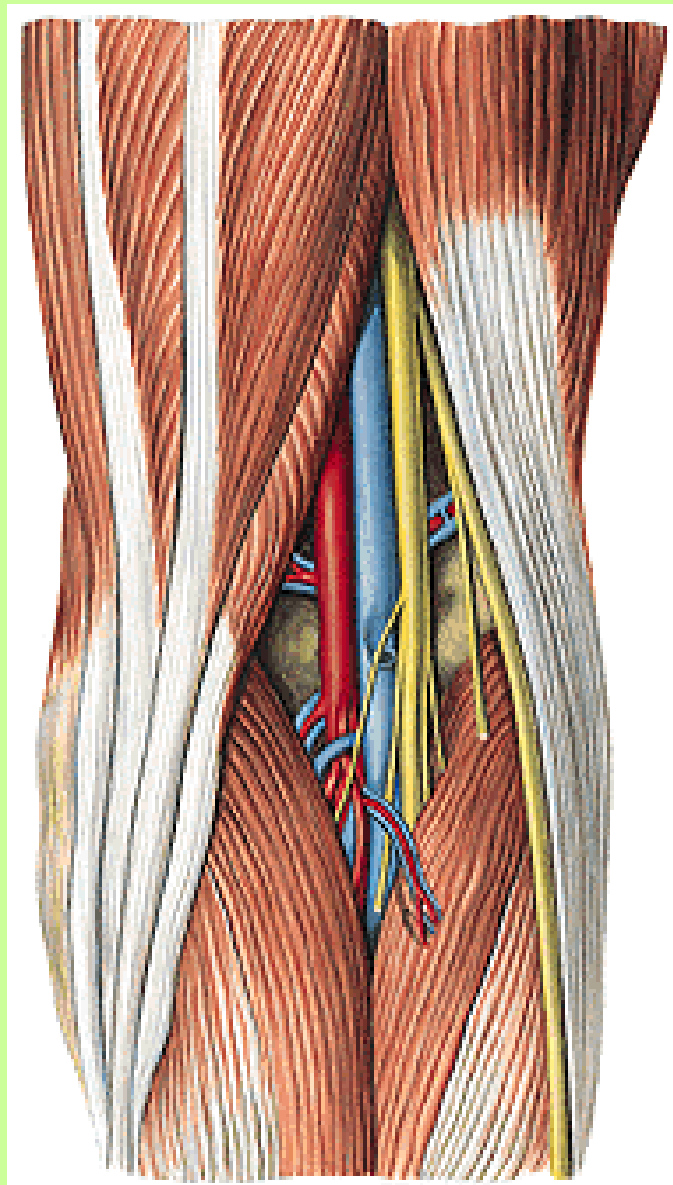


**TOPO:** mezi flexory  
**biceps**  
**semitend.**  
**semimembr.**

**a) n. fibularis**  
**(12% vysoké štěpení)**

**b) n. tibialis**  
**fossa poplitea**





semitendin.

PES ANSERINUS

gastrocnem.

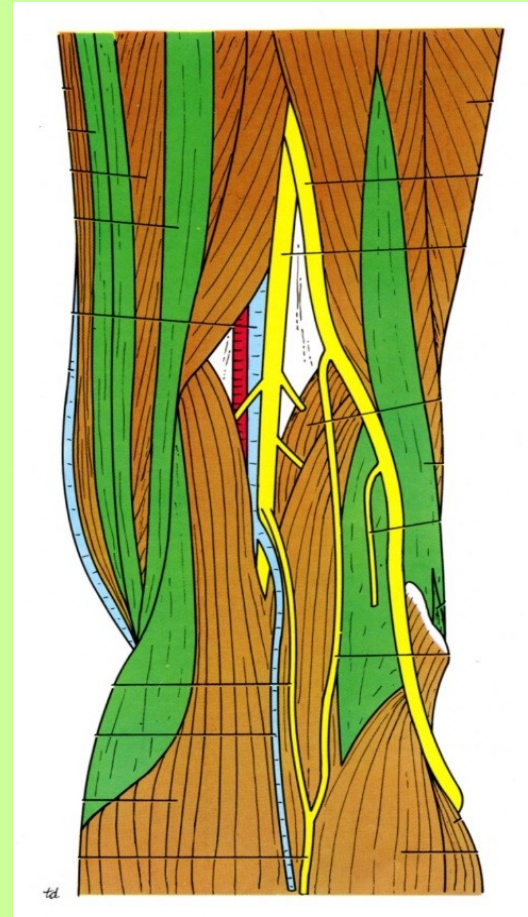
gracilis

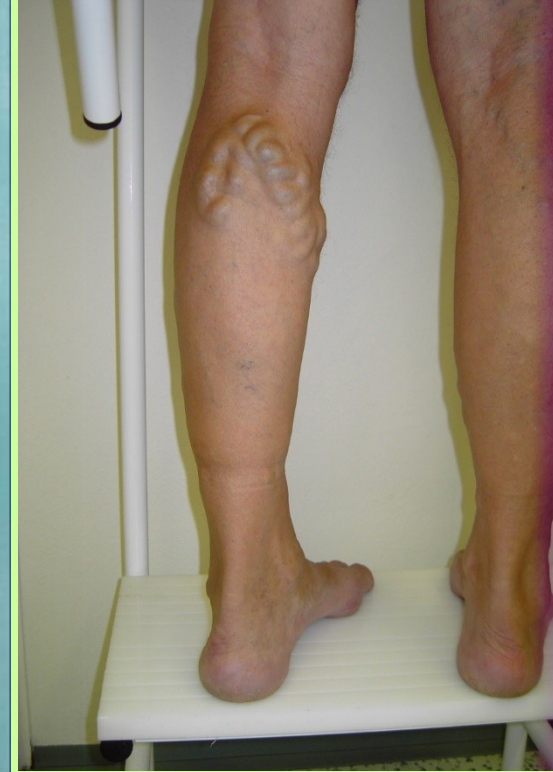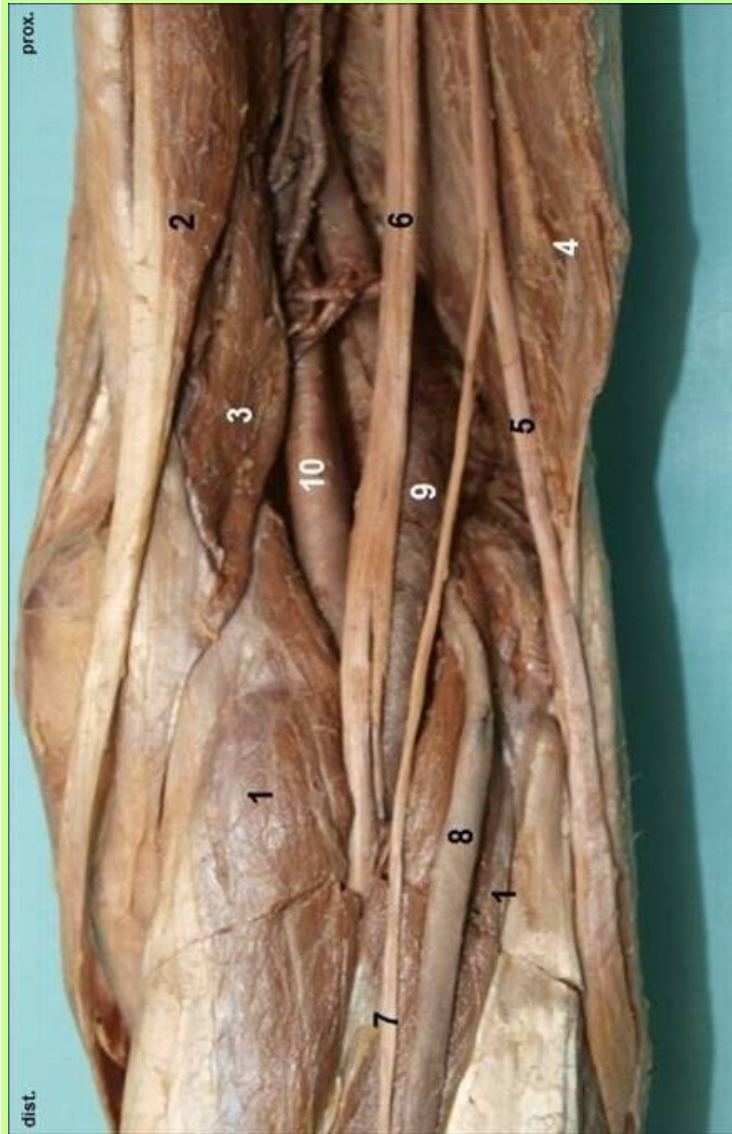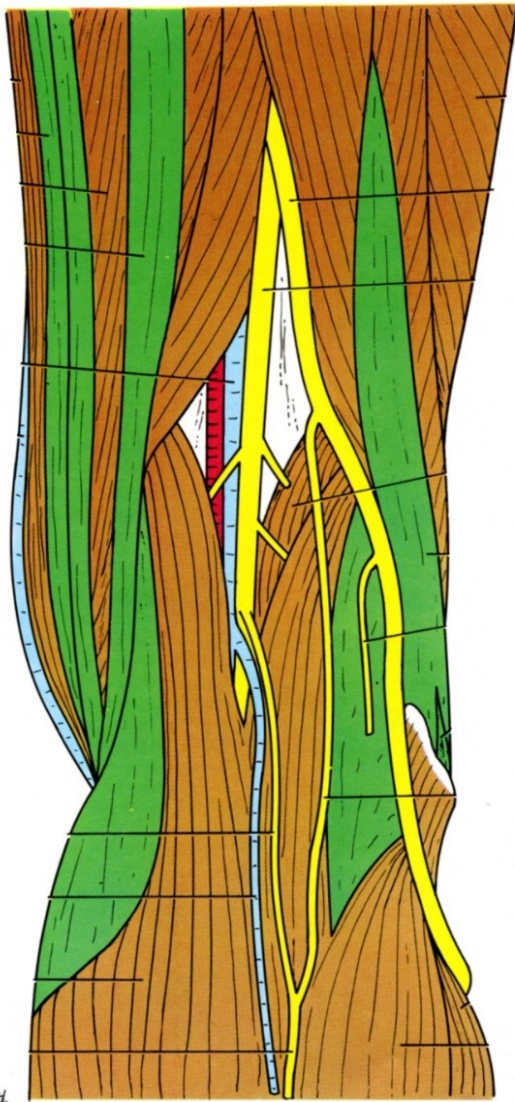
Fossa poplitea

biceps

n. fibul. comm.

n. tibialis



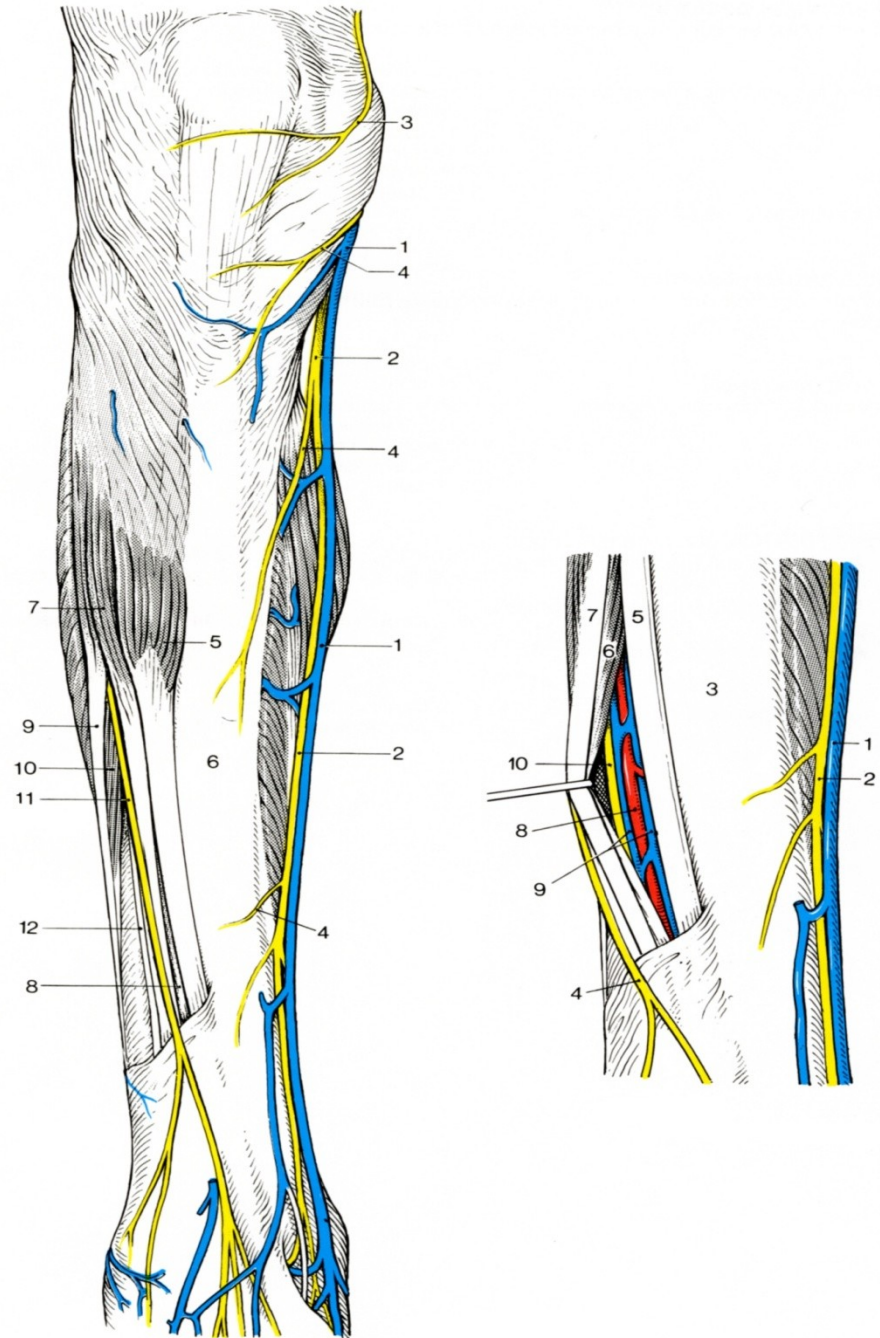


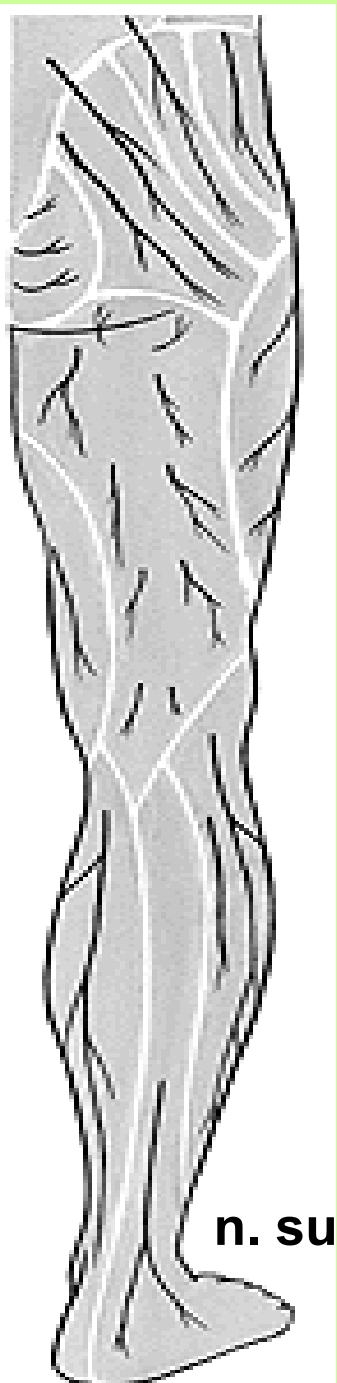
1 – gastrocnem. 2 – semitendin. 3 - semimembran. 5 – n.fibularis comm.  
 6 – n. tibialis 7 – n. suralis ( z obou cutanei ) 8 – v. saphena parva

## FOSSA POPLITEA

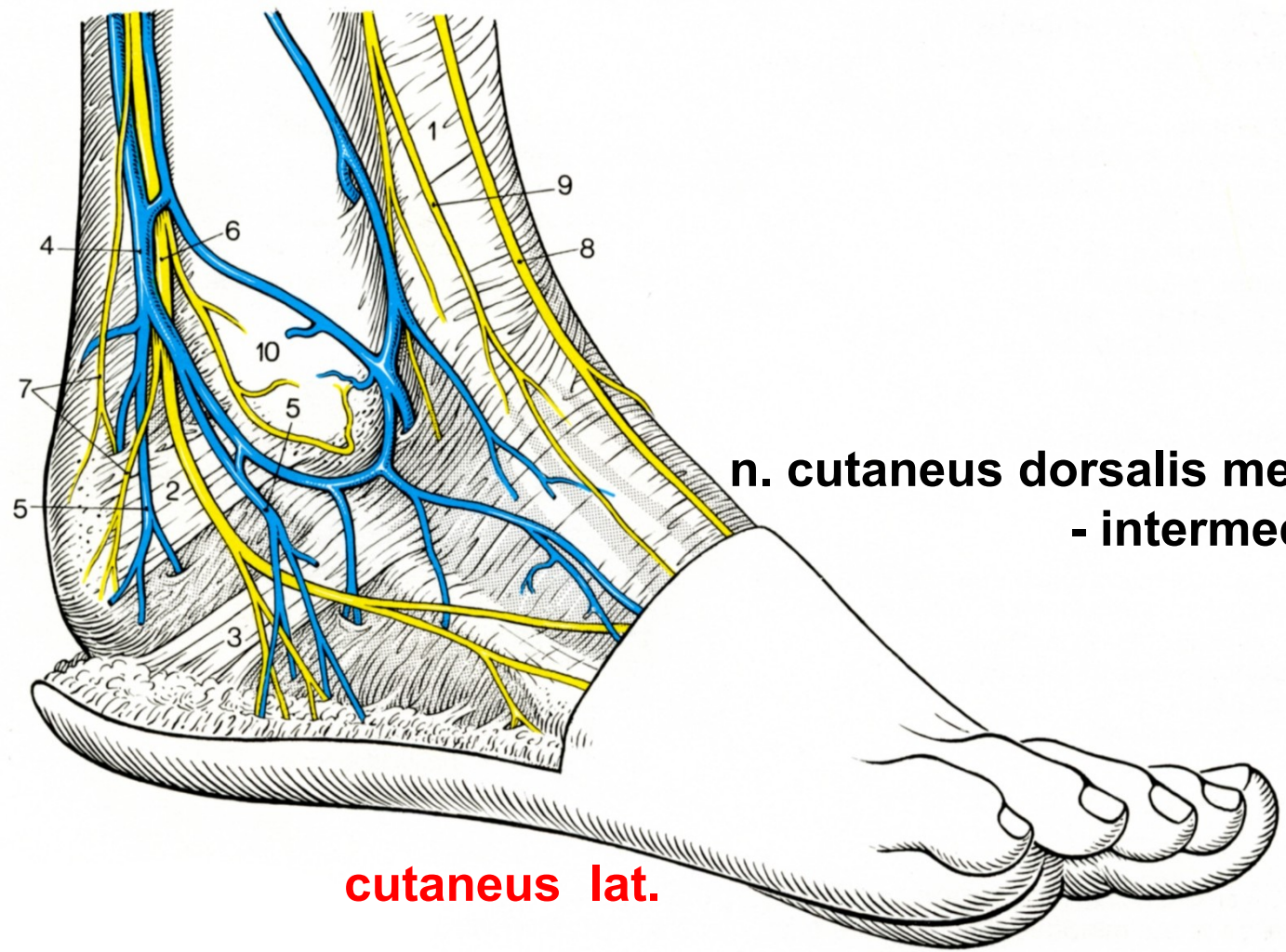
**n.peroneus superfic.**  
( mezi svaly peron.  
+ extenzor digit.)  
**svalové větve pro fibul. svaly**

**n. cutaneus dorsalis med.**  
**- intermed.**





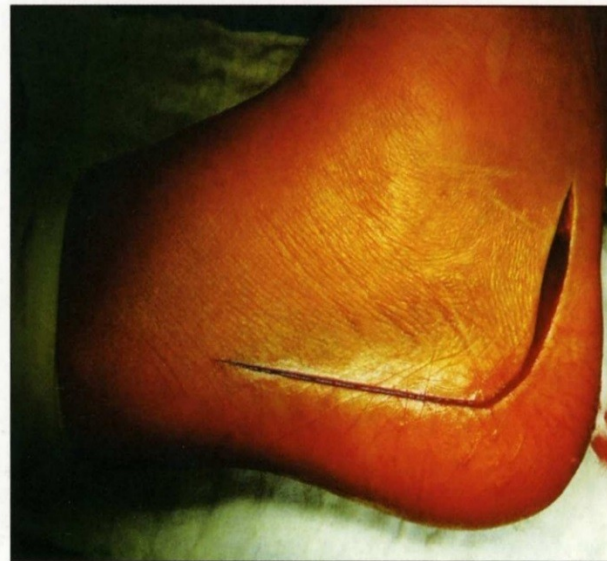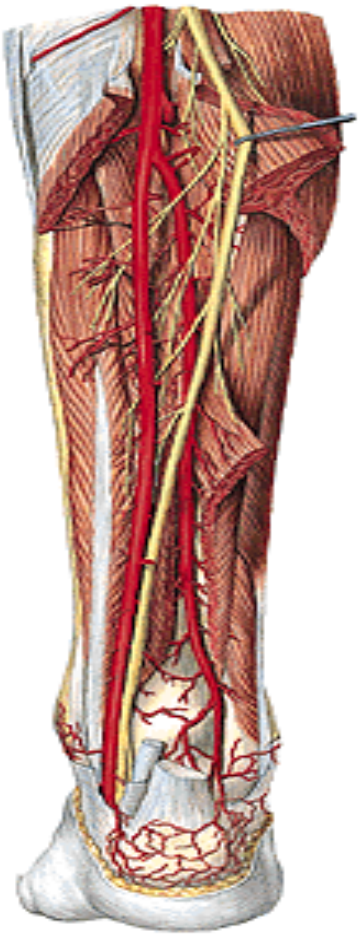
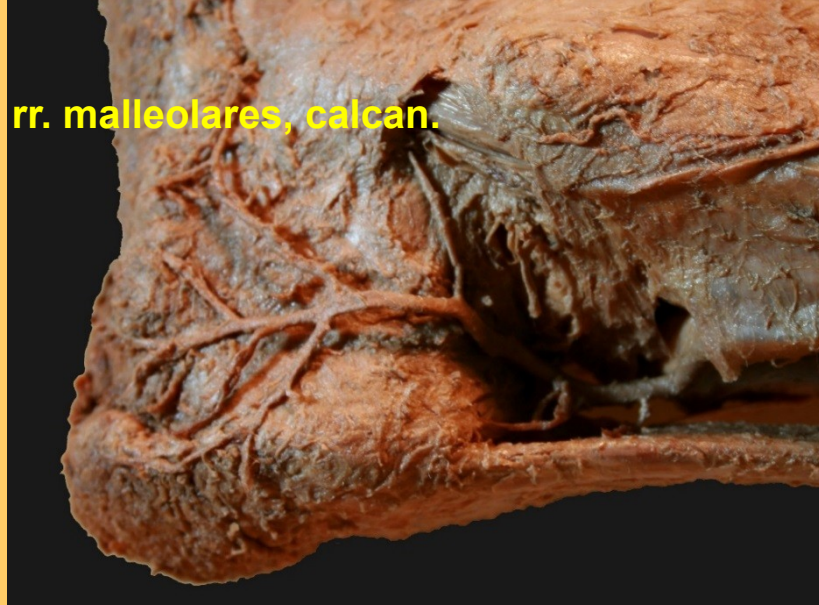**n. suralis**



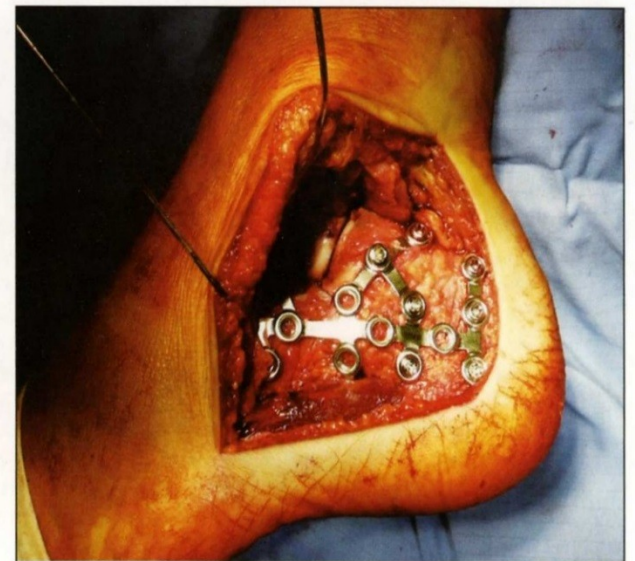
**n. cutaneus dorsalis med.  
- intermed.**

**cutaneus lat.**

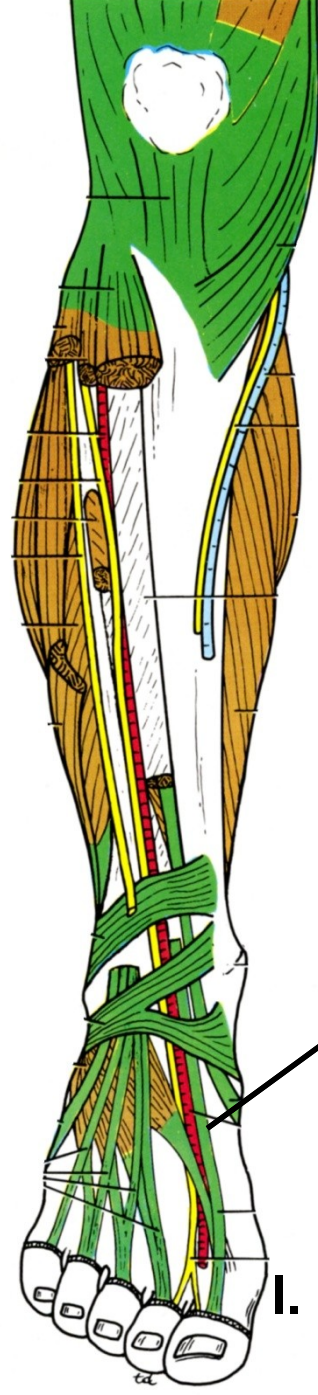
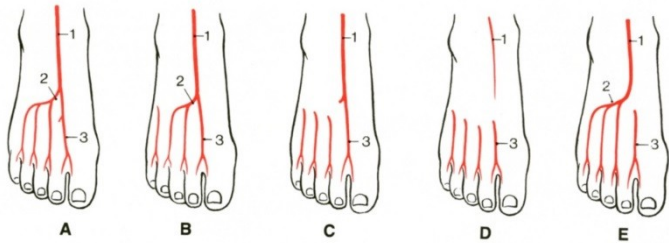
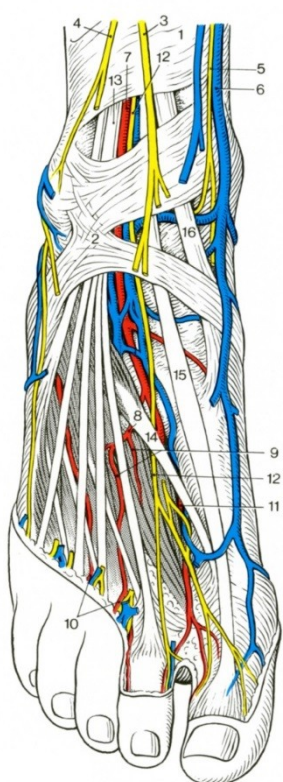
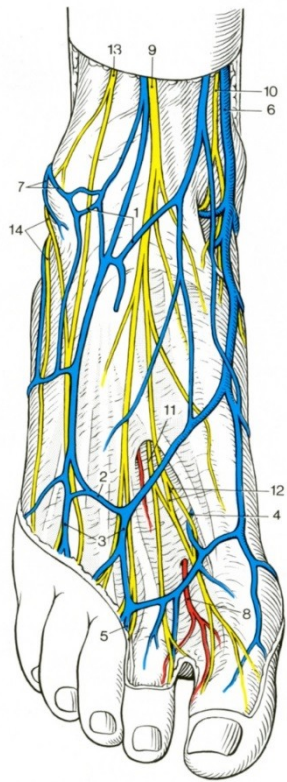
rr. malleolares, calcan.



Obr. 1a. Extenzivní laterální řez  
Fig. 1a. Extensive lateral incision



Obr. 1b. Stav po repozici a osteosyntéze patní dlahou LCP Synthes  
Fig. 1b. Situation following repositioning and completion of calcaneal osteosynthesis using the LCP Synthes plate



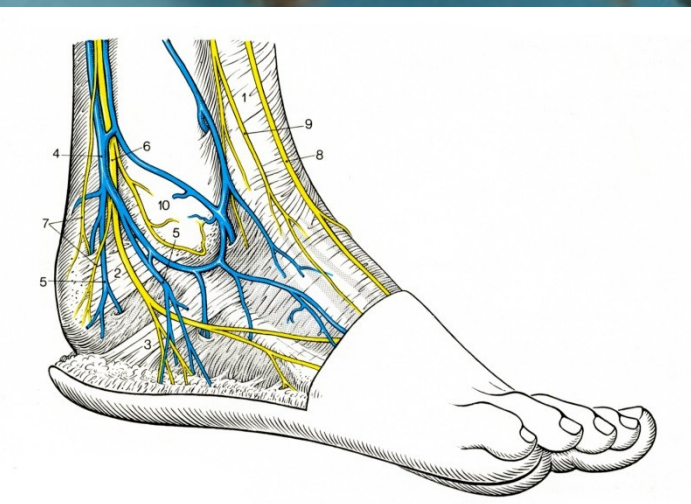
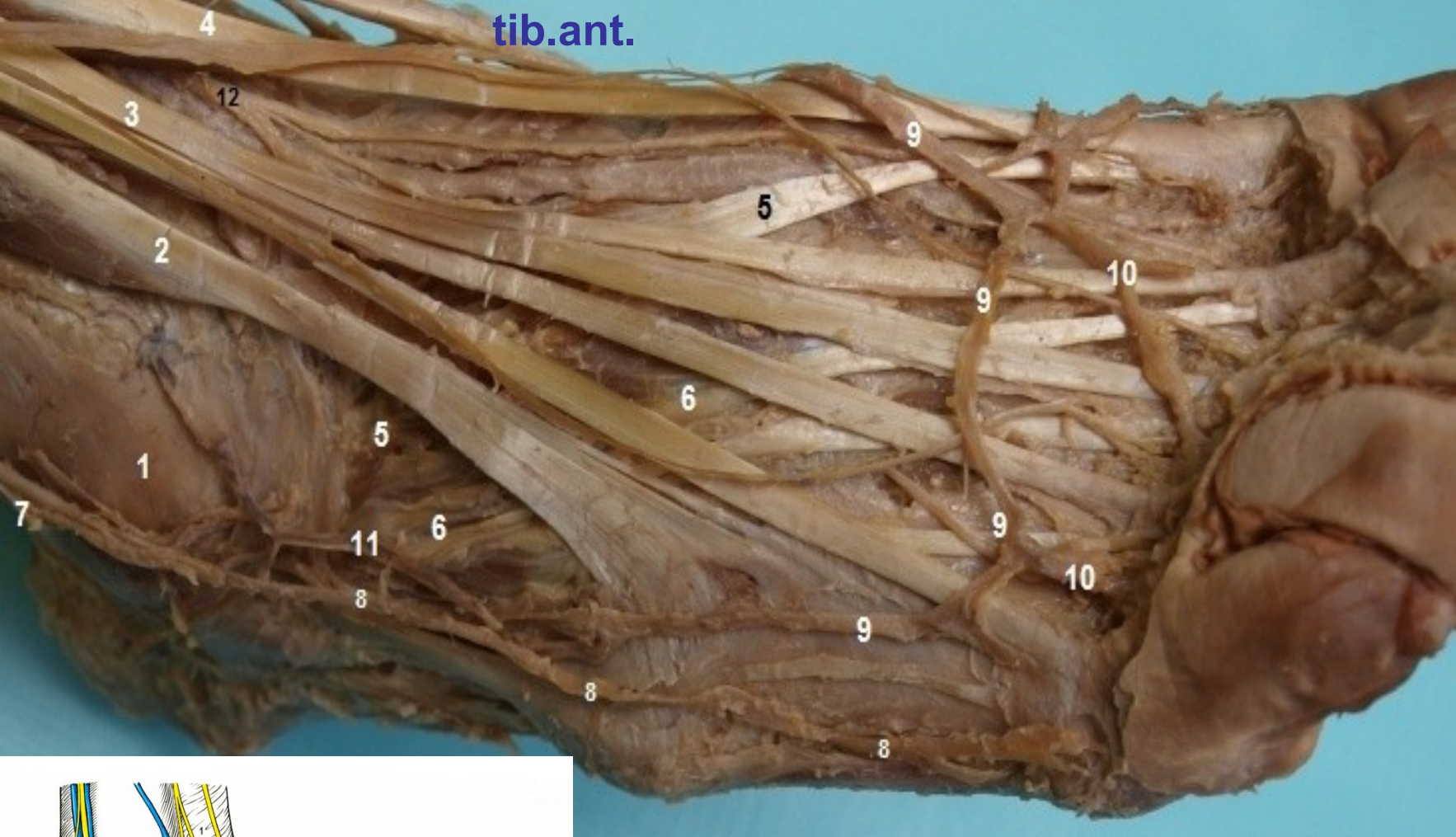
**TOPO:** křížení s arterií,  
 extensor hallucis  
 extenzor. prstů

I. meziprstní prostor

n. fibularis

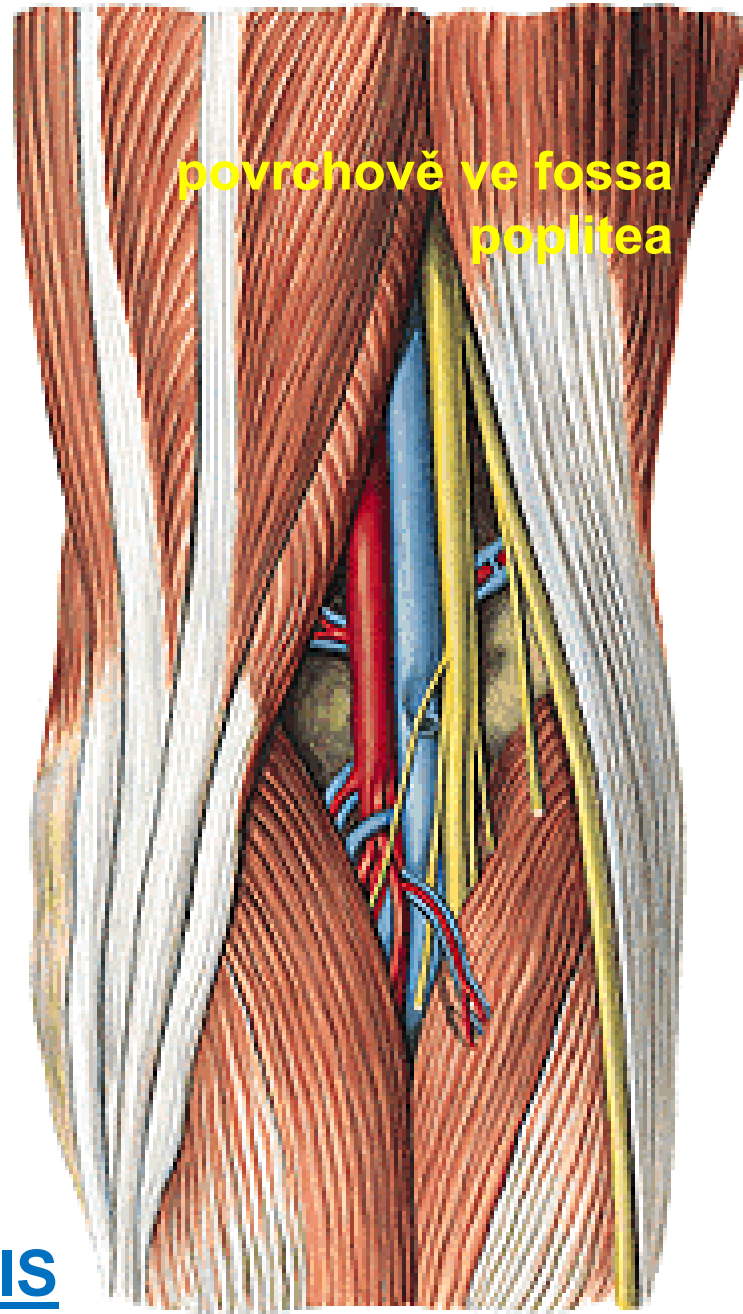
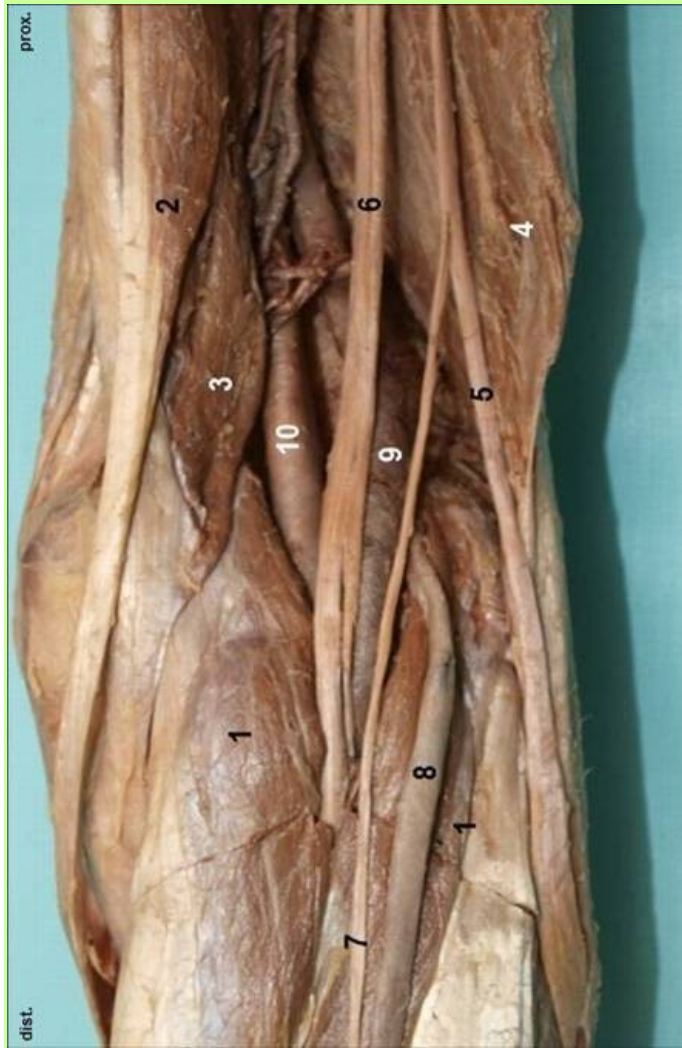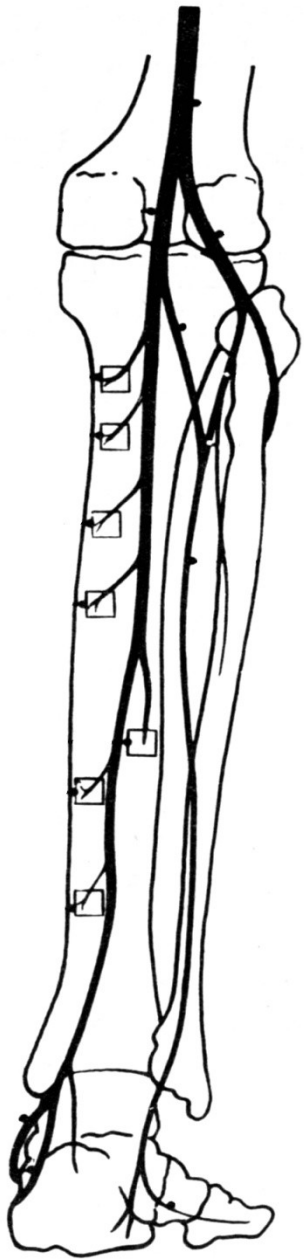
- profundus

tib.ant.



4 – m. extens. hallucis 3 – extens.- digit.

12 – n. peroneus prof. (superfic.)

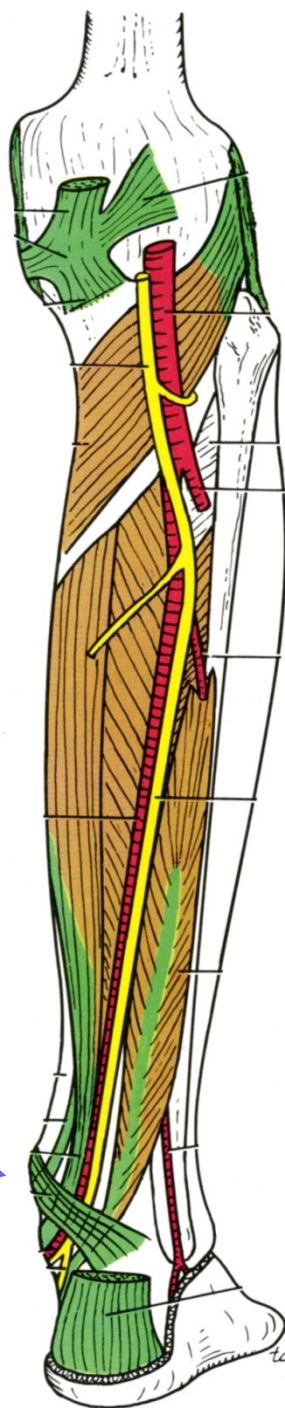


## N. TIBIALIS



- 

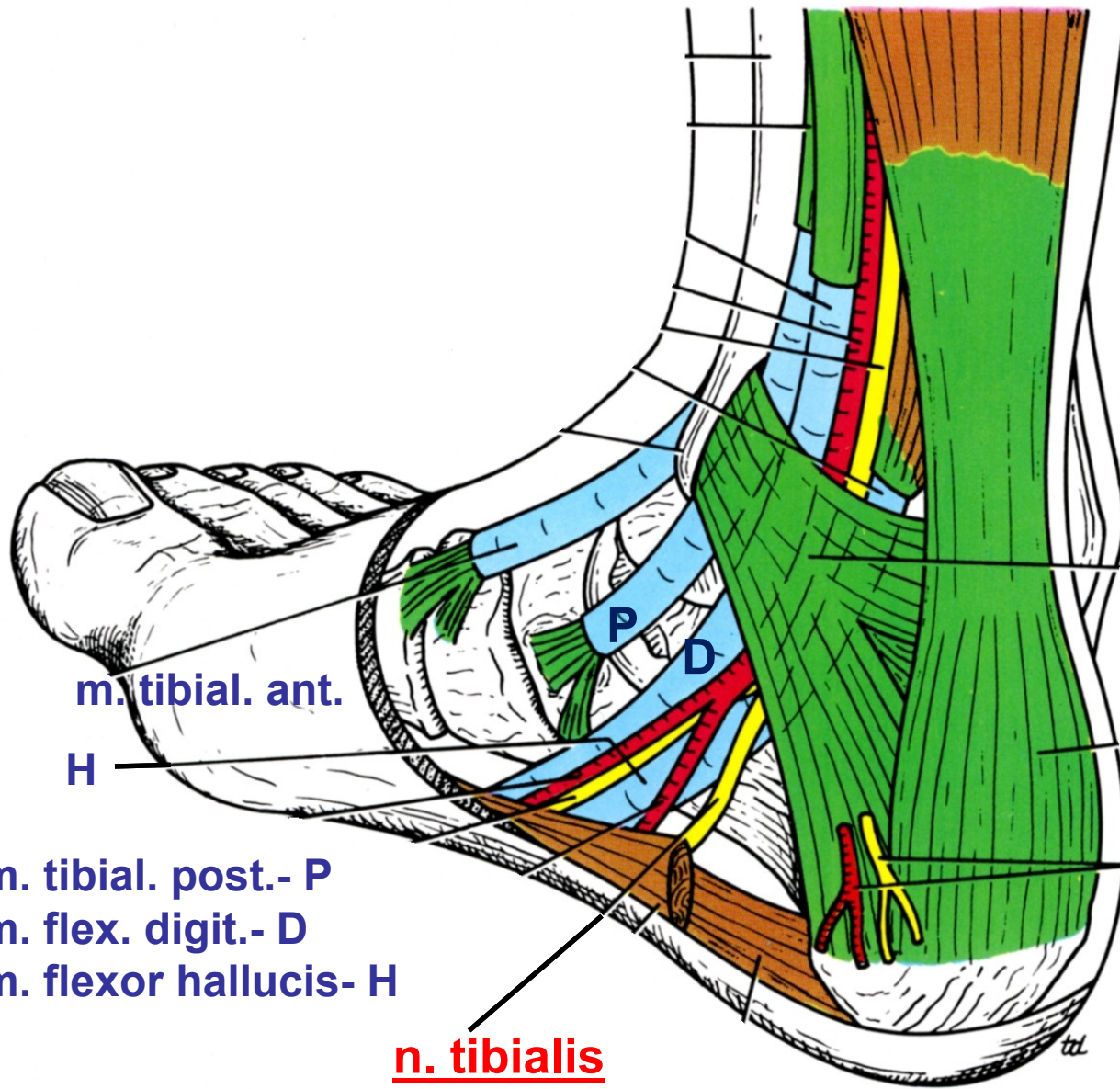
Další obr.



## N. TIBIALIS:

sleduje zadní tepnu  
mezi hlubokými svaly  
pod tricepsem

**Za mediální kotník**



retinaculum flex.

rr. calcanei

m. tibial. ant.

H

P

D

m. tibial. post.- P

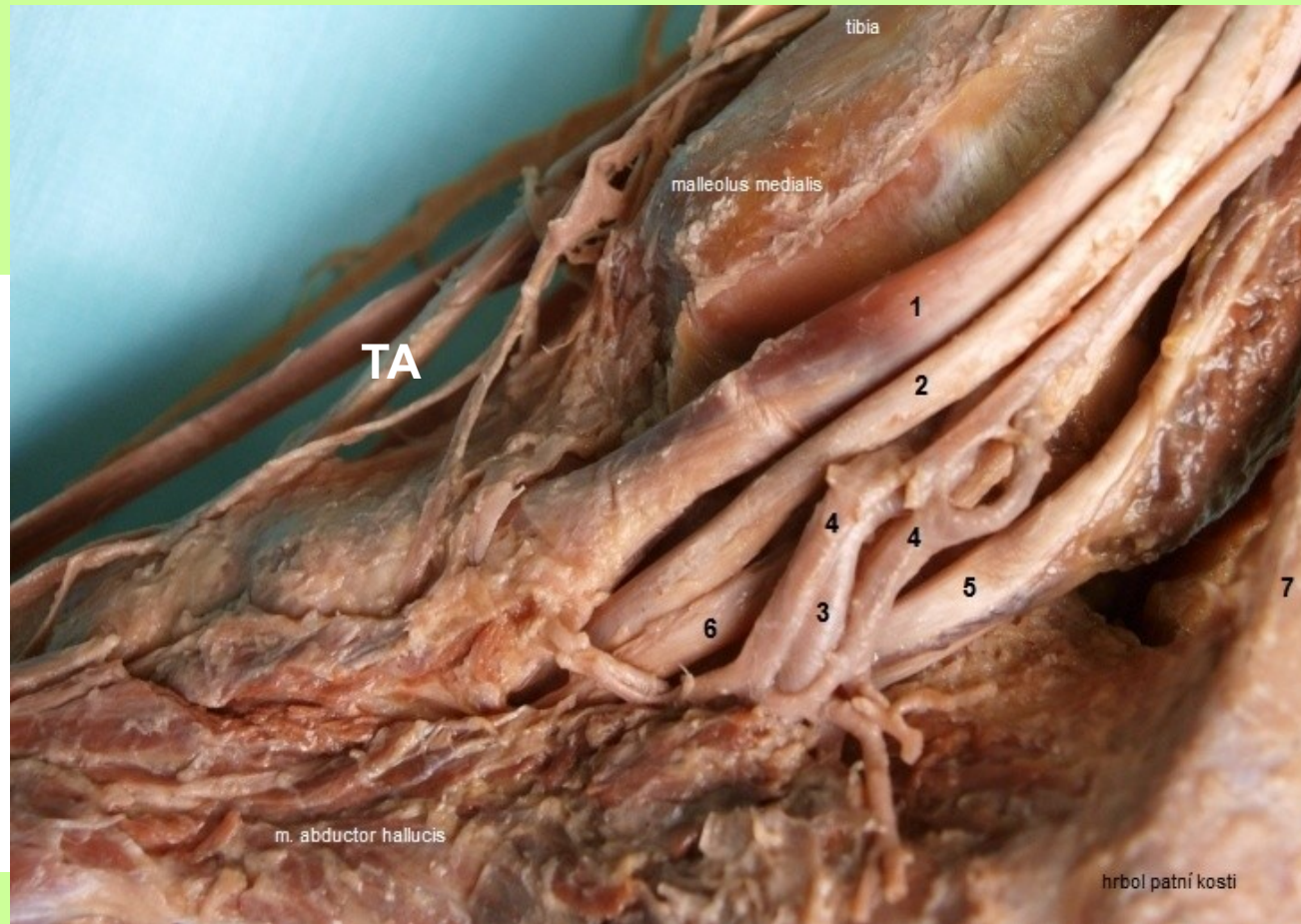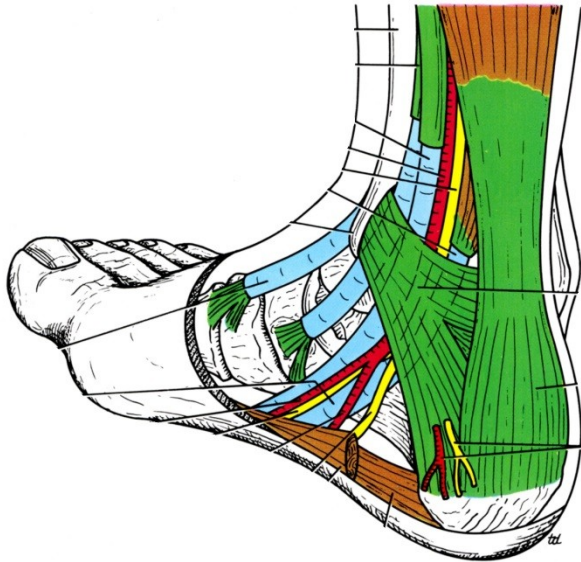
m. flex. digit.- D

m. flexor hallucis- H

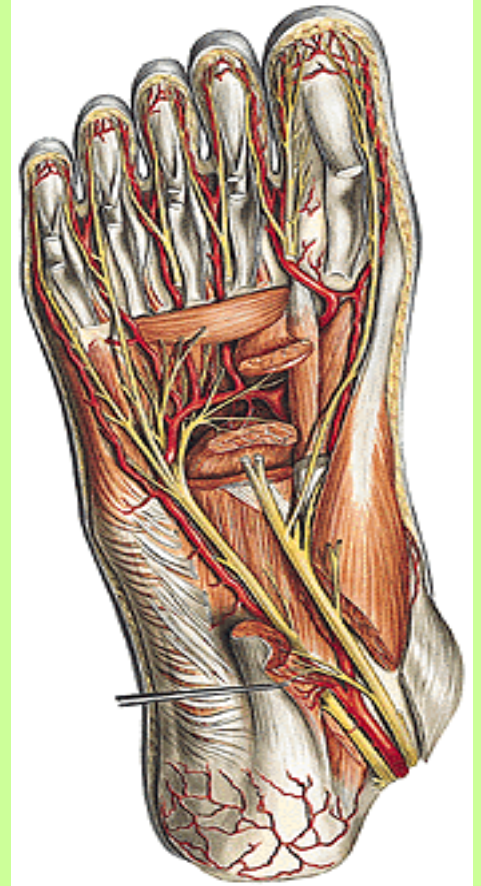
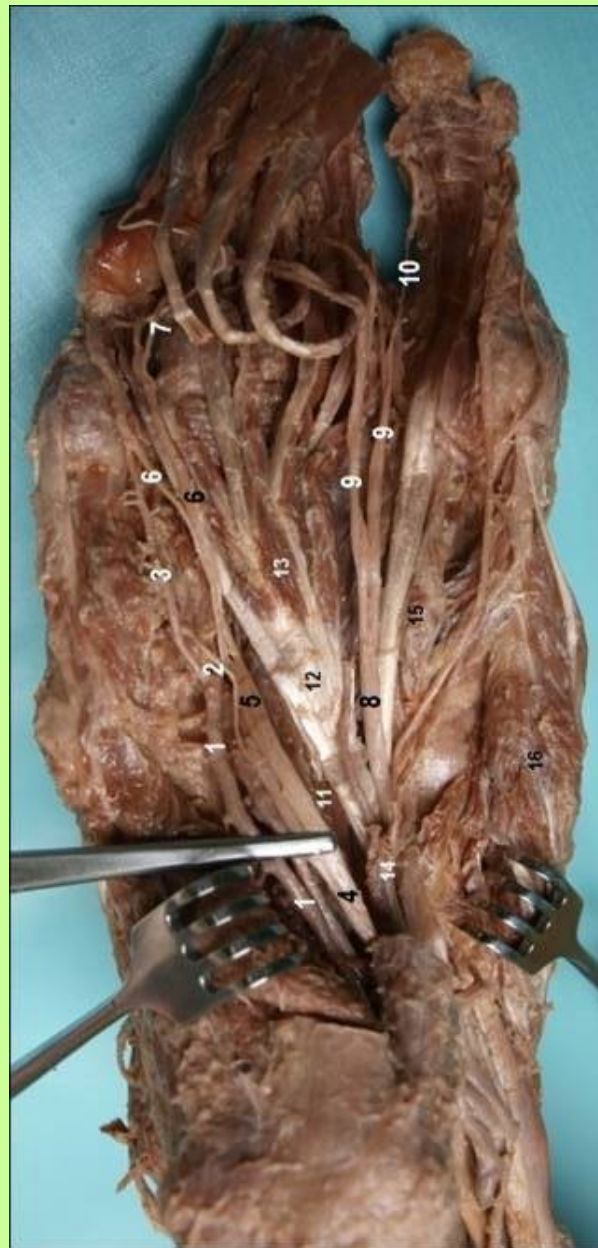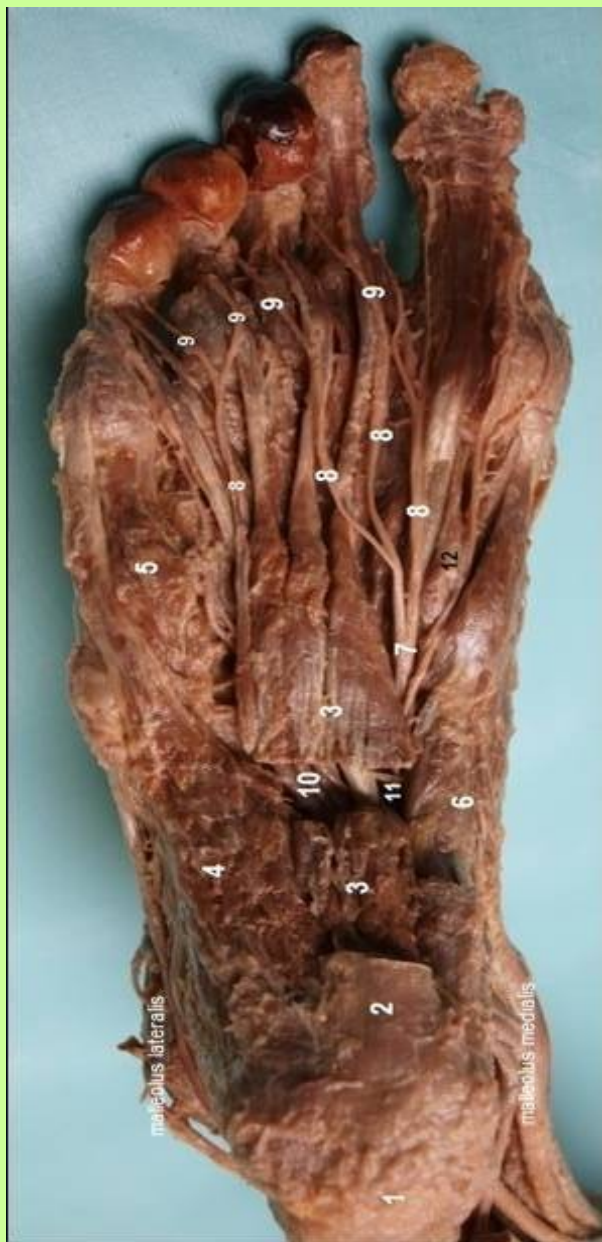
n. tibialis

Topo mediálního kotníku

*preparát* ⇒



1– m. tibialis post., 2 - m. flexor digitorum, 5- m.flexor hallucis, 6 – n. tibialis



**n. plantaris lateralis, med.**



**FINE**

**děkuji za pozornost**