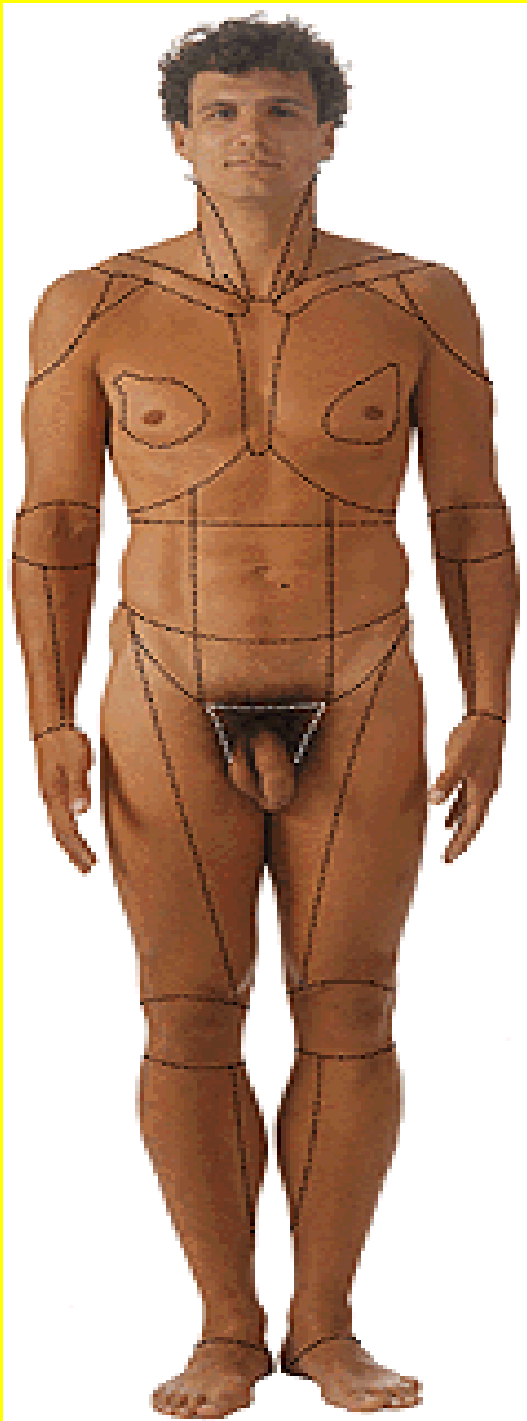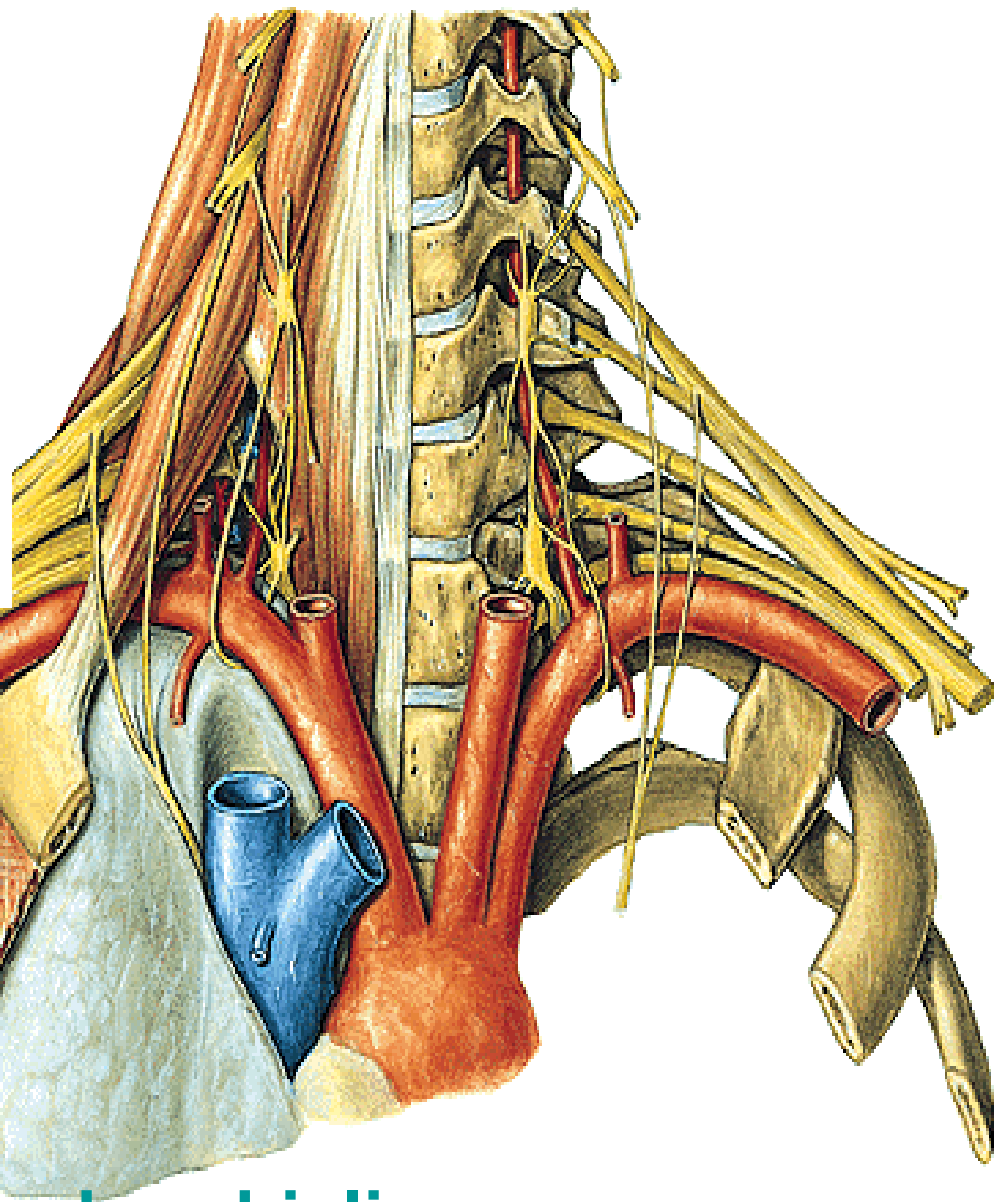
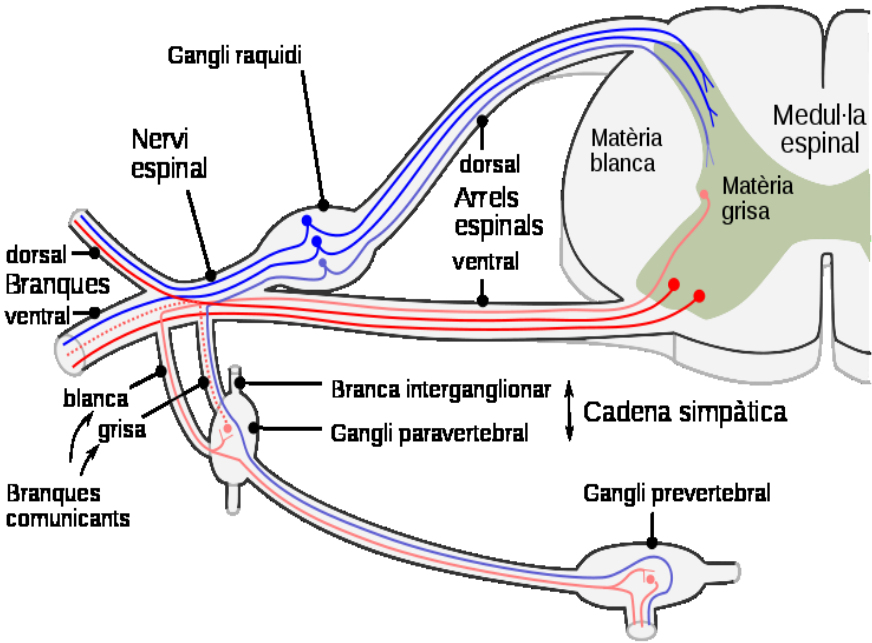


NERVY

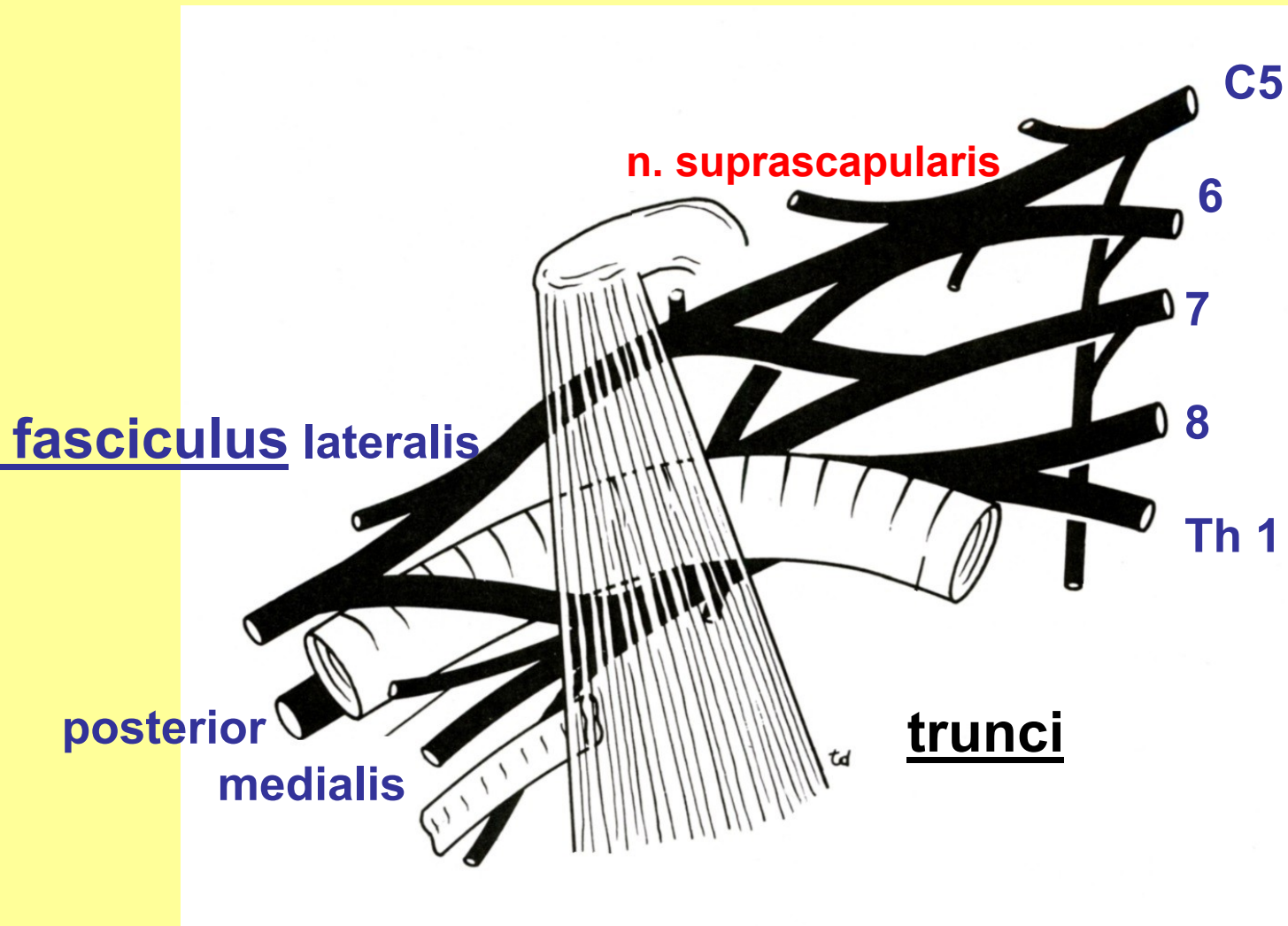
HORNÍ KONČETINY

Topografie
krajiny



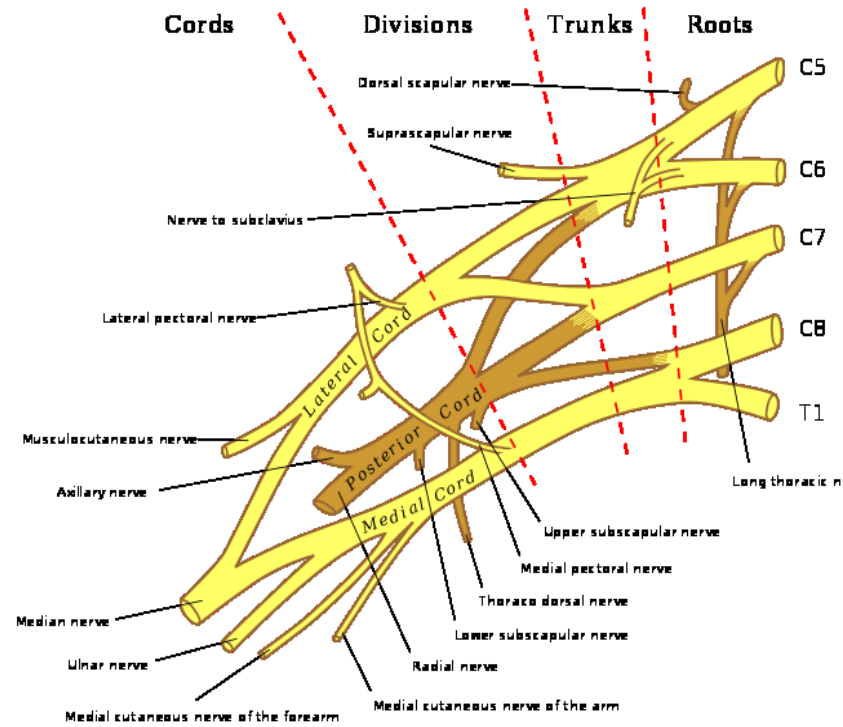
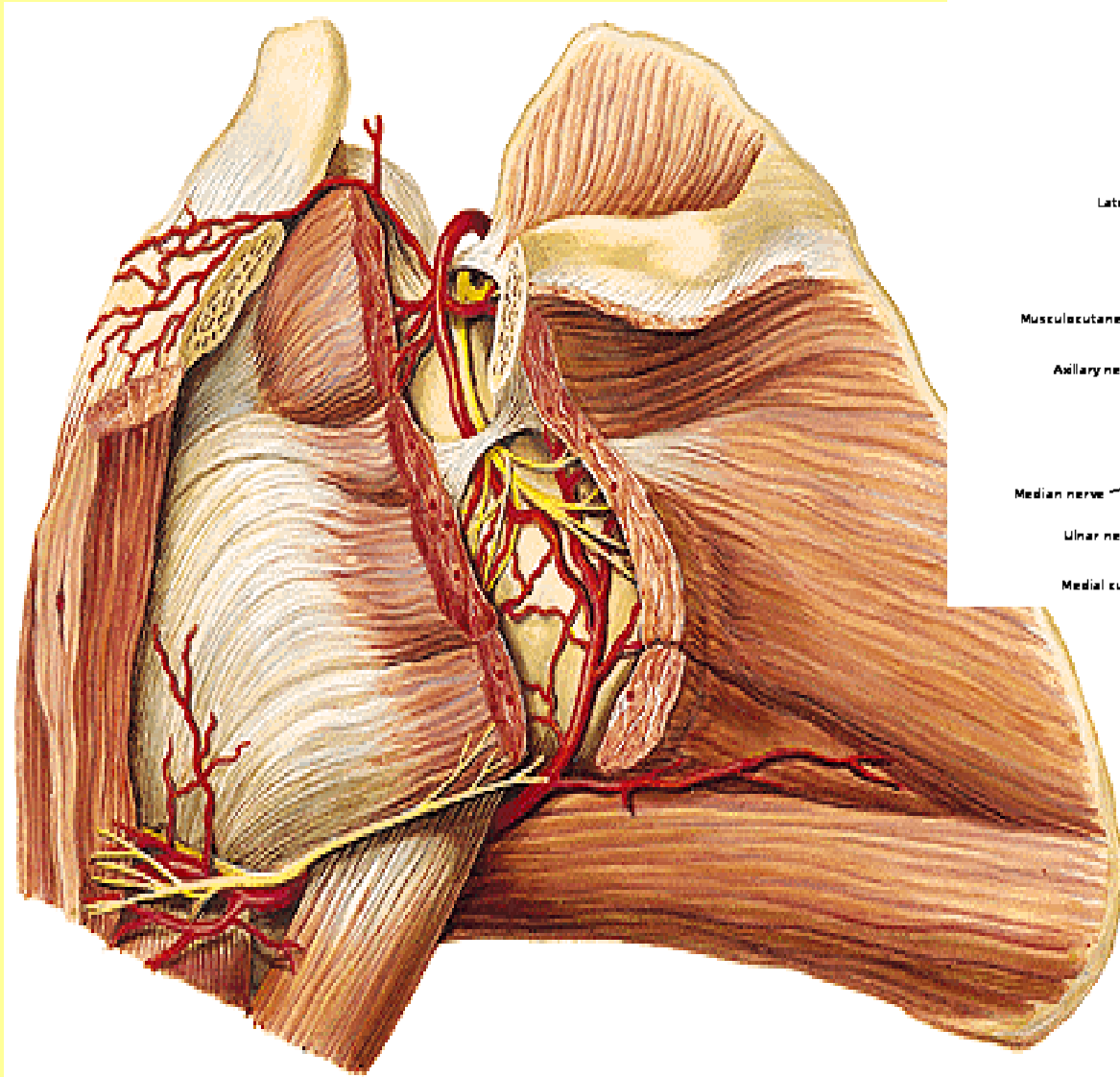
fissura scalenorum

Plexus brachialis - rr. ventrales



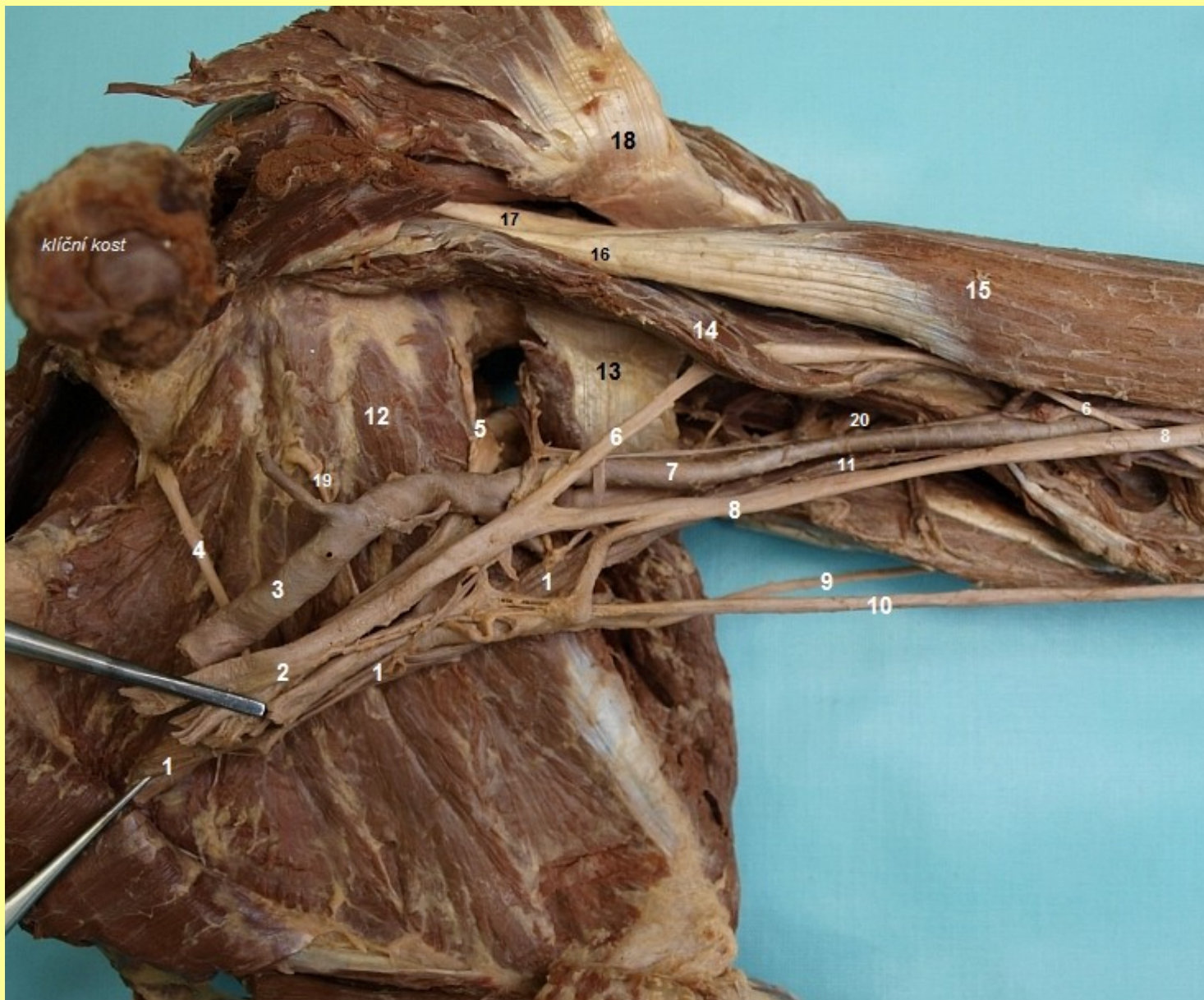kořeny

Plexus brachialis: a) pars supraclavicularis (n.suprascap.,pect....)
b) infraclavicularis



Pars supraclavicularis:

Nervus suprascapularis



**Nervus suprascapularis - ventrální
pohled**



Divisions

Trunks

Roots

Dorsal scapular nerve

Suprascapular nerve

C5

C6

C7

C8

T1

Lateral pectoral nerve

n.musculocutaneus

Musculocutaneous nerve

Axillary nerve

Lateral Cord

Posterior Cord

Medial Cord

Long thoracic nerve

Upper subscapular nerve

Medial pectoral nerve

Thoraco dorsal nerve

Lower subscapular nerve

n.medianus

Median nerve

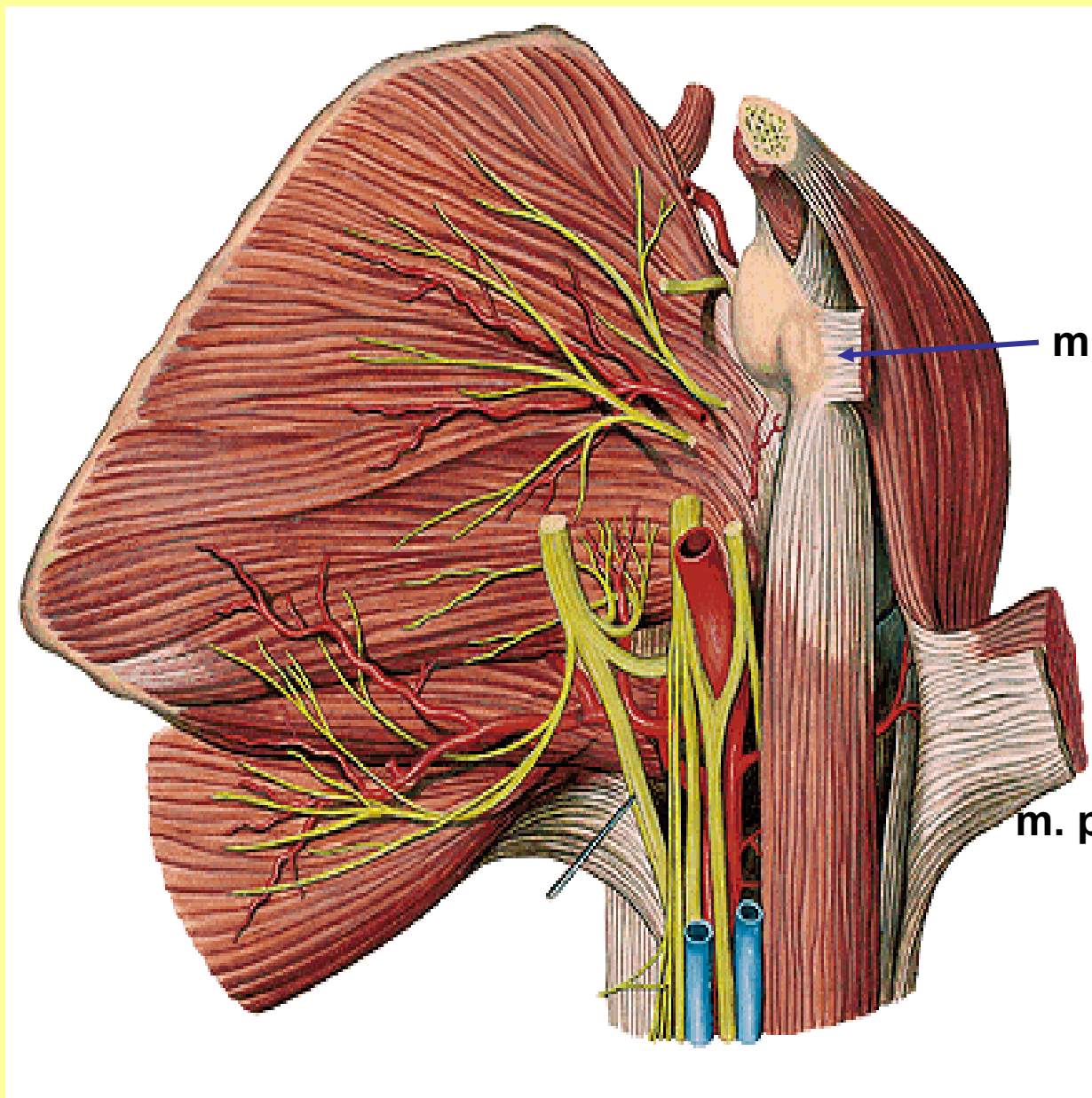
Ulnar nerve

Radial nerve

fasciculus lateralis

Medial cutaneous nerve of the forearm

Medial cutaneous nerve of the arm

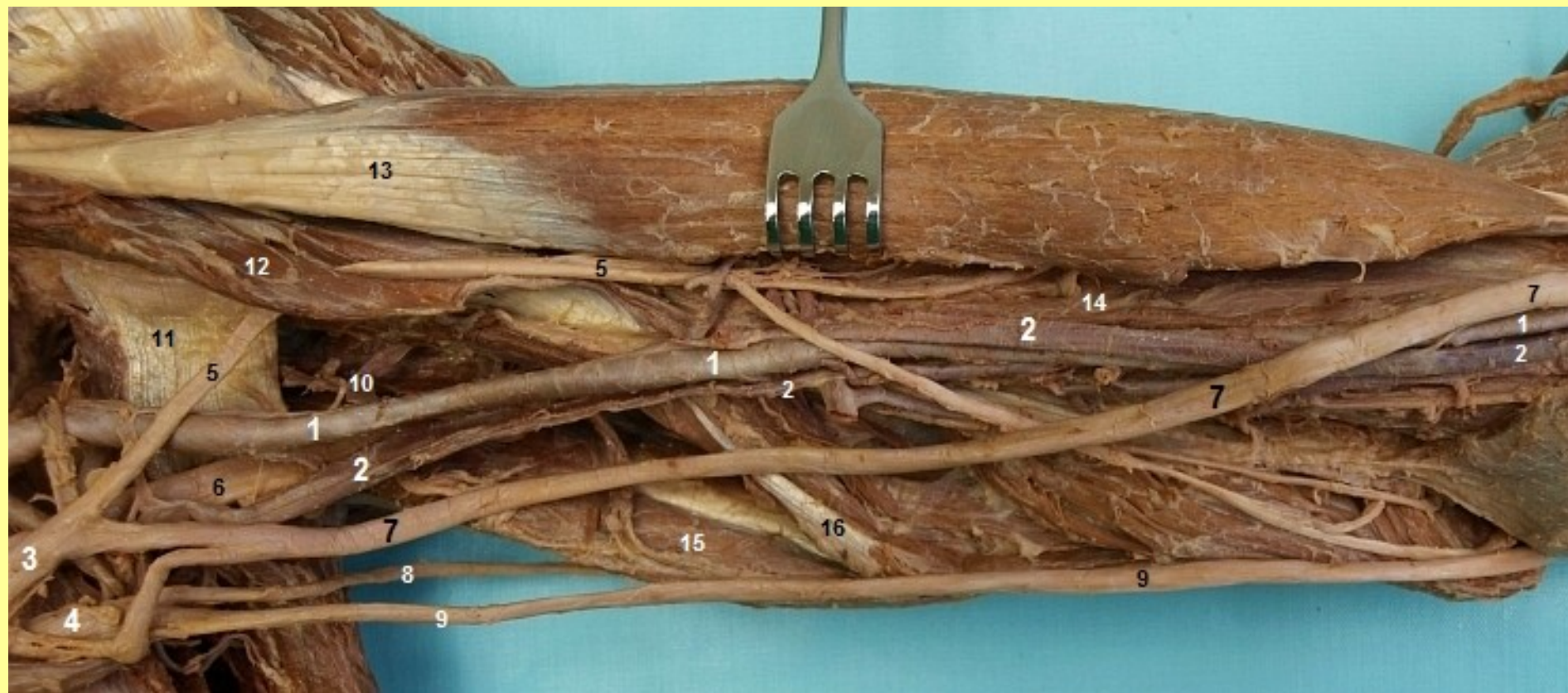


m. pect.min.

TOPO: sval, tepna

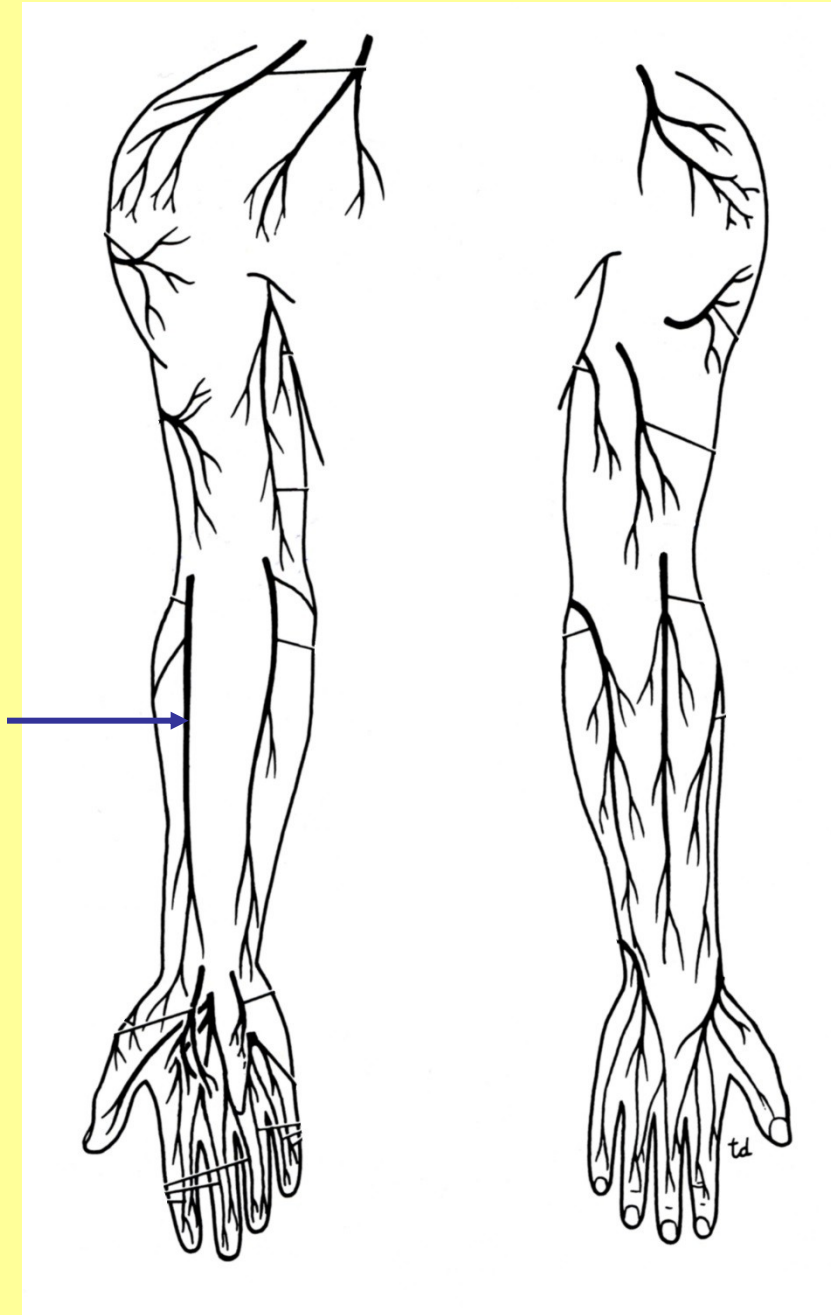
m. pect. maj.

Fasciculus lateralis - nervus musculocutaneus



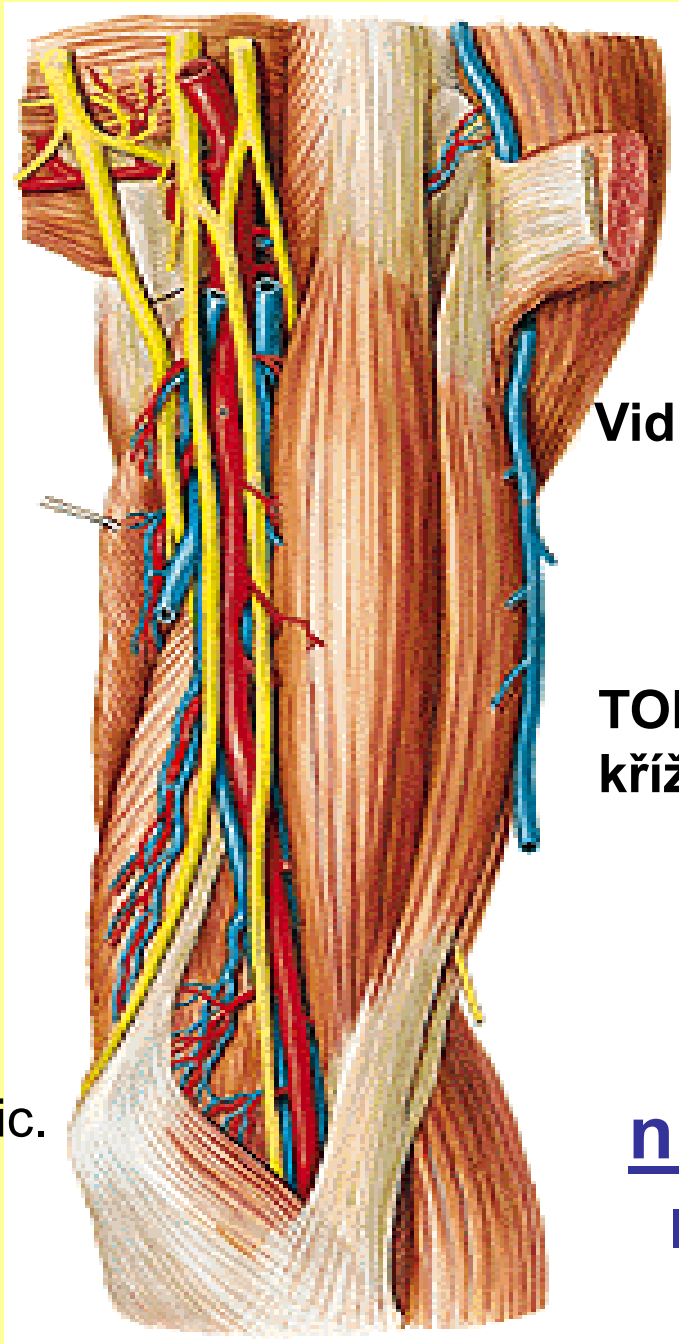
n. musculocutaneus

n. cutaneus
antebrachii lat.





med. epic.

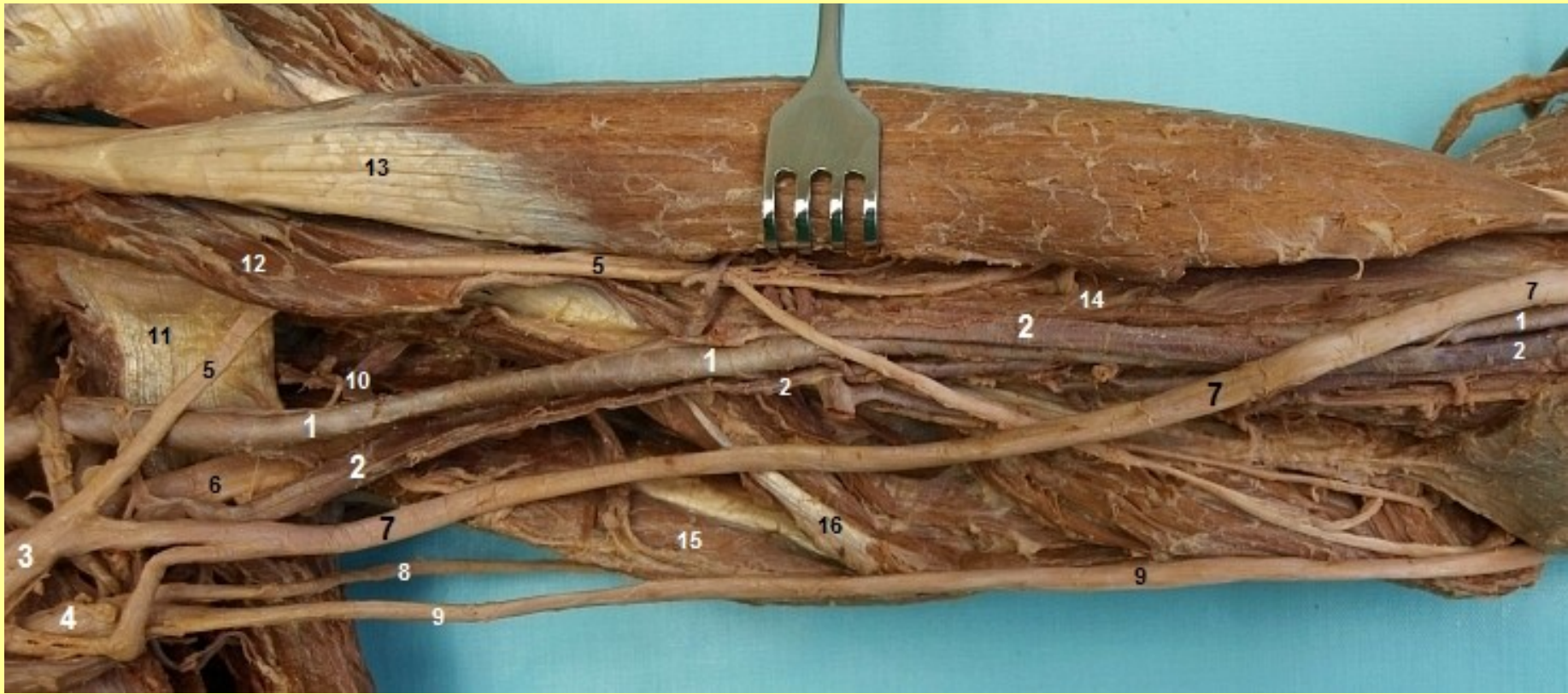


Vidlice: radix lat., med.

TOPO:
křížení, mezi flexory

n. medianus

levá strana



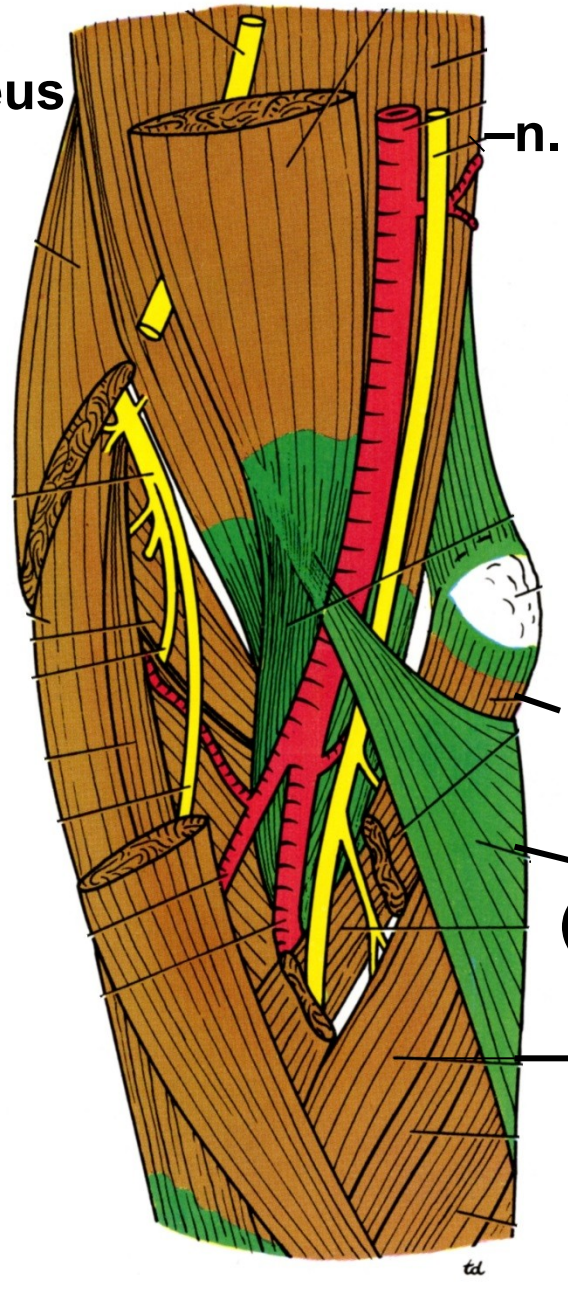
n. medianus, n. musculocutaneus

n. musculocutaneus

n. radialis



N. Pirogov, + 1881



n. medianus

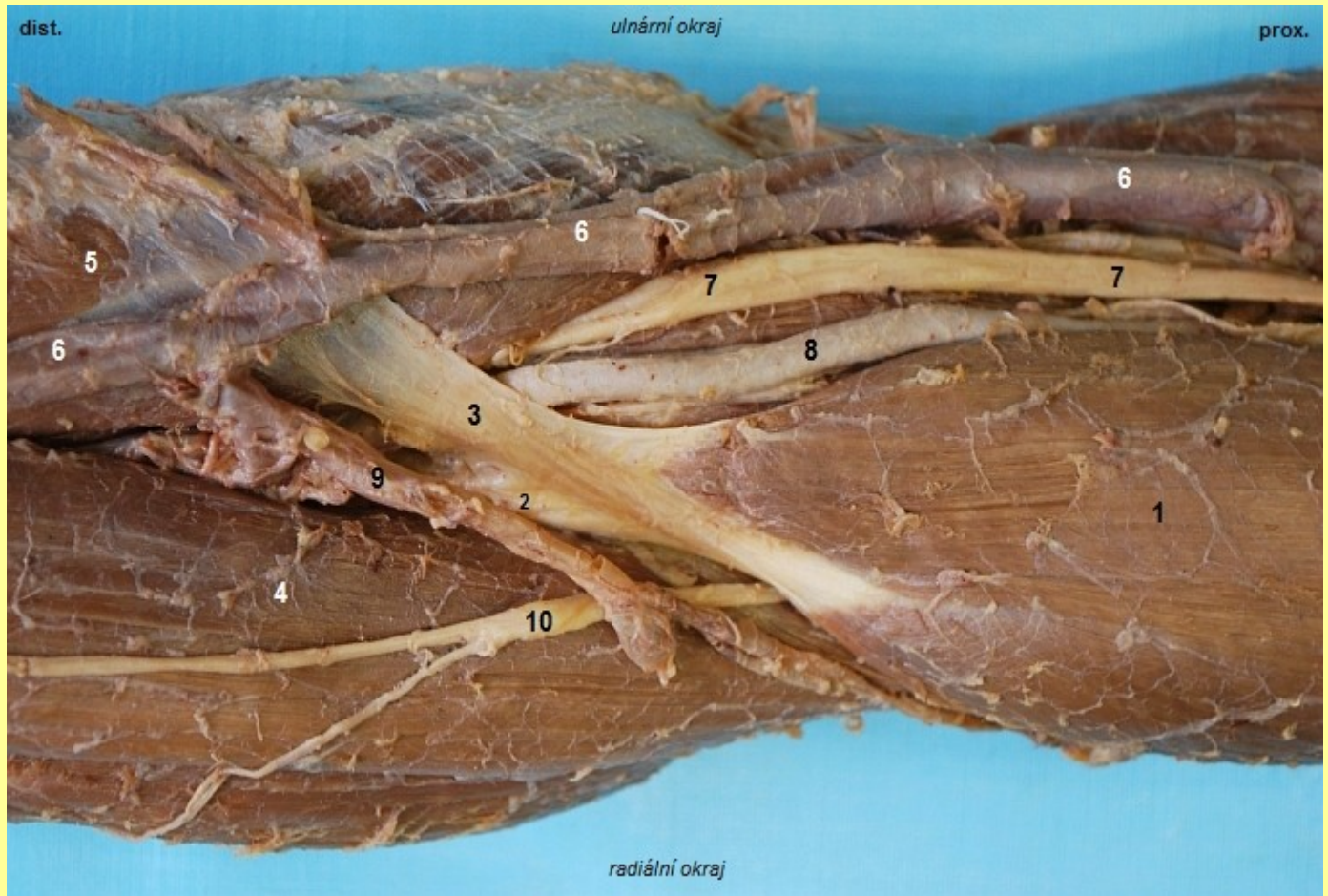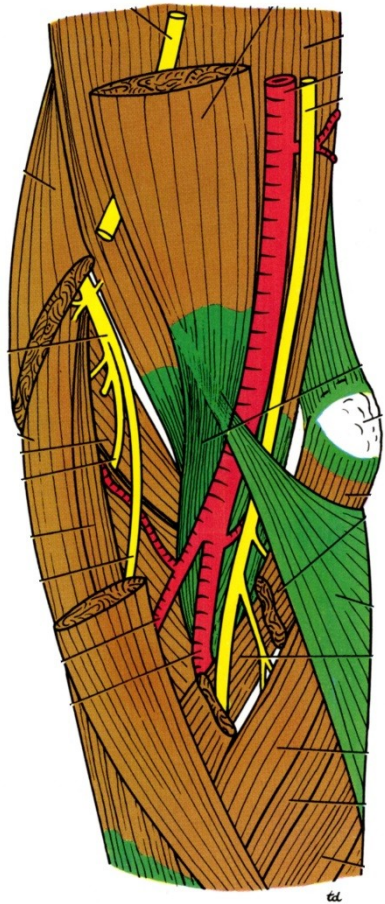
med. epic.

m. pronator teres

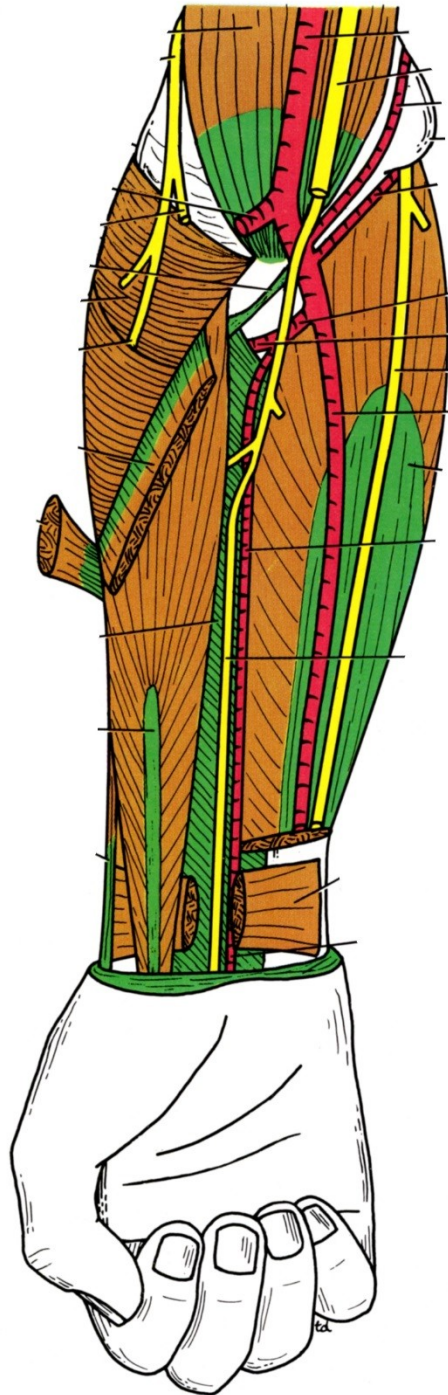
aponeurosis m. bicipitis
(lacertus fibrosus, Pirogovi)

flexory med. epikond.

n. medianus dx.



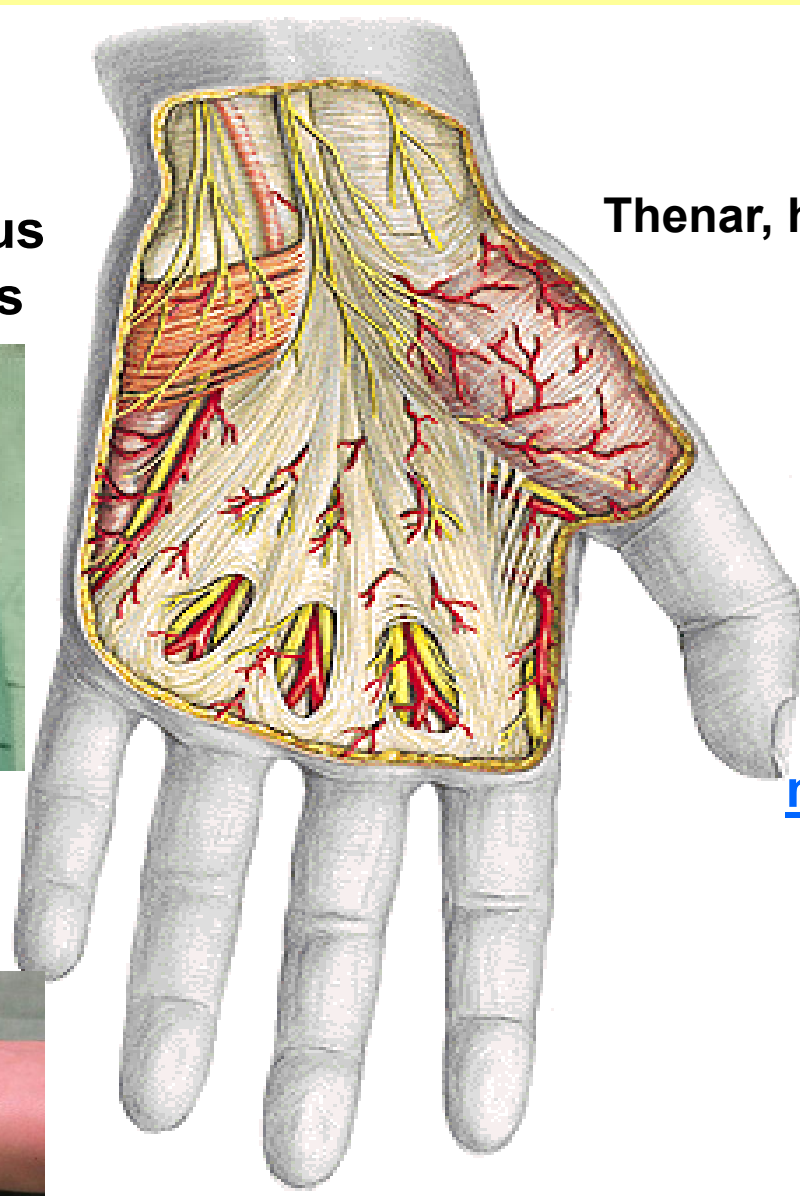
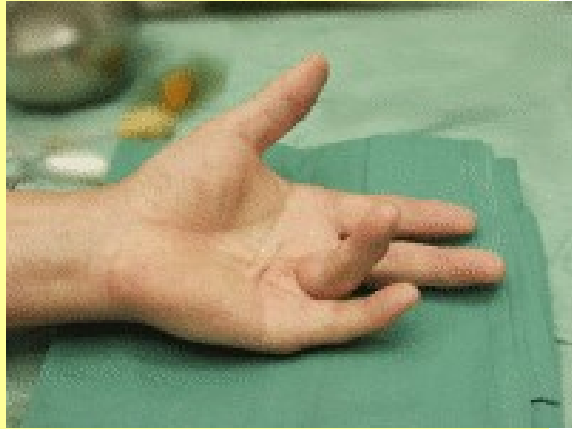Nervus medianus – fossa cubiti



n. interosseus

ant.

m. palmaris longus
brevis

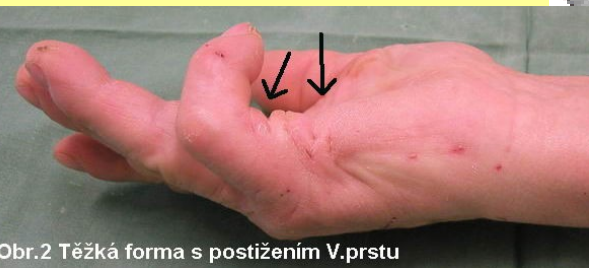

Thenar, hypothenar

PA : Dupuytren
kontraktura

fasciculi
longitudin.,transv.

nn. digitales palmares

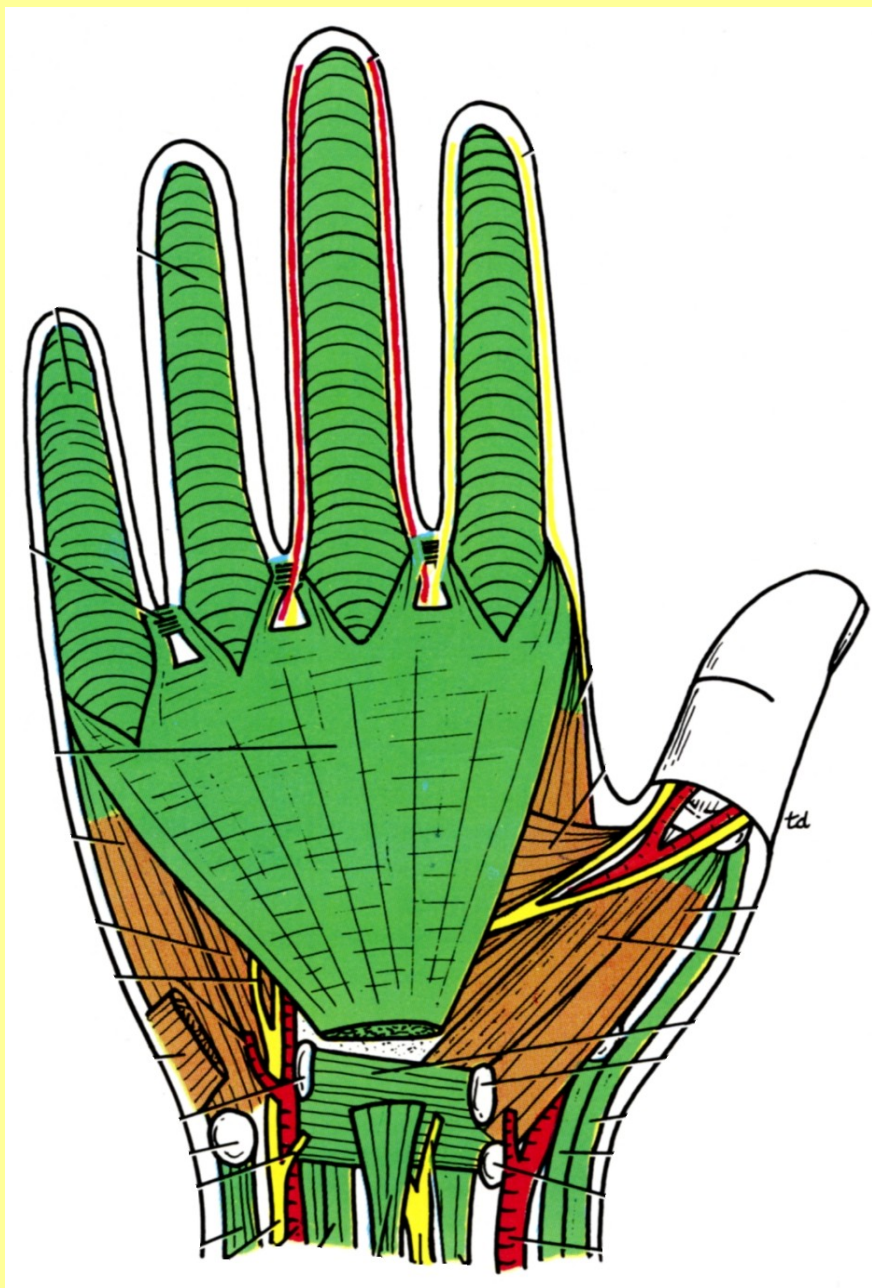


Obr.2 Těžká forma s postižením V.prstu

palmární aponeuróza (PA) – nervus medianus

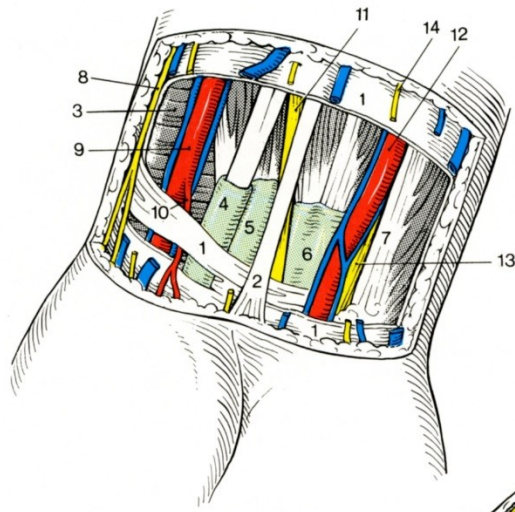
fasciculi
longitudinales
transversi

n. medianus



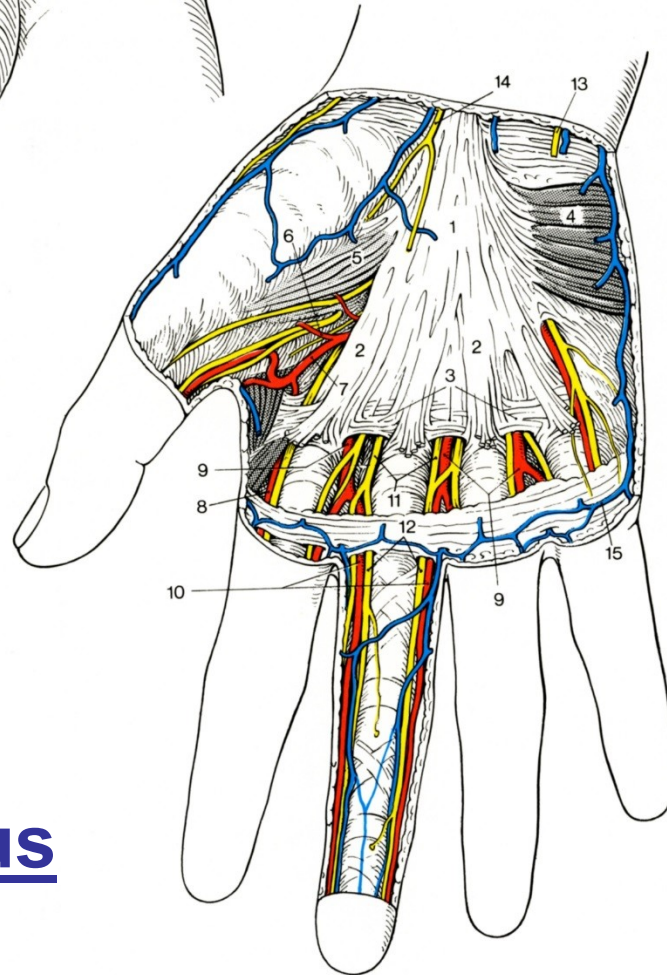
G. Dupuytren
+ 1836

PALMÁRNÍ
APONEURÓZA



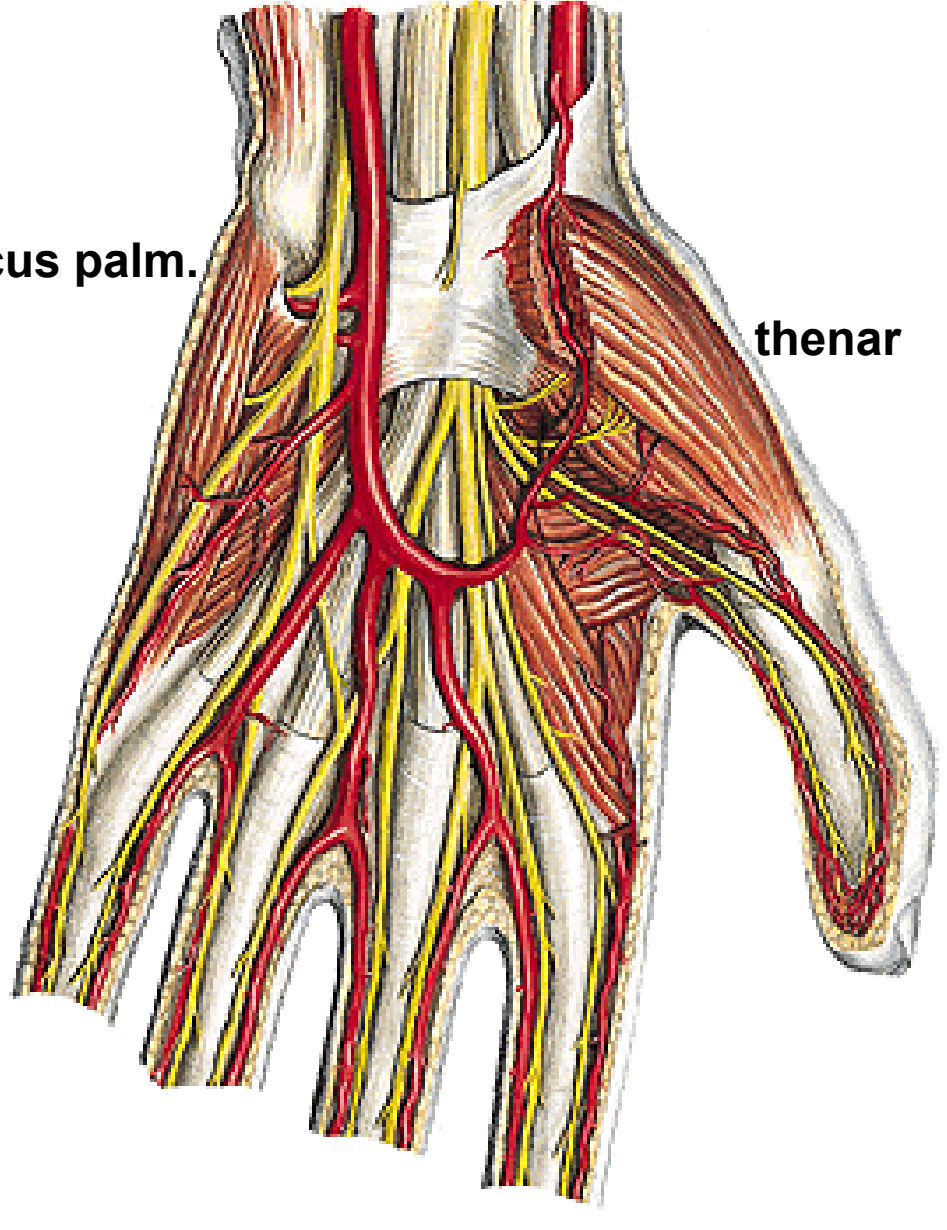
m. palmaris longus
aponeuróza

nervi digitales
palmares



Nervus medianus

Arcus palm.



thenar

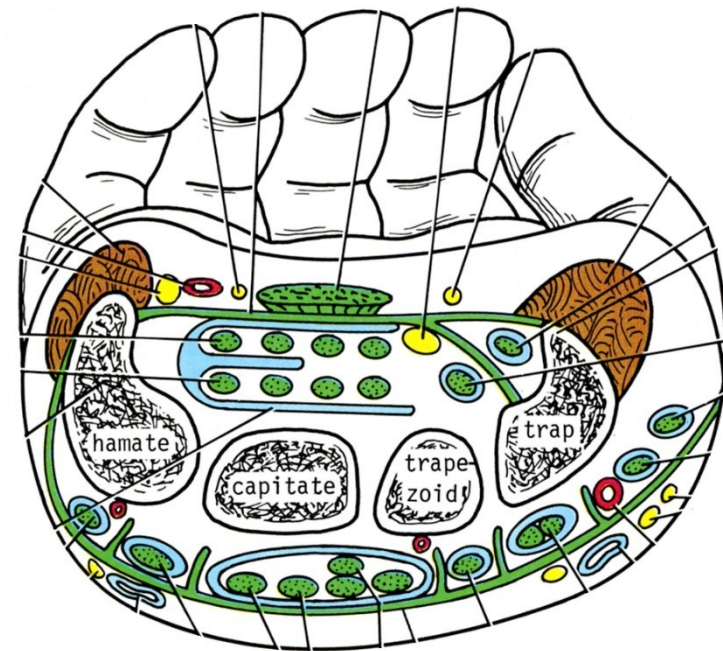
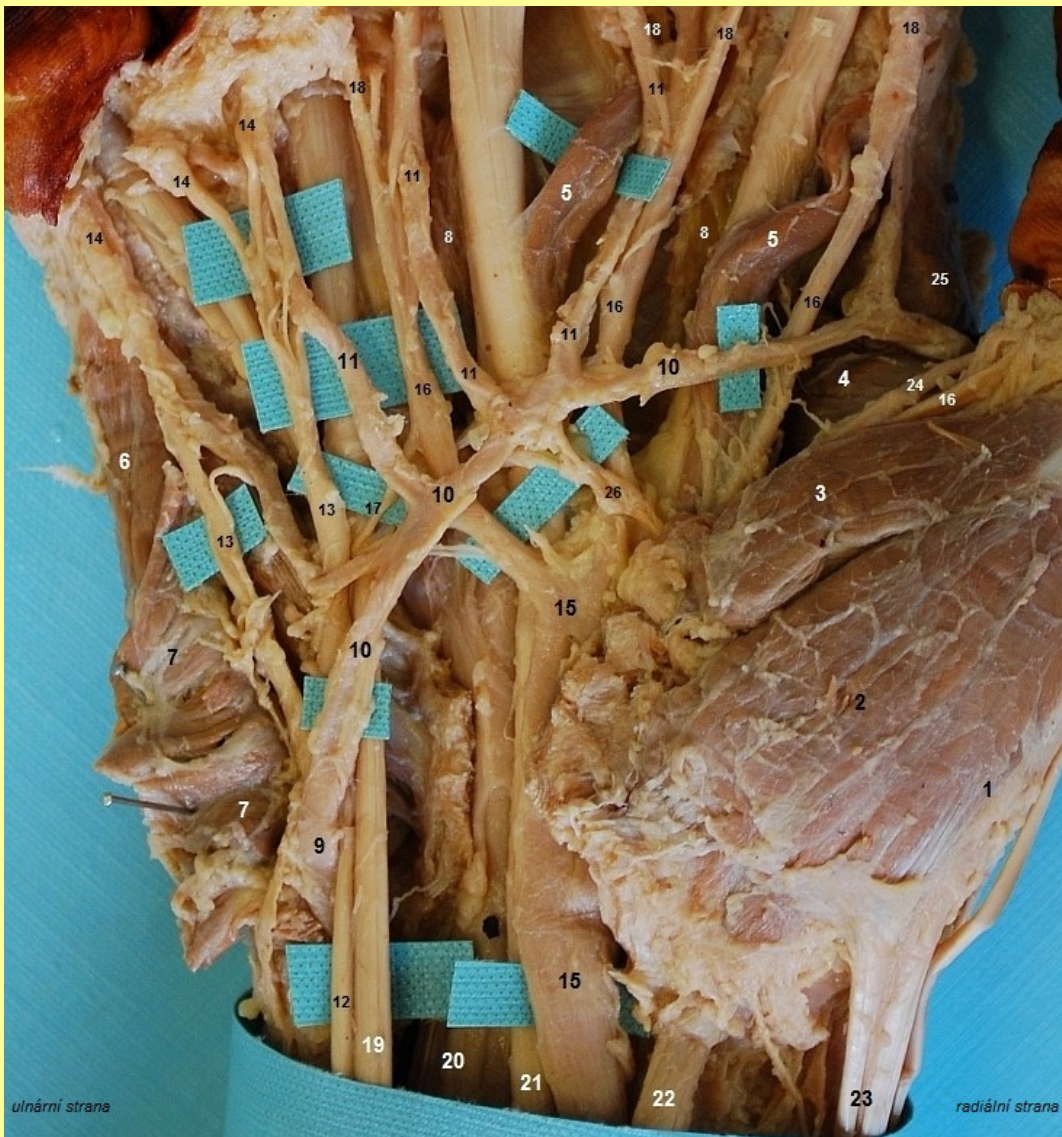retinaculum,
eminence
karpální kanál

nn. digitales palmares:

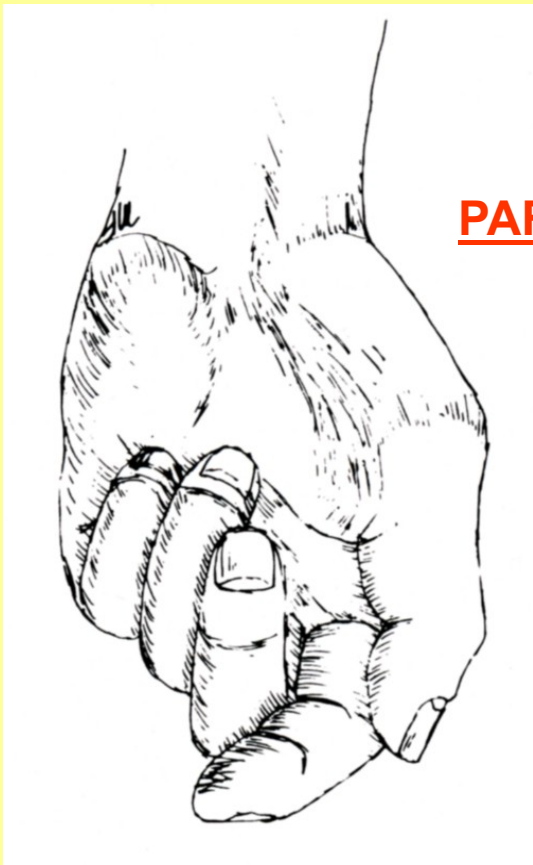a) communes

b) proprii

Odstraněna palmární aponeuróza



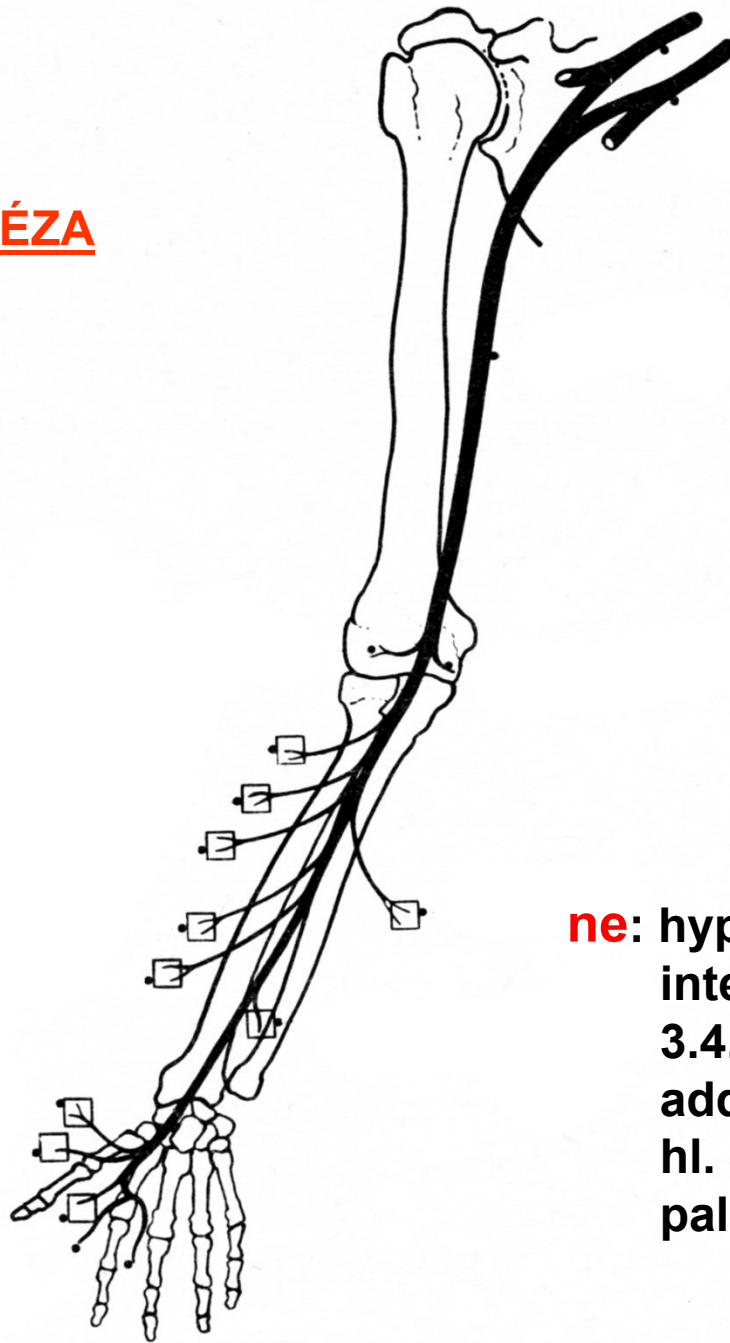
Thenar
Eminence, n. medianus, ulnaris
Karpální kanál –úžinové syndromy



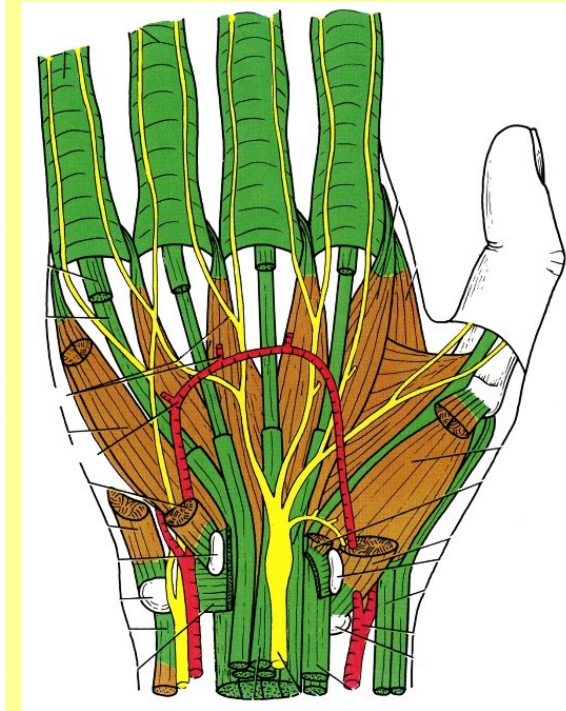
PARÉZA

Větve: rr. musculares

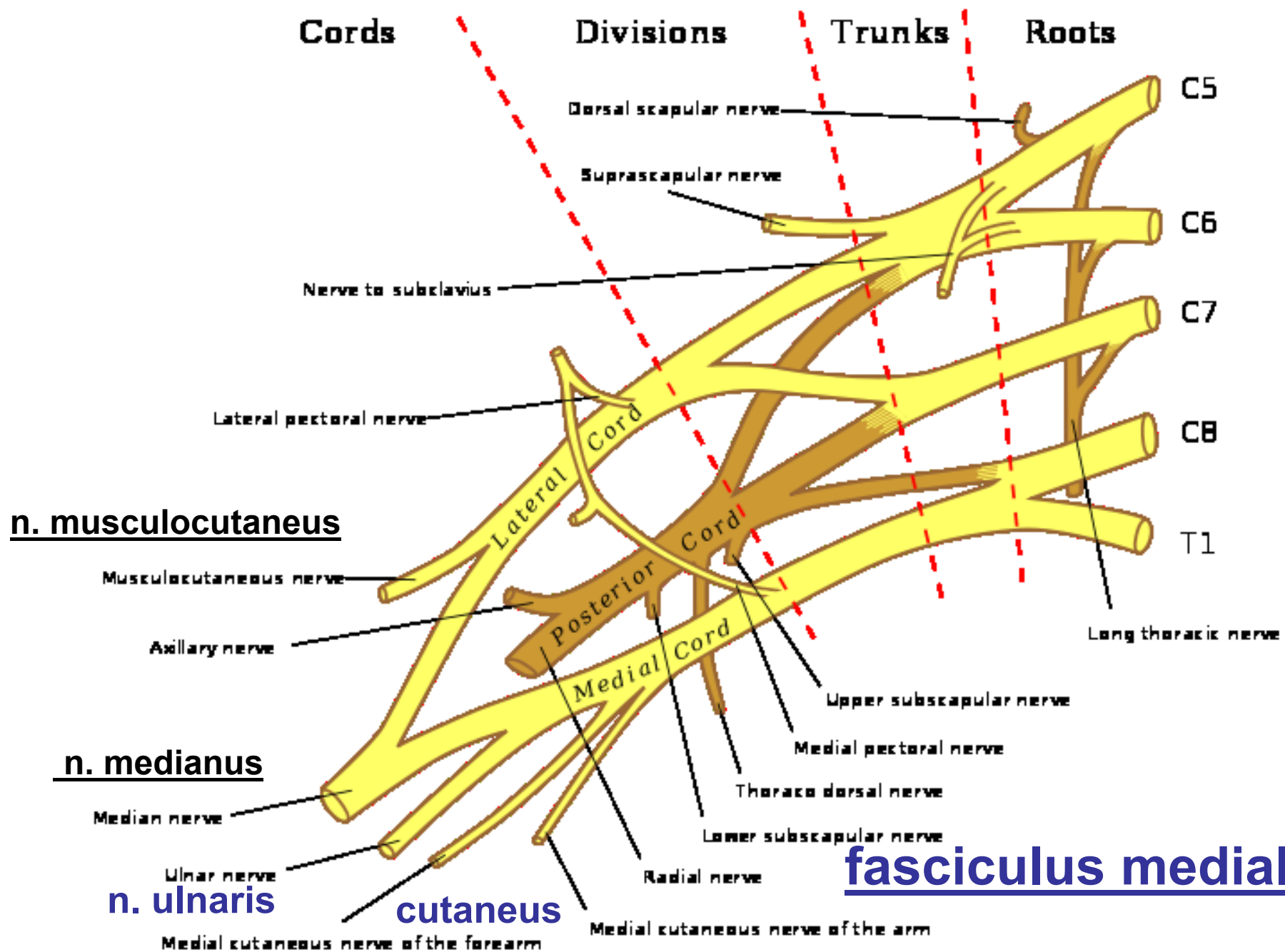
n. interosseus
nn. digitales

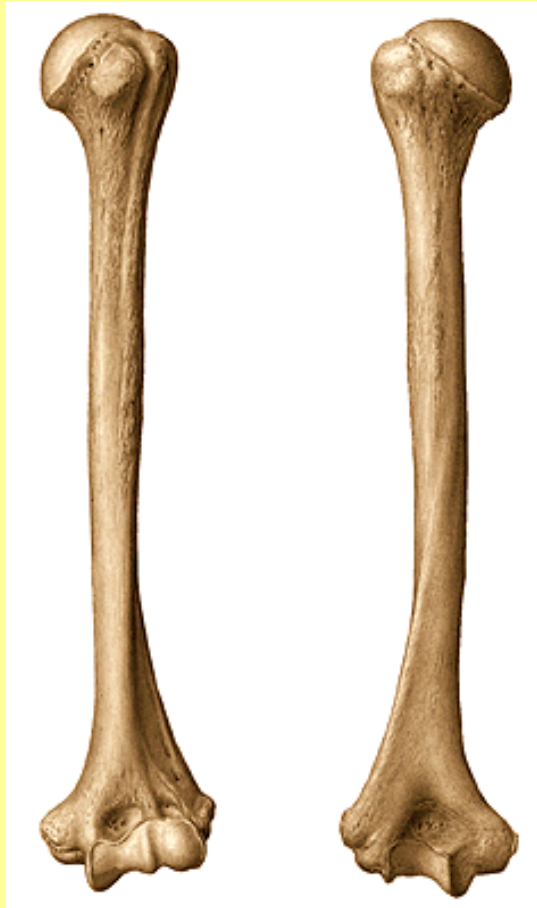

vidlice

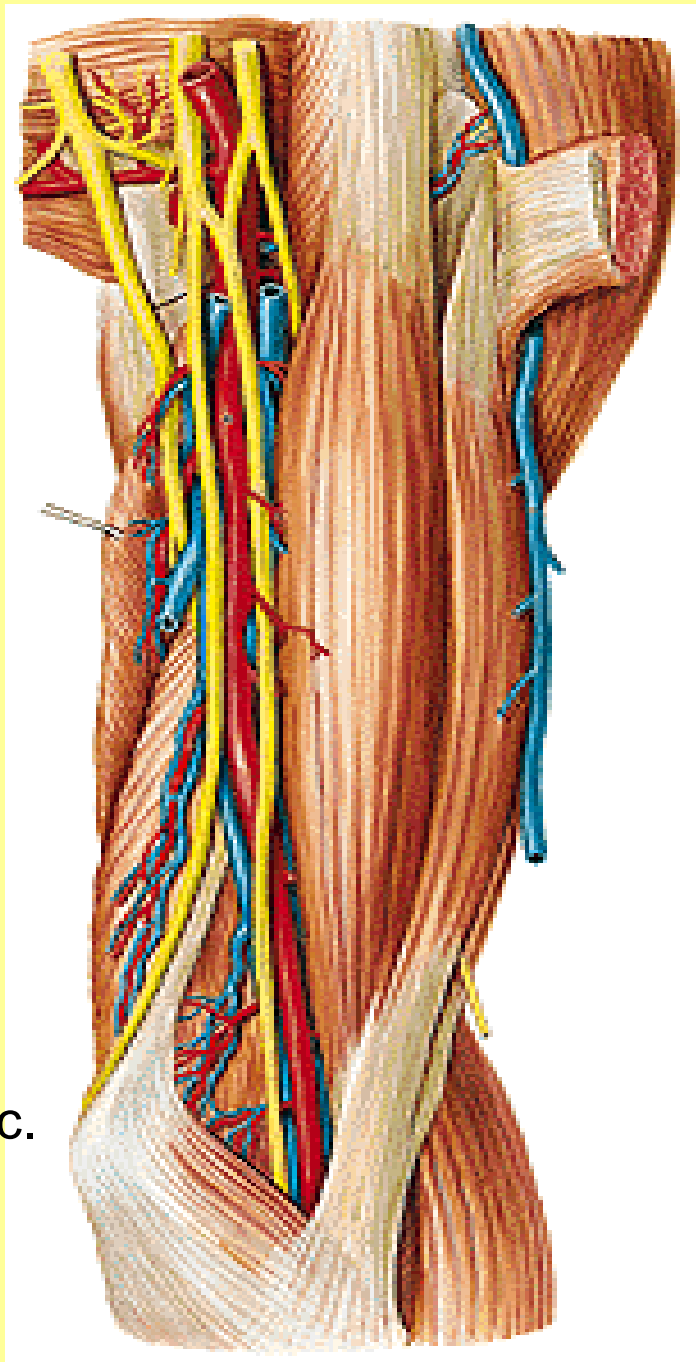


ne: hypothenar
interossei
3.4. lumbric.
adduct. pollicis
hl. hlava flexoru
palce





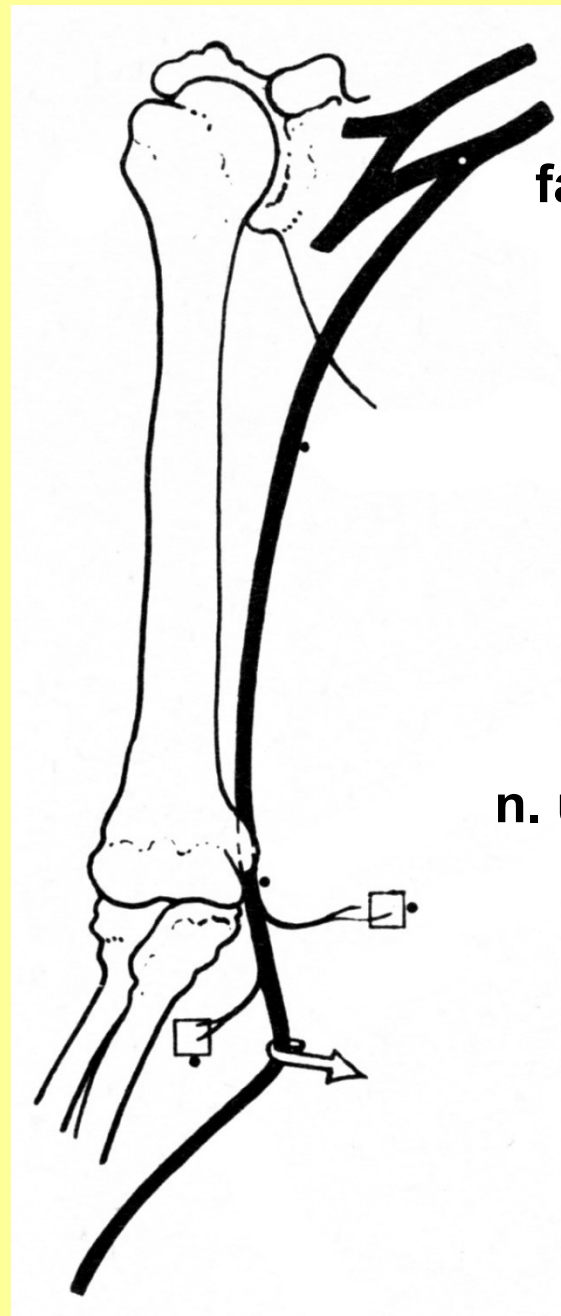
med. epic.



Vidlice

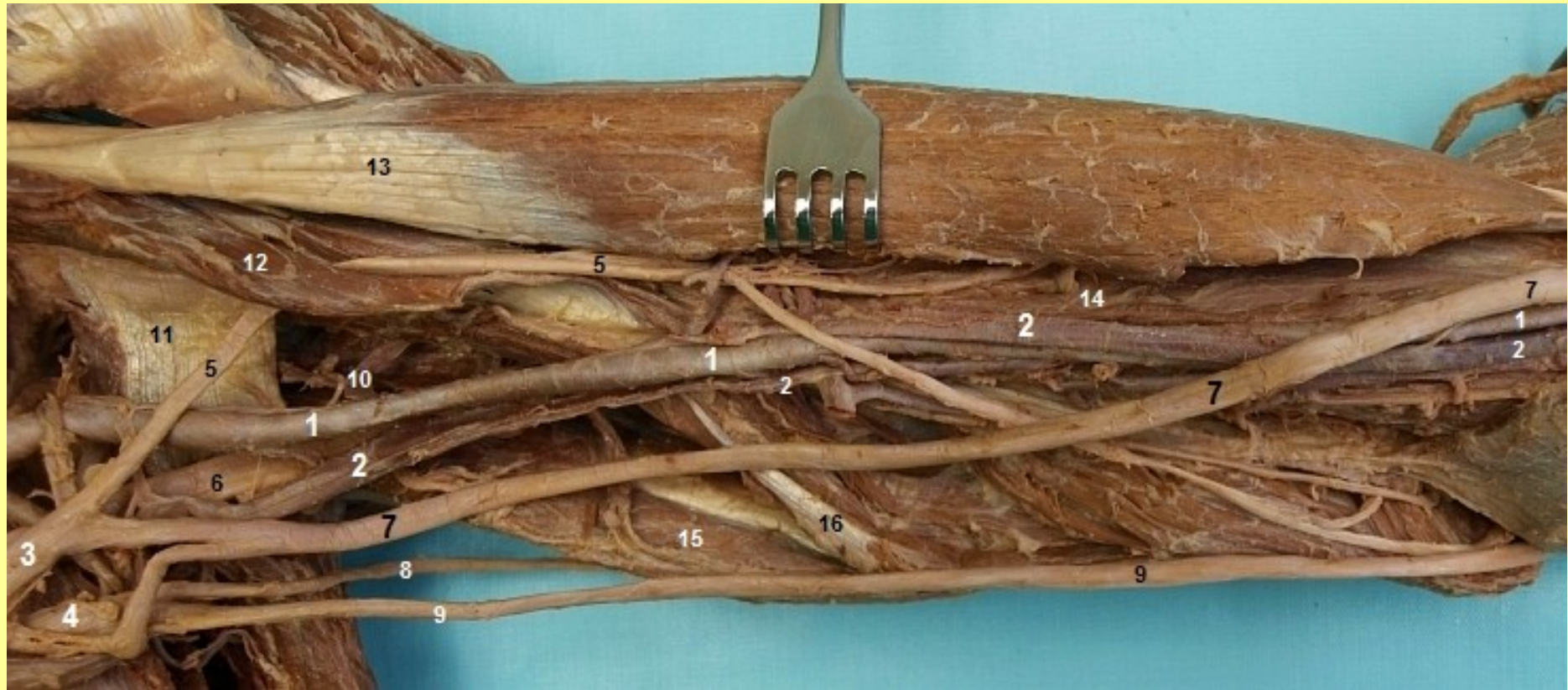
TOPO: med. sulcus,
septum

n. ulnaris

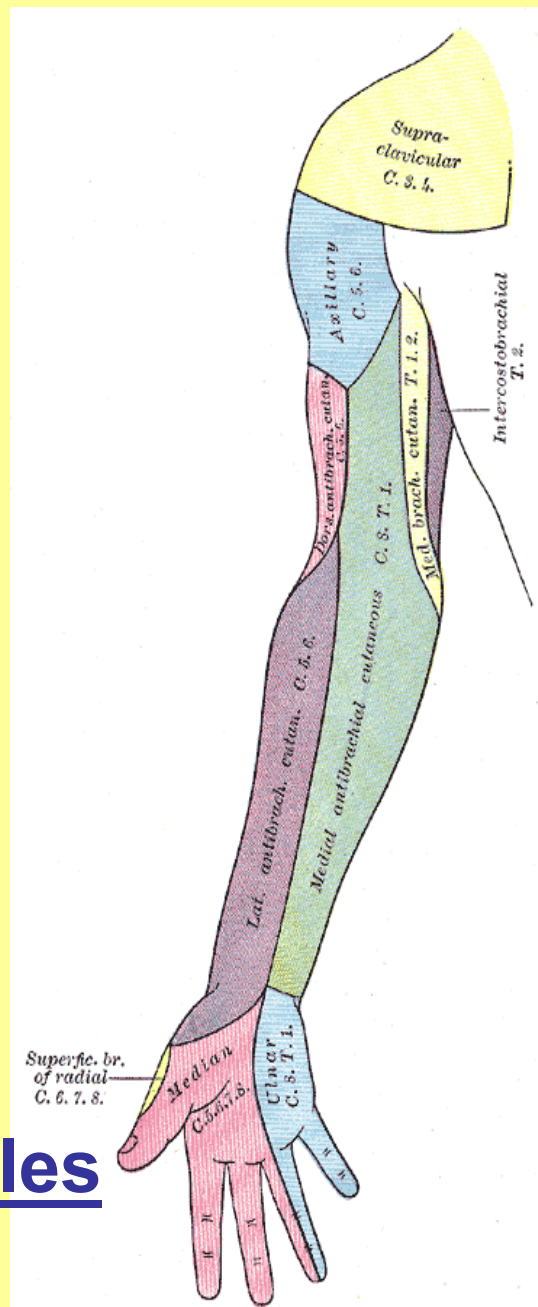
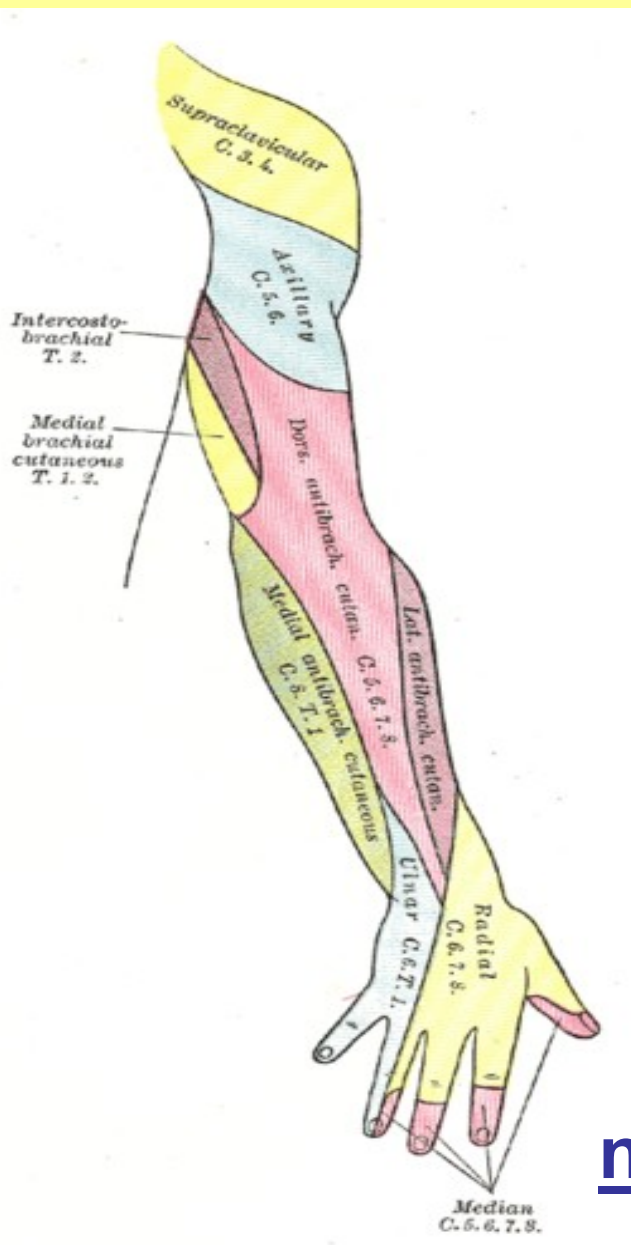


fasciculus medialis

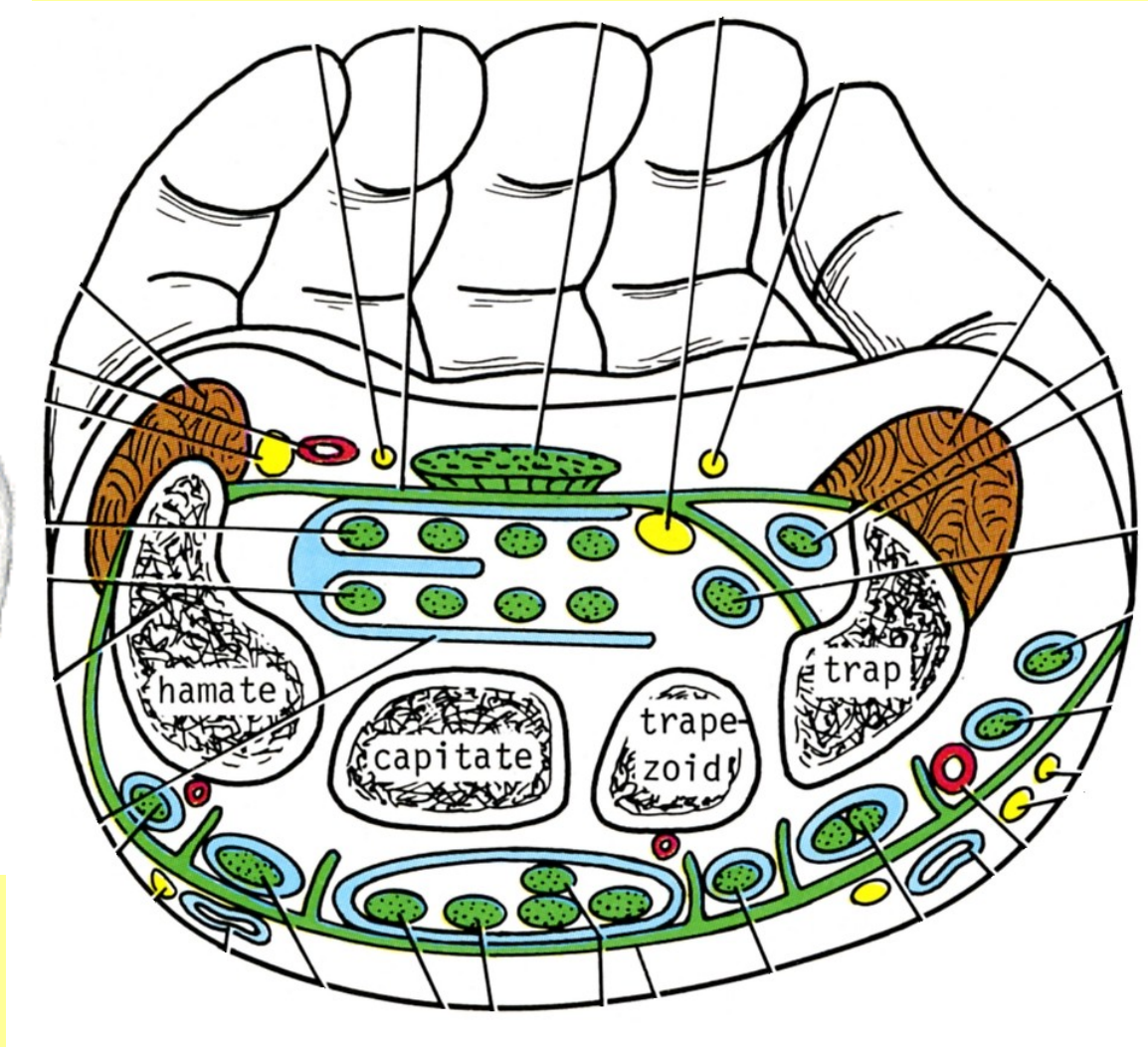
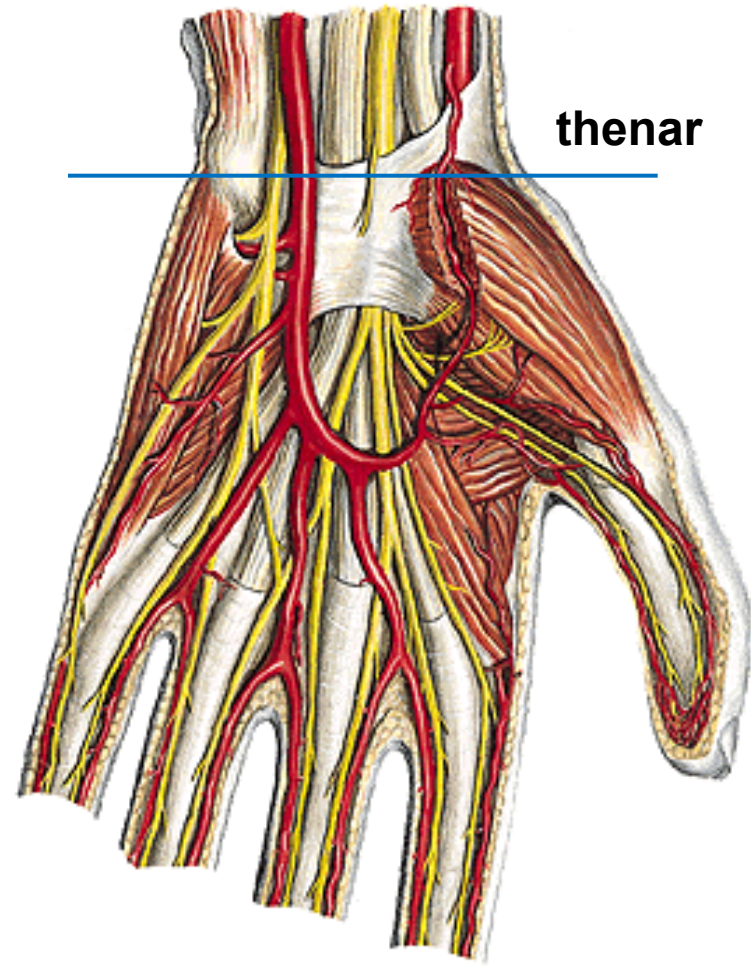
n. ulnaris za epikondylem



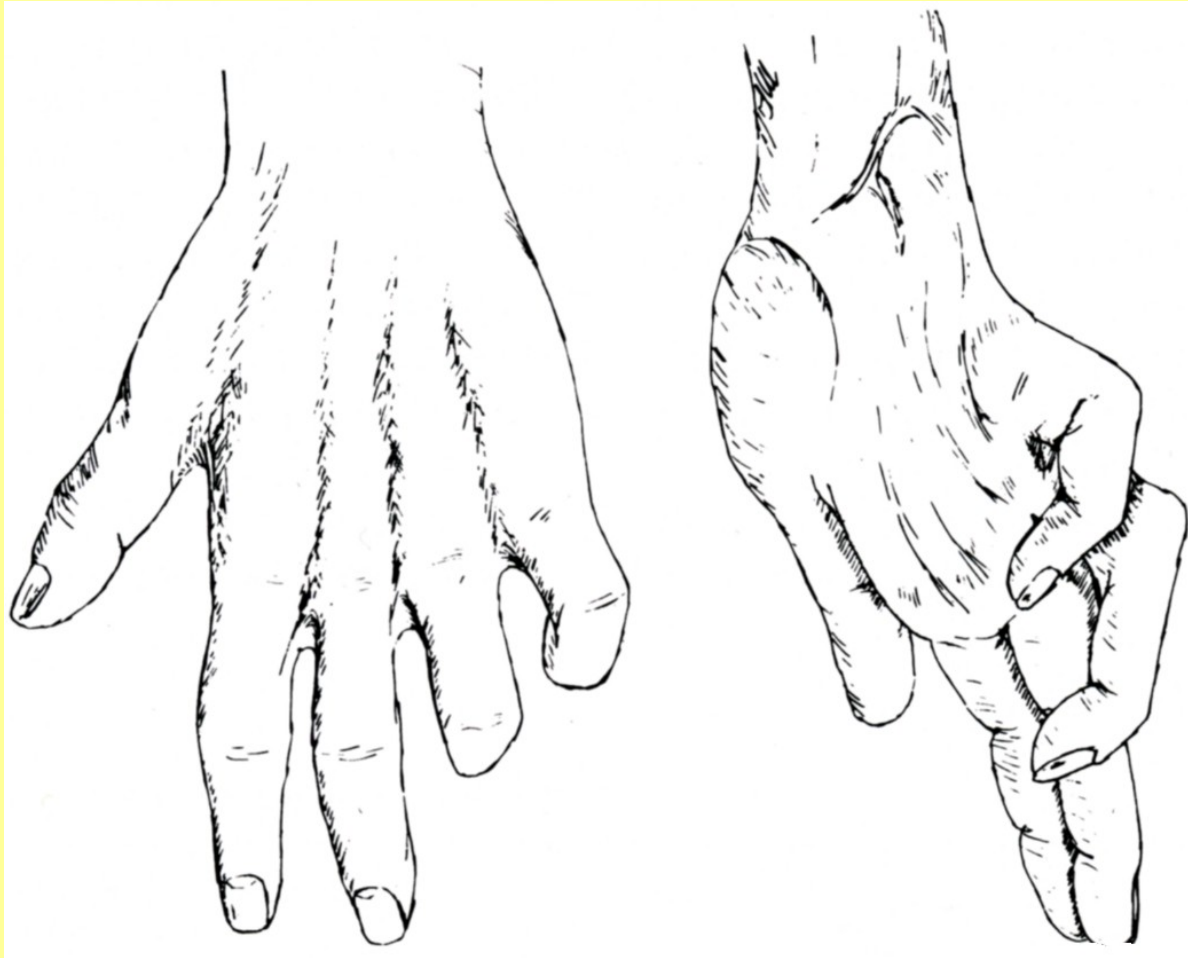
Mediální svazek: n. ulnaris a cutaneus antebrachii



nn. digitales



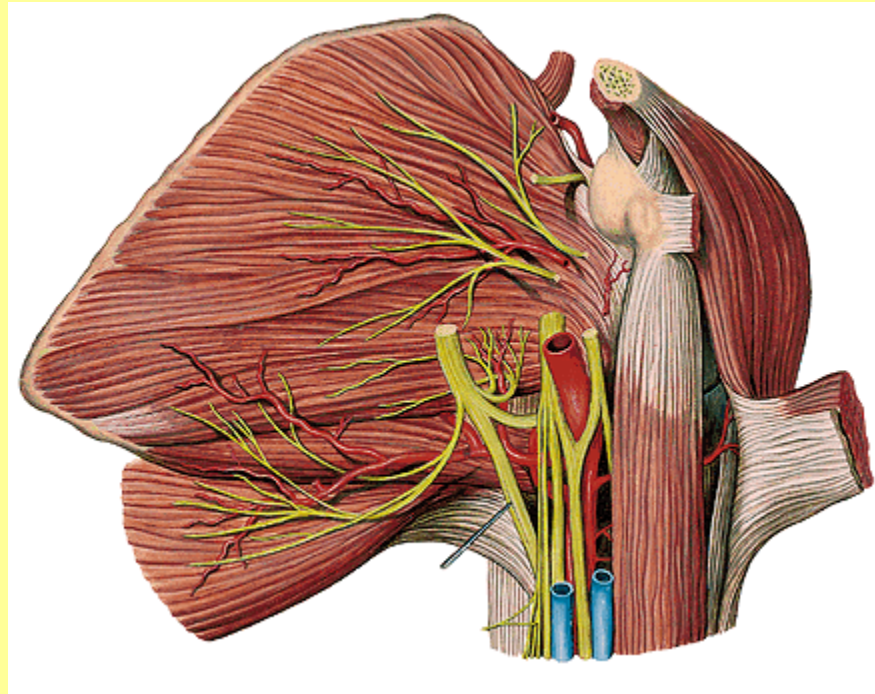
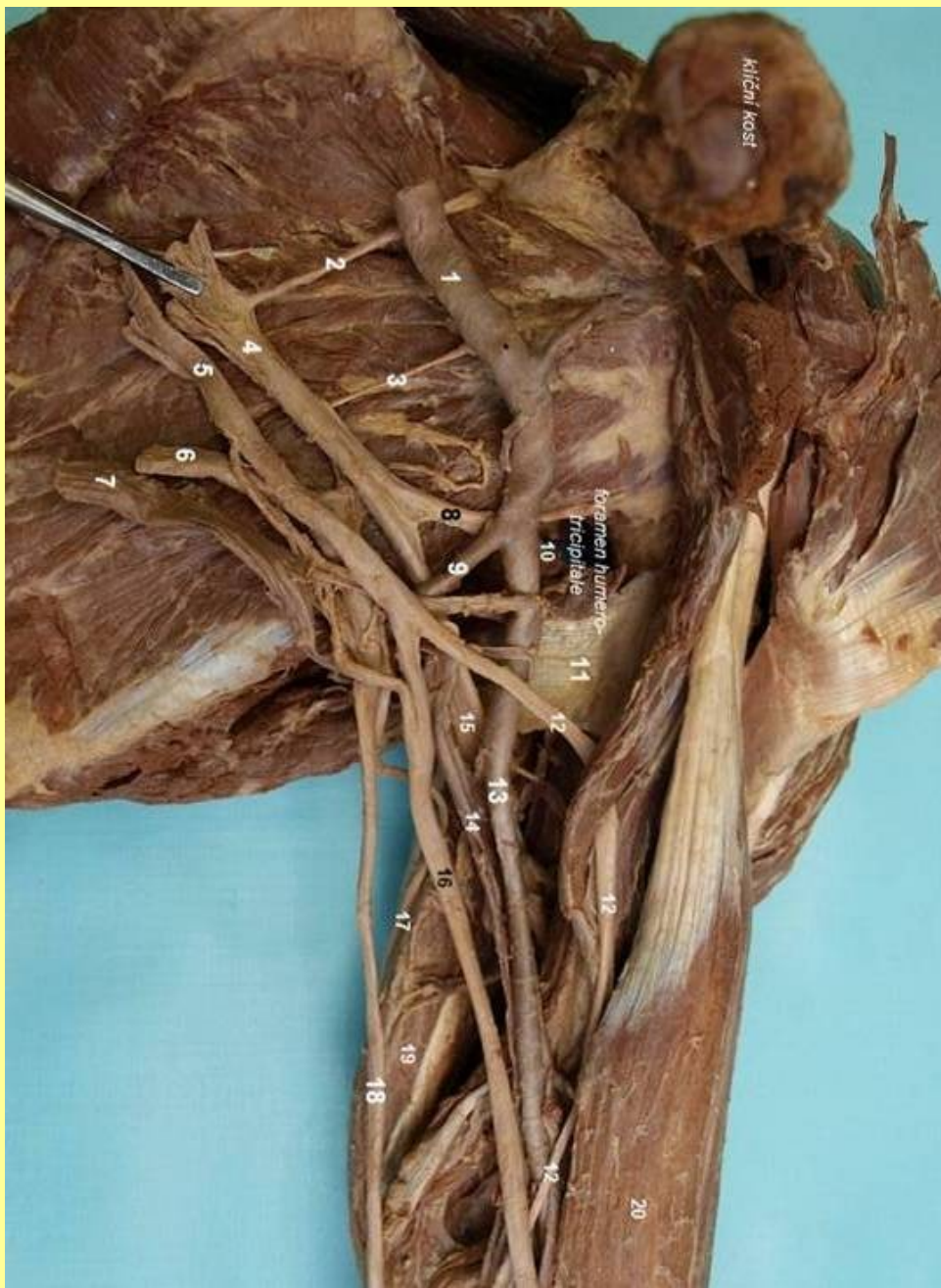n. ulnaris -
r. superficial., prof.



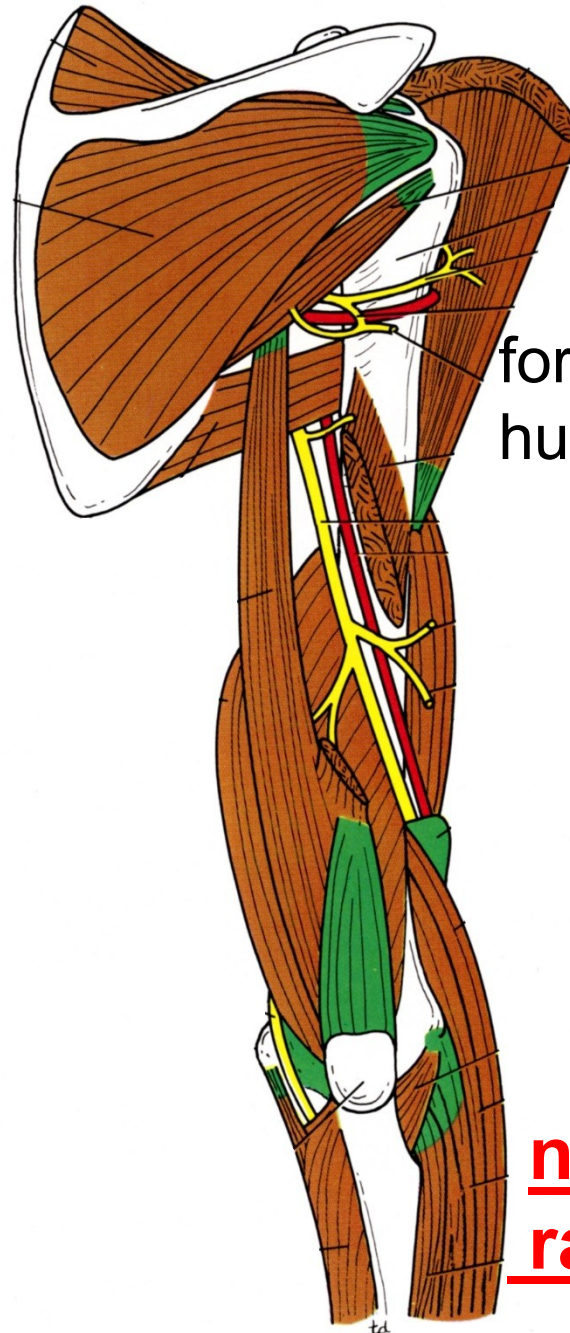
extenze MF

flexe 4.,5. prstu

paréza n. ulnaris – drápvitá ruka

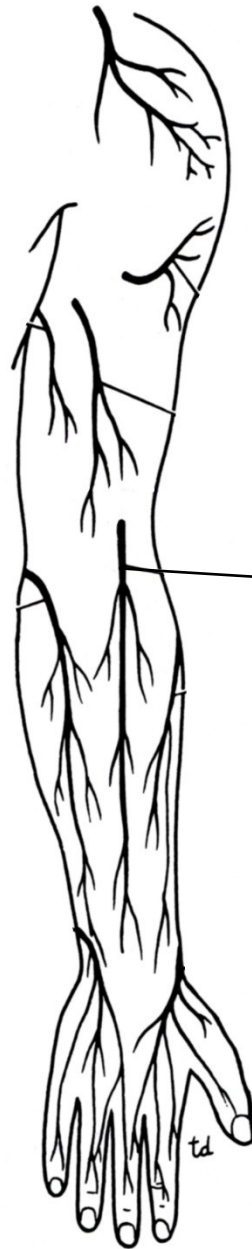
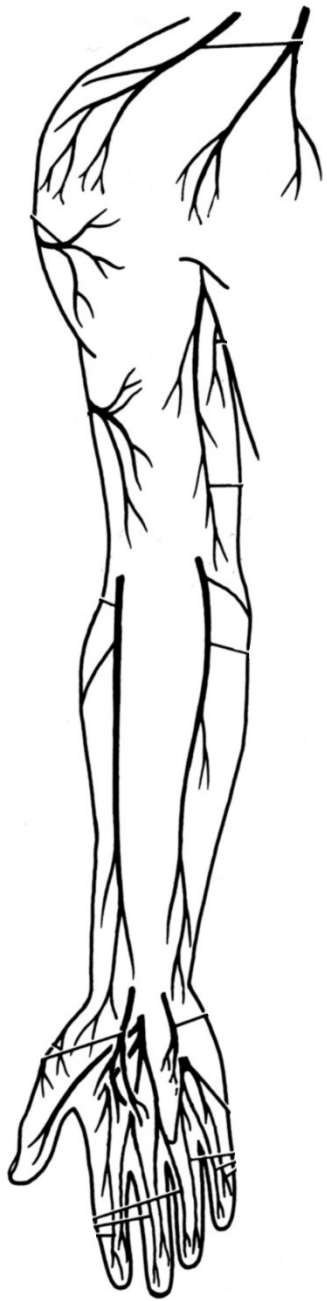
Fasciculus post. :
n. axillaris, radialis



foramen
humero-tricip.

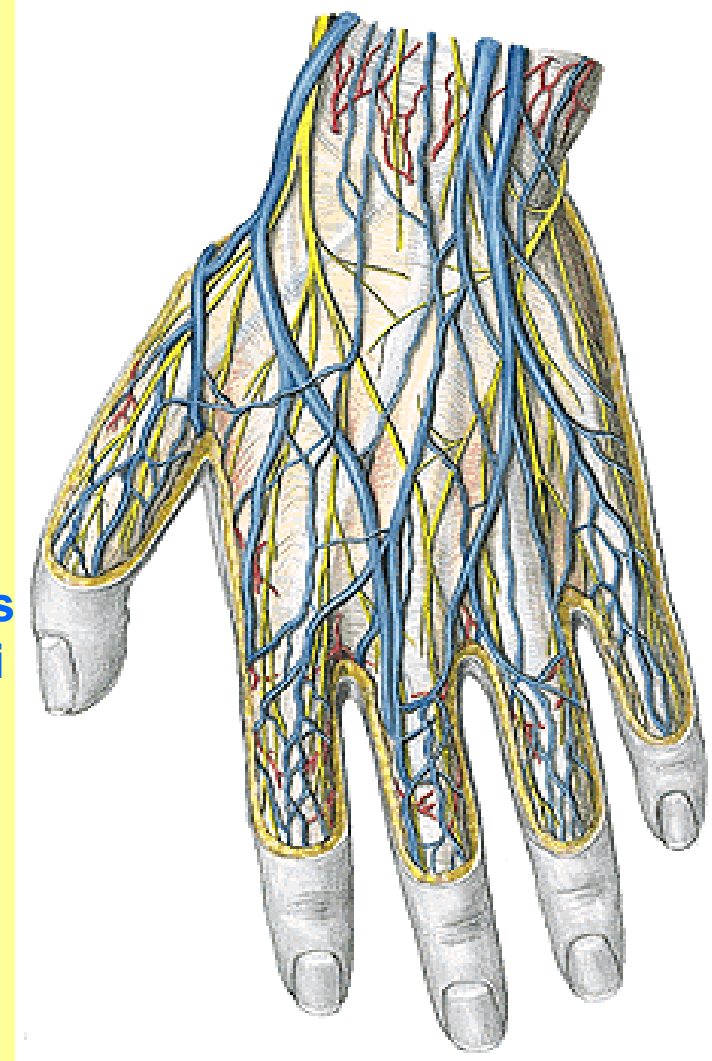
n. axillaris,
radialis

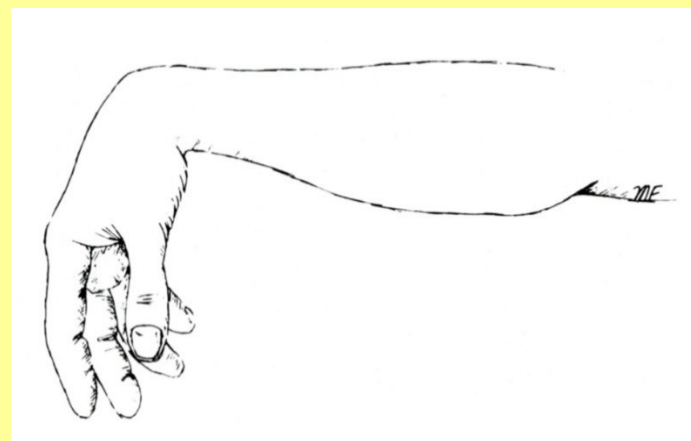
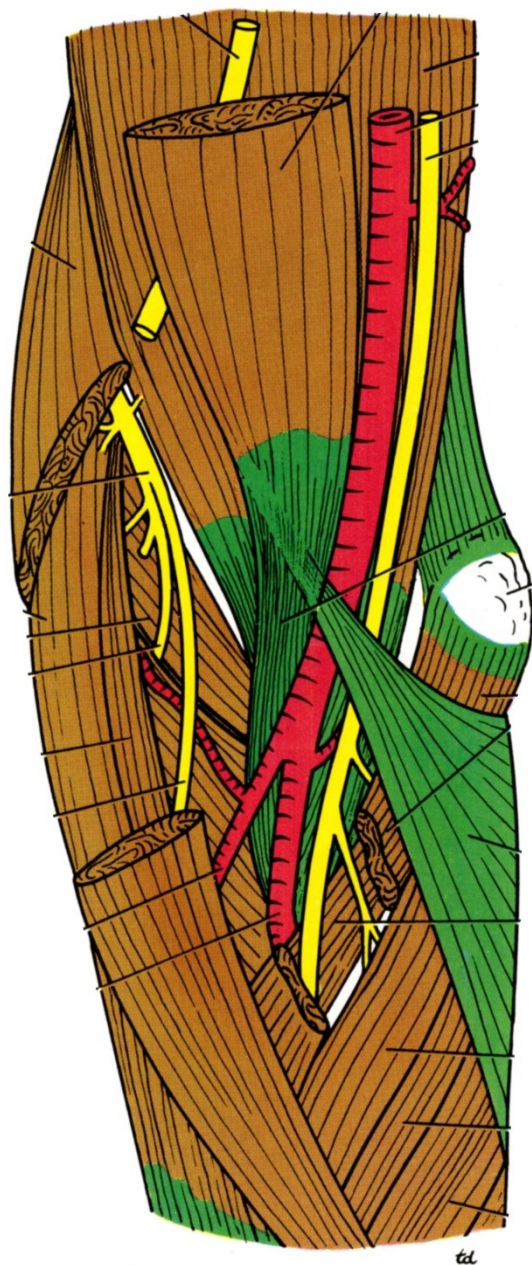
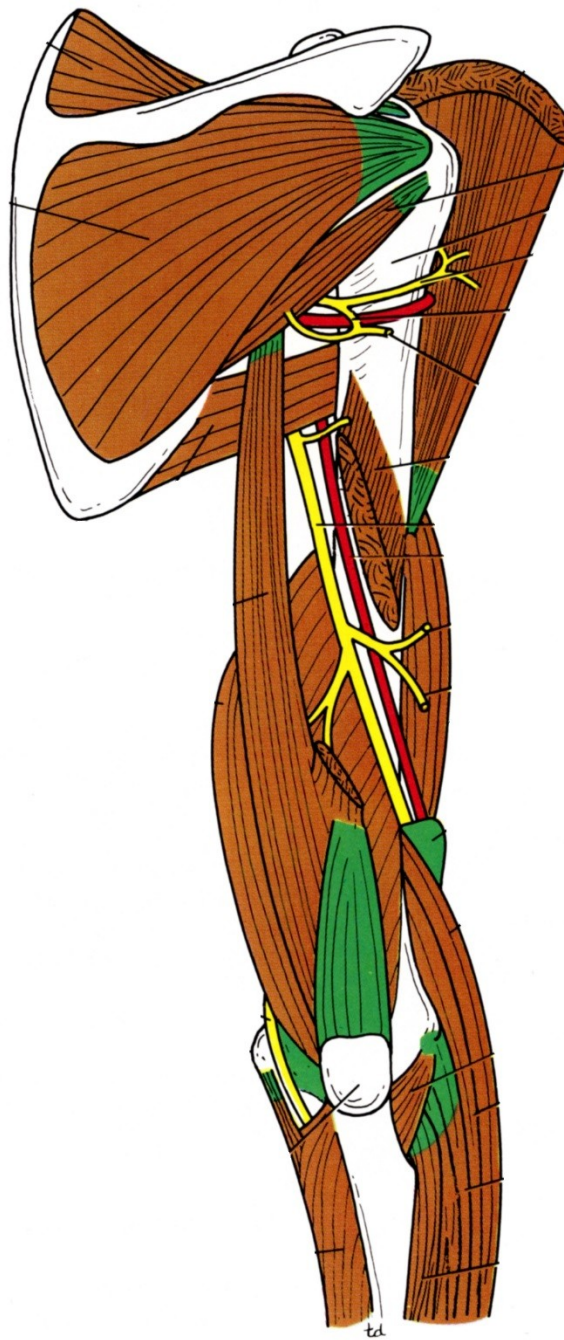


**n. cutaneus
antebrachii
posterior**

**r. superficialis – nn. digitales
dorsales**

r. profundus





Paréza: “syndrom labutí šije“

n. radialis

Podkožní (povrchové) žíly HK, DK

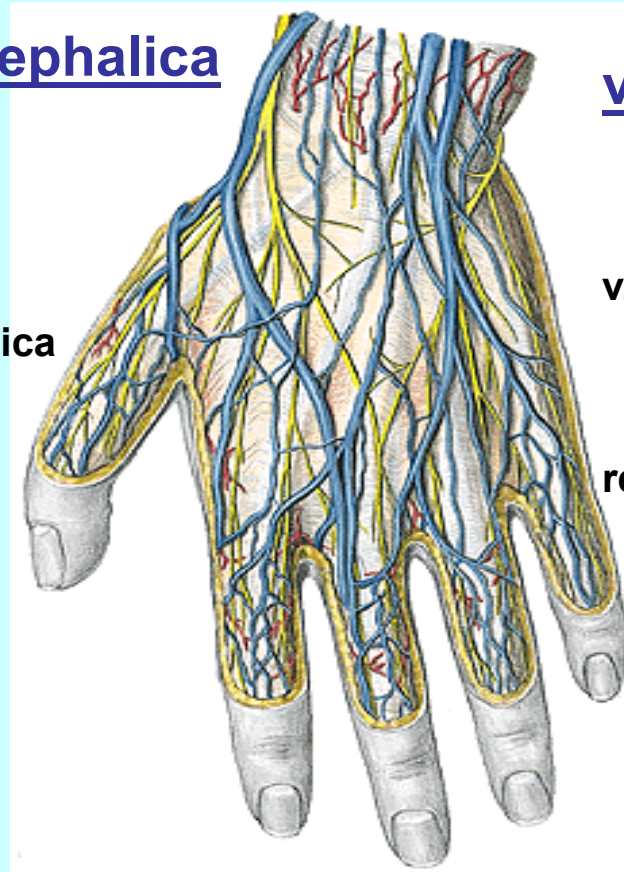
v. cephalica

v. basilica

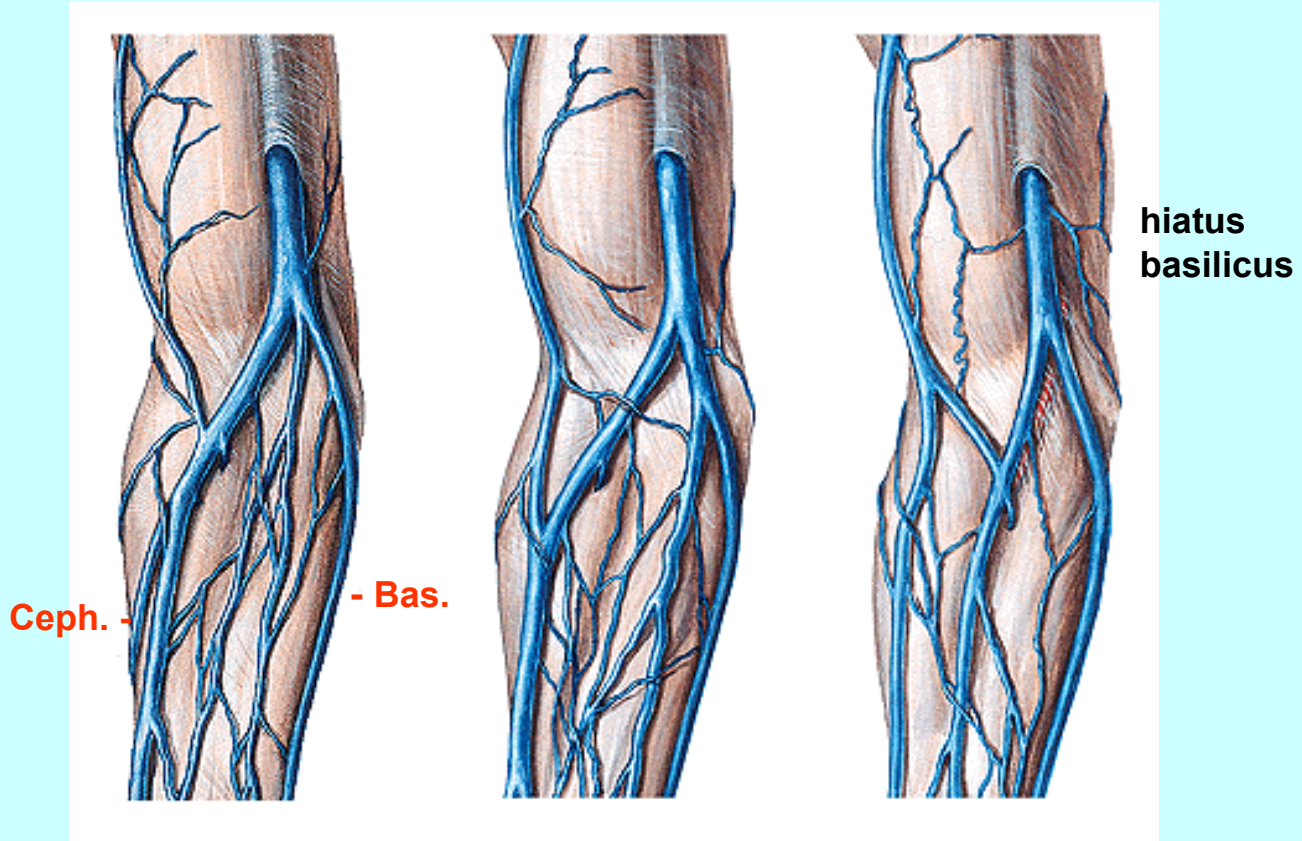
vena cephalica
pollicis

v. salvatela (IV)

rete digitale dorsale



Rete venosum dorsale
manus

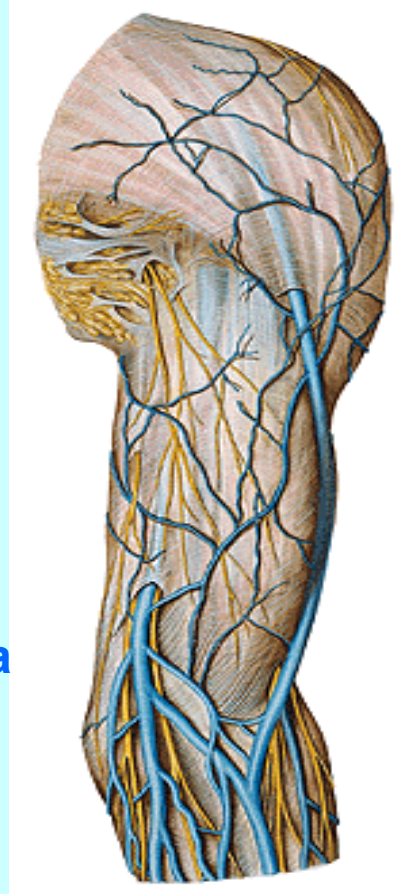


v. cephalica, basilica, mediana antebrachii - variabilita

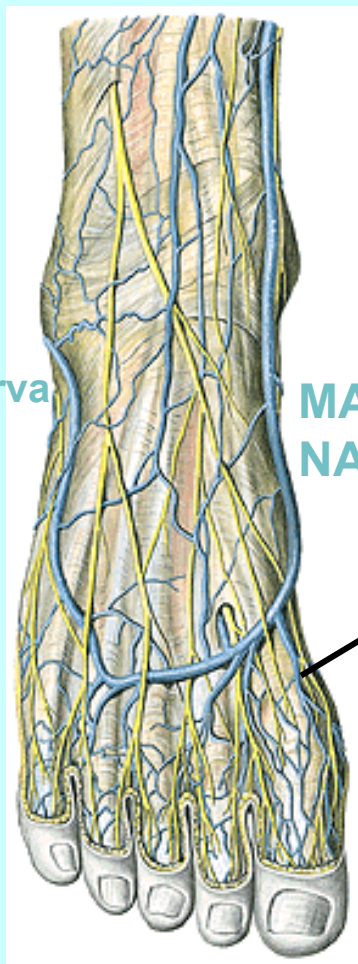
hiatus
basilicus - levá strana

+ n. cutaneus

VE FASCIA BRACHII



v. cephalica
(do v. axillaris)
v trigonu



parva

MAG
NA

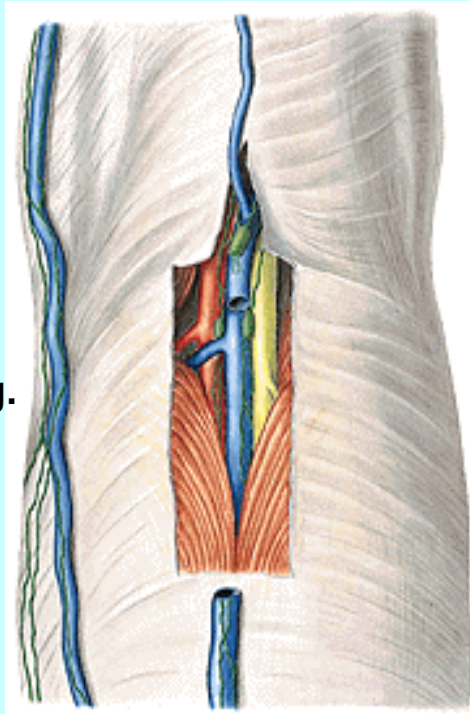
před kotníkem

v. marginalis med.

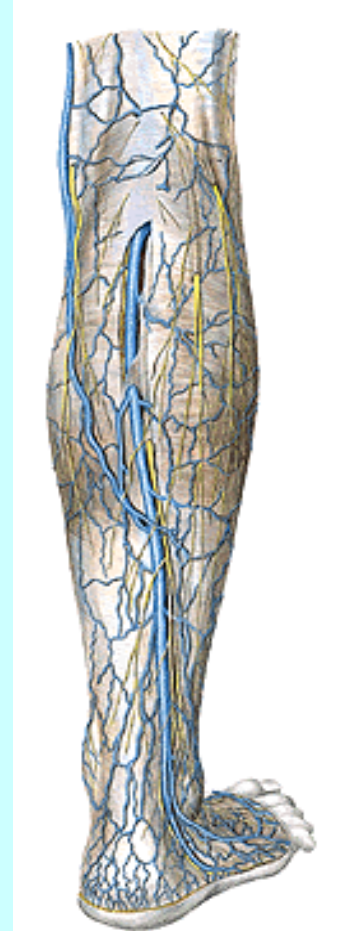rete venosum dorsale

vena saphena magna

Saph.mag.



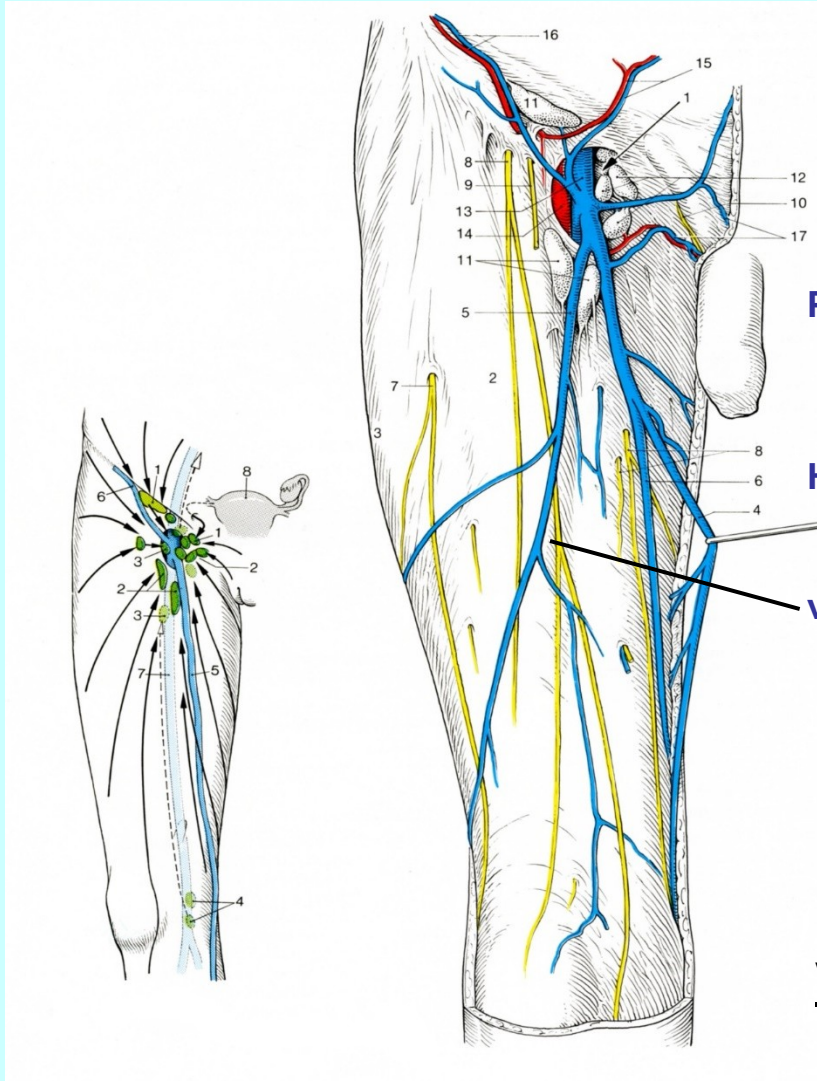
parv
a



RETE VENOSUM
DORSALE

v. marginalis lat.

VENA SAPHENA PARVA

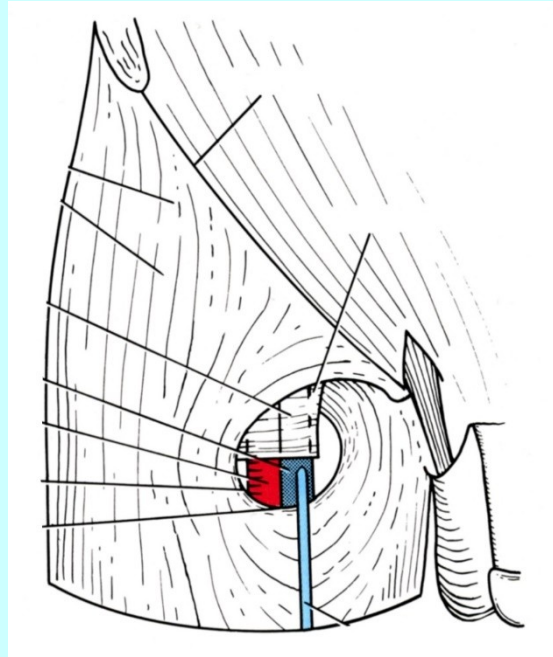
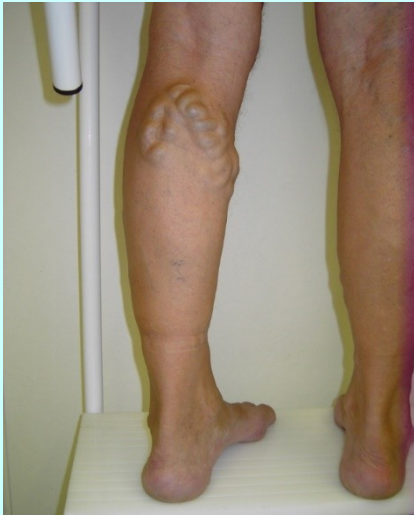
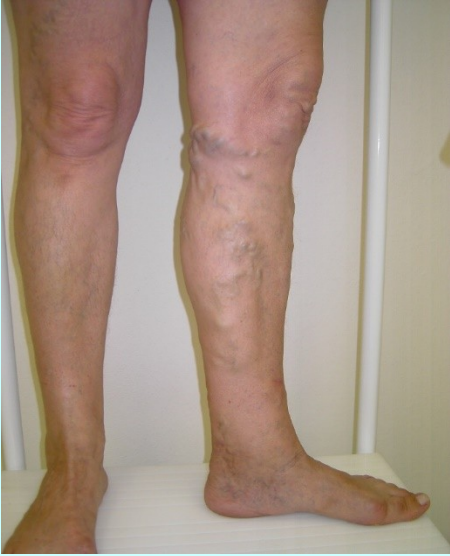
PŘÍTOKY: pudendae ext.
epigastr. superf.
circumflexa ilium

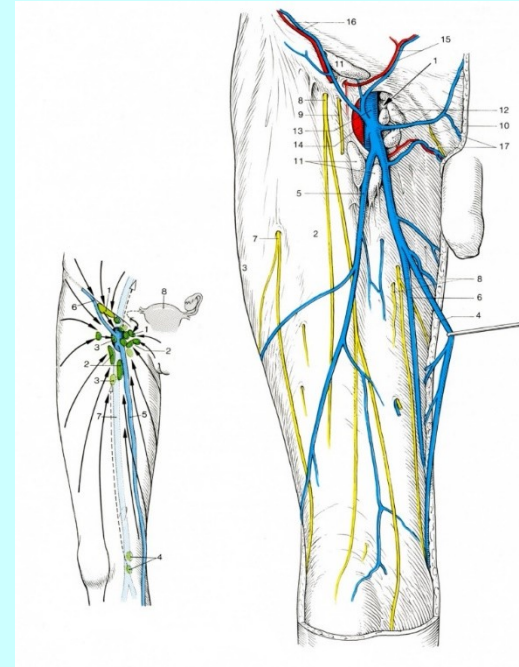
HIATUS

v. saphena accessoria

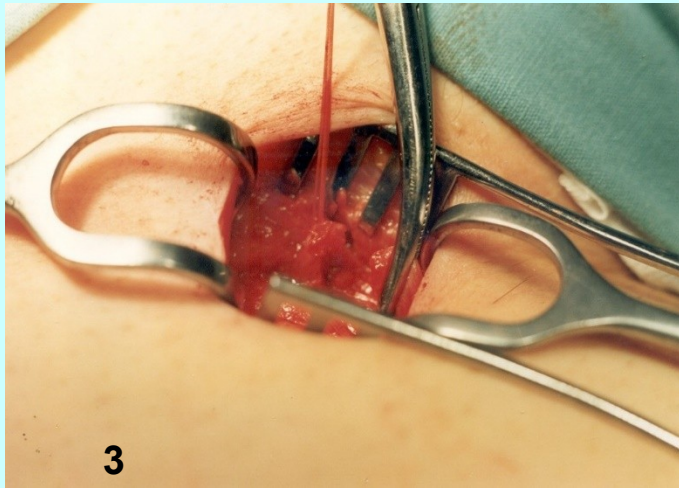
V. SAPHENA MAGNA



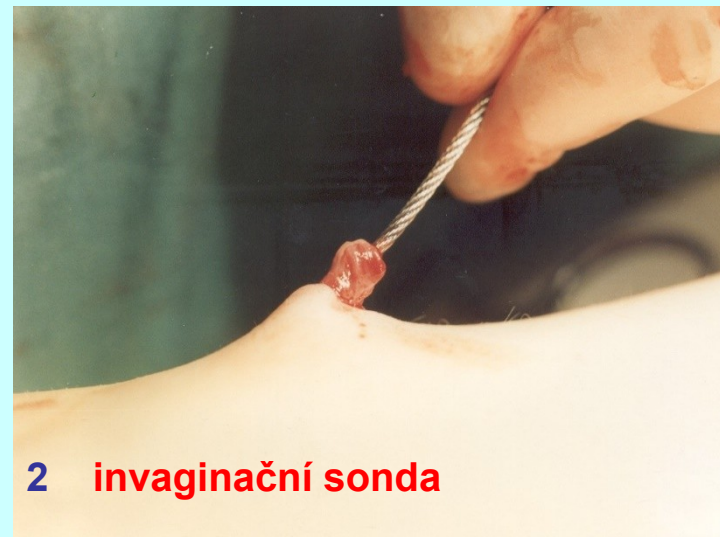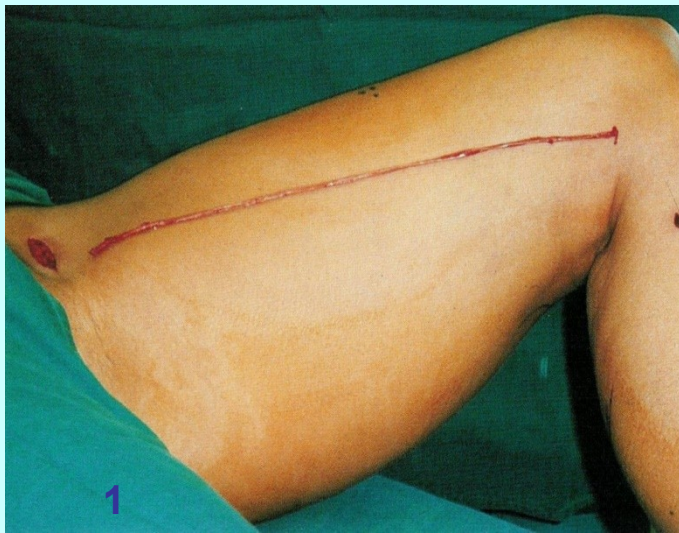margo falciformis
fascia cribrosa



HIATUS SAPHENUS



c) Invaginační striping
(svléci, stáhnout)





Preparace těl
Svalová soustava atd.
Kardiovaskul. systém
Malířství
Vynálezy

Fine

Leonardo da Vinci , 1452