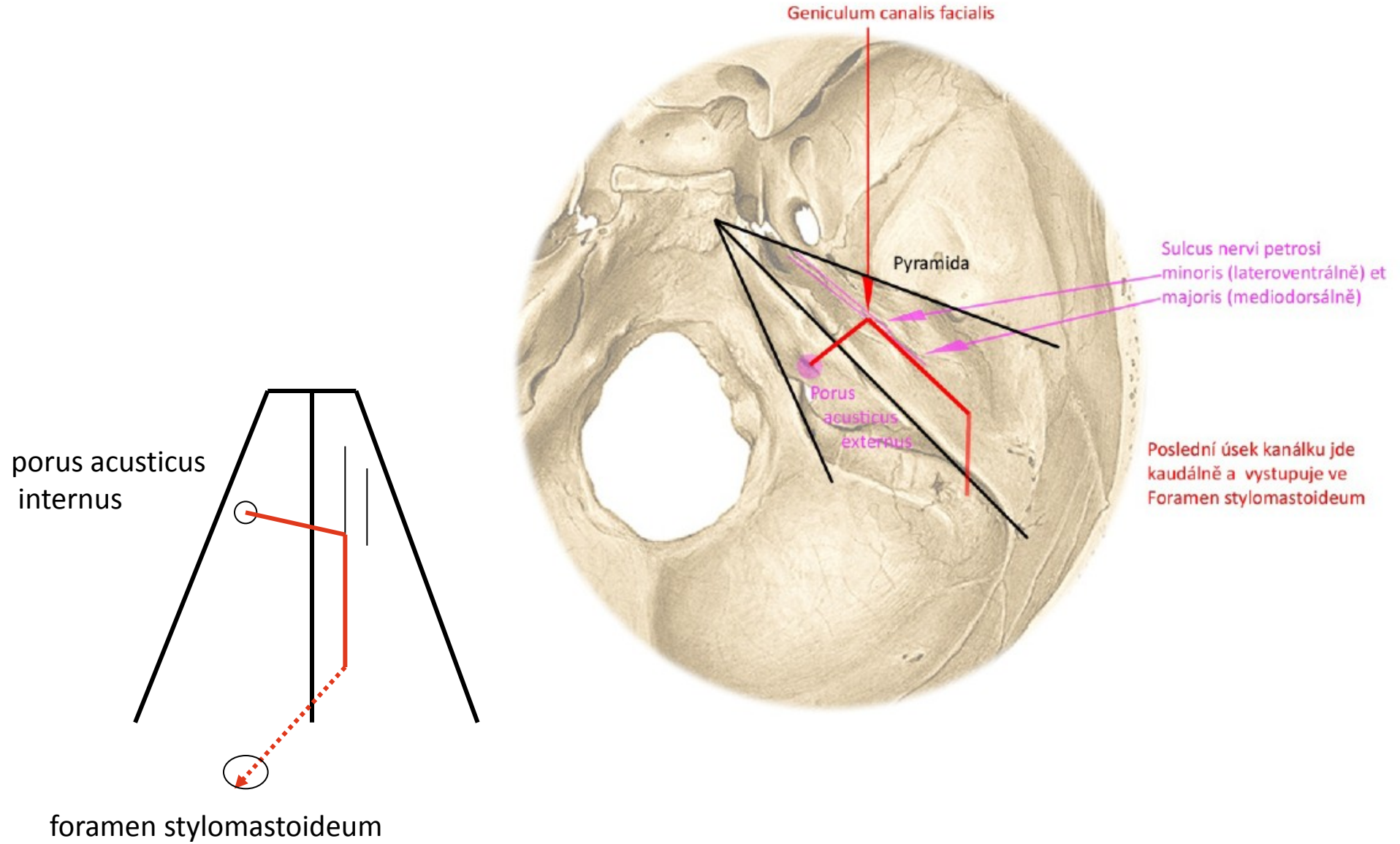


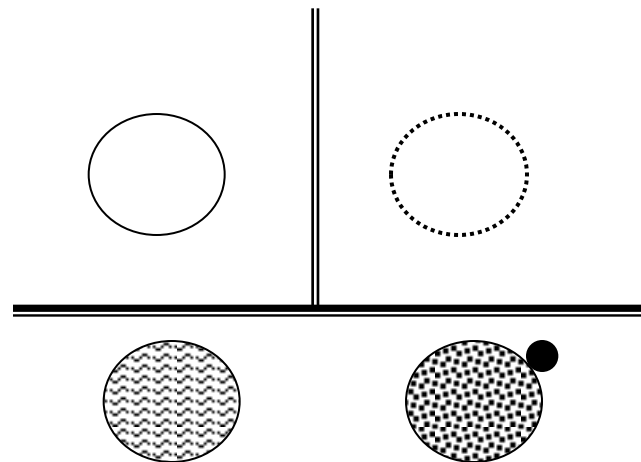
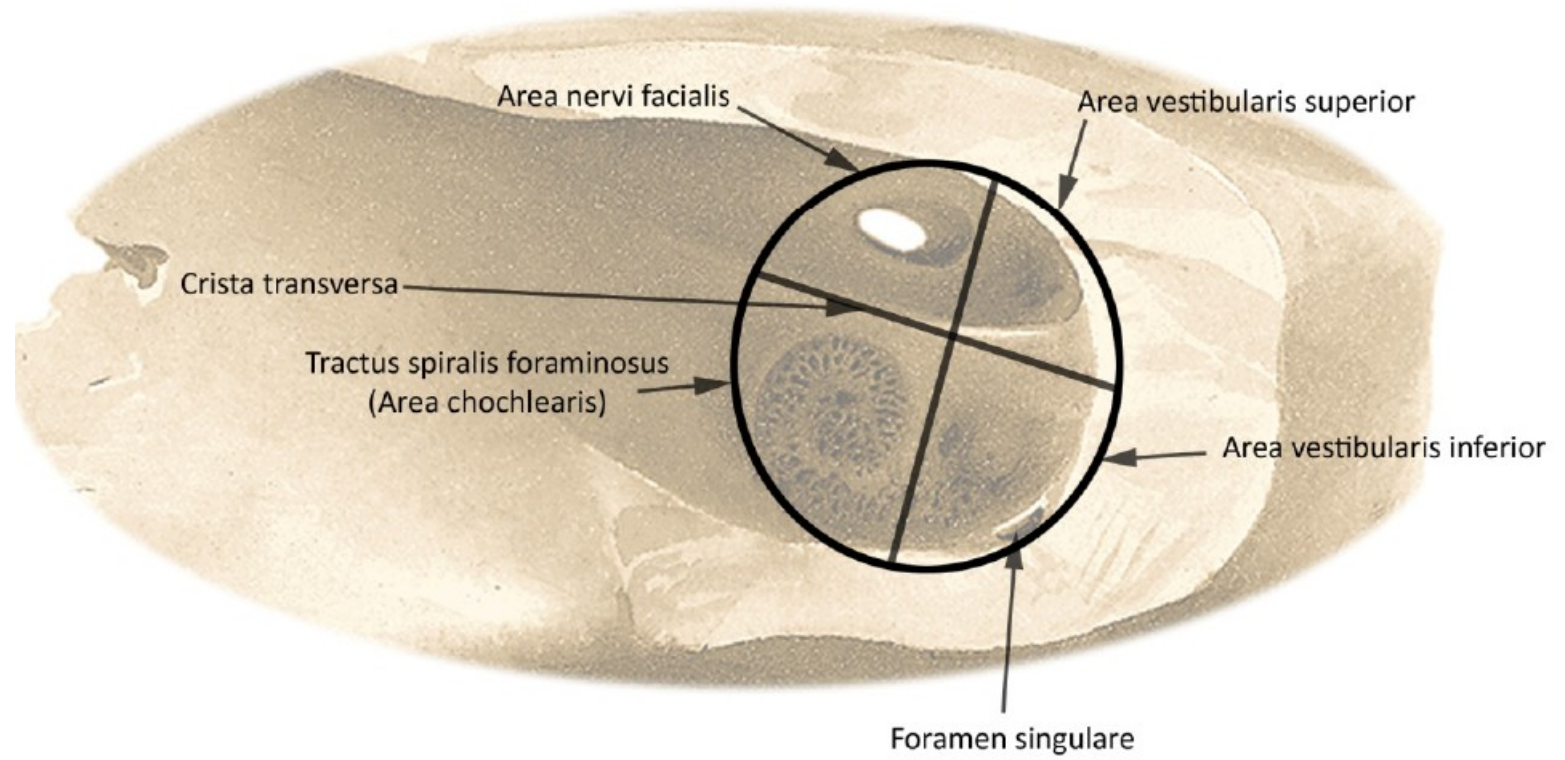
DIAGRAMS

SKULL BONES AND CAVITIES

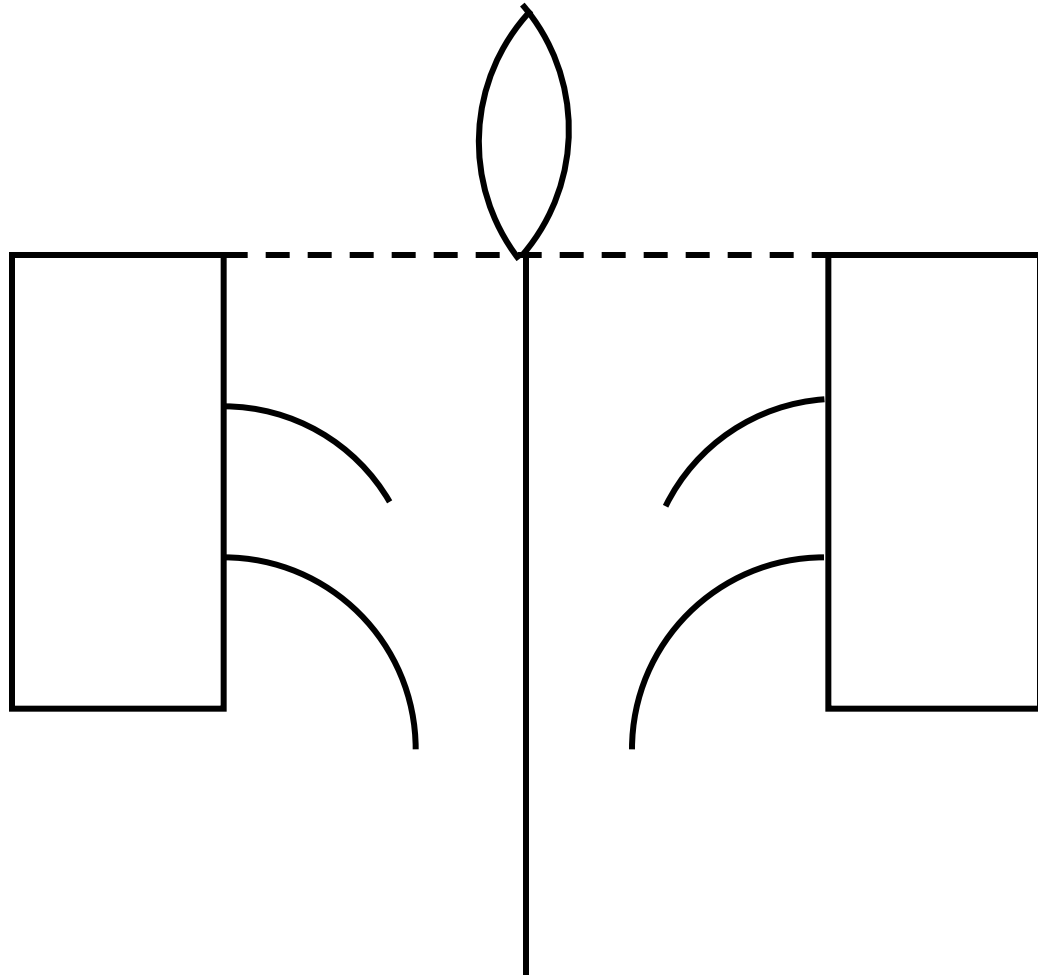
Canalis n. facialis inside the pyramis ossis temporalis Cranial view



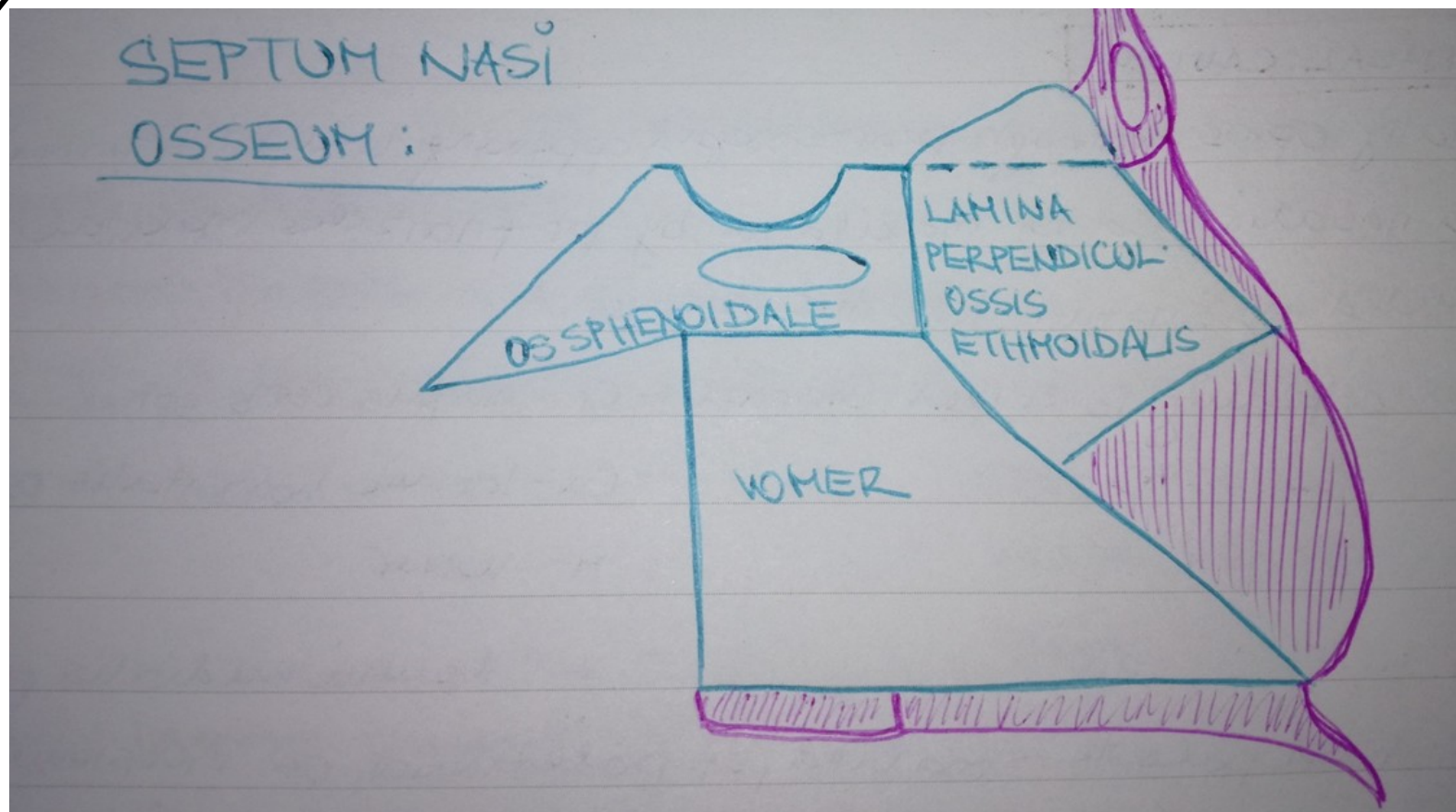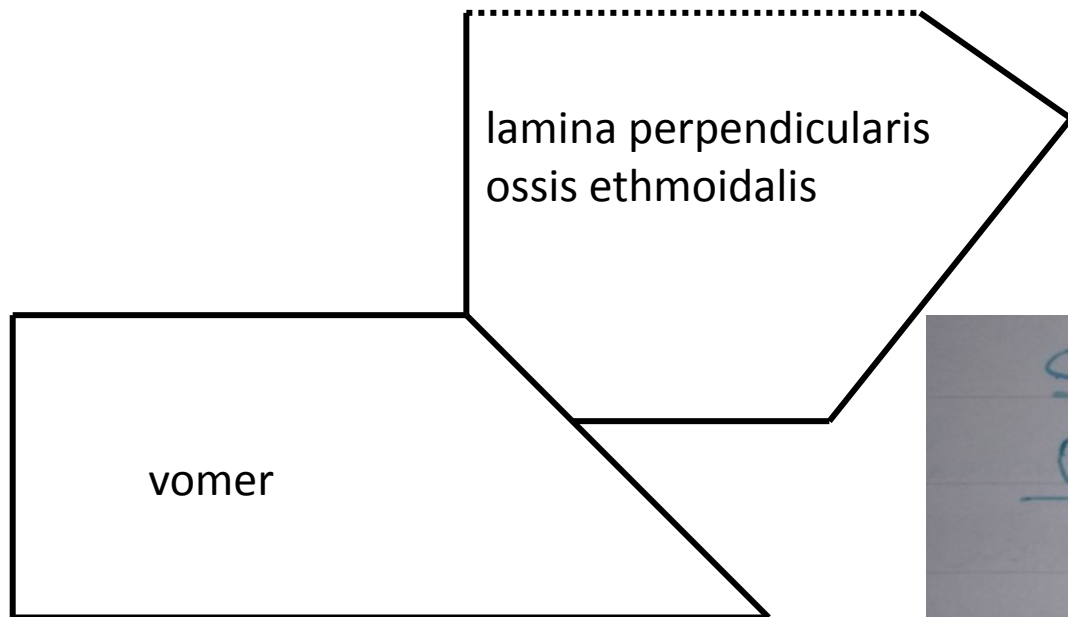
DIVISIONS OF FUNDUS MEATUS ACUSTICUS INTERNUS



Os ethmoidale

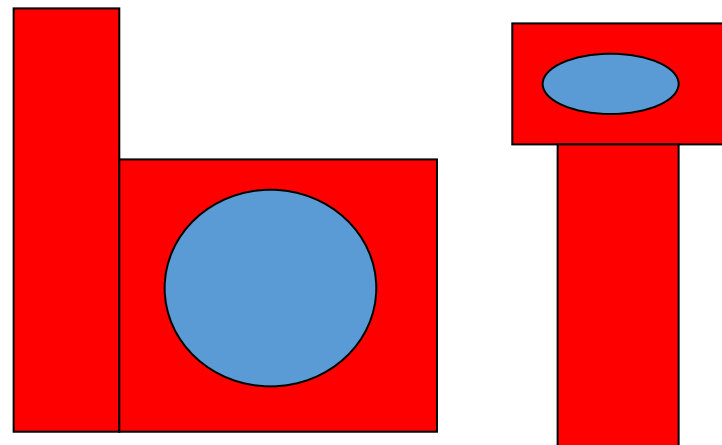


SEPTUM NASI OSSEUM

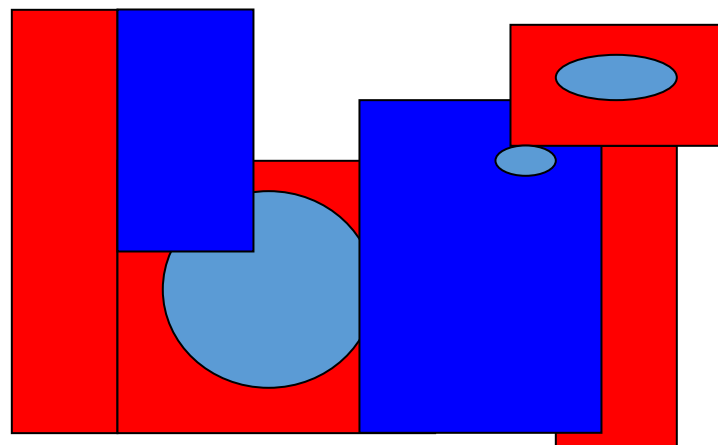


Laterální stěna dutiny nosní

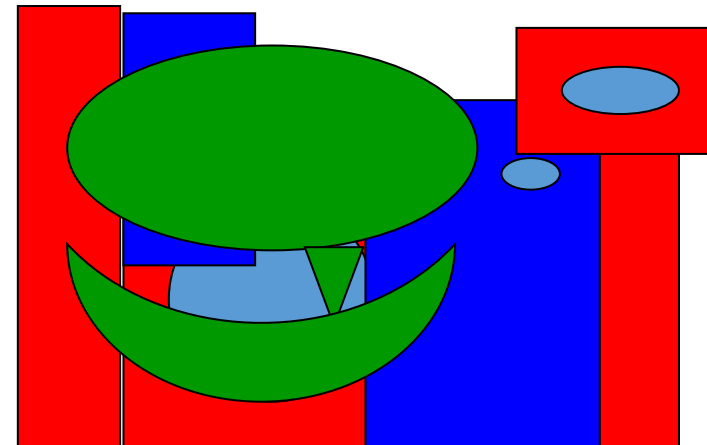
laterální stěna DN- zevní vrstva



laterální stěna DN- střední vrstva

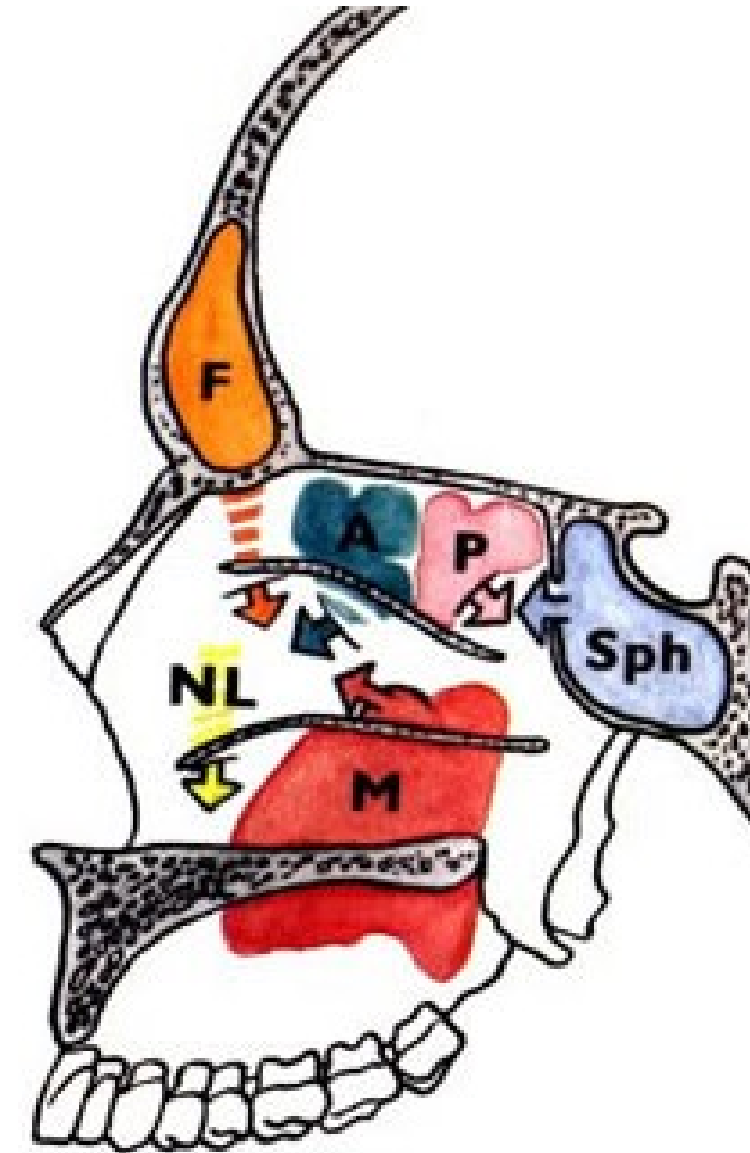


laterální stěna DN- vnitřní vrstva

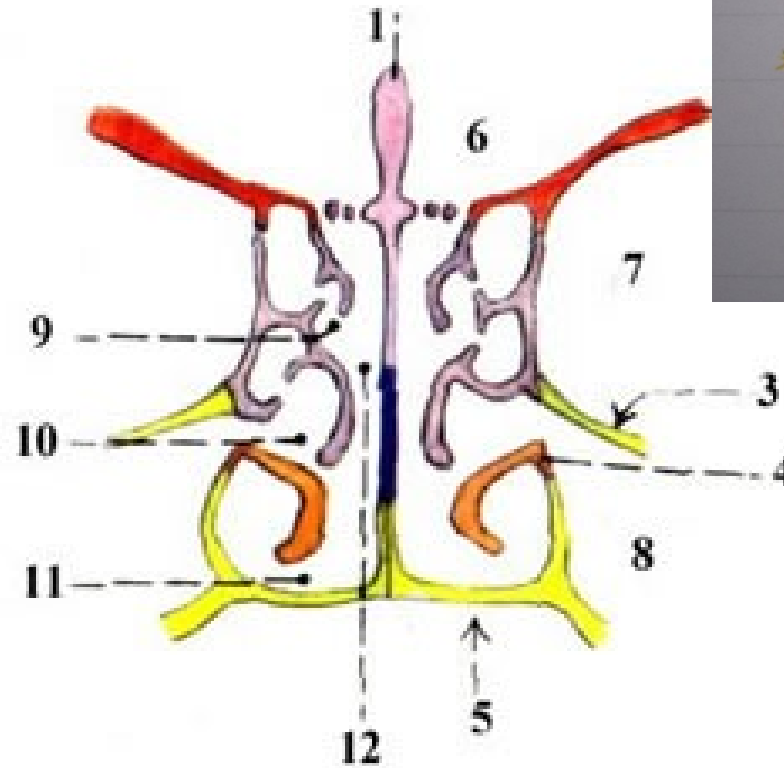
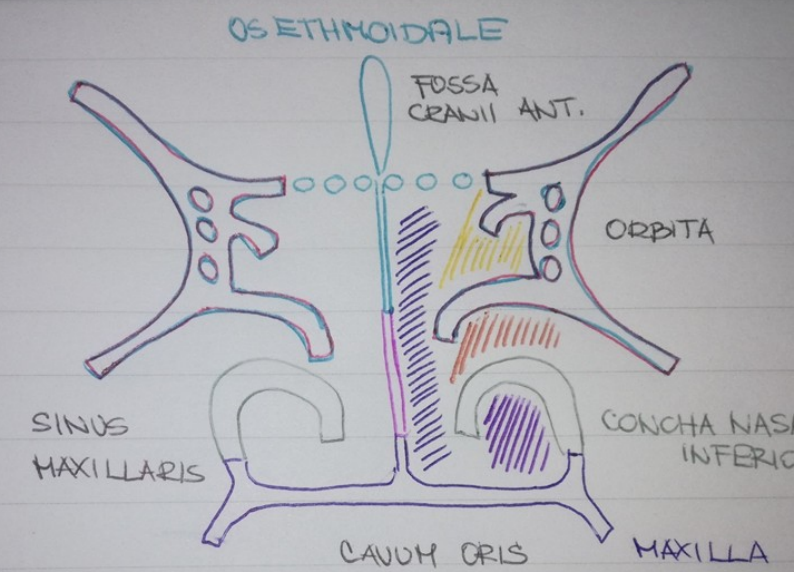


CAVUM NASI

MEATUS NASI SUPERIOR, MEDIUS, INFERIOR



CAVUM NASI:



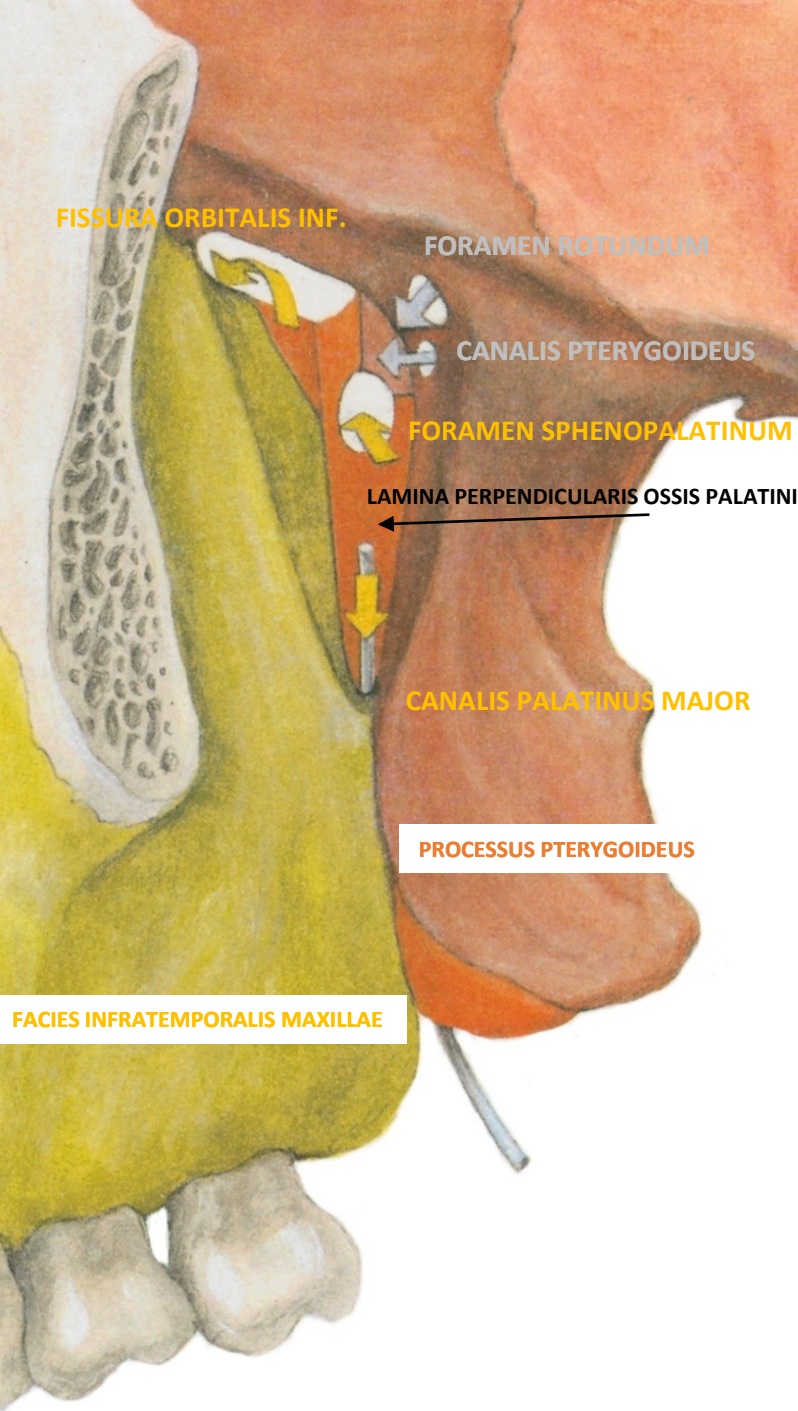
* MEATUS NASI SUPERIOR

* MEATUS NASI MEDIUS

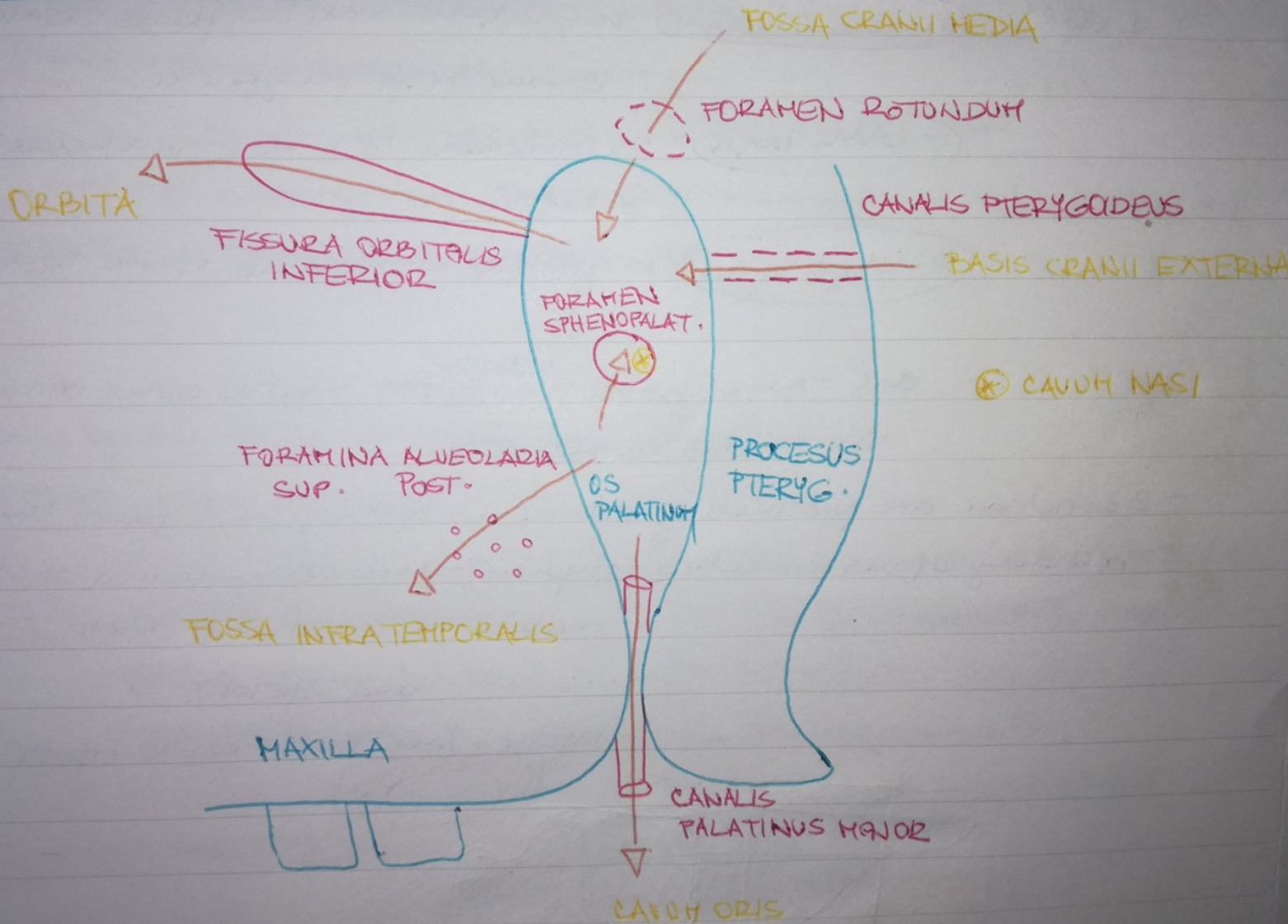
* MEATUS NASI INFERIOR

* MEATUS NASI COMMUNIS

FOSSA PTERYGOPALATINA



FOSSA PTERYGOPALATINA :



FOSSA PTERYGOPALATINA:

FOSSA CRANII MEDIA

FISSURA ORBITALIS
INT.

FOR. ROTUNDUM

ORBITA

CANALIS PTERYGOIDEUS

BASIS CRANII EXT.

TUBER
MAXILLAE

FORAMINA ALVEOLARIA
POSTERIORA
SUPER.

PROCESUS PTERYGOIDEUS

FOSSA

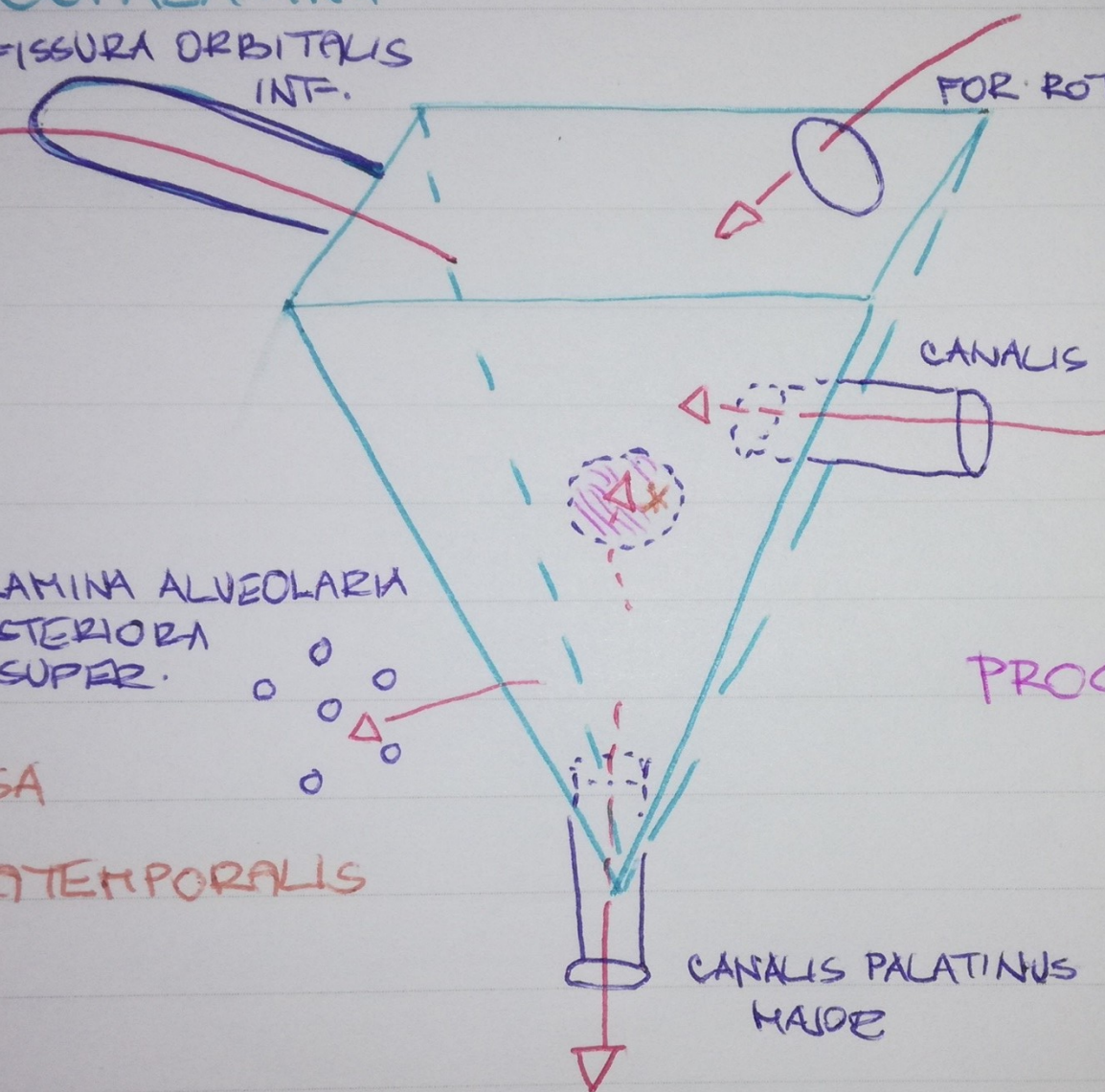
INFOTEMPORALIS

CANALIS PALATINUS
MAJOR

LAMINA PERPEND.
OSSIS
PALATINI

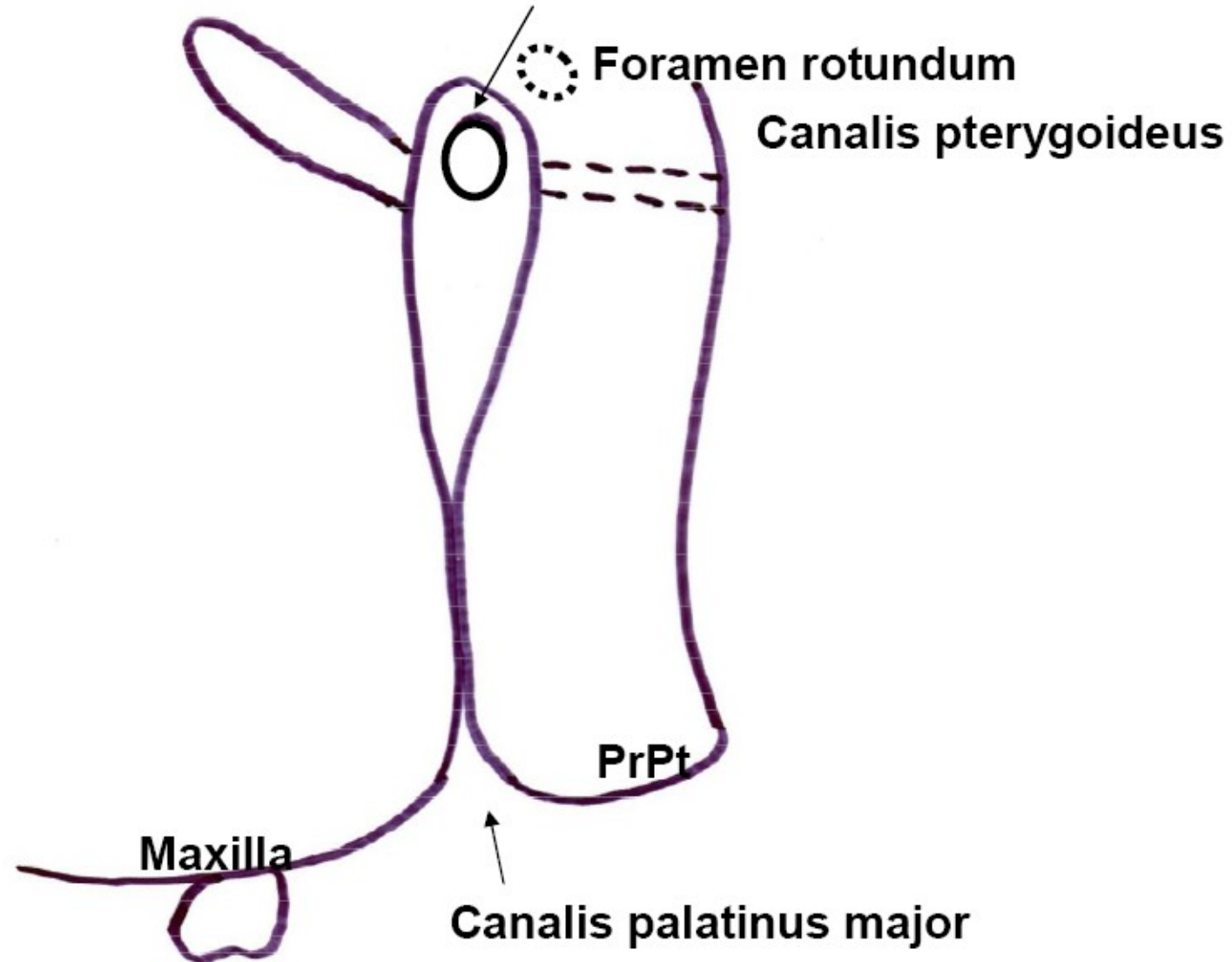
* CAVUM NASI

CAVUM ORIS

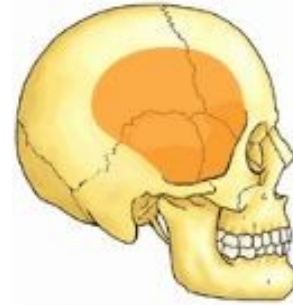


Pohled na fossa pterygopalatina z boku

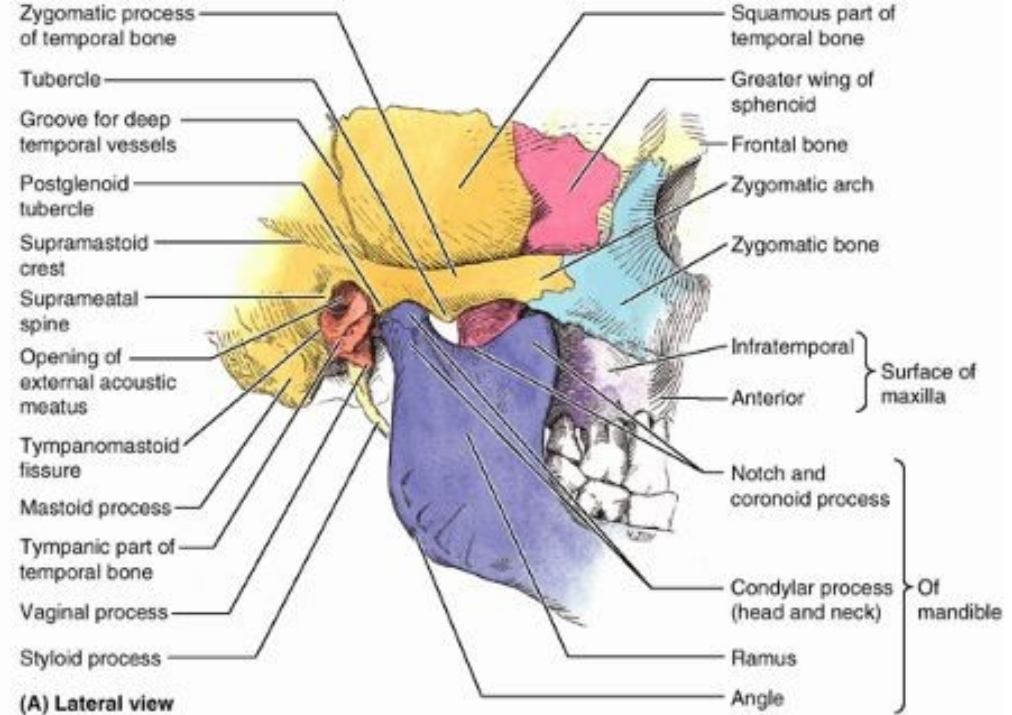
Fissura orbitalis inferior Foramen sphenopalatinum



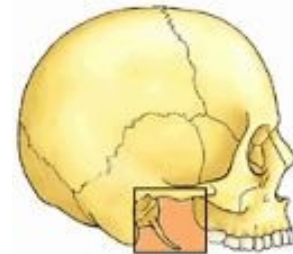
FOSSA TEMPORALIS



Temporal fossa



FOSSA INFRATEMPORALIS



Infratemporal fossa

