

**SKELETON OF THE LOWER
EXTREMITY**
(ossa membri inferioris)

SKELETON OF THE LOWER EXTREMITY ***(ossa membri inferioris)***

- Organ of support and locomotion
- In comparison with the UE– more robust bones
- Very limited mobility (joints)

Skeleton of pelvic girdle

hip bone/pelvic bone– **os coxae**
(**os ilium, os ischii, os pubis**)

Skeleton of free extremity

femur– **femur**

knee-cap – **patella**

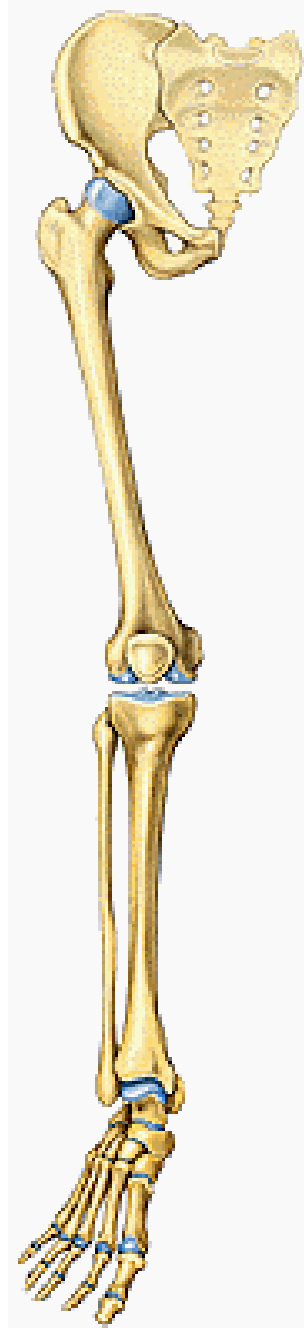
Shin bone– **tibia**

fibula– **fibula**

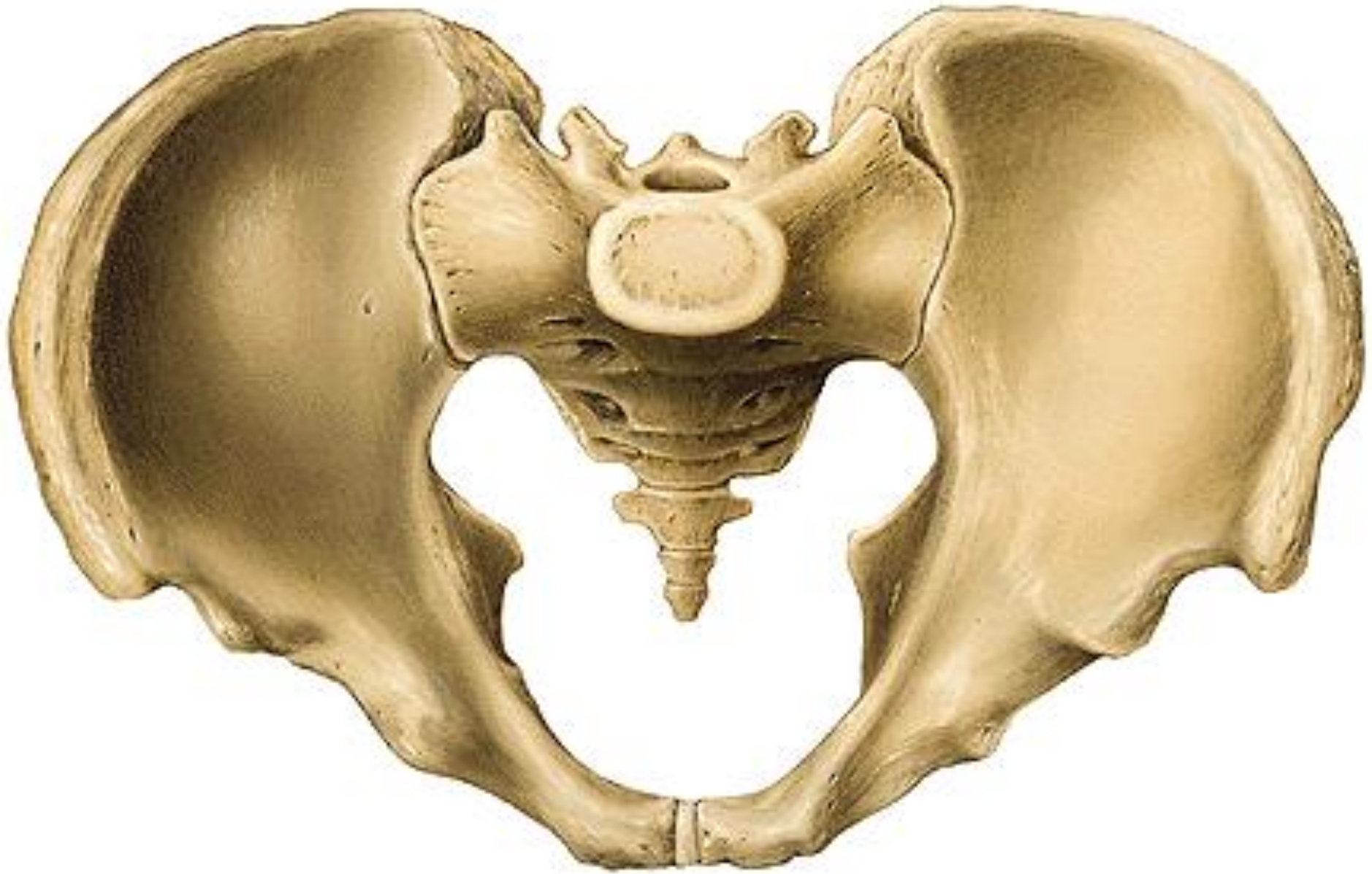Tarsal bones– **ossa tarsi**

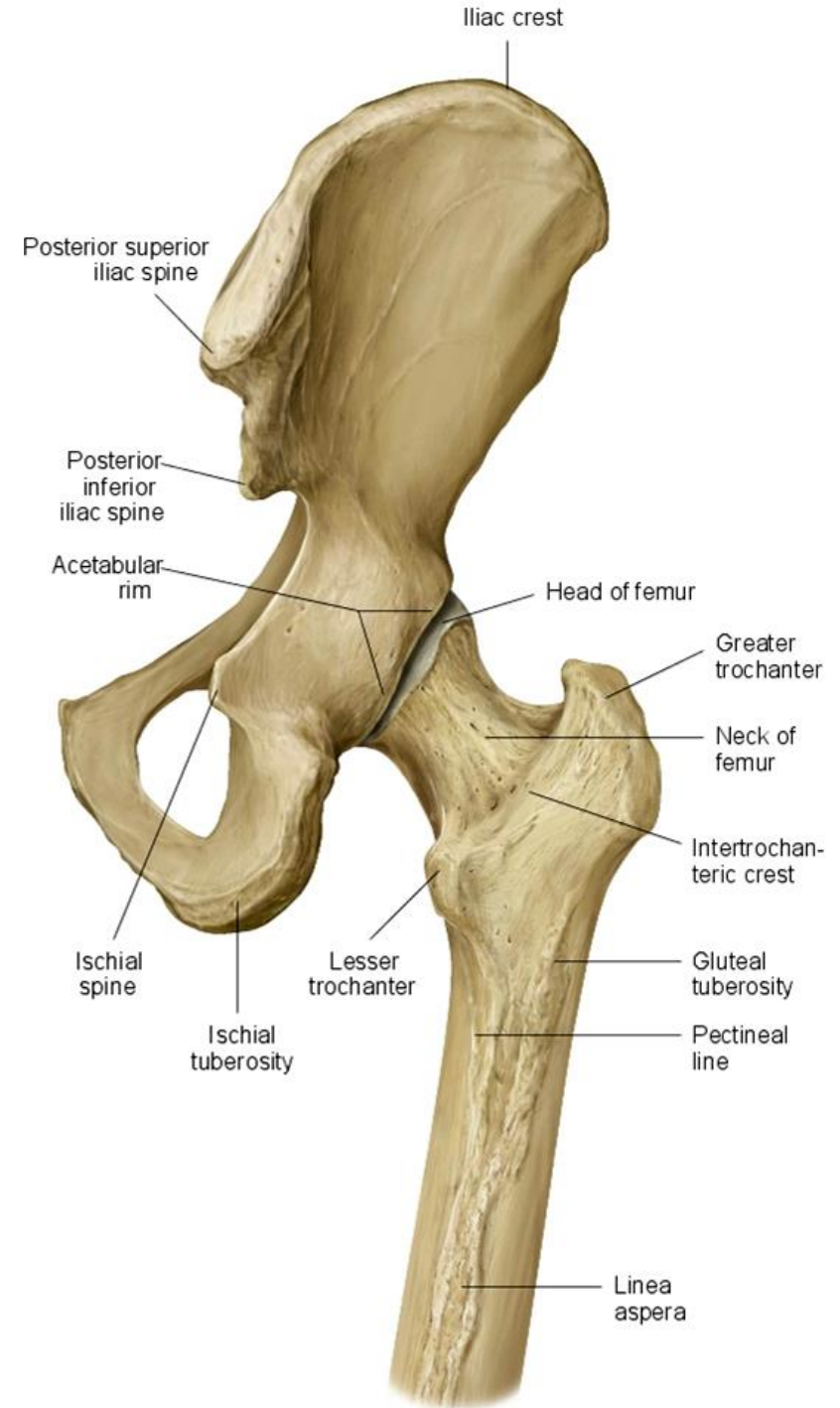
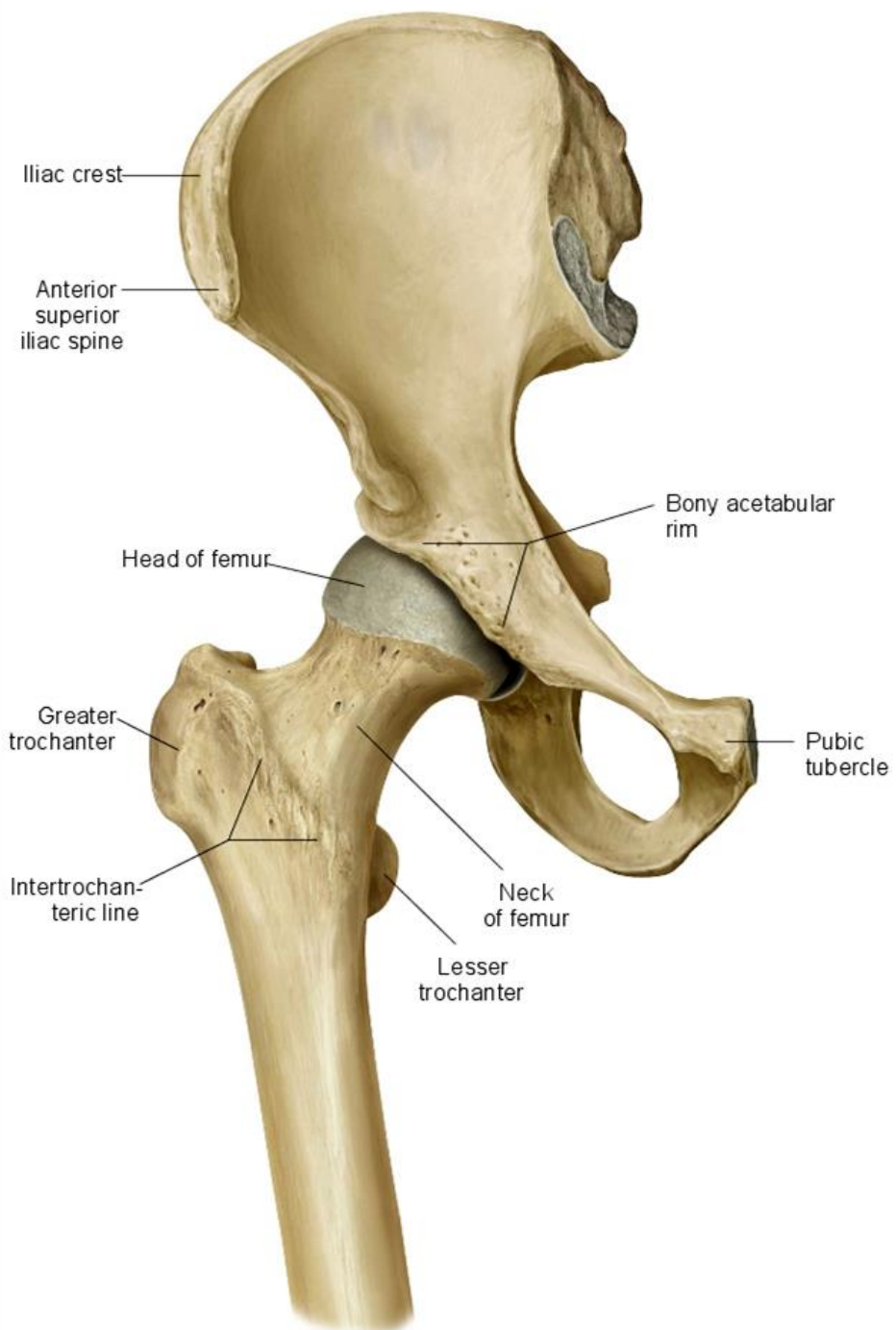
Metatarsal bones– **ossa metatarsi**

Phalanges of toes (**ossa digitorum pedis – phalanges**)



Cingulum membri inferioris

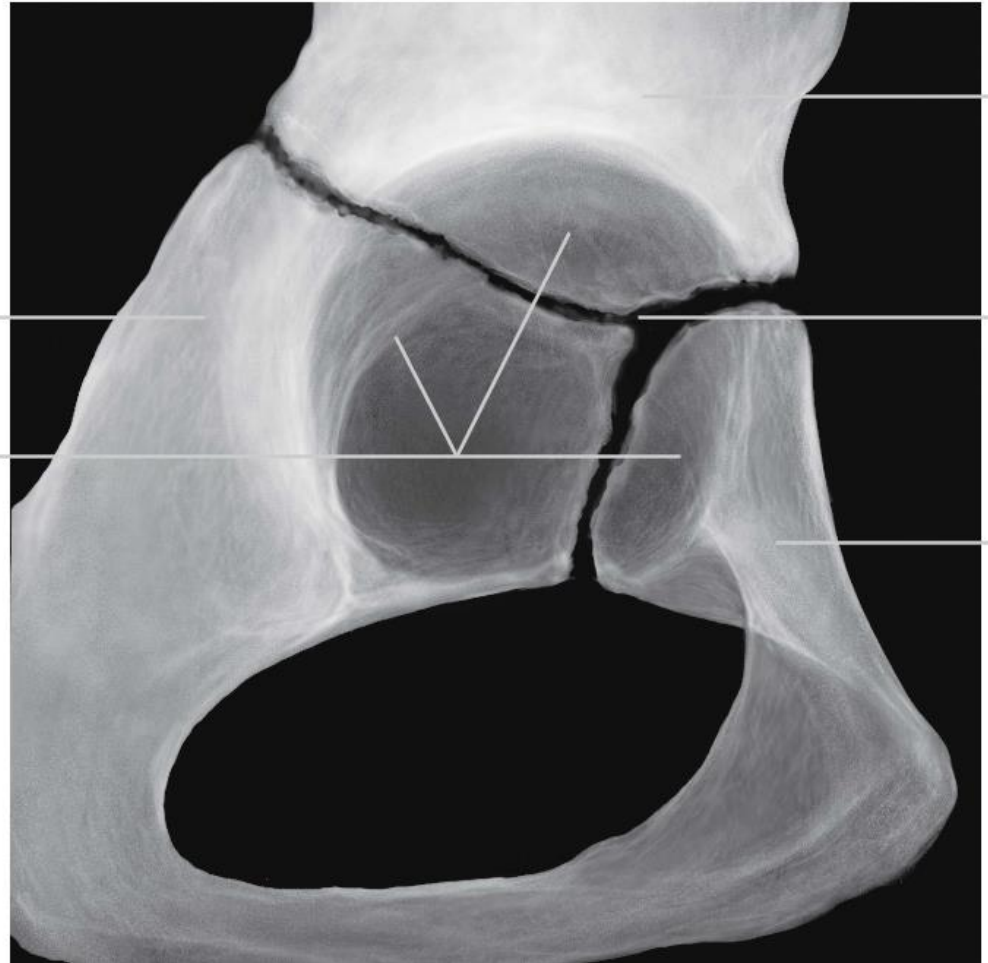
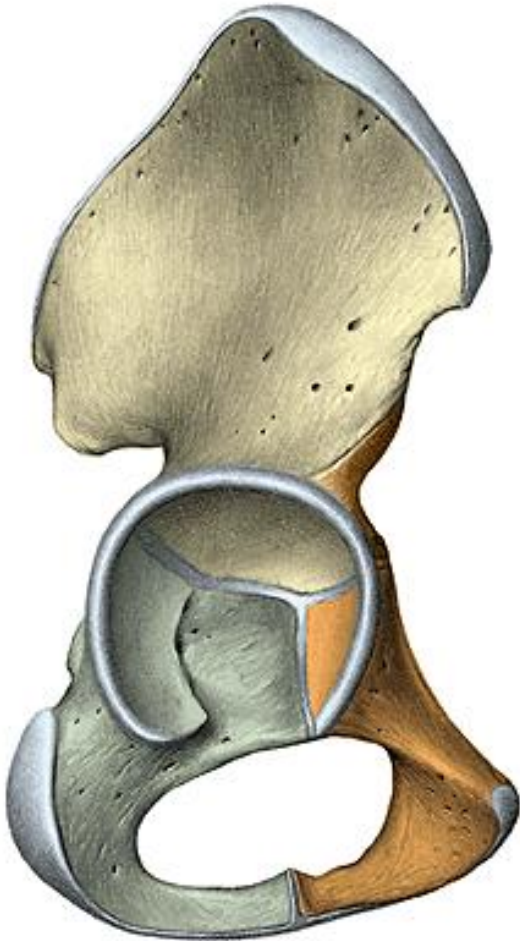




Os coxae (hip bone)

os ilium, os pubis, os ischii

- Flat bone- it is formed by the fusion of three originally separate bones at the end of teenage years



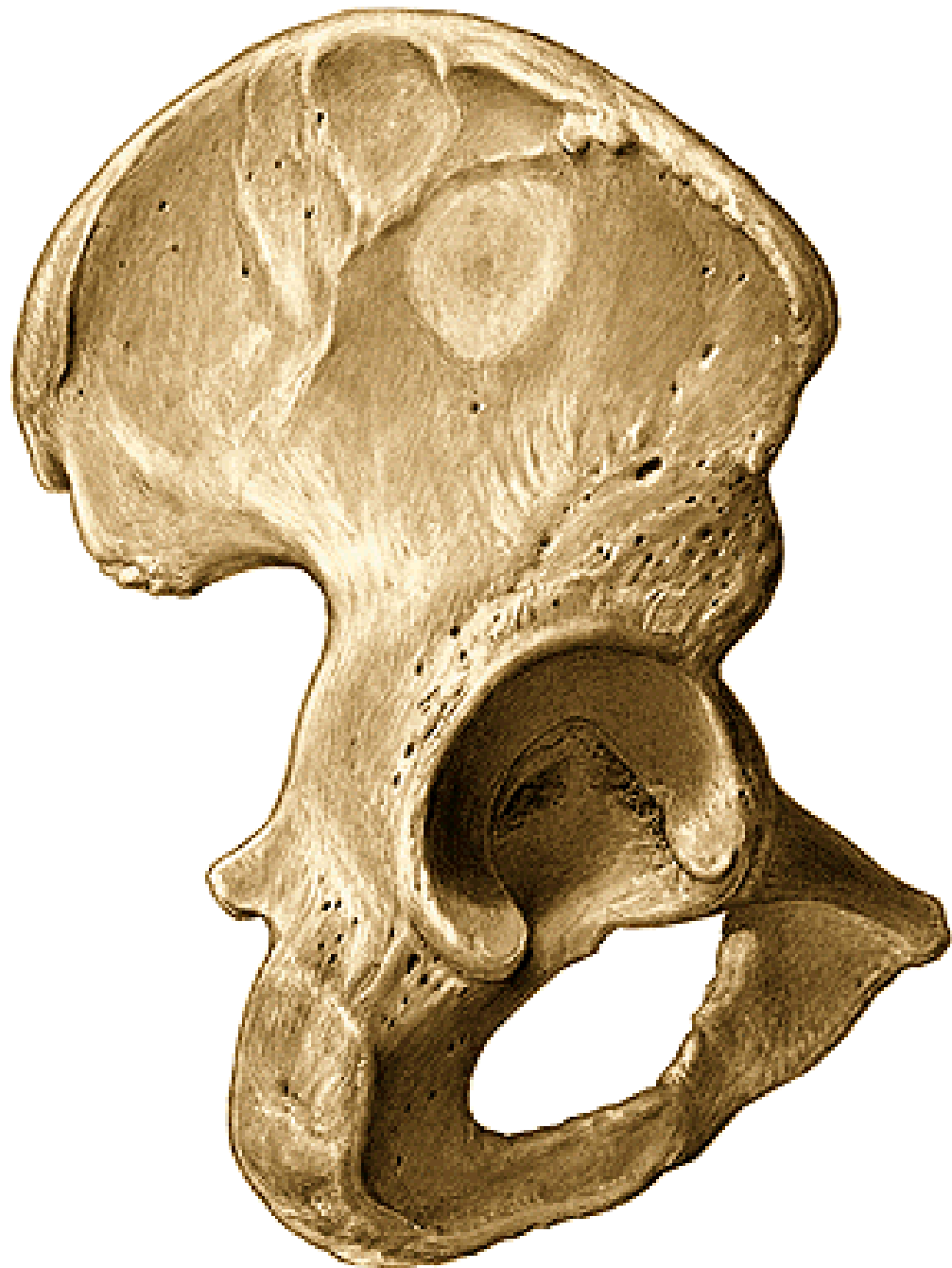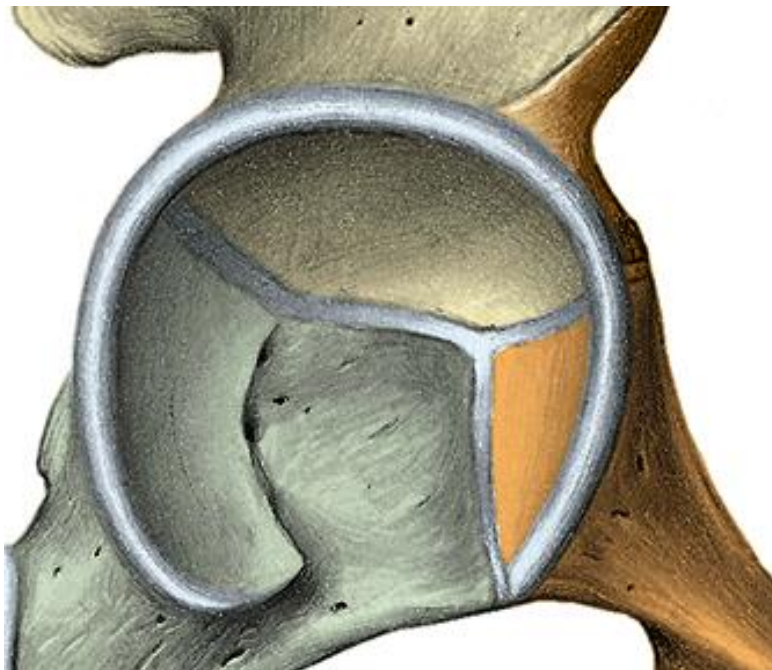
acetabulum

facies lunata

fossa acetabuli

incisura acetabuli

foramen obturatum

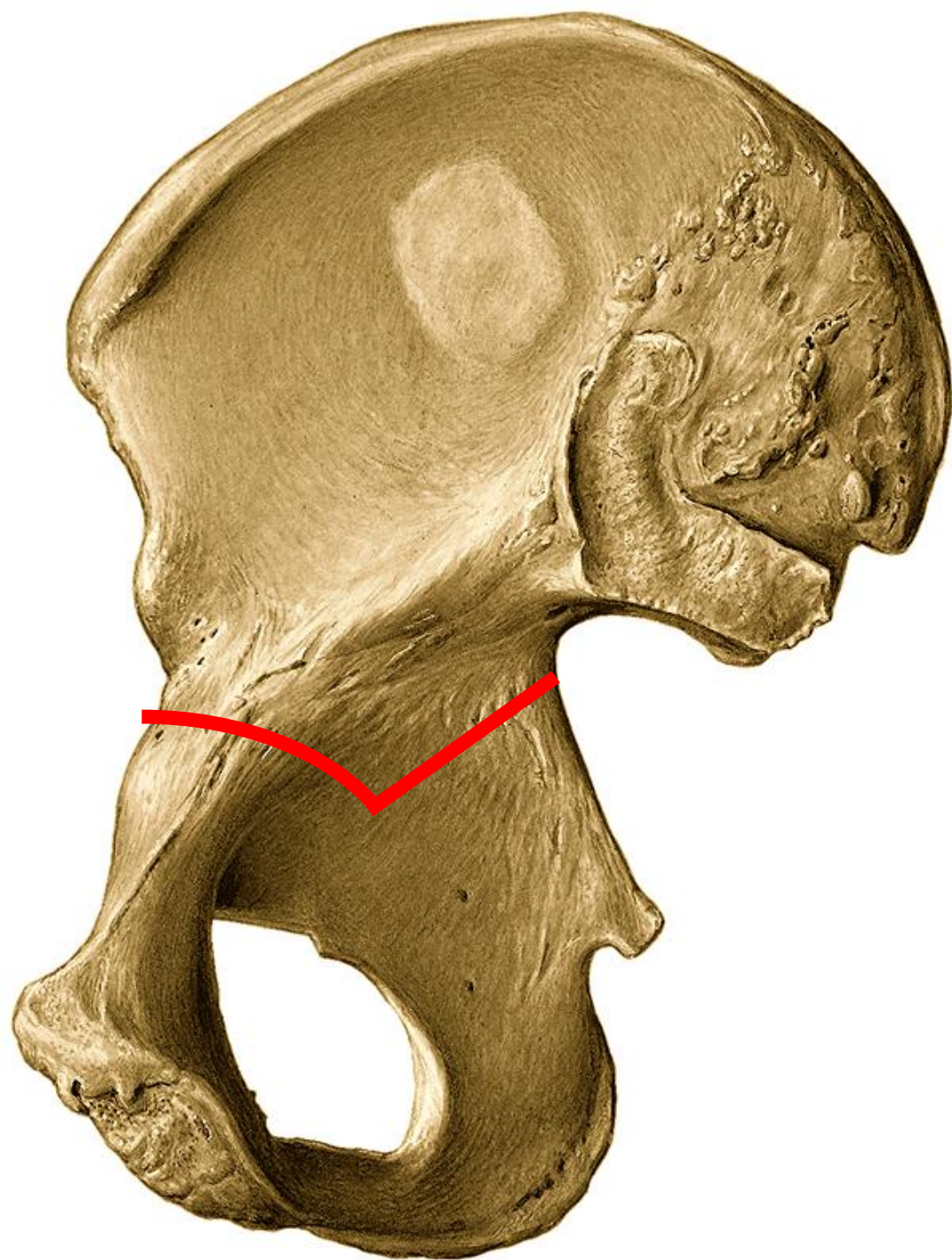


Iliac bone– os ilium

corpus

ala

- medial surface
- fossa iliaca
- facies auricularis
- tuberositas iliaca
- linea arcuata

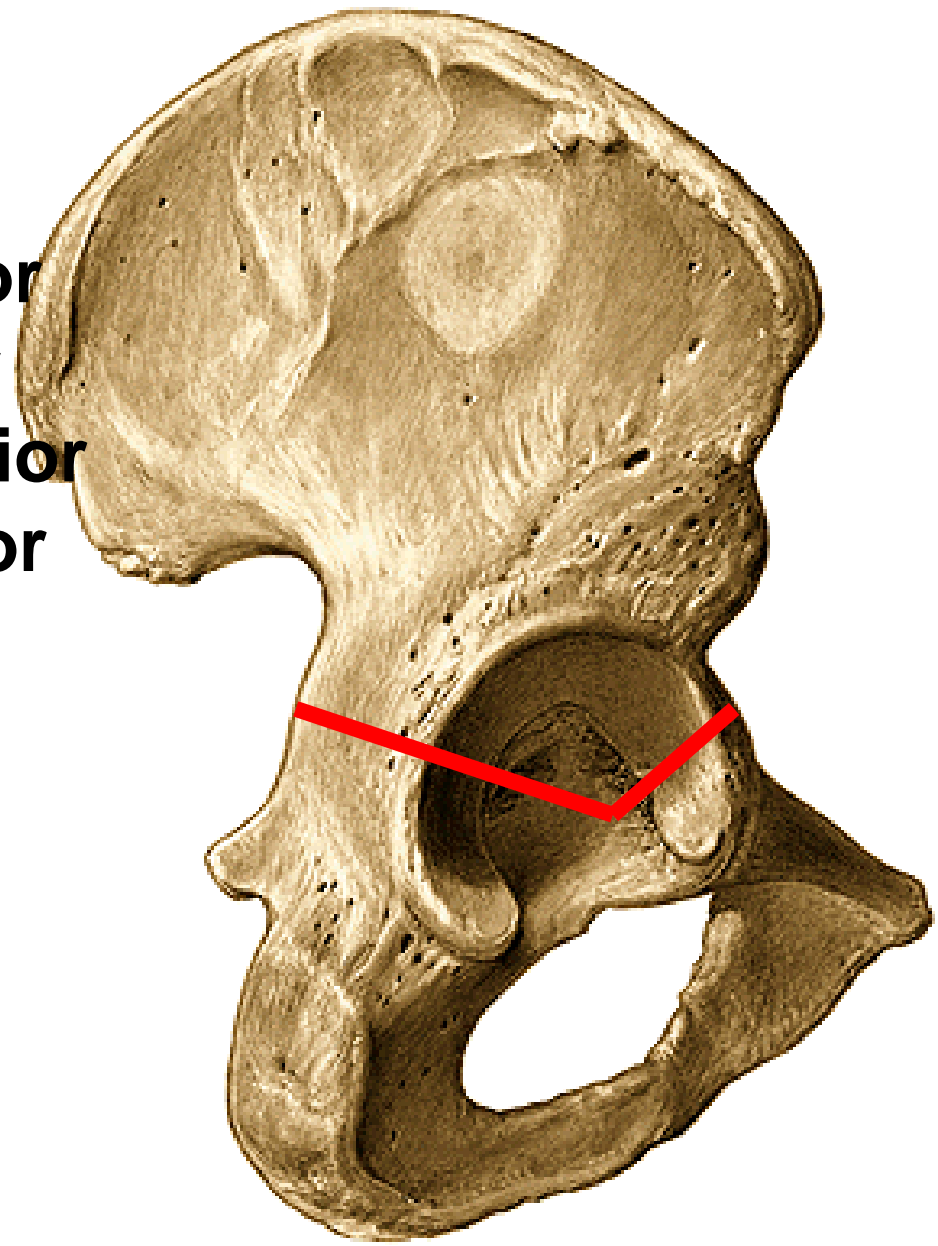


crista iliaca

spina iliaca anterior superior
spina iliaca anterior inferior
spina iliaca posterior superior
spina iliaca posterior inferior

• lateral surface

linea glutea posterior
linea glutea anterior
linea glutea inferior



Sciatic bone– OS ischii

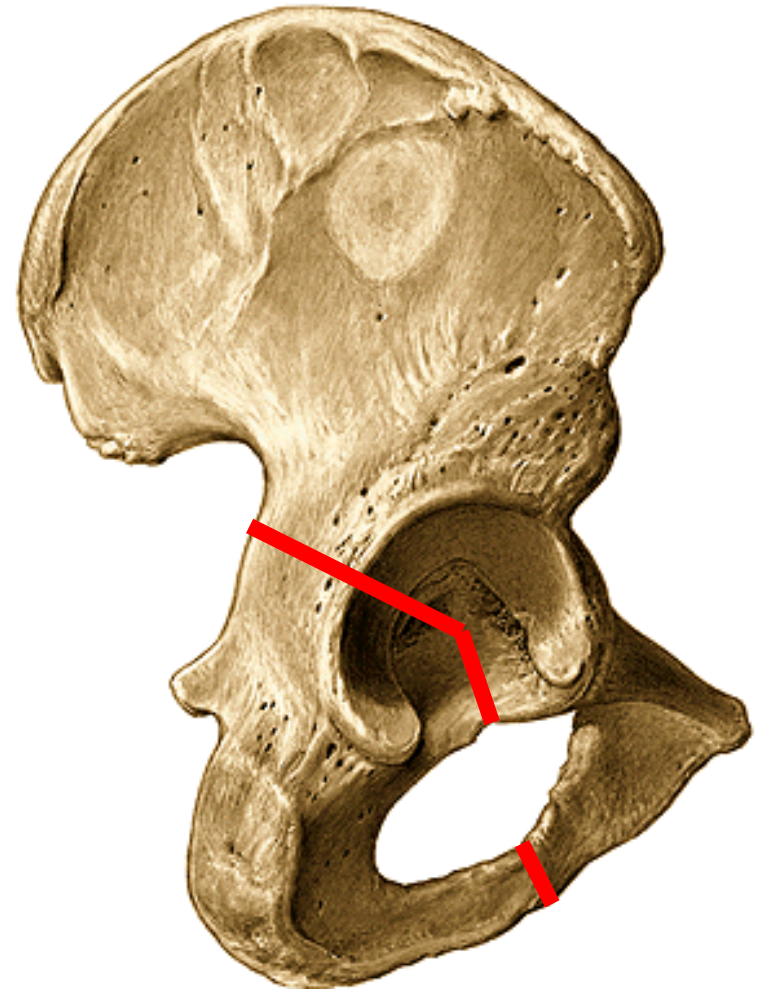
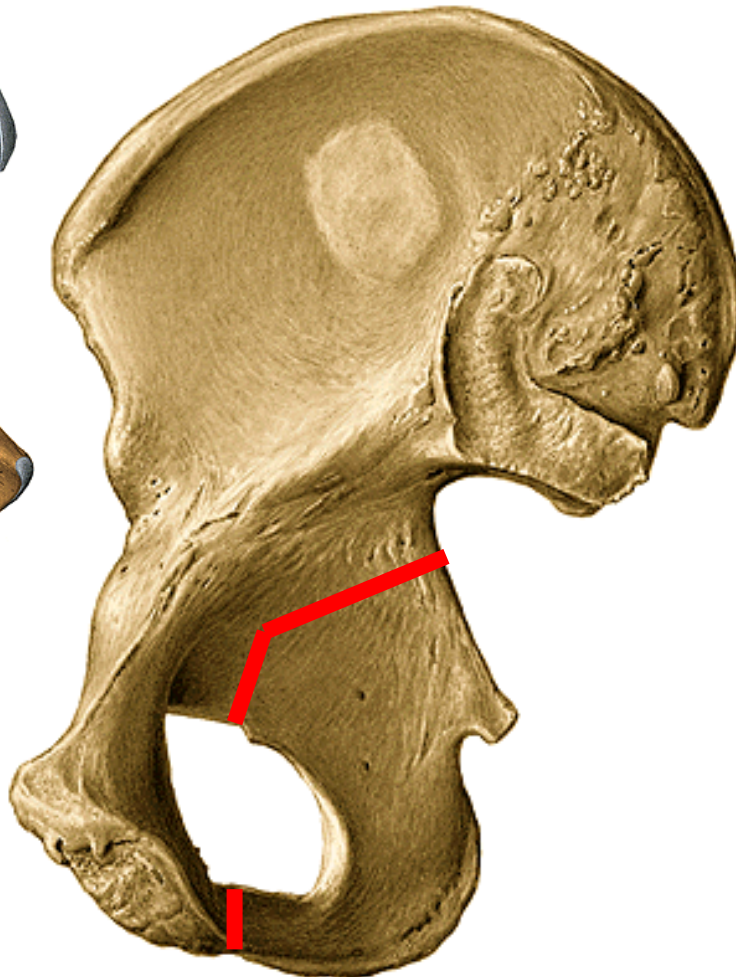
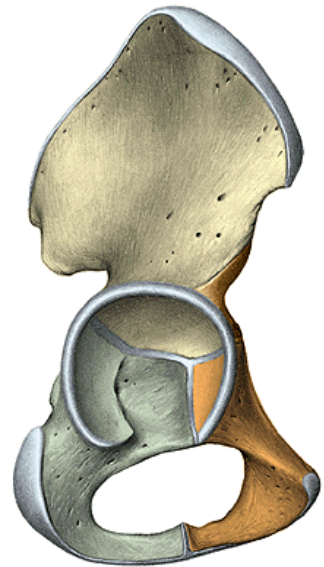
corpus
ramus

tuber ischiadicum

spina ischiadica

incisura ischiadica major

incisura ischiadica minor

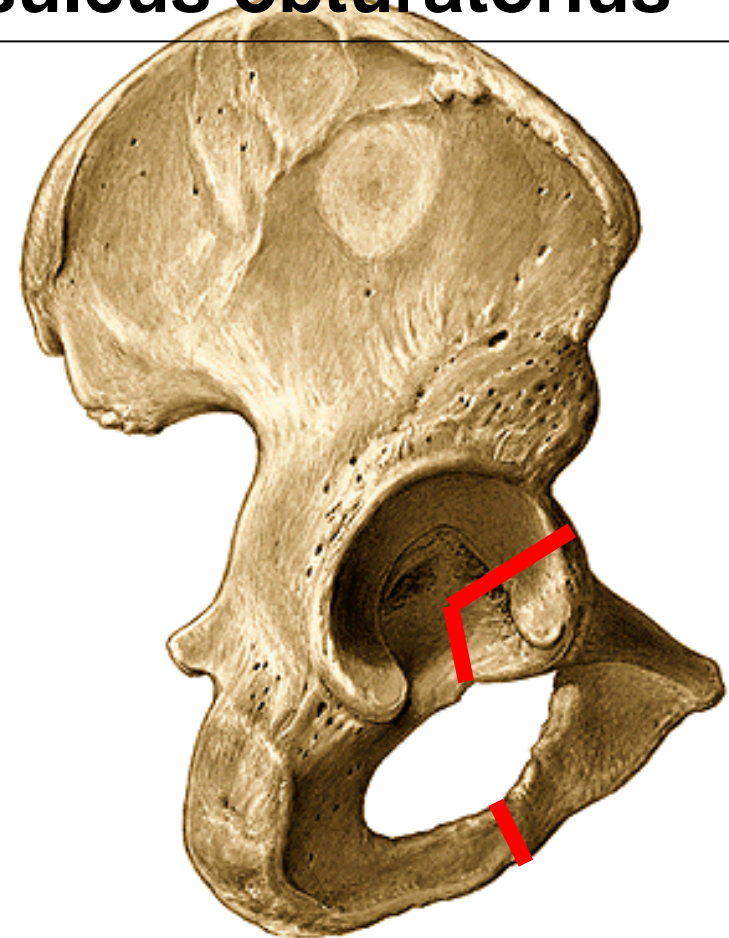
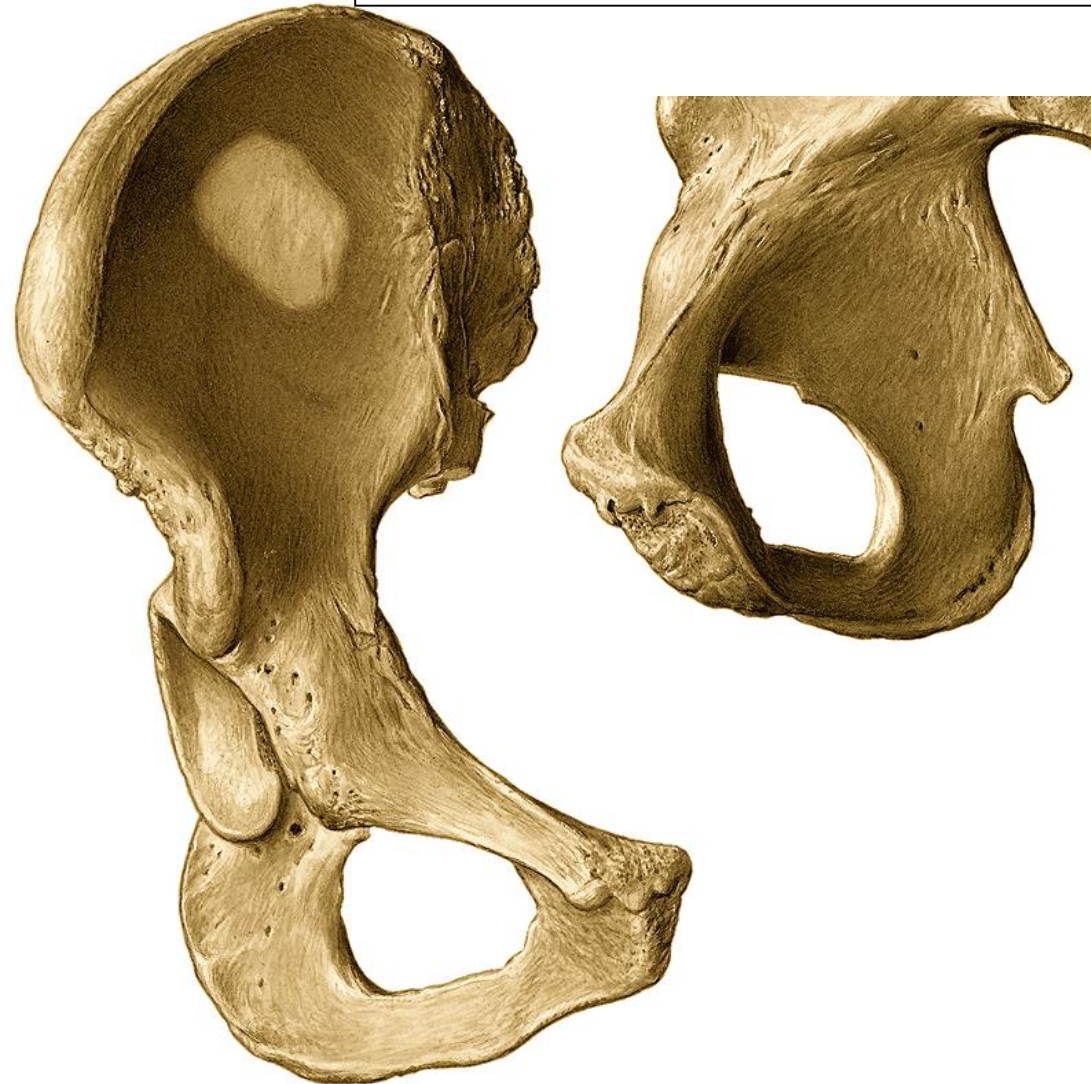

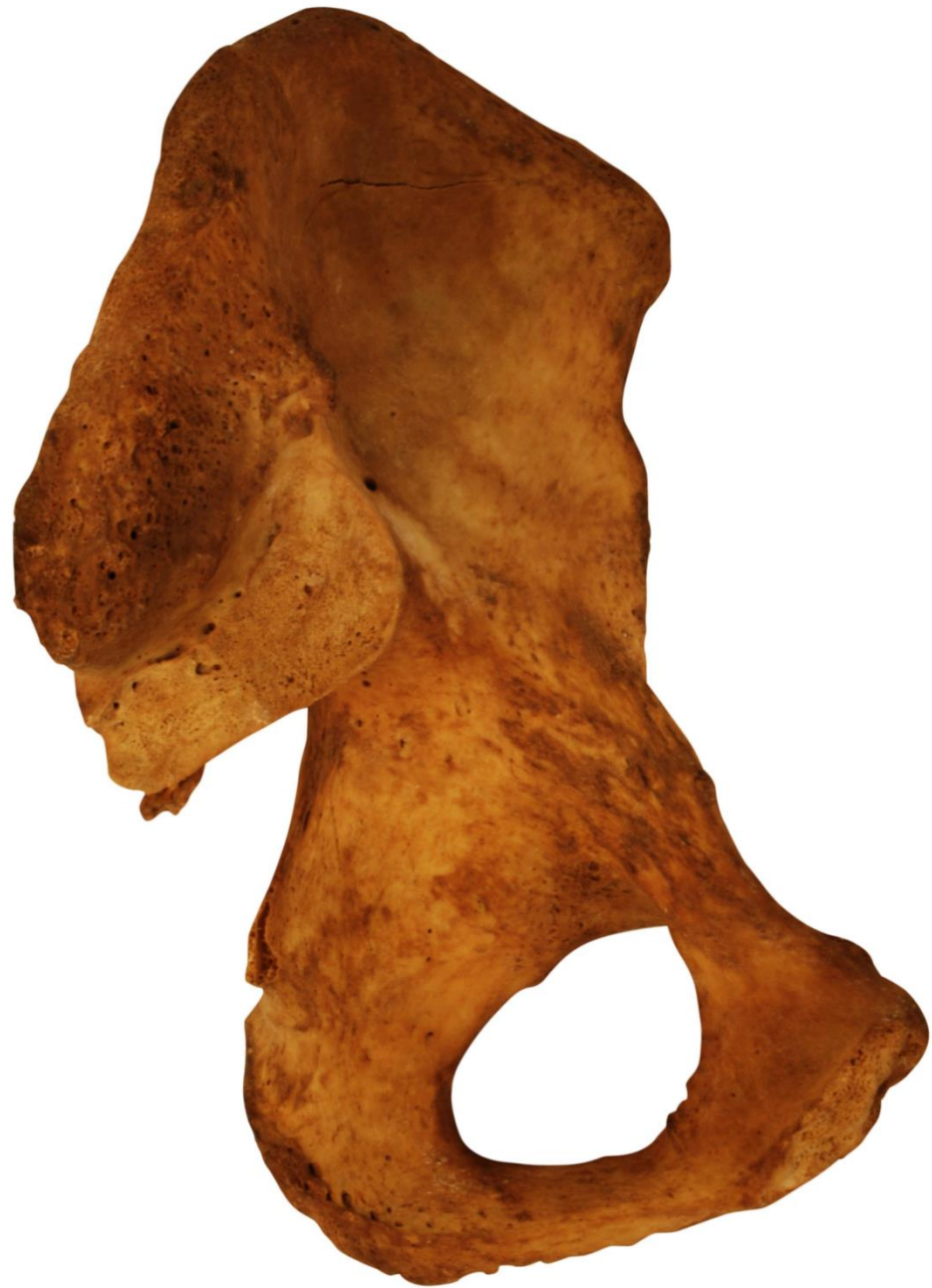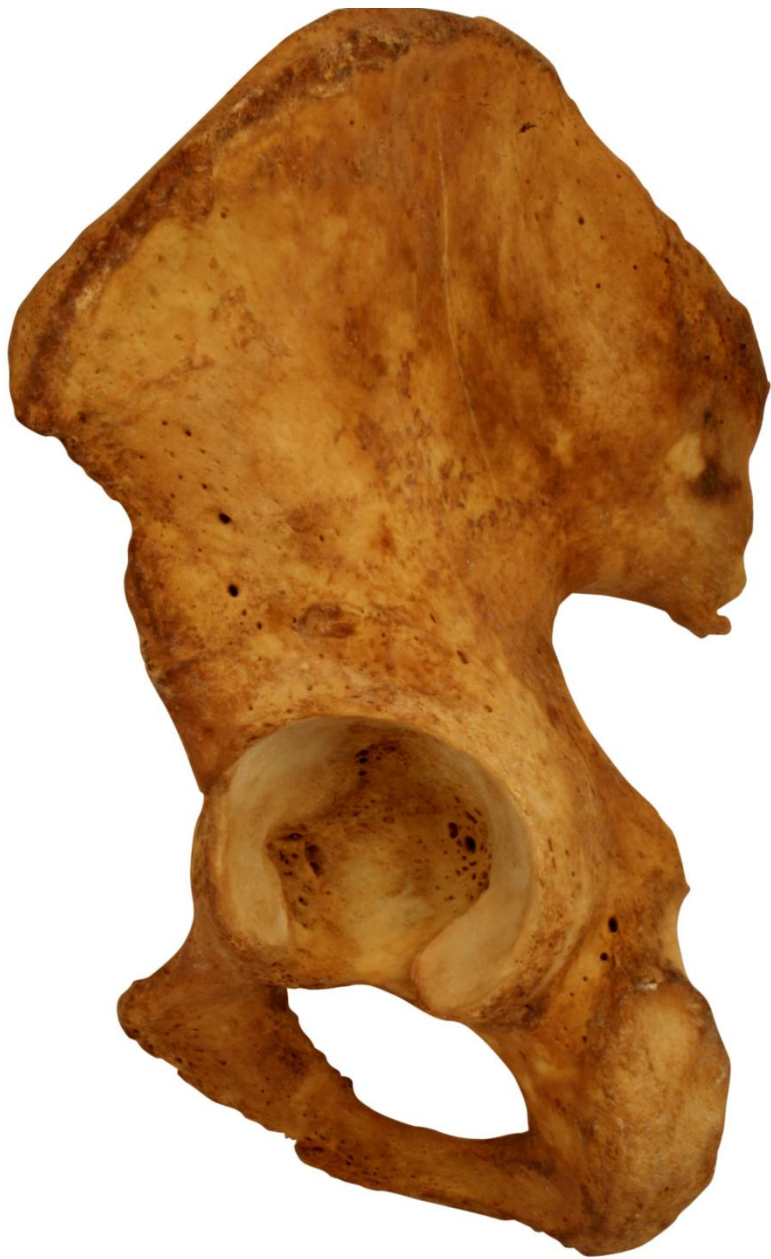Pubic bone– OS pubis

corpus

ramus inferior
facies symphysealis
crista phallica

ramus superior
eminentia iliopubica
pecten ossis pubis
tuberculum pubicum
sulcus obturatorius





Femur – femur

Proximal end:

caput femoris

fovea capitis femoris

collum femoris

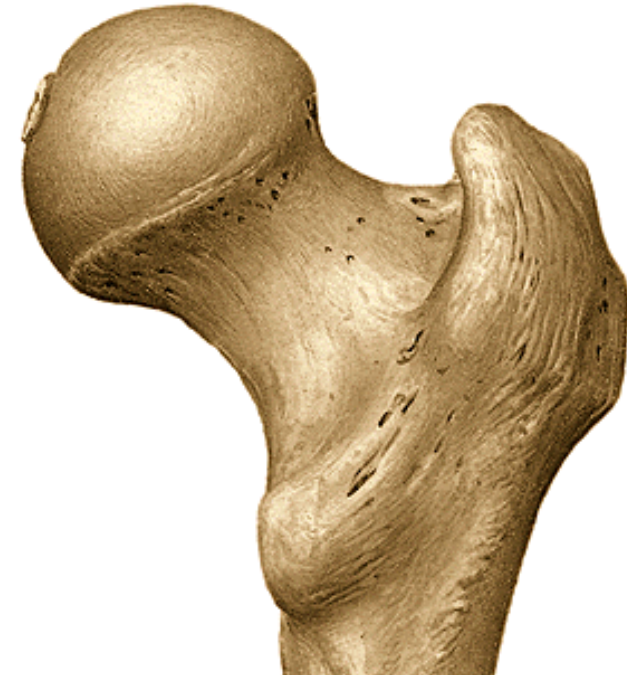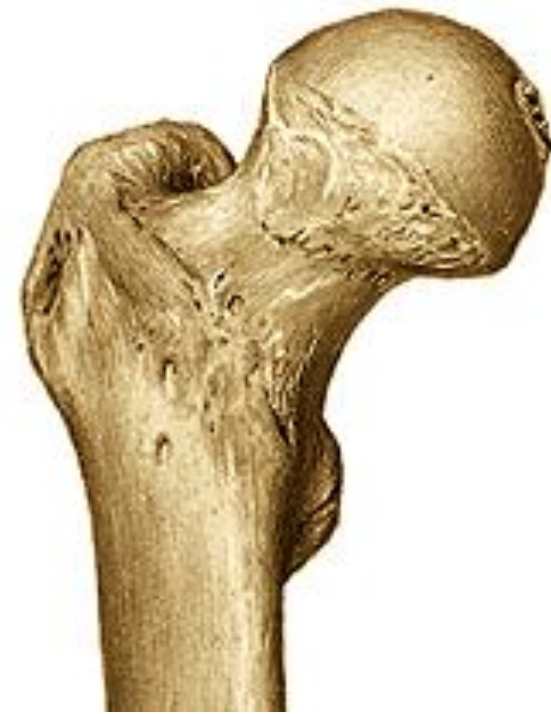trochanter major

trochanter minor

linea intertrochanterica

crista intertrochanterica

fossa trochanterica

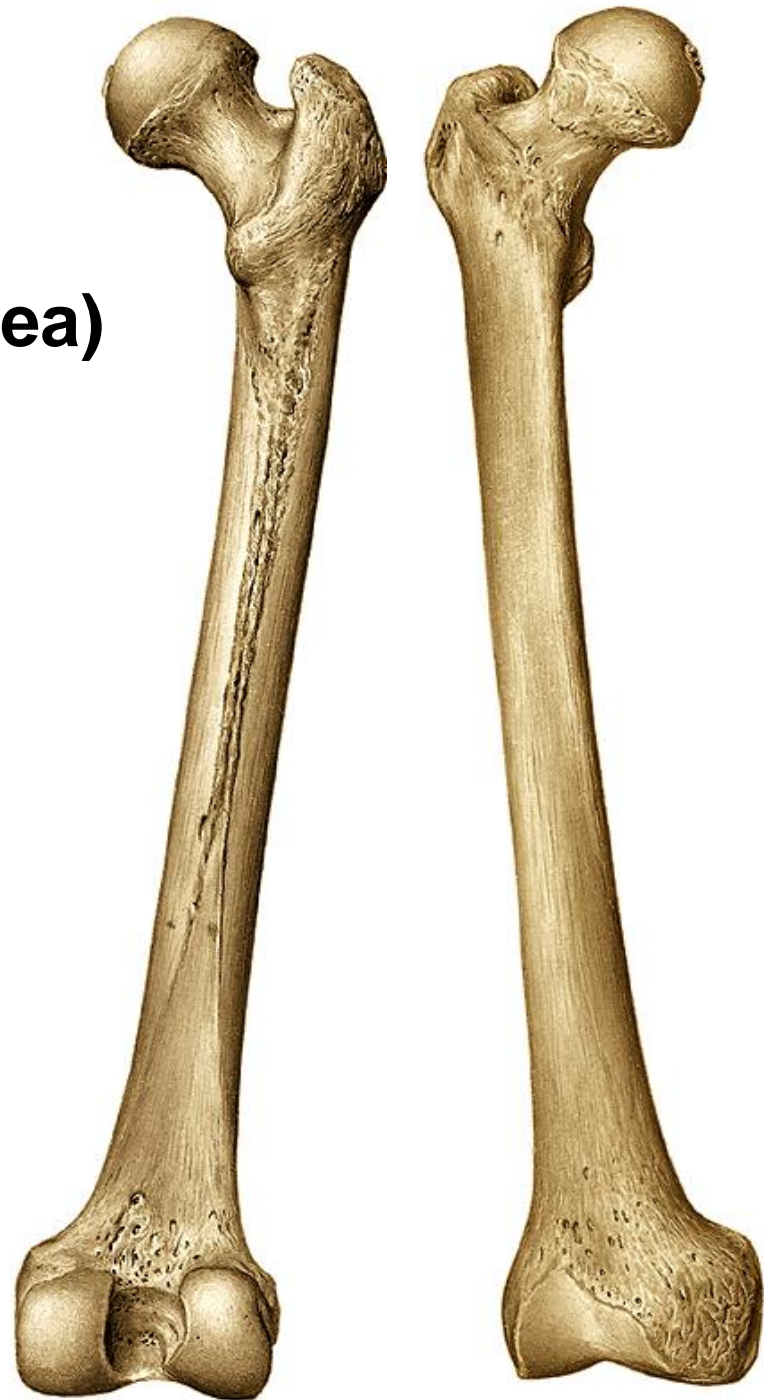
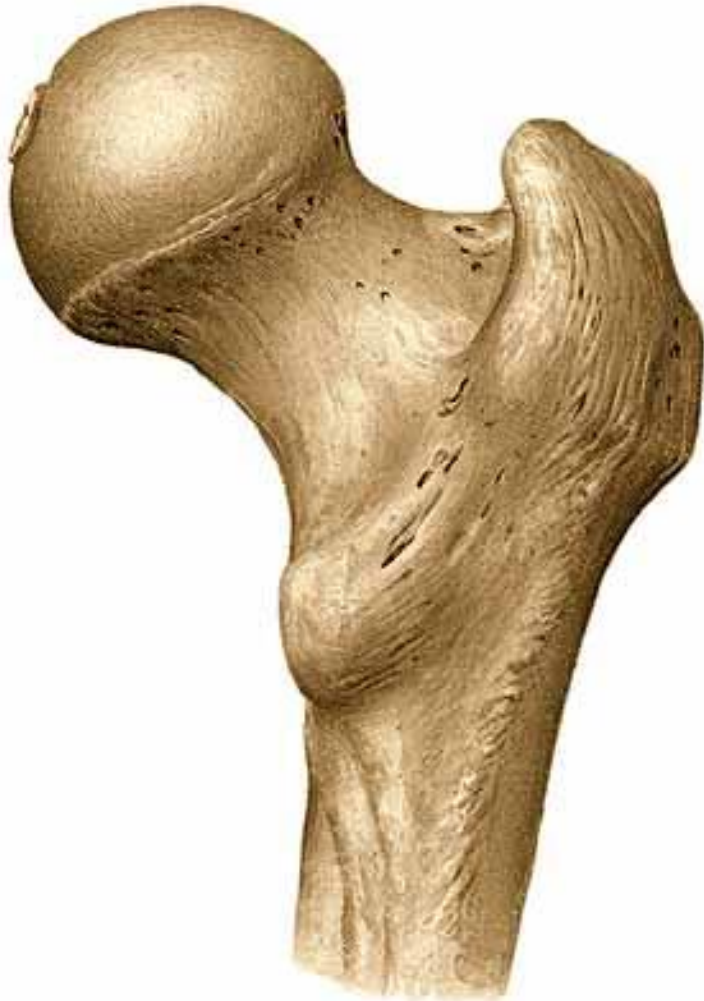
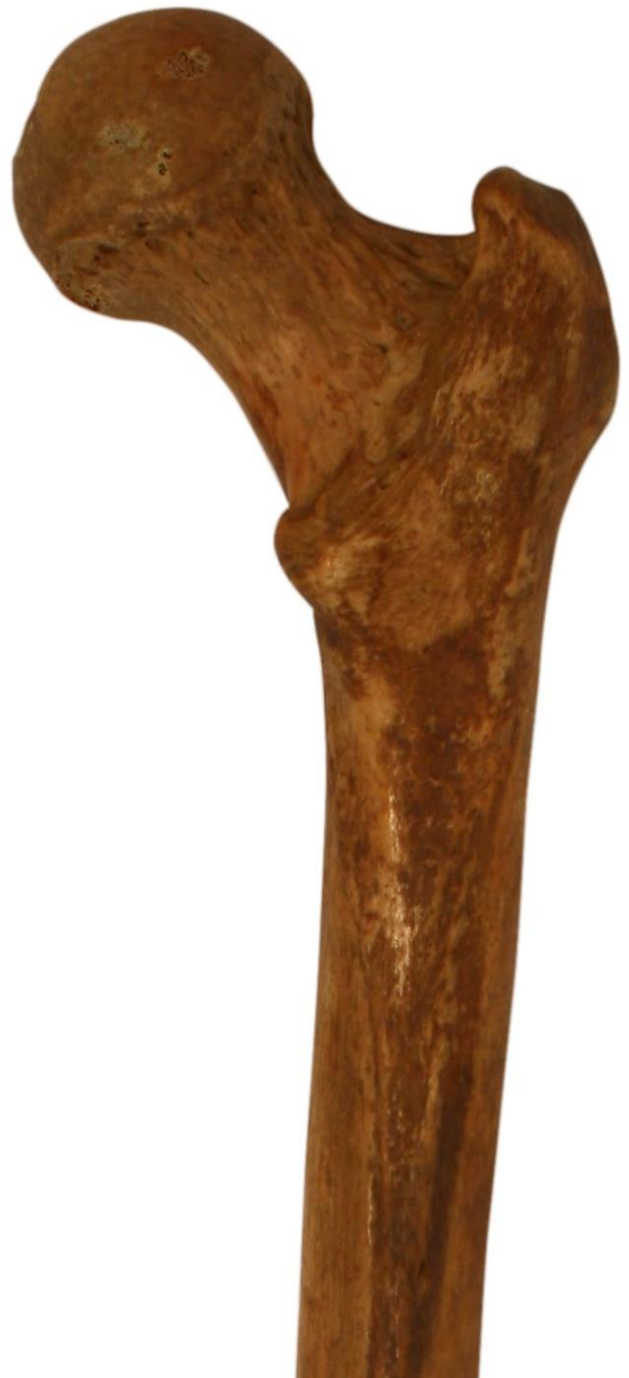corpus femoris

linea aspera

labium mediale

labium laterale (tuberositas glutea)





Distal end:

condylus medialis

condylus lateralis

epicondylus medialis

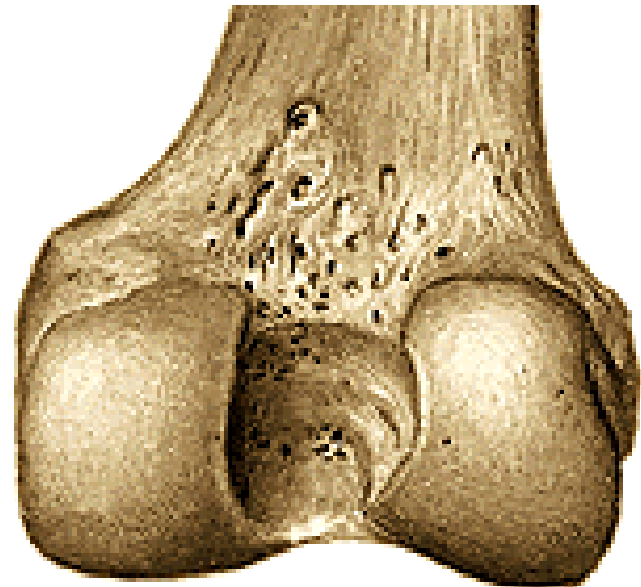
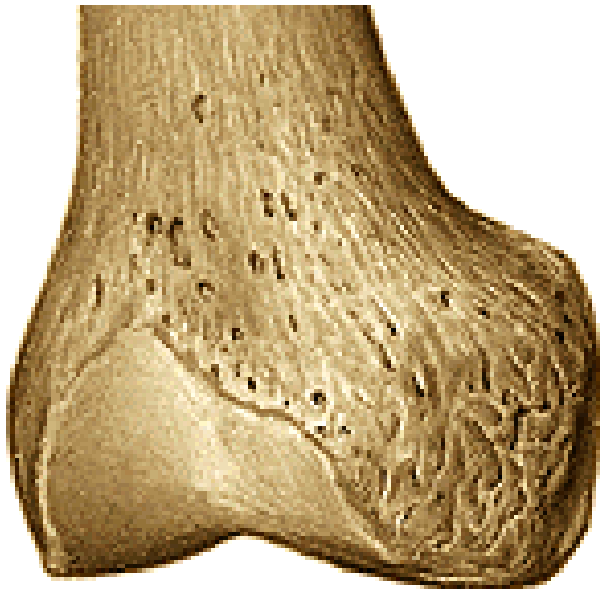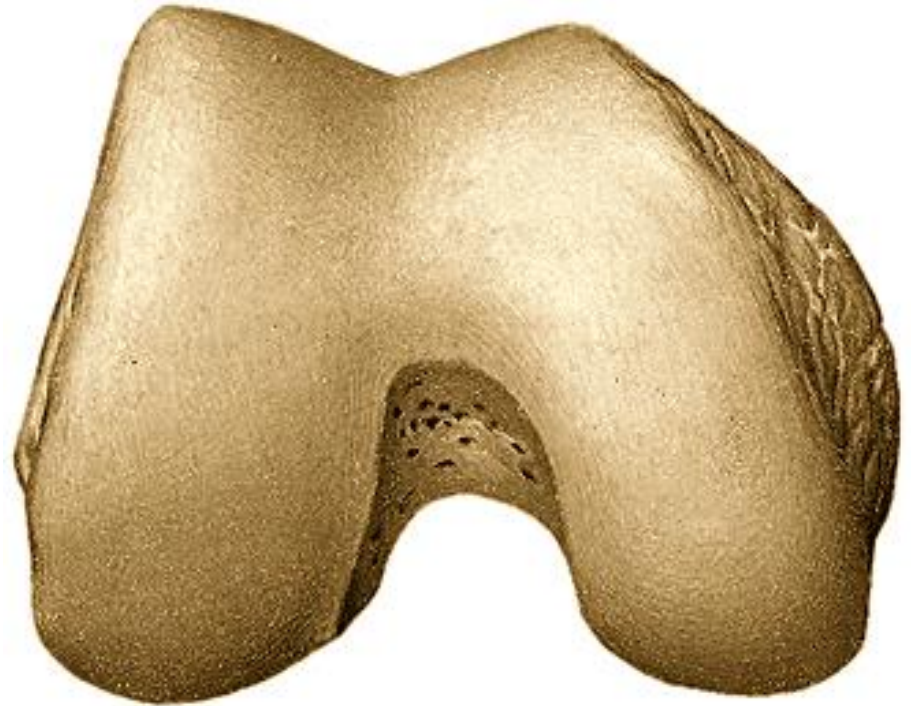epicondylus lateralis

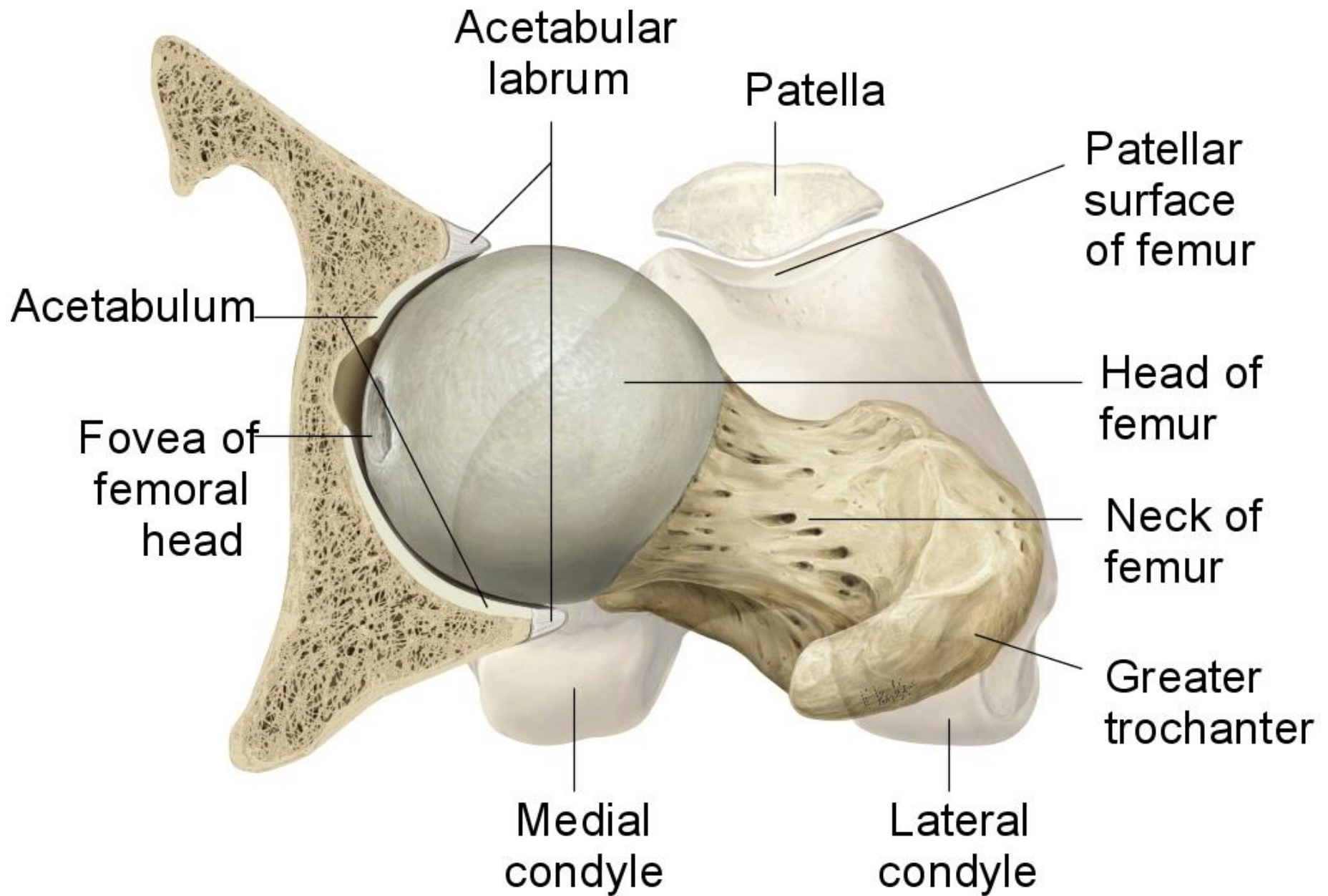
facies patellaris

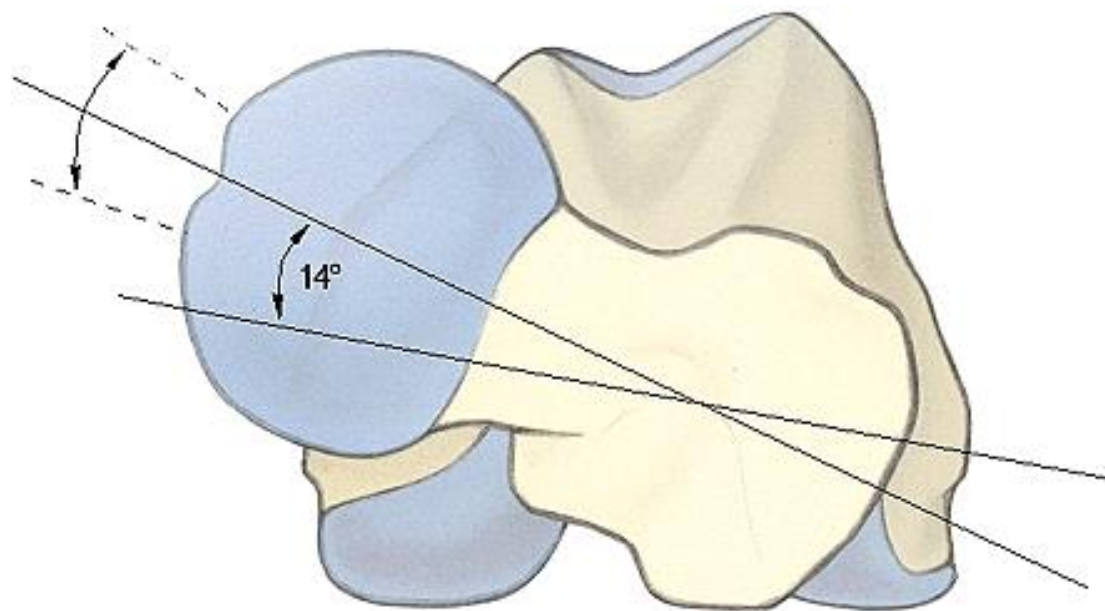
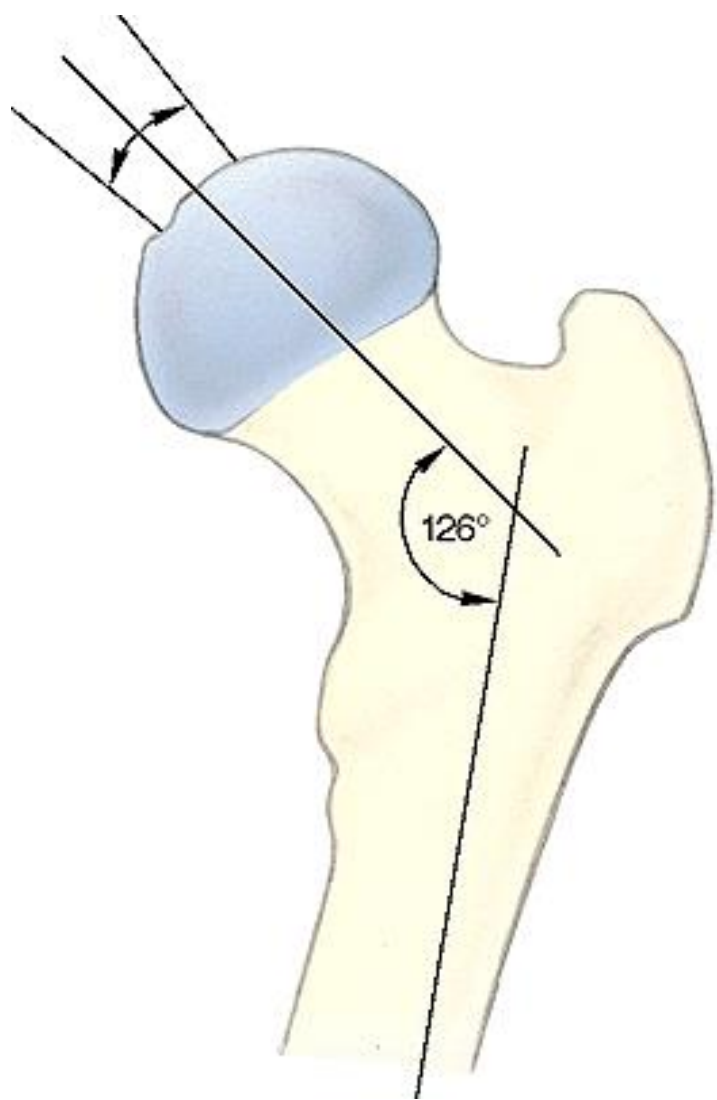
facies poplitea

fossa intercondylaris

linea intercondylaris







Patella – knee-cap

basis patellae

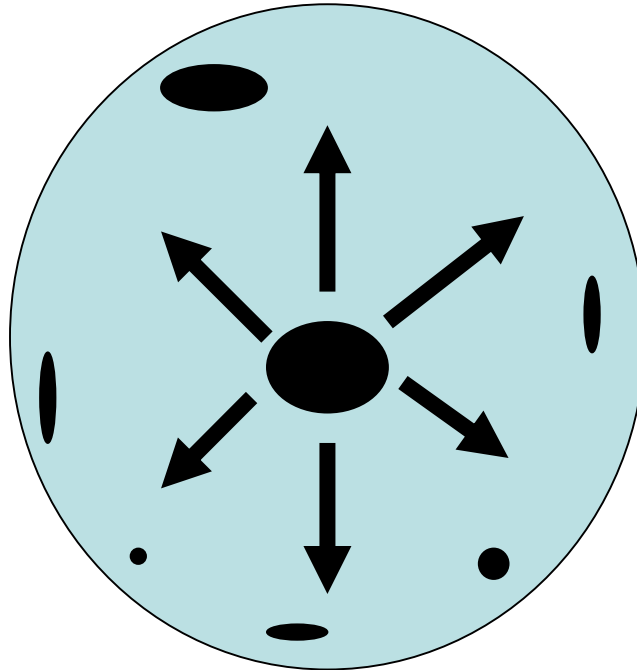
apex patellae

facies articularis patellae- lateral and medial facet

facies anterior



OSSIFACATION OF PATELLA

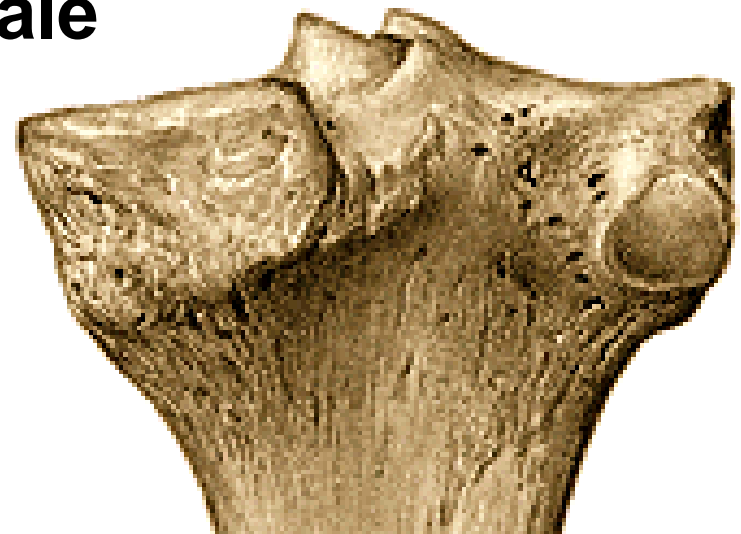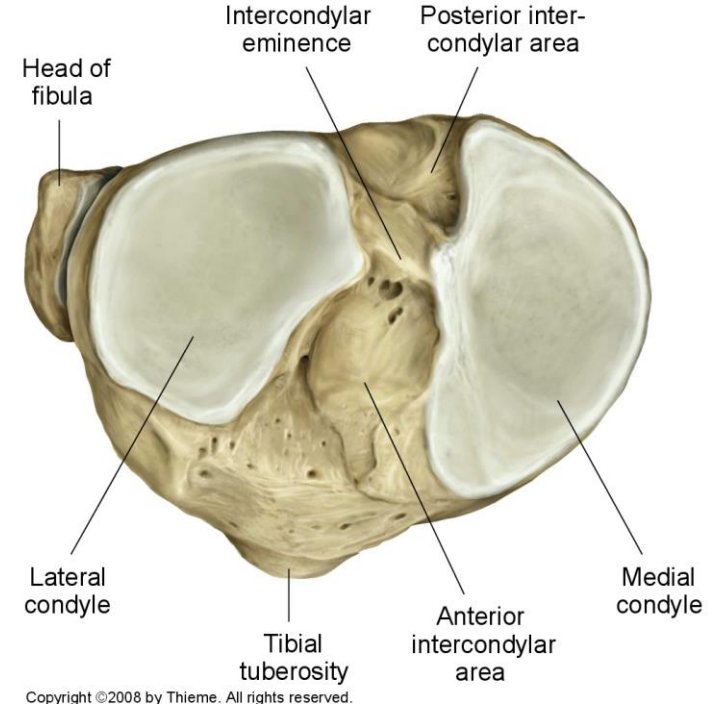


Tibia – shine bone

Proximal end:
condylus medialis
condylus lateralis

facies articularis superior
eminentia intercondylaris
tuberculum intercondylare mediale
tuberculum intercondylare laterale
area intercondylaris anterior
area intercondylaris posterior

facies articularis fibularis



corpus

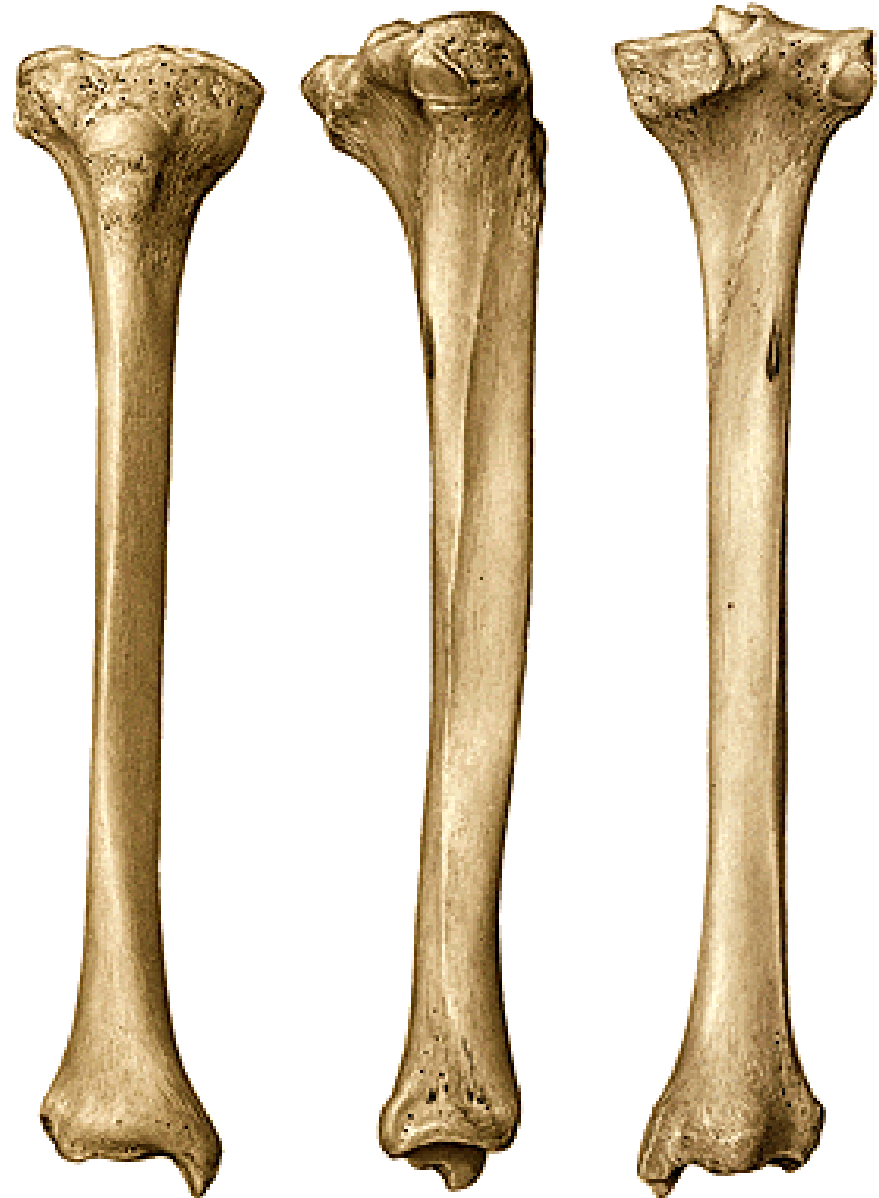tuberositas tibiae

linea musculi solei

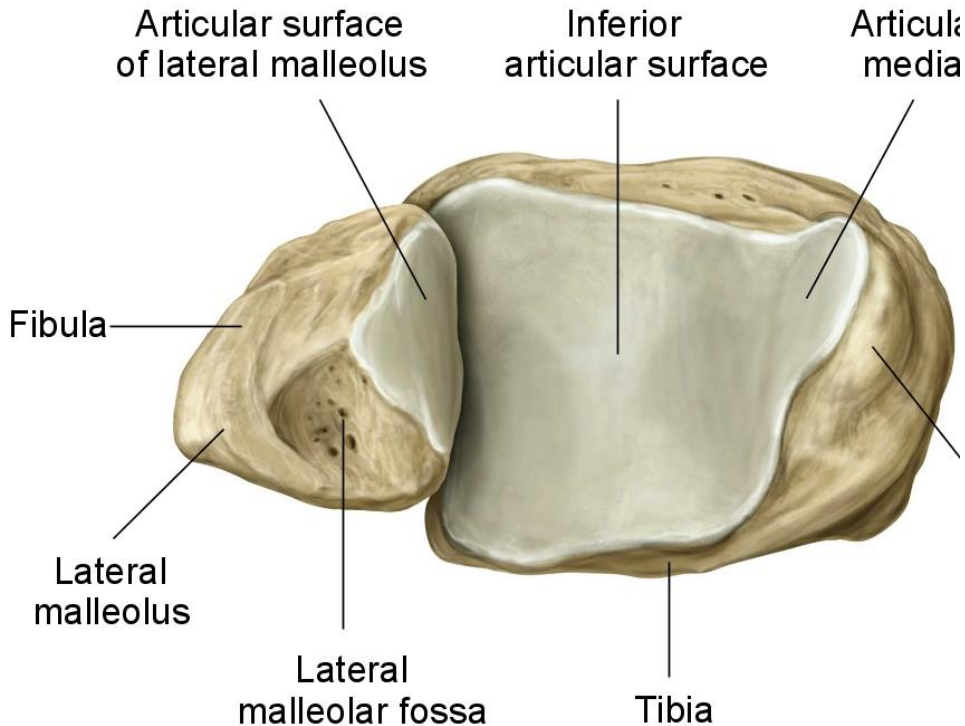
margo medialis

margo anterior

margo interosseus



Distal end:
malleolus medialis
sulcus malleoli medialis
facies articularis malleoli medialis
incisura fibularis
facies articularis inferior (distalis)





Fibula – fibula

Proximal end:

caput fibulae (facies articularis capitis fibulae)
apex capitis fibulae

corpus:

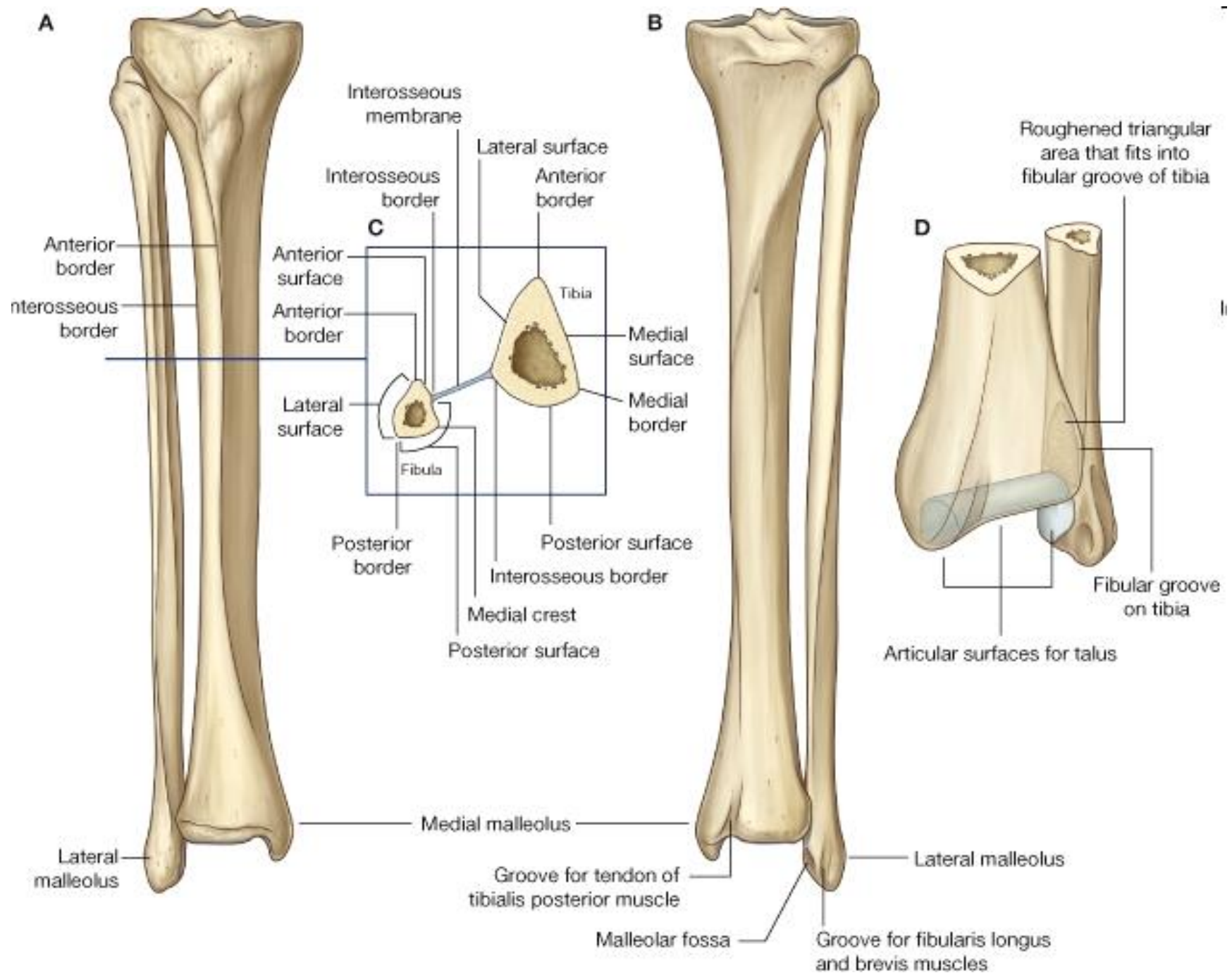
margo anterior
margo medialis
margo posterior
margo interosseus

Distal end:

malleolus lateralis
facies articularis malleoli lateralis
sulcus malleoli lateralis
fossa malleoli lateralis





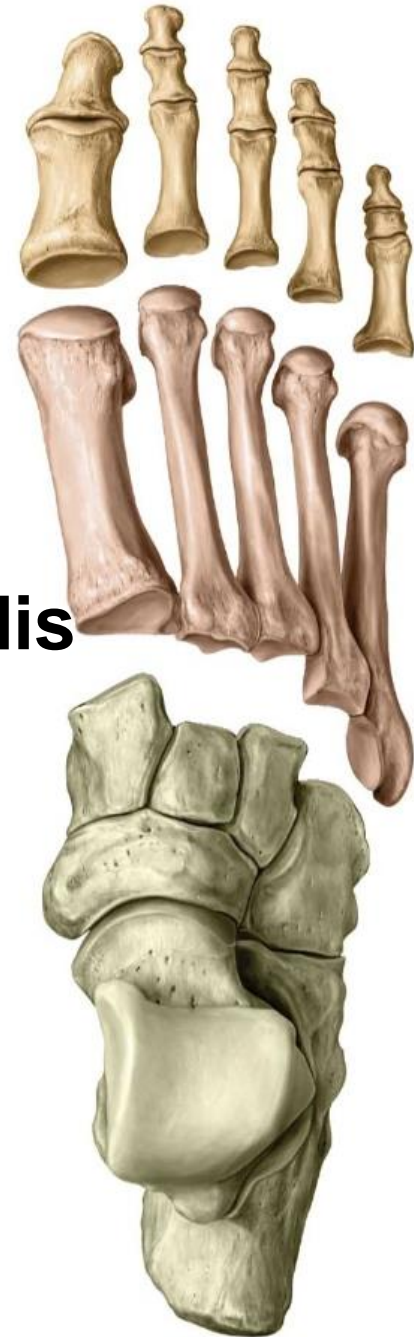

ossa pedis– bones of the foot

I. Tarsal bones– ossa tarsi

II. Metatarsal bones– ossa metatarsi

III. Phalanges of toes– ossa digitorum pedis



Tarsal bones– ossa tarsi (7)

talus

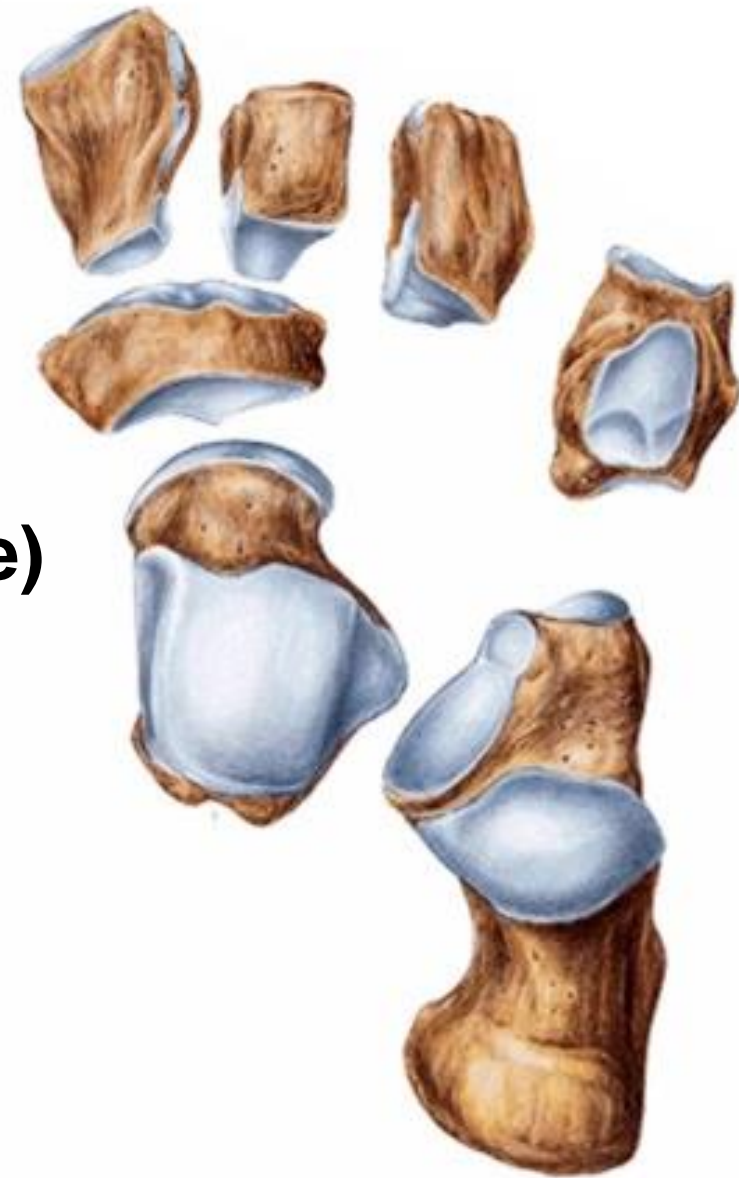calcaneus

Navicular bone

Cuboideal bone

Cuneiform bones

(mediale, intermedium et laterale)



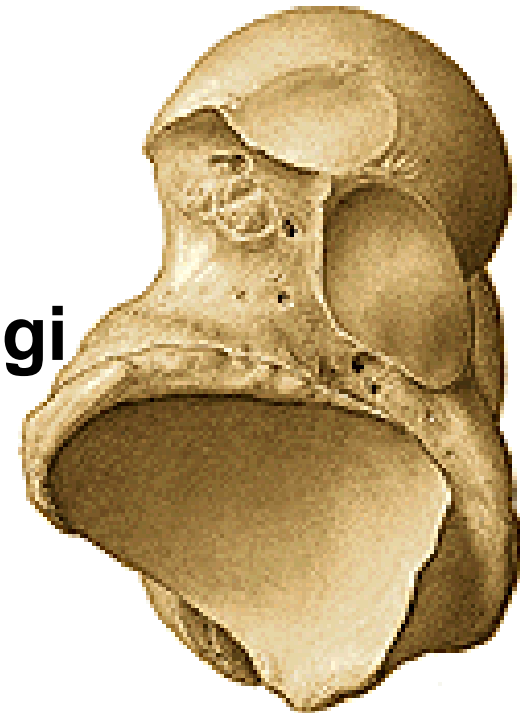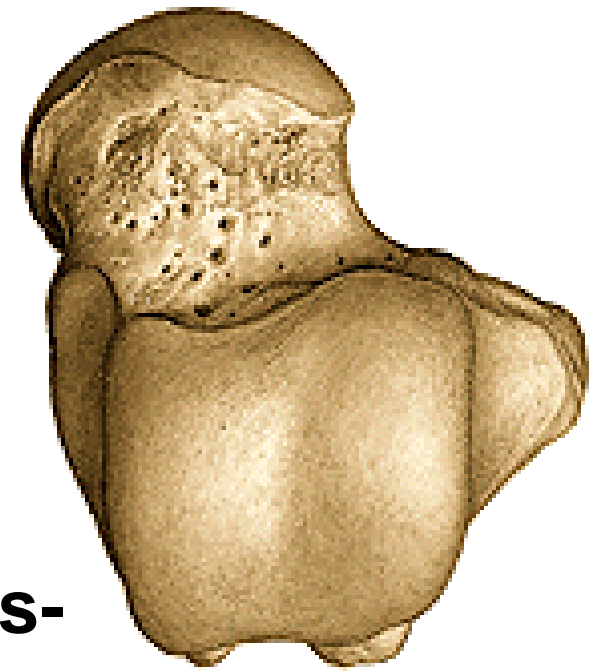
Talus

Proximal part:

corpus tali

- **dorsally**: trochlea tali-
facies superior et maleolaris
(lateralis, medialis)
- **plantar**: facies articularis calcanearis-
posterior, media, anterior
sulcus tali- sinus tarsi
- **processus posterior tali-**
tuberculum mediale et laterale-
sulcus tendinis m. flexoris hallucis longi
- **processus lateralis tali**

collum tali



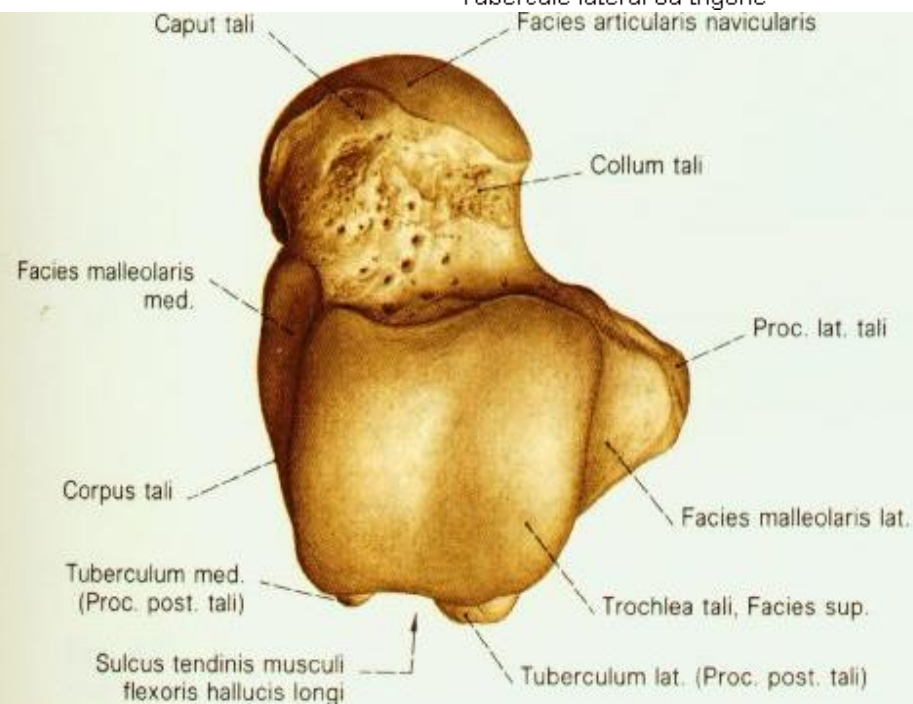
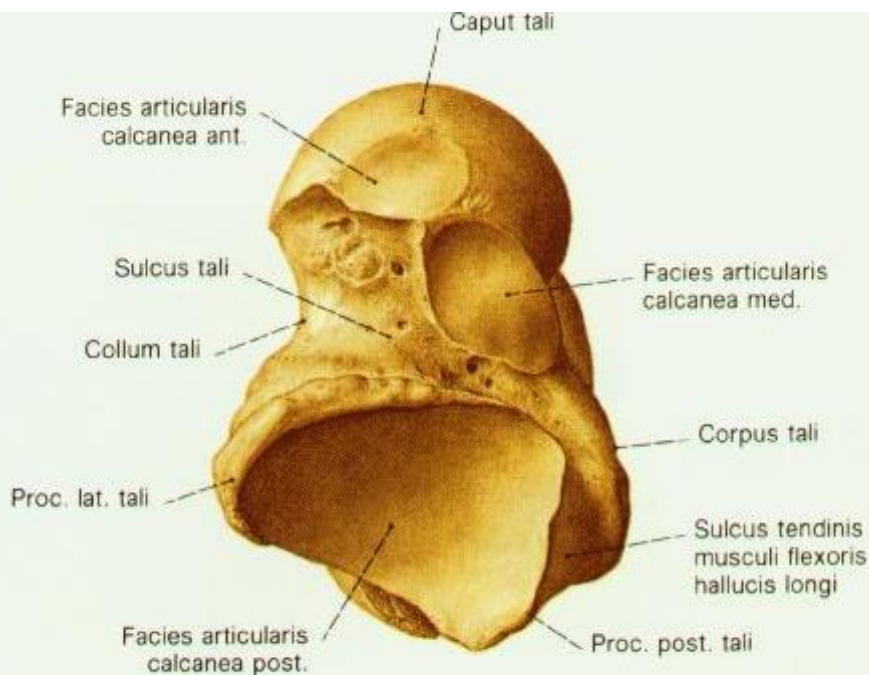
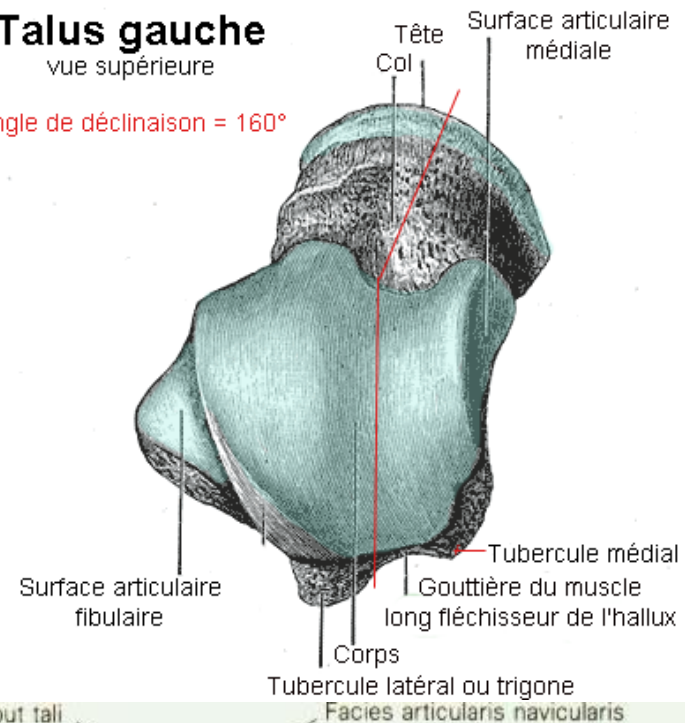
Distal part

- caput tali- facies articularis navicularis

Talus gauche

vue supérieure

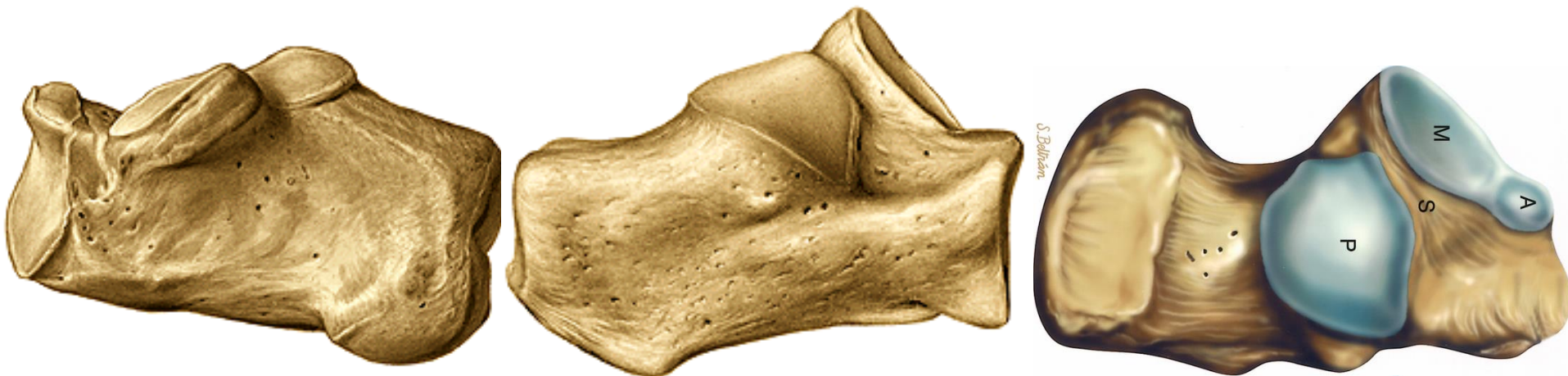
Angle de déclinaison = 160°

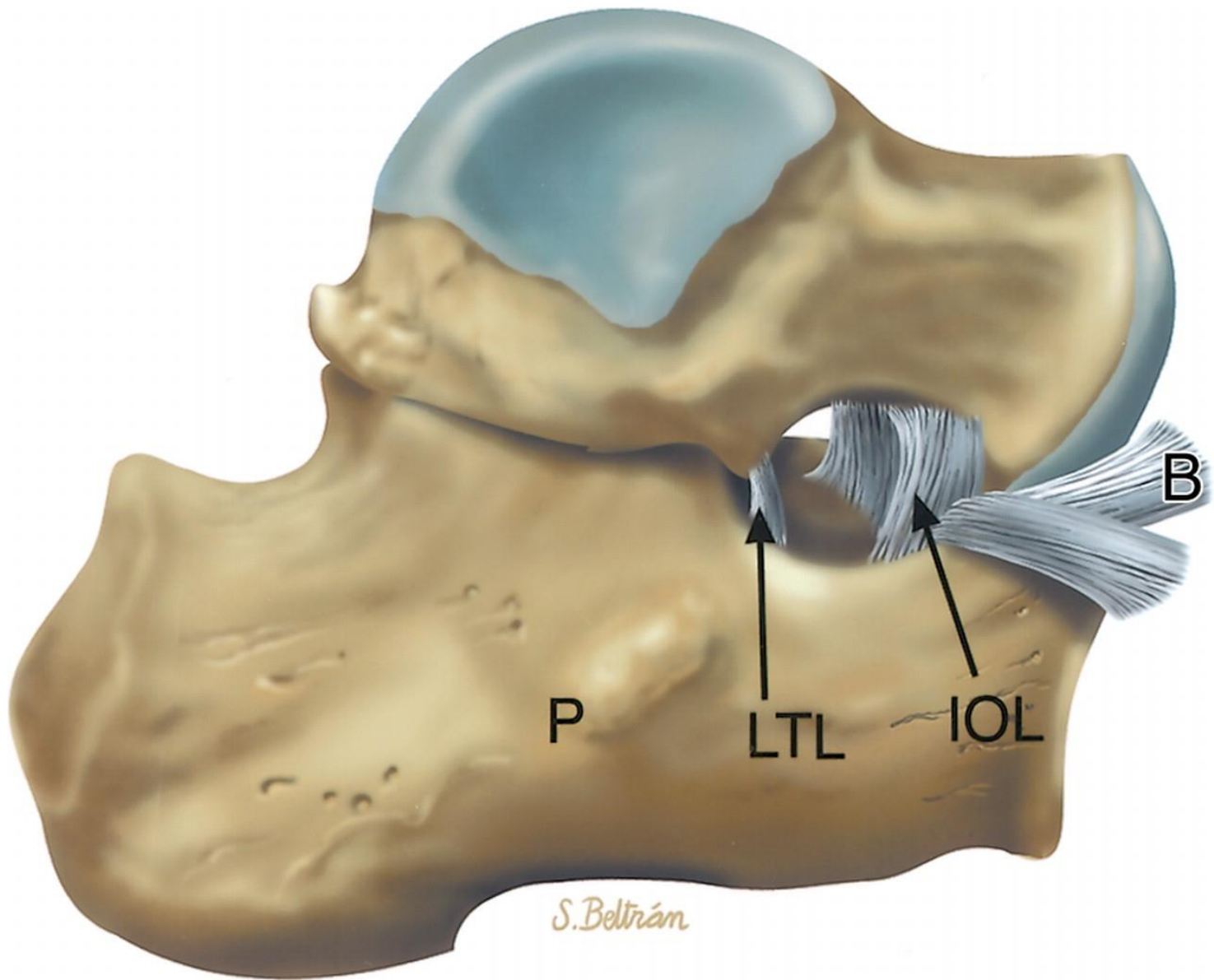




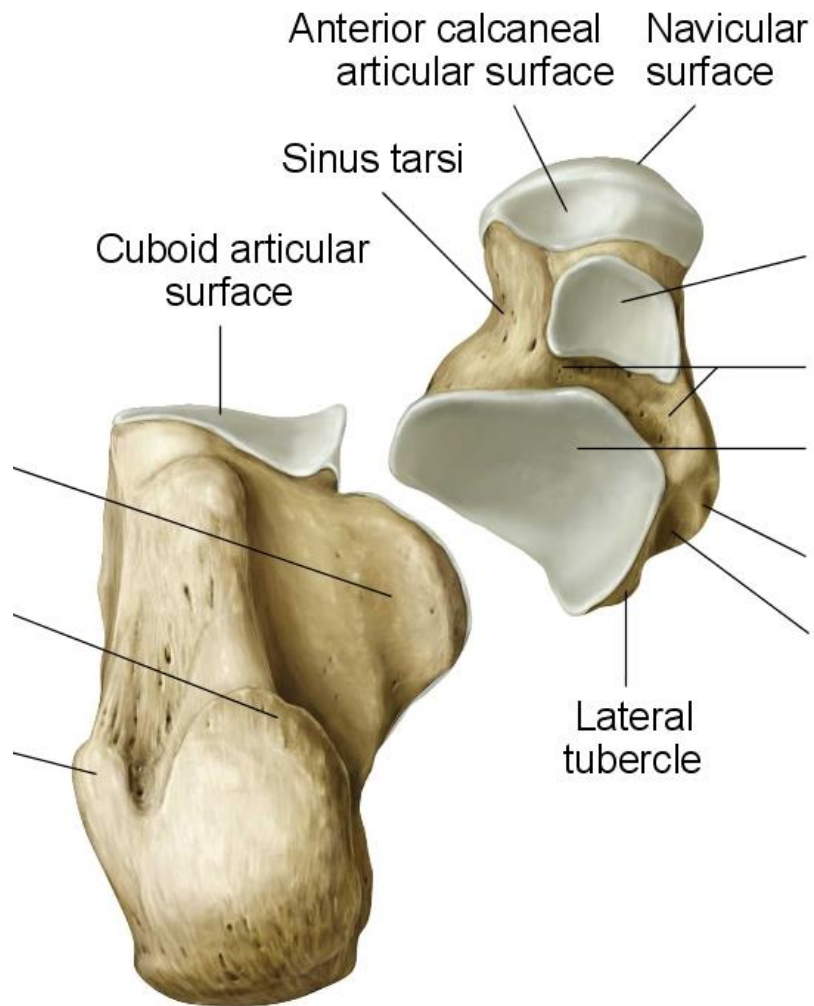
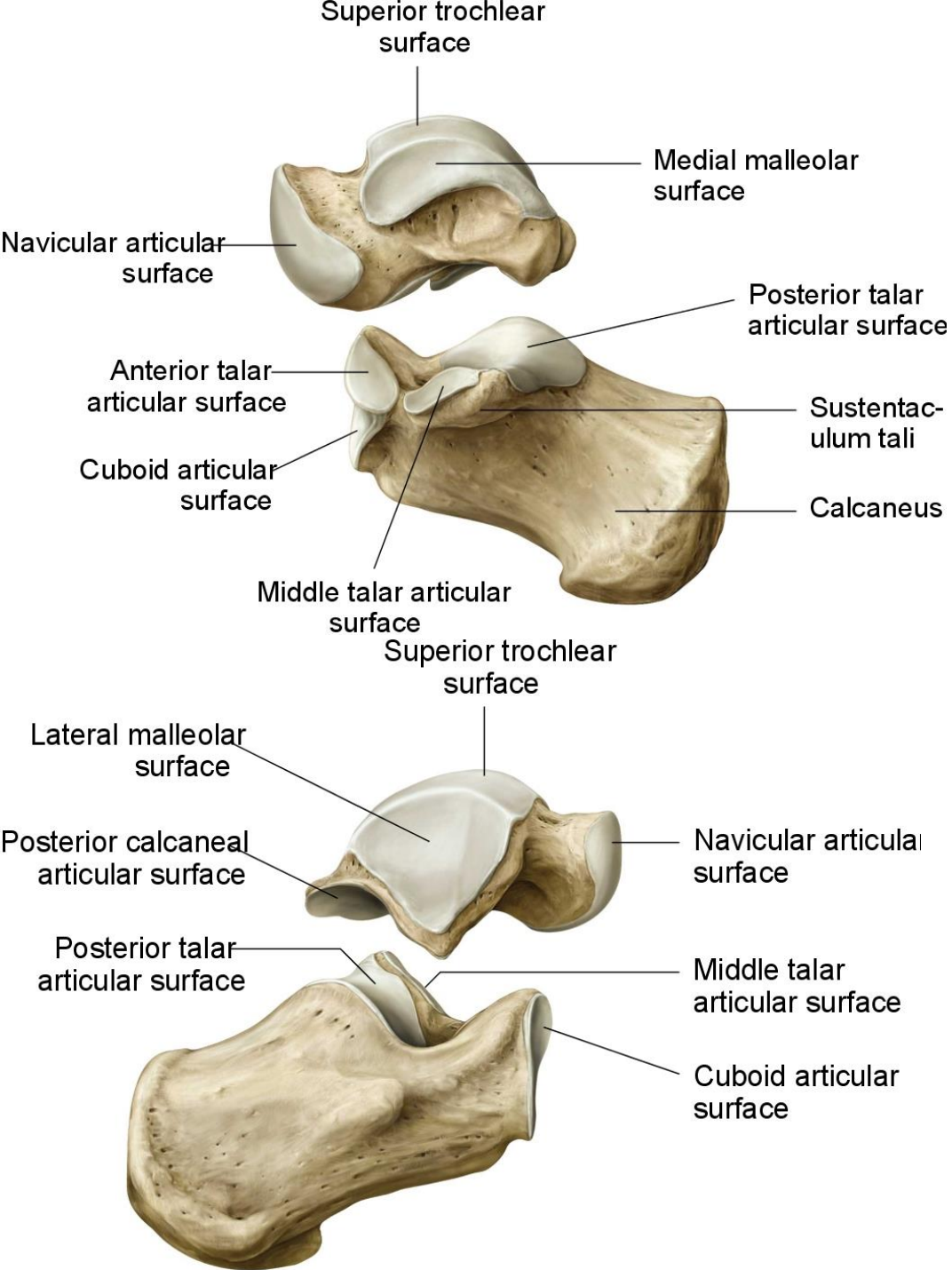
Calcaneus

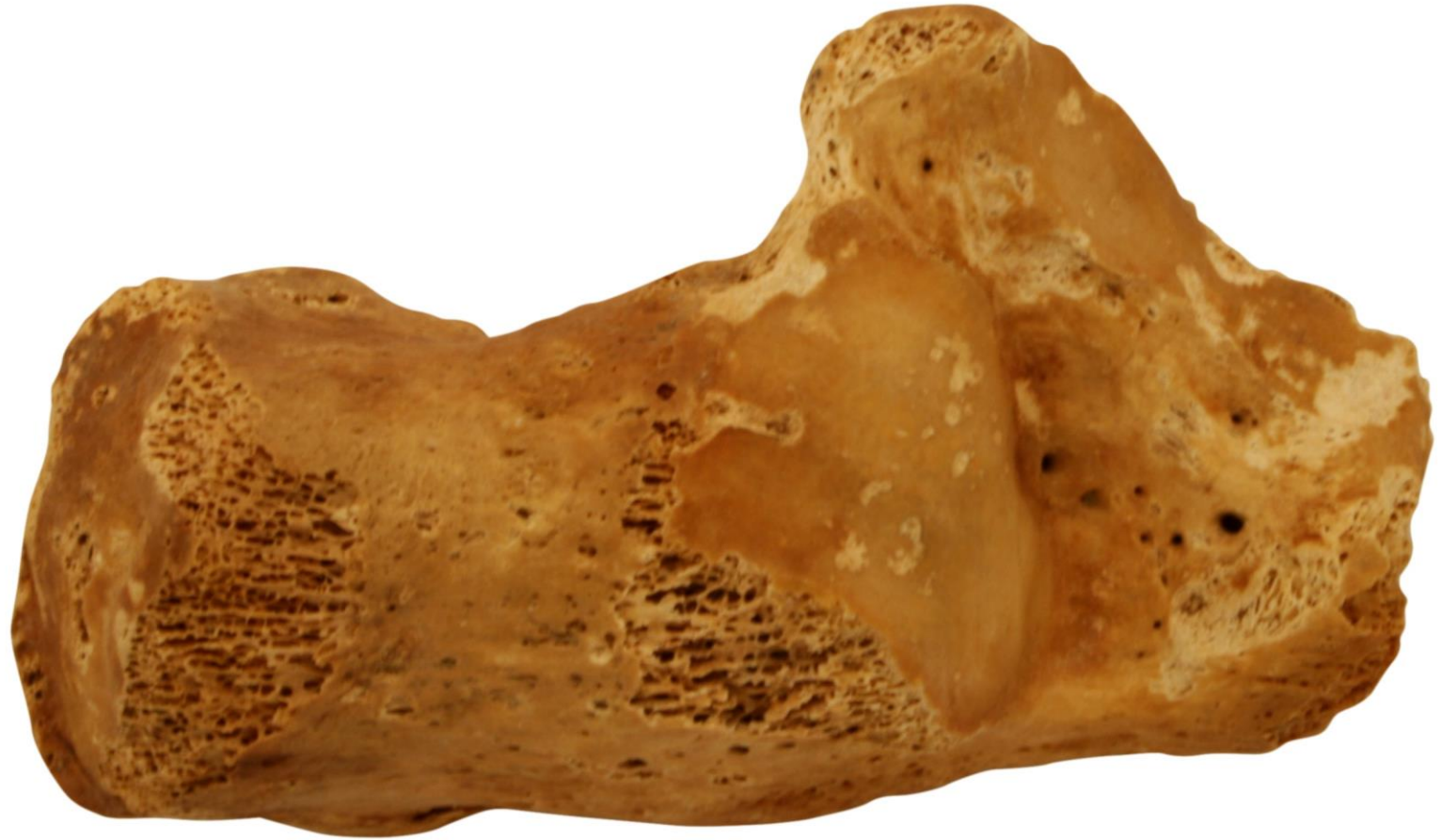- tuber calcanei (processus medialis et lateralis)
 - sustentaculum tali (sulcus tendinis musculi flexoris hallucis longi)
 - trochlea peronealis- sulcus tendinis musculi peronei longi
 - facies articularis cuboidea
 - facies articularis talaris posterior, media et anterior
 - sulcus calcanei
- sulcus tali + sulcus calcanei = sinus tarsi





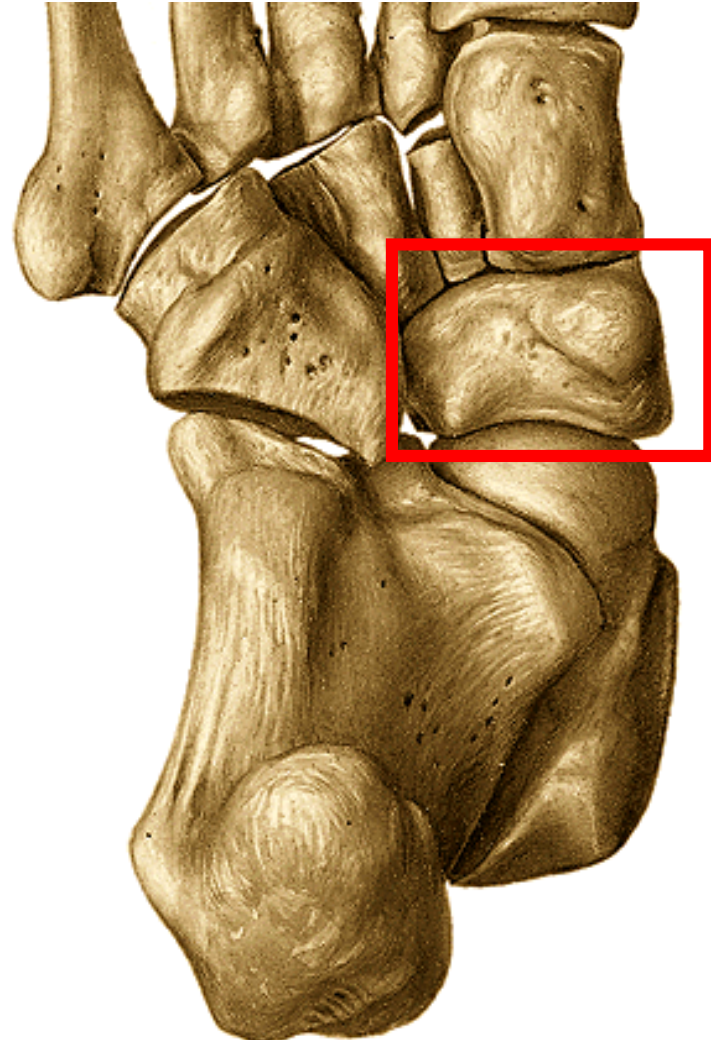
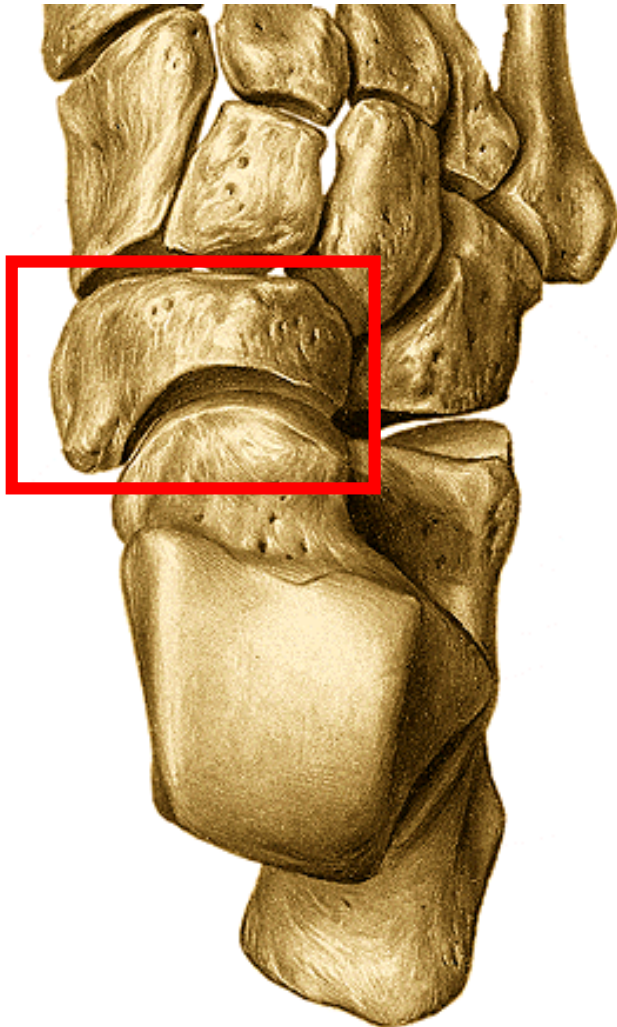
S. Beltrám





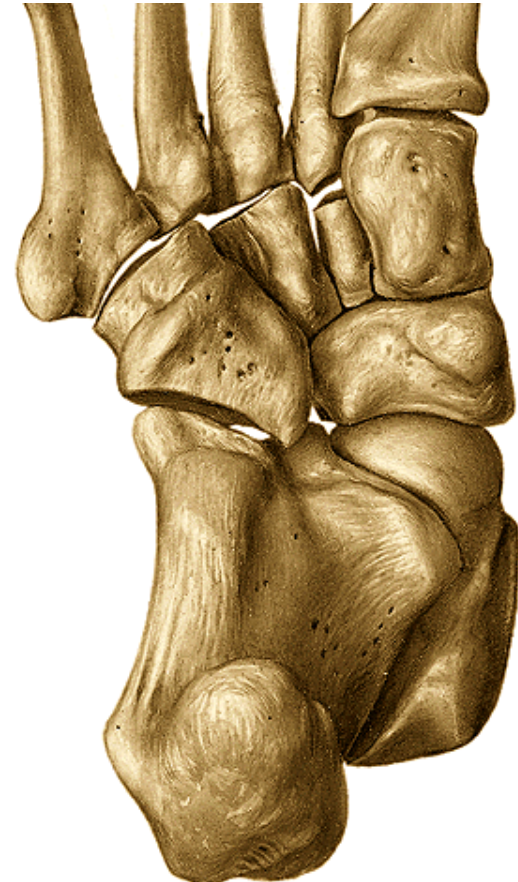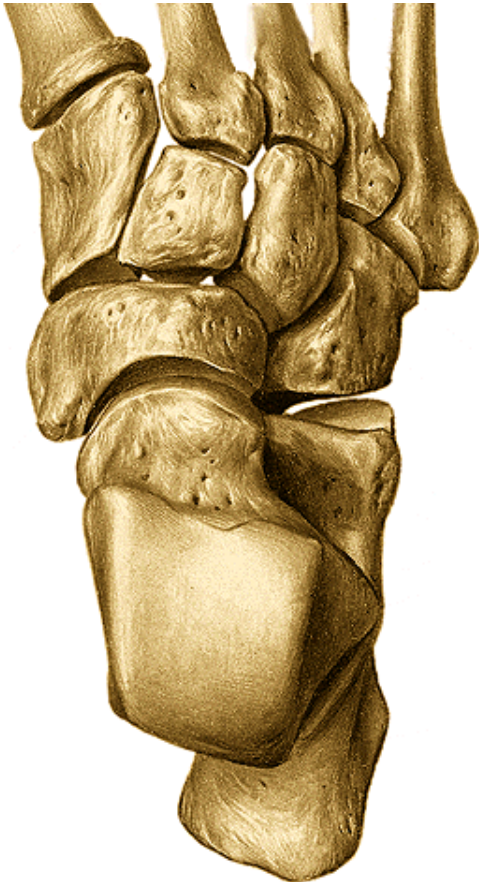Navicular bone

- **facies articularis talaris**- concave
- **facies articularis cuneiformis**- convex- 3 facets
- **tuberositas ossis navicularis**- plantar



cuboid

- **f. articularis calcanearis**, 2 facets for 4th and 5th metatarsal bone
- Surface for articulation with os cuneiforme laterale
- **tuberositas ossis cuboidei**
- **sulcus tendinis musculi peronei longi**



Cuneiform bones:

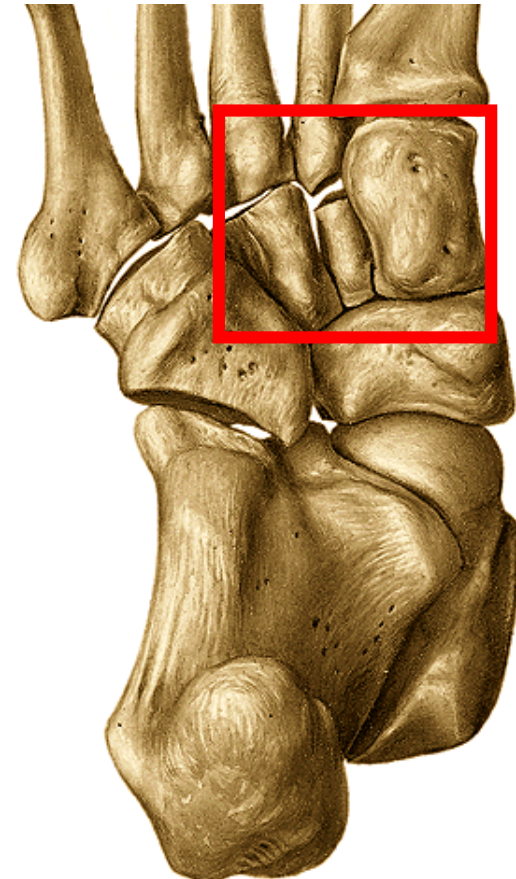
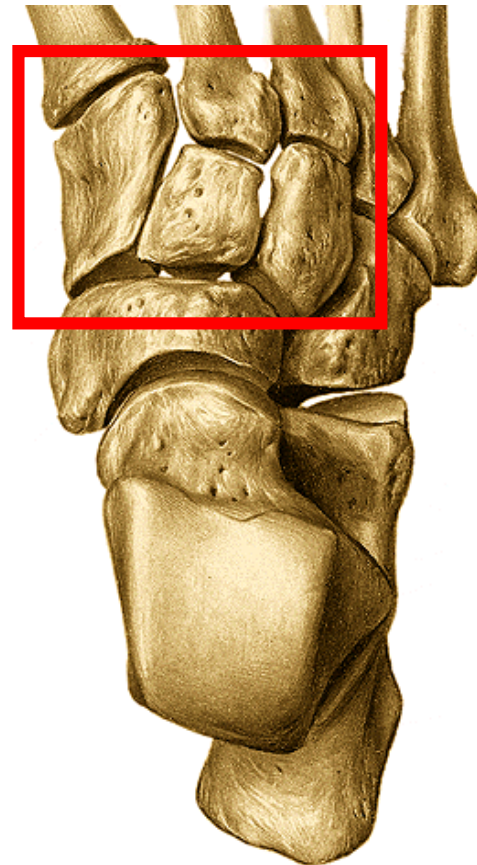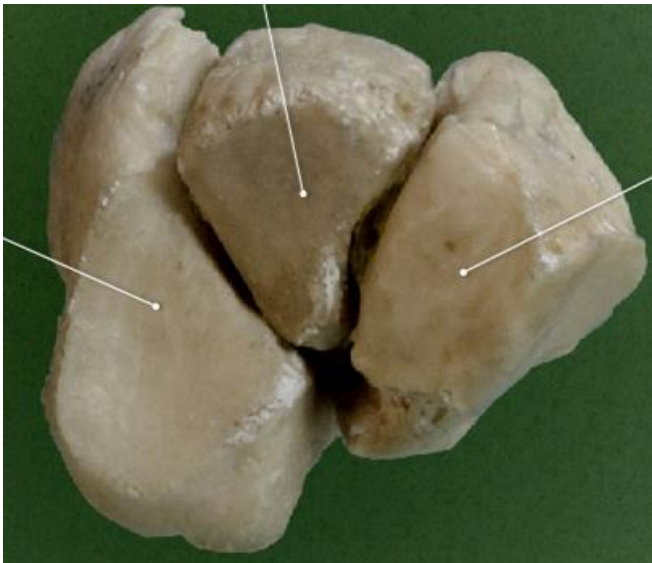
mediale, intermedium et laterale

mediale: the largest, edge of wedge-dorsally

intermedium: edge of wedge - plantar

laterale: edge of wedge - plantar

They participate in the foot vault

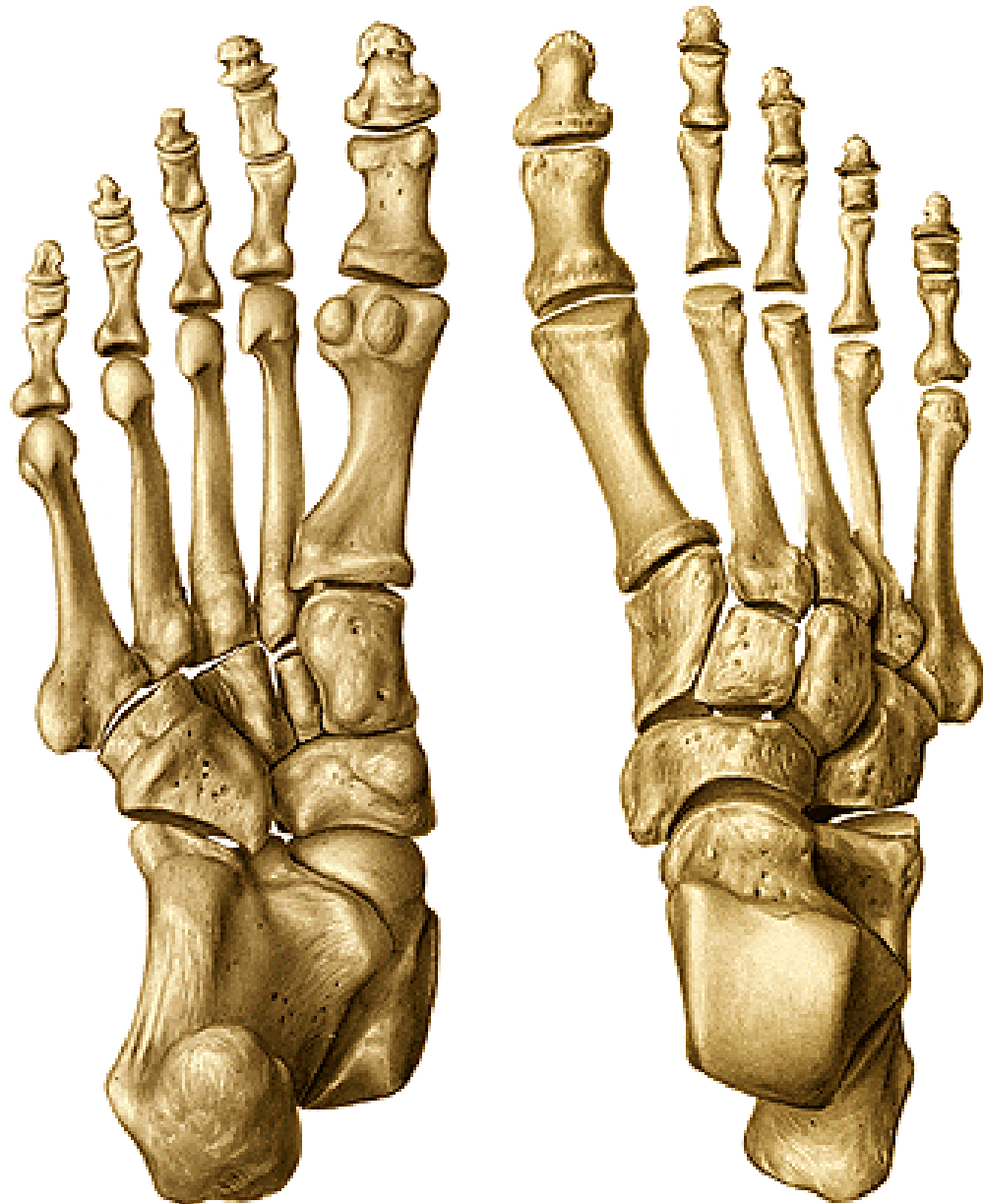

Metatarsal bones– ossa metatarsi (I. – V.)

basis (tuberositas ossis metatarsi I. et V.)

corpus

caput



Phalanges of toes – ossa digitorum pedis

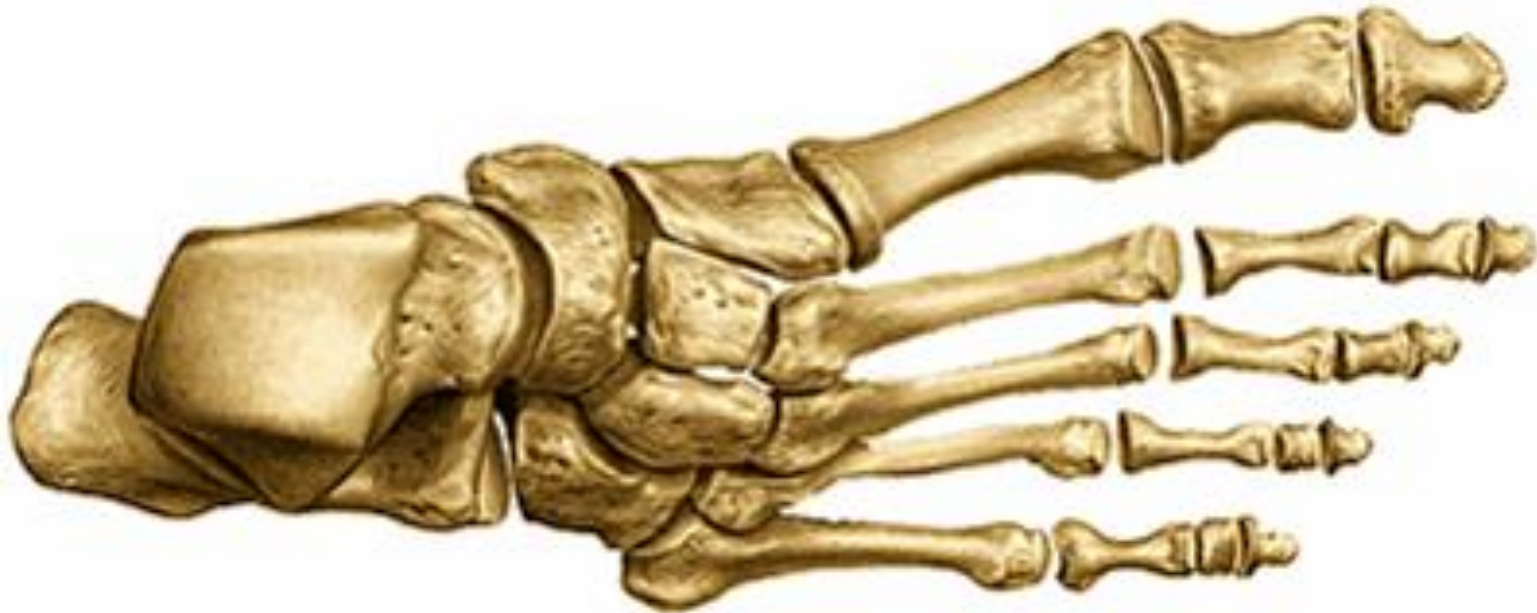1st – phalanx proximalis et distalis

2nd – 5th toe – phalanx proximalis, media et distalis

basis phalangis

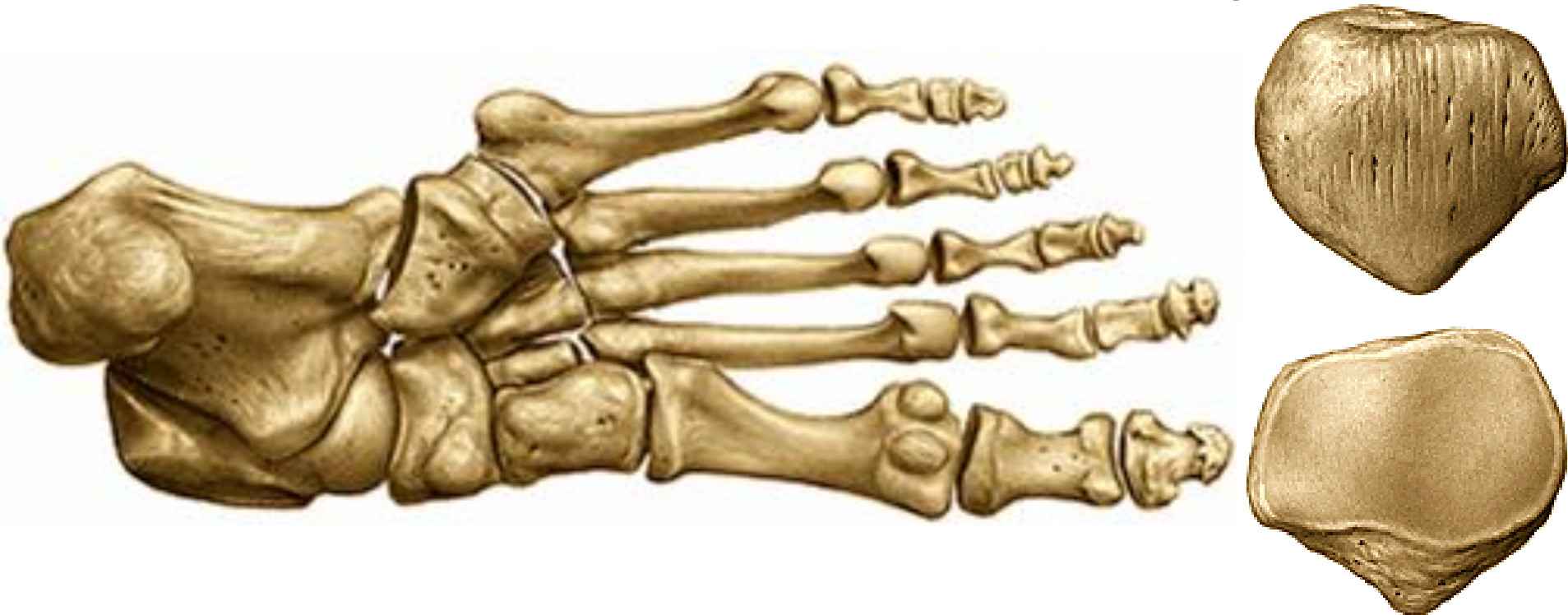corpus phalangis

trochlea (distal phalanx – tuberositas phalangis distalis)



Ossa sesamoidea

- patella
- Bellow the head of the 1th metatarsal bone: two bones (lateral and medial) **in metatarsophalangeal joint**
- Sometimes also bellow the head of 2nd and 5th met. bone, within the tendon of m.peroneus longus



ossification

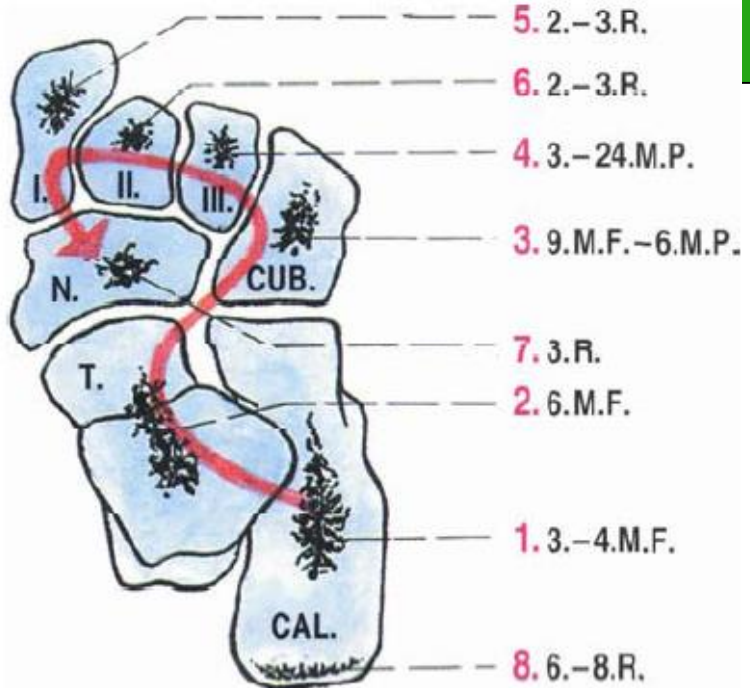
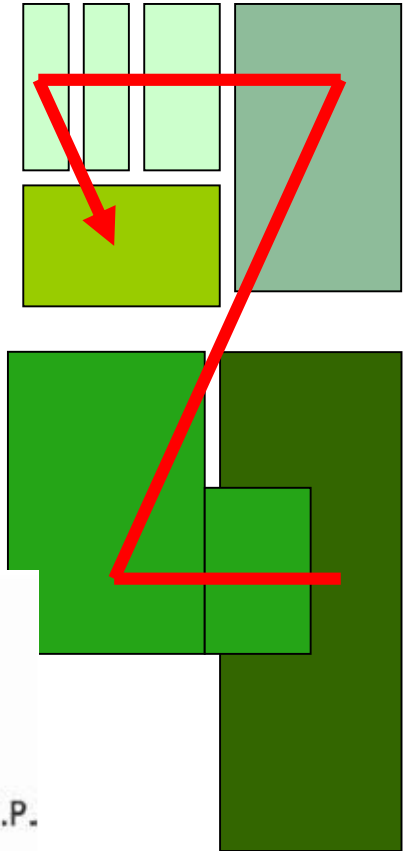
Os intermetatarsale

Os Vesali

Os tibiale
exter.

Calcaneus accesorius

Os trigonum



Tank you for your attention!

Obrázky:

Atlas der Anatomie des Menschen/Sobotta. Putz,R., und Pabst,R. 20. Auflage.

München:Urban & Schwarzenberg, 1993

Netter: Interactive Atlas of Human Anatomy.

Naňka, Elišková: Přehled anatomie. Galén, Praha 2009.

Čihák: Anatomie I, II, III.

Drake et al: Gray's Anatomy for Students. 2010