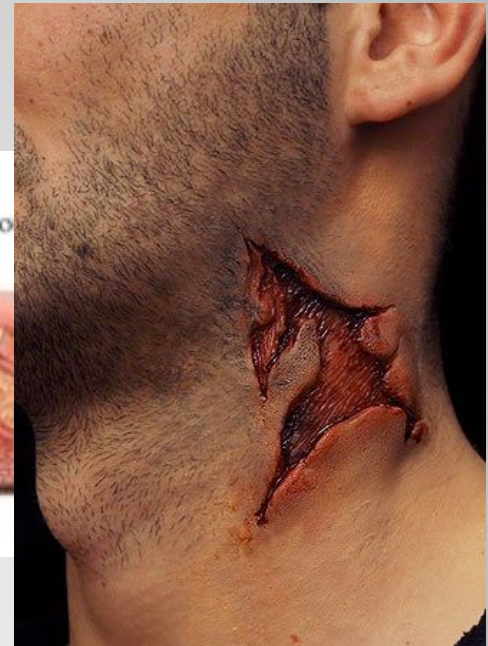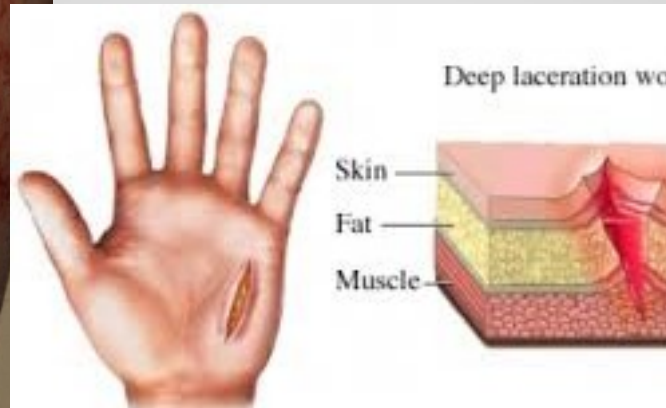

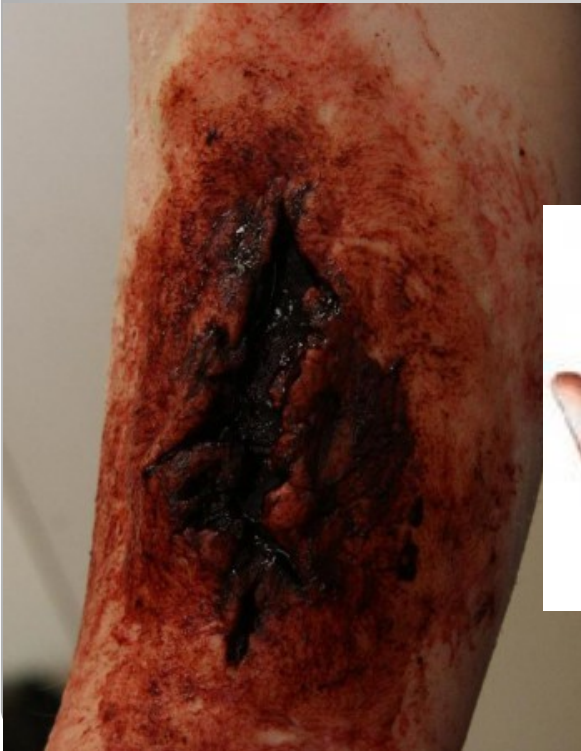
INJURIES

IN CLINICAL TERMINOLOGY

Tear wound = a wound produced by the tearing of body tissue. External lacerations may be small or large and may be caused in many ways, such as a blow from a blunt instrument, a fall against a rough surface, or an accident with machinery. Lacerations within the body occur when an organ is compressed or moved out of place by an external or internal force.

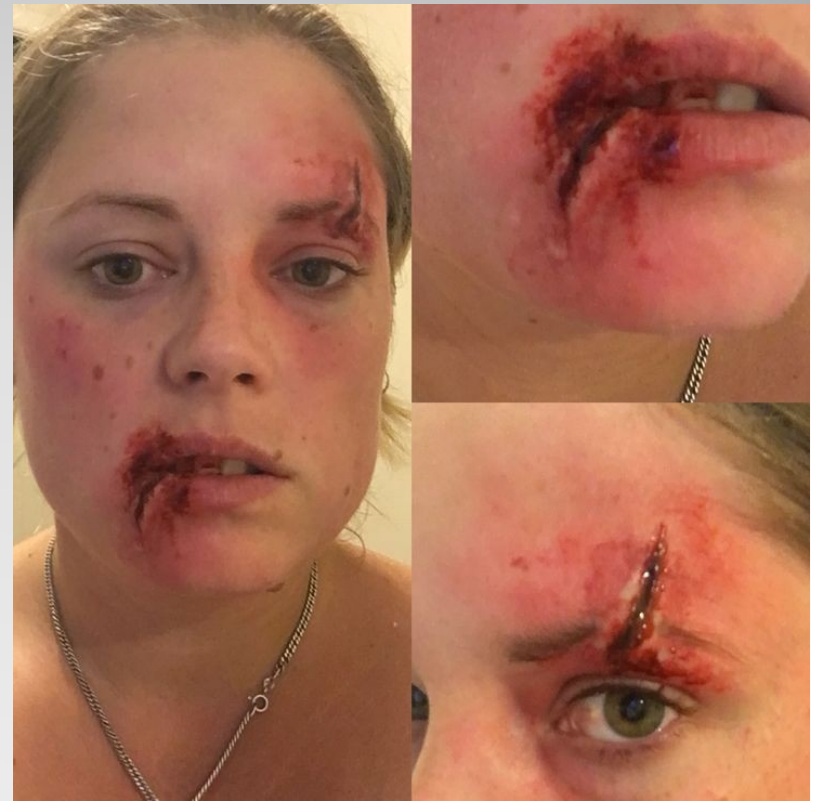

Vulnus lacerum

Put the words in correct order

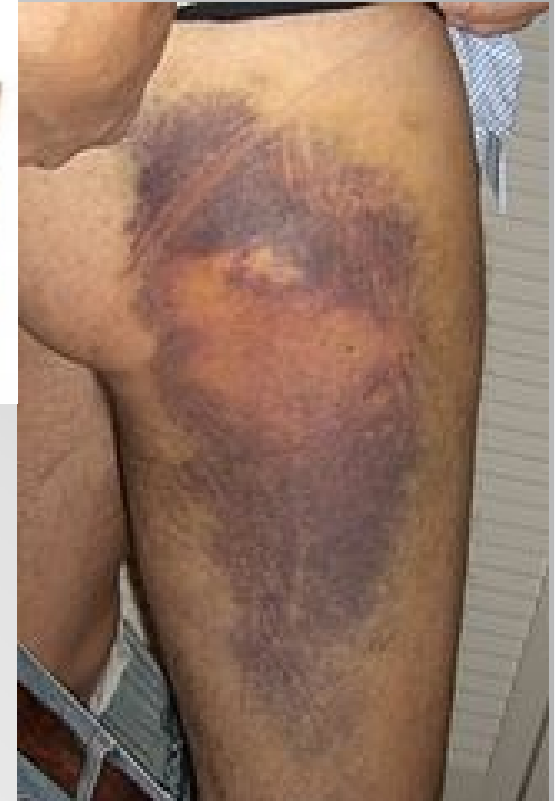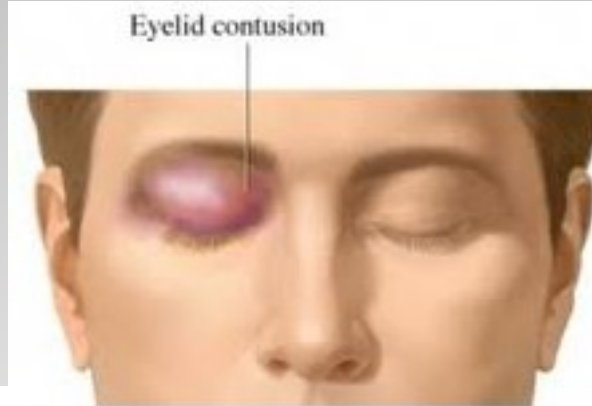supercilii - oris - l. - vulnus - sin.- labii - et-
lacerum - inferioris

- vulnus lacerum labii inferioris oris et supercilii l. sin.

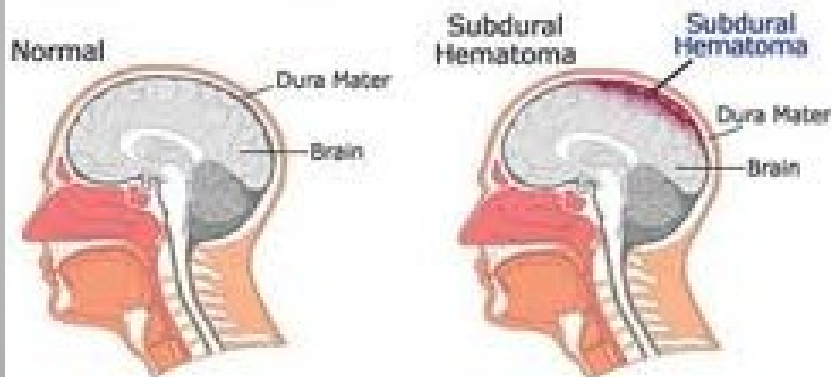


Bruise wound = an injury to tissues with skin discoloration and without breakage of skin. Blood from the broken vessels accumulates in surrounding tissues, producing pain, swelling, and tenderness, and the discoloration is the result of blood seepage just under the skin.

Haematoma
= localized swelling filled with blood

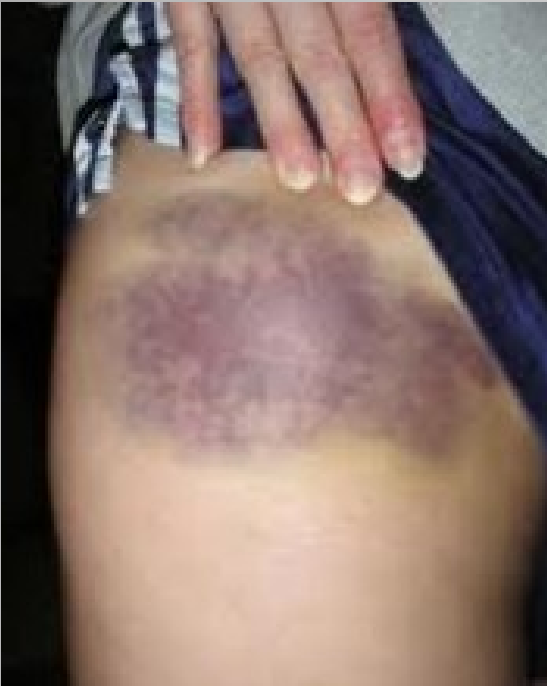

Subdural Hematoma

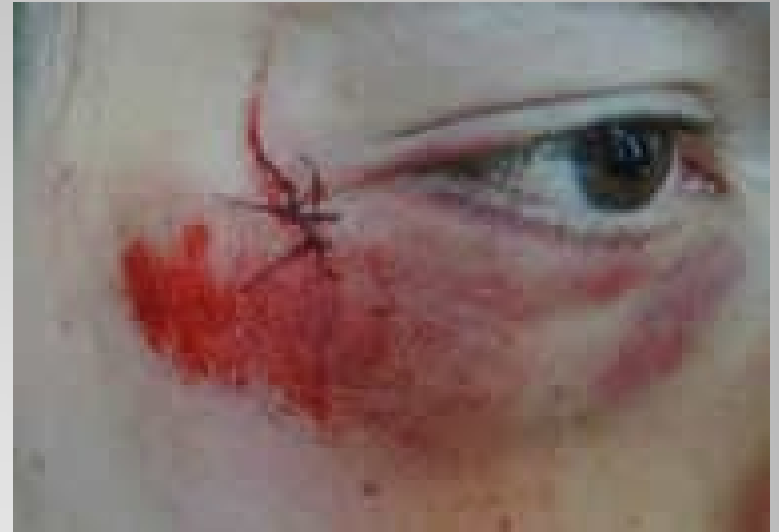
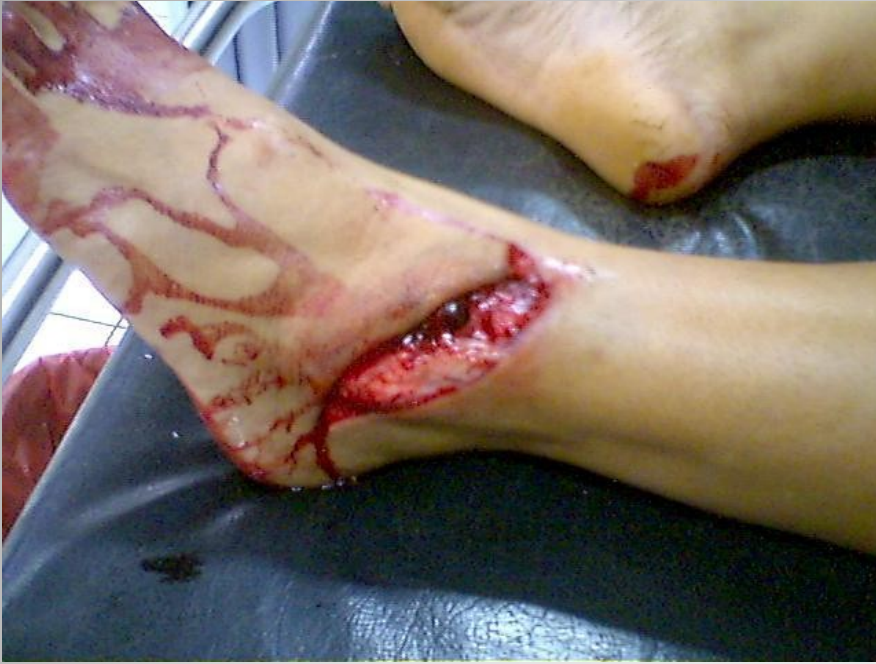
Vulnus contusum = contusio

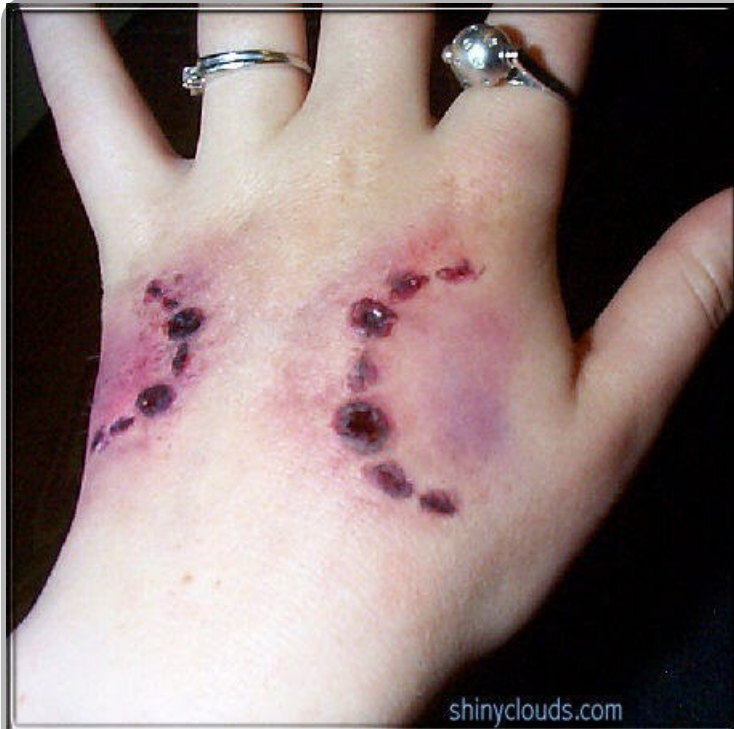Fill in missing endings



*Contusio femoris lateris
dextri cum haematomate*



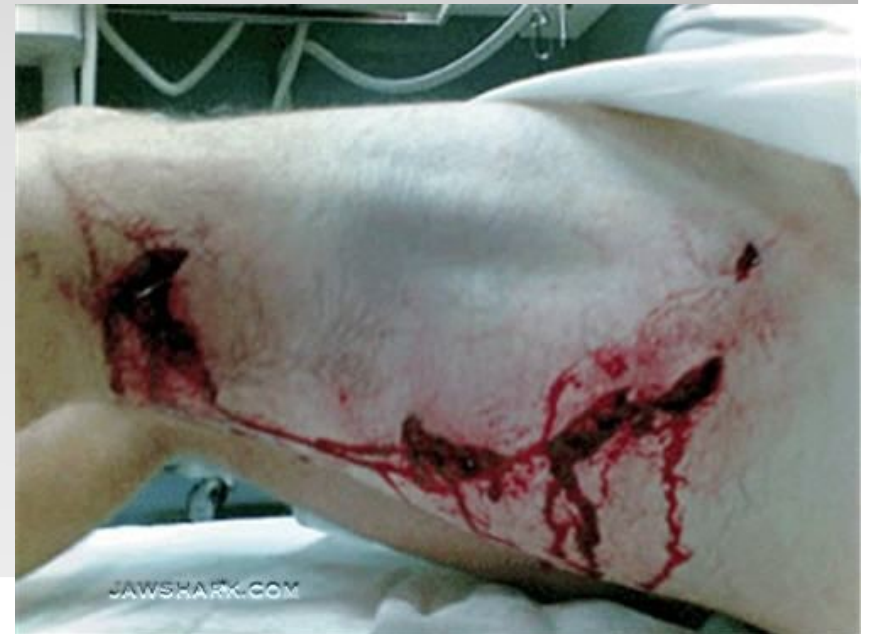**Vulnus contusolacerum
= lacerocontusum**



Bite wound

= usually a puncture or laceration, caused by teeth. An animal bite usually results in a break in the skin but also includes contusions from the excessive pressure on body tissue from the bite. The contusions can occur without a break in the skin.

Animal bites often result in serious infections and mortality.

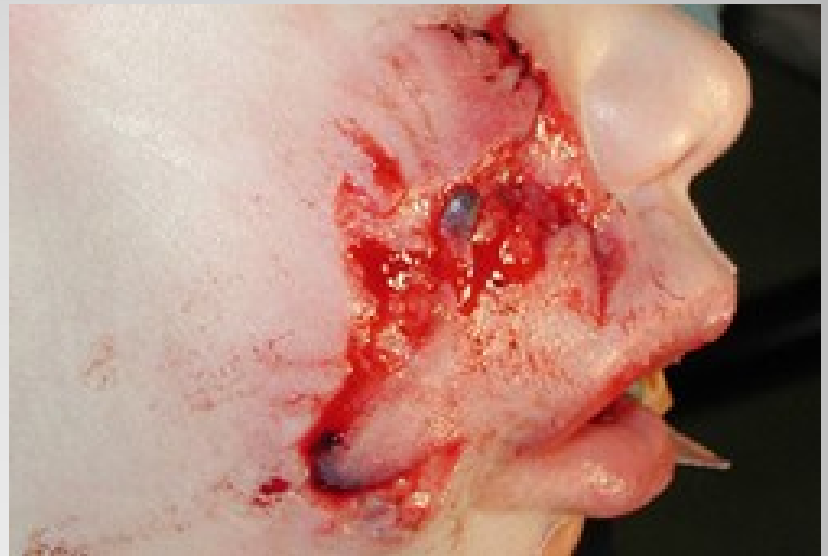

Vulnus morsum

Translate the diagnose

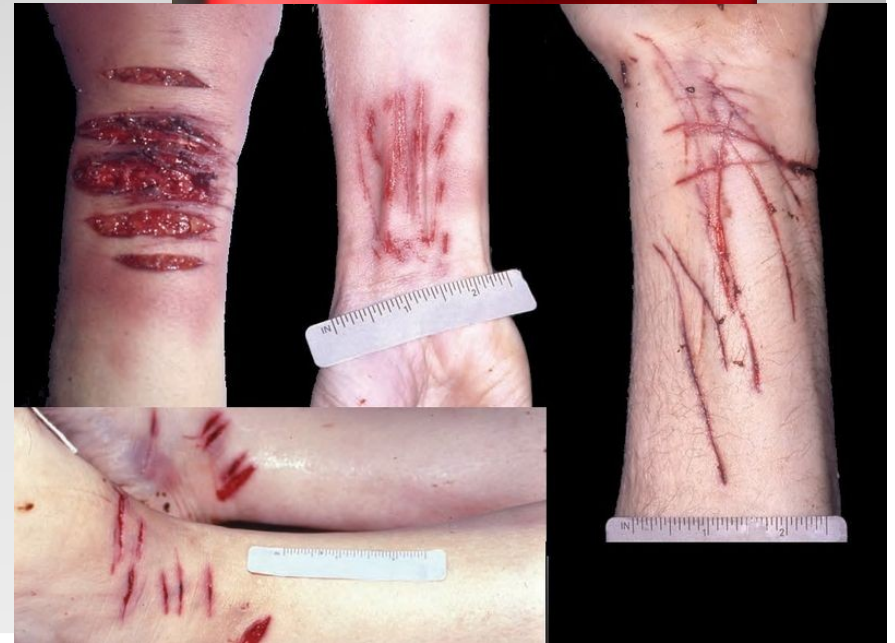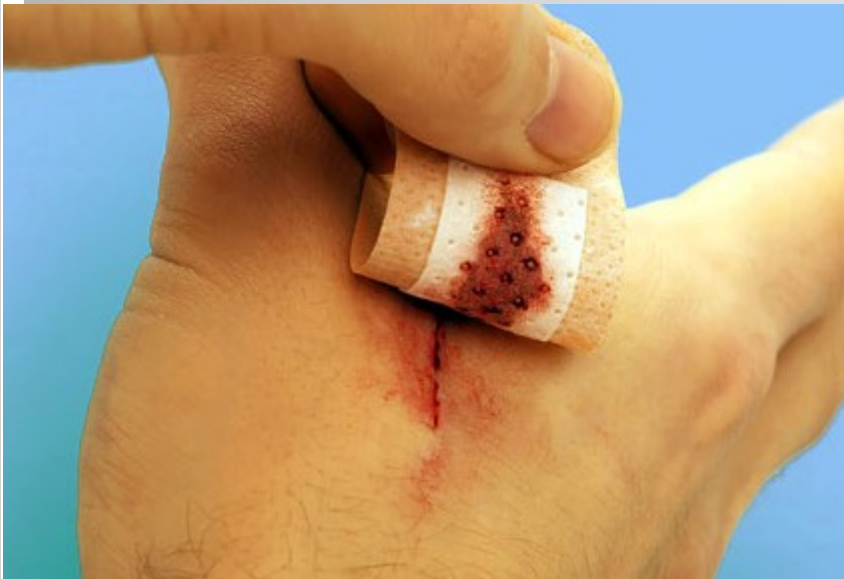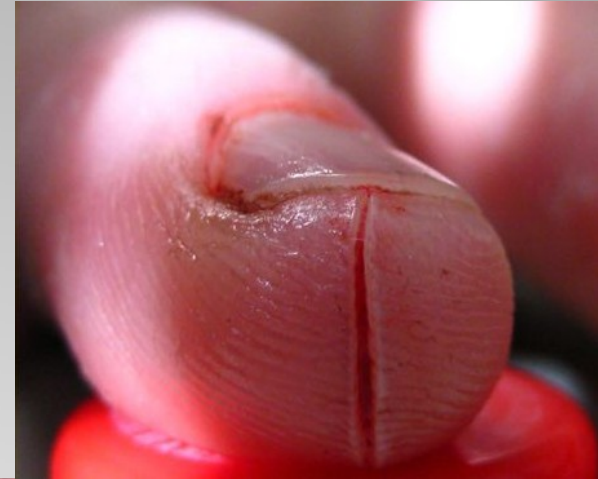Bite wounds of the right face after an animal bite ?

- Vulnera morsa faciei lateris dextri post morsum animalis



cut wound = incision

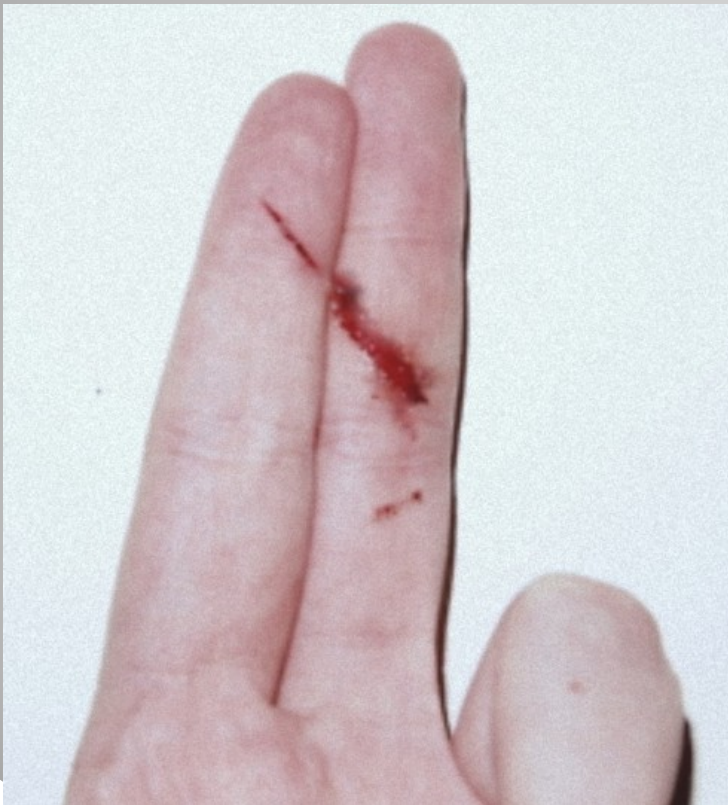= a wound made by pulling of a sharp instrument, leaving even edges. They may be as minimal as a paper cut or as significant as a surgical incision. or a wound made by a sharp instrument.



Vulnus scissum / incisum

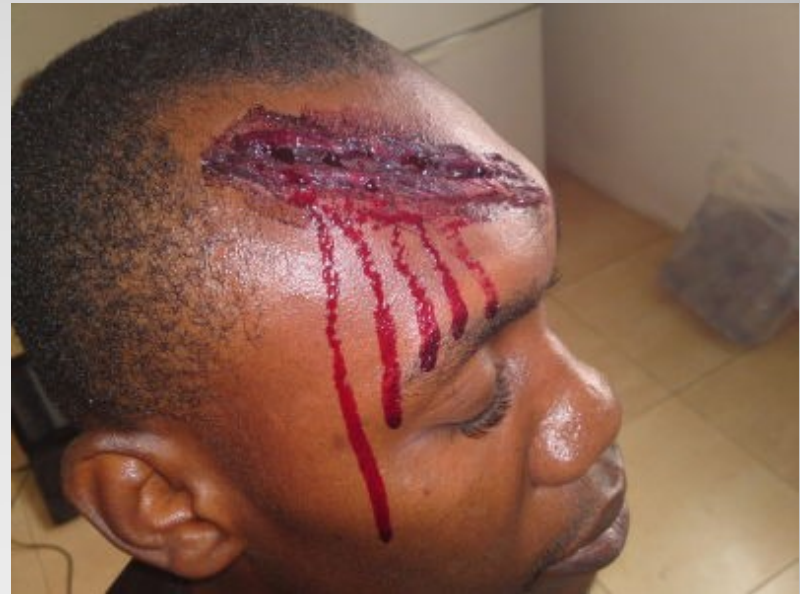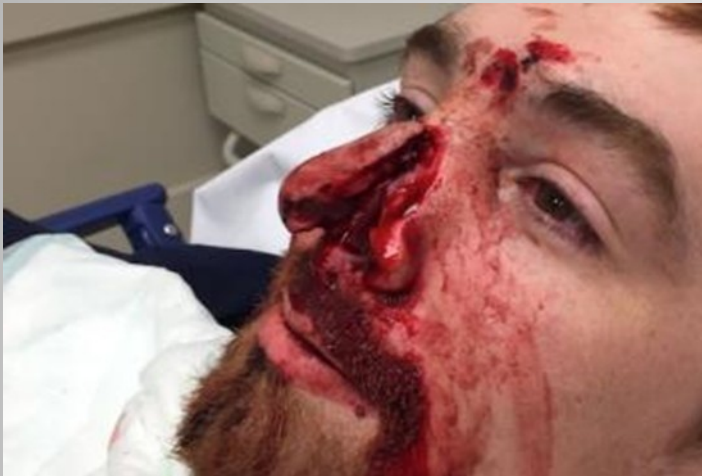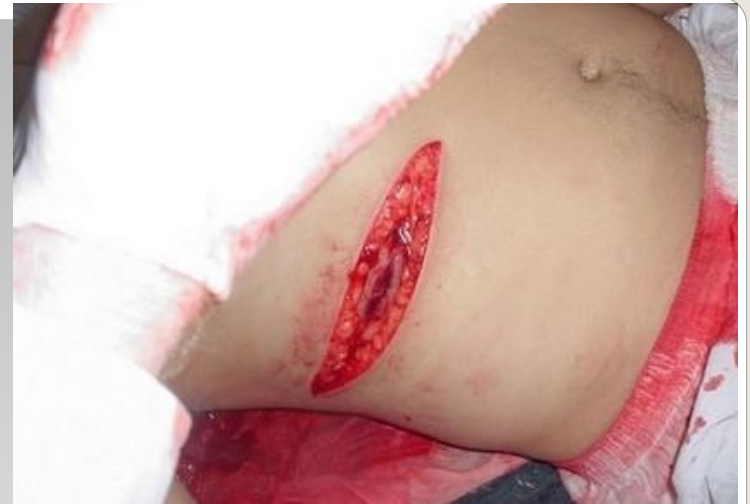Give full forms of the abbreviations and numbers

- vv. scissa dig. II-III manus l. sin.

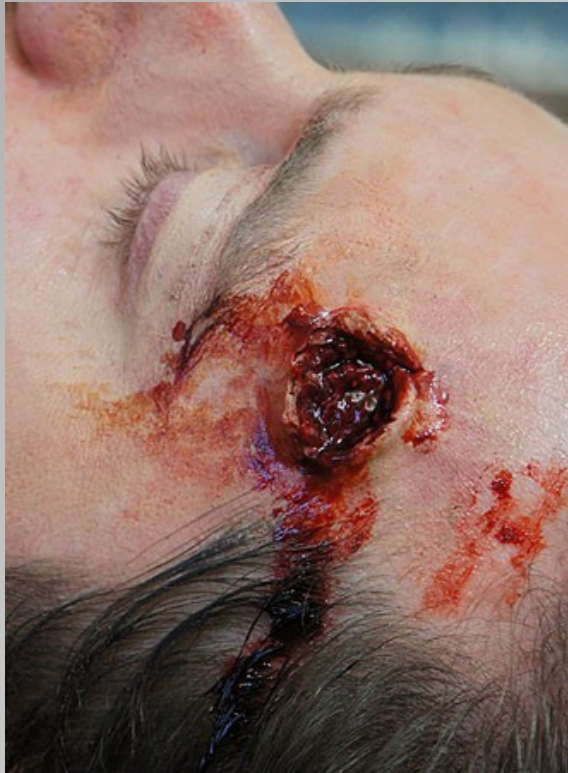

▶ vulnera scissa digiti secundi
et tertii manus lateris sinistri

A **cut wound** = a wound caused by falling of a sharp object, typically an axe or a knife...



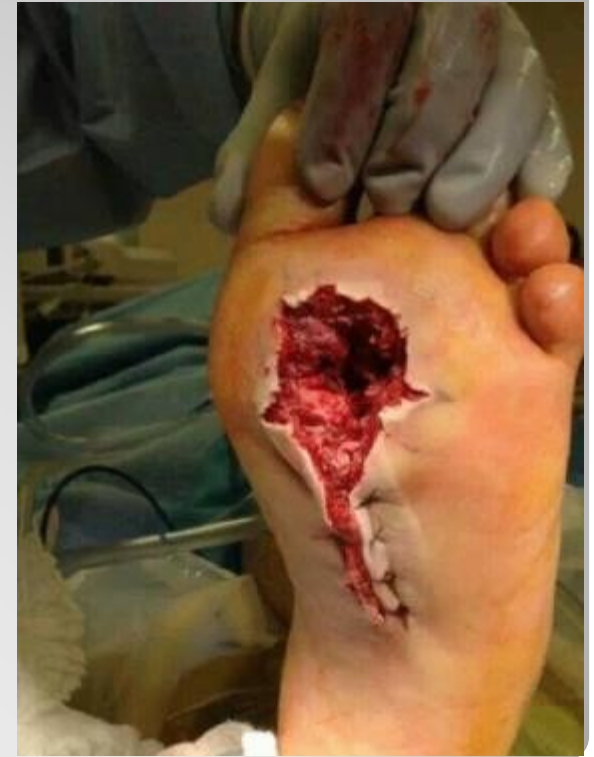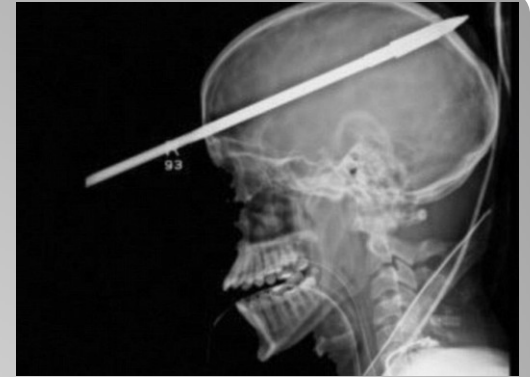Vulnus sectum



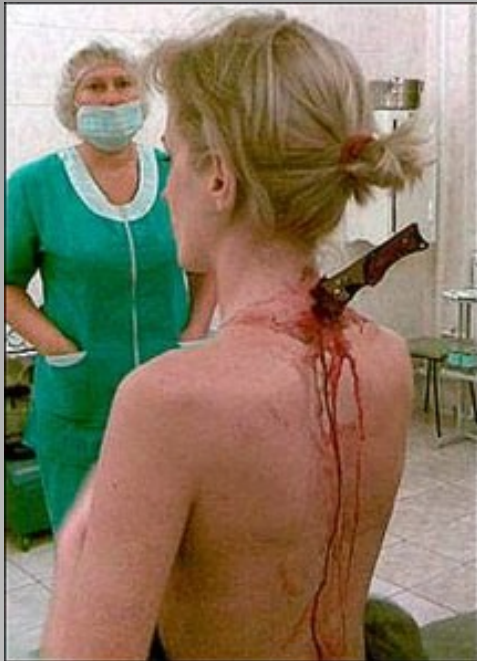A **gunshot wound (GSW)** (**ballistic trauma** or **bullet wound**)

= a wound caused by the discharge of arms or munitions.

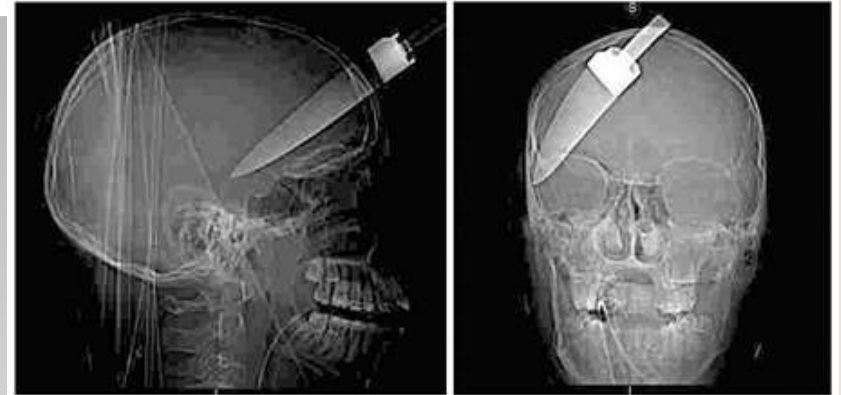
Ballistic trauma can be fatal or cause long-term consequences.



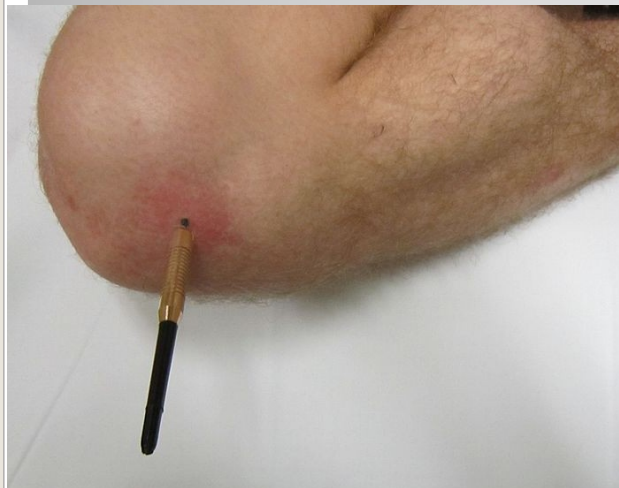Vulnus sclopetarium



stab wound



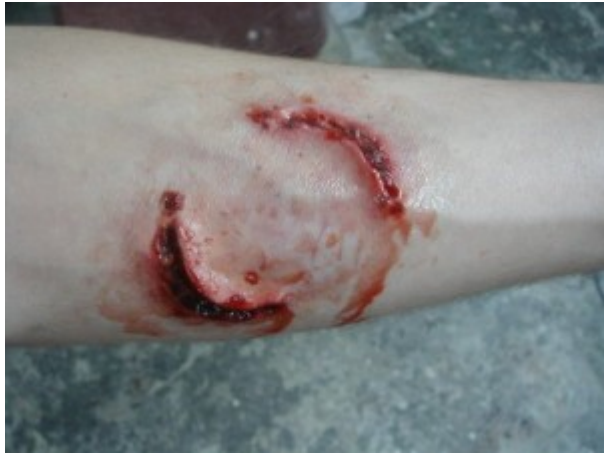= a specific form of penetrating trauma to the skin that results from a knife or a similar pointed object that is "deeper than it is wide".



Stab wounds can occur not only from knives, but also from ice picks, pens, broken bottles, and even coat hangers.

Even though stab wounds are inflicted at a much greater rate than gun shot wounds, they account for less than 10% of all penetrating trauma deaths.

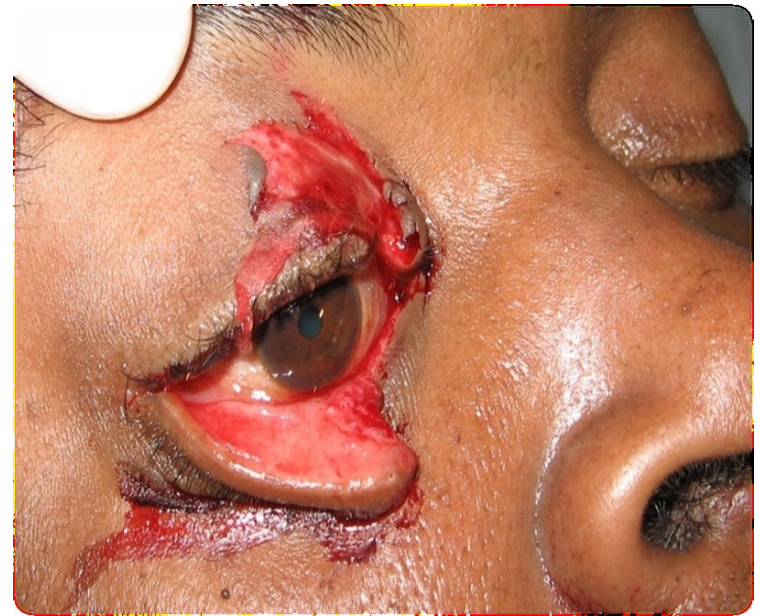Vulnus punctum



vulnus _____ regionis

vulnera

??



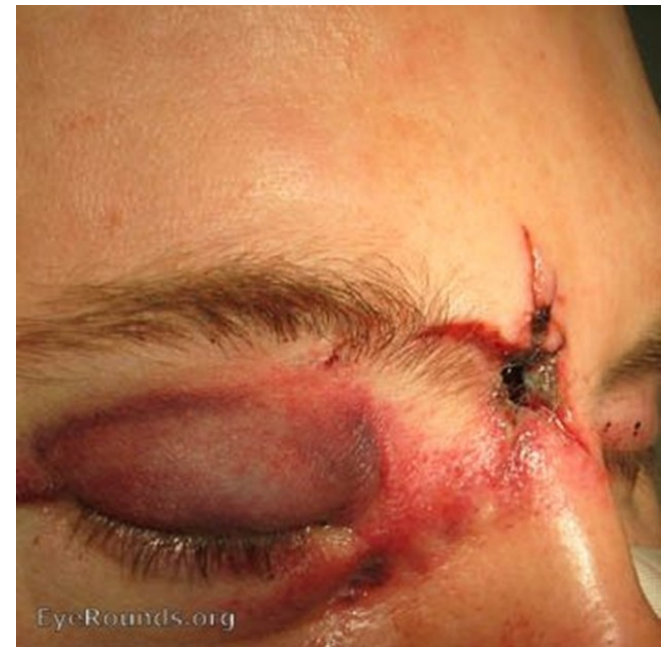

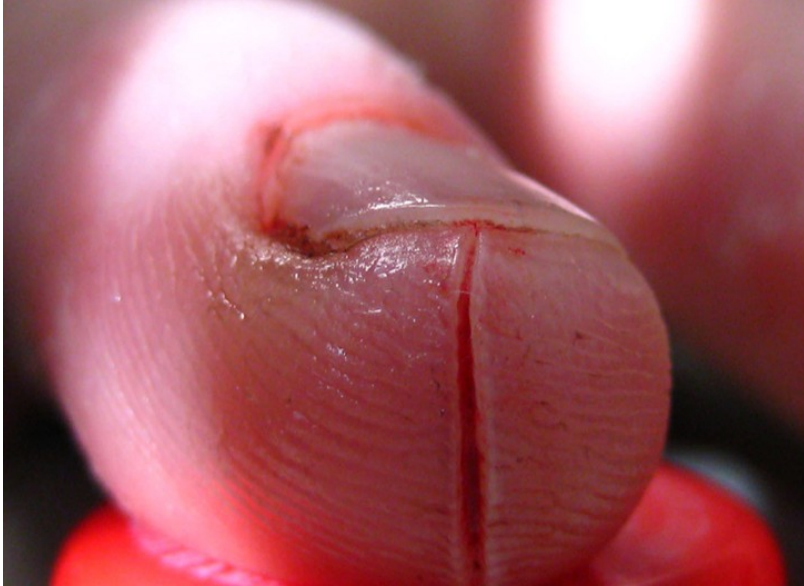vulnus

_____ ???

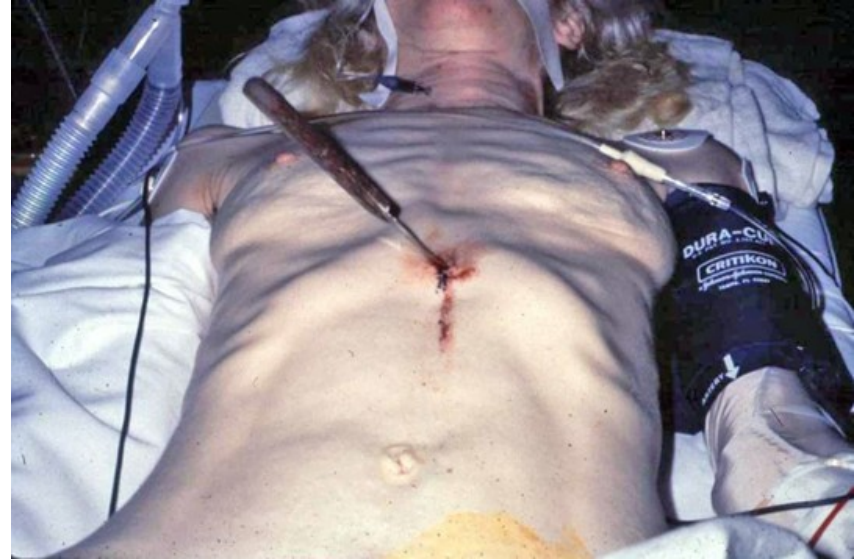mors propter

_____ ?

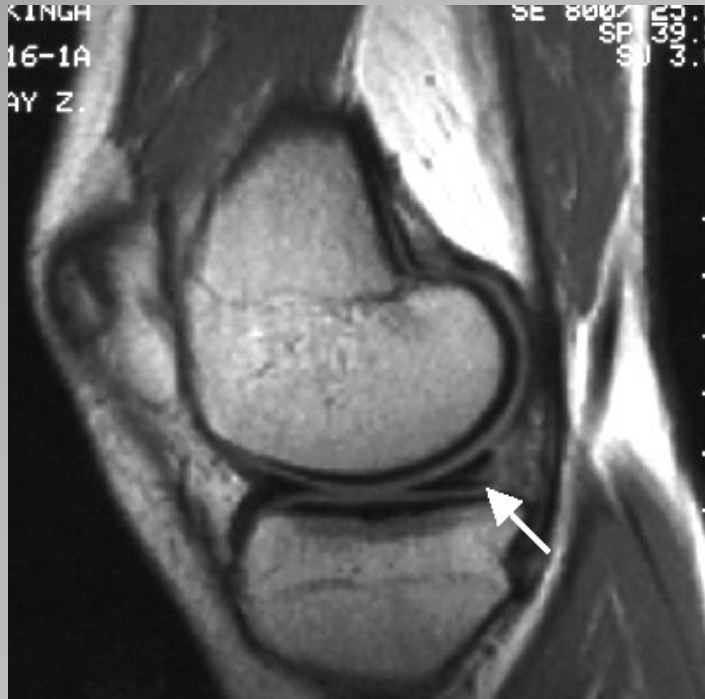



???

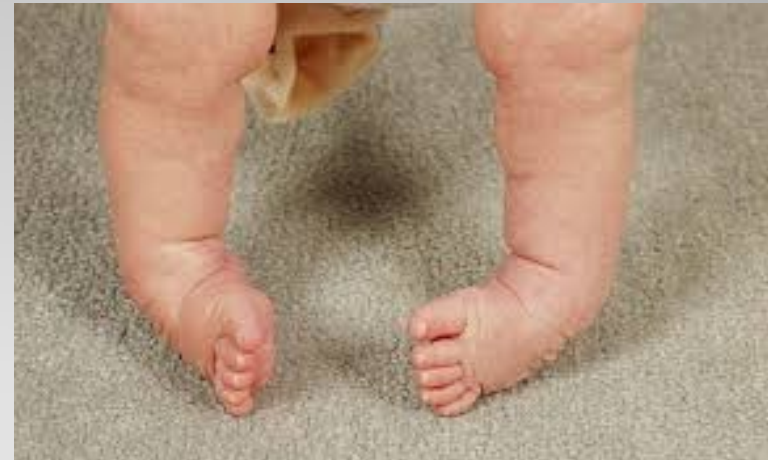

Torn meniscus



= any damage of an organ or tissue that leads to its damaged function

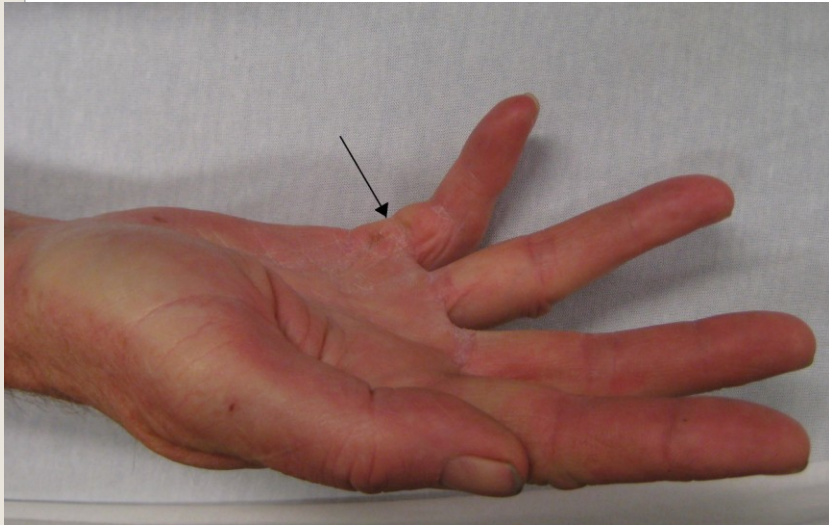
club foot in a baby



= permanent bodily malformation of the shape of and organ or part of the body

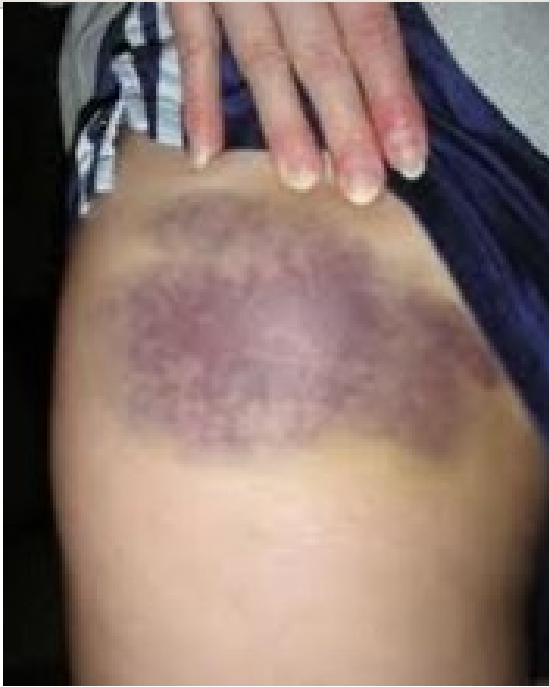laesio, onis, f.

deformitas, atis, f.



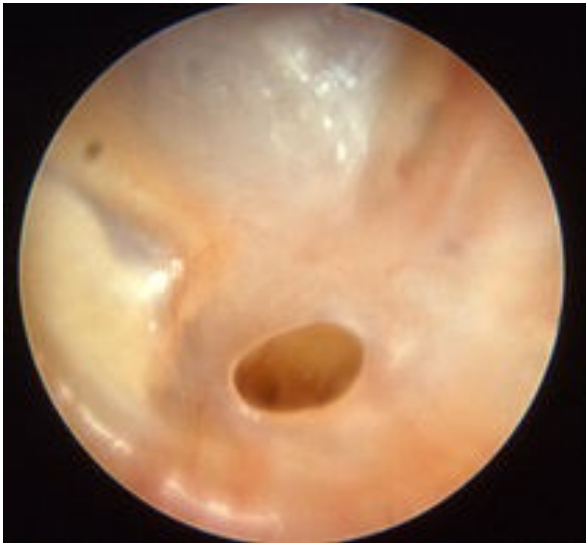*laesio – ligamentum –
musculus – flexor –
digitus – minimus –
manus – latus – sinister*

ENDINGS??



*vulnus contus__ femor__
dextr__ cum haematomat__*

MISSING ENDINGS??



*perforatio membranae
tympani*

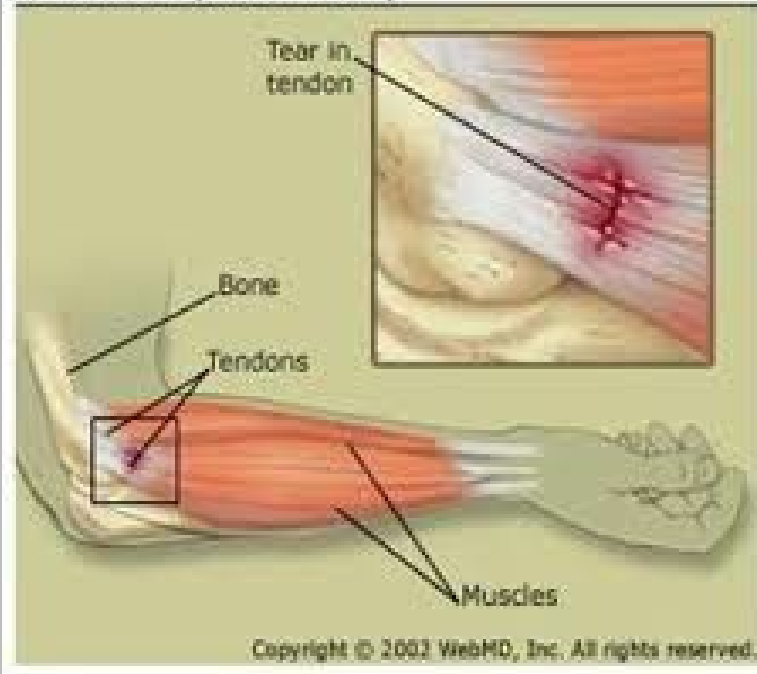
status post

??

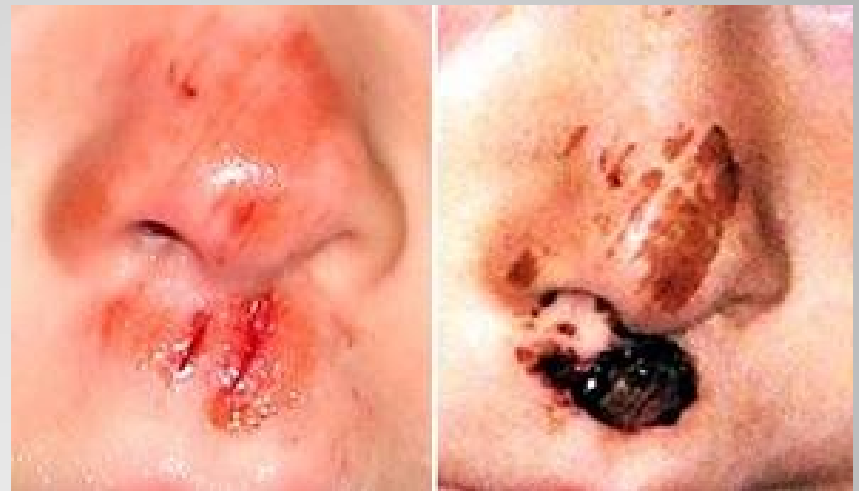?

a strain (of muscle,
ligament, etc.)

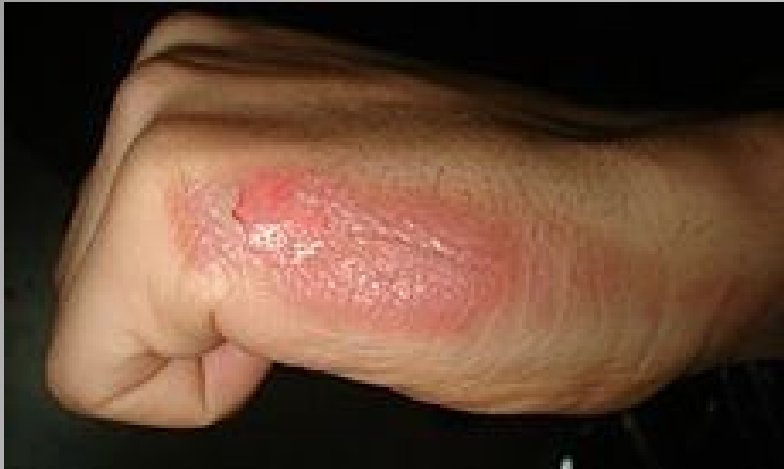Tendinitis (Elbow strain)



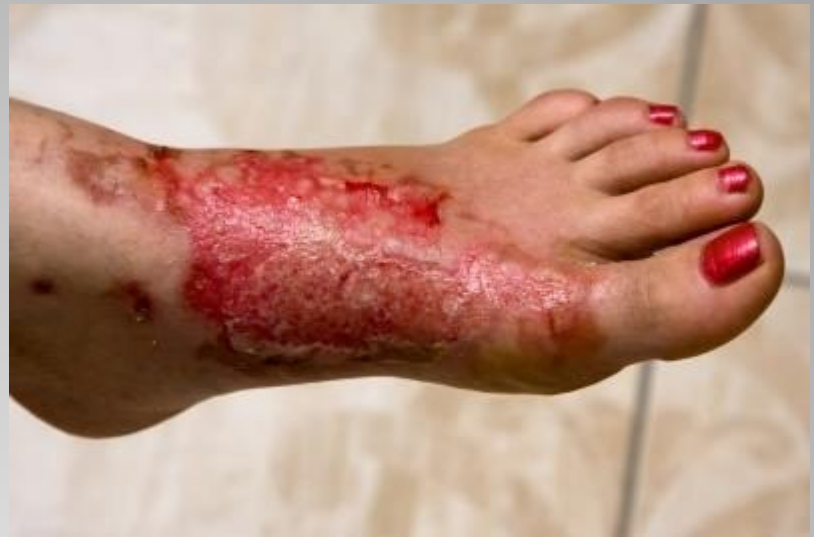a scratch or abrasion
of skin



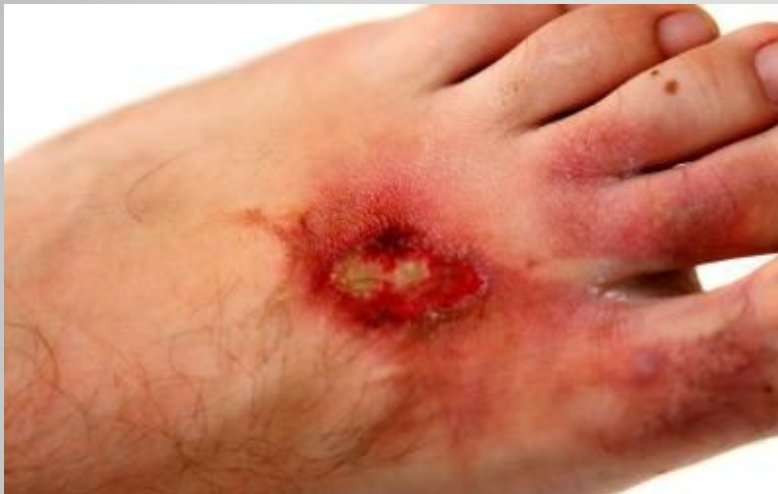distensio, onis, f **excoriatio, onis, f.**



2nd degree/grade burn



3rd degree/grade burn



infected burns

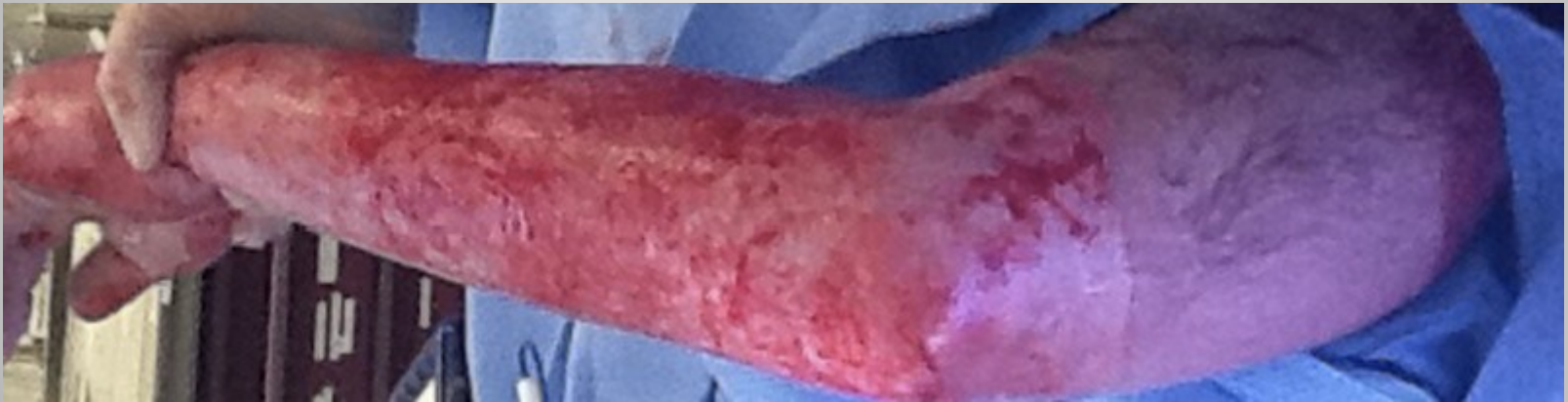
-change in the color of the skin around the burn, swelling, strange odor, the wound sinks deeper into the skin and gets larger, green or yellow pus develops, a fever

Combustio, onis, f. = a burn

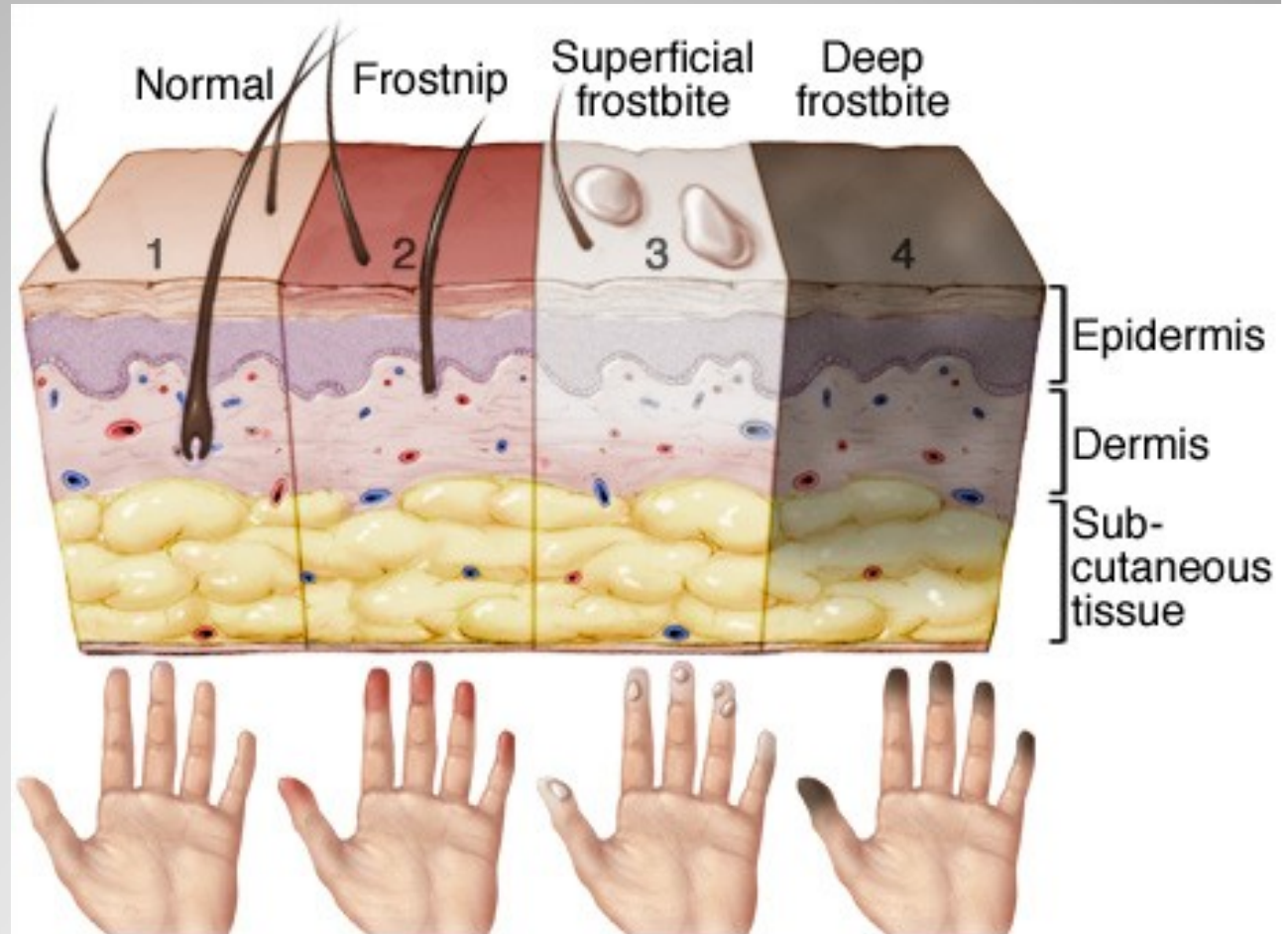
Write a diagnose of this second degree burn

- Combustio antebrachii l. sin. gradus secundi

*gradus, us, m. = degree, stage – always expressed in Genitive!

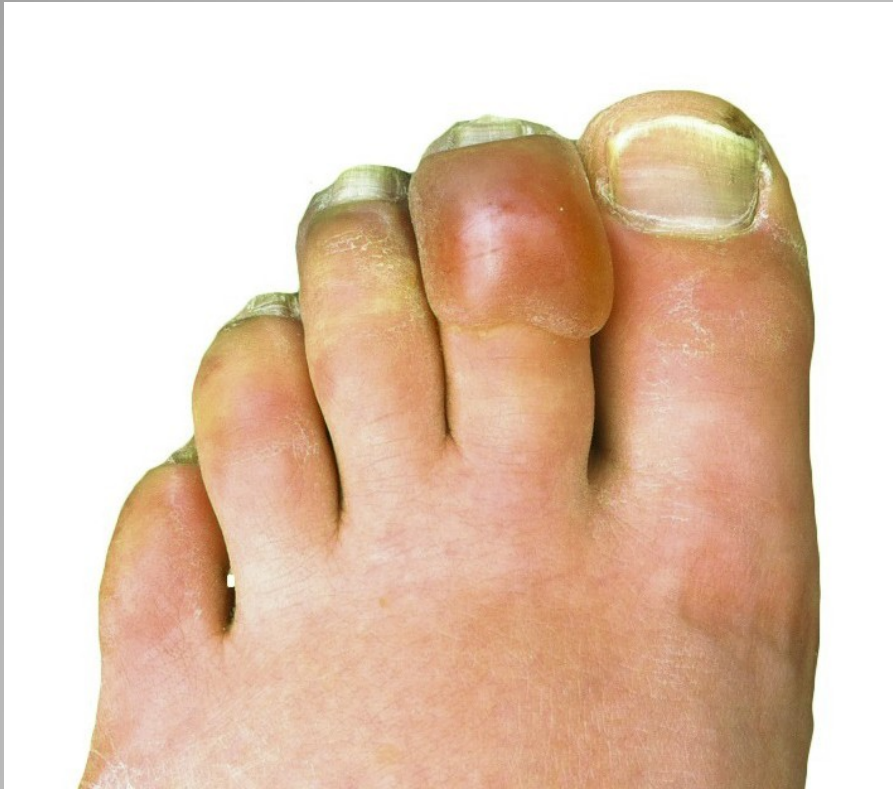

frostbite

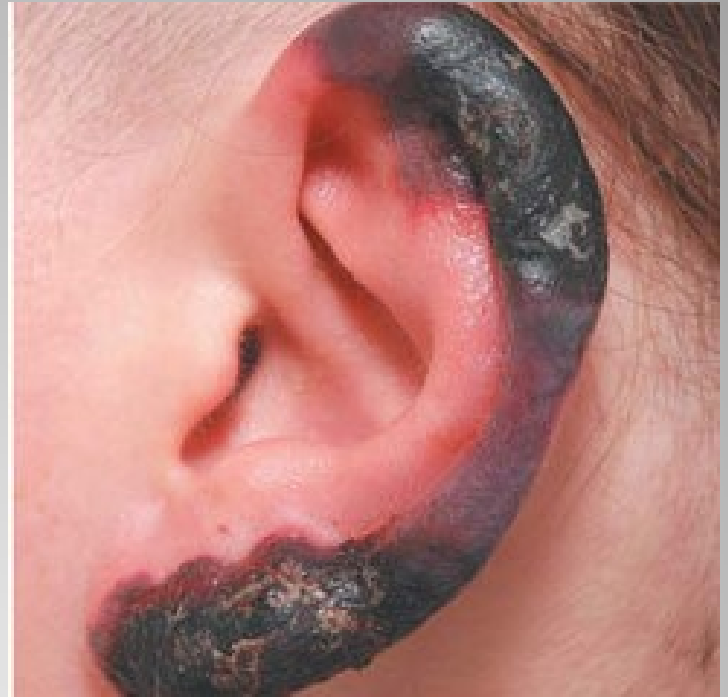

© MAYO FOUNDATION FOR MEDICAL EDUCATION AND RESEARCH. ALL RIGHTS RESERVED.

Congelatio, onis, f.

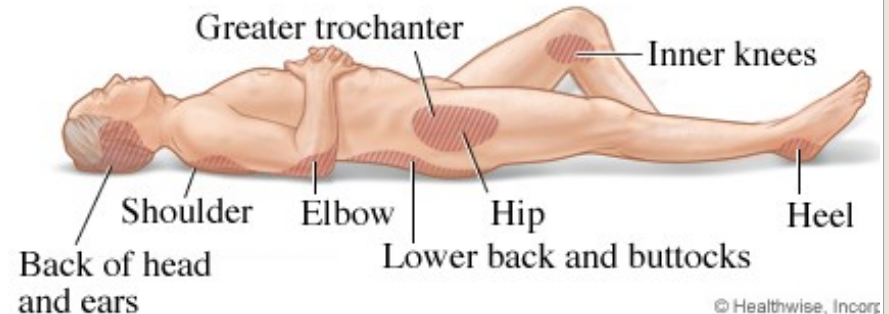
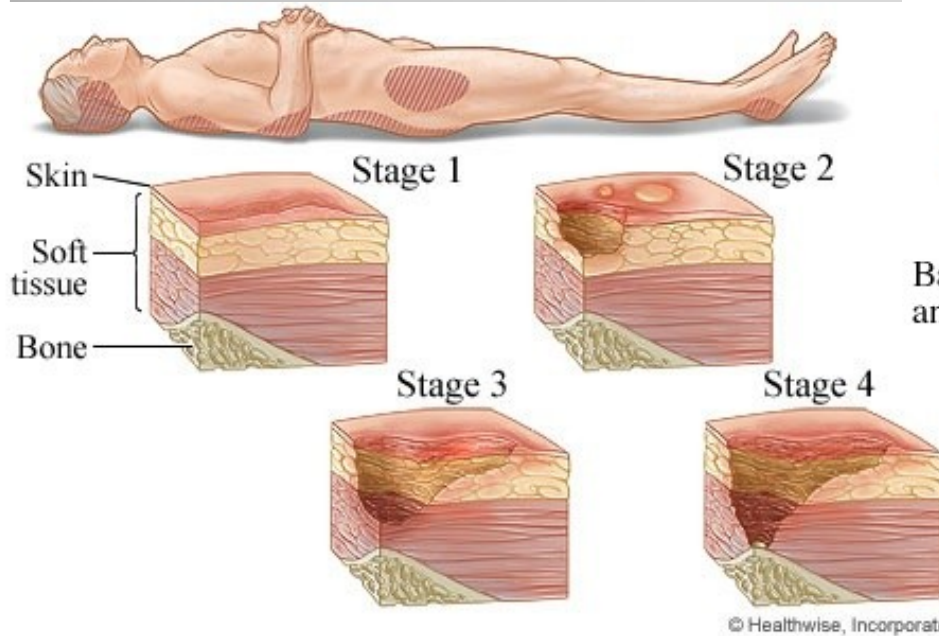
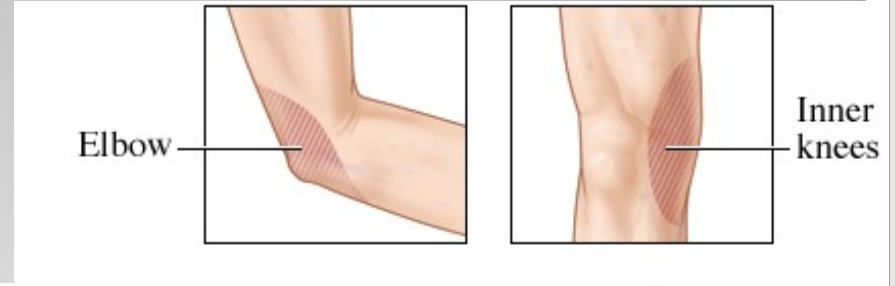


Congelatio digiti secundi
pedis l. sin.

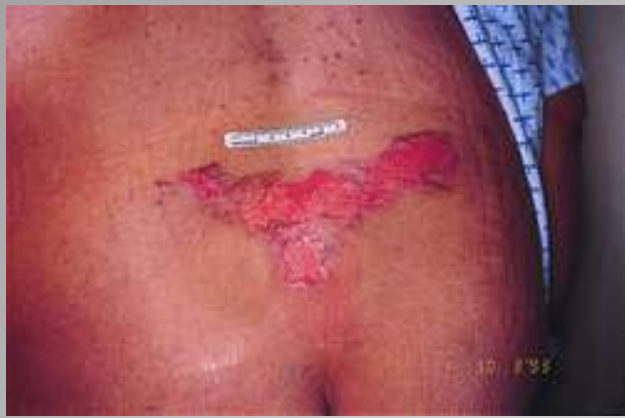

Congelatio auriculae
l. dx./ l. sin.

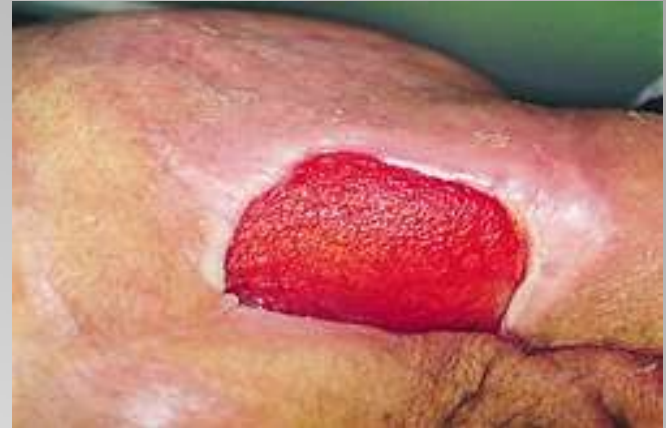bedsore = a pressure ulcer due to local interference with circulation; persons most at risk are those who are emaciated (nutritionally deficient in protein), obese, immobilized by traction or anything else, diabetic, or suffering from a circulatory disorder.



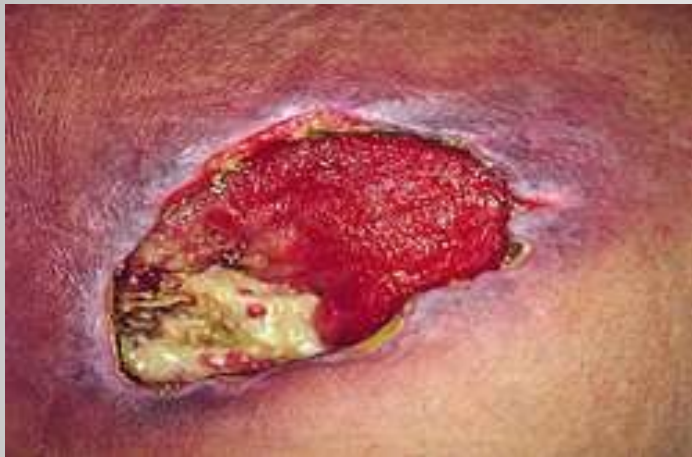Decubitus, us, m.



stage 1 pressure ulcer



stage 2 pressure ulcer



stage 3 pressure ulcer

Decubitus, us, m.

- fractura – luxatio – distorsio
 - contusio
 - commotio
 - perforatio
 - laceratio
- haematoma
 - abruptio
 - laesio
- distensio

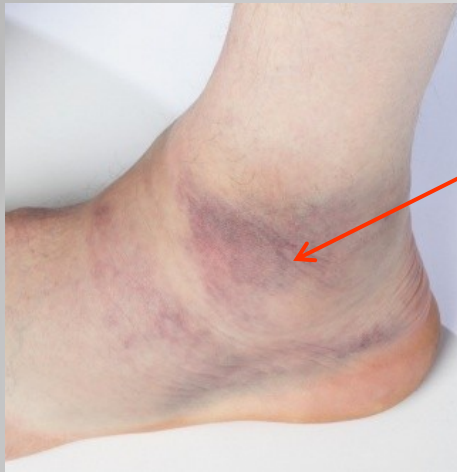Internal injuries

OS = ostesynthesis; FE = ferrum (iron)

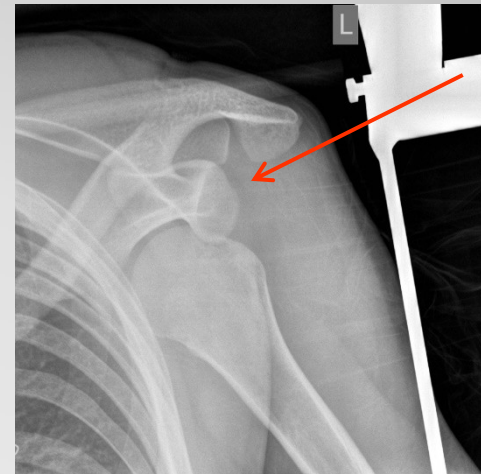
S8220 Fr. cruris l.sin cum fr.fibulae duplex disloc.aperta
stp. OS FE 17.7. 2010

S332 Luxatio art. SI l. sin stp. reposit. 17.7.
articulationis sacroiliacae repositionem

S818 Decollement partis proximalis cruris l.sin.
= severe damage of soft tissues



Vulnus contusum/distorsio
tali/malleoli l. sin.

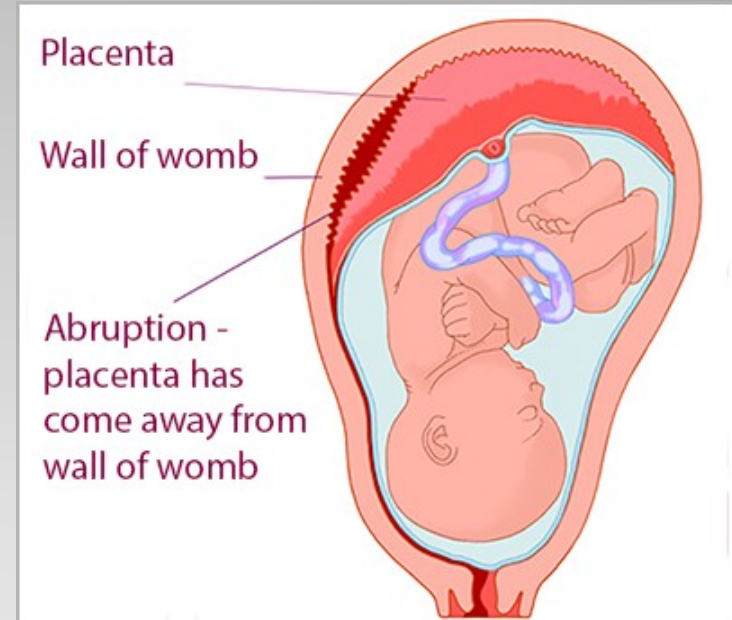
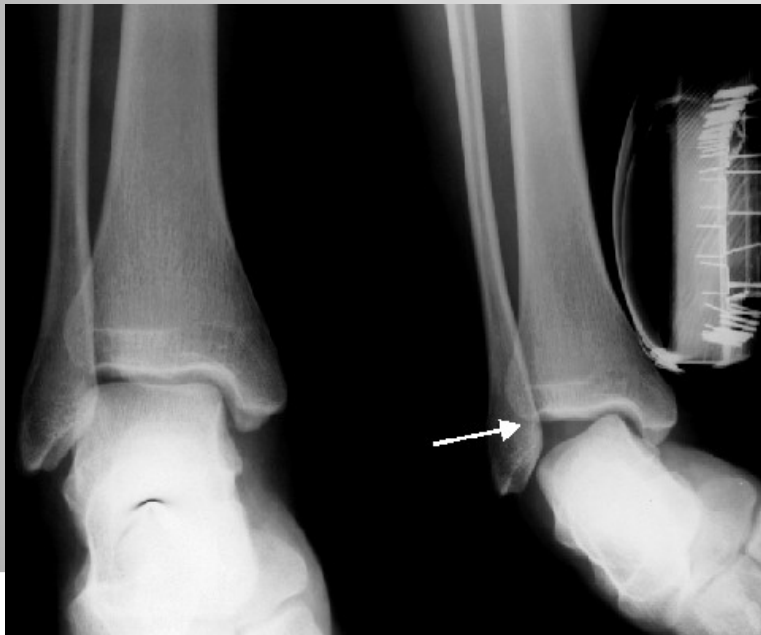

Luxatio (capitis) humeri
l. sin.

Bones, ligaments, soft tissues

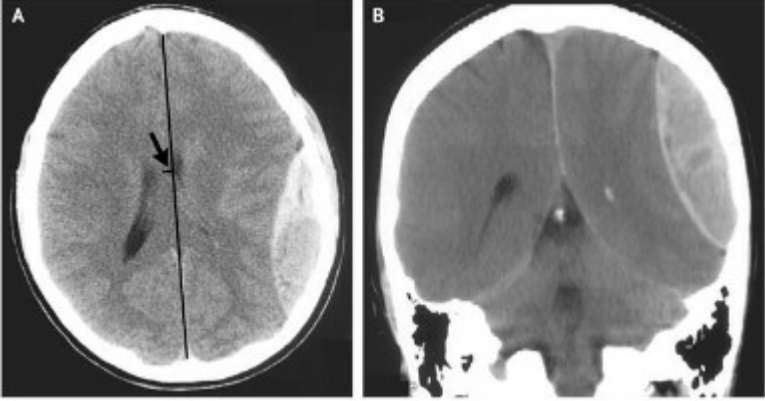
distorsio, onis, f.

= a joint injury in which some of the fibers of a supporting ligament are ruptured but the continuity of the ligament remains intact



= a tearing away, separation, or detachment

abruptio, onis, f.

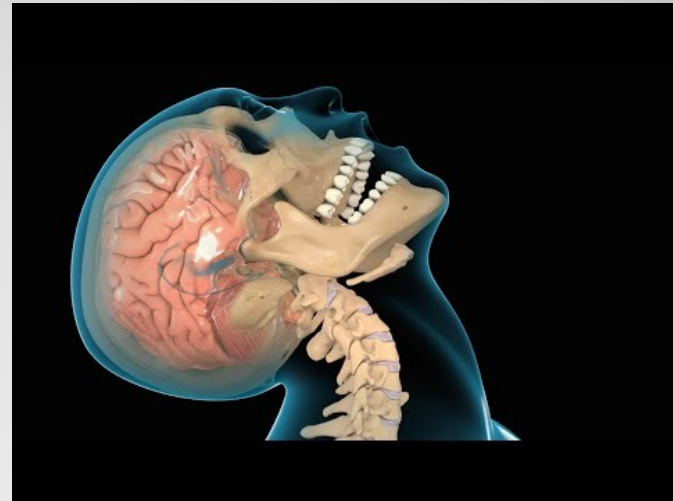


epidural haematoma in the left parietal region

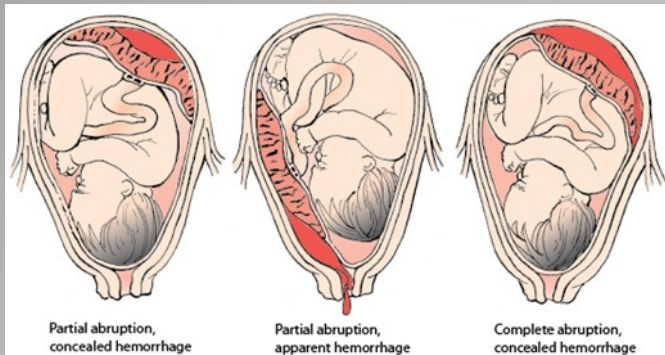
haematoma epidurale reg. parietalis l.sin.

traumatic brain injury (TBI) ?

commotio cerebri



Organs, soft tissues



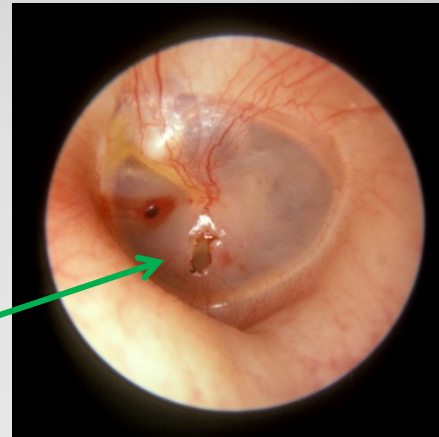
partial abruption of placenta in the 36th week (+ 4 days) of pregnancy?

abruptio placentae partialis in grav. hebd. 36+4

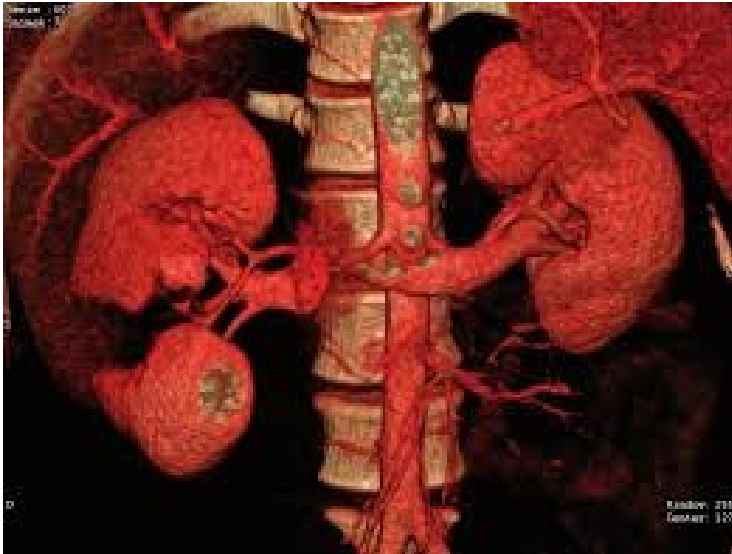in graviditatis hebdomade

traumatic perforation of the tympanic membrane in the right ear ?

perforatio tympani l. dx. traumatica

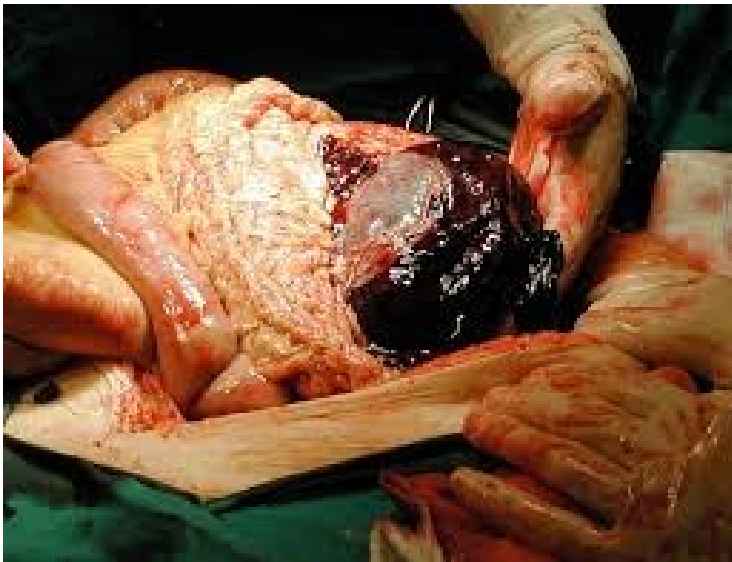

Organs, soft tissues



laceratio

_____??



contusio lienis

mors propter

_____??

Dg: T068 Polytrauma

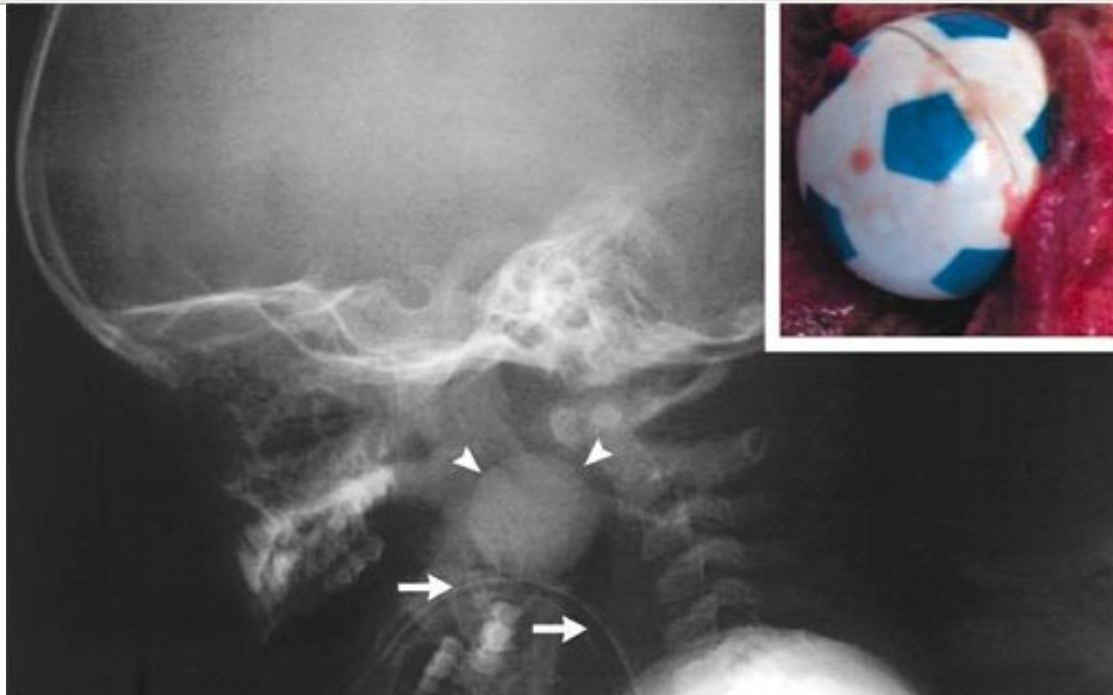
V1701 Cykl.řid.x pev.přek.;neprov.neh.;volný čas
S0640 Haemorrhagia epidurale reg. temporale l.sin
F100 Ebrietas aethylica
S0601 Commotio cerebri
S0240 Fr.compl. zygomaticomaxillaris l.sin cum hemosinus sphenoid
S4201 Fr.claviculae l.sin apeta
S4210 Fr. scapulae l.sin comminutiva
S0210 Fr.allae ossis sphenoidalis l.sin cum hemosinus sphenoid.
S2240 Fr.costarum II-IV hemithoracis l.sin
S2700 Pneumothorax traum. reg. dorsobasale l.sin /dle CT/
S2720 Fluidothorax l.sin. min. dle RTG
S2730 Contuio pulmonisl.sin, reg.dorsobasale
S407 Excoriationes extrem.super. l.sin multipl.
S607 Excoriationes digitorum manuum bilat.
S013 Dilaceratio auriculae l.sin
S708 Excoriationes extrem. inf. l.sin multipl.

- 1) **problem**: *Nominative*
 - fractura; corpora aliena; subluxatio
- 2) **localization**: *Genitive* (rarely preposition)
 - cruris l.dx.; calcanei; circum genu
- 3) **further specification** of the problem:
 - traumatica; non dislocata; comminutiva

Basic structure of a diagnose

- Side expressed by **l.sin./l.dx.**
- The specifying **adjective** usually stands **in the end**:
perforatio tympani l. dx. traumatica
- **Abbreviations** - *disloc., comm., mult.*

Specifics of clinical Latin



A three-year-old boy was playing with a plastic ball while in the backseat of a car. The father heard a gasp, saw that the child was unconscious, and suspected the child to aspirate the toy ball. Emergency personnel intubated the child, no foreign body was visualized then. The child was dead on arrival at the hospital. During the postmortem examination, a radiograph of the head and neck showed *a spherical foreign body located in the oropharynx*. The oropharynx contained a toy soccer ball 2.5 cm in diameter.

A healthy 25-year-old man presented to the surgical clinic with a hole in the roof of his mouth, present for a year, and he requested surgical correction. The patient reported a 5-year history of nasal cocaine use from which he had recently abstained. Examination revealed a *large perforation of the nasal septum and middle palate*. Local complications of intranasal cocaine abuse include *chronic rhinitis, sinusitis, epistaxis, ossification or necrosis of the nasal septum*, and in rare cases, palatal perforation.

