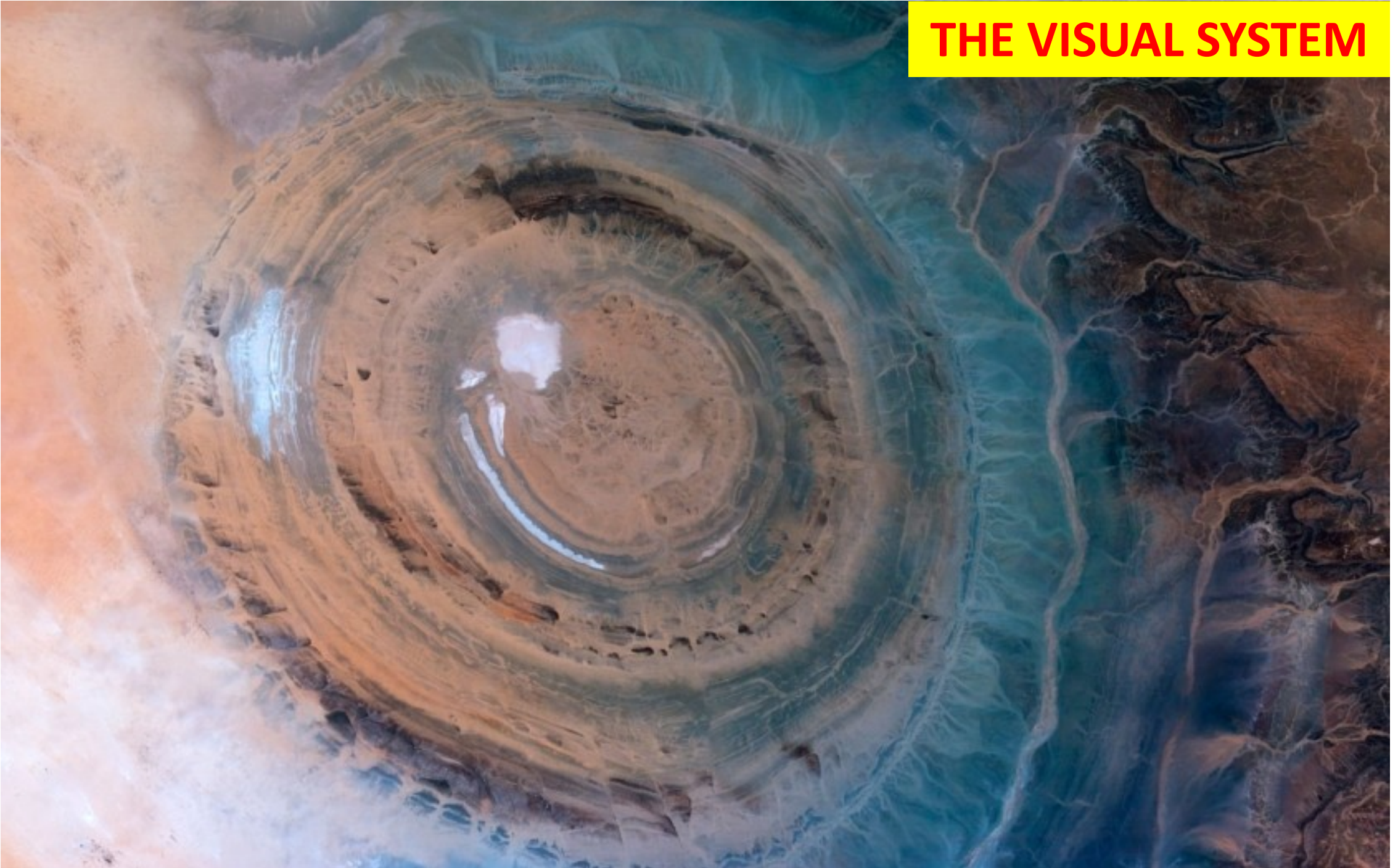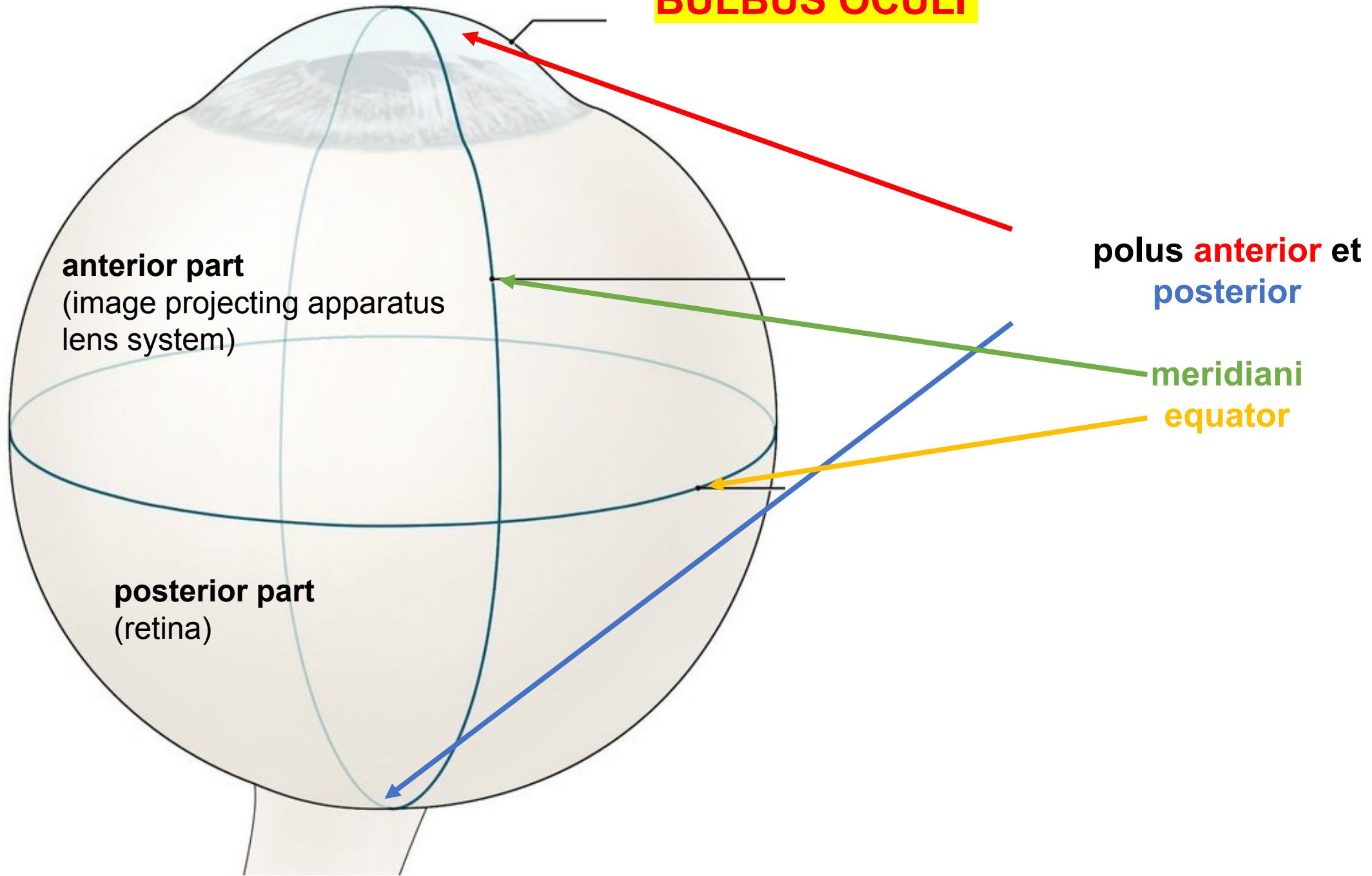
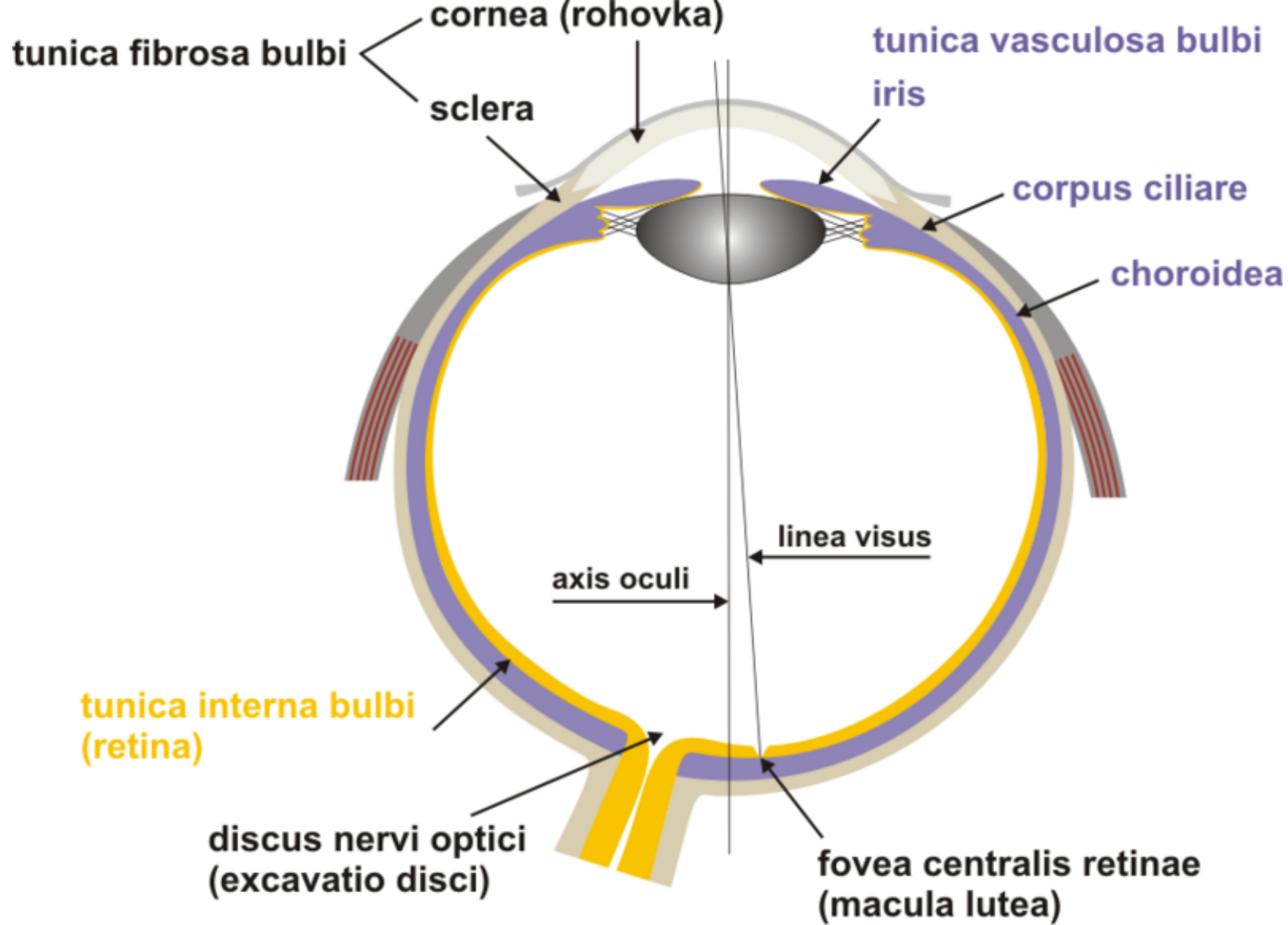


THE VISUAL SYSTEM



BULBUS OCULI





BULBUS OCULI

EYEBALL

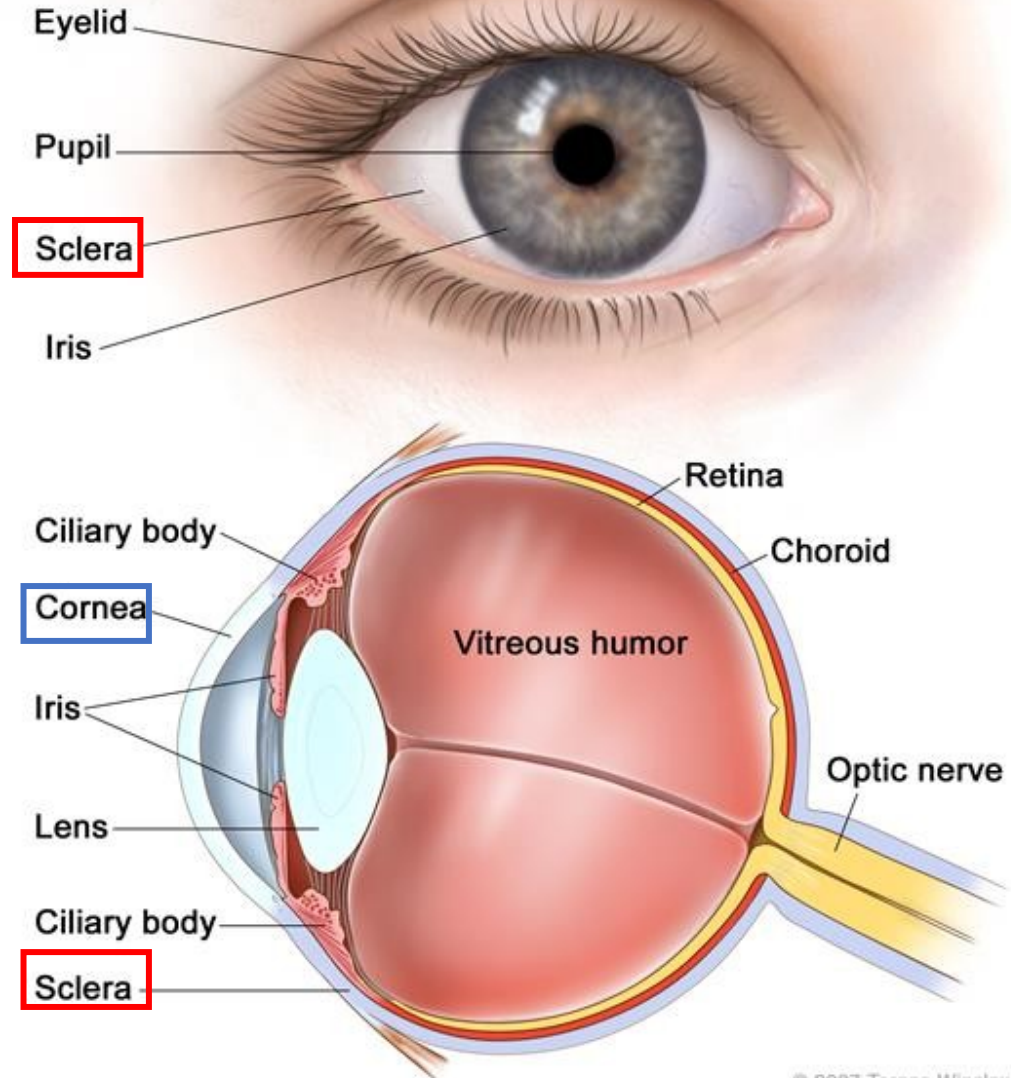
axis bulbi externus
X
linea visus

- 1. Tunica fibrosa**
- 2. Tunica vasculosa**
- 3. Tunica interna (nervous tunic)**

1. Tunica fibrosa

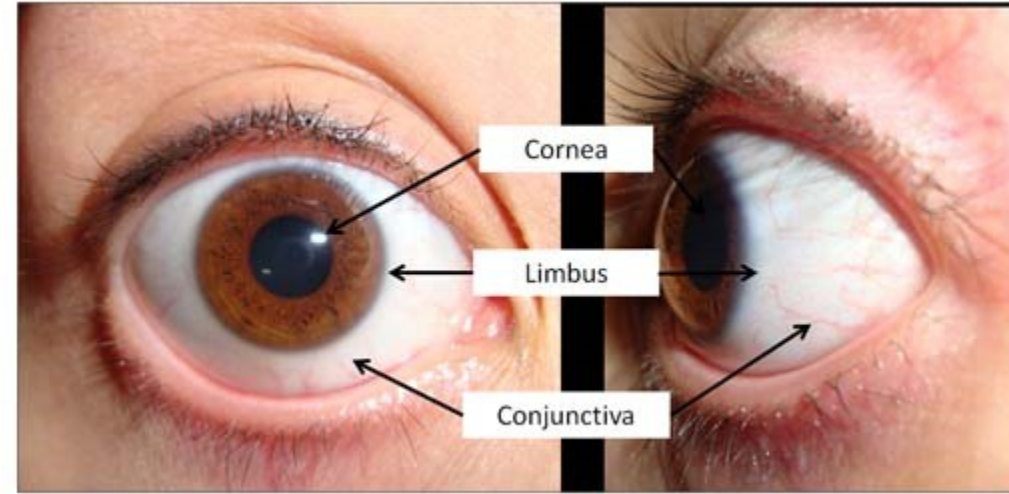
a) cornea – anterior, transparent

a) sclera – posterior, white



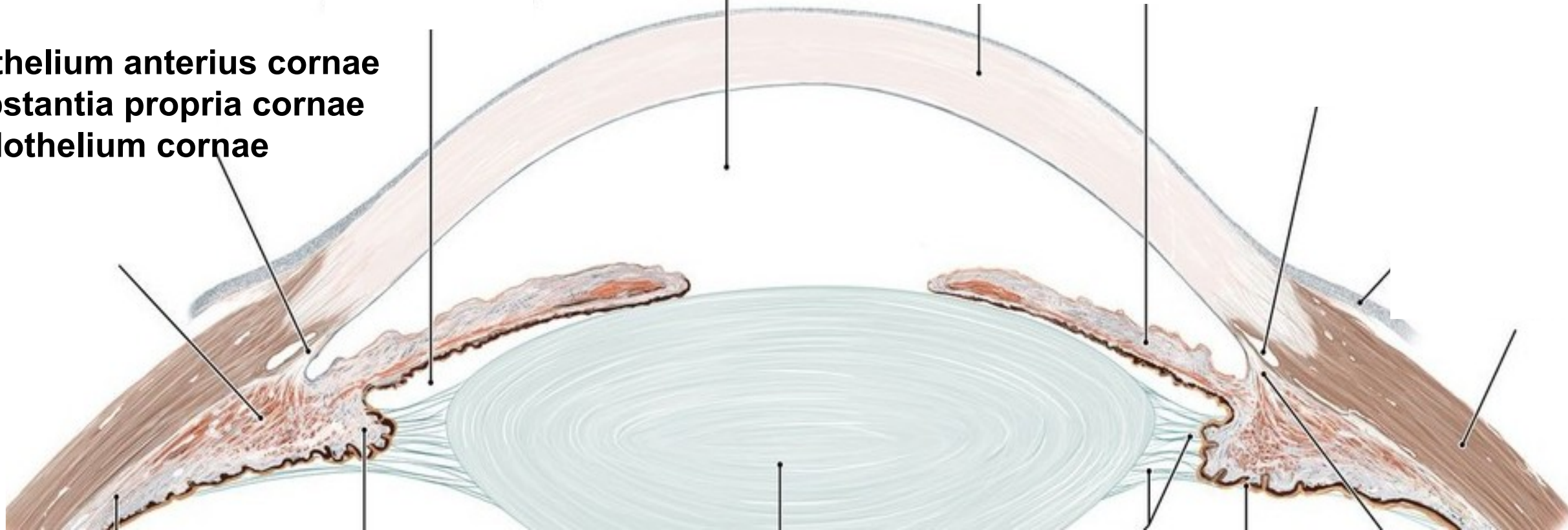
CORNEA

nonvascular, transparent fibrous coat, like a watch glass
it is a part of refractive media of eye

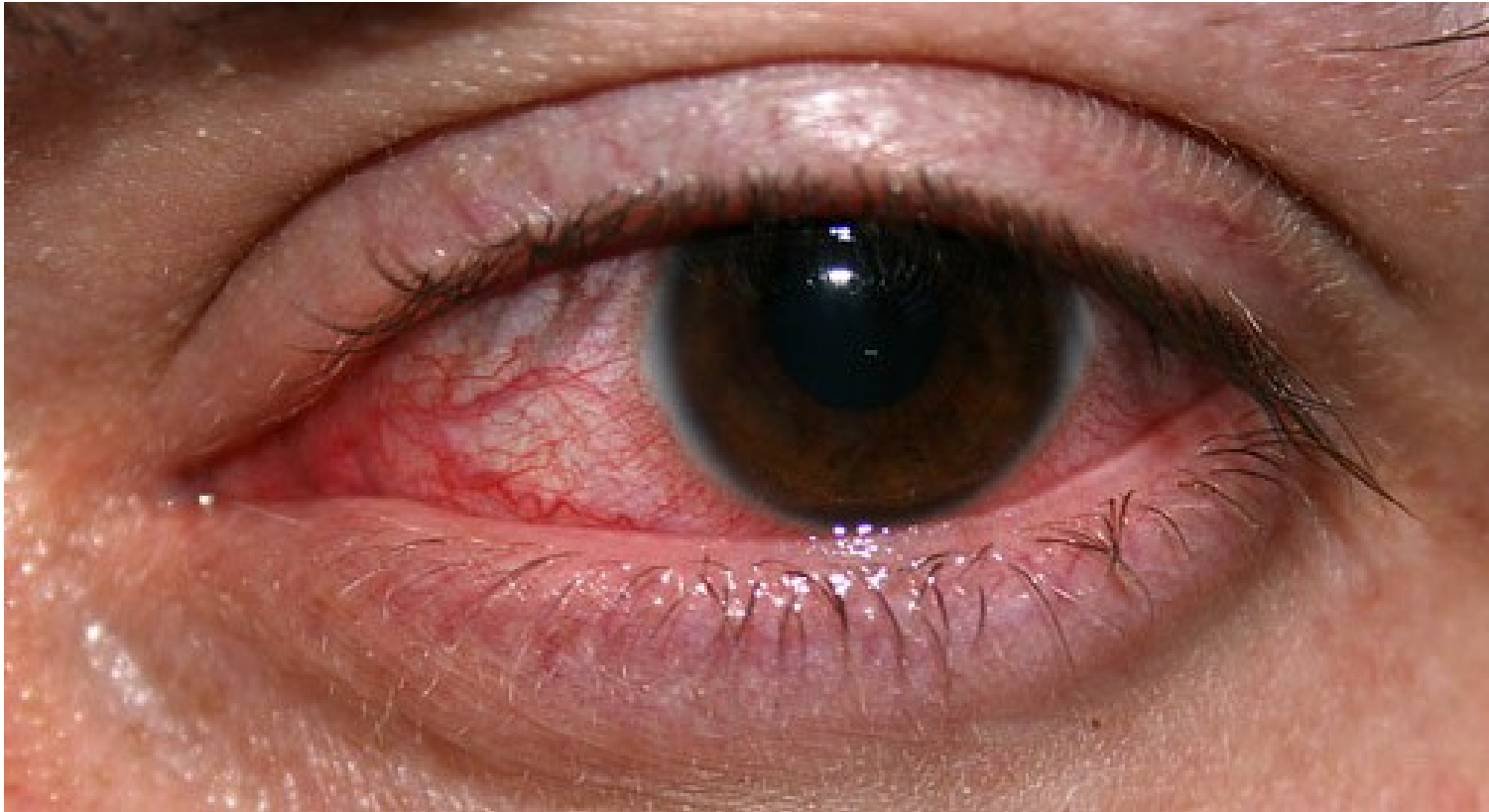

facies anterior (vertex cornae) et posterior
limbus cornae (sulcus sclerae) – sclerocorneal junction

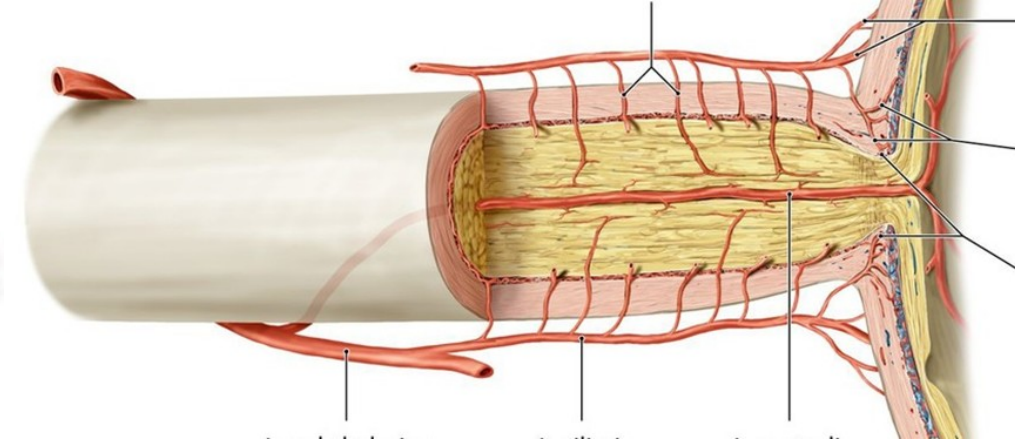
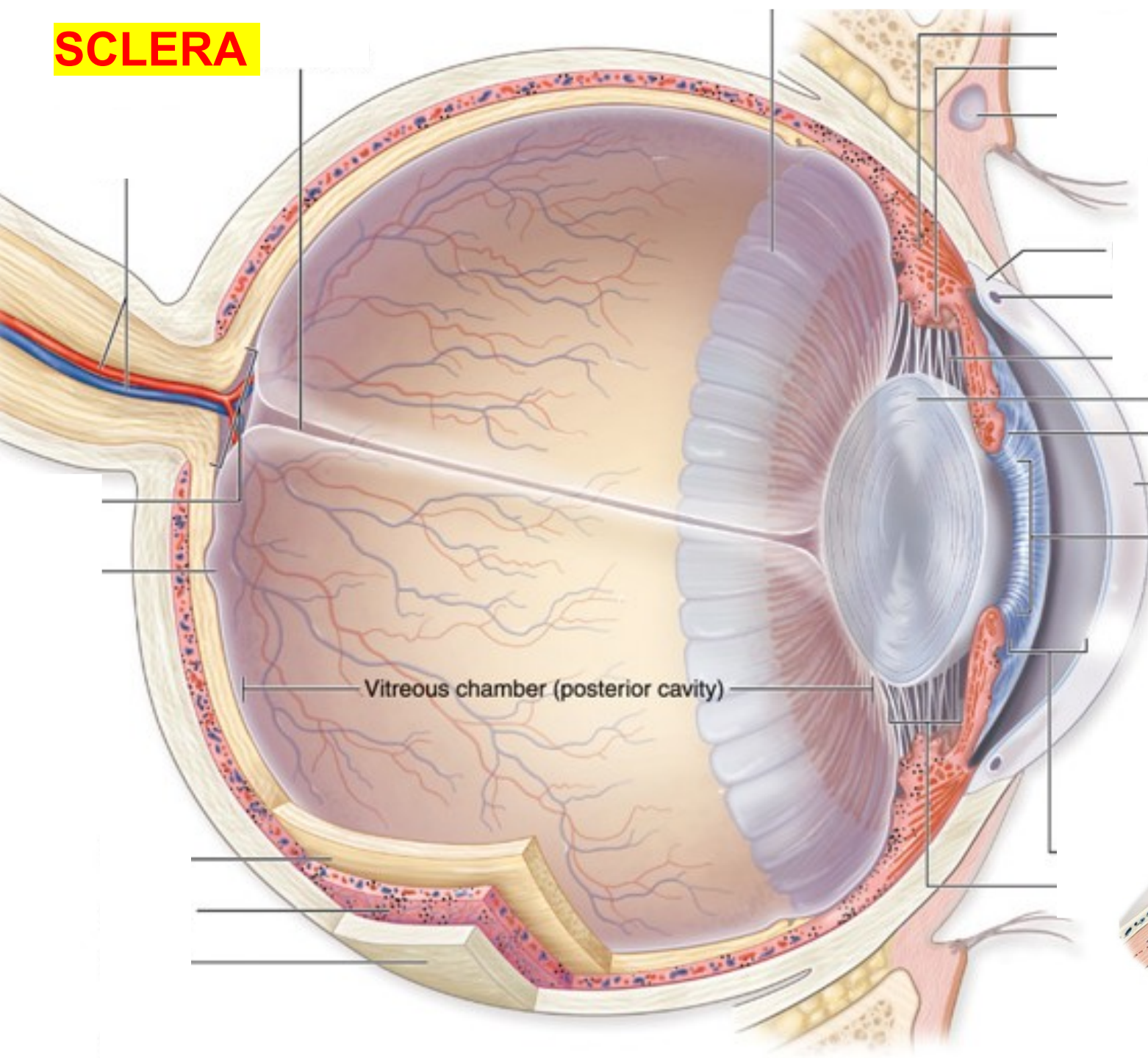
epithelium anterius cornae
substantia propria cornae
endothelium cornae



KERATITIS



SCLERA

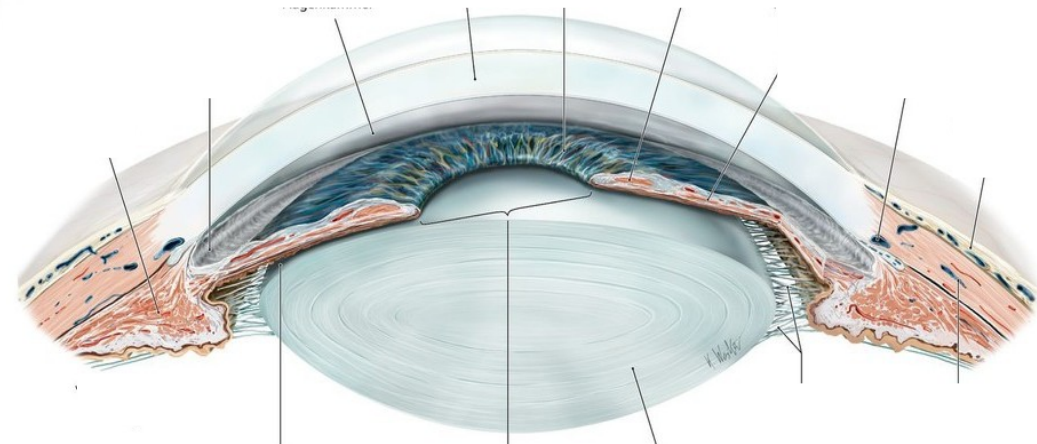


**dense, connective tissue capsule
gives the shape of the eyeball**

limbus sclerae

sinus venosus sclerae

lamina cribrosa sclerae



2. Tunica vasculosa

a) choroidea

b) corpus ciliare

c) iris

Eyelid

Pupil

Sclera

Iris

Ciliary body

Cornea

Iris

Lens

Ciliary body

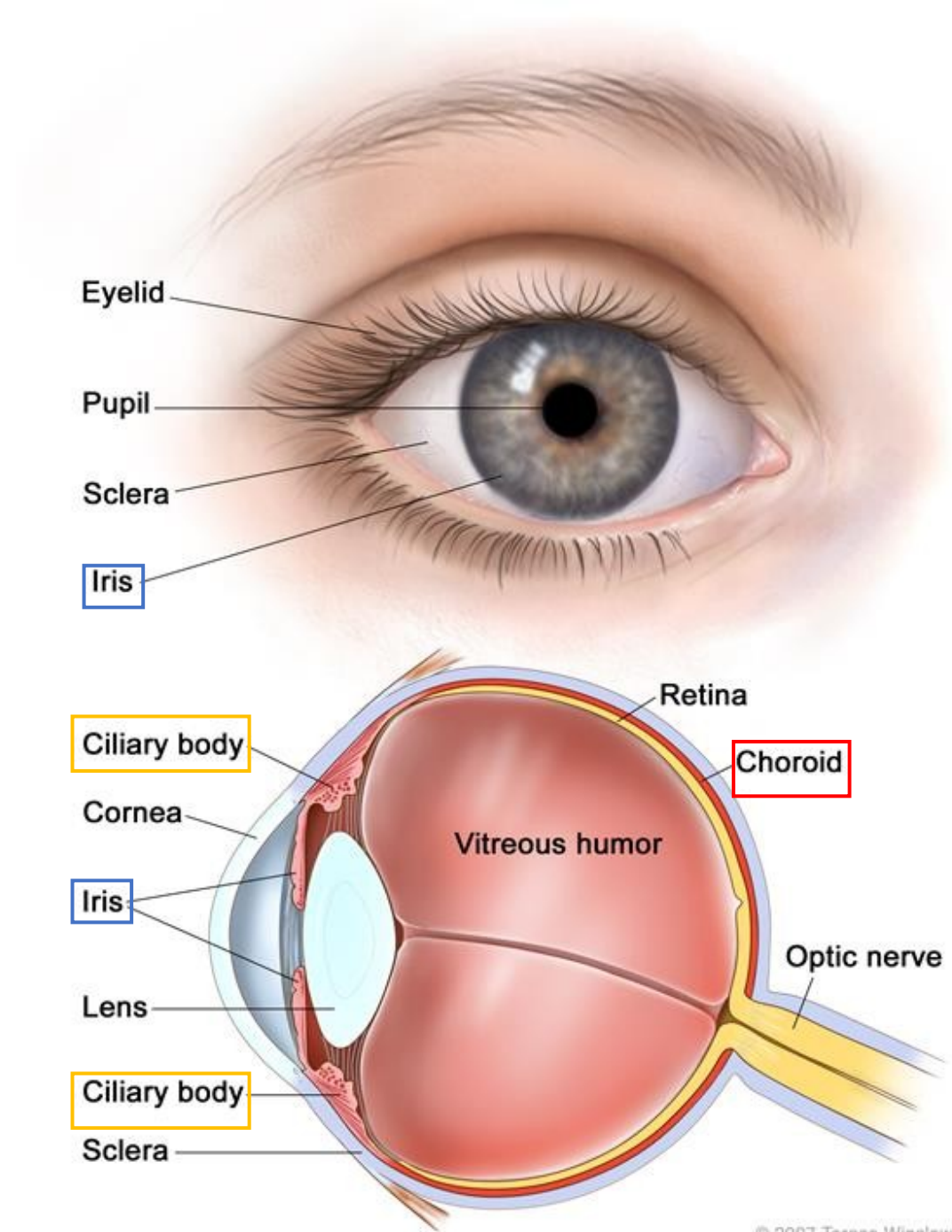
Sclera

Retina

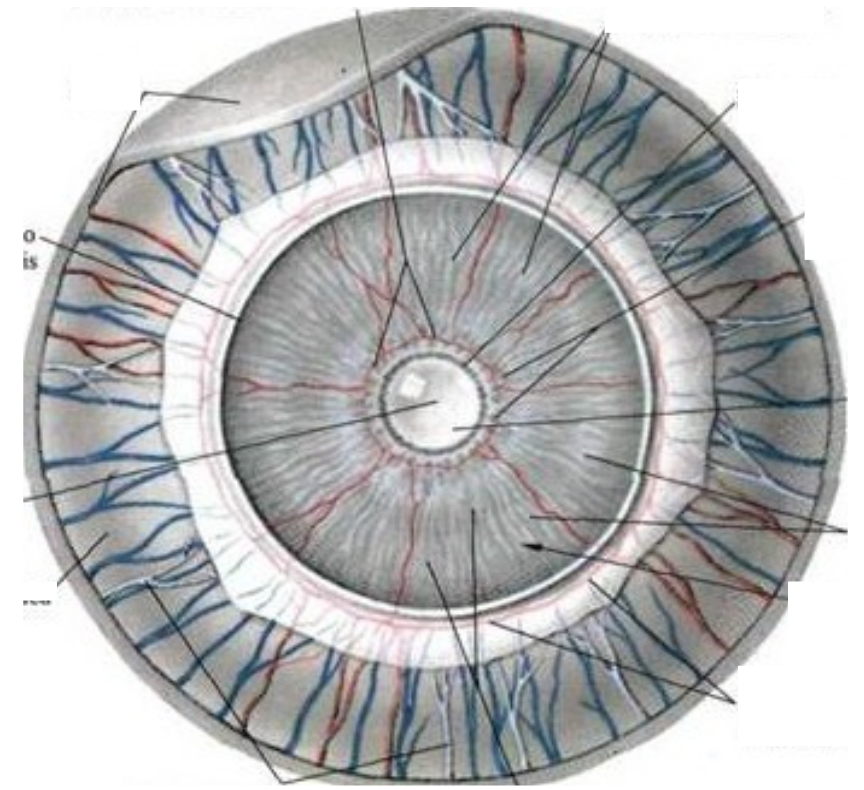
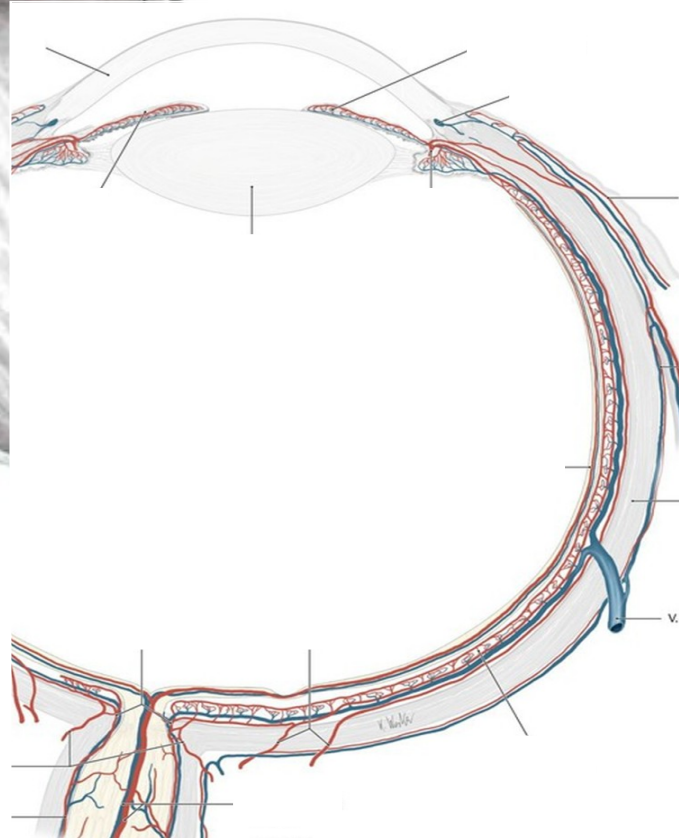
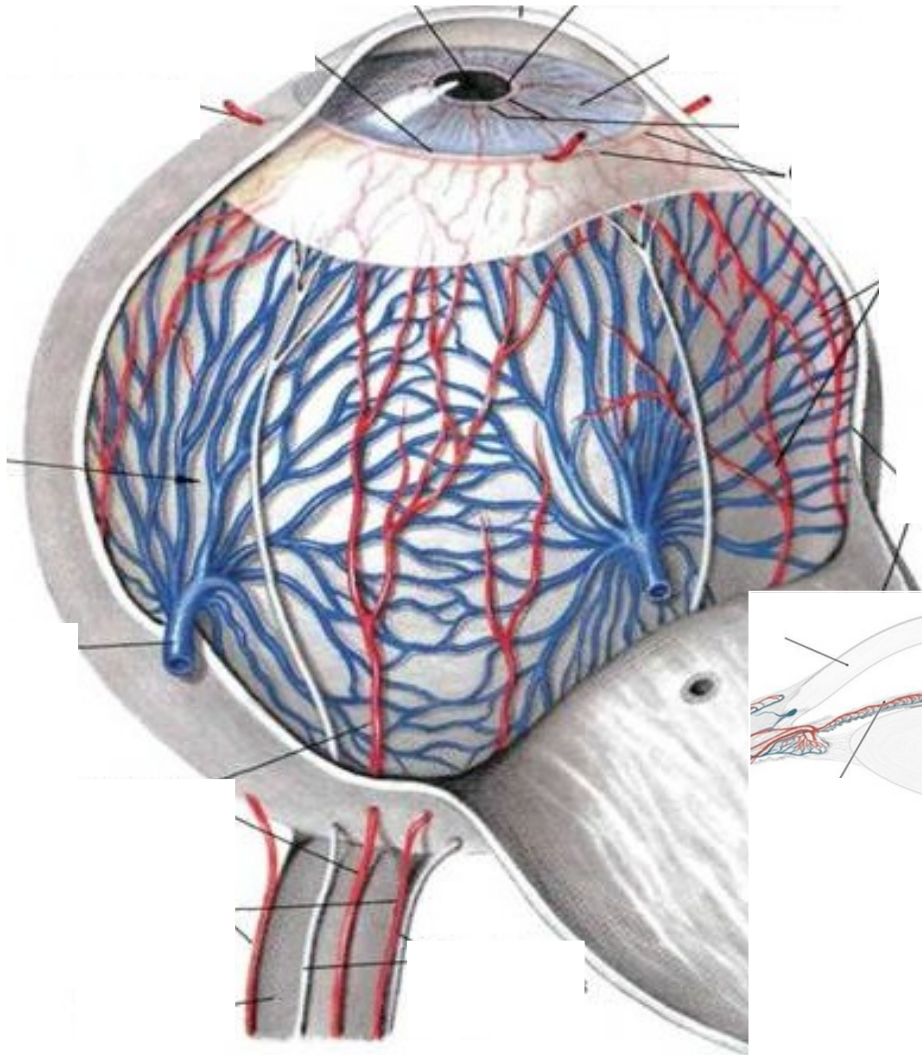
Choroid

Vitreous humor

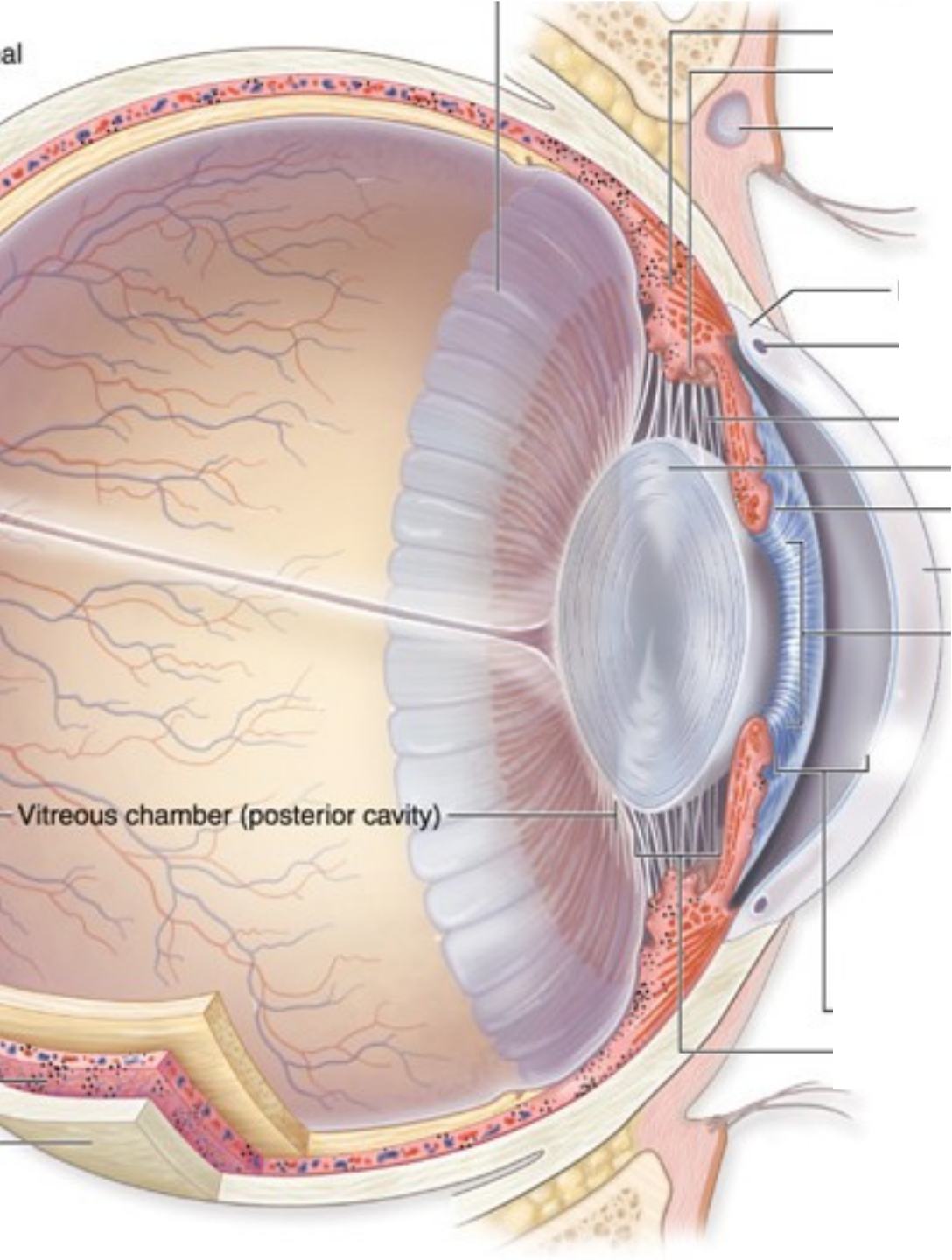
Optic nerve



CHOROIDEA

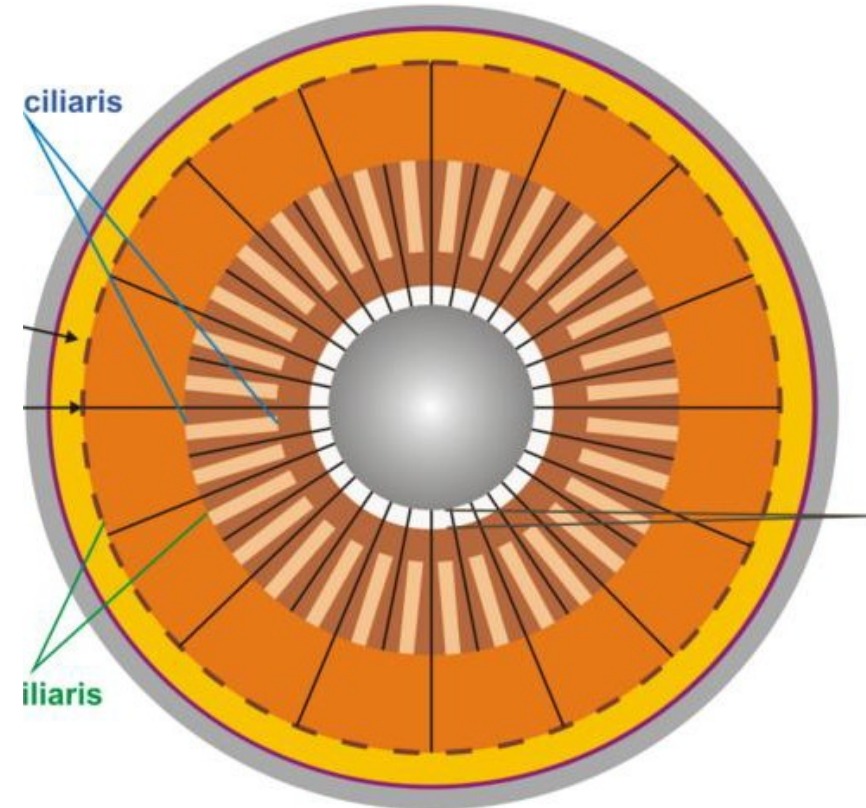


**posteriorly,
highly vascularized – nutrition of retina
brown/black appearance – melanocytes
(melanin)
venous plexuses and layers of capillaries**

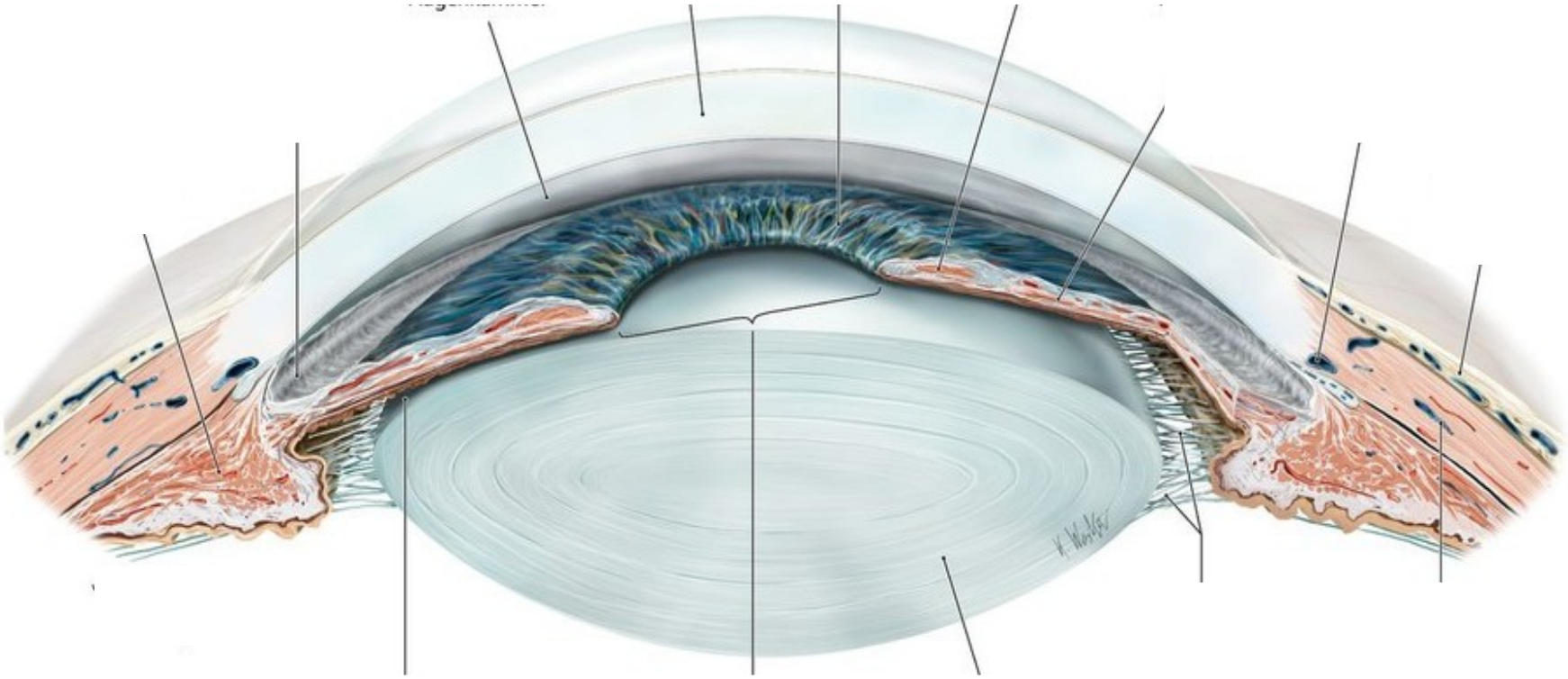


CORPUS CILIARE

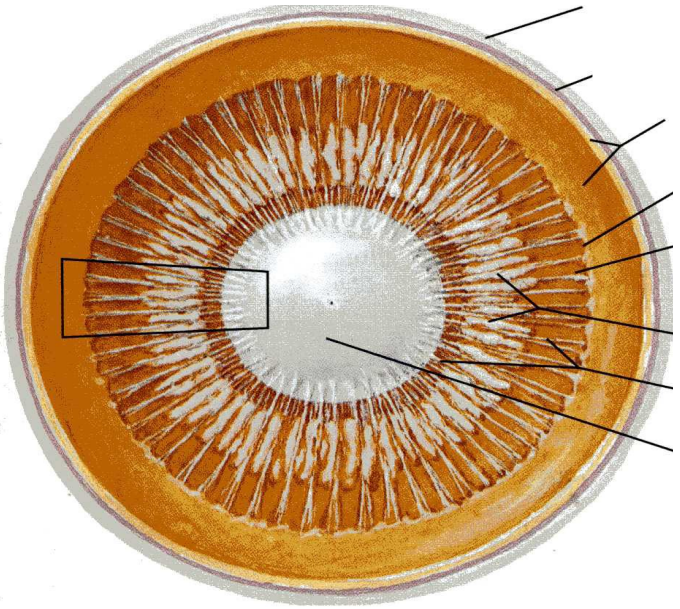
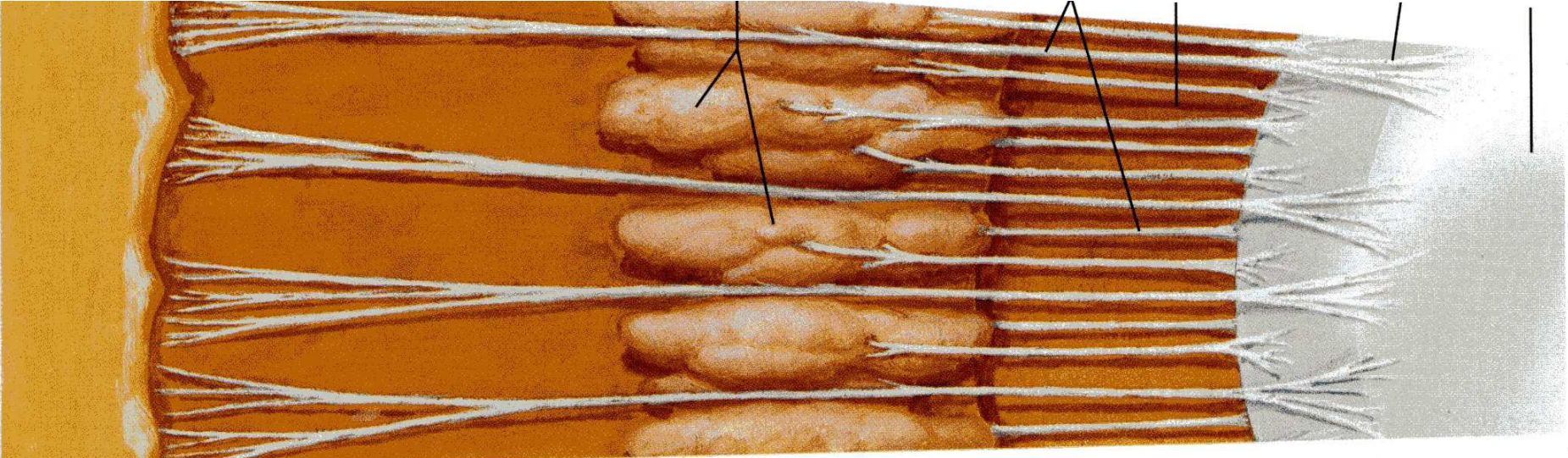
Anteriorly, containing ciliary muscles, place of attachment of suspensory ligaments of lens
Between ora serrata and sclerocorneal junction
1) orbiculus ciliaris (L)
2) corona ciliaris (M) (processus et plicae ciliares)
humor aquosus



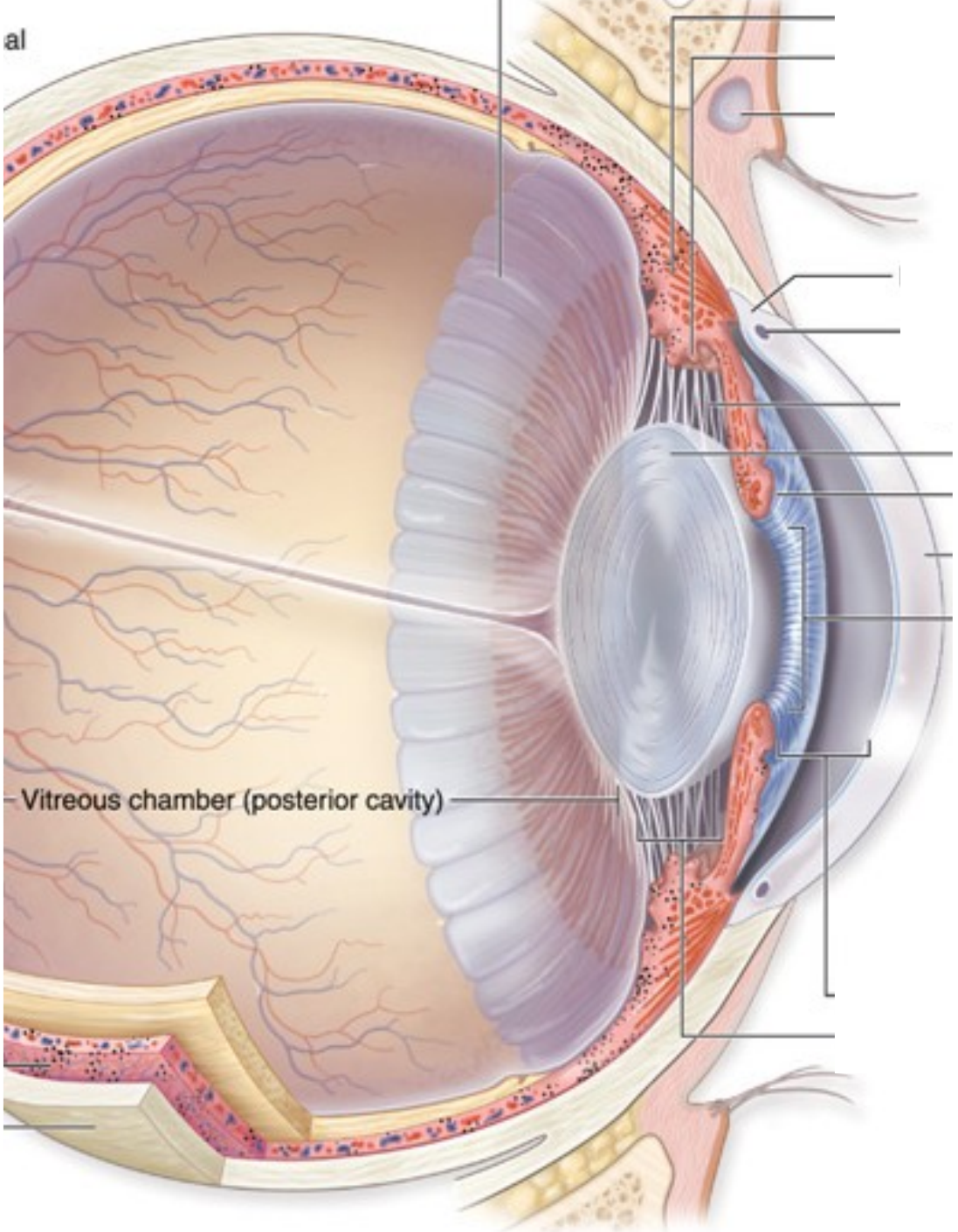
SUSPENSORY APPARATUS OF LENS



**zonula ciliaris
(fibrae zonulares)
m.ciliaris**



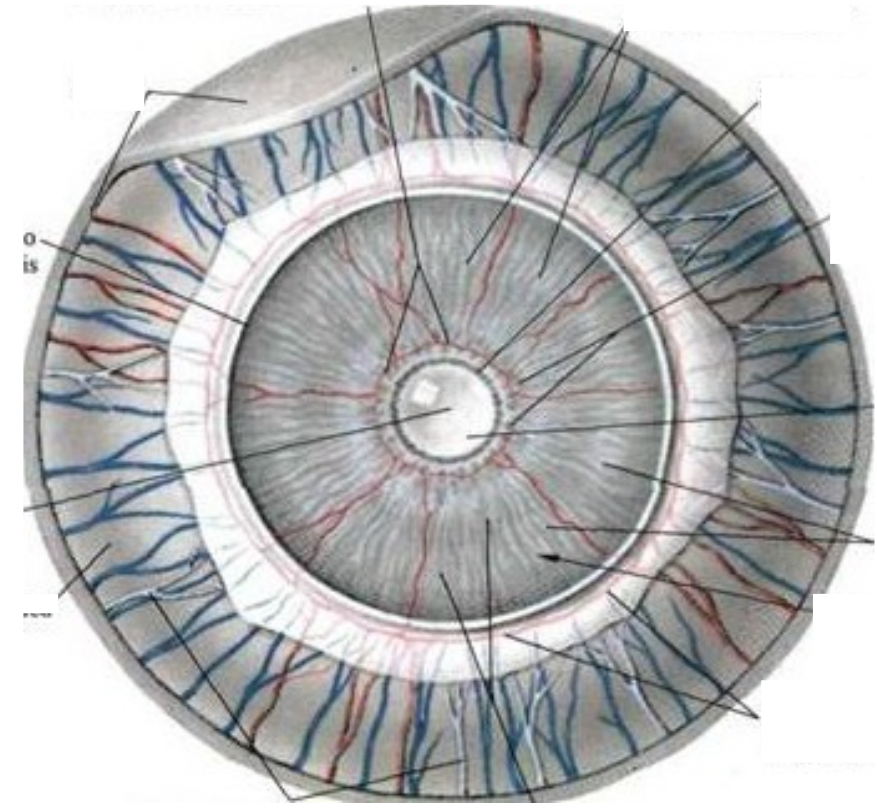
IRIS



**Colored disc with hole - pupil
margo ciliaris et pupularis(pupilla)**

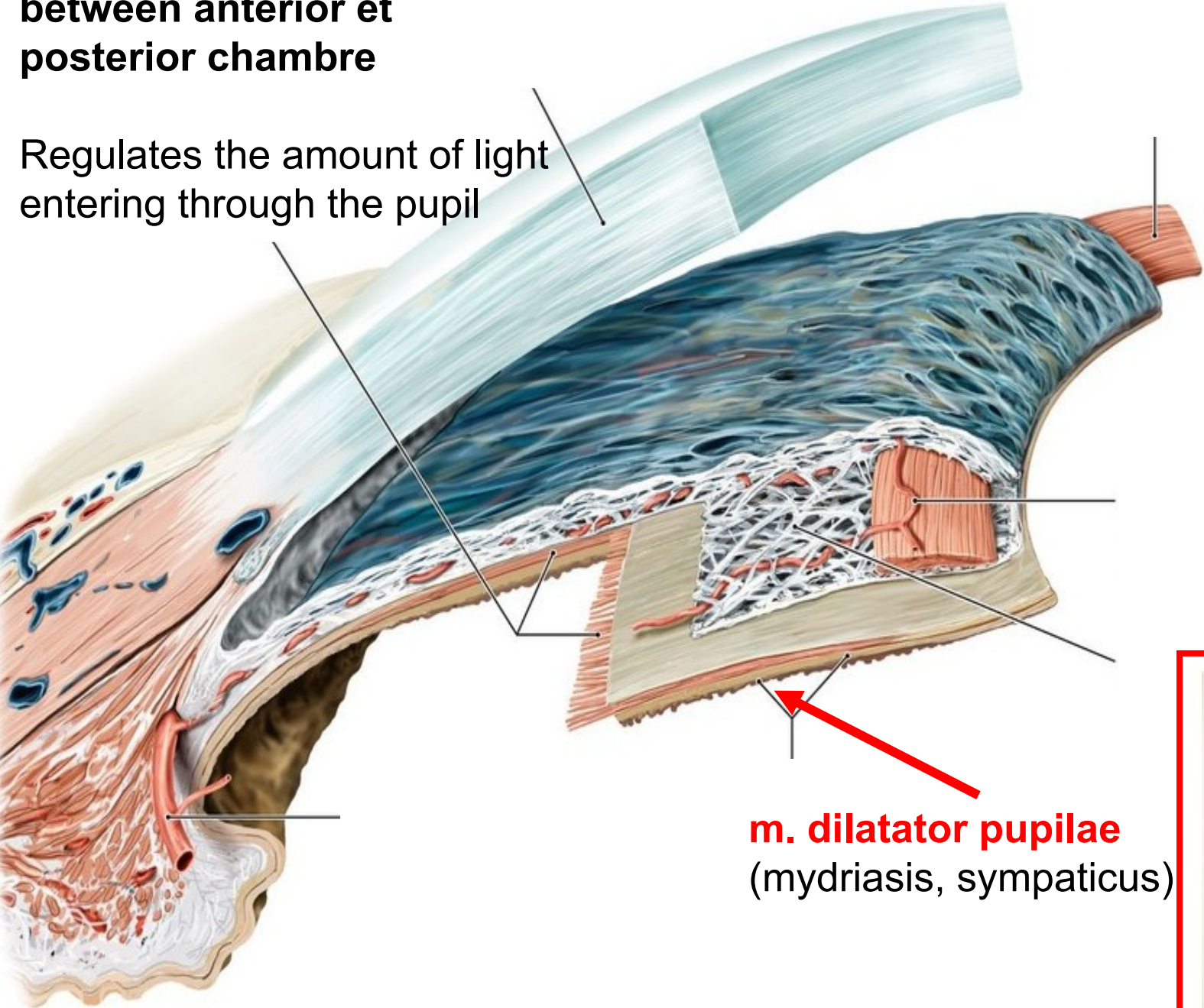
**facies anterior iridis et posterior iridis
stroma iridis**

fce světelné clony



between anterior et posterior chambre

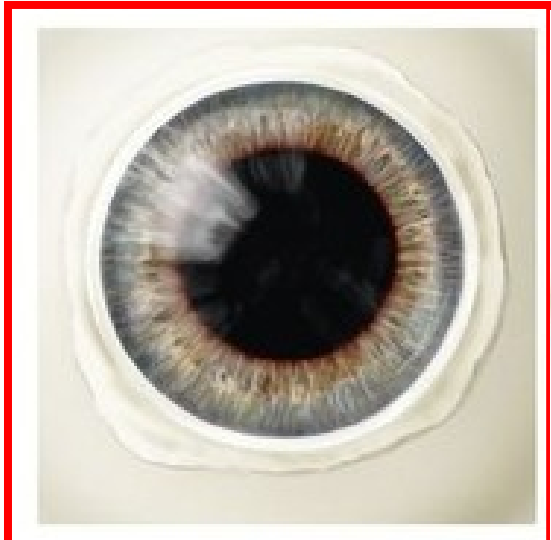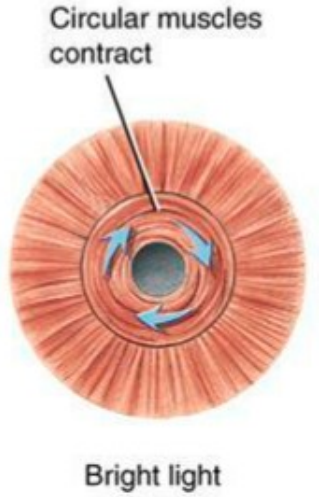
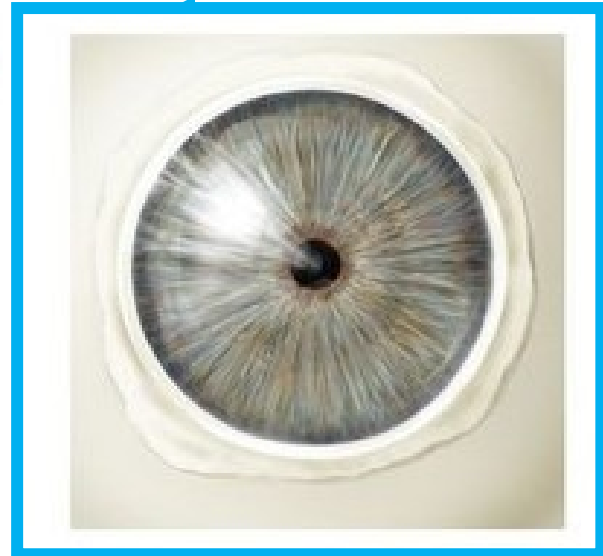Regulates the amount of light entering through the pupil

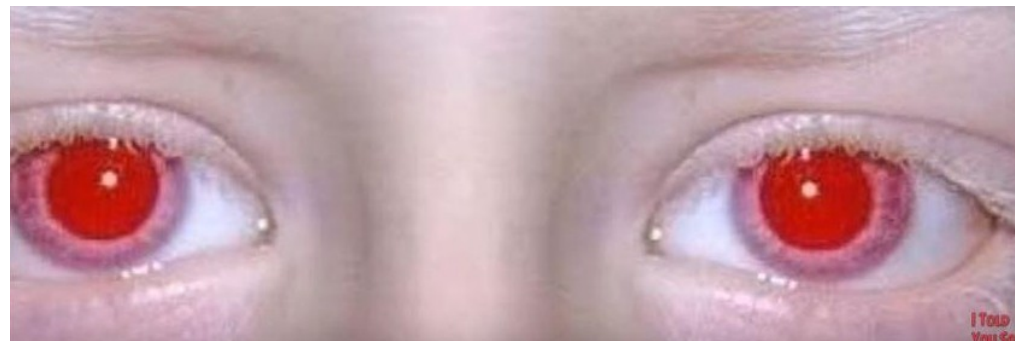
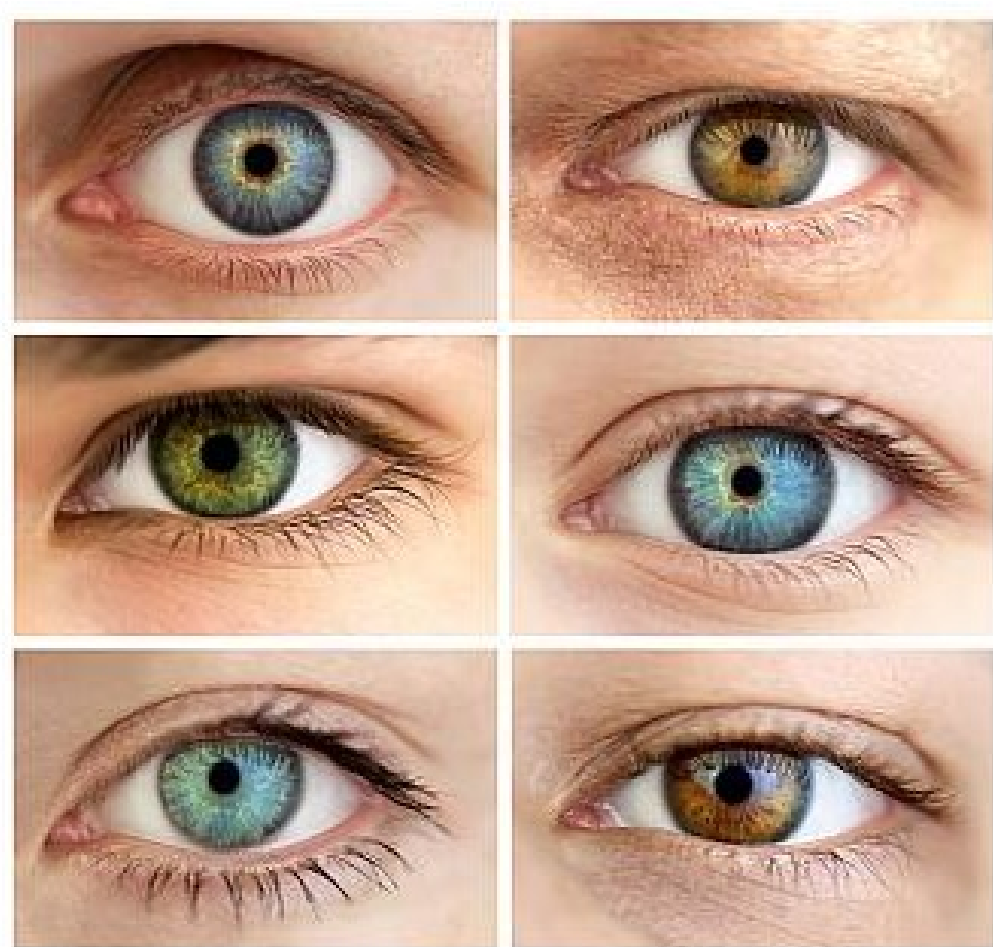

m. dilatator pupillae
(mydriasis, sympaticus)

Circular and radial smooth muscle fibers:

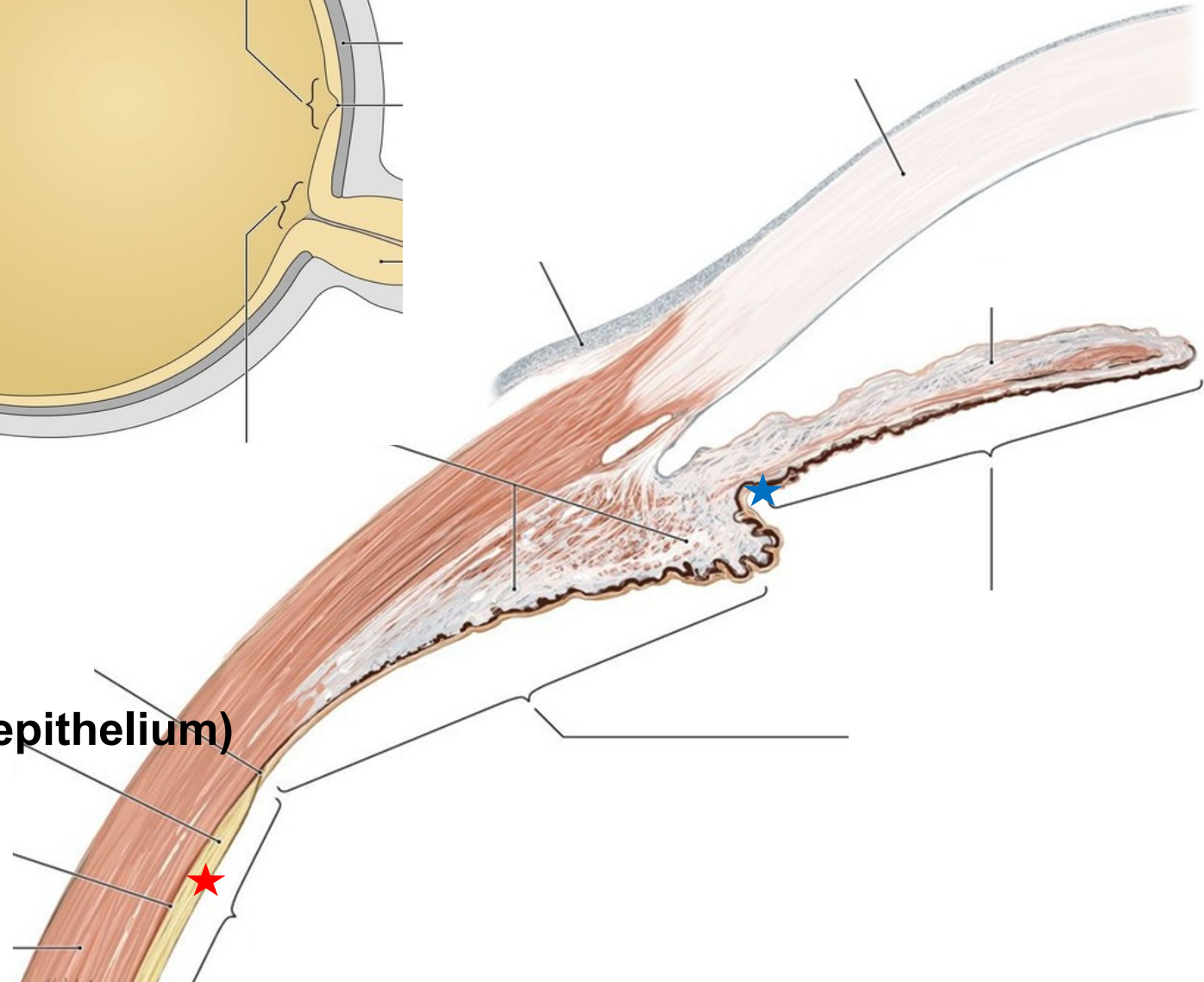
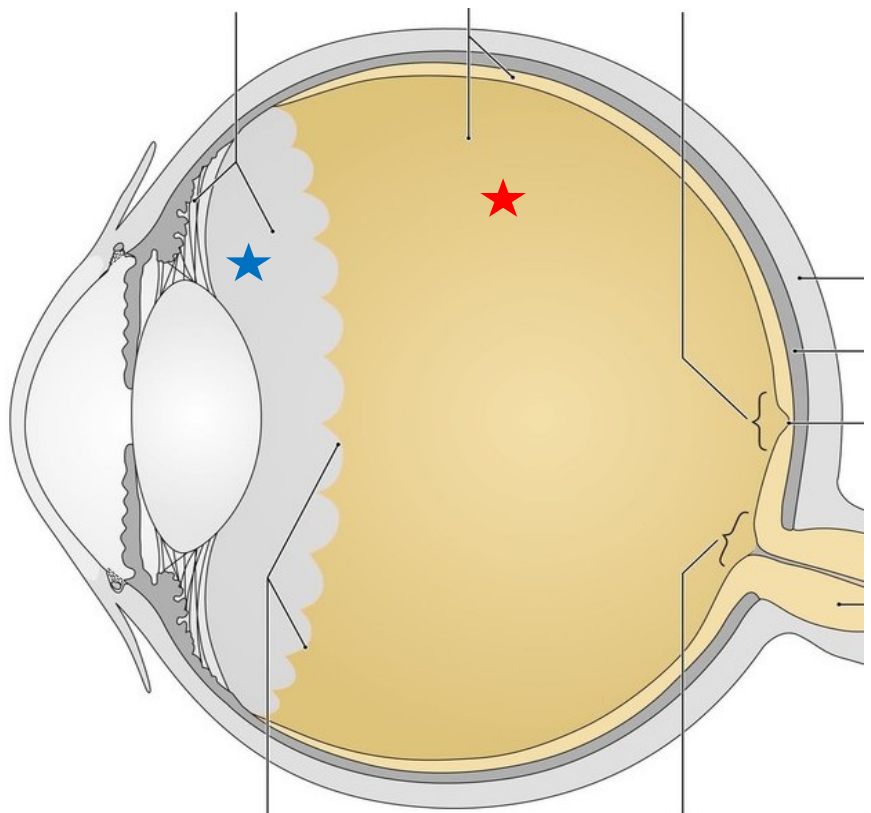
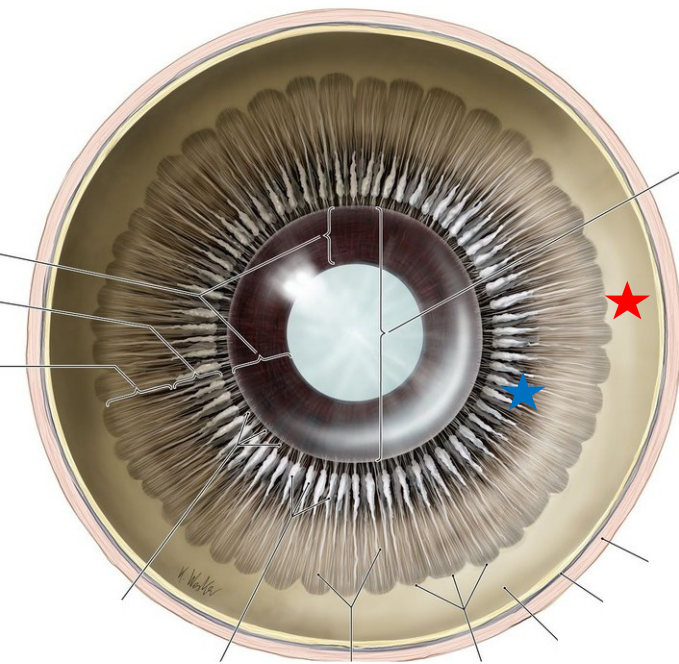
m.sphincter pupillae
(miosis, parasympaticus)





pigment (eye color)

RETINA



Stratum pigmenti retinae - outer
Neuronal layer - inner

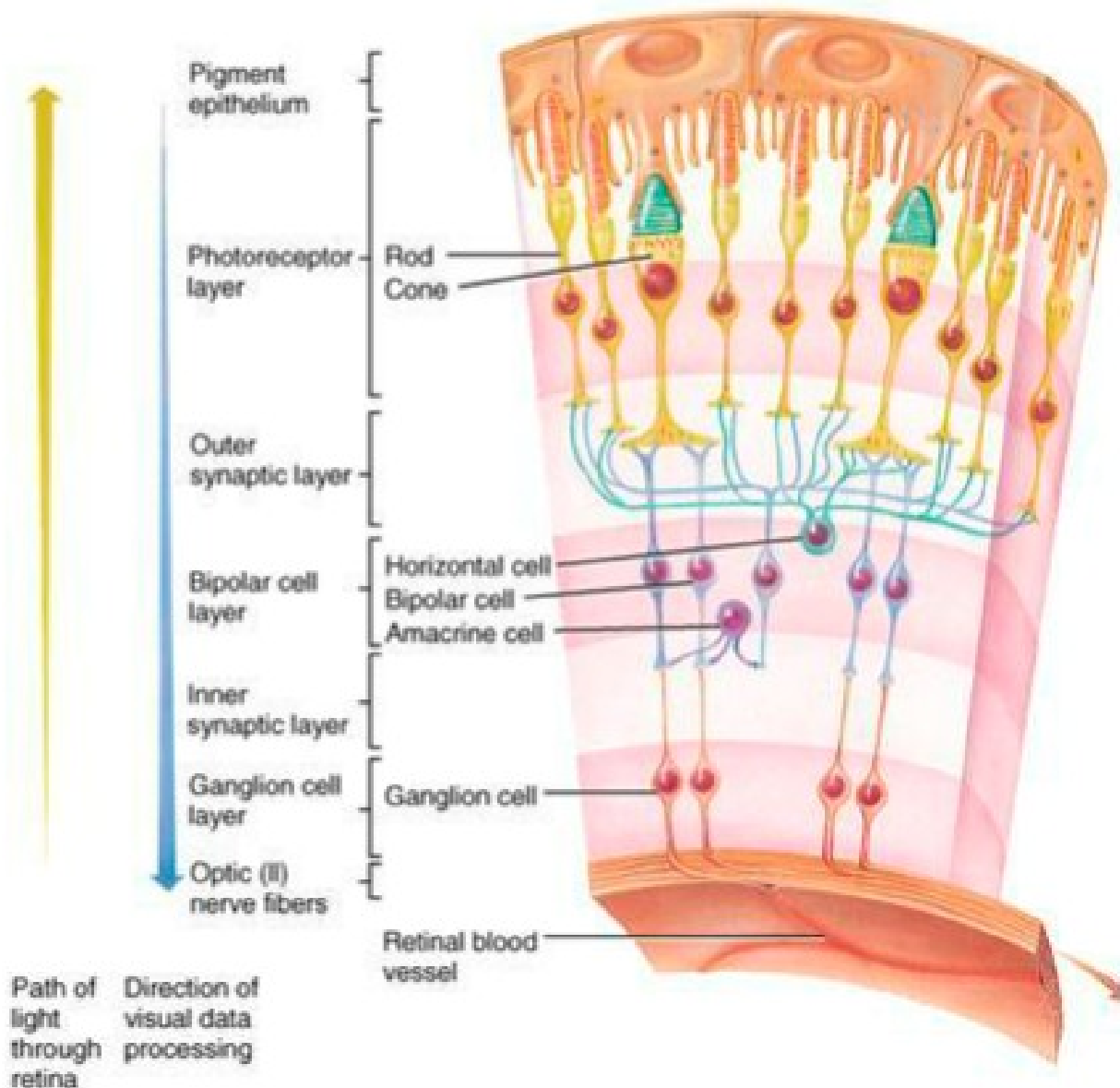
pars optica retinae (with sensory cells)

pars ciliaris et iridica retinae (with pigment epithelium)

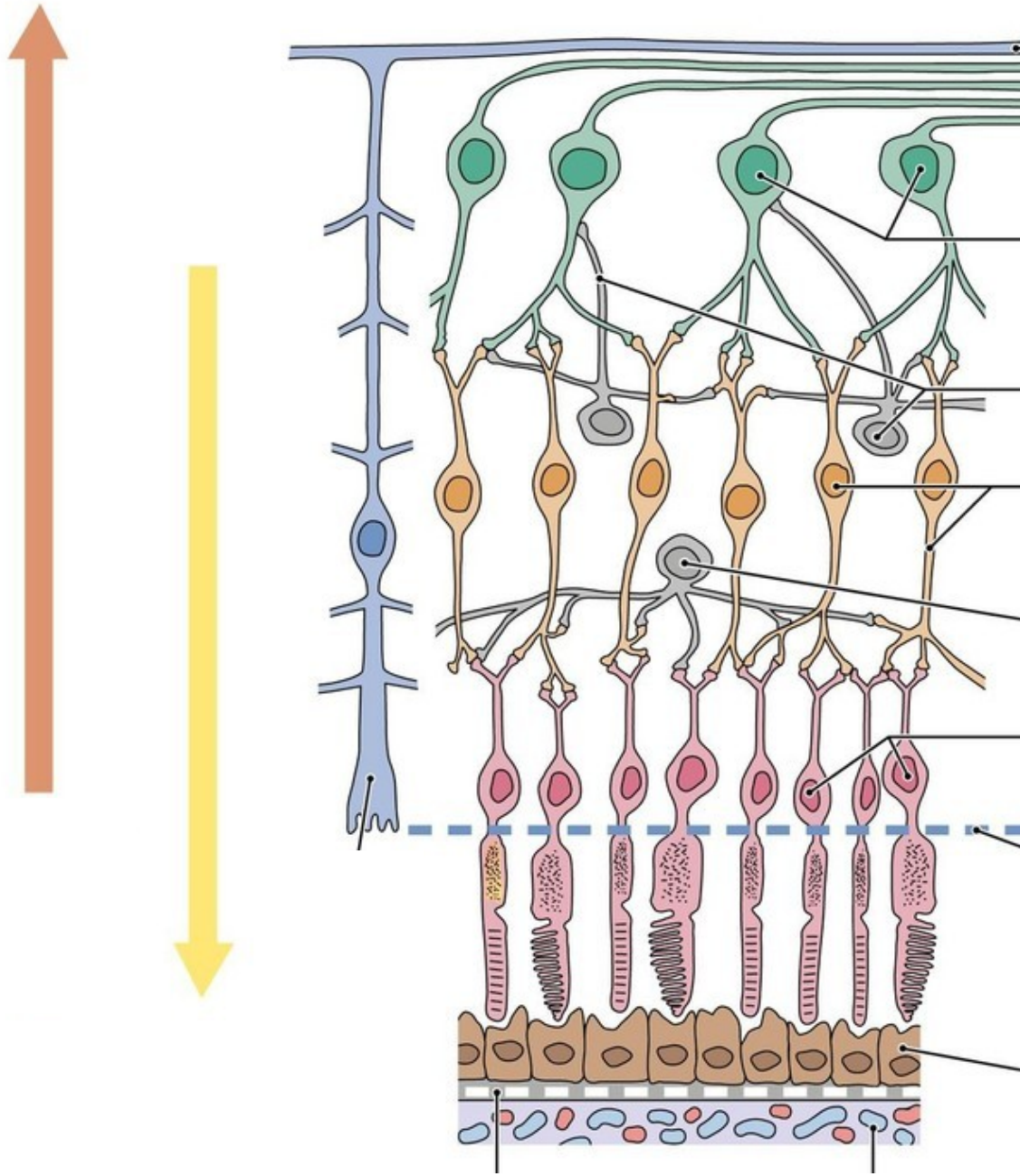
(pars caeca retinae)

between is ora serrata

PARS OPTICA RETINAE



- ***Pigmented epithelium***
 - nonvisual portion
 - absorbs stray light & helps keep image clear
- **3 layers of neurons (outgrowth of brain)**
 - photoreceptor layer
 - bipolar neuron layer
 - ganglion neuron layer
- **2 other cell types (modify the signal)**
 - horizontal cells
 - amacrine cells



**4. neuron – ncl.corporis geniculati lateralis
– radiatio optica (area 17)**

**3. Multipolar neurons Stratum ganglionare
n. optici – n. opticus**

**2. Bipolar neurons (Stratum ganglionare
retinae)**

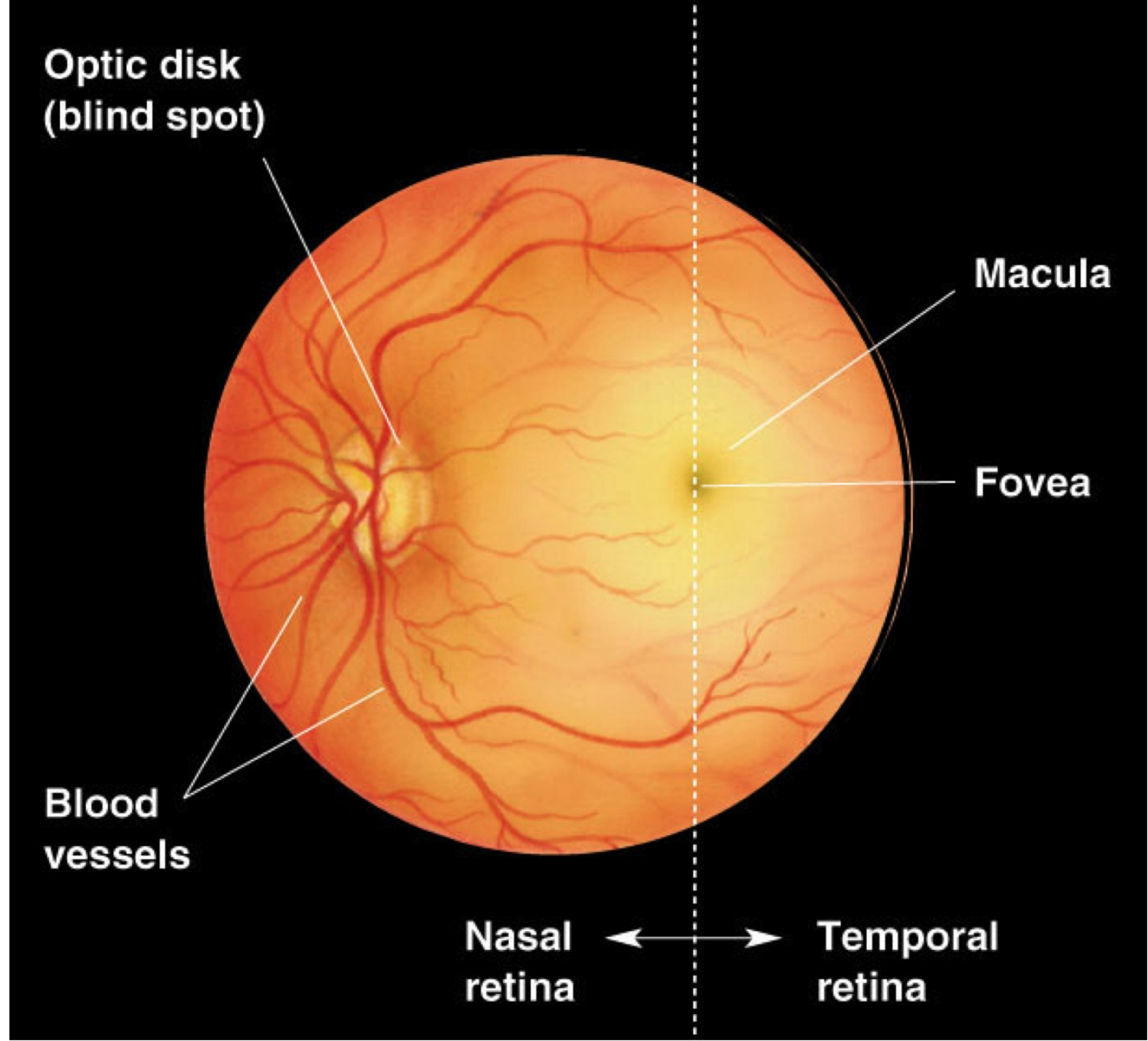
1. Stratum neuroepitheliale
Rod (130 million)
Cones (6-7 million, macula lutea)

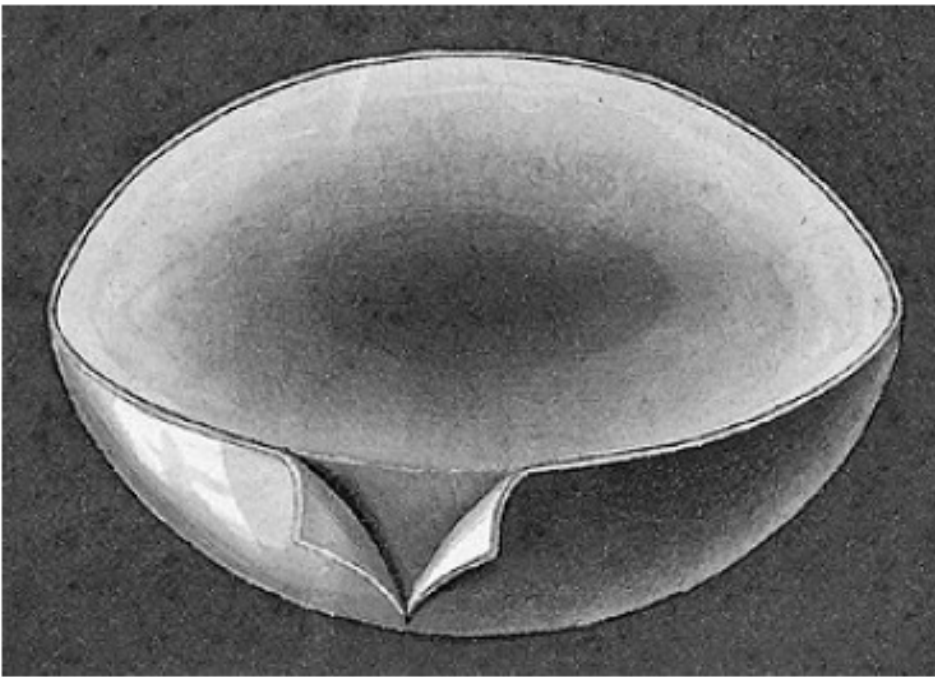
FUNDUS OCULI

= posterior part of the eye –
examination with ophthalmoscope
through pupil

macula lutea – **fovea centralis** –
linea visus (cones)

discus n.optici – **blind spot** –
macula caeca (no rods and cones)





**Transparent
Biconvex body**

**facies anterior
facies posterior**

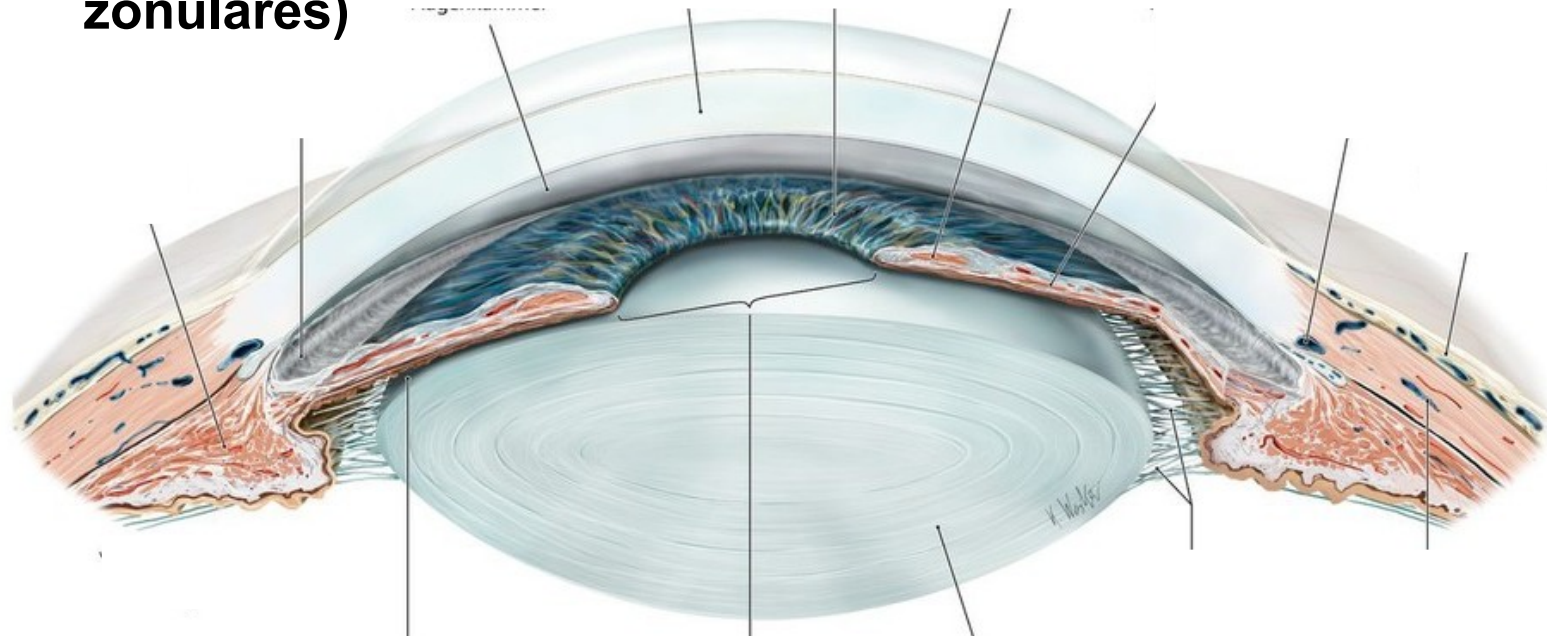
**polus anterior
polus posterior**

**equator lentis
(fibrae
zonulares)**

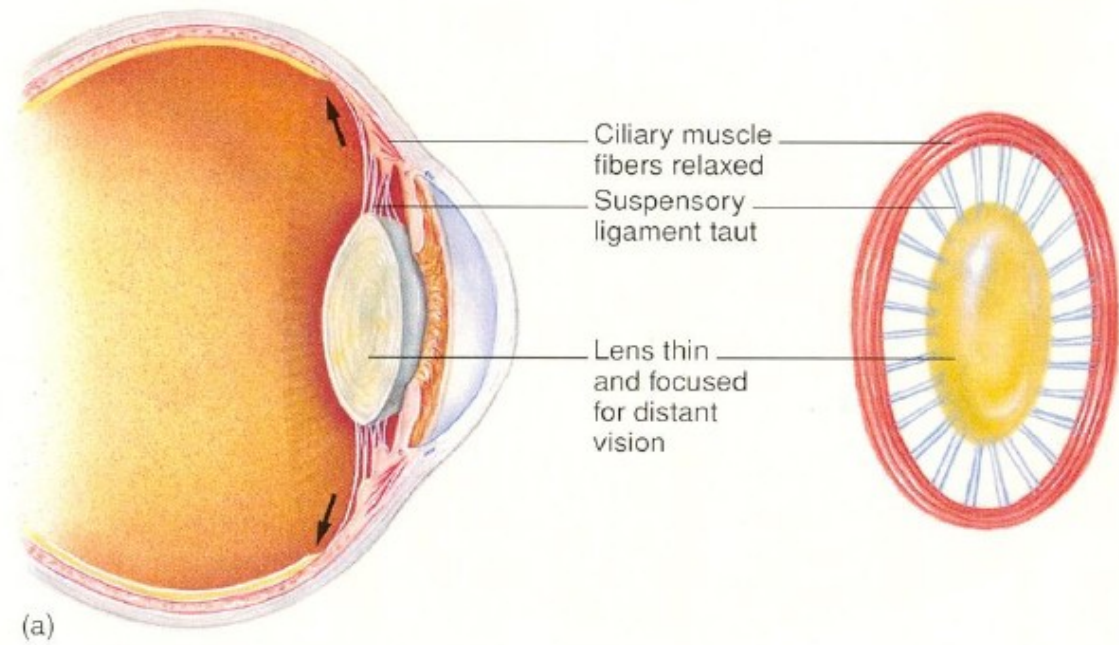
LENS

**capsula lentis
epithelium lentis (fibrae lentis)**

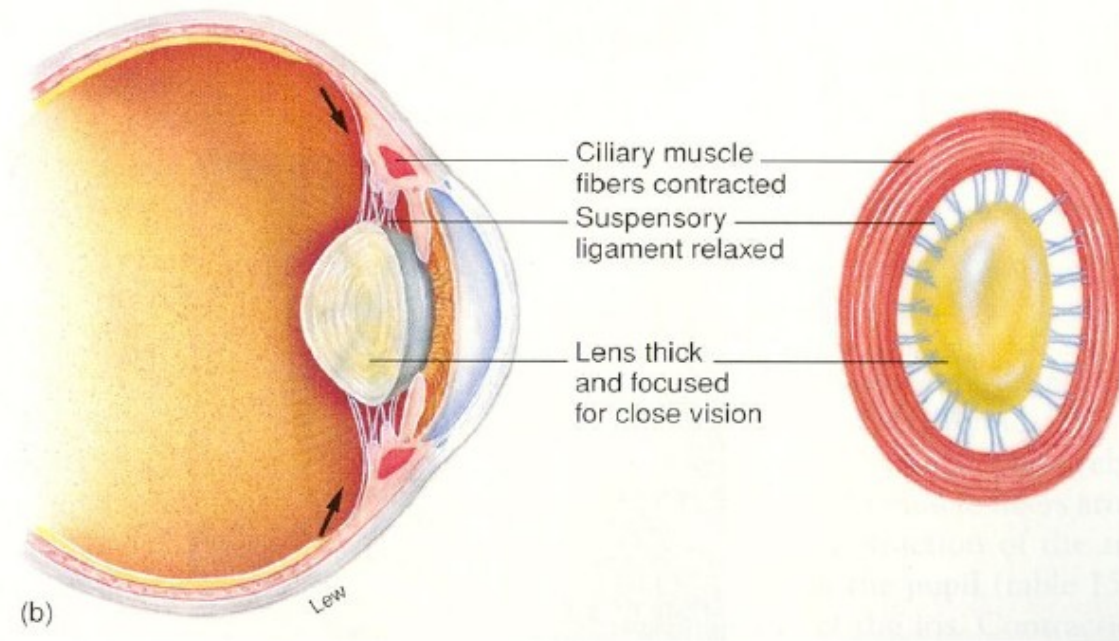
**cortex lentis
nucleus lentis**



AKOMODACE

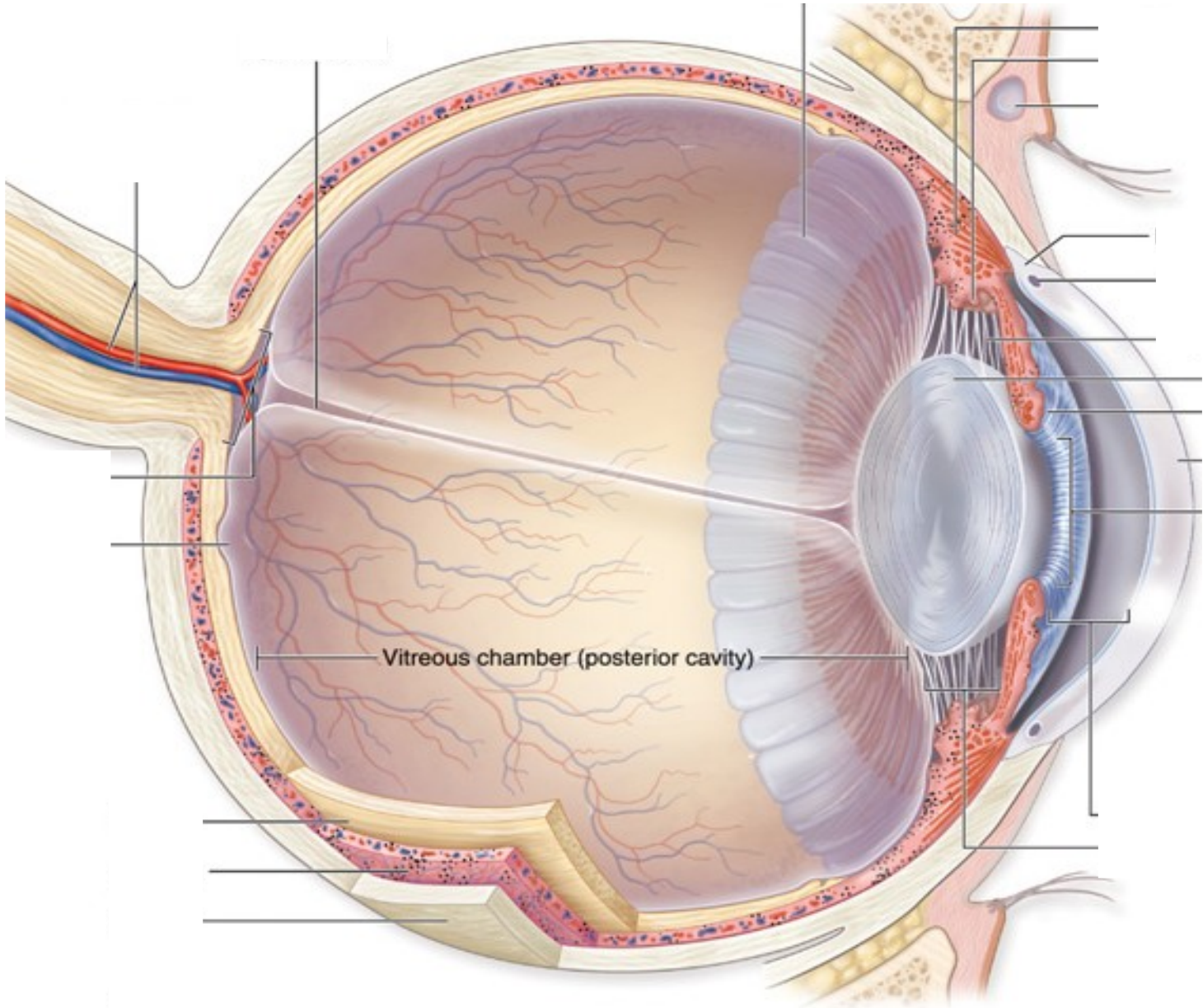


pohled do dálky,
sval je povolený



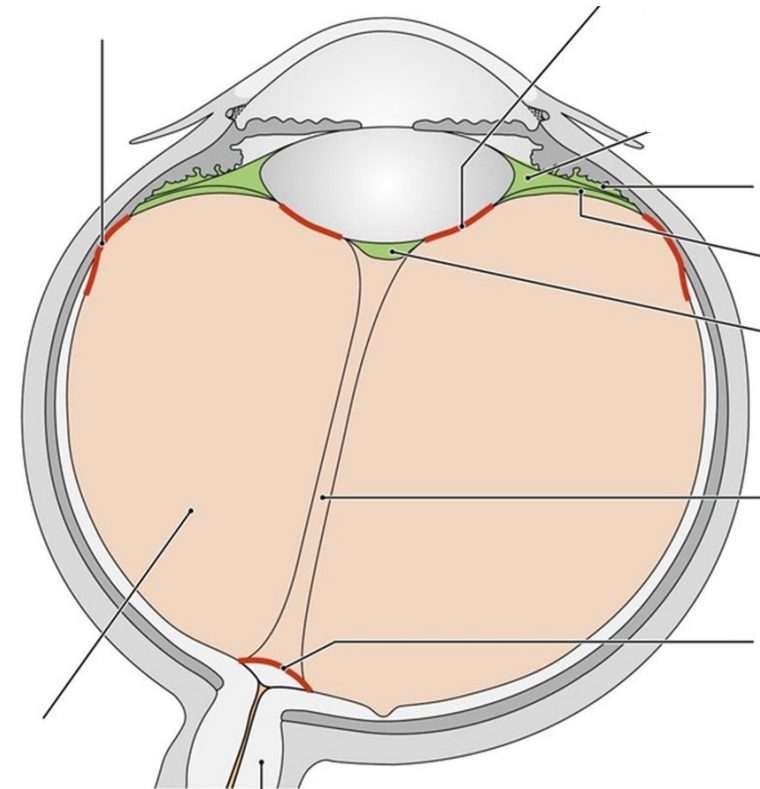
pohled do blízka,
sval je smrštěný

CORPUS VITREUM



= transparent gel occupies the space between the lens and the retina = camera vitrea

jelly- like substance called humor vitreus



humor aquosus

(is produced by vessels of the iris and epithelial cells of ciliary body)

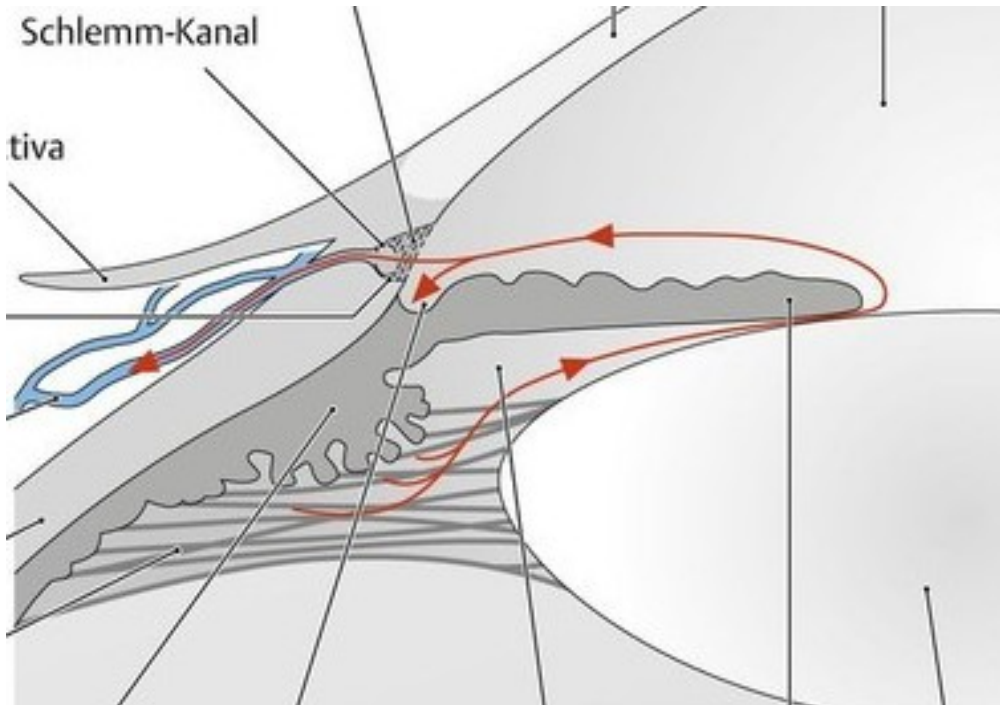
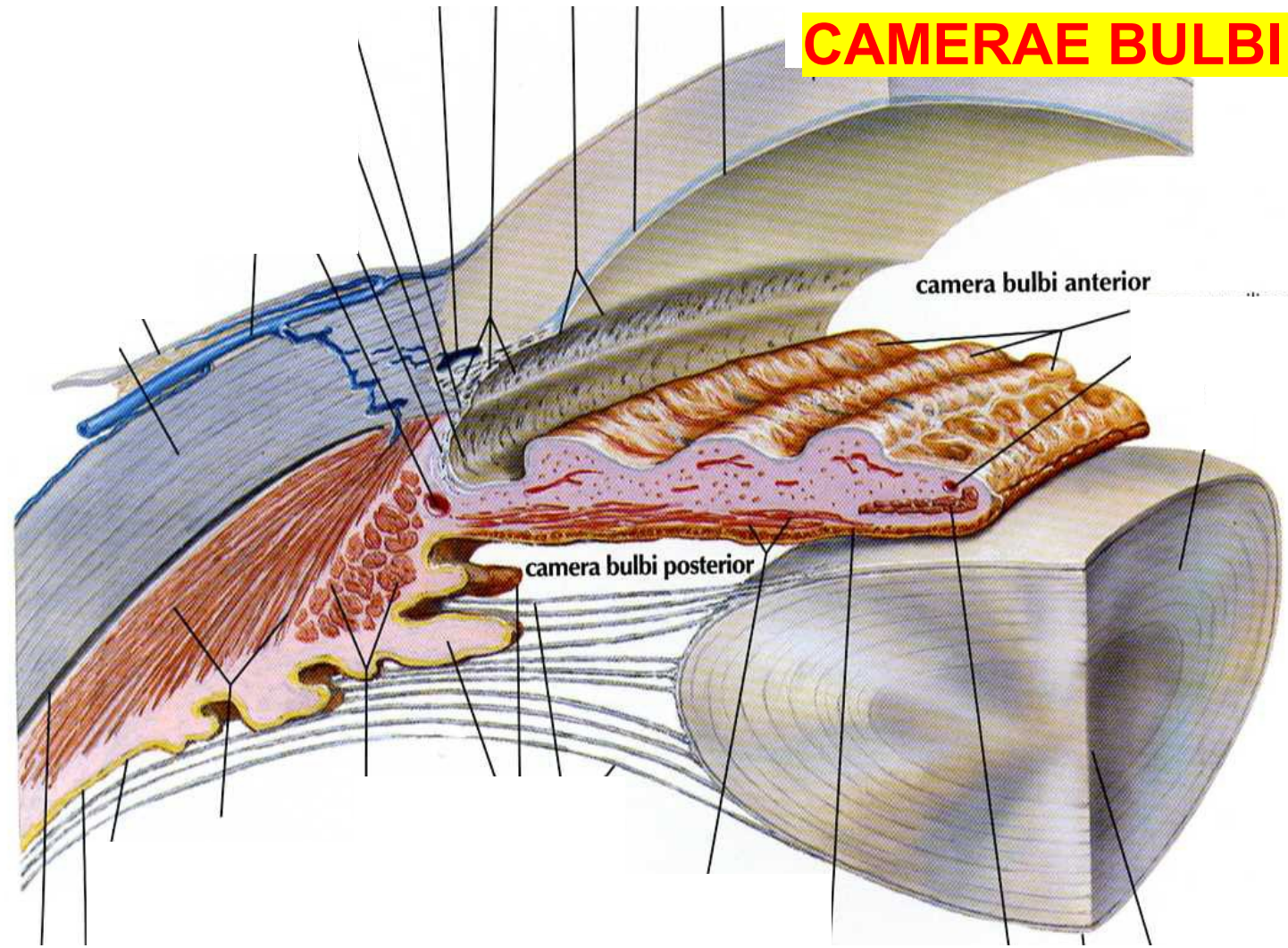
posterior chamber

anterior chamber

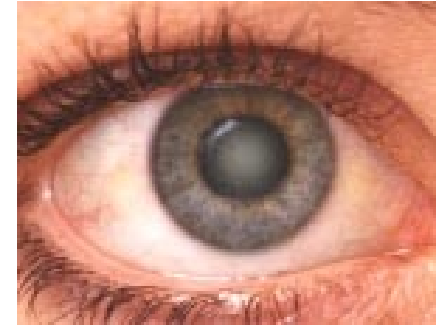
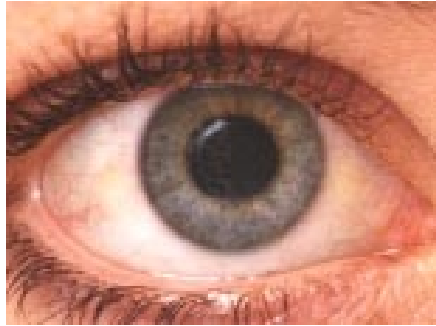
iridocorneal angle

sinus venosus sclerae

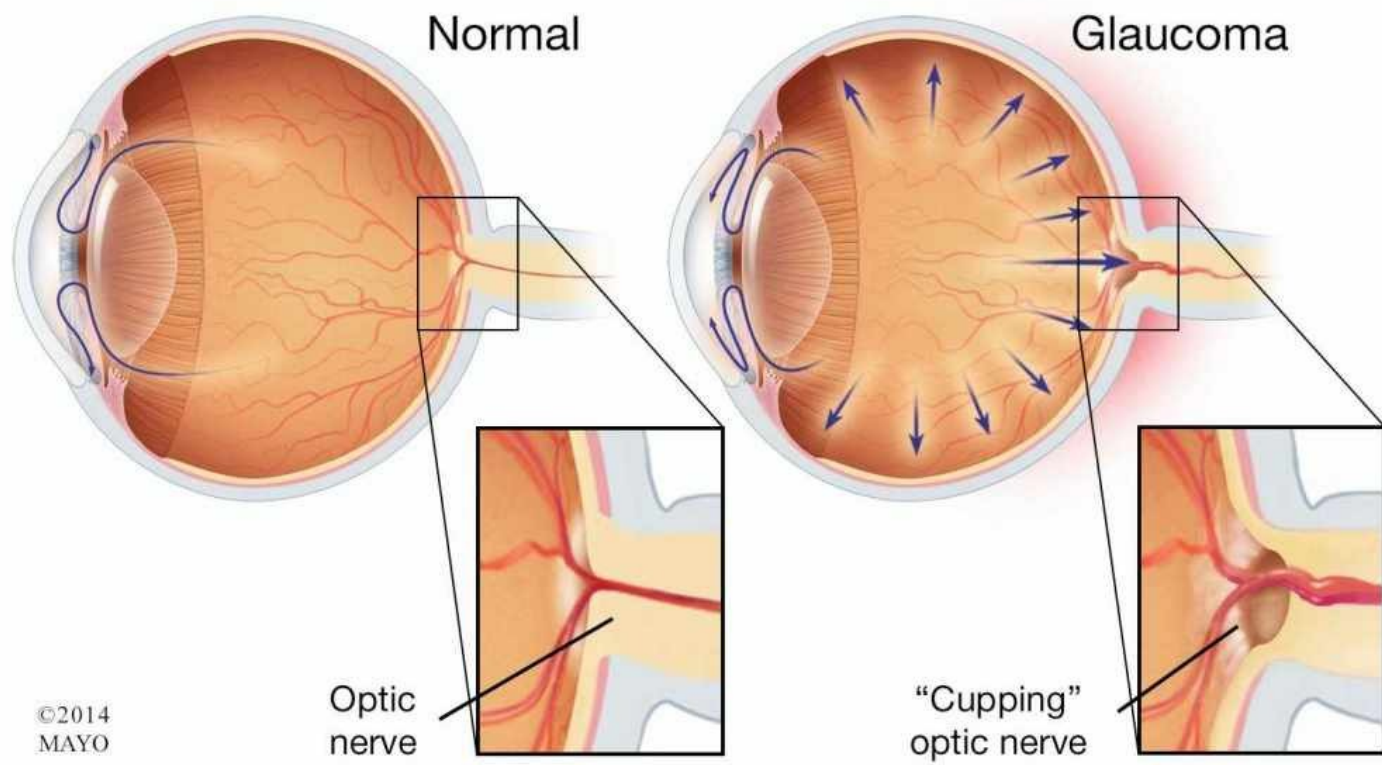
CAMERAE BULBI



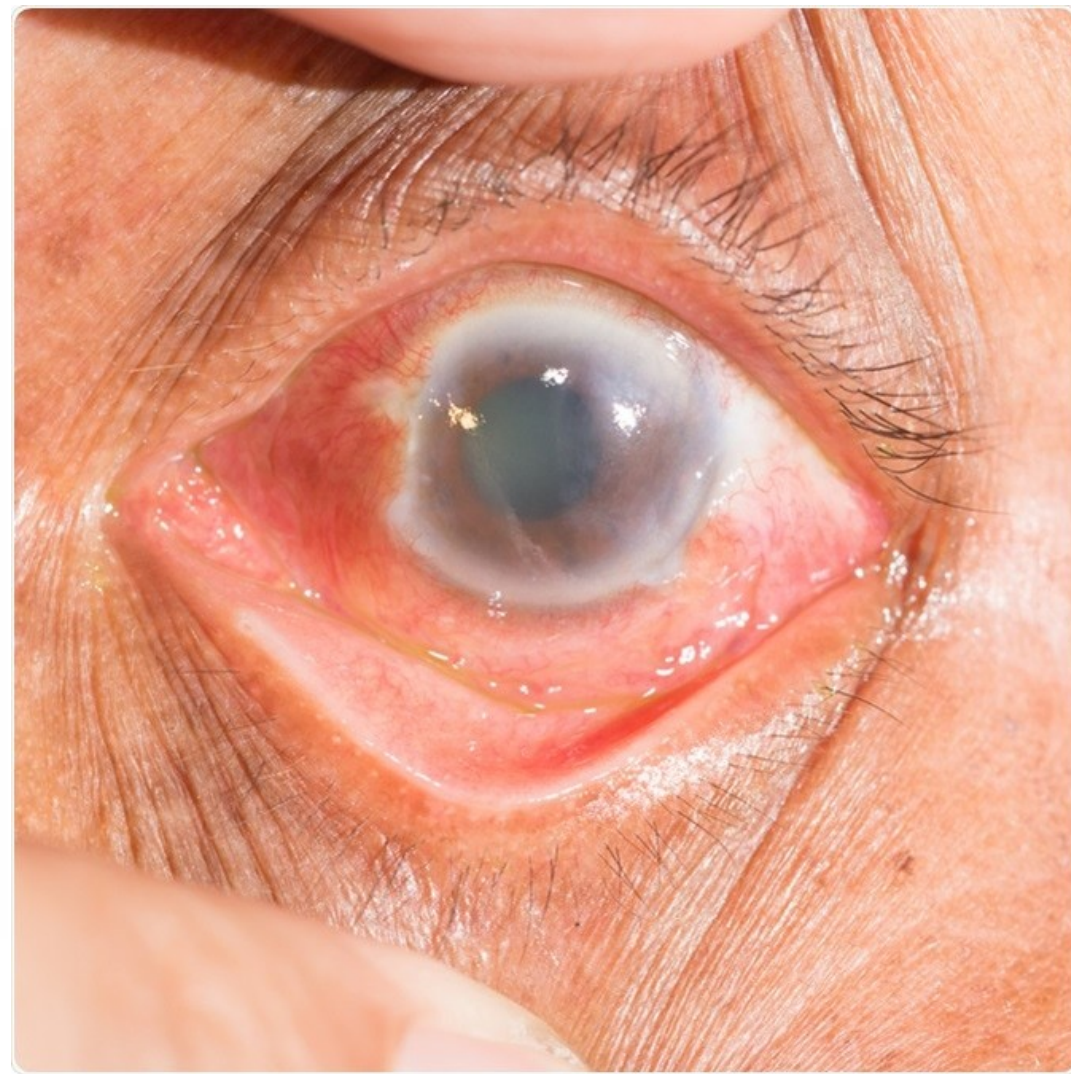
cataracta



- ✓ ztráta průhlednosti čočky
- ✓ vidění neostré a zamlžené
- ✓ v každém věku, nejčastěji následek přirozeného stárnutí oka



©2014
MAYO



**PAPEBREA
(eyelids)**

palpebra superior
palpebra inferior

rima palpebrarum

angulus oculi medialis
angulus oculi lateralis

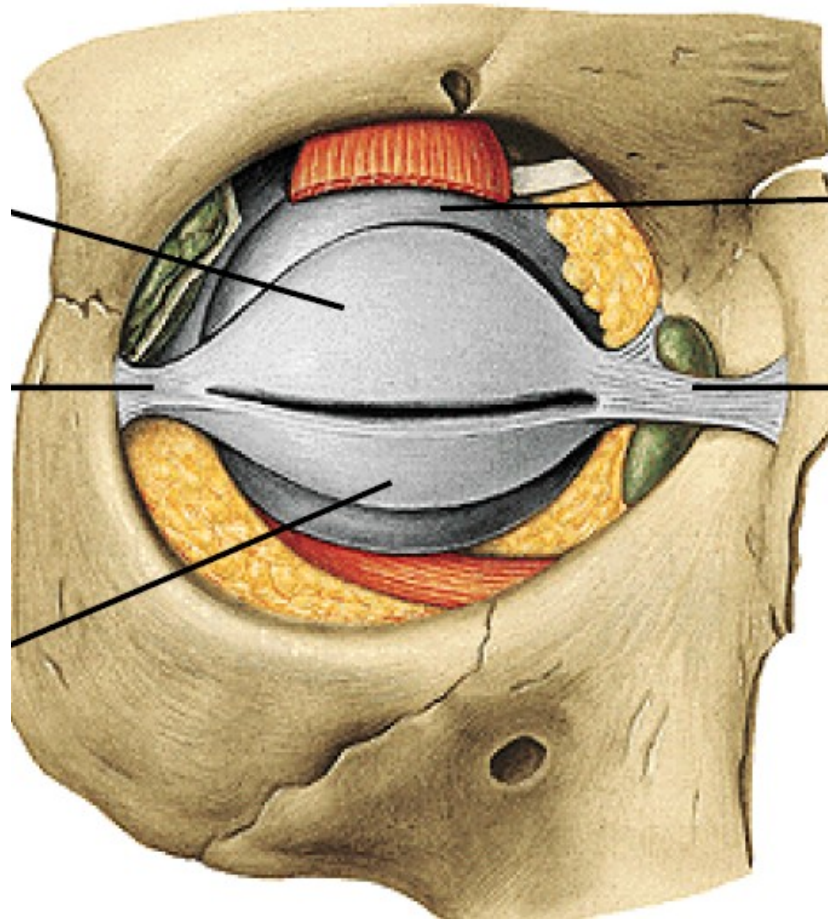
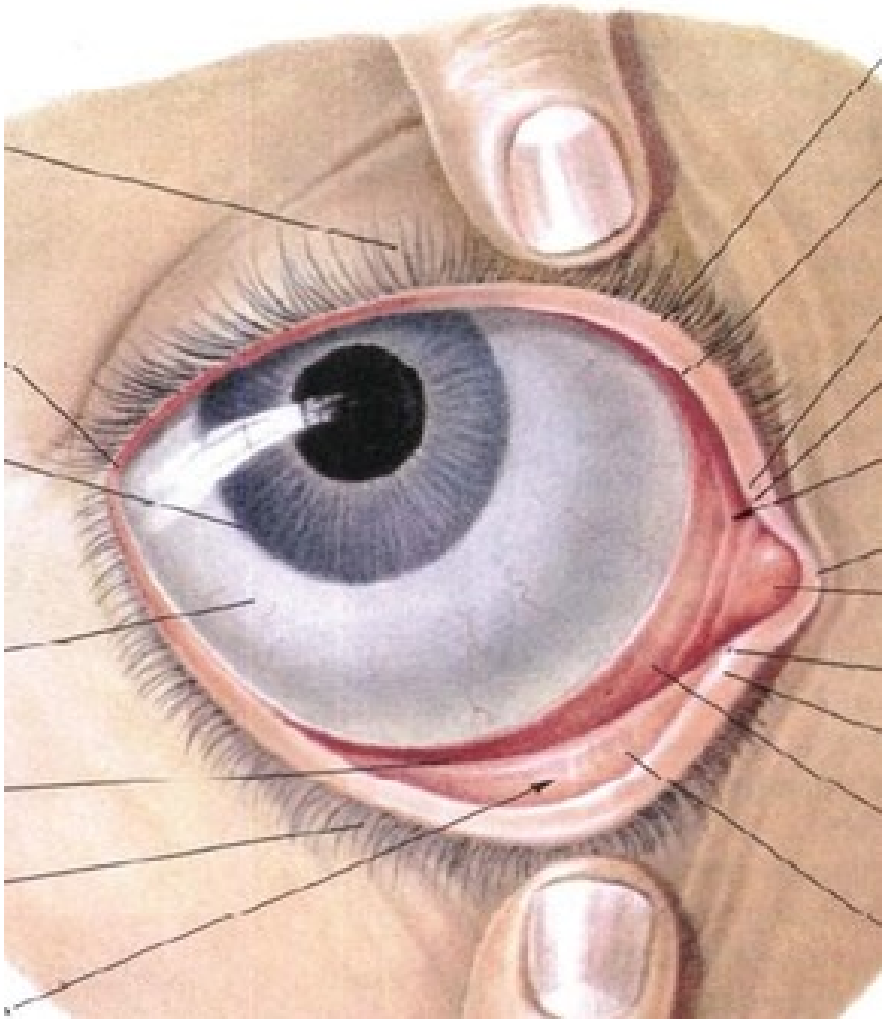
facies anterior
facies posterior

limbus palpebralis anterior
(cilia, gll. sebaciae, gll. ciliares)
limbus palpebralis posterior

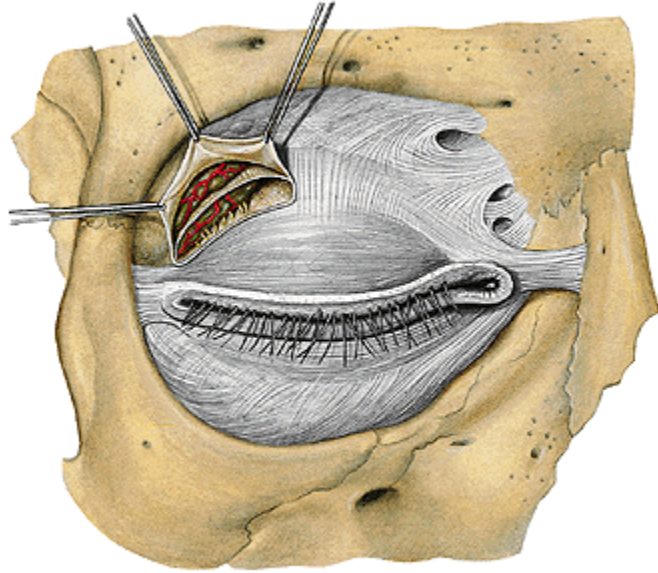
rivus lacrimalis

papilla lacrimalis
(punctum lacrimale)

tarsal plates



EYELID MORPHOLOGY



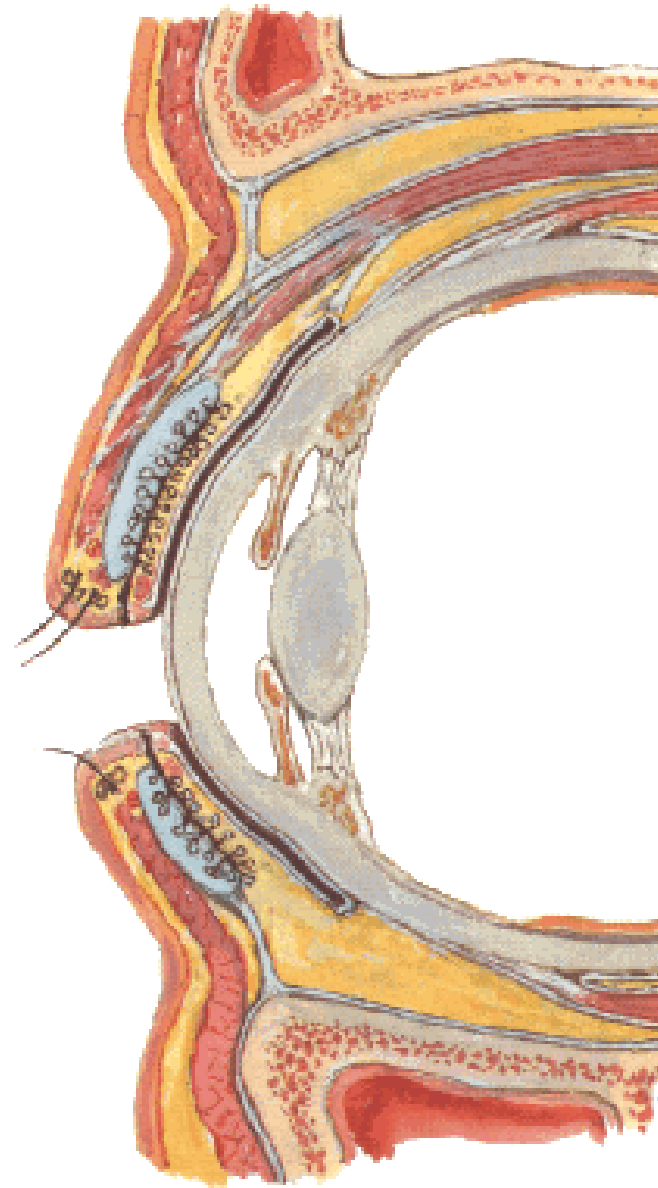septum orbitale

tarsus superior, inferior
gl. tarsales (Meibomi)

lig. palpebrale med., lat.

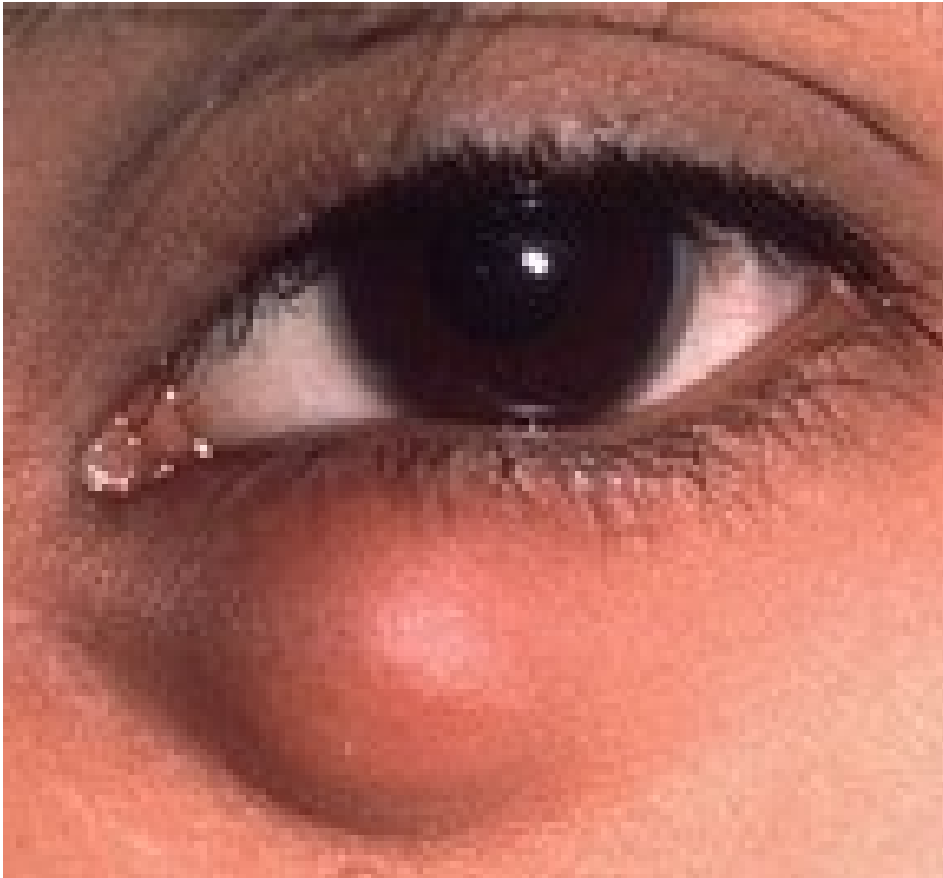m. tarsalis sup., inf.

m. orbicularis oculi



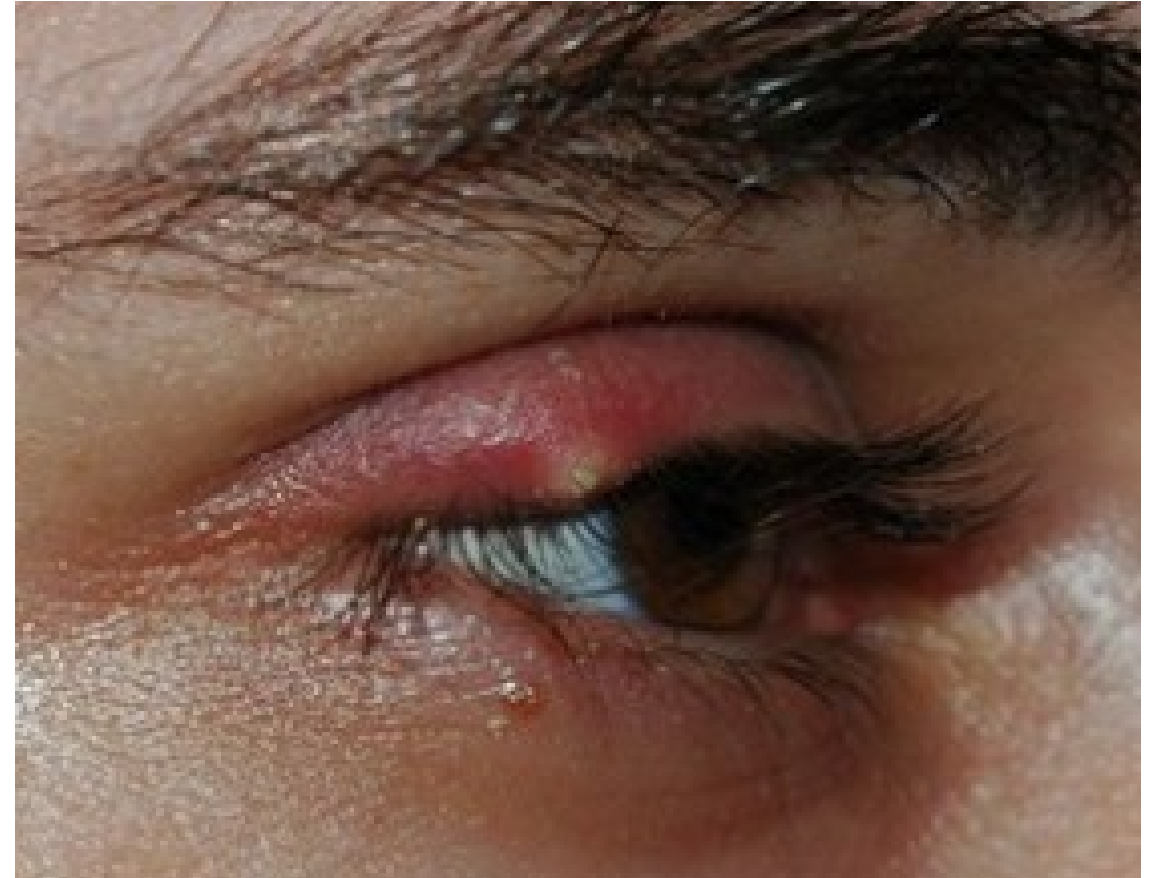Chalazion

(inflammation of gl. tarsalis)

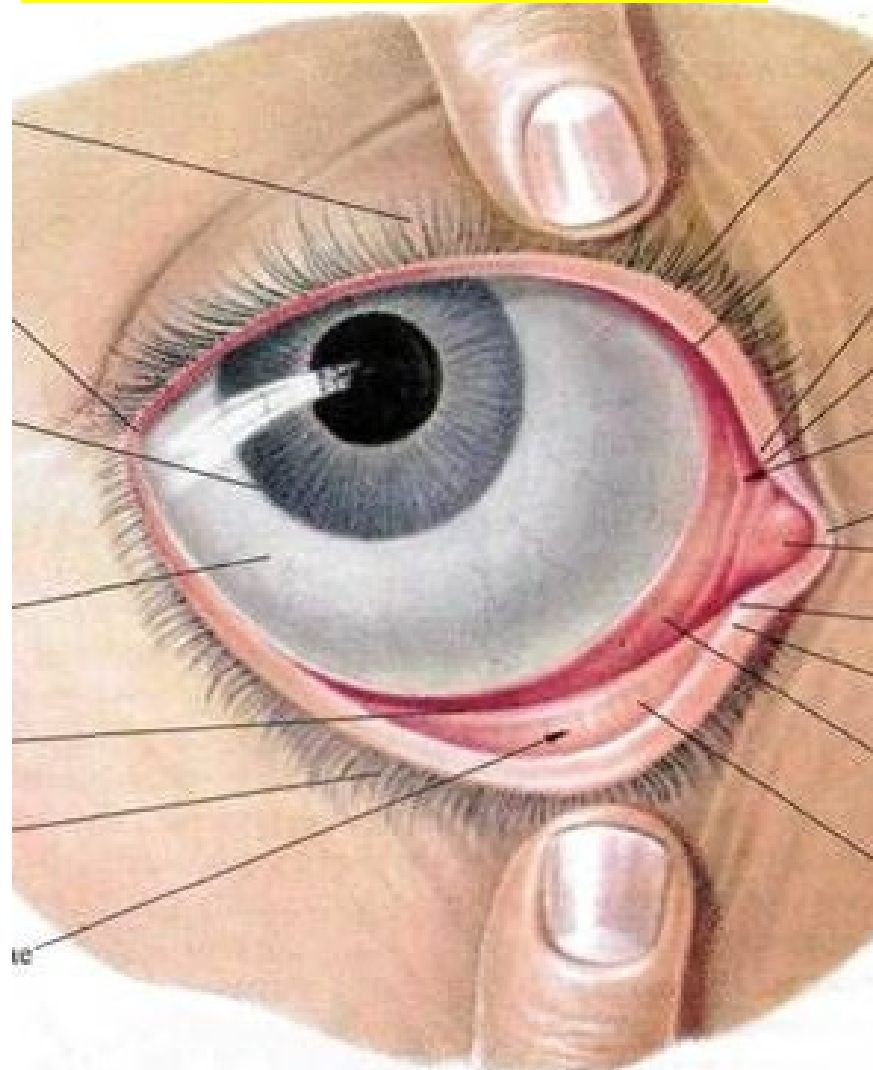


Hordeolum

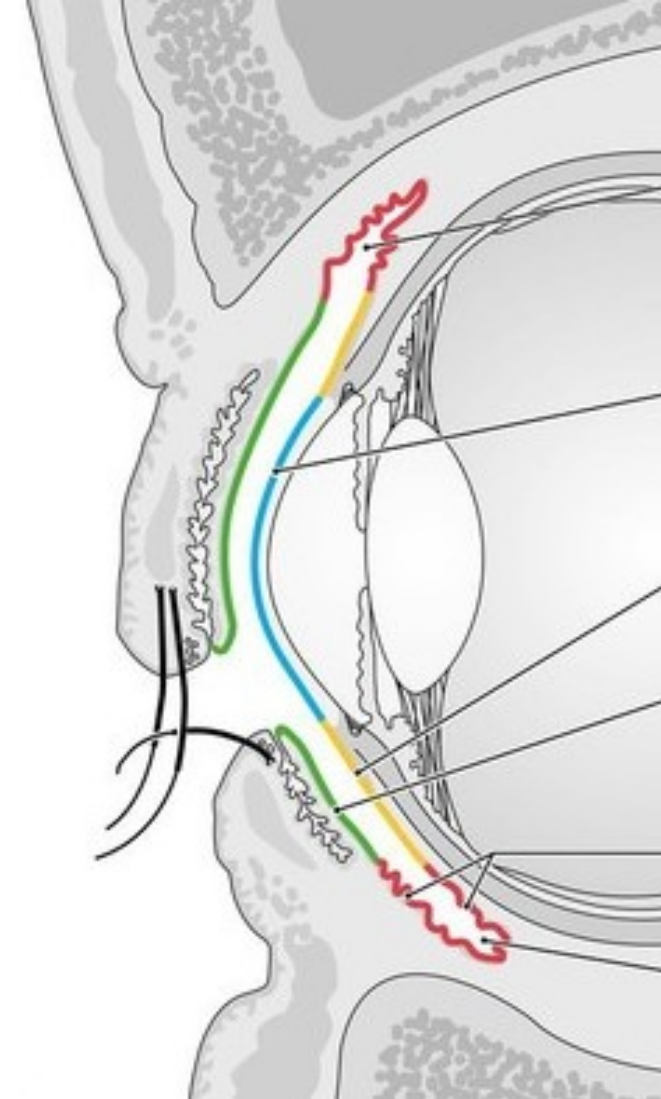
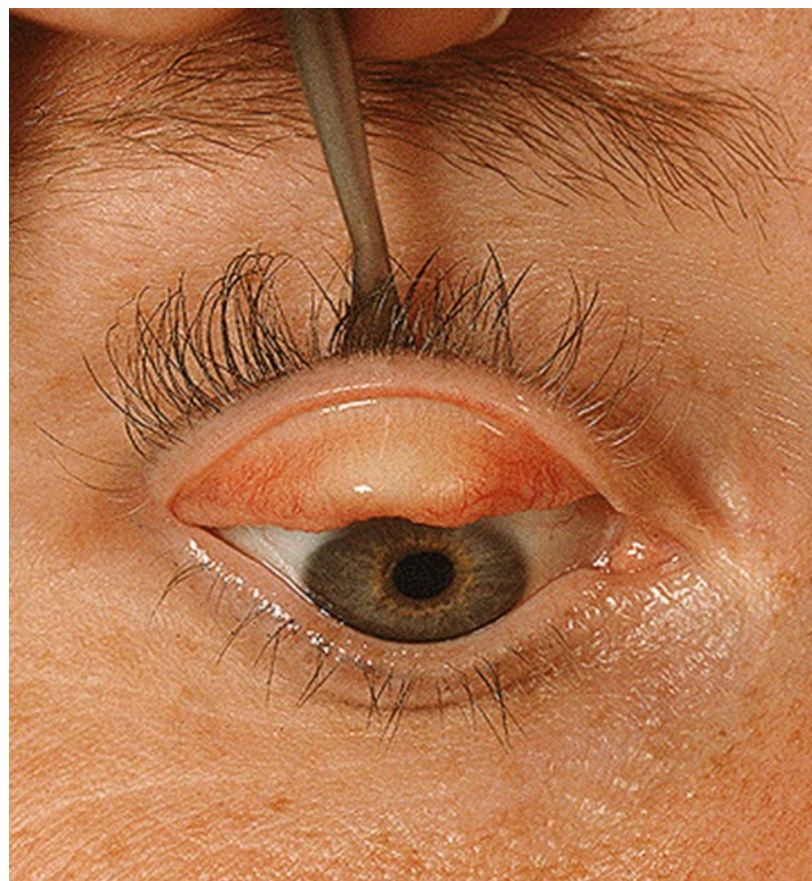
(inflammation of gl. ciliaris)



TUNICA CONJUNCTIVA

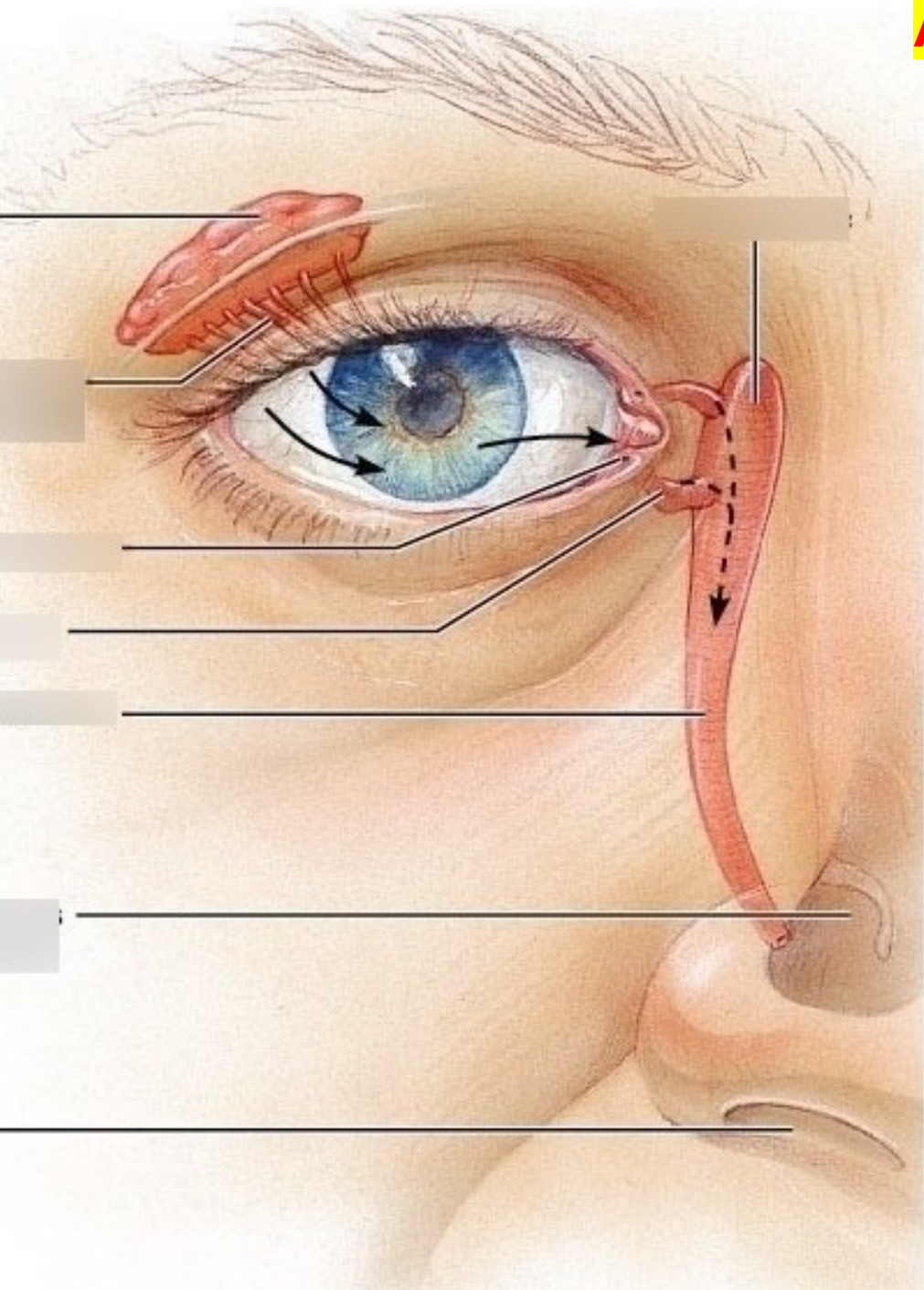


lacus lacrimalis
caruncula lacrimalis
papilla lacrimalis
punctum lacrimale



tunica conjunctiva palpebrarum
tunica conjunctiva bulbi
fornix conjunctivae super. et infer.
saccus conjunctivae
plica semilunaris

APARATUS LACRIMALIS



Gl. lacrimalis (pars orbitalis a palpebralis)

Ductuli exretorii (fornix conjunctivae sup.)

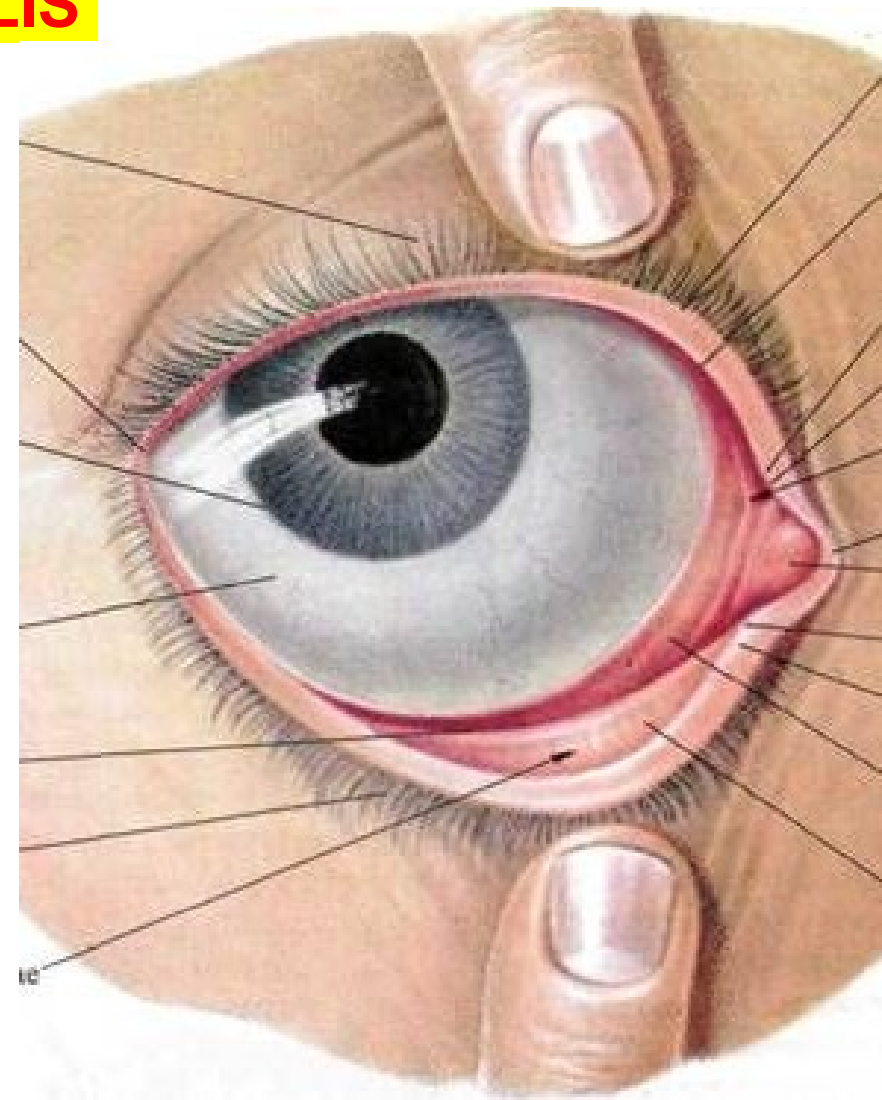
Lacrimae

Punta lacrimalis

Canaliculi lacrimales

Saccus lacrimalis

Ductus nasolacrimalis (meatus nasi inferior)



**lacus lacrimalis
caruncula lacrimalis
papilla lacrimalis
punctum lacrimale**

MM. BULBI

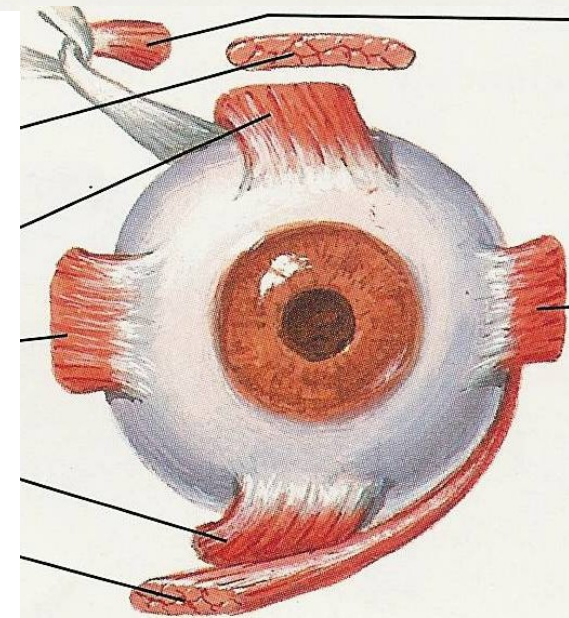
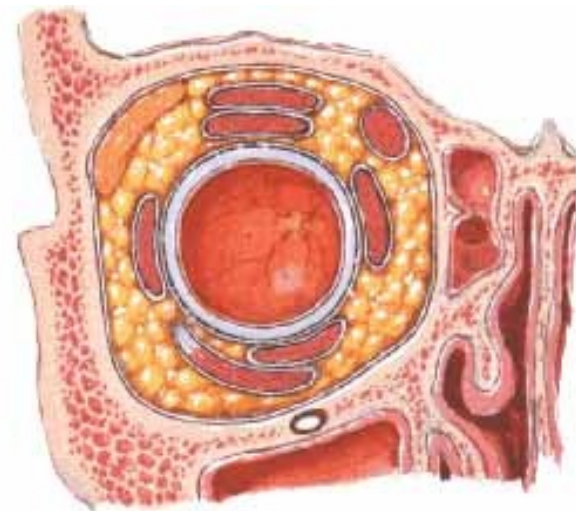
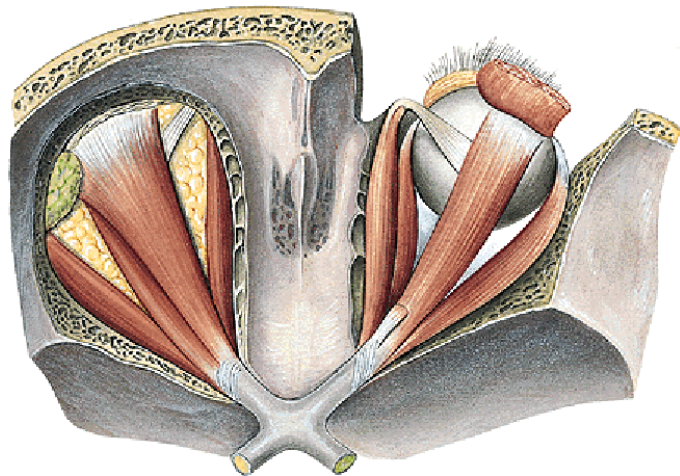
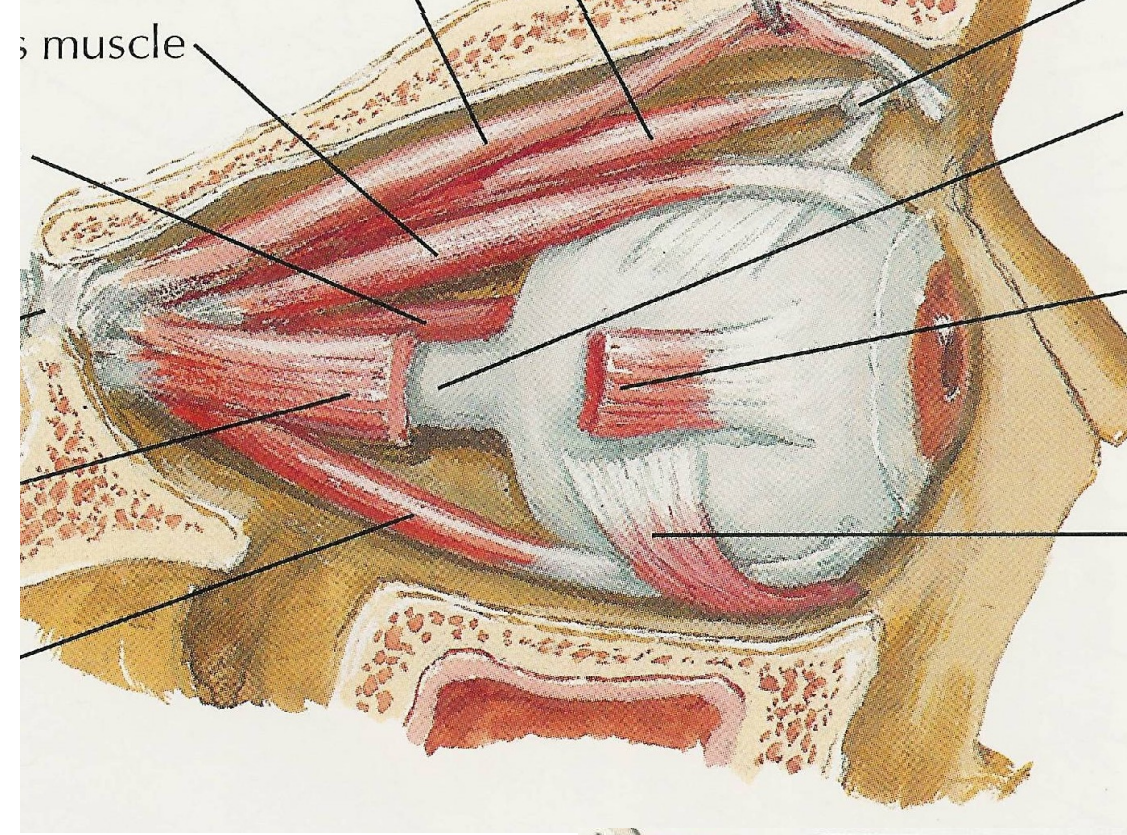
7 STRIATED MUSCLES

Innervation: n. III,IV,VI

origin: **anulus tendineus communis**,
m. obliquus inferior: **inferior wall of the orbit**

insertion: bulbus oculi

1. **M. LEVATOR PALPEBRAE SUPERIORIS** (N. III)
2. **M. RECTUS SUPERIOR** (N. III)
3. **M. RECTUS INFERIOR** (N. III)
4. **M. RECTUS MEDIALIS** (N. III)
5. **M. RECTUS LATERALIS** (N. VI)
6. **M. OBLIQUUS SUPERIOR** (N. IV)
7. **M. OBLIQUUS INFERIOR** (N. III)

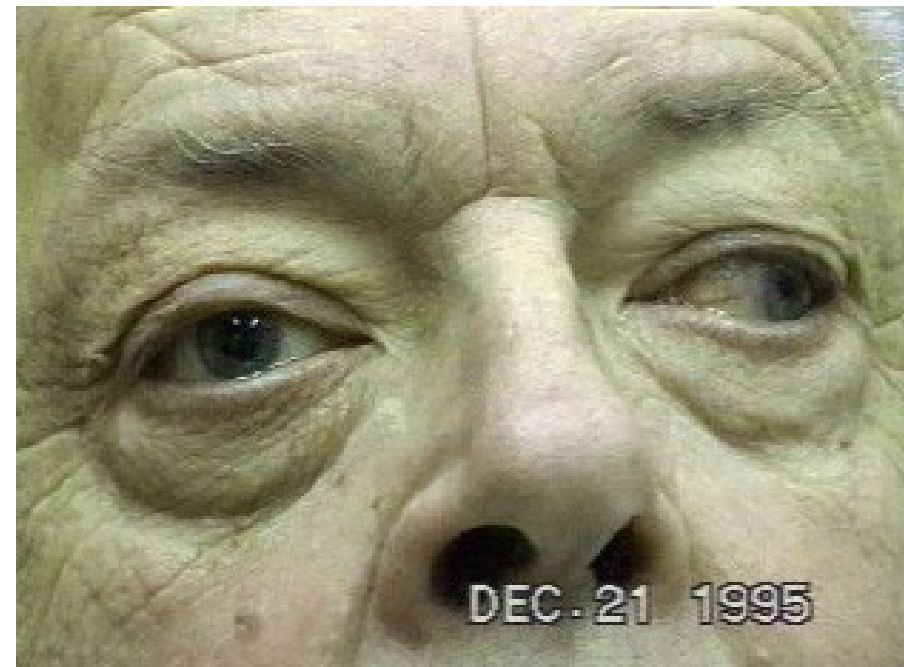
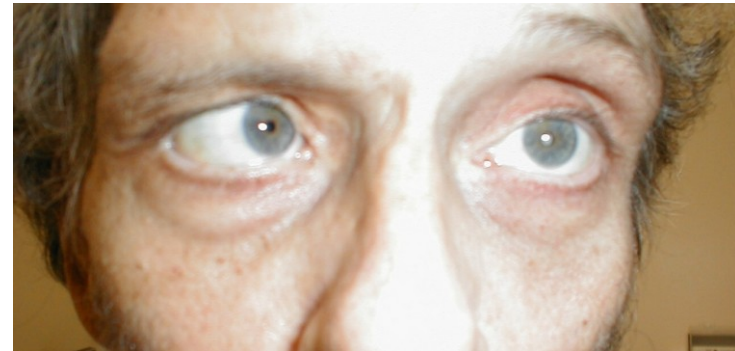
diplopie

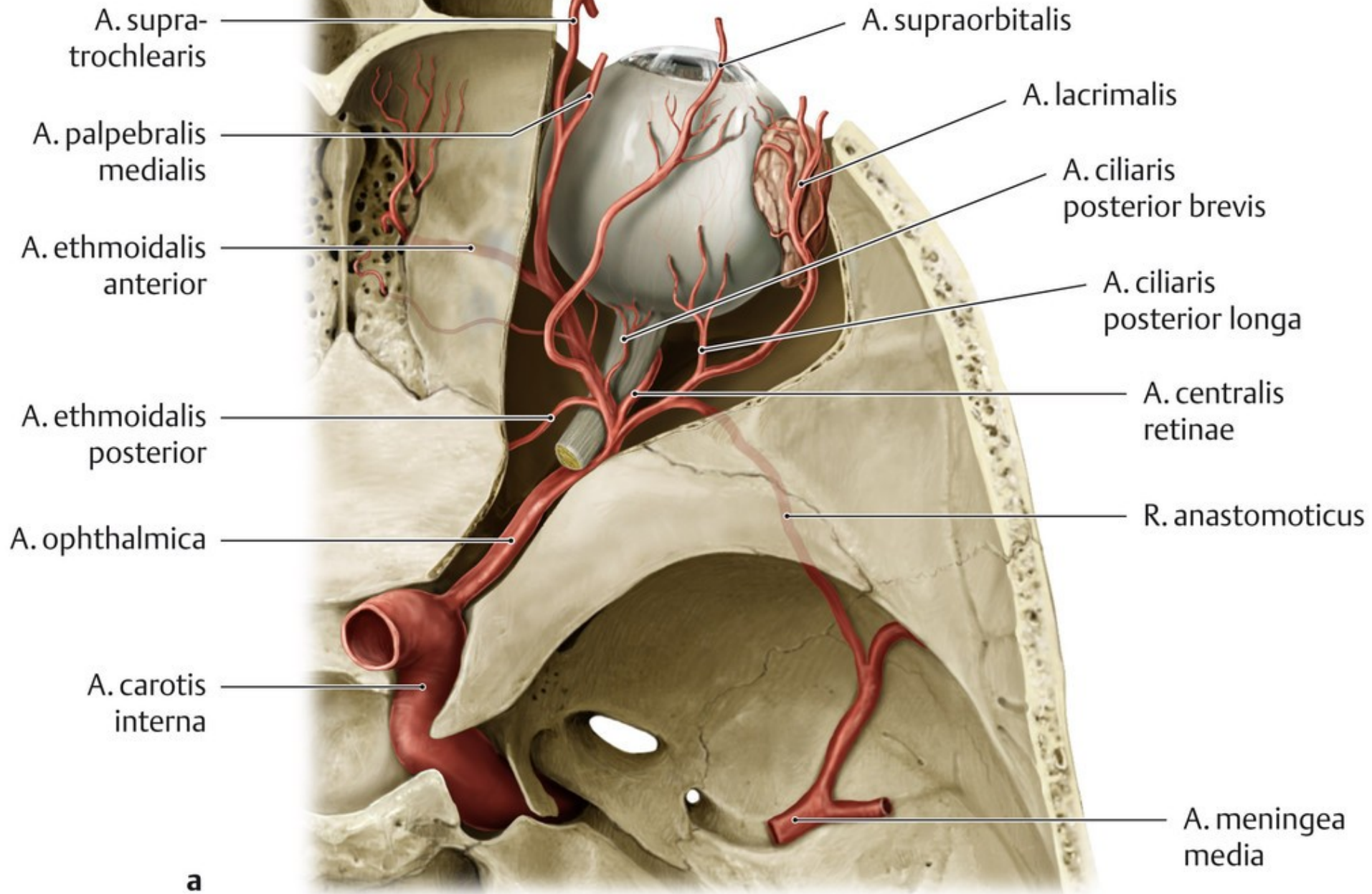
Discoordination of extraocular muscles



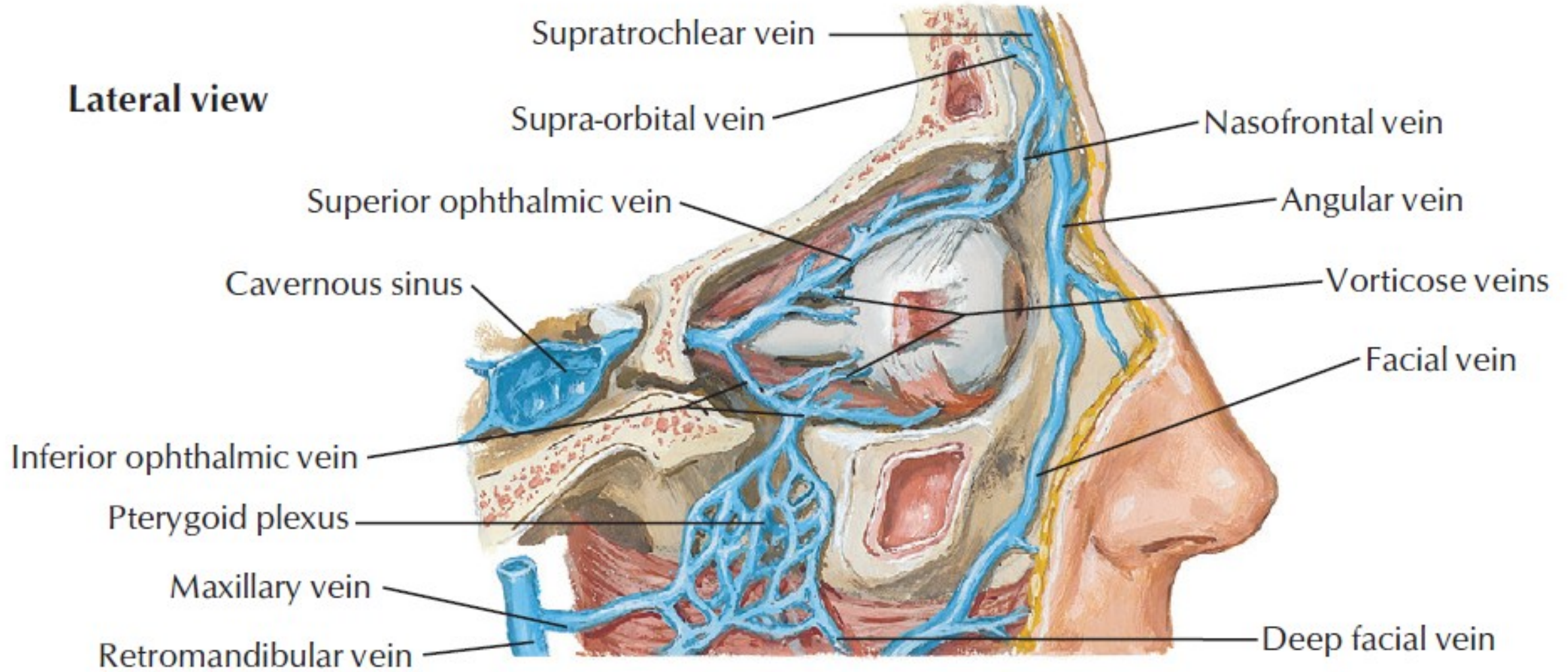
Strabismus



ARTERIA OPHTHALMICA

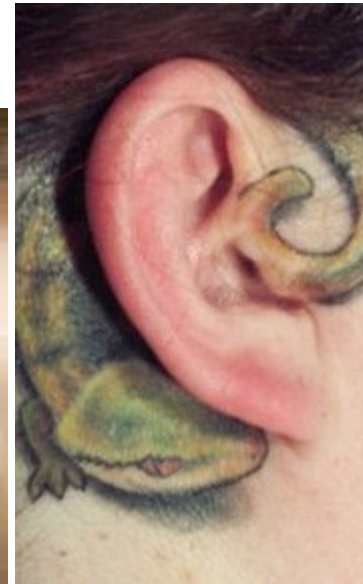
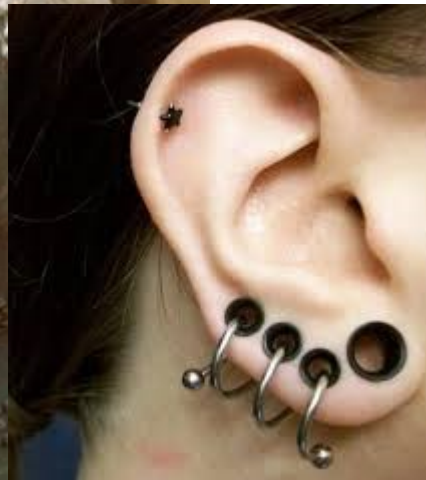
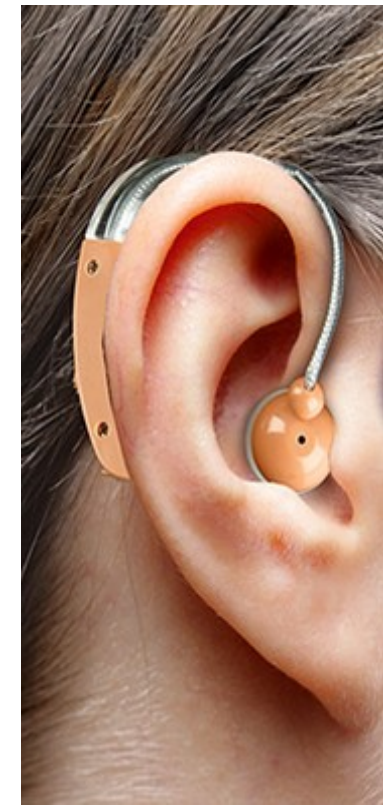VENAE OPHTHALMICAE



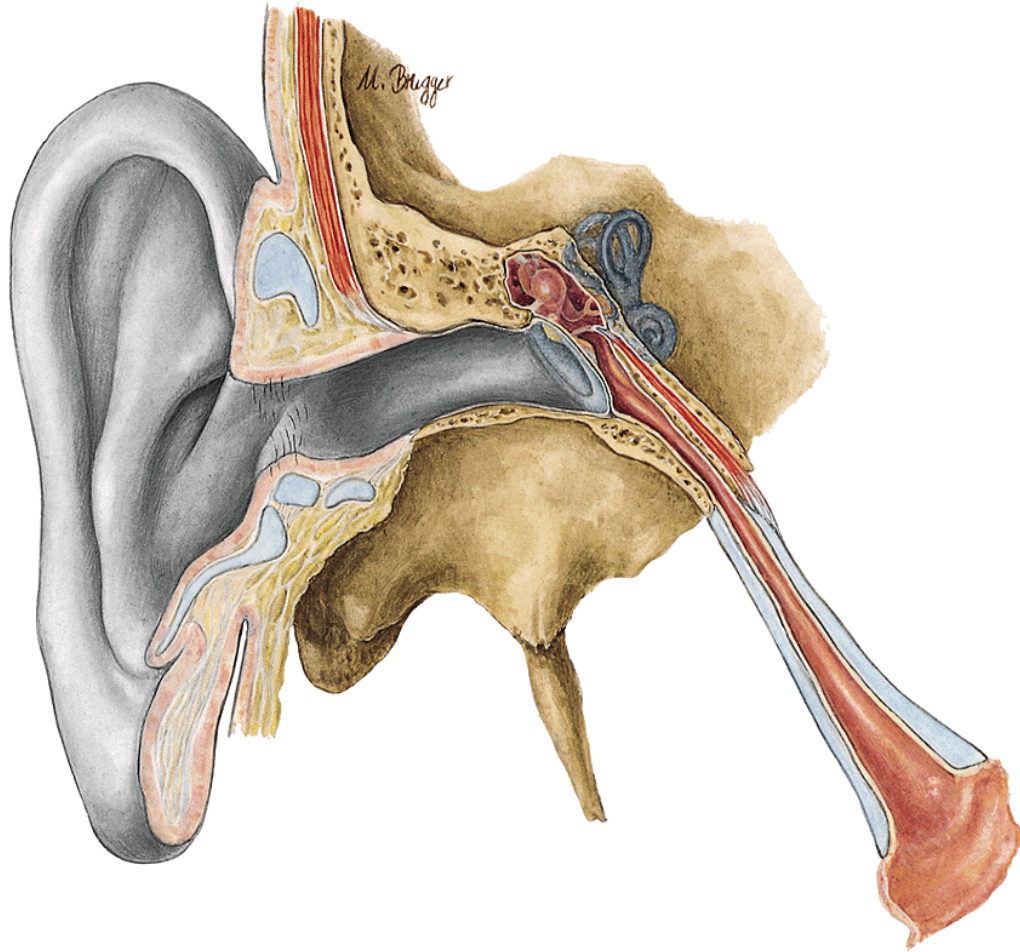
Anastomosis with v. facialis (v. faciei profunda, v. angularis),

Organum vestibulocochleare



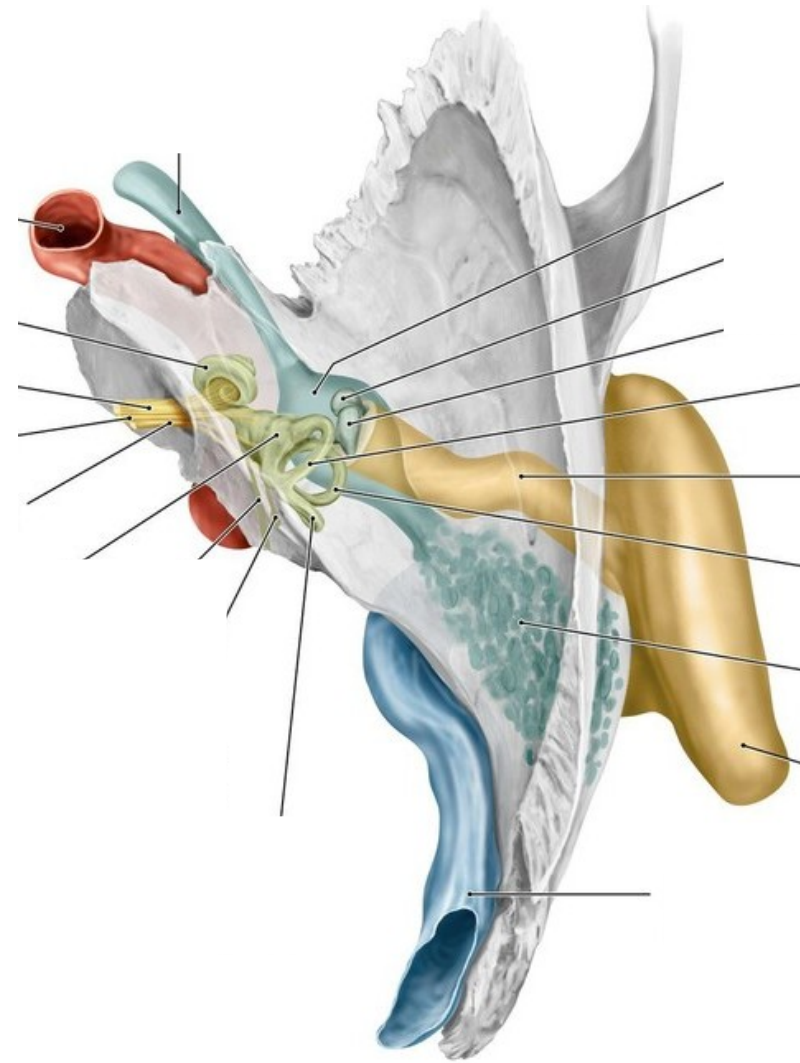
Auris ext.

Auricula
Meatus acusticus ext.
Membrana tymp.



Auris med.

Cavum tympani
Tuba auditiva
Cellulae mastoideae

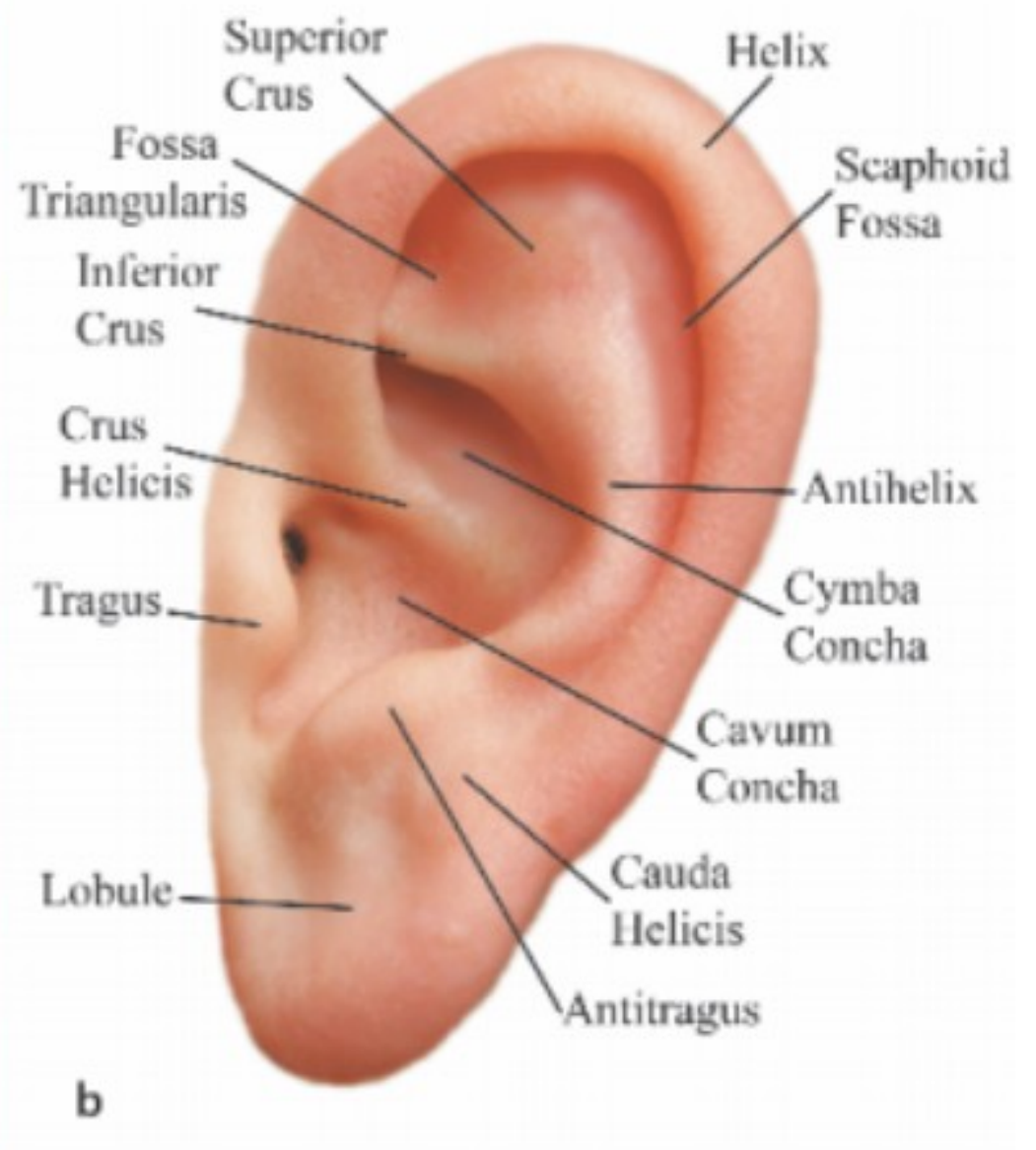
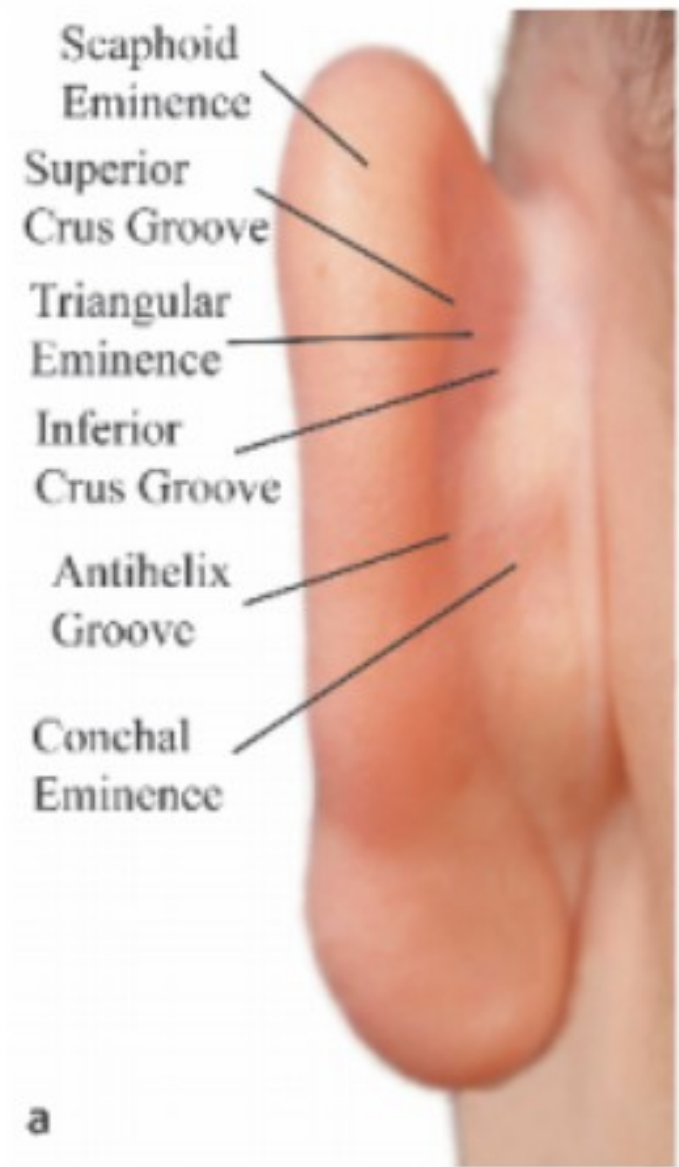


Auris int.

Labyrinthus
osseus et
membranaceus

A. AURIS EXTERNA

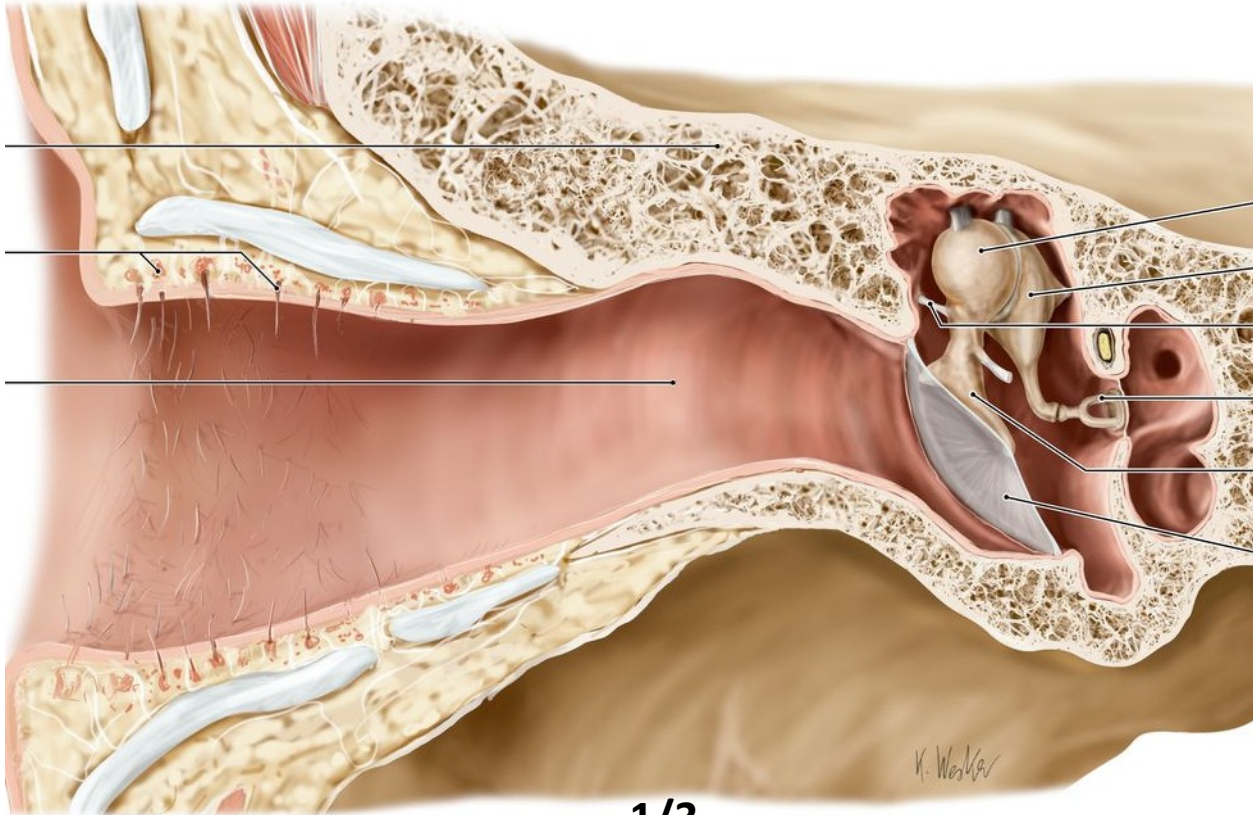
1. Auricula



2. Meatus acusticus ext.

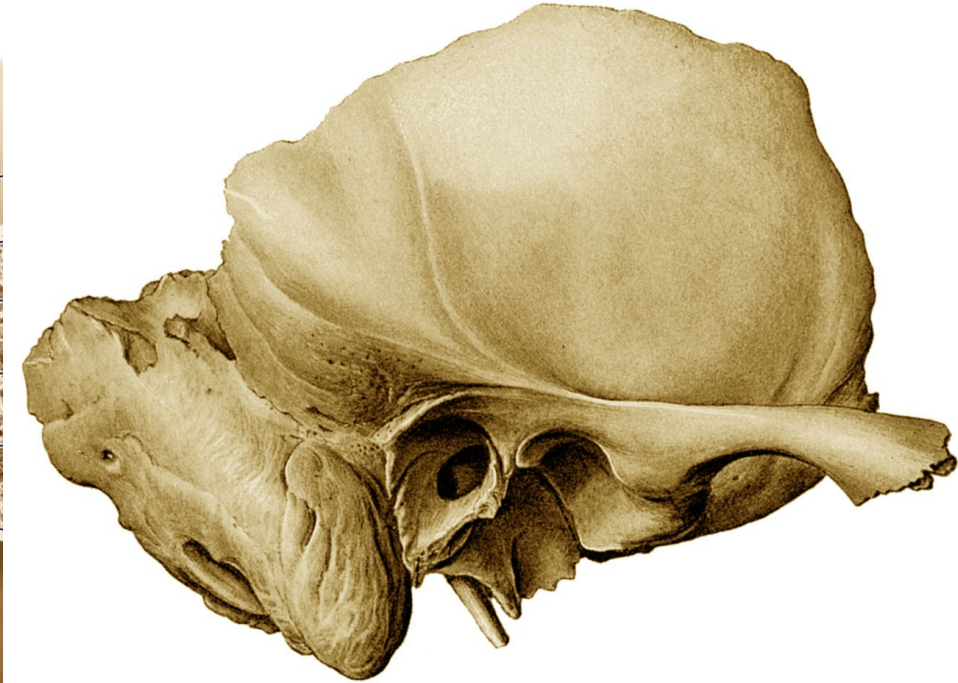2/3

Meatus acusticus
externus cartilagineus

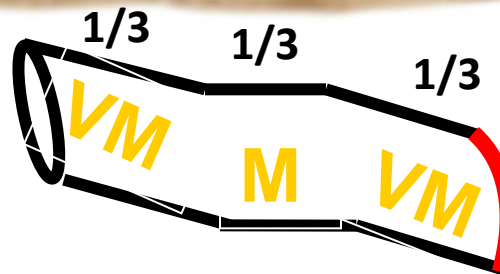


1/3

meatus acusticus externus osseus
(pars tympanica)



Porus
ac. ext.

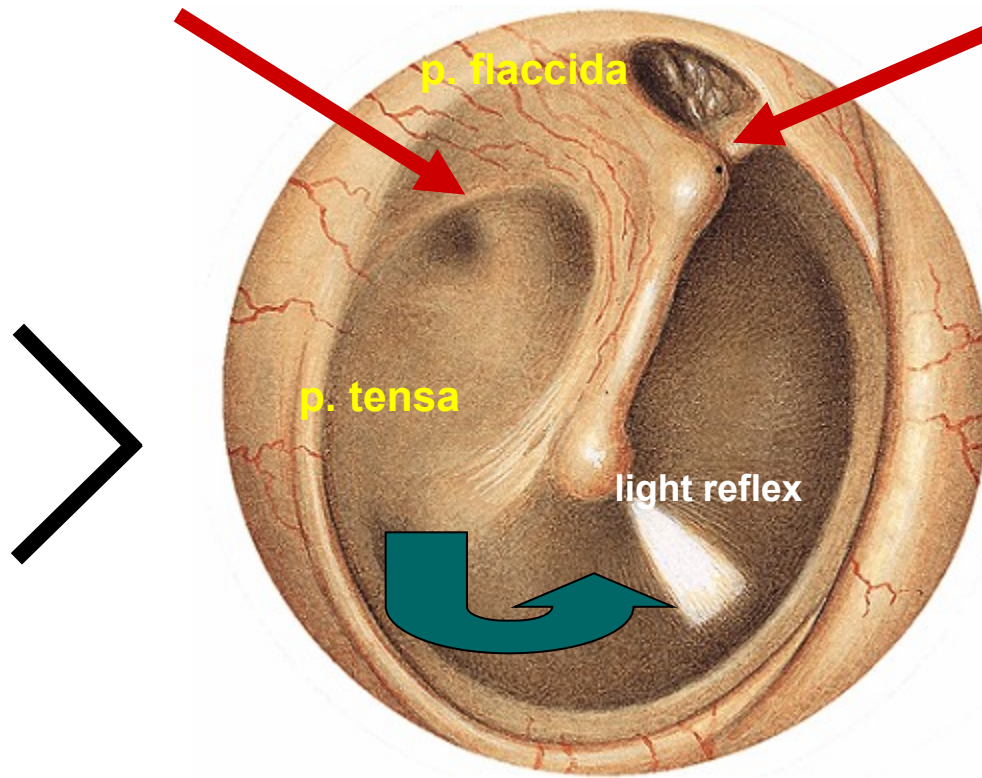


Membr.
tymp.

Skin with glandulae
ceruminosae (cerumen), tragi

3. Membrana tympani

Plica mallearis post.



Plica mallearis ant.

Prominentia mallearis

(proc. lat. mallei)

Stria mallearis

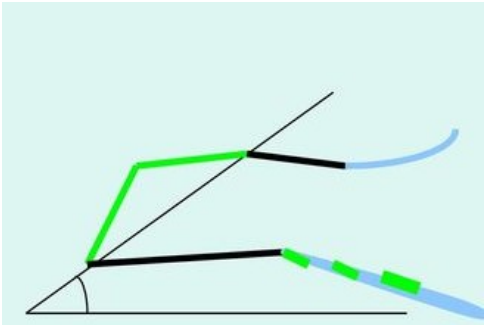
(manubrium m.)

Umbo membraneae tympani

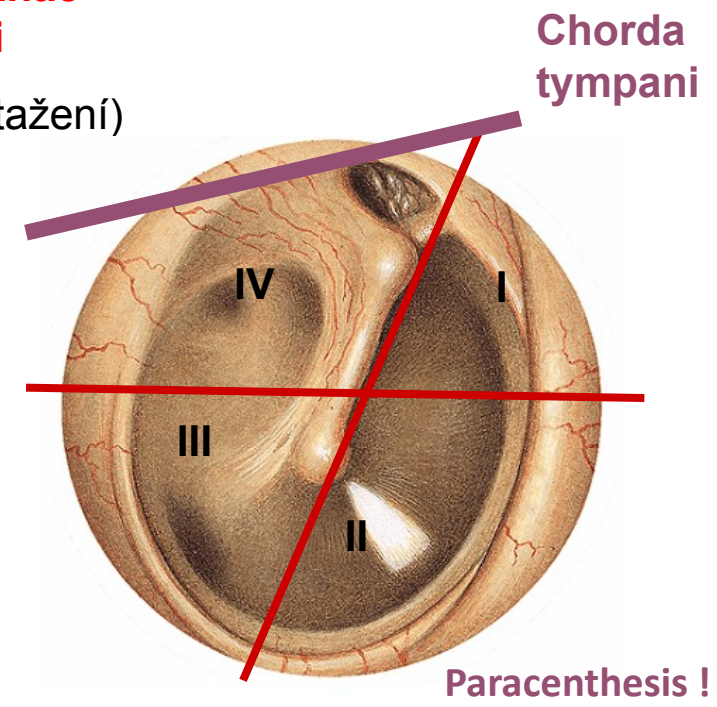
(místo vtažení)

Limbus membranae tympani, anulus fibrocartilagineus in sulcus tympanicus

Structure of (TM)
Stratum fibrosum + anulus fibrocartilagineus, externally skin internally mucosis



Position:
horizontal plane - 45° (inclination of TM)



Paracentesis !

B. AURIS MEDIA

1. Cavum tympani

D p. mastoideus

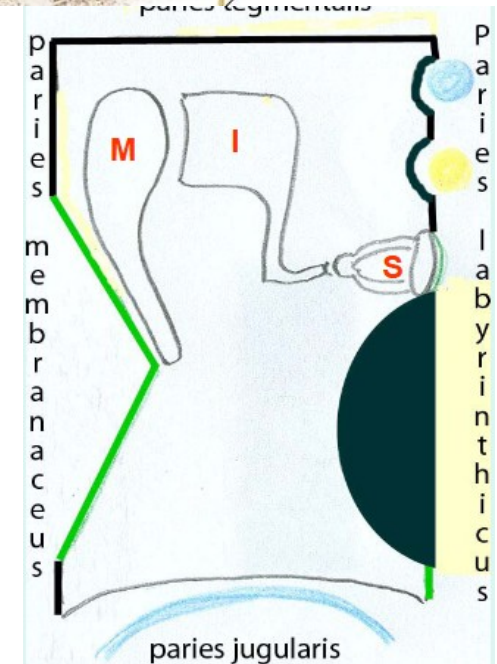
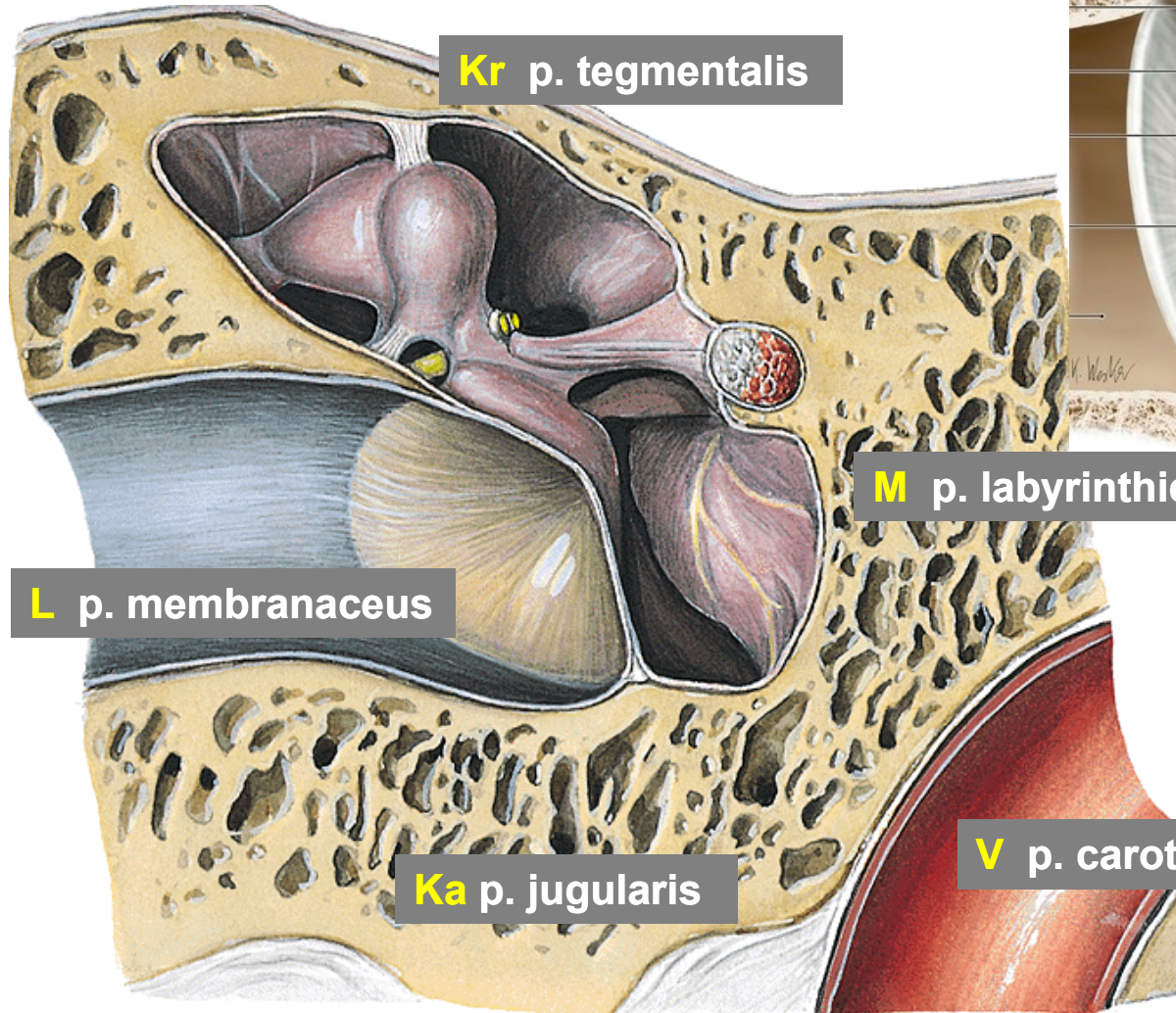
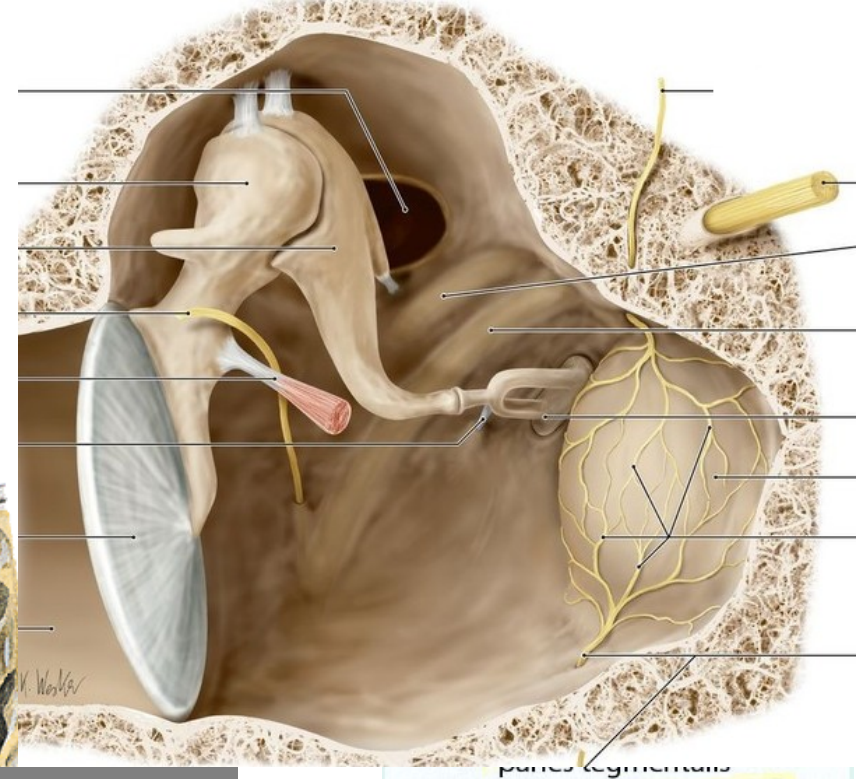
Kr p. tegmentalis

M p. labyrinthicus

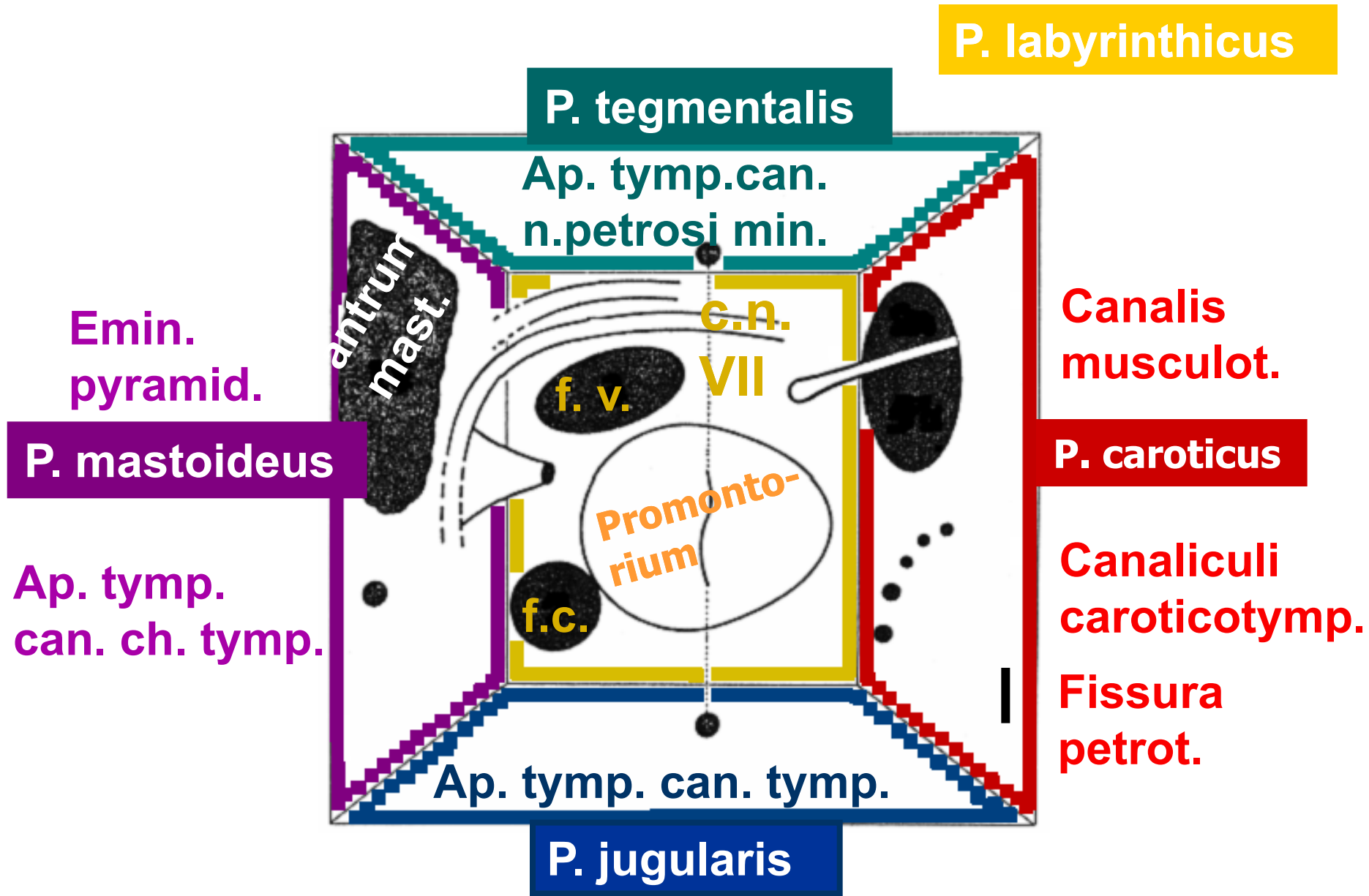
L p. membranaceus

Ka p. jugularis

V p. caroticus



Shape as a biconcave lens



P. labyrinthicus

P. tegmentalis

Ap. tympan. can.
n. petrosi min.

Emin.
pyramid.

P. mastoideus

antrum
mast.

c.n.
VII

f. v.

Promontorium

f.c.

Ap. tympan.
can. ch. tympan.

P. caroticus

Canalis
musculot.

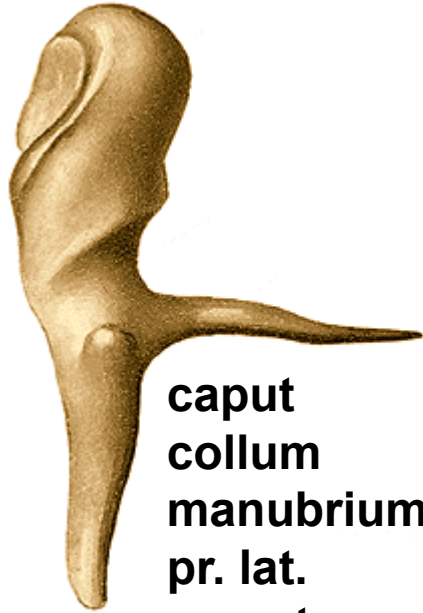
Canaliculi
caroticotymp.

Fissura
petrot.

Ap. tympan. can. tympan.

P. jugularis

Malleus



caput
collum
manubrium
pr. lat.
pr. ant.

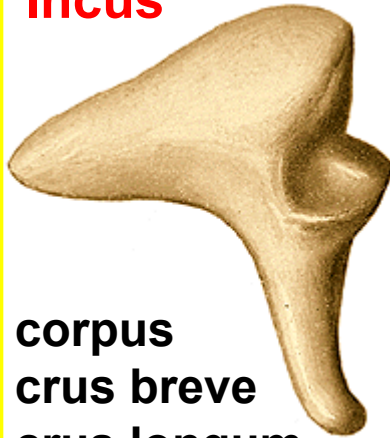
Stapes



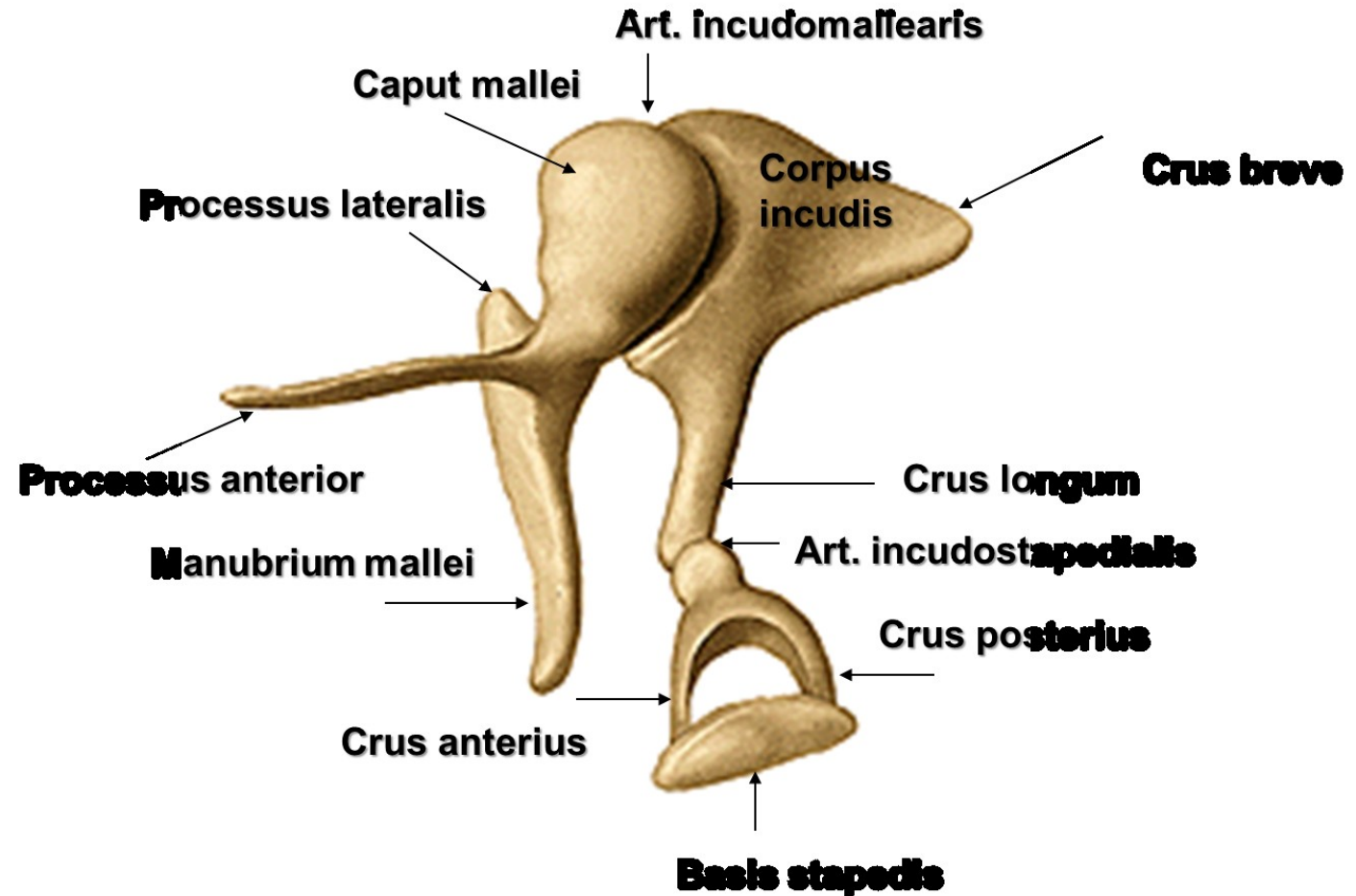
caput
crus ant.
crus post.
basis

Ossicula auditus

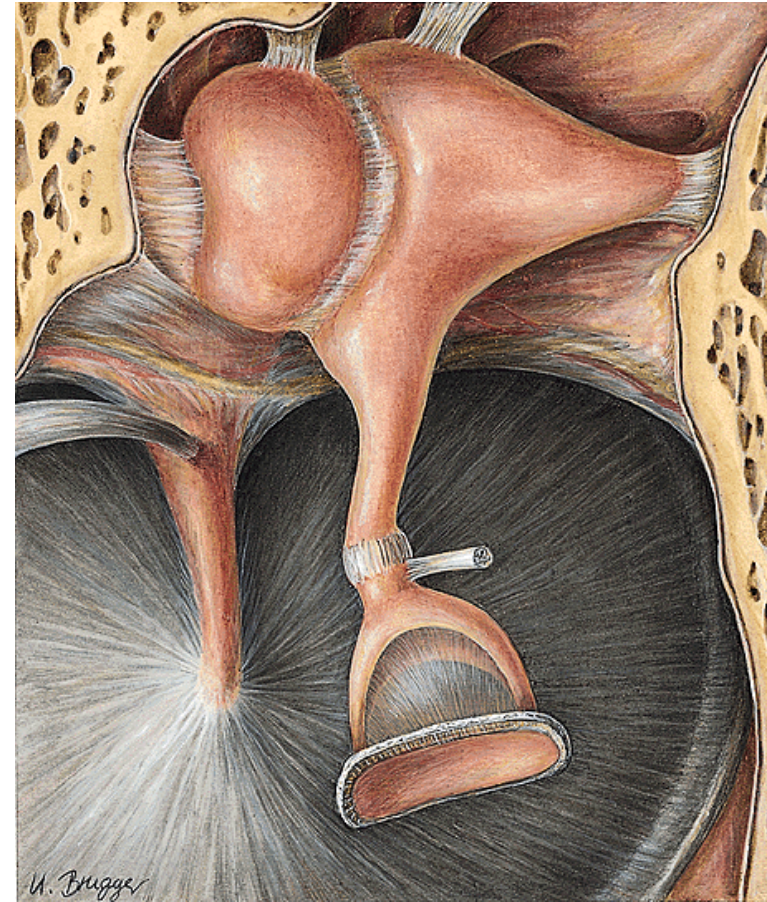
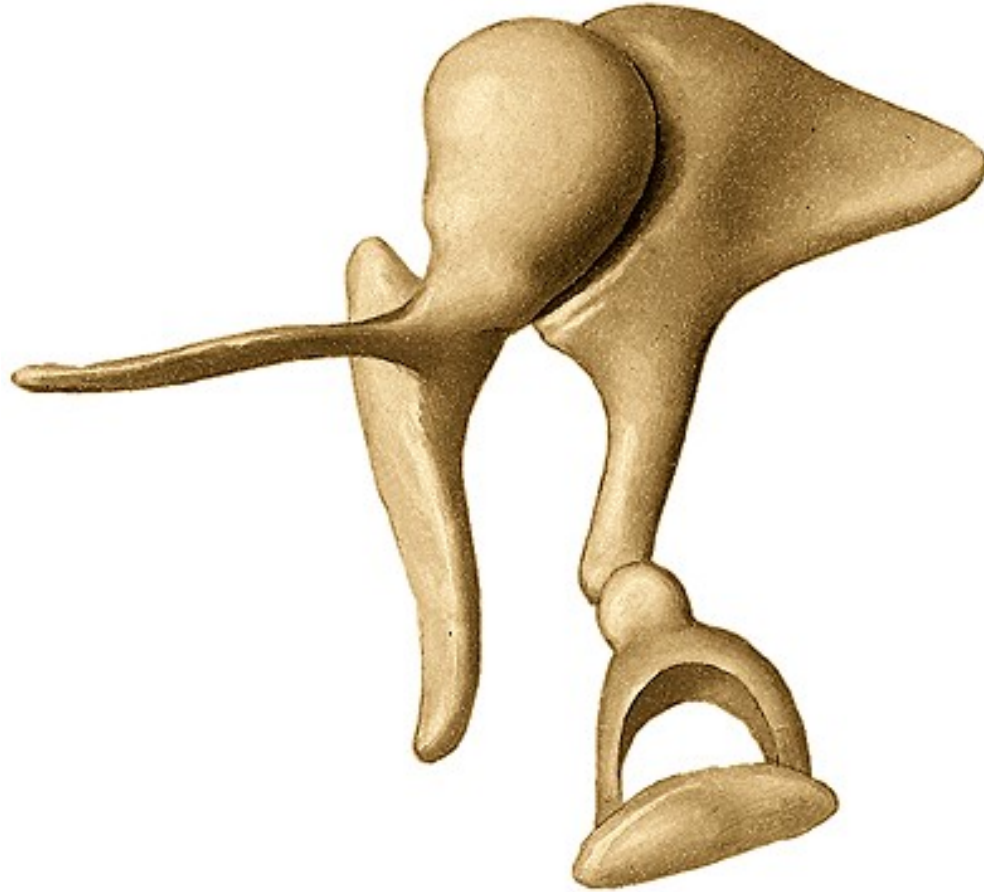
Incus



corpus
crus breve
crus longum
pr. lenticularis



Connections of ossicula auditus



1. joints

Art. incudomallearis

Art. incudostapedia

2. bands

lig. mallei sup., lat., ant.

lig. incudis sup., post.

membrana stapedis

lig. anulare stapedis

3. muscles

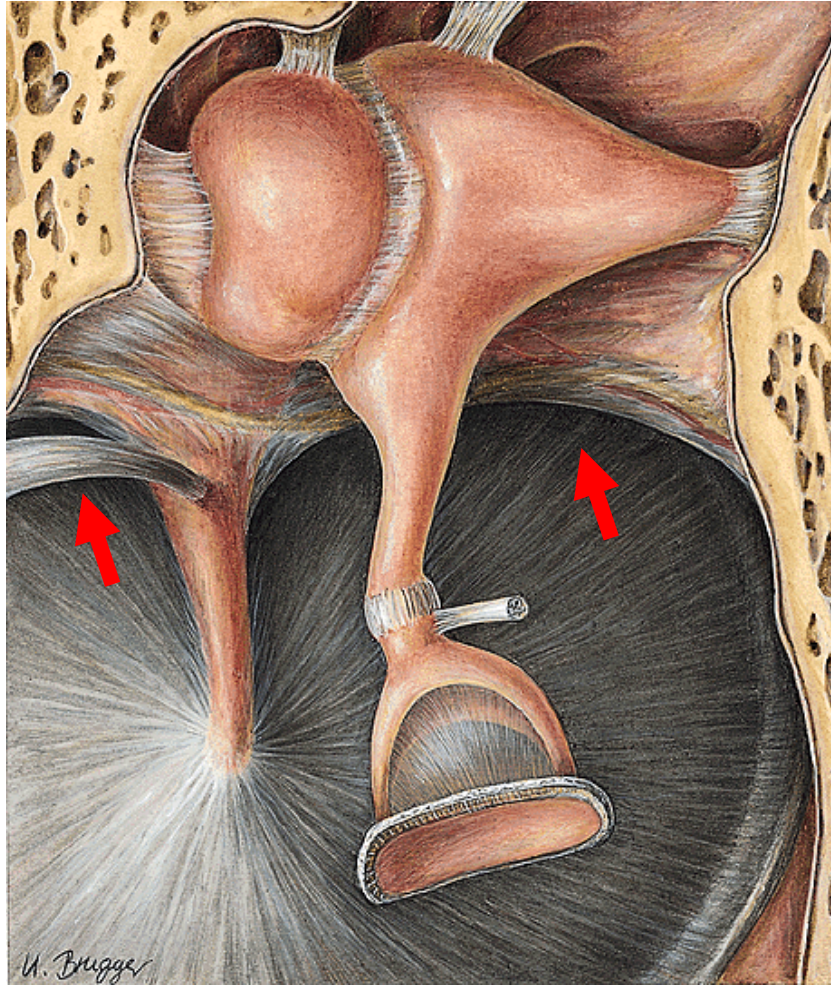
M. stapedius

M. tensor tympani

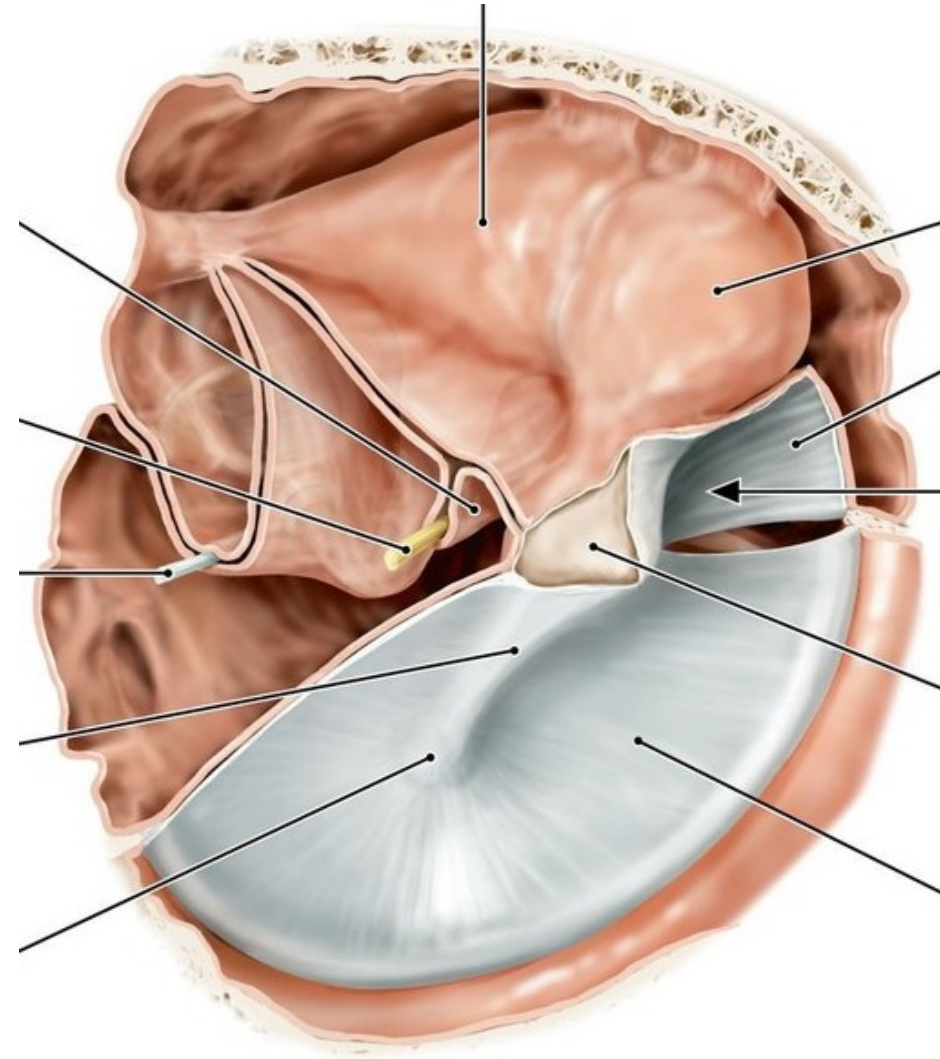
Mucose of middle ear

Plica chordae tymp.

Plica chordae tymp.



**Recessus
membranae tympani
ant.**



**Recessus
membranae tympani
post.**

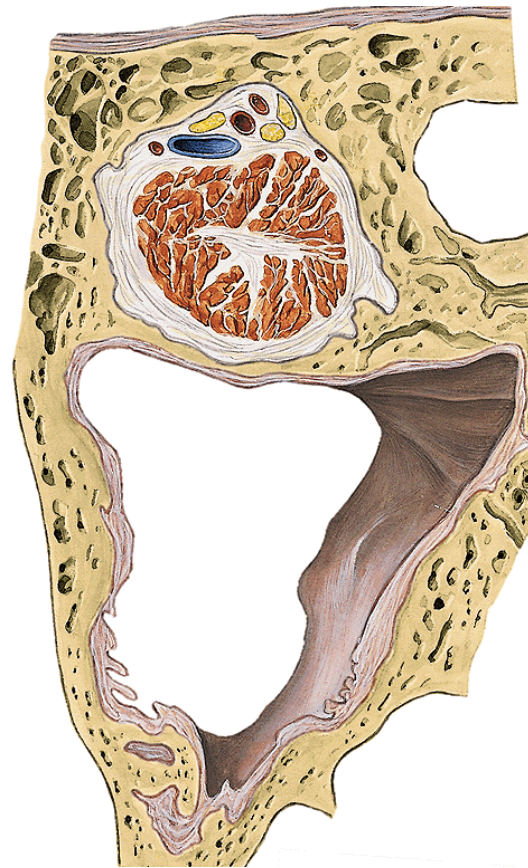2. Tuba auditiva

joins tympanic cavity with pharynx
(baroperception)

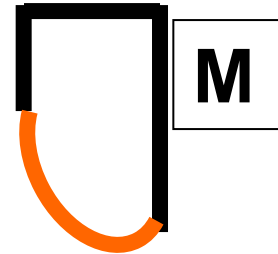
ostium pharyngeum TA – lat. + dors. + up
and opens in TC to anterior wall as ostium
tympanicum of TA.

Lateral 1/3 is located in semicanalis TA =
pars ossea TA,

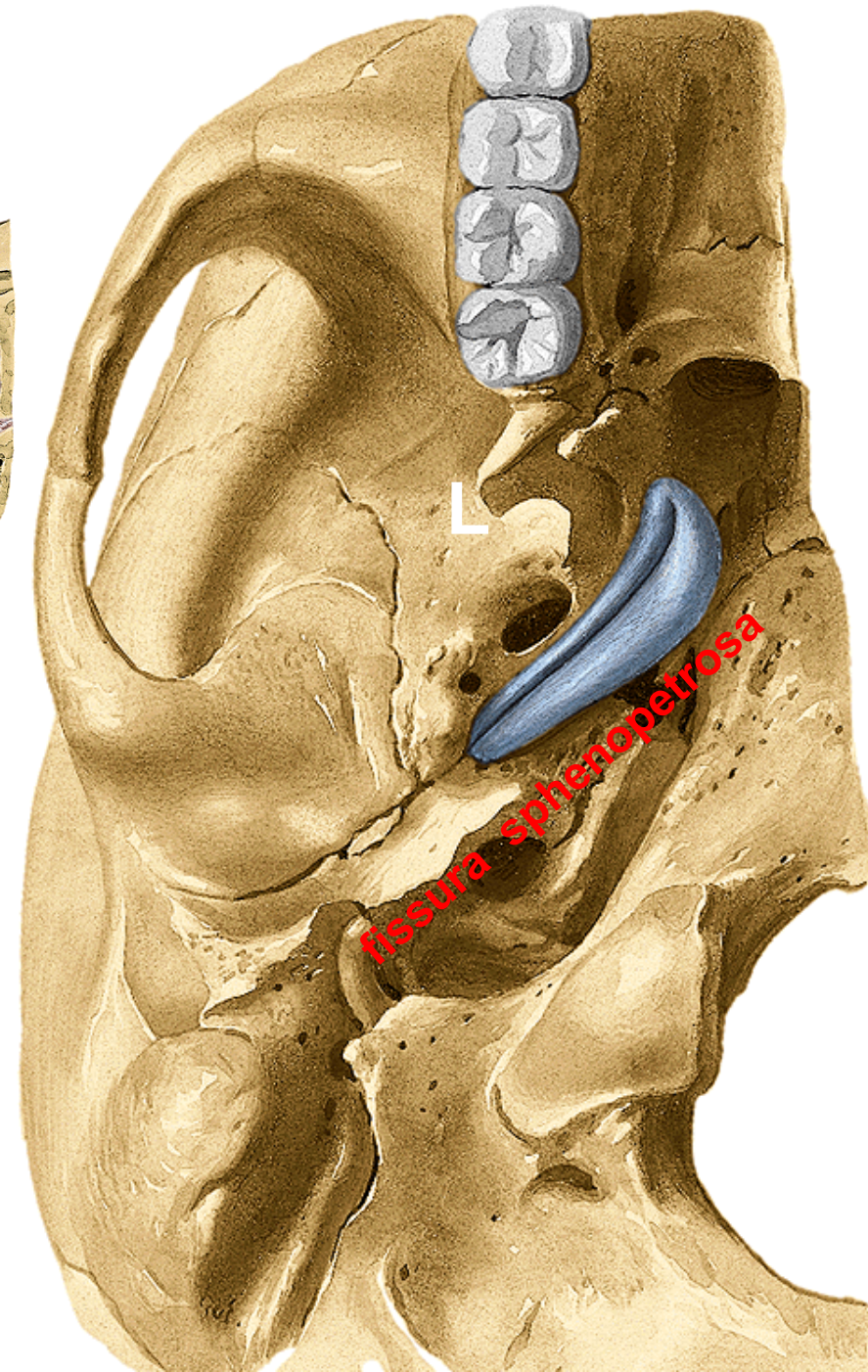
medial 2/3 = pars cartilaginea TA – is
opened caudally (with lamina
membranacea), between bone and
cartilaginous part is isthmus TA;

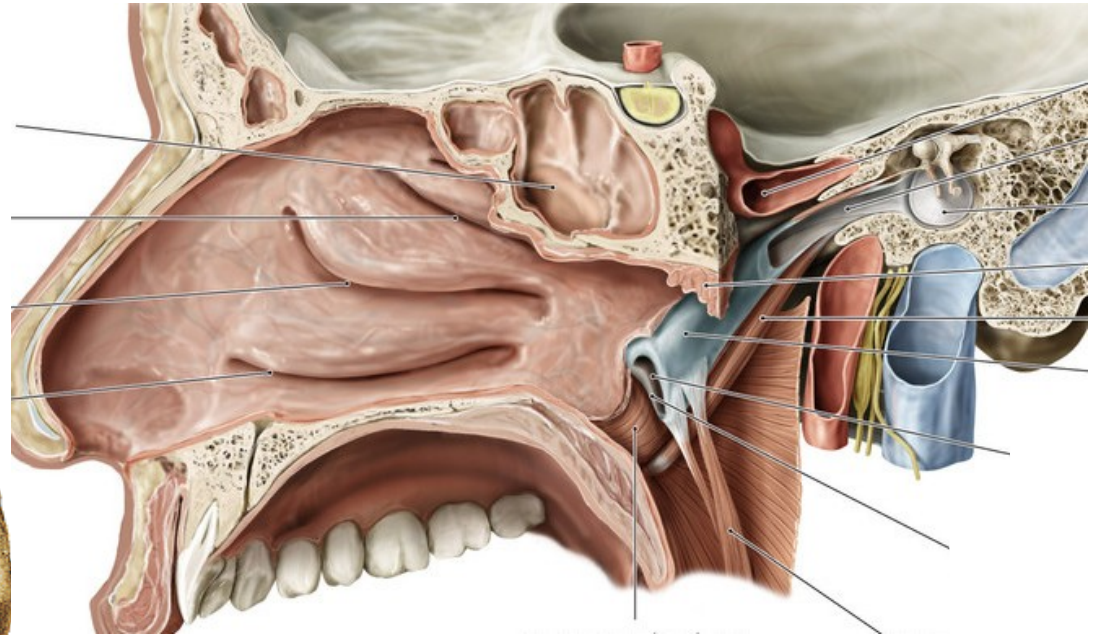
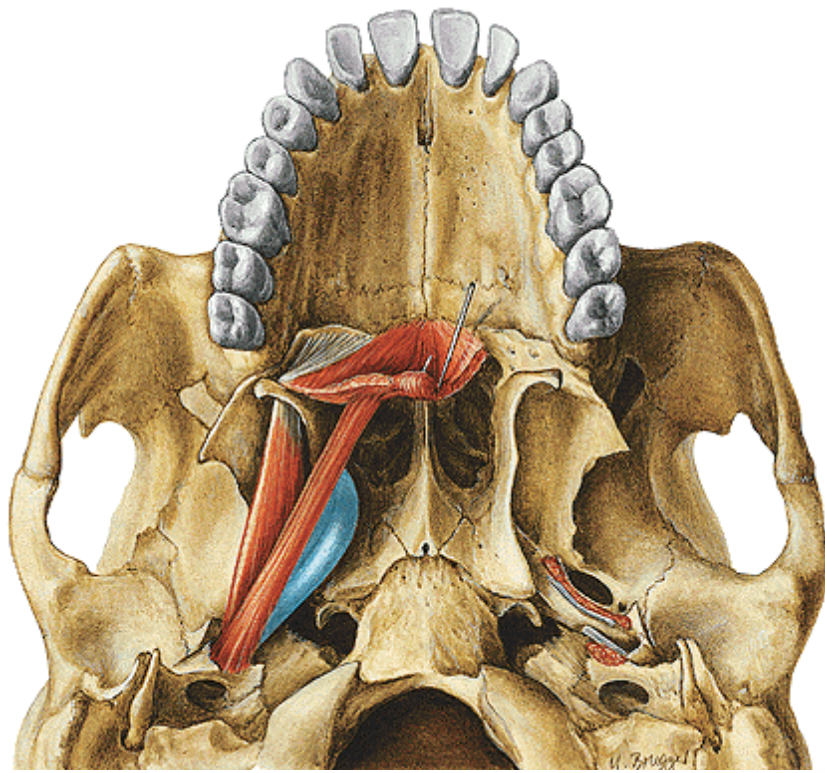


Kr



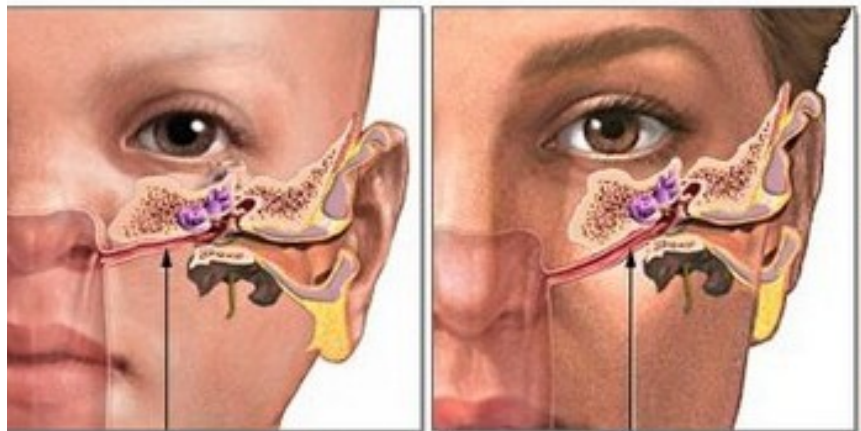
lamina membranacea



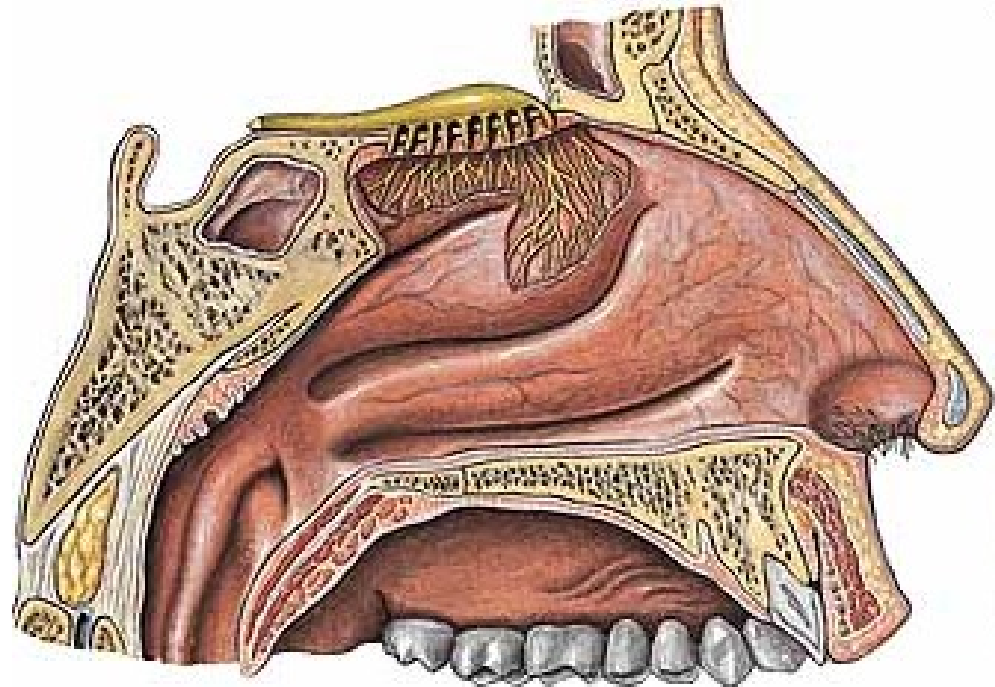


Dítě

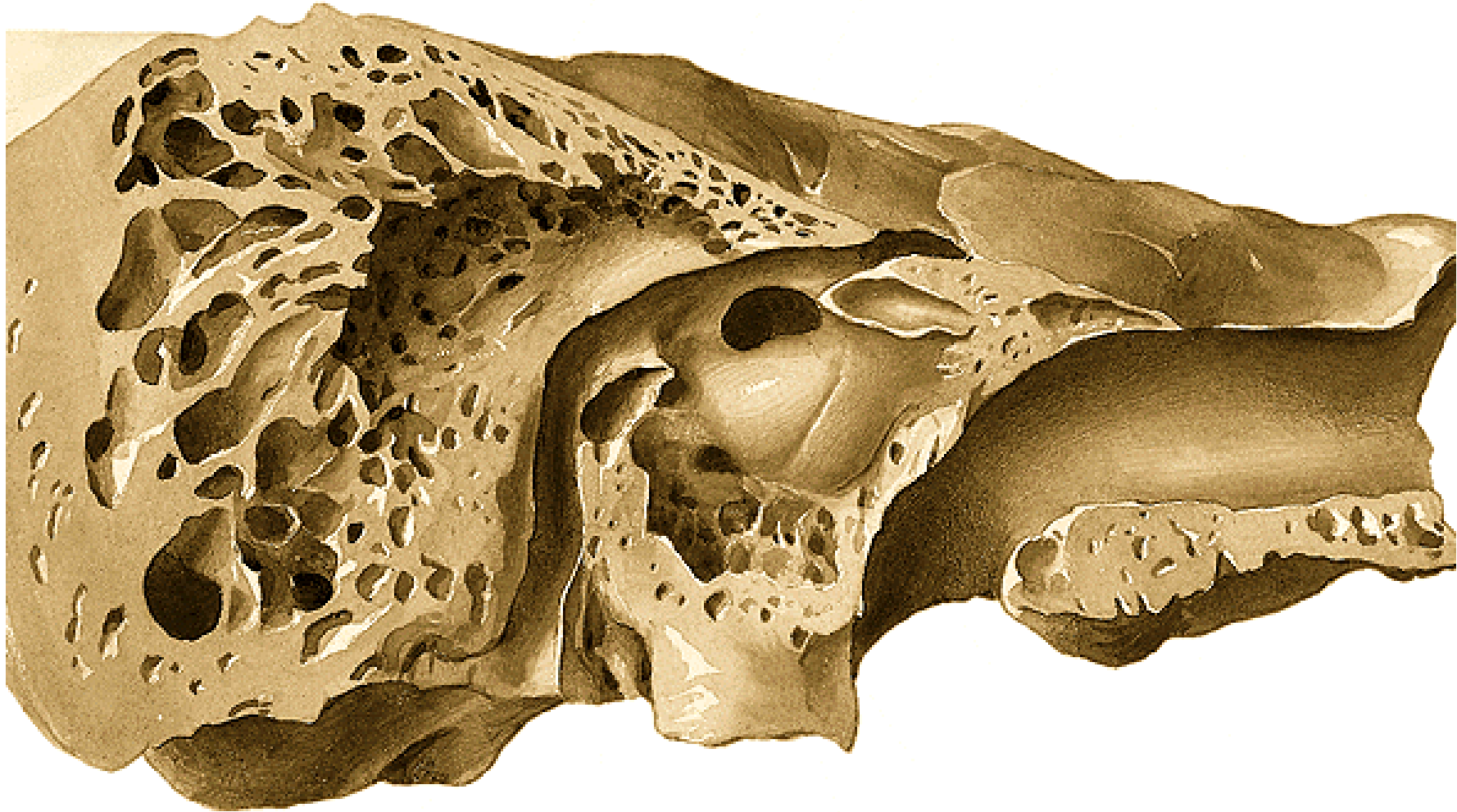
Dospělý



Eustachova trubice

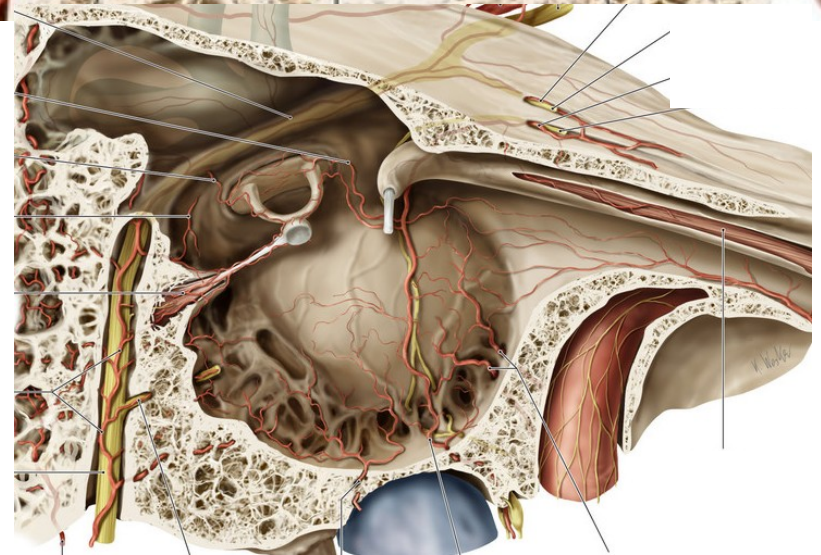
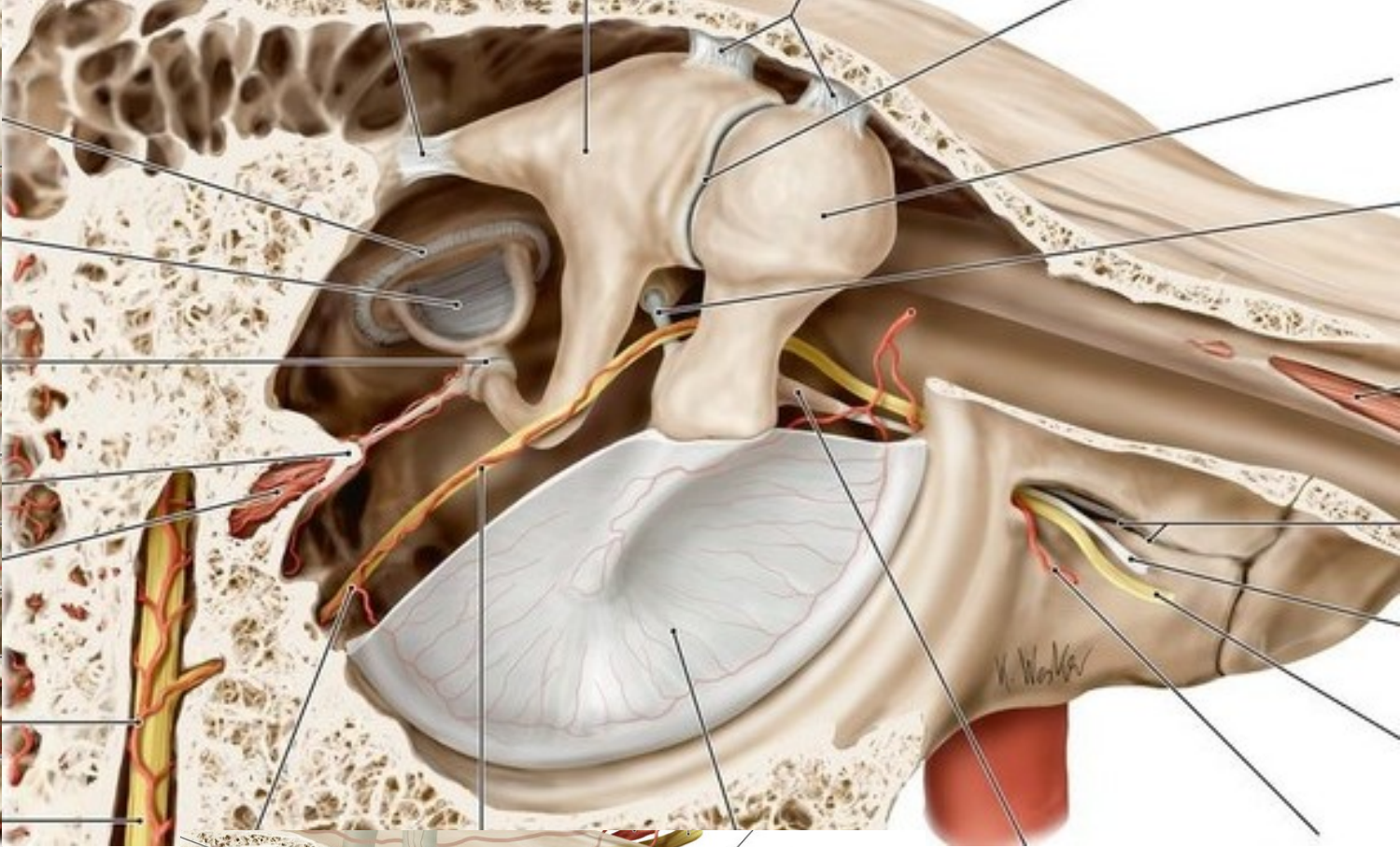
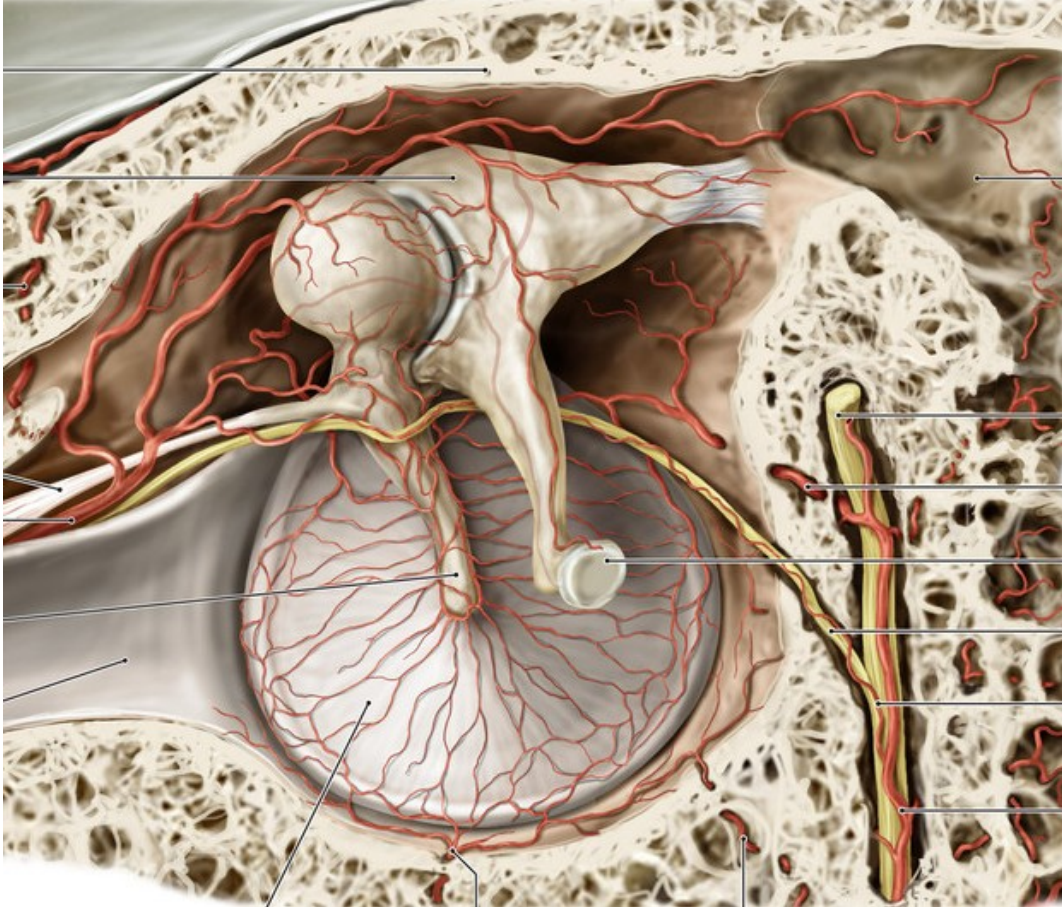


3. Cellulae mastoideae



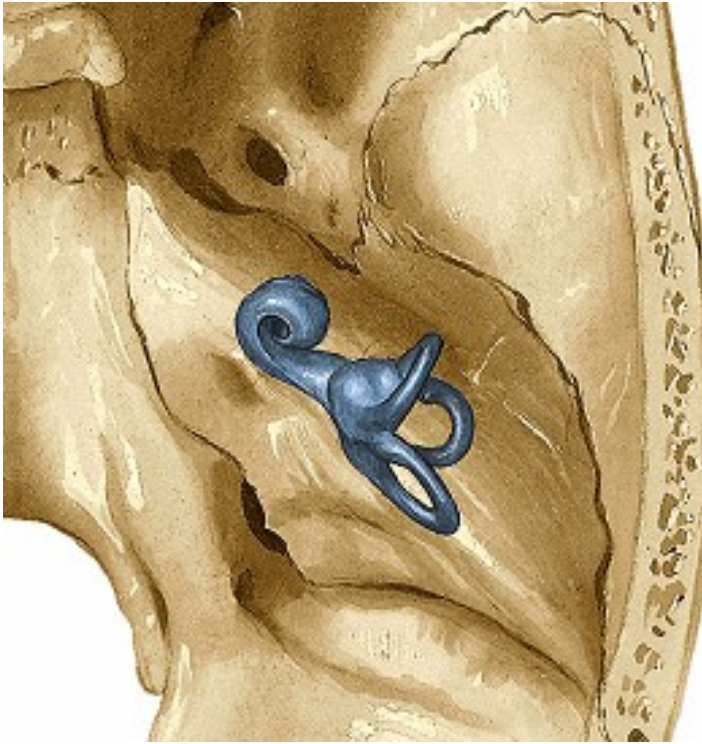Antrum mastoideum

Relationship with sinus sigmoideus



C. AURIS INTERNA

Labyrinthus osseus

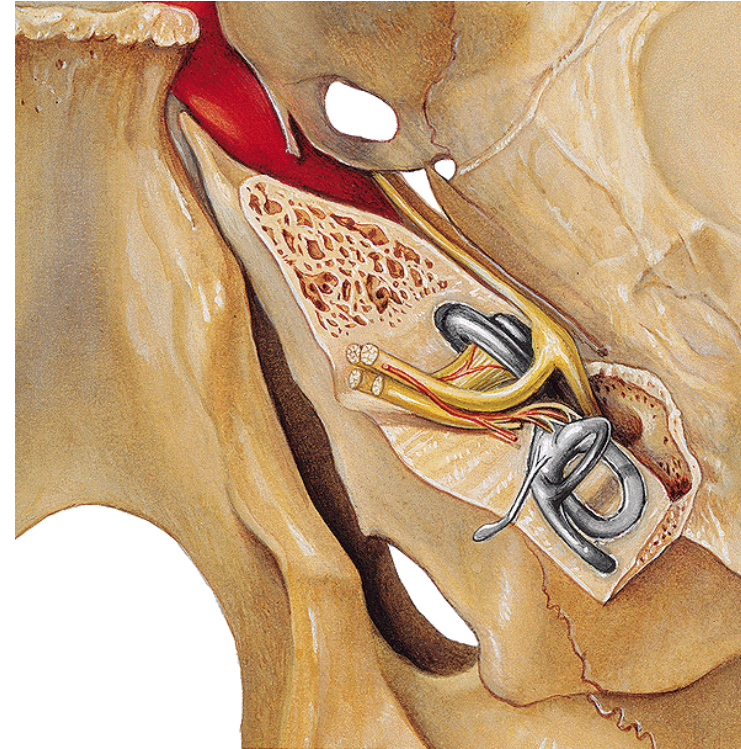


Vestibulum

Canales semicirculares ossei

Cochlea

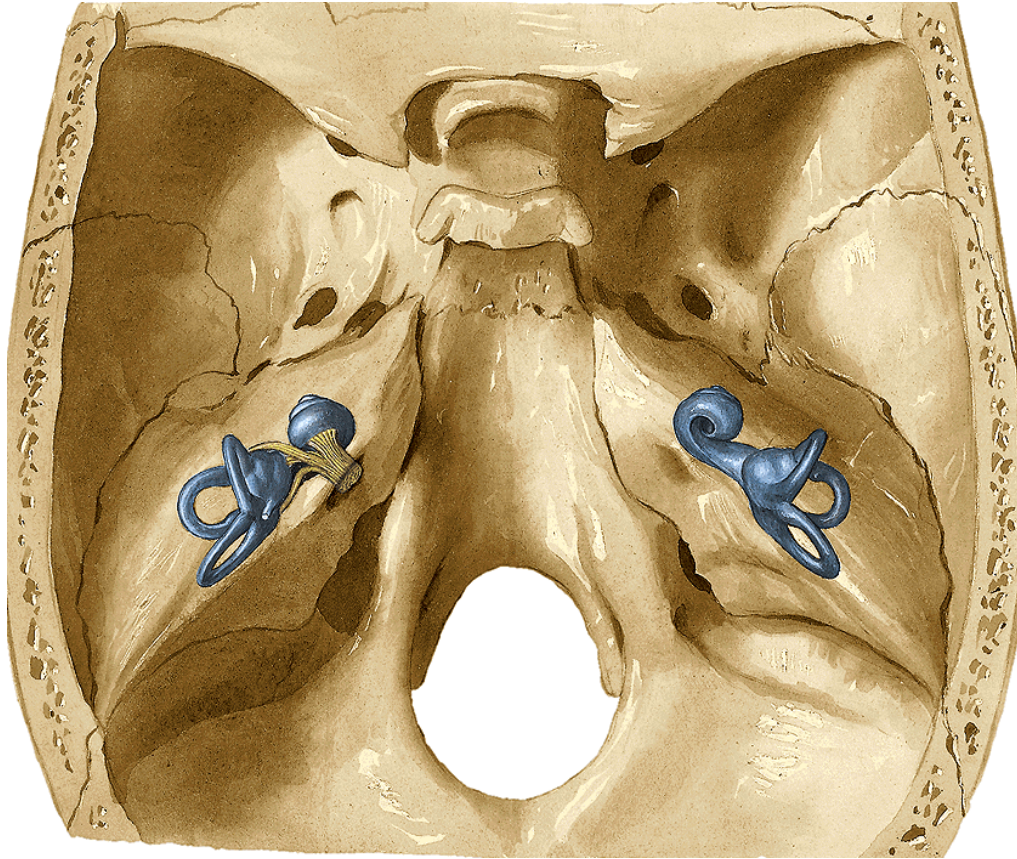
Labyrinthus membranaceus



Labyrinthus vestibuli (utricleus, sacculus, ductus semicirculares)

Labyrinthus cochlae (ductus cochlearis)

Labyrinthus osseus



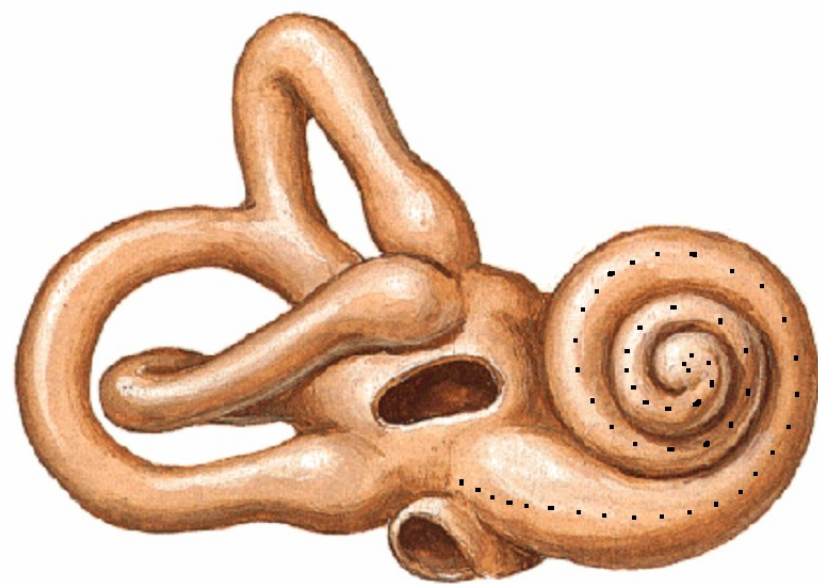■ pars cochlearis
cochlea

■ pars vestibularis

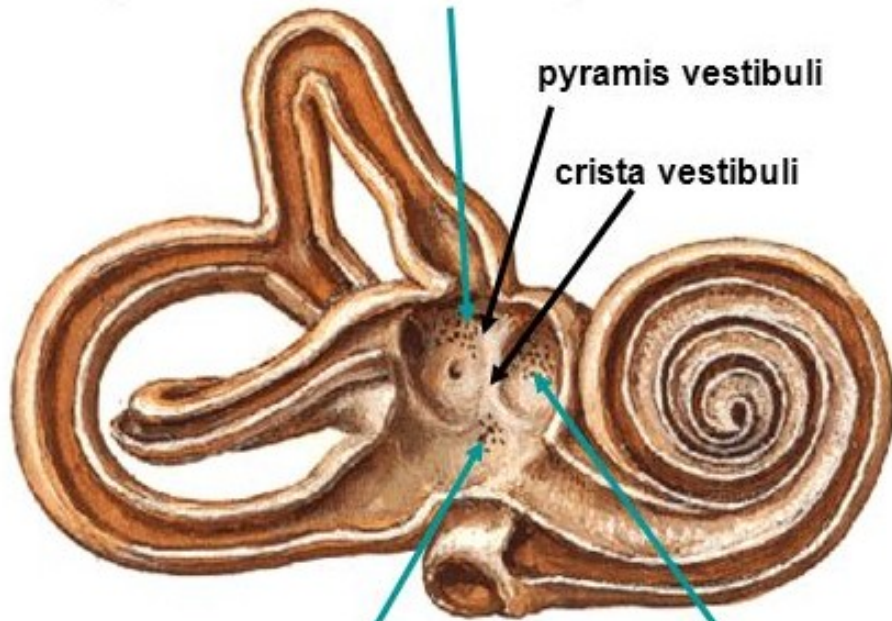
vestibulum

canalis semicircularis ossei

Perilymfa



recessus ellipticus - macula cribrosa superior



pyramis vestibuli

crista vestibuli

recessus cochlearis - macula cribrosa inferior

recessus sphericus - macula cribrosa media

Lateral wall (tympanic):

fenestra vestibuli (for basis stapedis)

Vestibulum

Medial wall:

crista vestibuli with pyramis vestibuli

recessus utriculi=ellipticus with macula cribrosa superior (for n. utriculoampullaris) and utricle

recessus sacculi=sphericus with macula cribrosa media (for n. saccularis) and saccule

recessus cochlearis with macula cribrosa inferior (for acoustic nerve)

apertura interna aquaeductus vestibuli (ductus endolymphaticus)

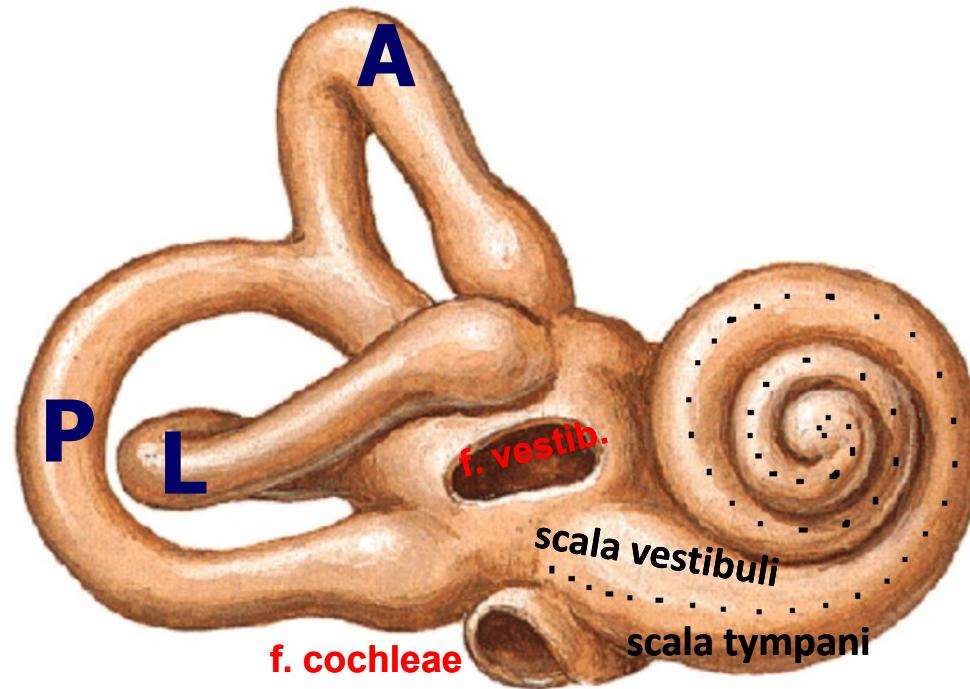
macula cribrosa posterior (n. ampullaris posterior)

Anterior wall – communication with scala vestibuli

Posterior wall – openings of semicircular canals

Canales semicirculares ossei

Canales semicirculares ossei
lateralis, anterior, posterior
crus osseum simplex and commune,
crus osseum ampullare




Cochlea

Anterior part of labyrinth,
Lying anterior to the vestibule




Modiolus

= central conical axis
basis modioli
(tractus spiralis foraminosus),



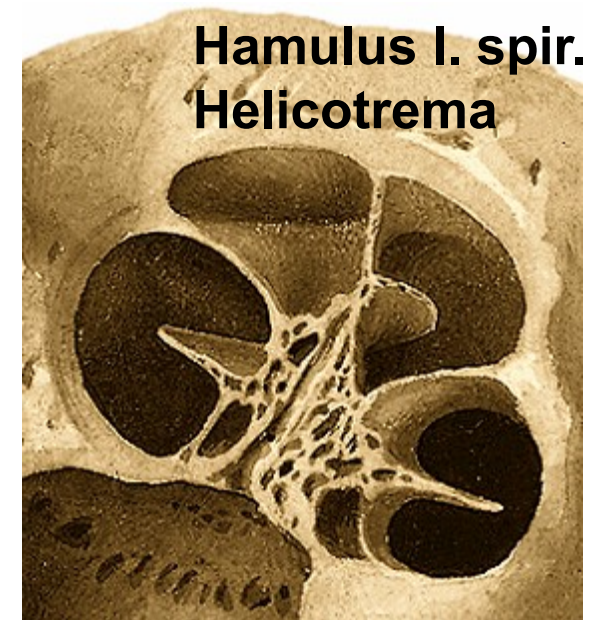
Lamina spiralis ossea

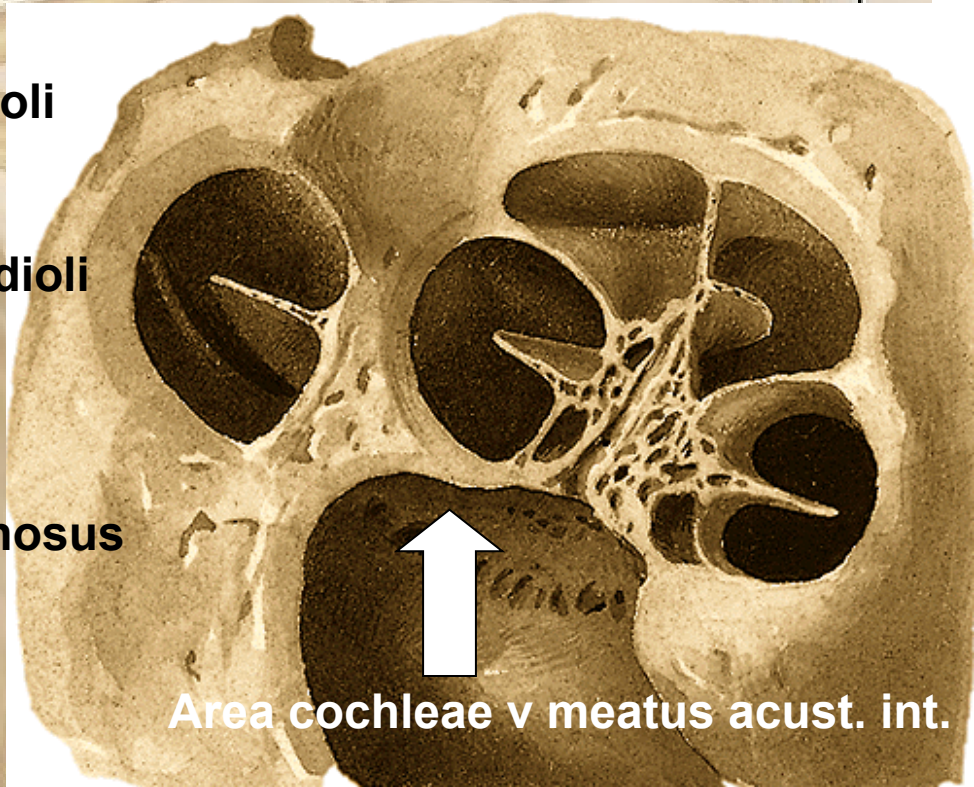
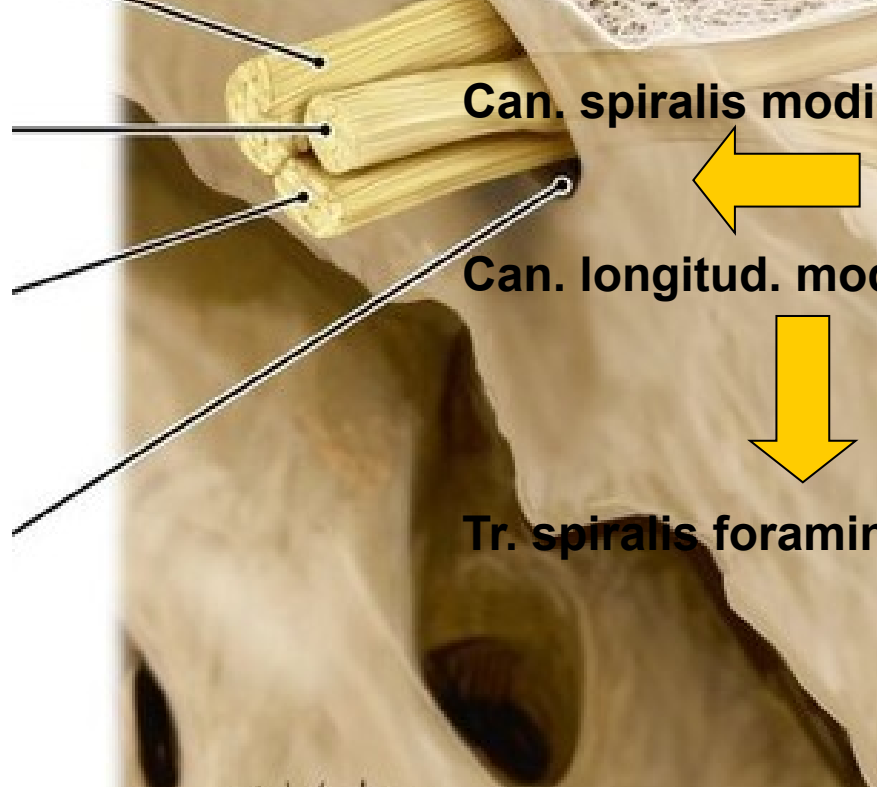
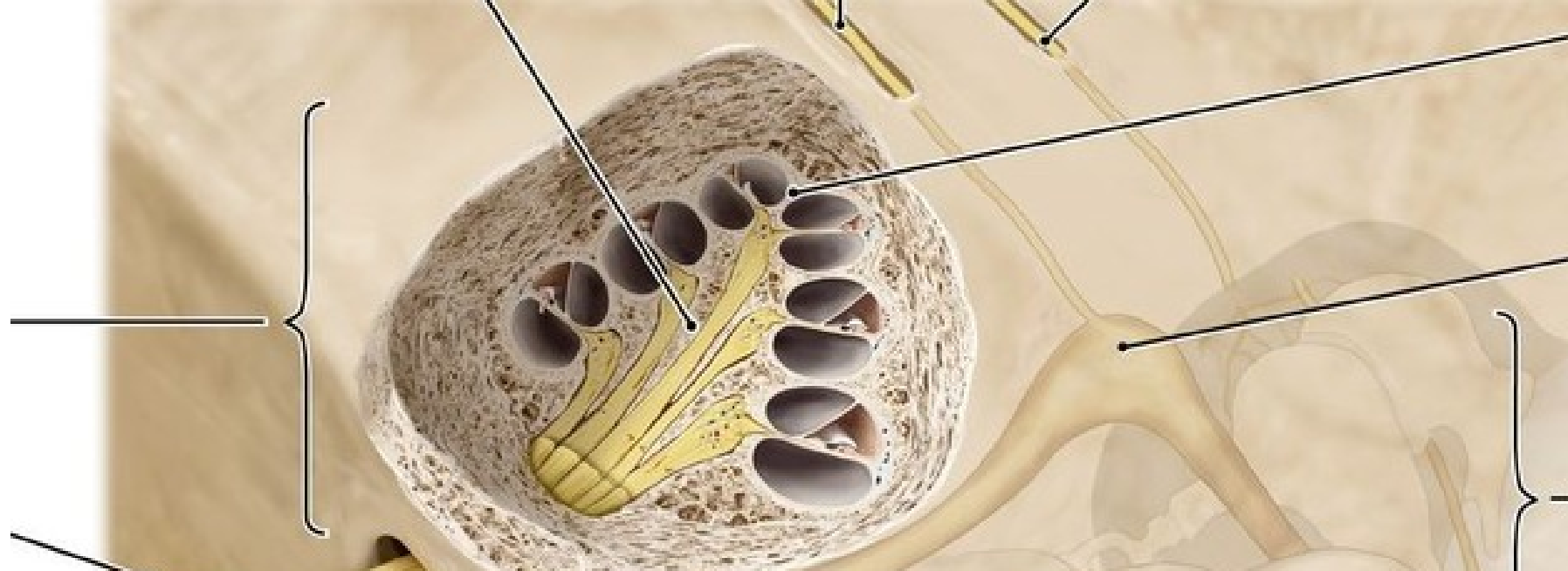
Scala vestibuli (opens to vestibulum),
scala tympani (opens to CT –
membrana tympani secundaria),
hamulus laminae spiralis,
helicotrema



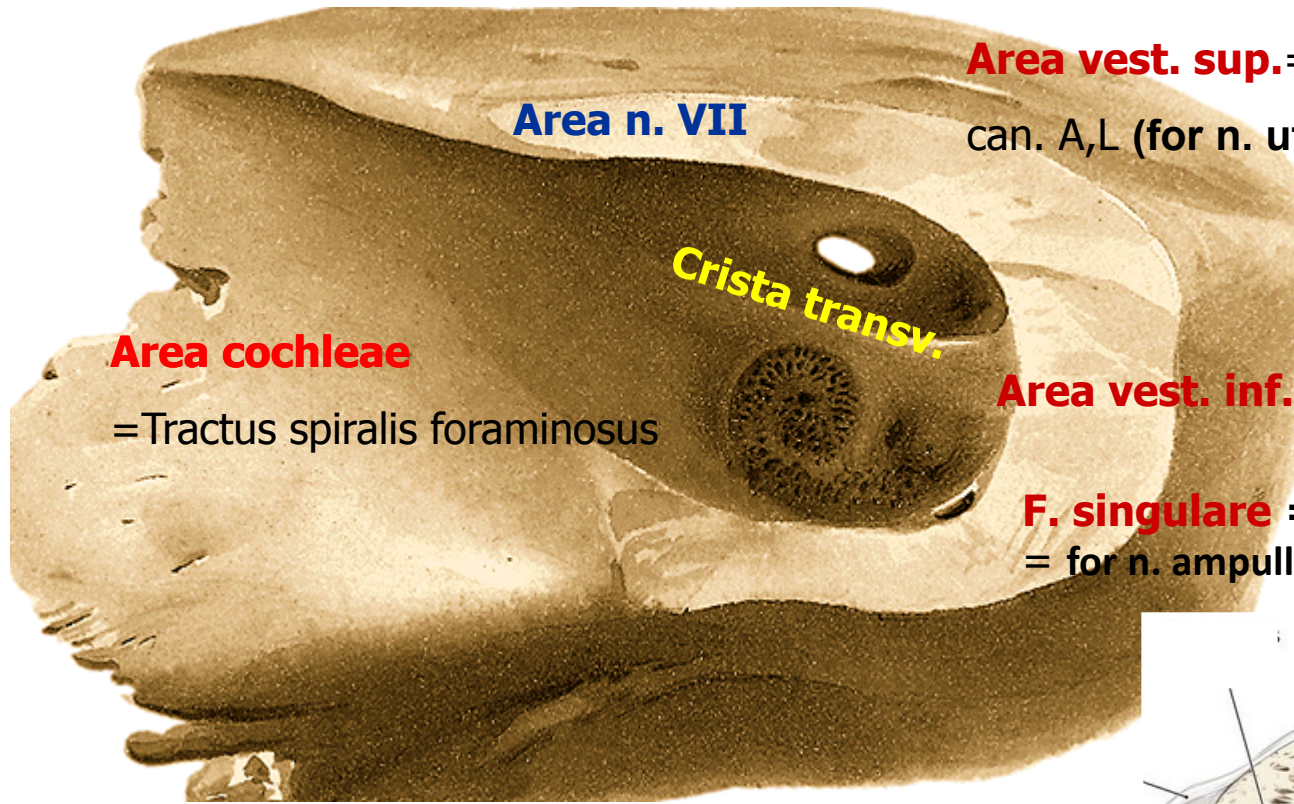
Canalis spiralis cochlae

by scala vestibuli is joined with
vestibulum,
scala tympani passes under
vestibulum,
by fenestra cochlae opens to CT,
ductus perilymphaticus





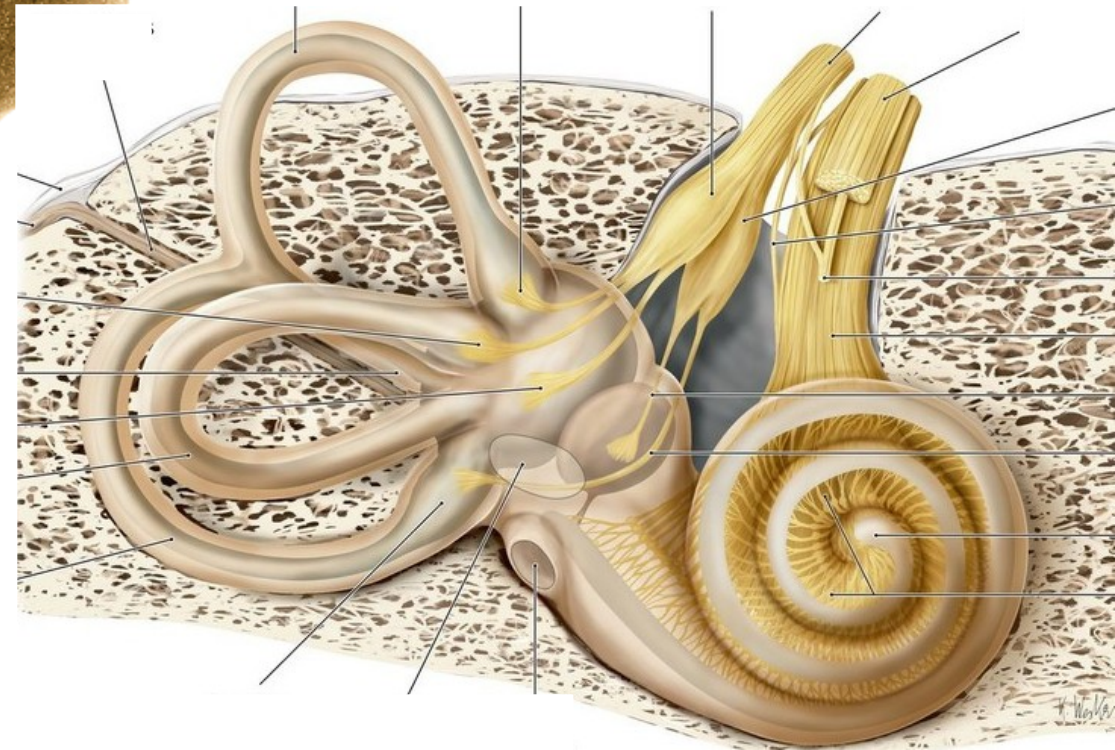
Meatus acusticus internus

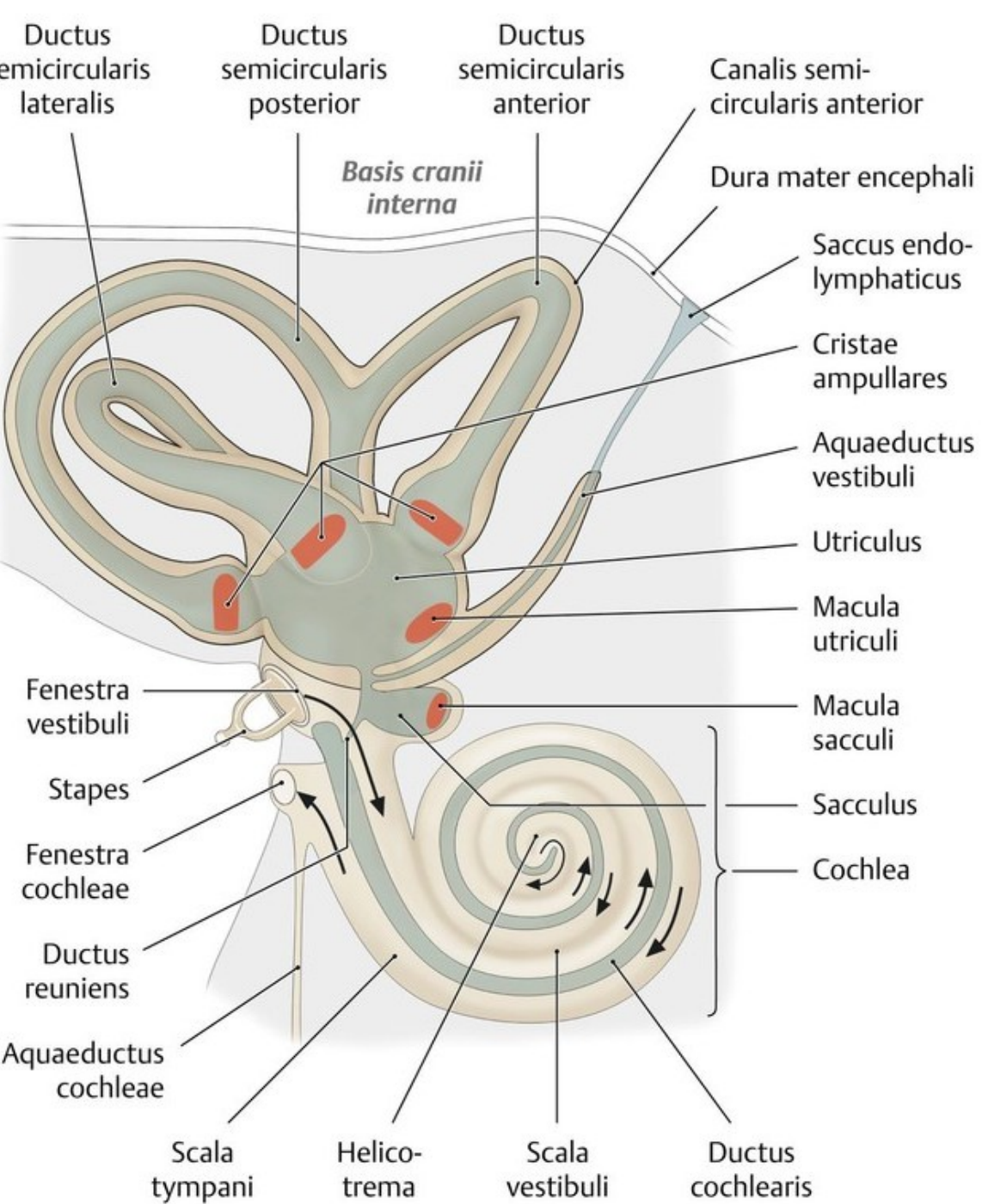


Area vest. sup. = macula cribrosa sup.
can. A,L (for n. utriculoampullaris)

Area vest. inf. = macula cribrosa med. (n. saccularis)

F. singulare = macula cribrosa inf.
= for n. ampullaris posterior)





Labyrinthus membranaceus

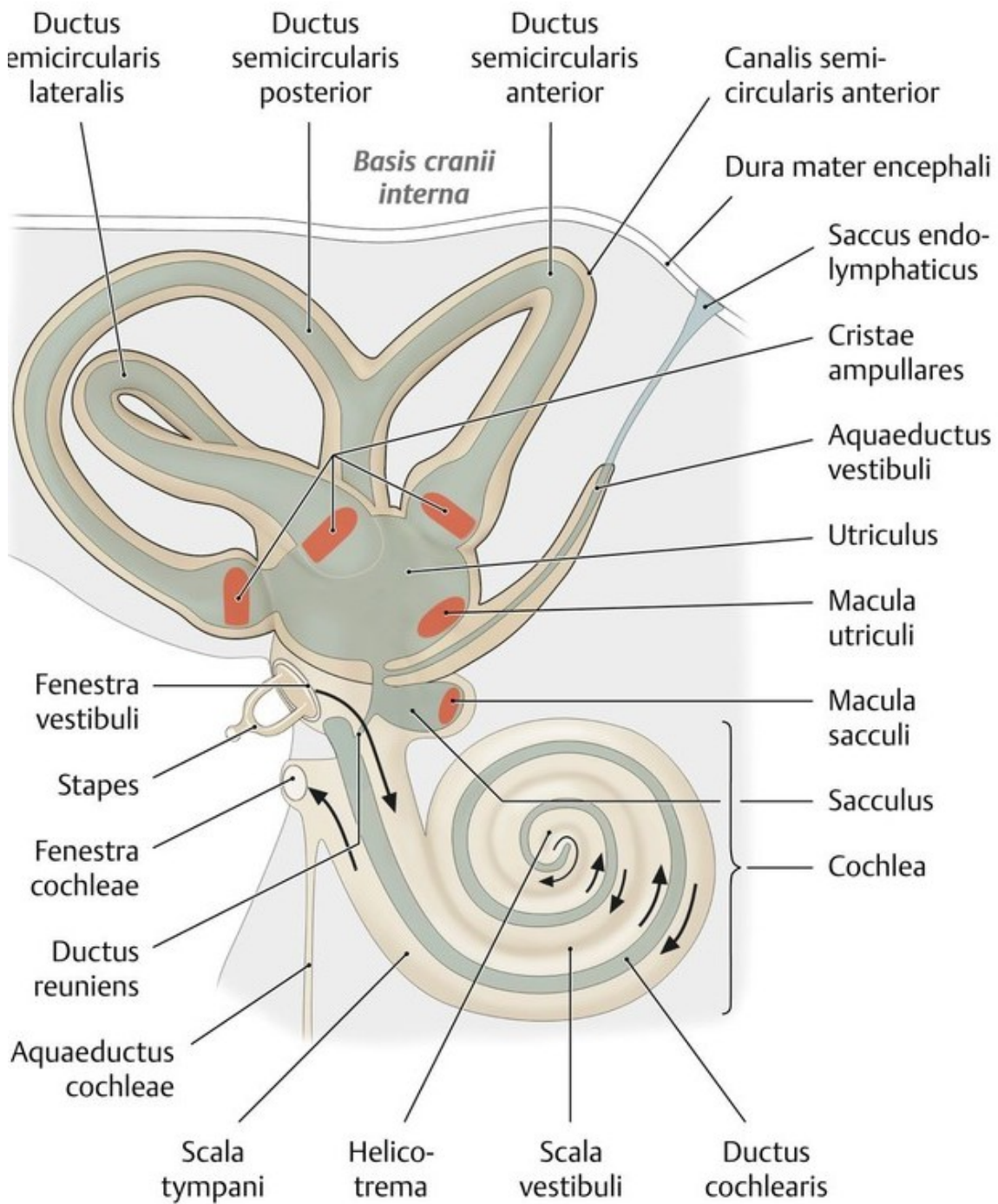
Labyrinthus vestibularis

Utriculus - on medial wall of vestibulum in recessus utriculi (ellipticus), utricular macula is located horizontally, by ductus utriculosaccularis is joined with ductus endolymphaticus)

Sacculus - on medial wall of vestibulum in recessus sacculi (sphericus), macula sacculi is in the vertical position

endolympha

Epithelium – sensory hair - membrana statoconiorum with statoconia, ganglion vestibulare



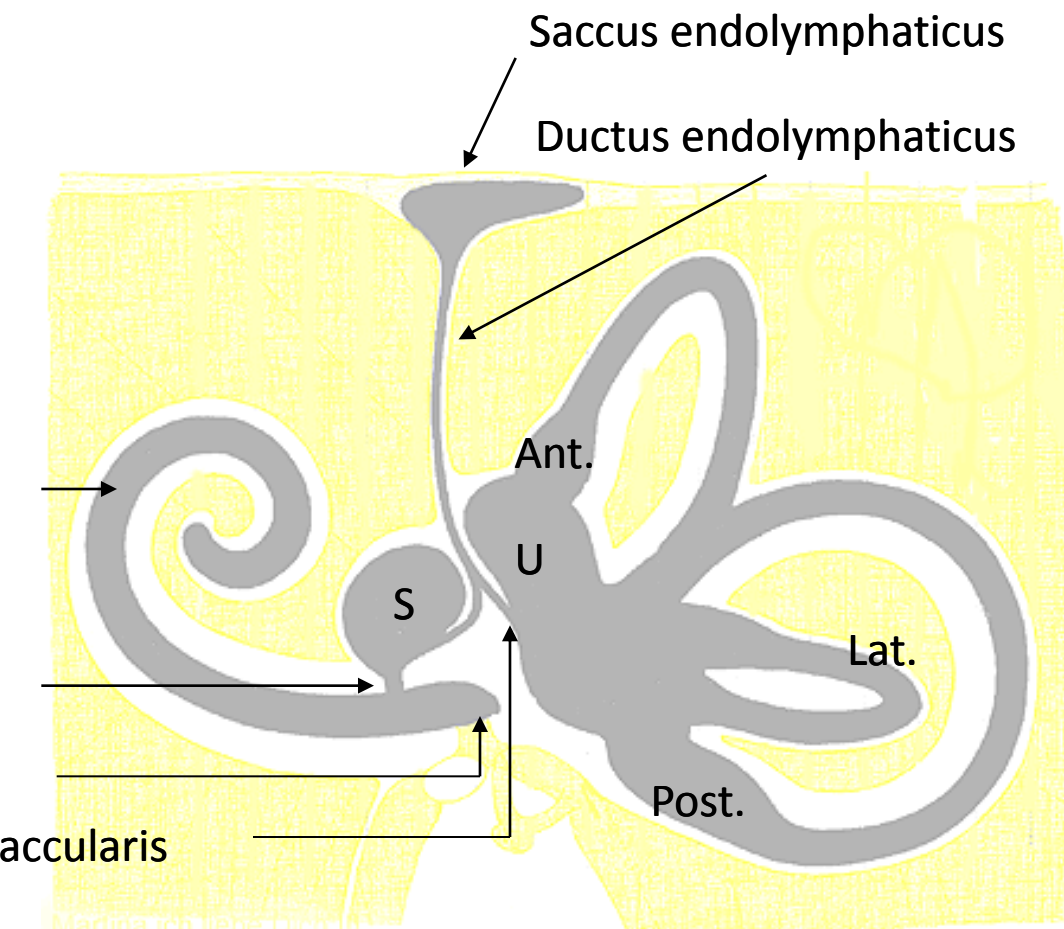
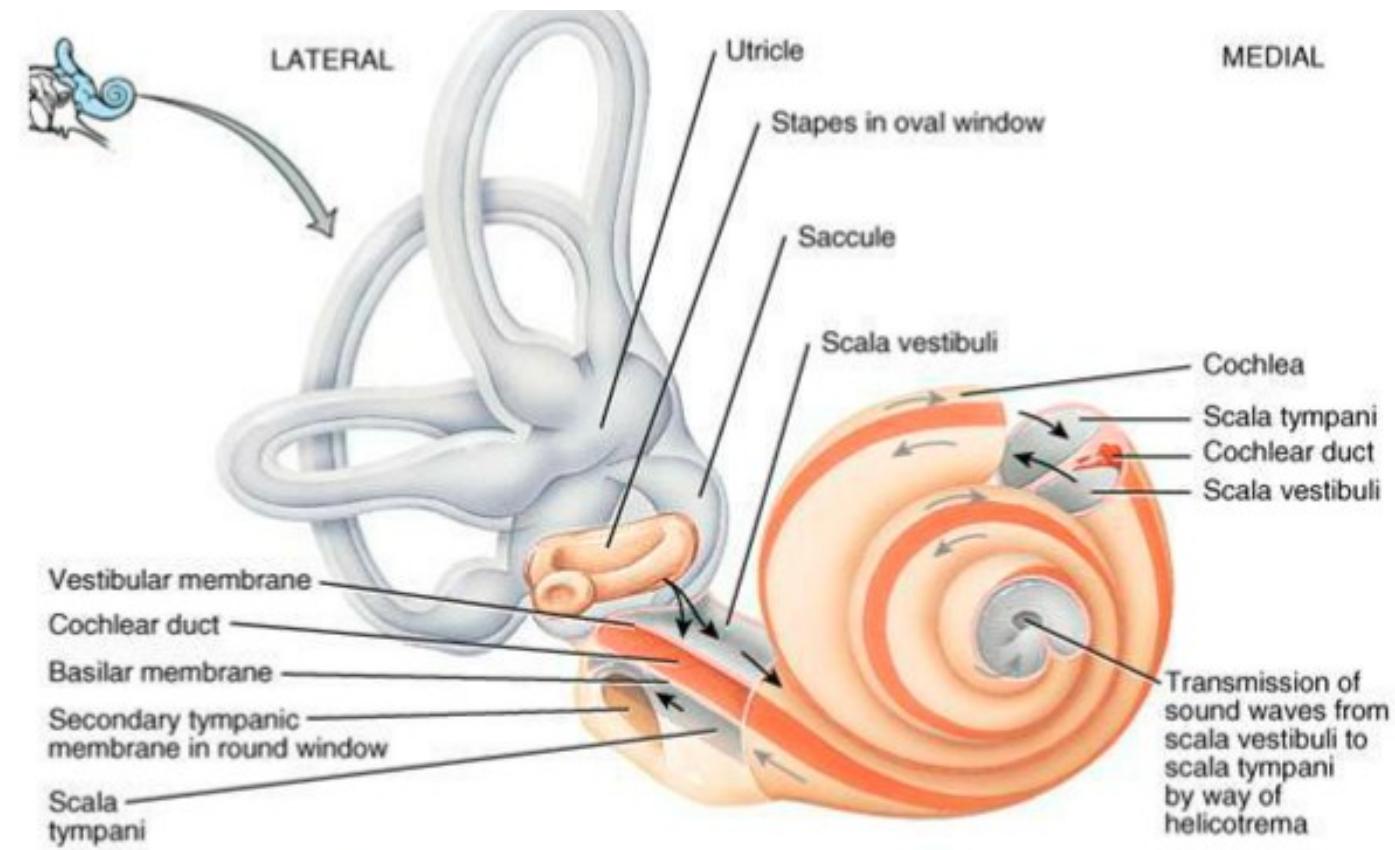
Ductus semicirculares –

Similar with osseous canals, open into the utricle
 crista ampullaris, cupula ampullaris – movement of endolymph, register movements of the head

Ductus endolymphaticus is joined with ductus utriculosaccularis, and passes along aquaeductus vestibuli, and ends in the saccus endolymphaticus under the dura mater

Organ of balance

- utricle, saccule, semicircular ducts = vestibular apparatus
- register acceleration and changes of position
- orientation in space

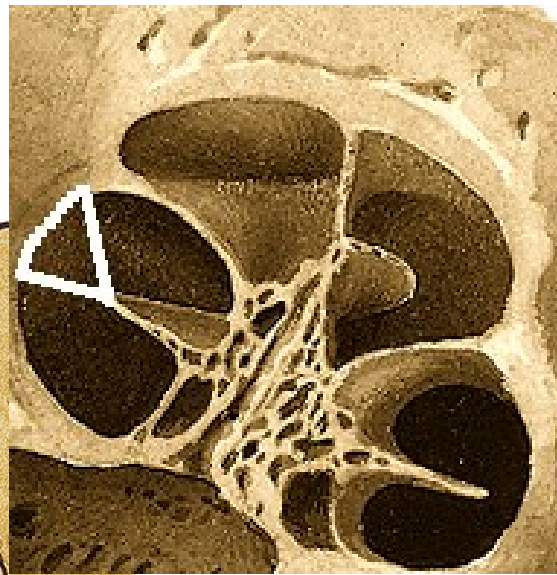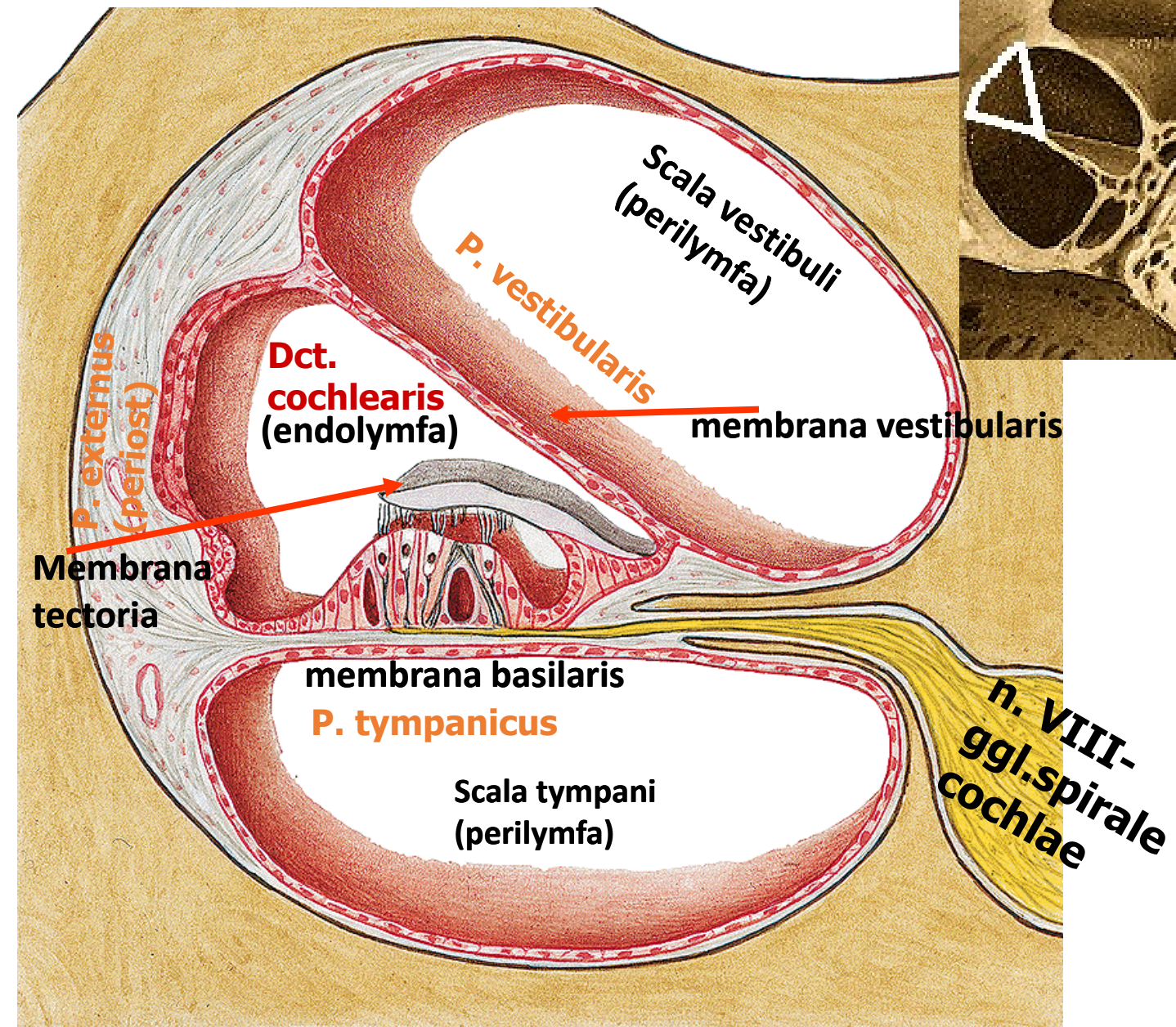


Labyrinthus cochlearis

Ductus cochlearis with caecum vestibulare and caecum cupulare, ductus reuniens (joins ductus cochlearis with sacculus). Is filled with endolymph.

Ductus cochlearis divides bone cochlea into scala tympani and scala vestibuli (with perilymph)

- Ductus cochlearis
- Ductus reuniens
- Caecum vestibulare
- Ductus utriculosaccularis



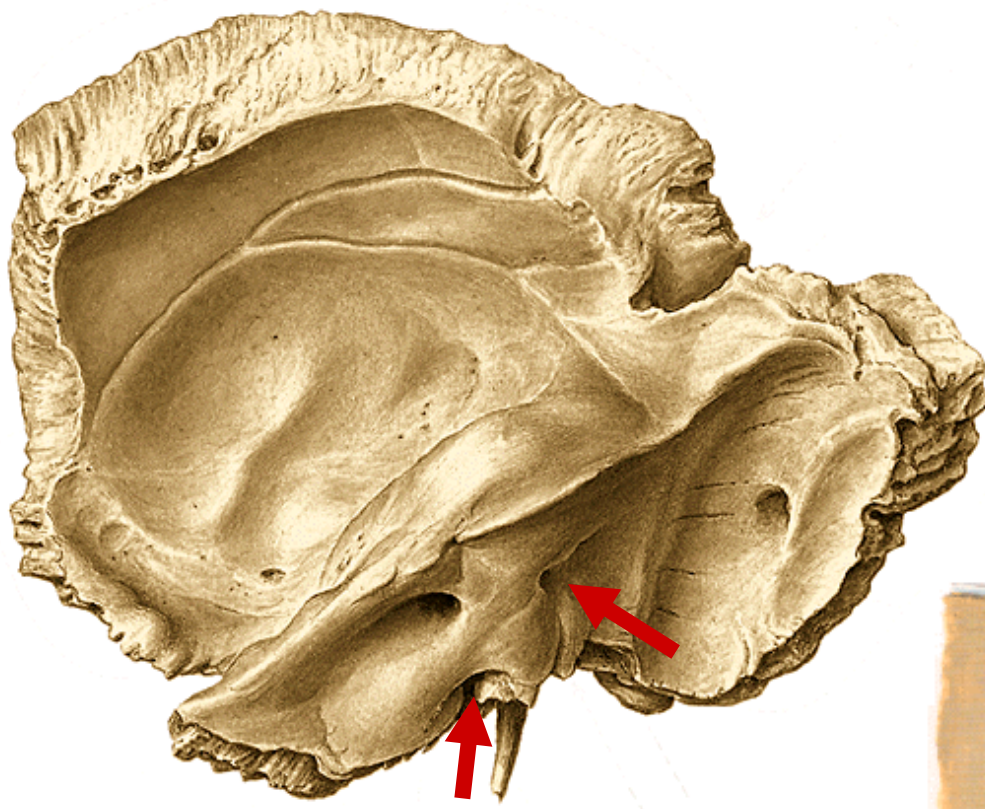
Ductus cochlearis

Lateral wall – joins with periosteum of canalis spiralis cochleae

Tympanic wall – forms bottom of DC and separates it from scala tympani, membrana basilaris

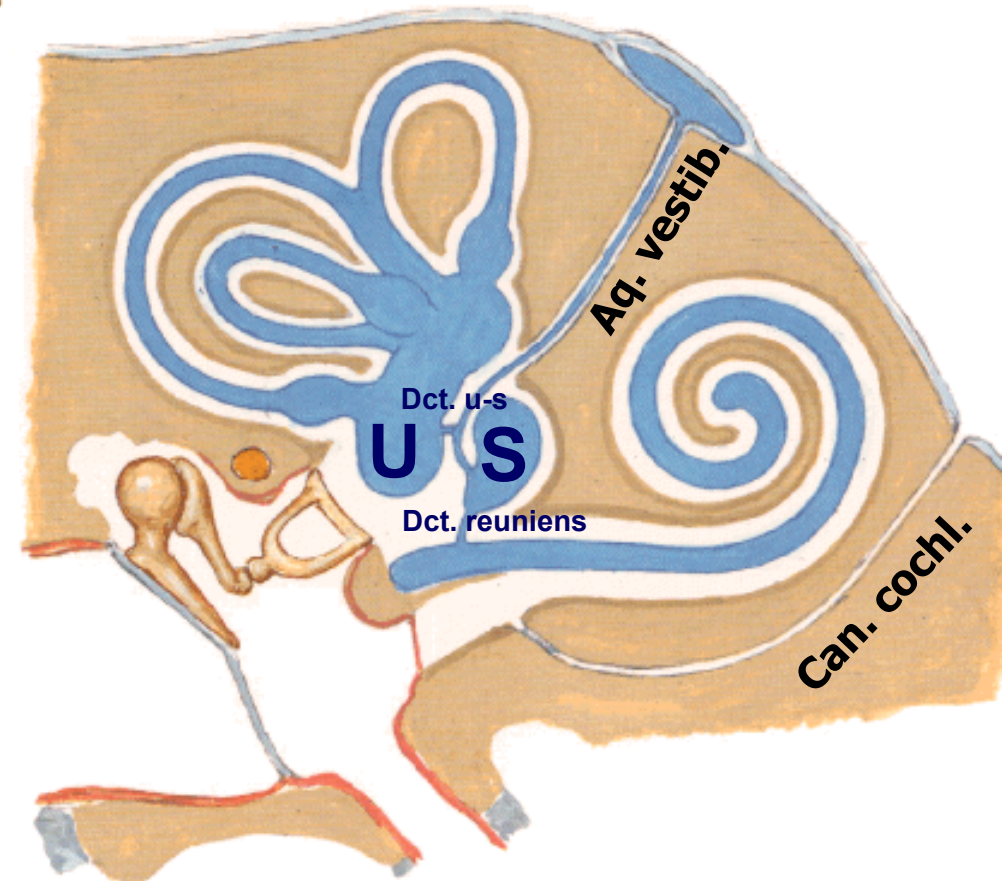
Organum spirale Corti located on the membrana basilaris, above this is membrana tectoria ganglion spirale cochleae (bipolar cells)

Vestibular wall – is formed by thin membrana vestibularis.

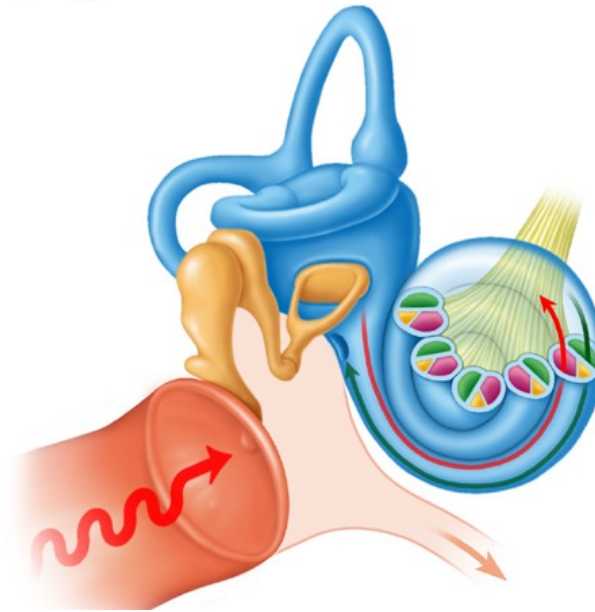
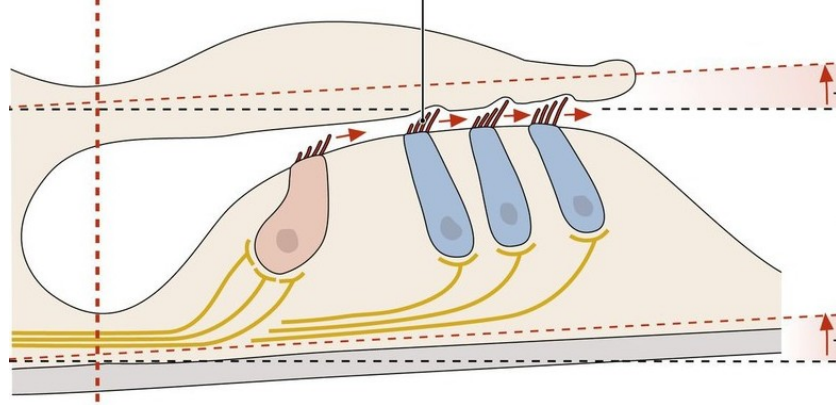
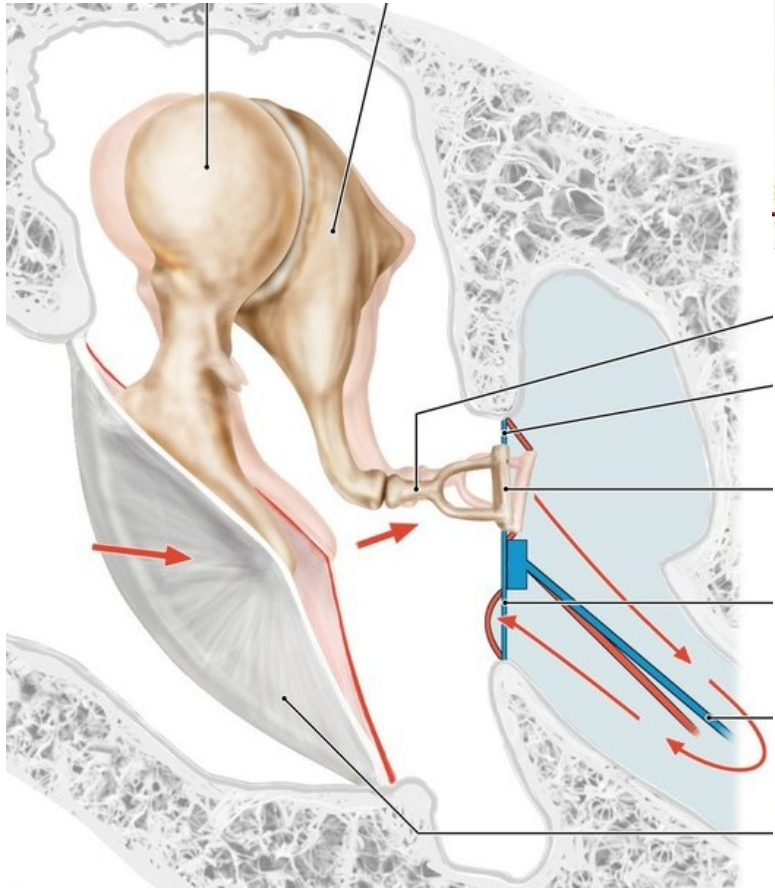


Endolymph – from plasma, ductus endolymphaticus to saccus and apertura externa aquaeductus vestibuli to subarachnoideal space.

Perilymph – in spatium perilymphaticum (between bone and membranaceous labytinth) – through canaliculus cochleae to subarachnoideal space.

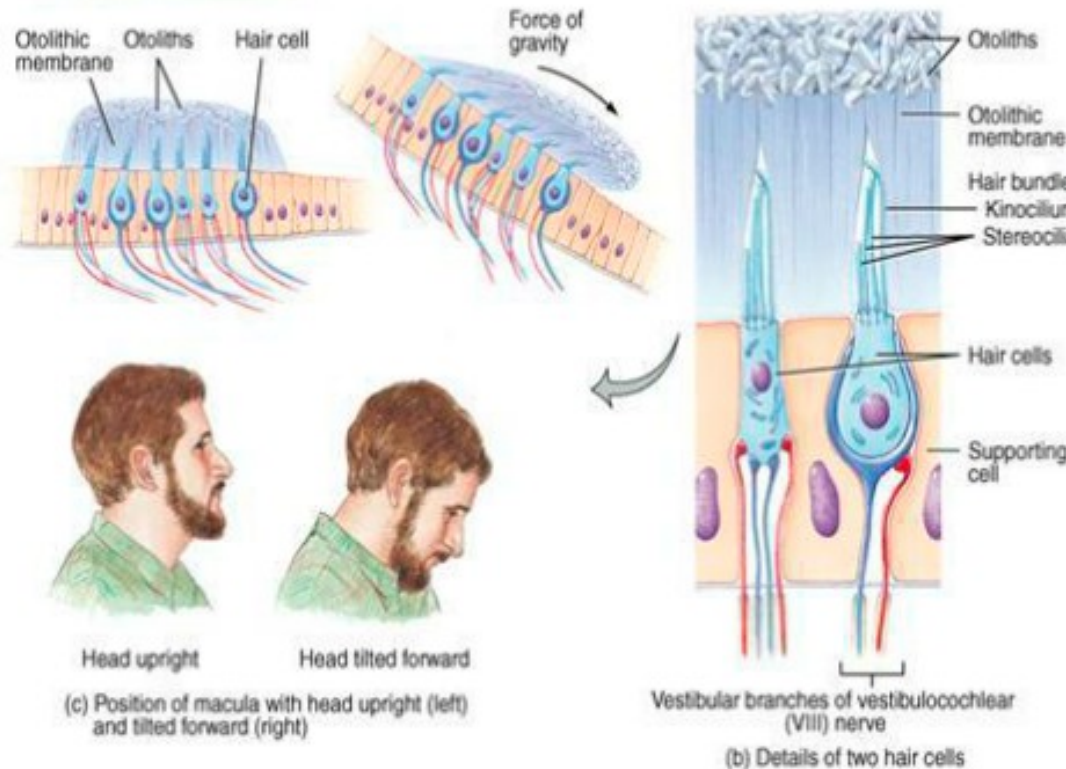
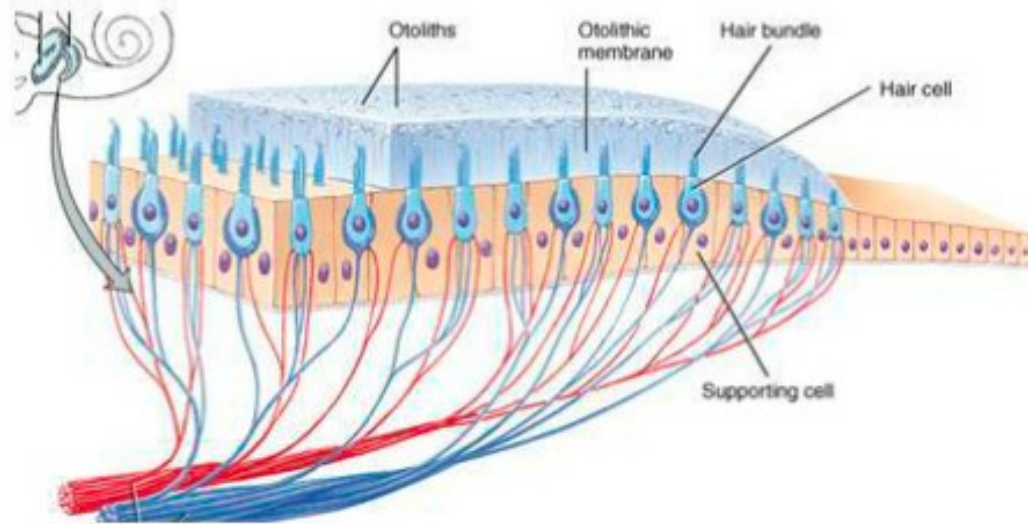


Hearing



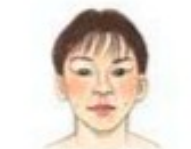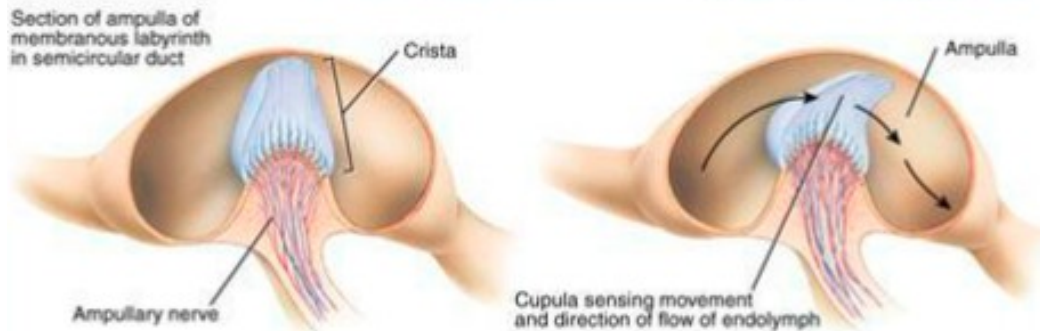
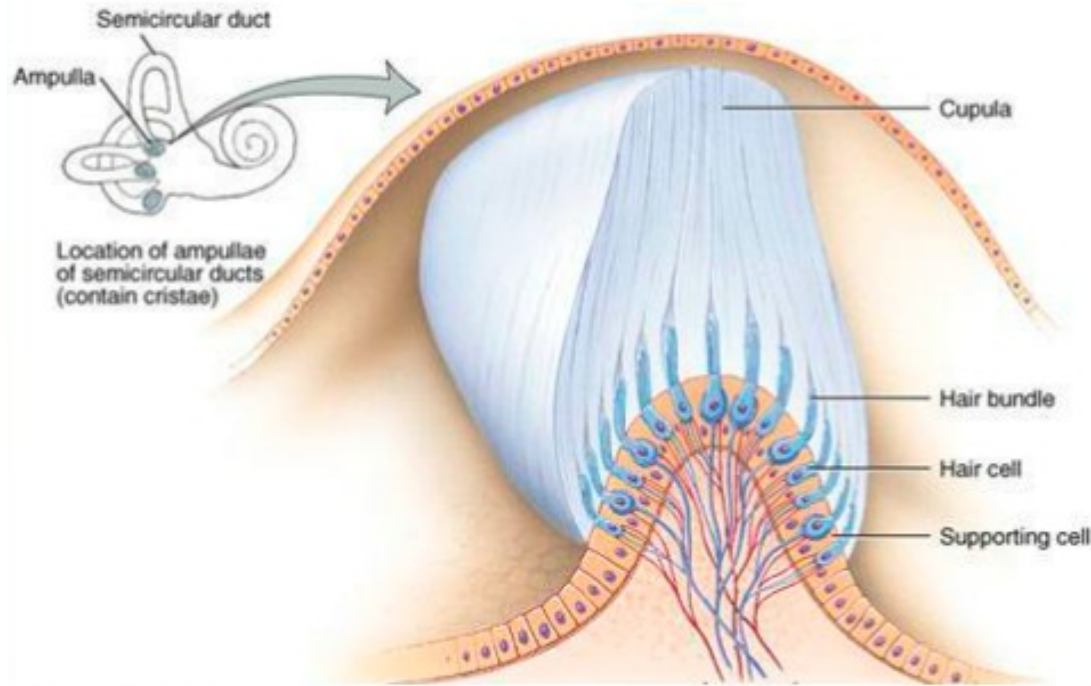
Sound waves are caught by auricula, to the meatus acusticus externus, to membrana tympani, by movement of ossicula auditus to fenestra vestibuli of inner ear , to perilymph of scala vestibuli/tympani – oscillation of endolymph – basilar membrane and Corti's organ – 1. neuron of auditory tract.

Static equilibrium: Sacculle & Utricle

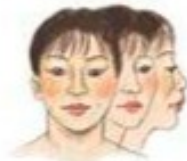

- Thickened regions called **macula** within the sacculle & utricle
- Cell types in the macula region
 - hair cells
 - supporting cells that secrete gelatinous layer
- Gelatinous **otolithic membrane** contains calcium carbonate crystals called otoliths that move when you tip your head
- head movement and otolith movement bends the hair cells and results in receptor potentials

Dynamic equilibrium: Semicircular Ducts



Head in still position



Head rotating

- Small elevation within each of three semicircular ducts
 - anterior, posterior & horizontal ducts detect different movements
- Hair cells covered with cupula of gelatinous material
- When you move, fluid in canal bends cupula stimulating hair cells that release neurotransmitter
- Fibers from vestibulocochlear nerve (VIII) end in **vestibular nuclei** and the cerebellum
- Fibers from these areas connect to:
 - cranial nerves that control eye and head and neck movements (III, IV, VI & XI)
 - vestibulospinal tract that adjusts postural skeletal muscle contractions in response to head movements
 - motor cortex can adjust its signals to maintain balance

The part of tunica vasculosa bulbi is:

- :r1 sclera
 - :r2 pupilla
 - :r3 lens
 - :r4 no statement is correct
- :r4 ok

Choose correct statement about humor aquosus :

- :r1 is part of lens
 - :r2 is part of corpus vitreum
 - :r3 fills the cameras bulbi
 - :r4 all statements are correct
- :r3 ok

--

Choose correct statement about conjunctiva :

- :r1 covers both sides of palpebrae
 - :r2 it is accessory structure of the eye
 - :r3 fills camerae bulbi
 - :r4 no statement is correct
- :r2 ok

--

Into the fenestra vestibuli is inserted:

- :r1 cochlea
 - :r2 nervus vestibularis
 - :r3 maleus
 - :r4 no statement is correct
- :r4 ok

What is the part of labyrinthus membranaceus:

- :r1 vláskové buňky
 - :r2 rosolovitá hmota s krystalky
 - :r3 endolymfa
 - :r4 všechny odpovědi jsou správné
- :r4 ok