

Female genital organs

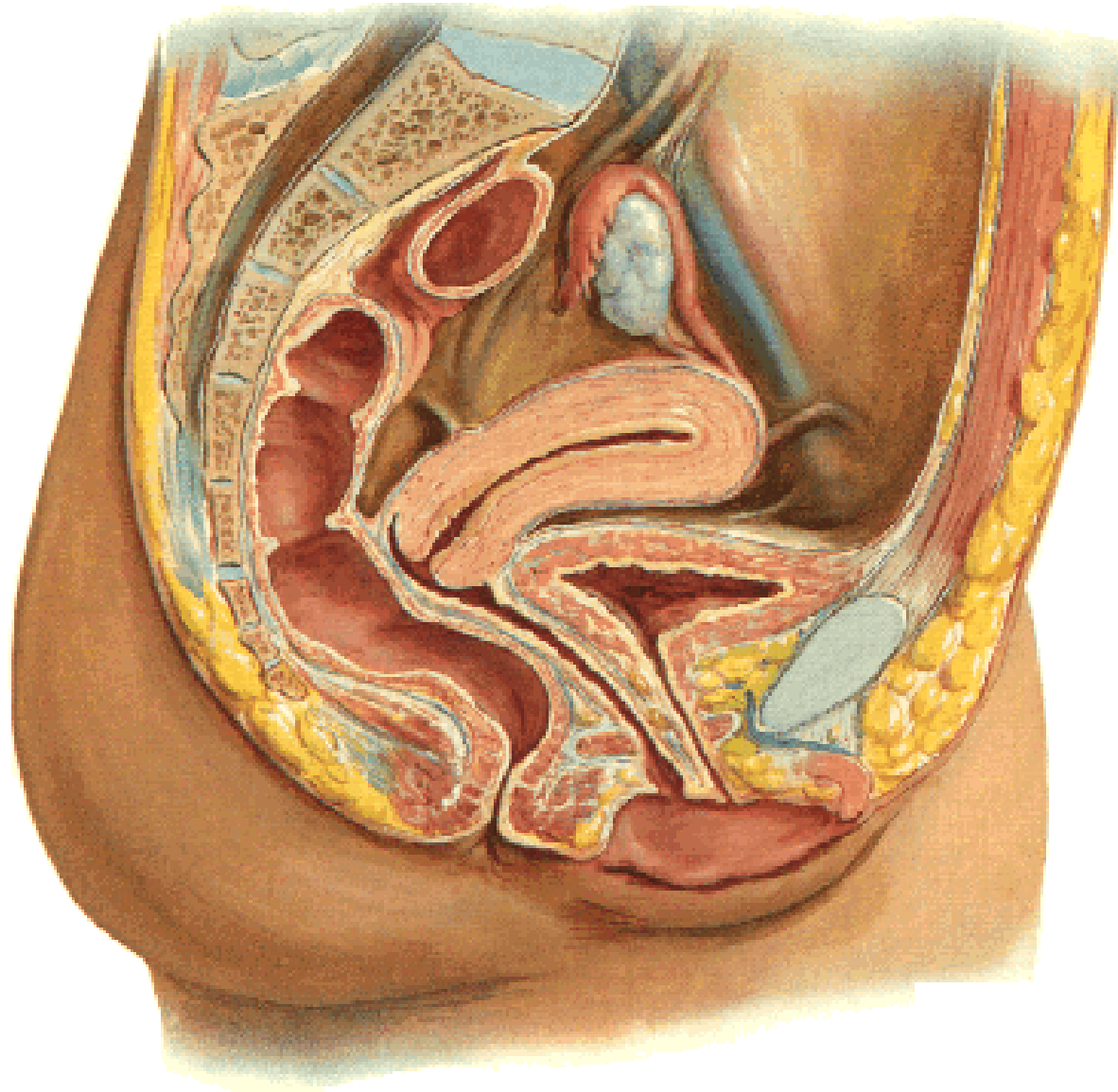
Internal female genital organs

Ovary (*ovarium*)

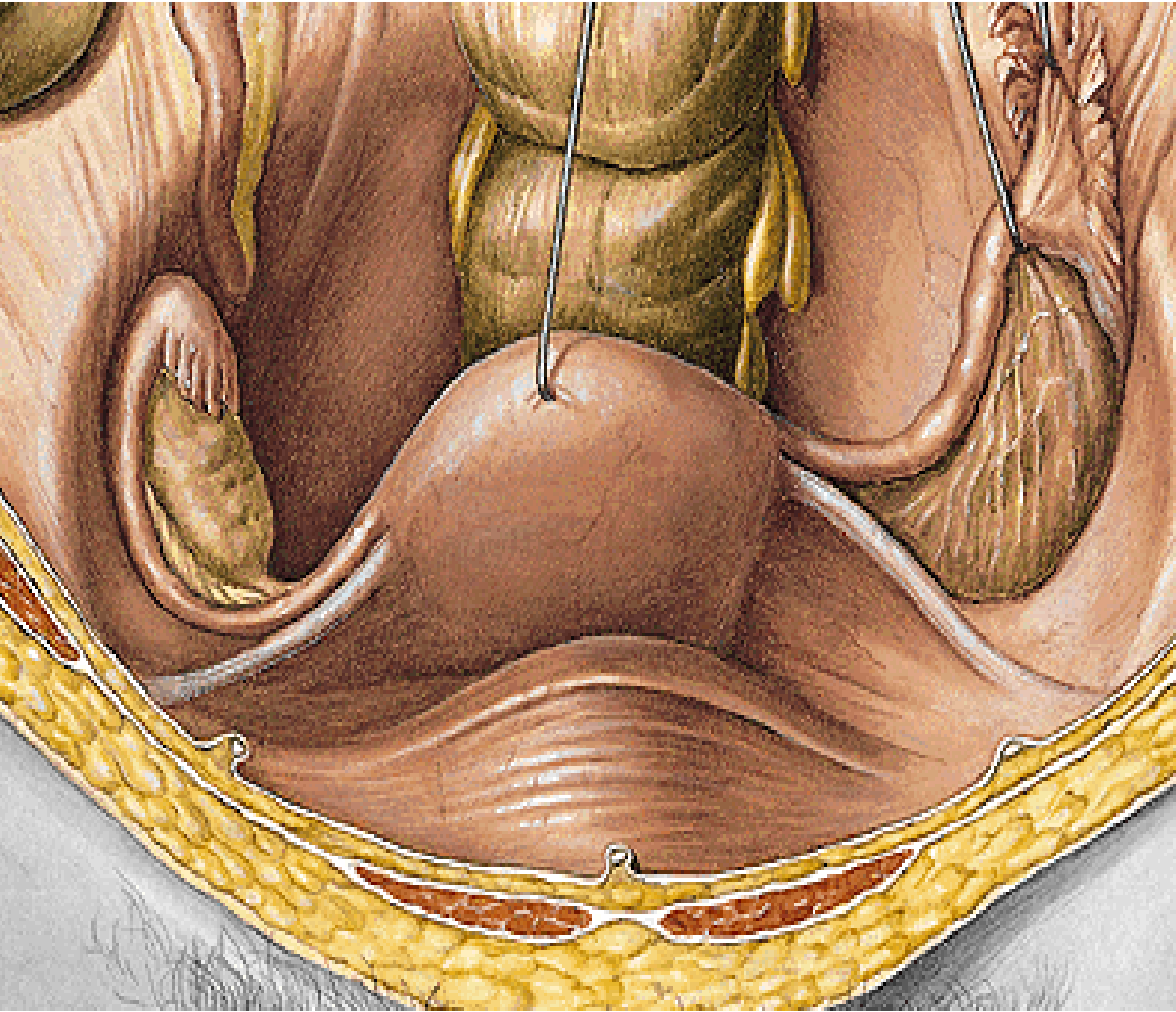
**Phalopian tube (*tuba
uterina*)**

Uterus

Vagina



OVARY



**Extremitas tubaria
(superior)**

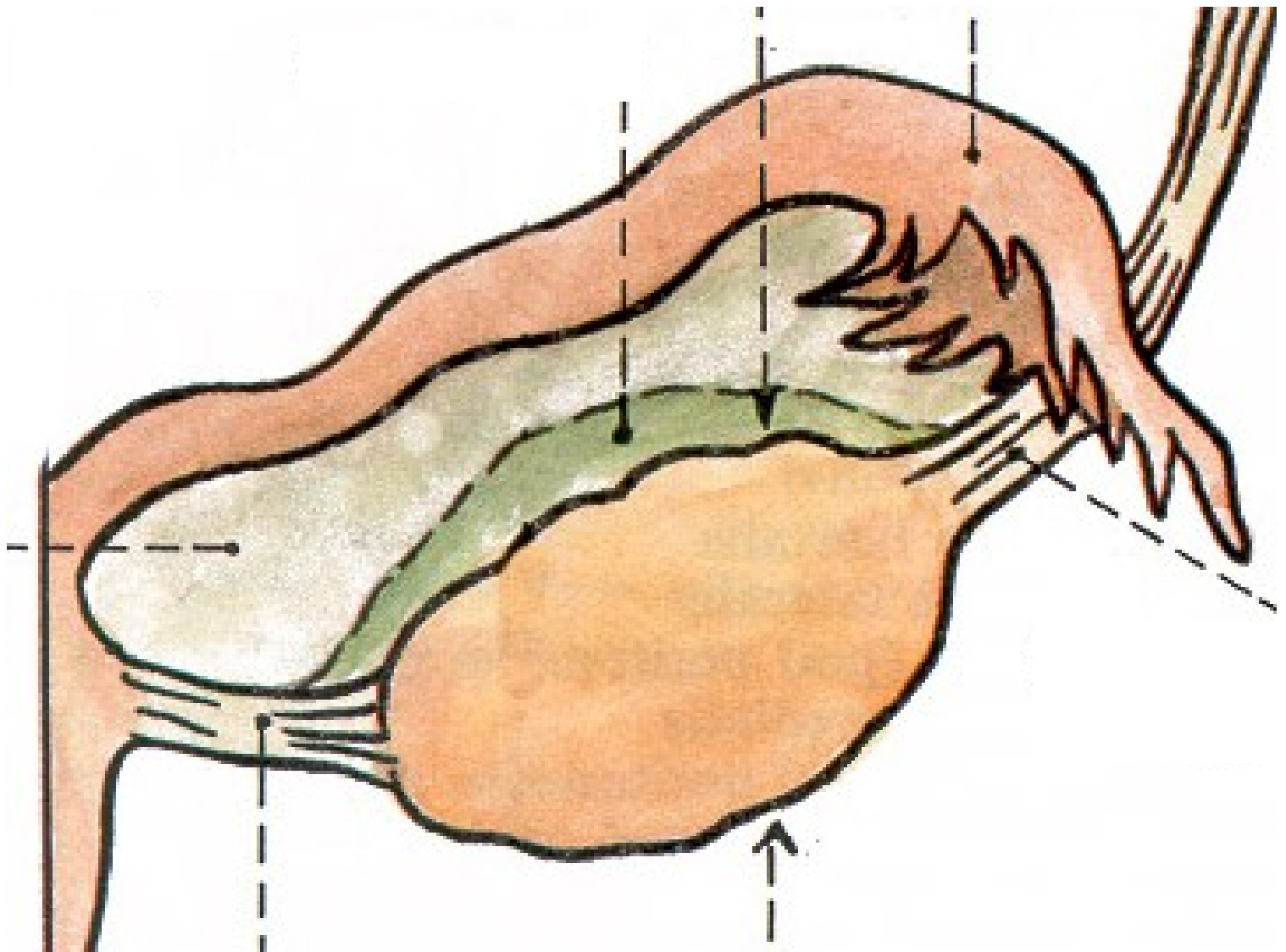
**Extremitas uterina
(inferior)**

Facies medialis

Facies lateralis

**Margo mesovaricus
(anterior)**

**Margo liber
(posterior)**



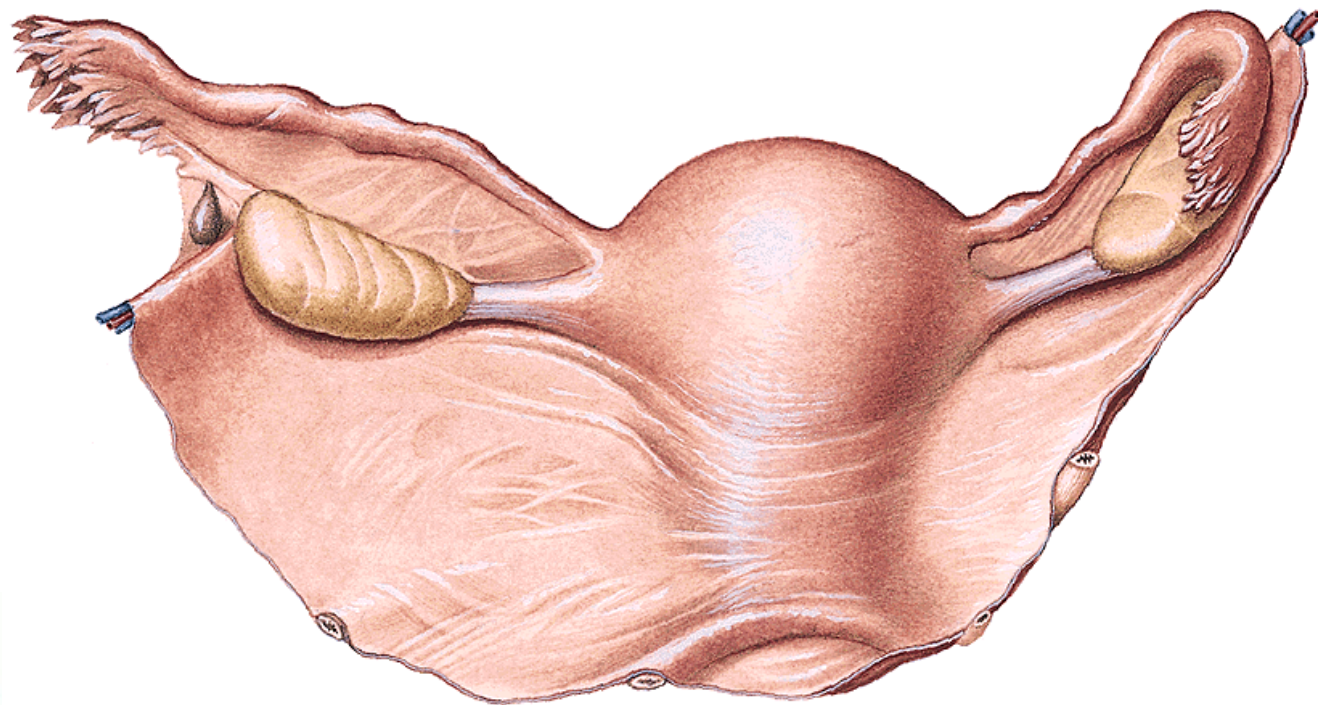
Lig. suspensorium ovarii (vasa ovarica)

Lig. ovarii proprium

Hilus ovarii

Mesovarium

Lig. latum uteri



Round ligament

Uterus

Ovarian ligament

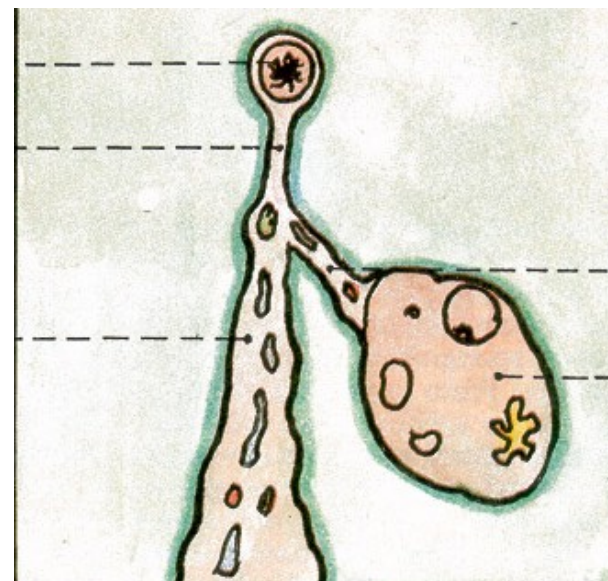
Mesovarium

Ovary

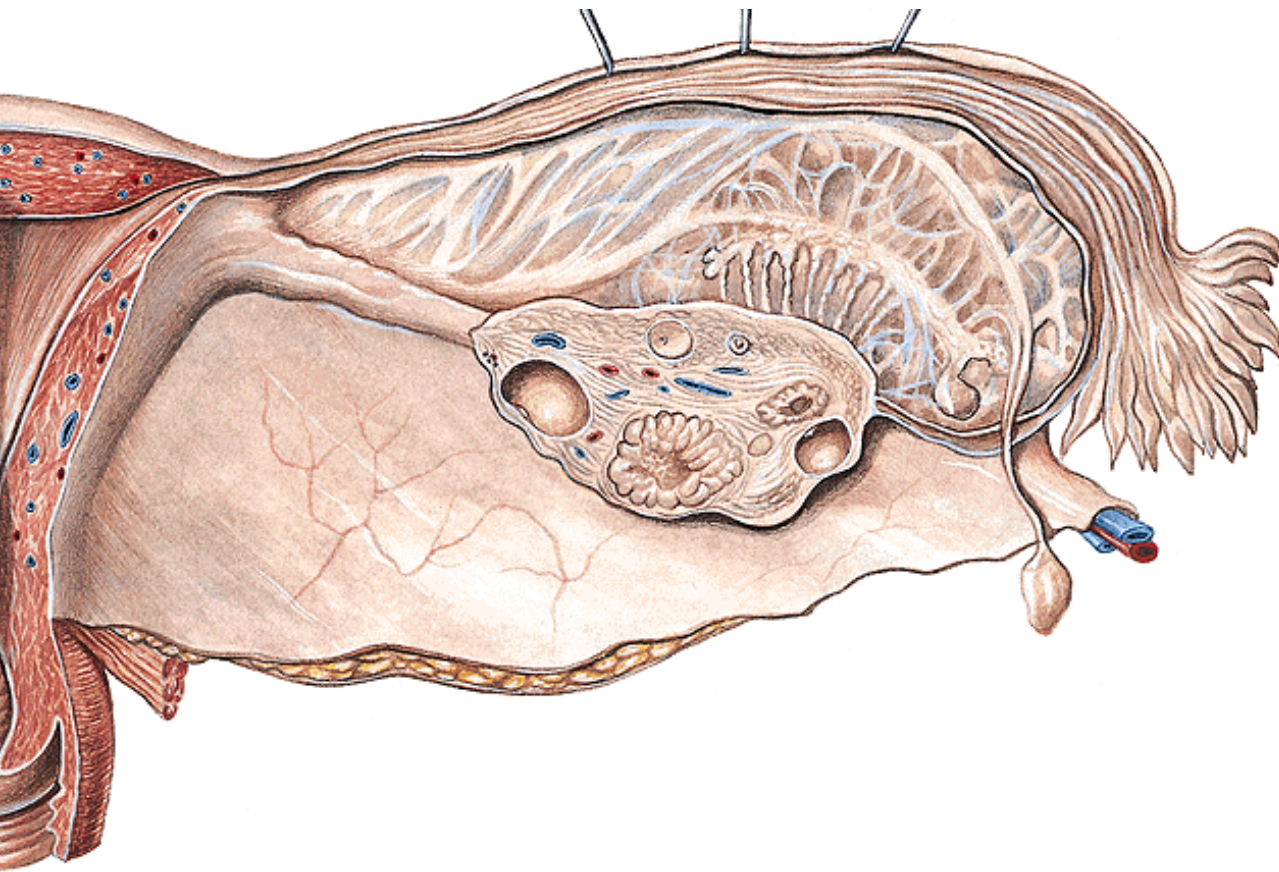
Uterine tube

Mesosalpinx

Mesometrium



Histology of ovarium



**Germinative
epithelium**

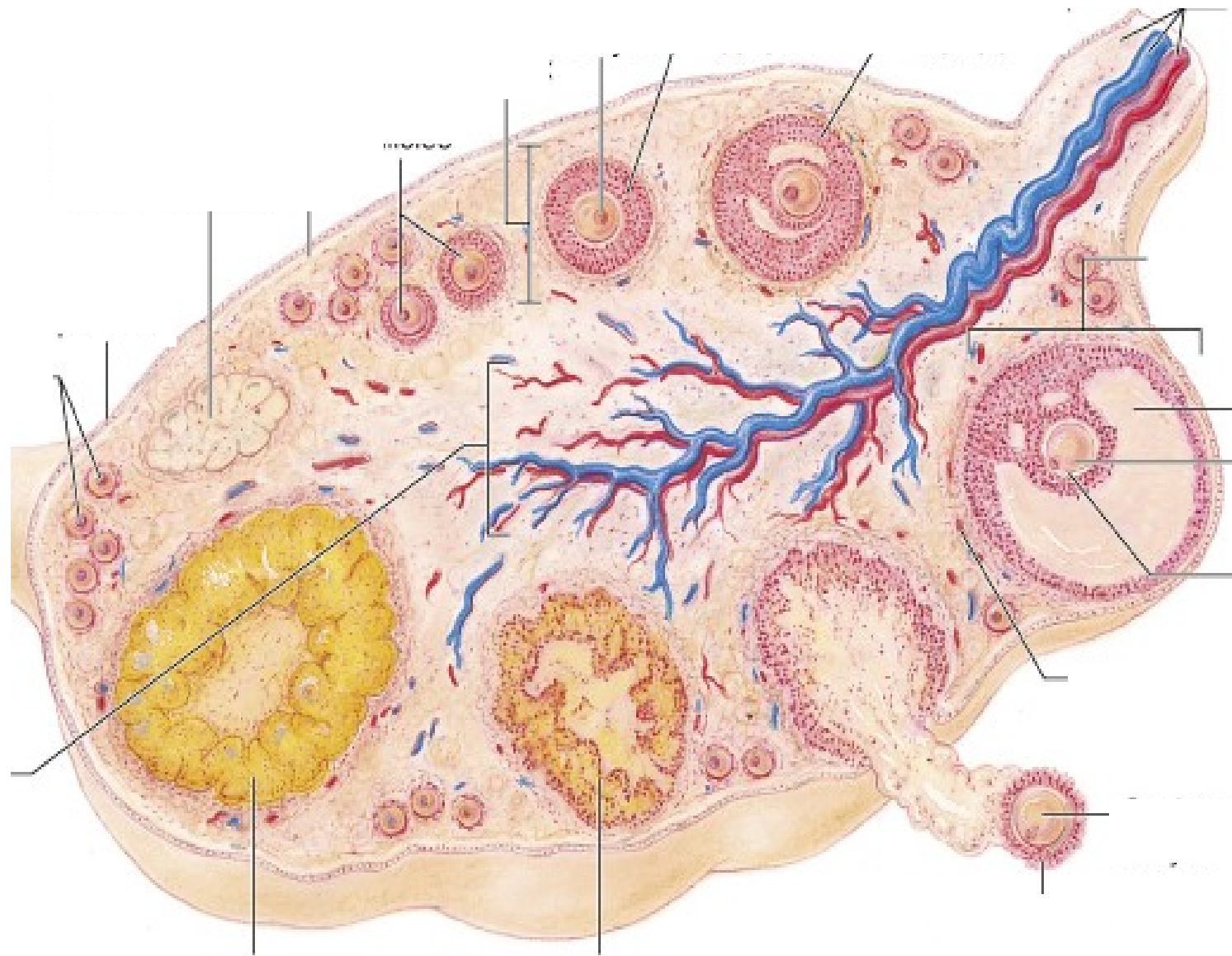
Tunica albuginea

Cortex ovarii

folliculi ovarici

corpora lutea

Medulla ovarii



Folliculi ovarici primarii (300 000- 400 000)

Folliculus ovaricus vesiculosus (Graaf's)

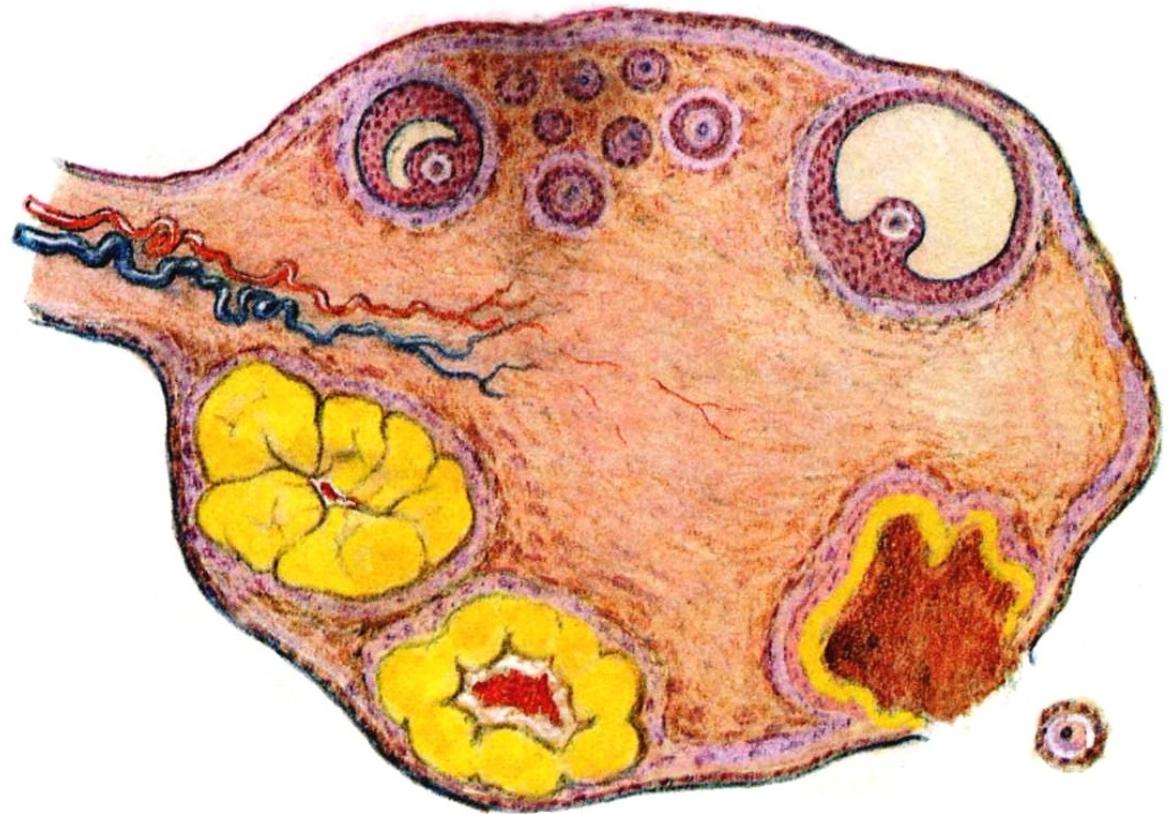
Ovulation

Corpus luteum

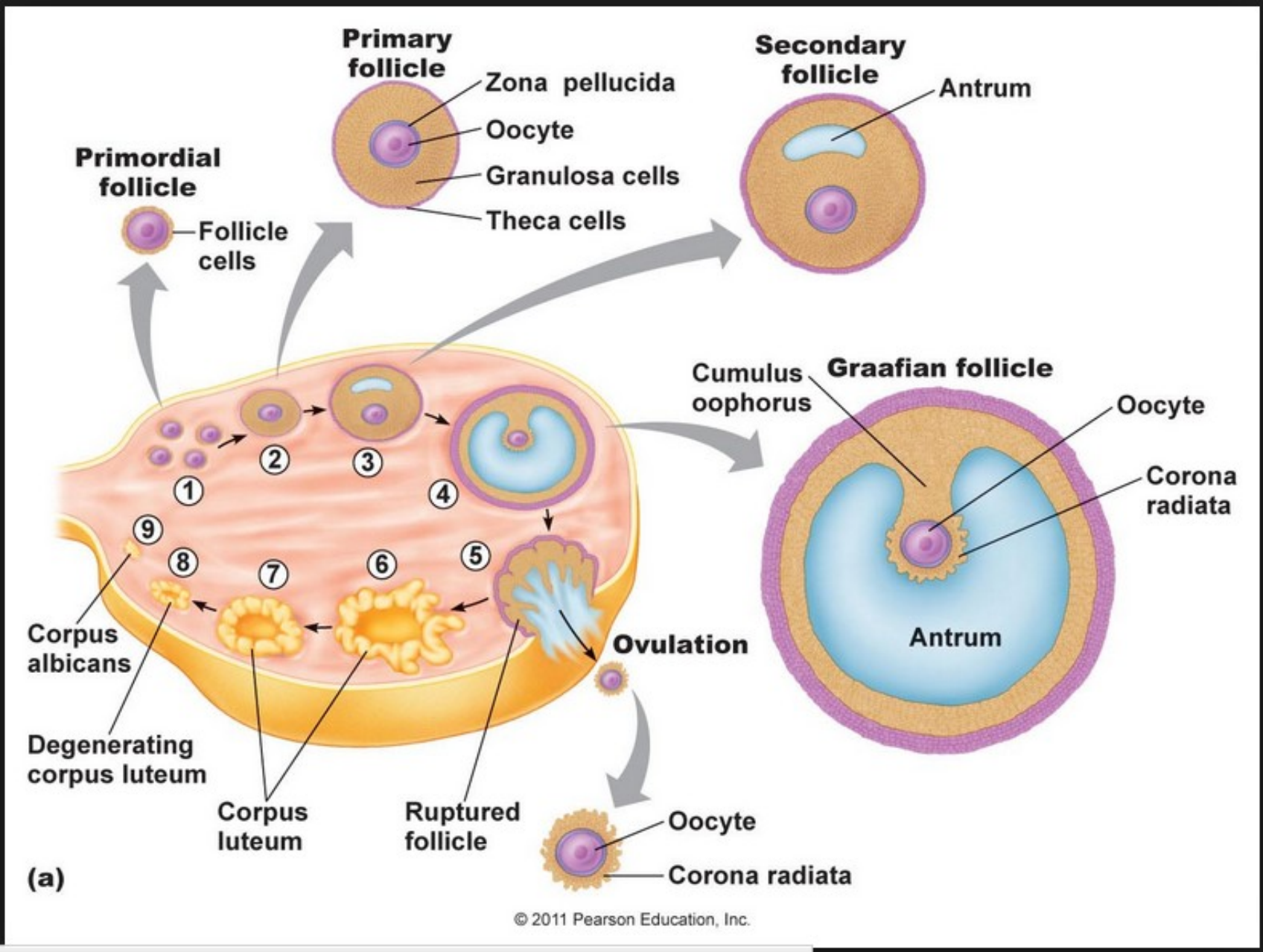
menstruationis

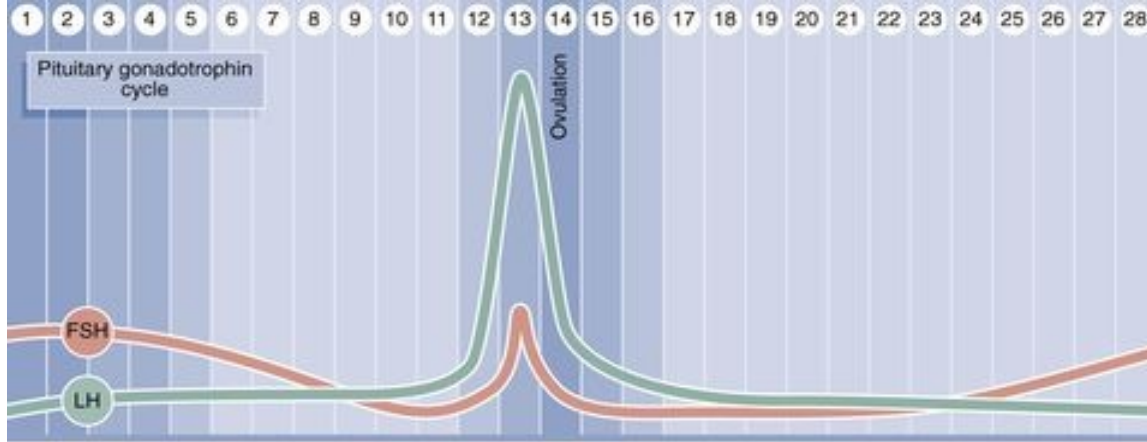
graviditatis

Corpus albicans

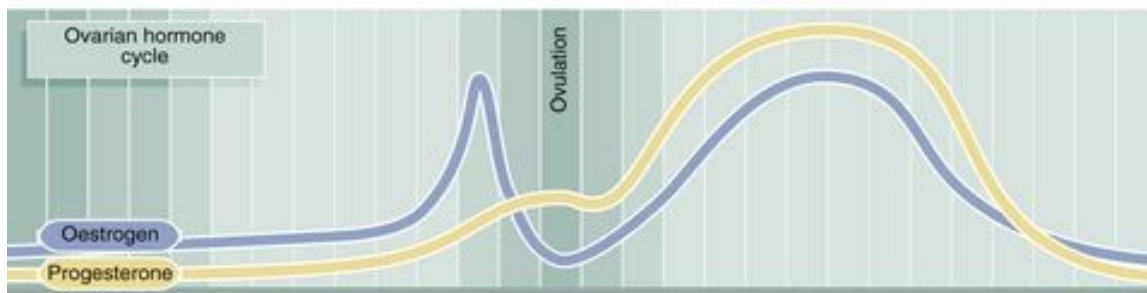


Ovarian cycle





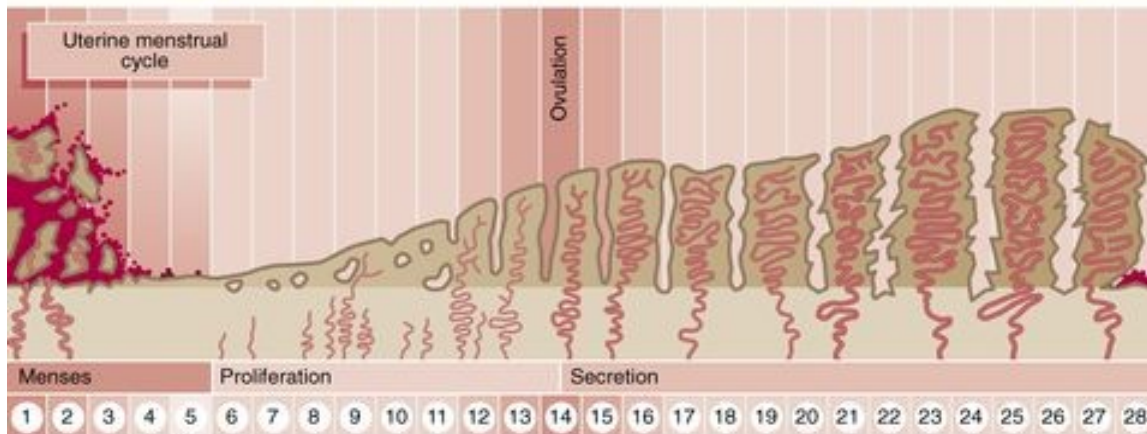
Hypophysis



Ovary - hormones

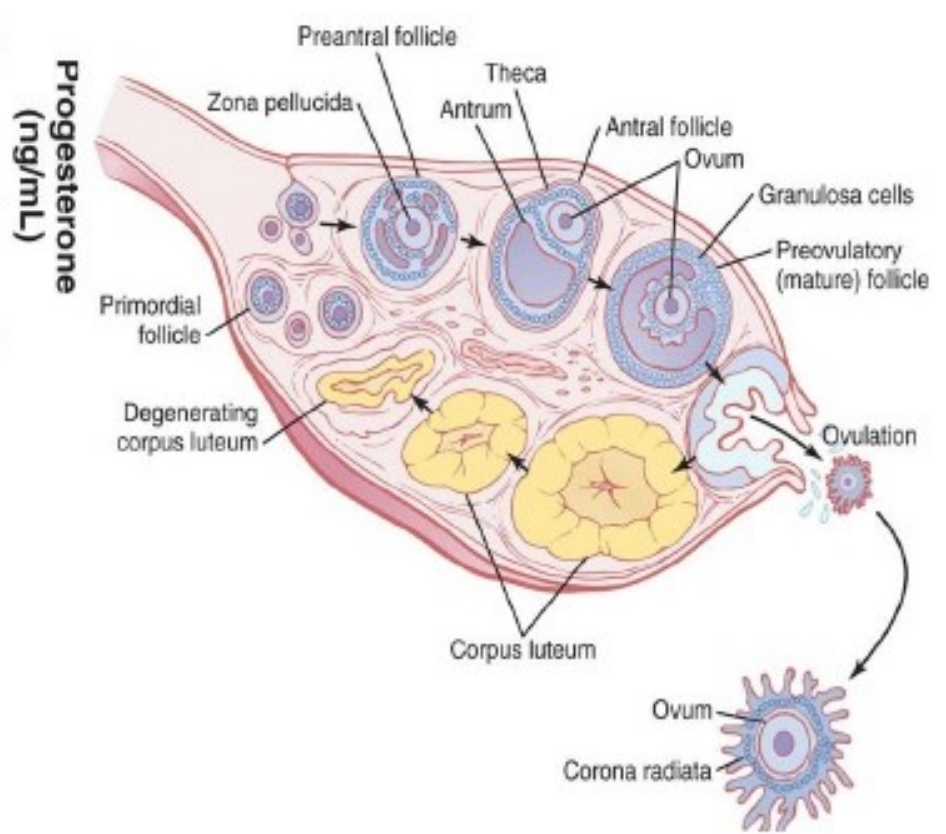
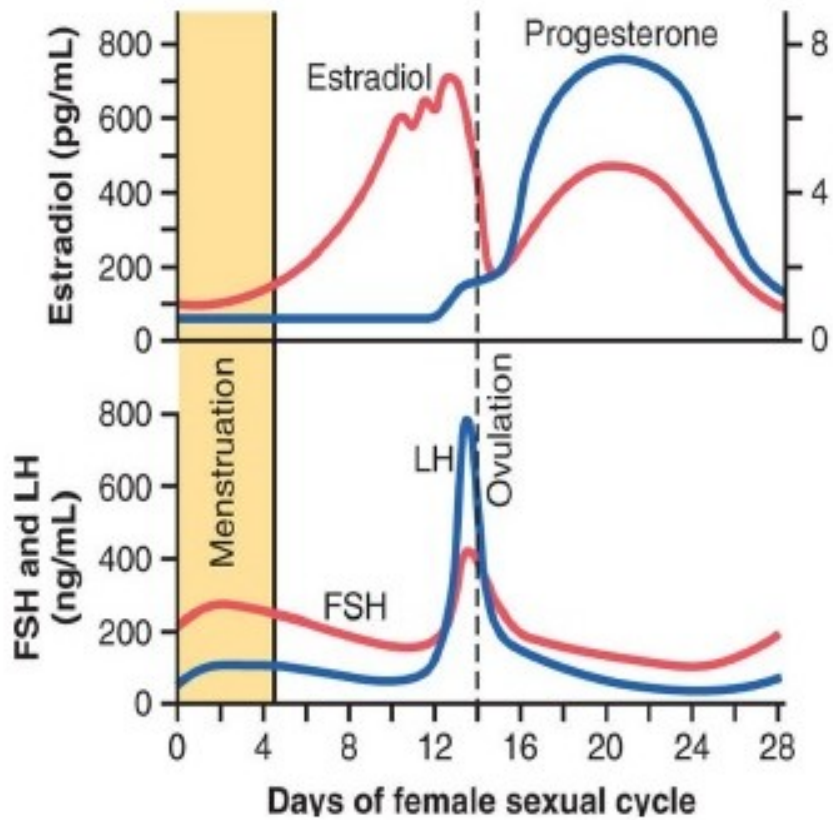


Ovulation cycle



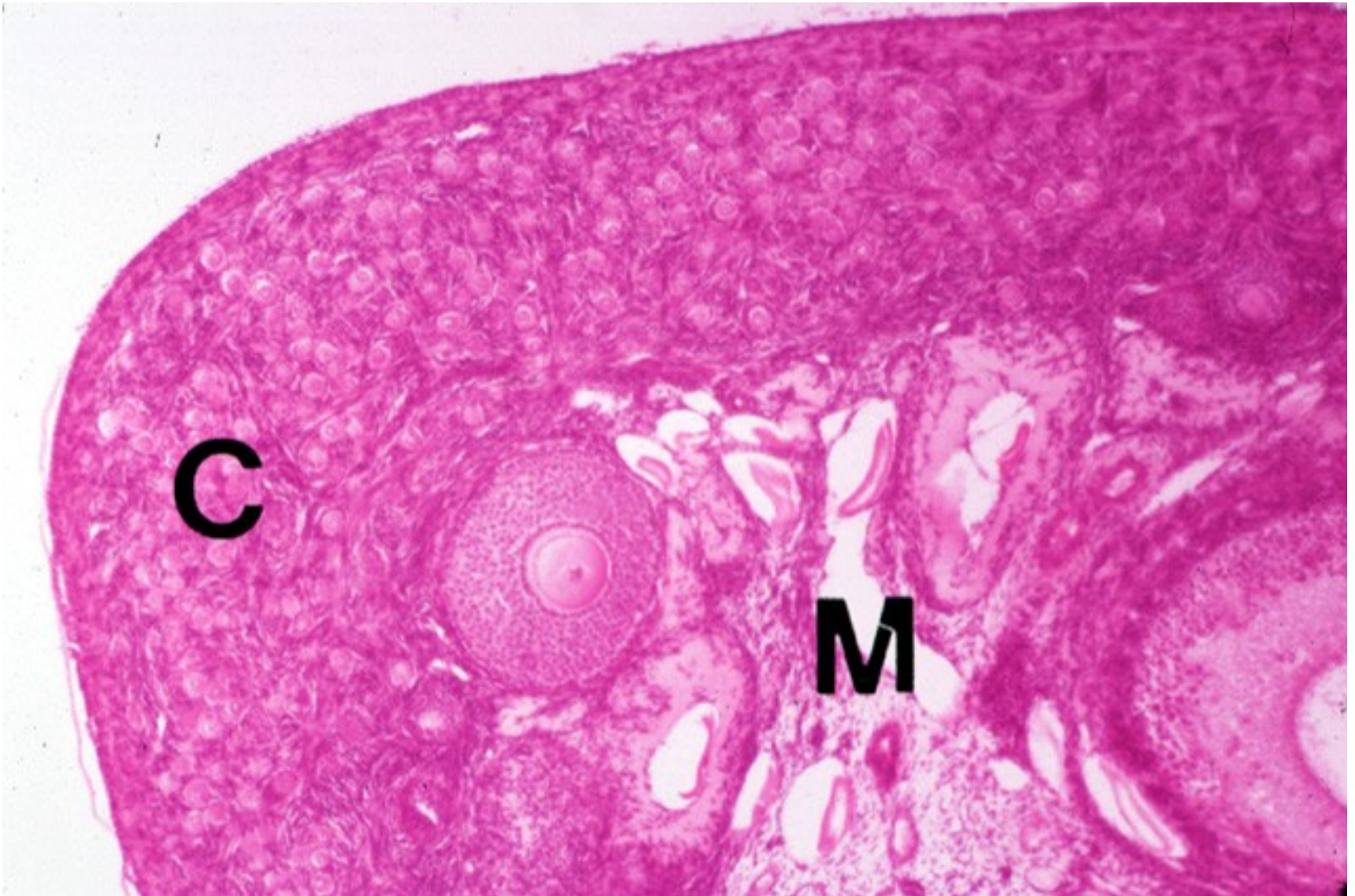
Uterus - menstr.cycle

Days of menstrual cycle



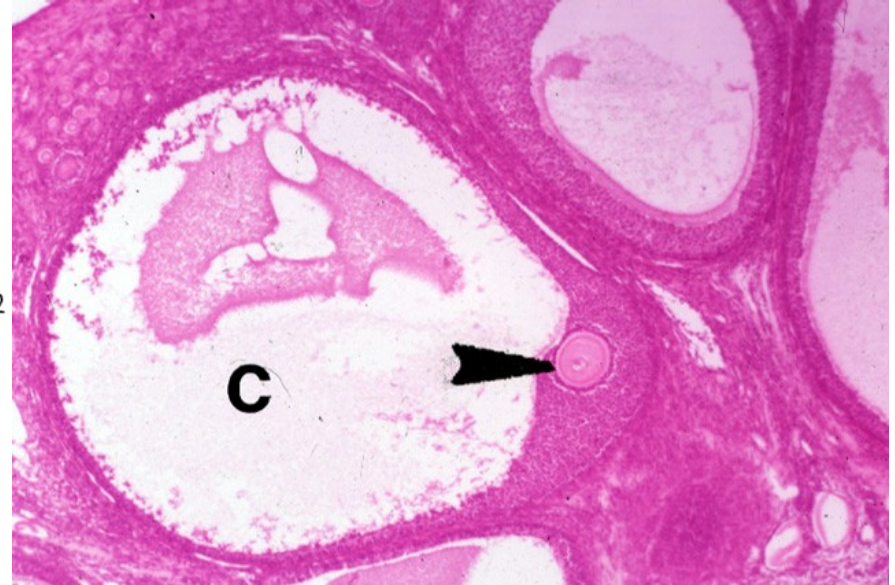
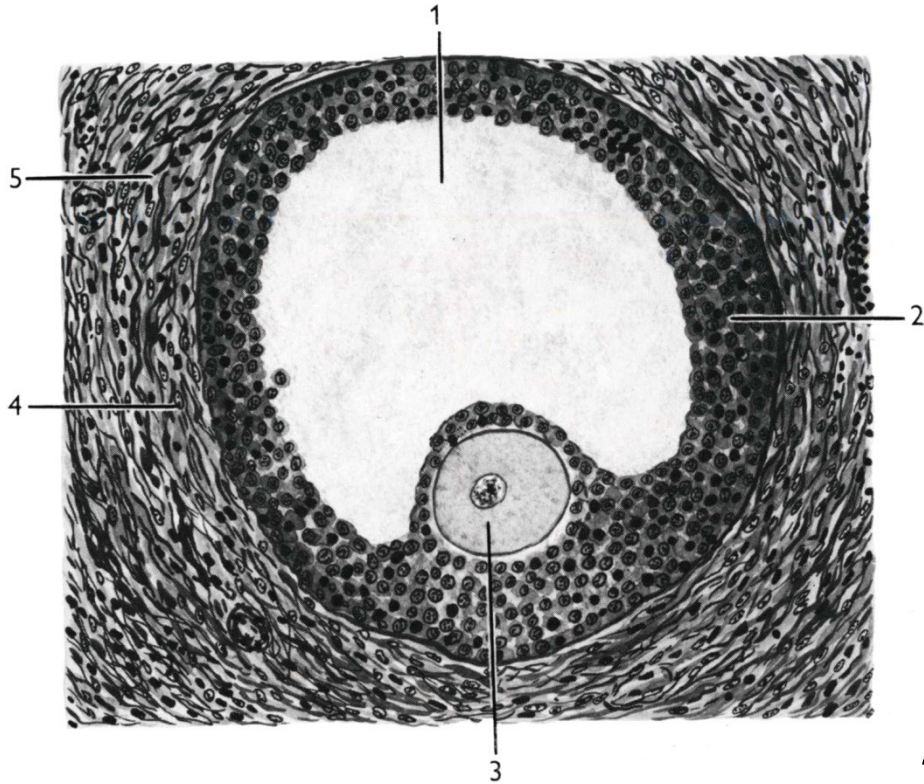
<https://www.youtube.com/watch?v=tOluxtc3Cpw&t=611s>

<https://www.youtube.com/watch?v=WGJsrGmWeKE&t=3s>

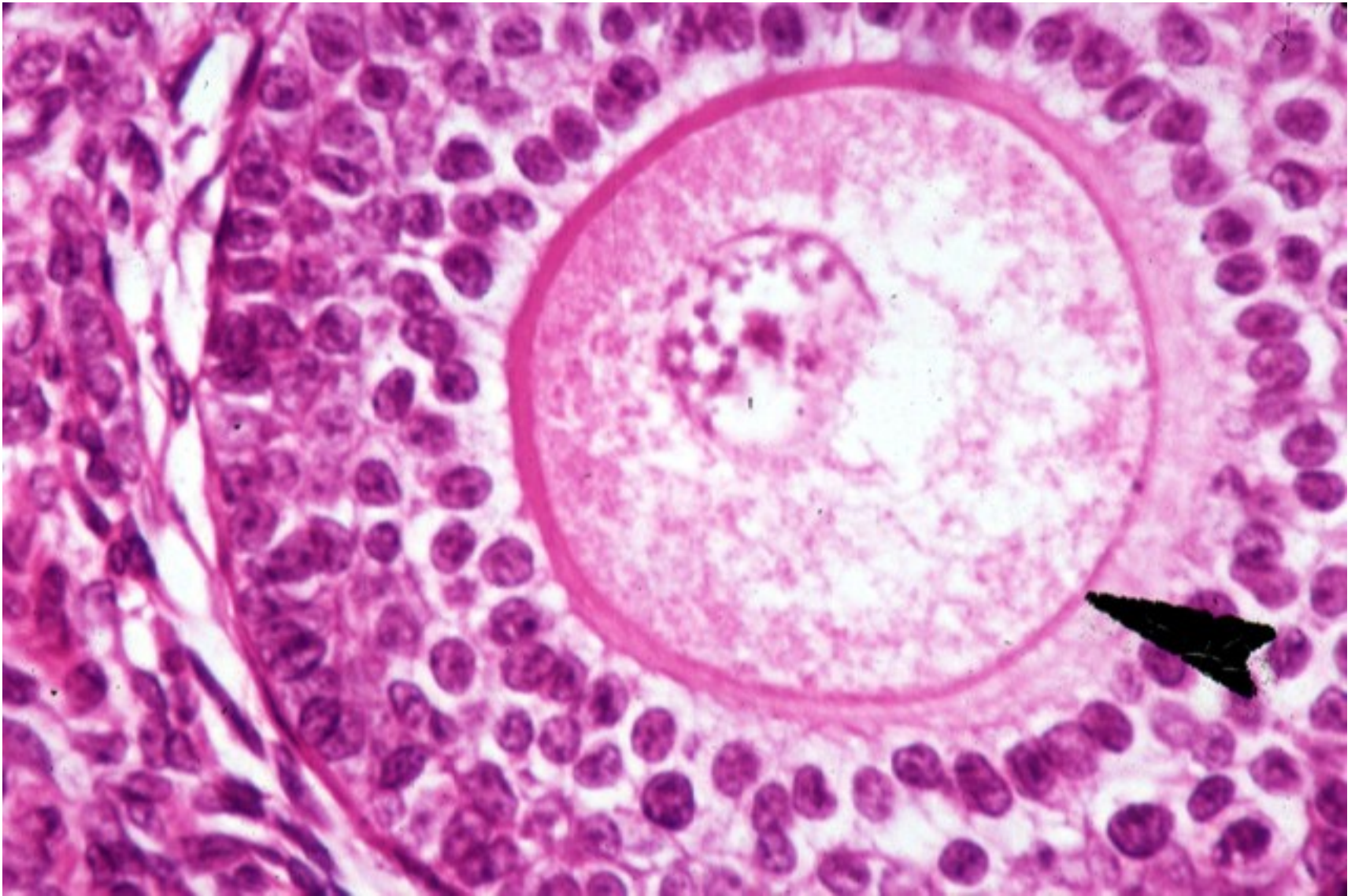


Ovary - cortex with follicle, medulla

Folliculus ovaricus vesiculosus (Graaf's)

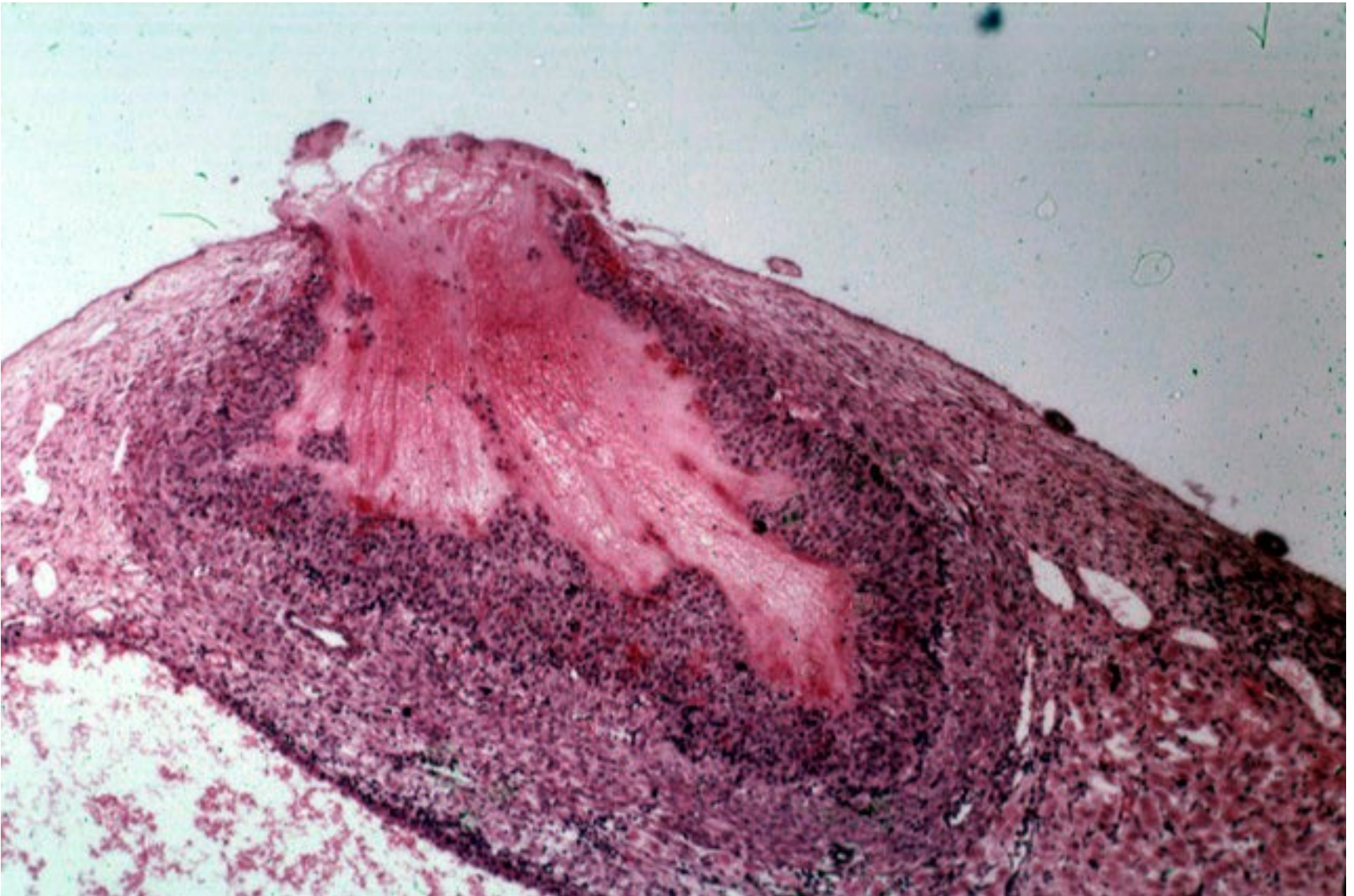


1. antrum folliculi (liquor folliculi)
2. membrana granulosa
3. oocyt (cumulus oophorus)
4. theca folliculi interna
5. theca folliculi externa

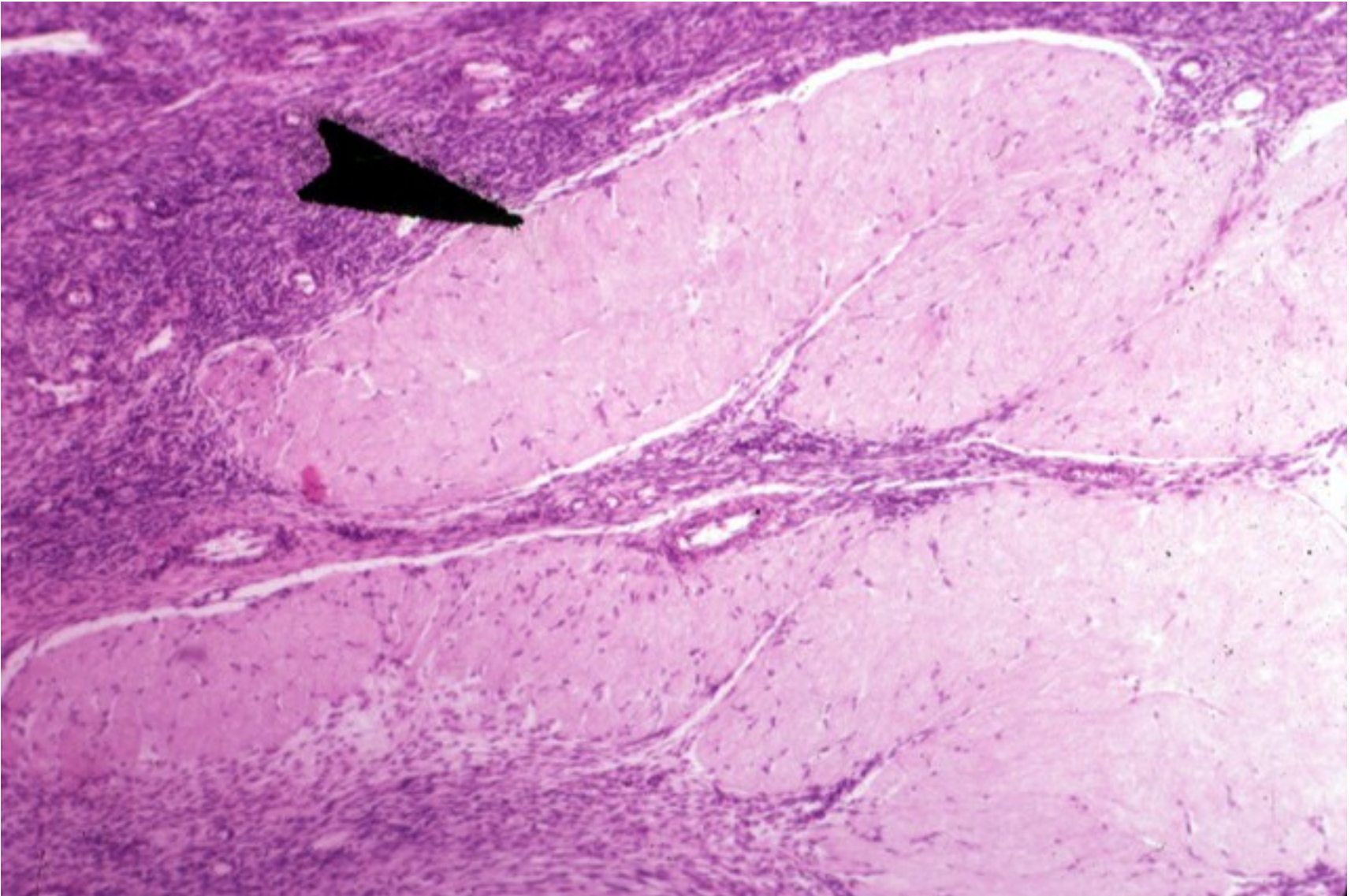


Ovum : zona pellucida, granulosa

Ovulation



Corpus luteum

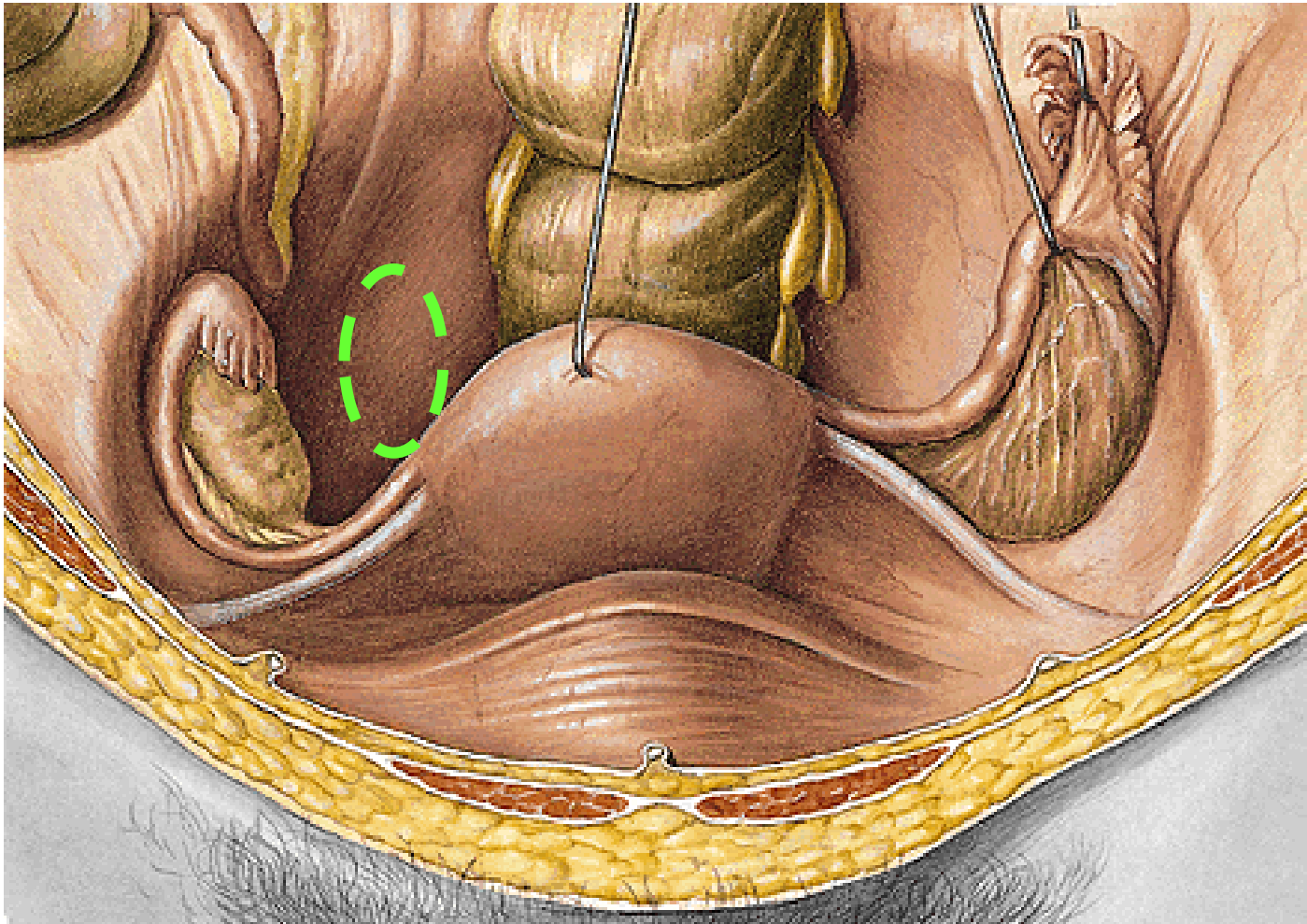


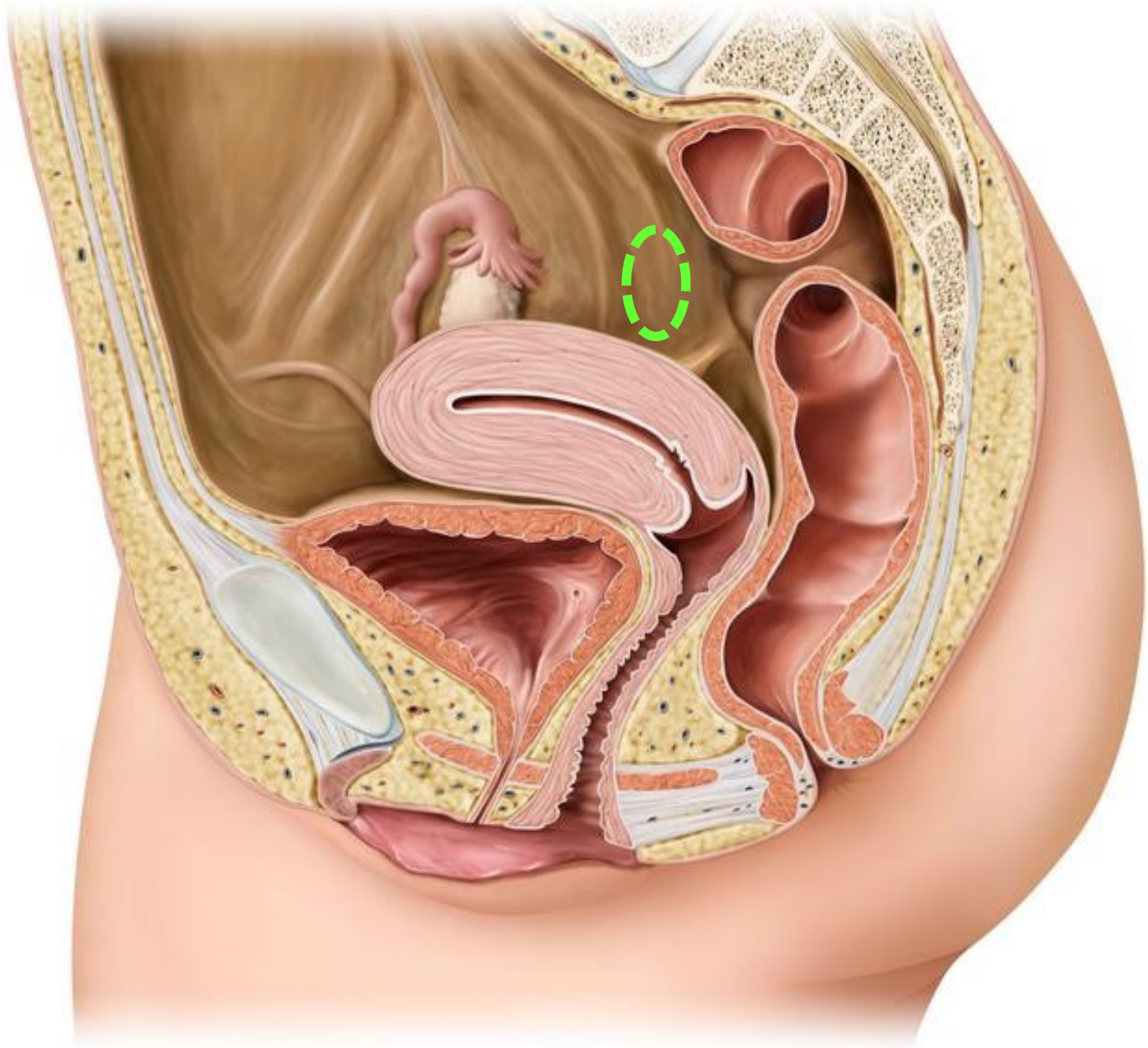
<https://www.youtube.com/watch?v=nLmg4wSHdxQ&t=25s>

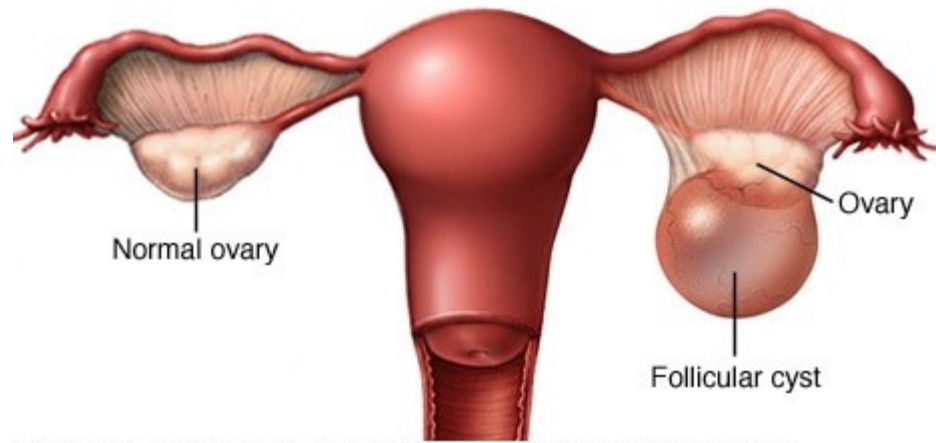
LOCALIZATION OF OVARY

Nullipara – fossa ovarica (in front of a. iliaca int.)

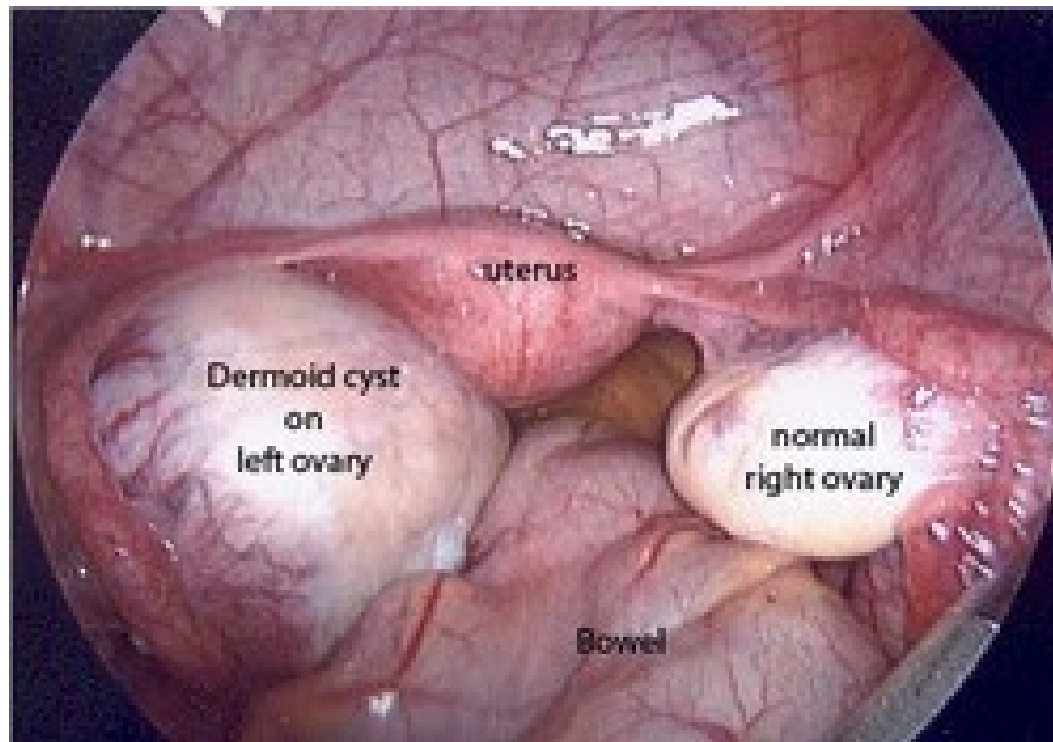
Multipara – Claudius fossa (behind a. iliaca int.)



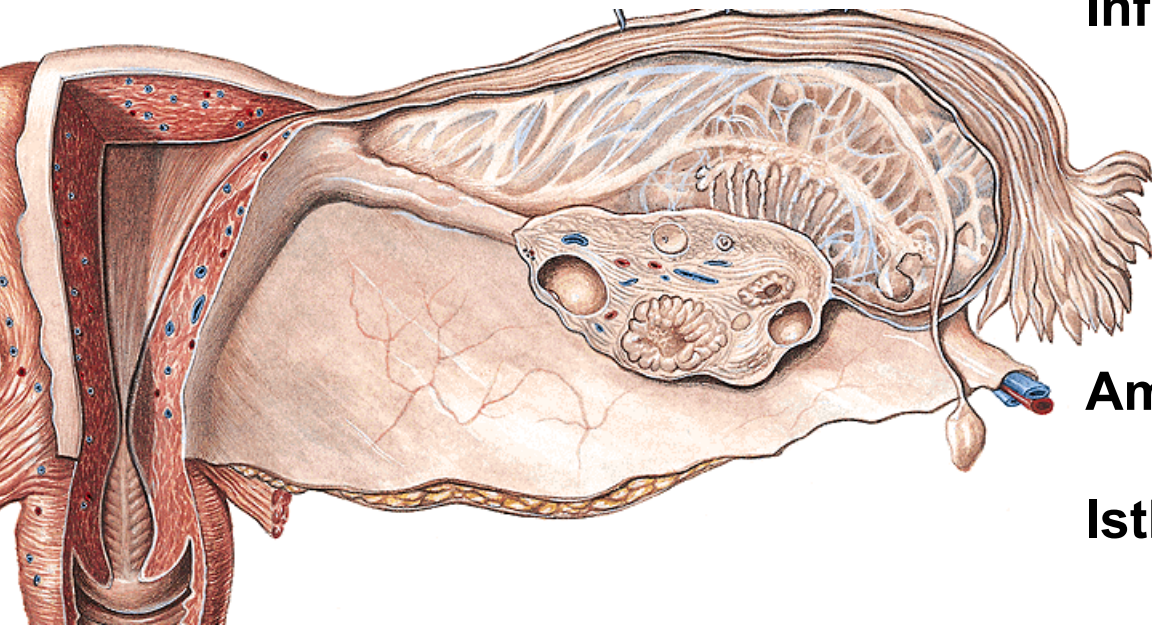




© MAYO FOUNDATION FOR MEDICAL EDUCATION AND RESEARCH. ALL RIGHTS RESERVED.



TUBA UTERINA (SALPINX)



Infundibulum tubae uterinae

ostium abdominale tubae

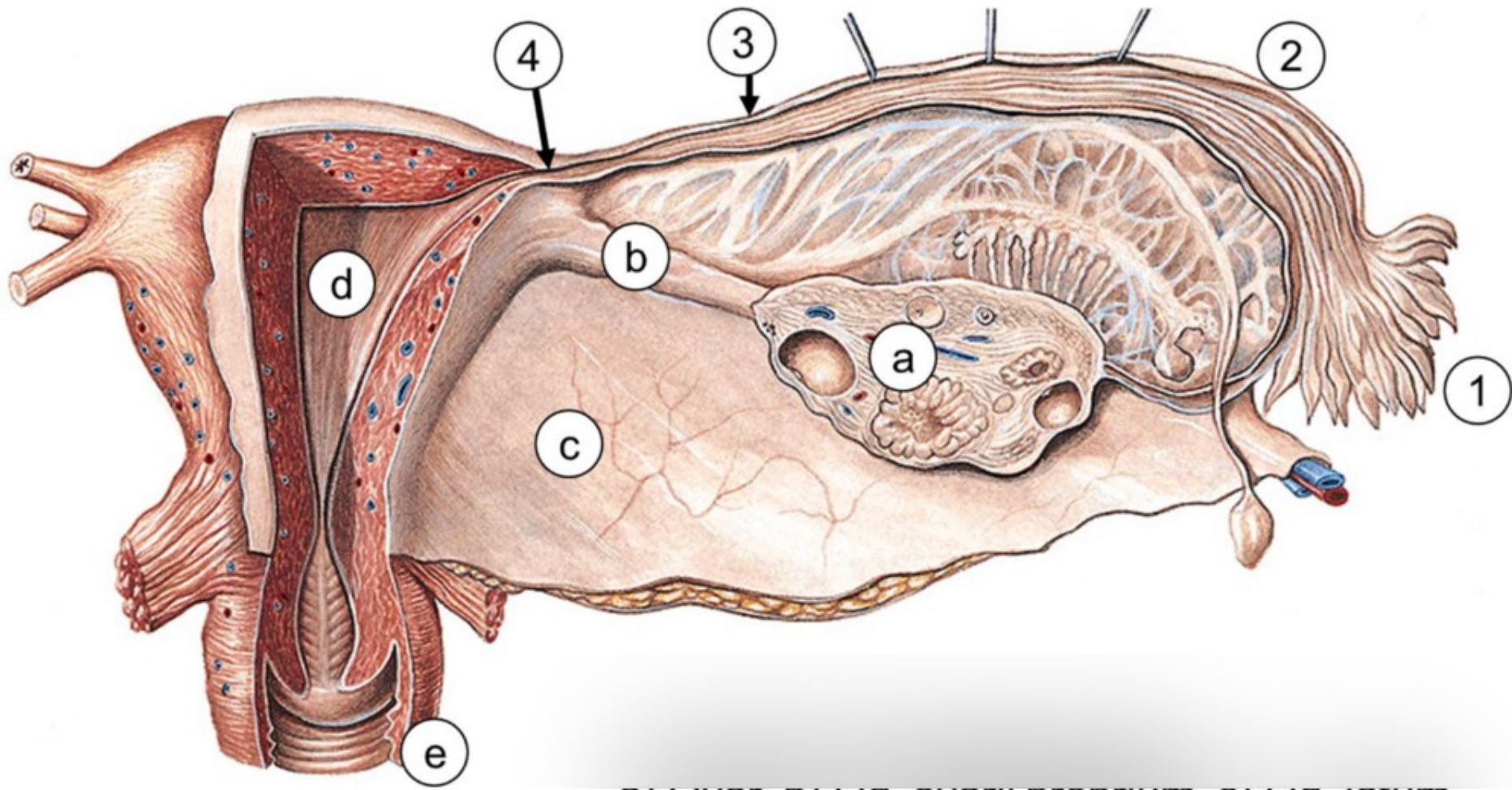
fimbriae (fimbria ovarica)

Ampulla tubae uterinae

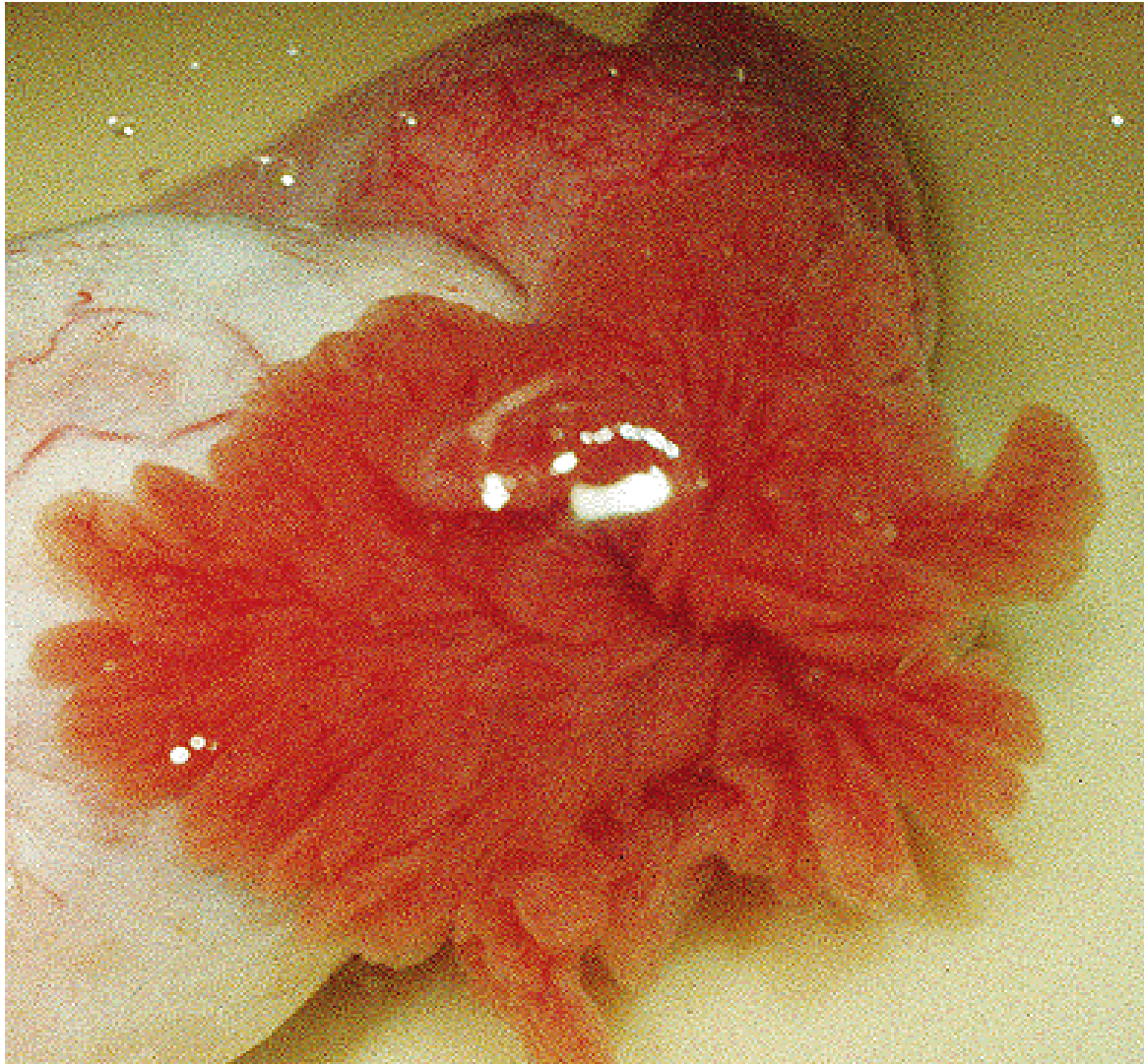
Isthmus tubae uterinae

Pars uterina tubae uterinae

ostium uterinum tubae

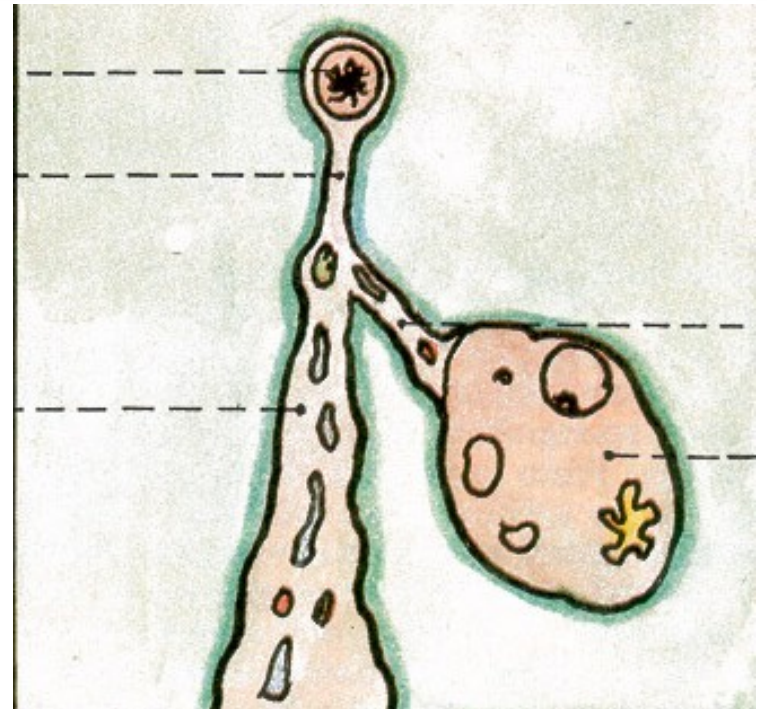
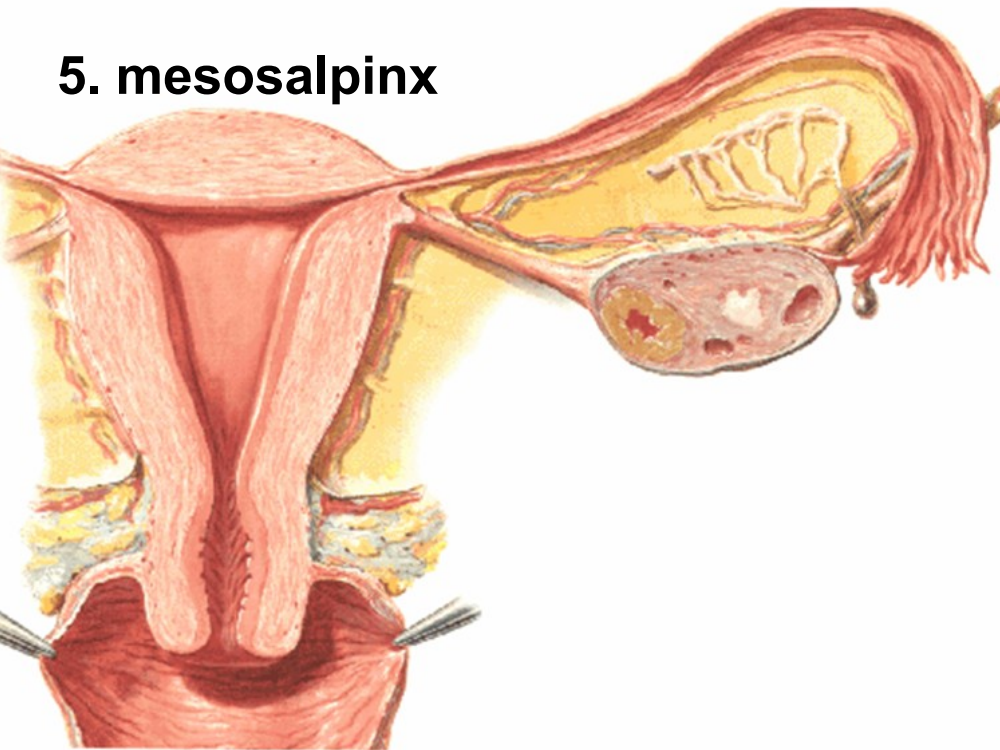
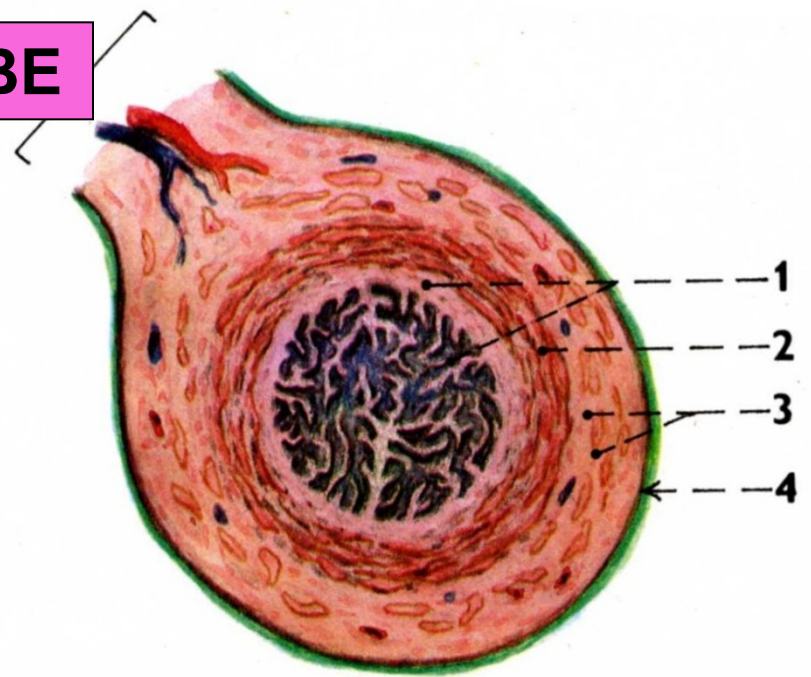


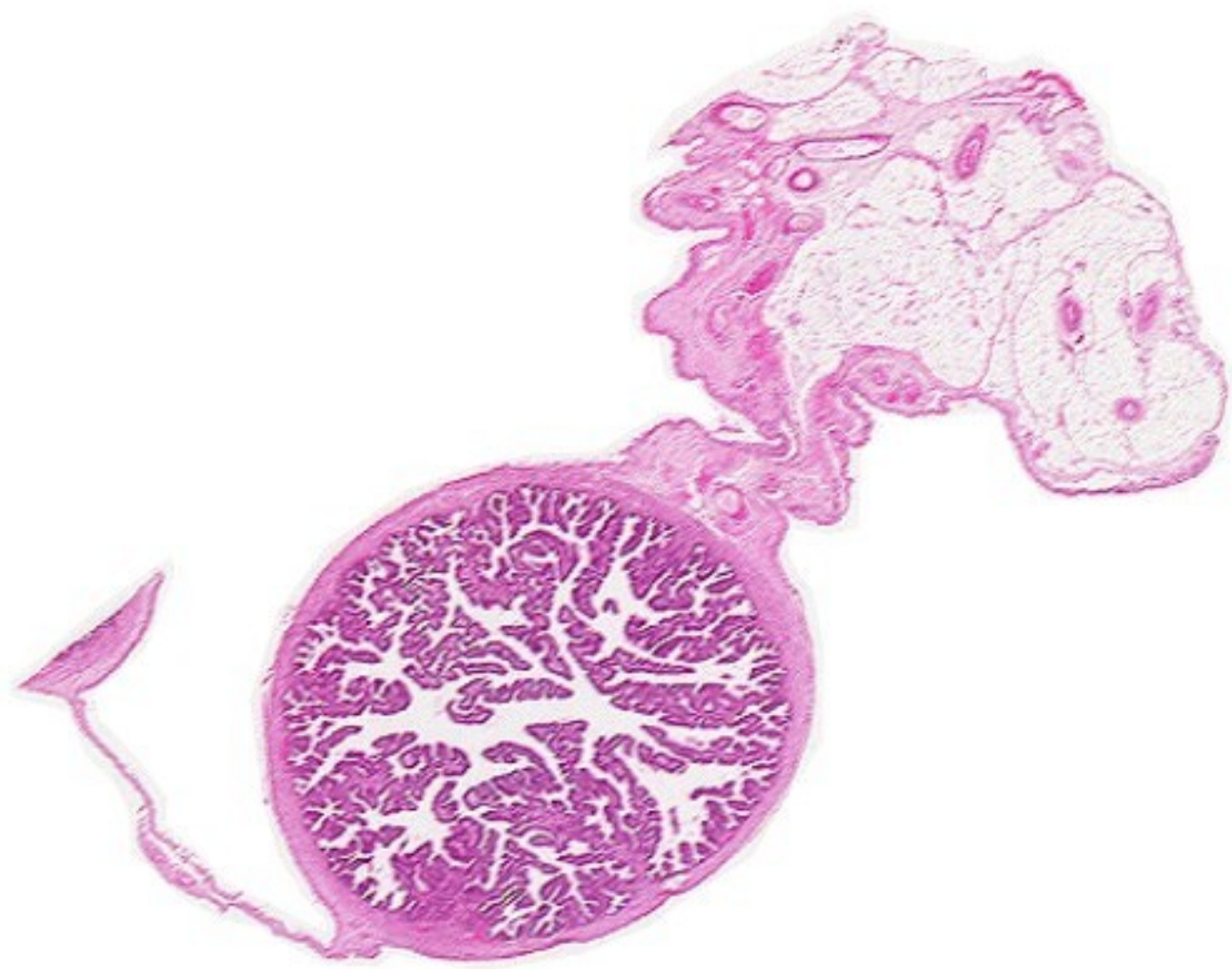OSTIUM ABDOMINALE TUBAE UTERINAE

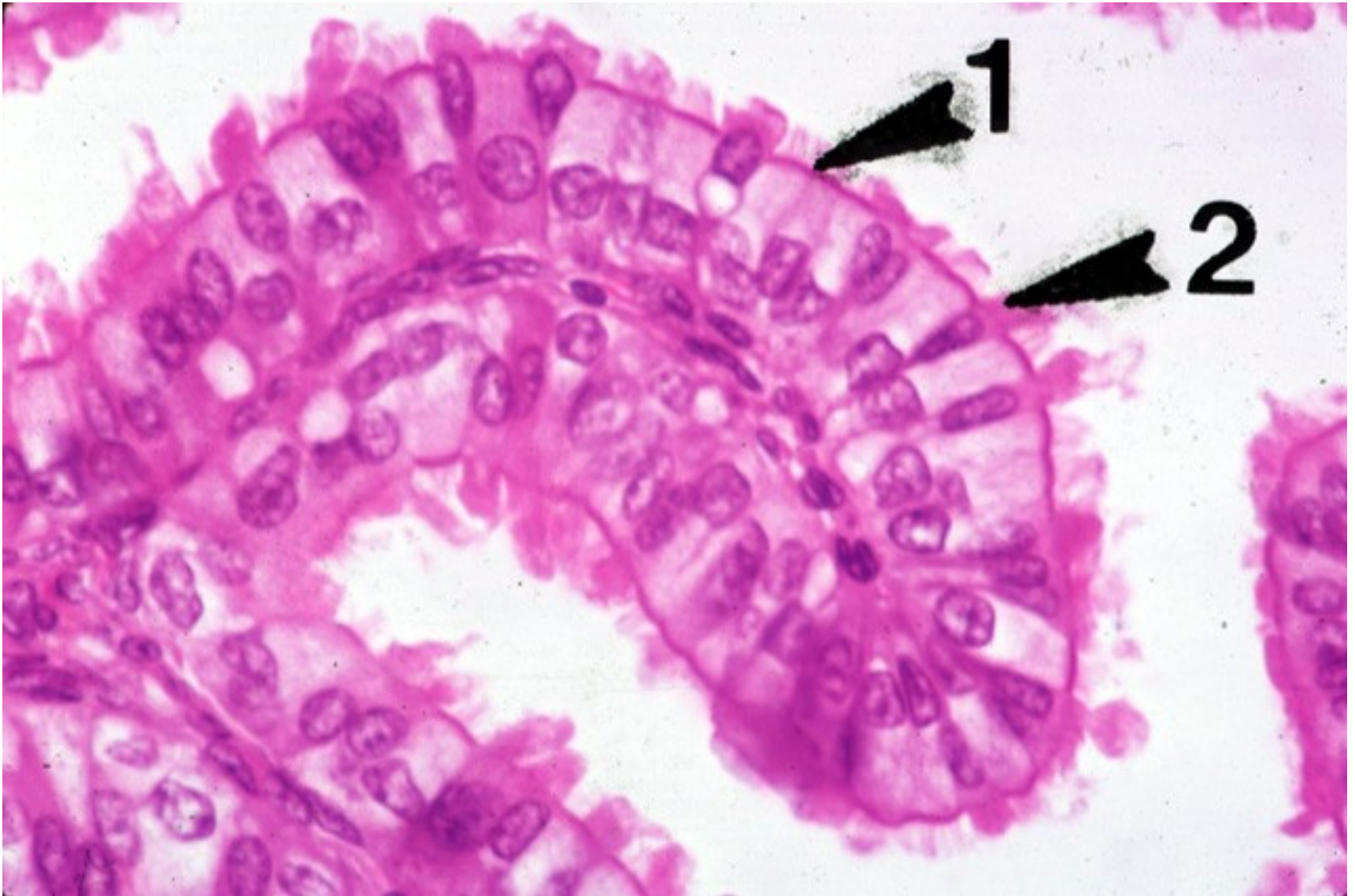

HISTOLOGY OF PHALOPIAN TUBE

1. Mucosal folds
(cylind. epithelium cilliated)
2. Circular muscular layer
3. Longitudinal muscular layer
4. tunica serosa
5. mesosalpinx



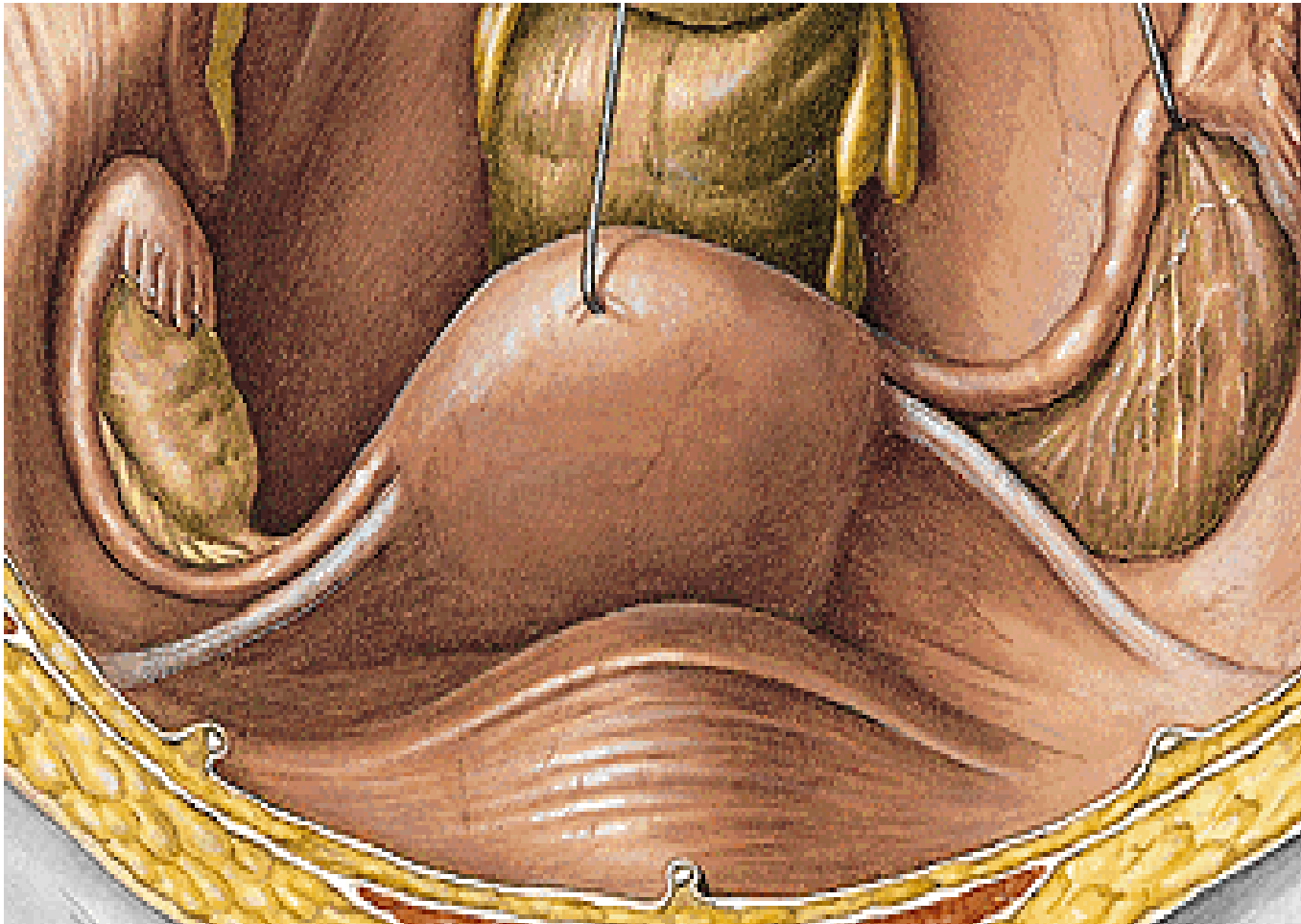




Tuba uterina – mucosal fold = cylindric. epithelium – 1. secretory cells - 2

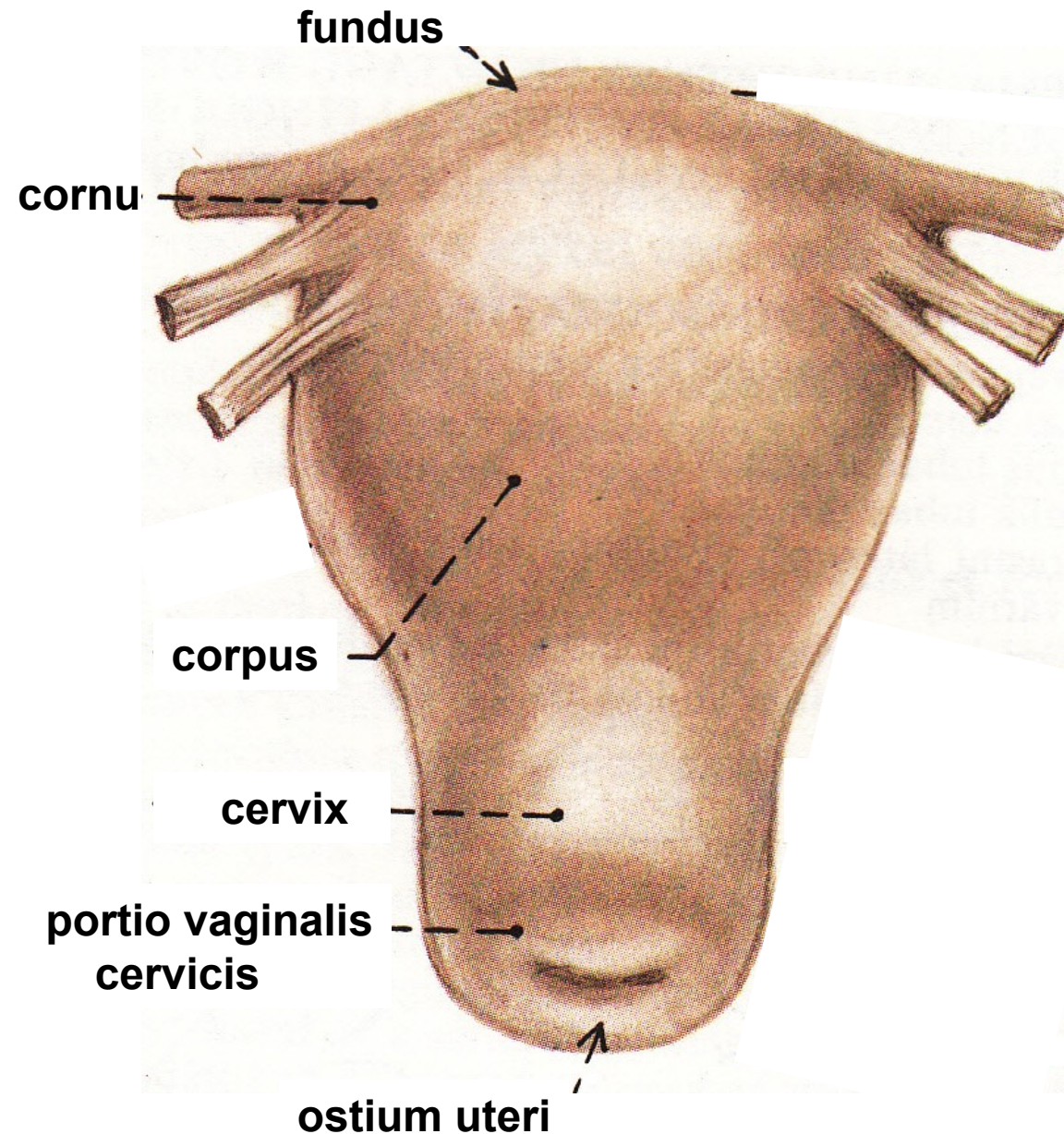
PHALOPIAN TUBE COURSE

- from uterus runs laterally to the pelvic wall
- dorsocranially to the upper pole of ovary
- fimbriae rotated to facies medialis ovarii



<https://www.youtube.com/watch?v=GxRJH2f--P0>

UTERUS (HYSTERA, METRA)



Fundus

Corpus

facies vesicalis

facies intestinalis

Cervix

Isthmus uteri

Margo dx. et sin.

Cornu dx. et sin.

lig. teres uteri

lig. ovarii proprium

Cavum uteri (3 ml)

Canalis isthmi

Ostium internum canalis cervicis

Canalis cervicis (plicae palmatae)

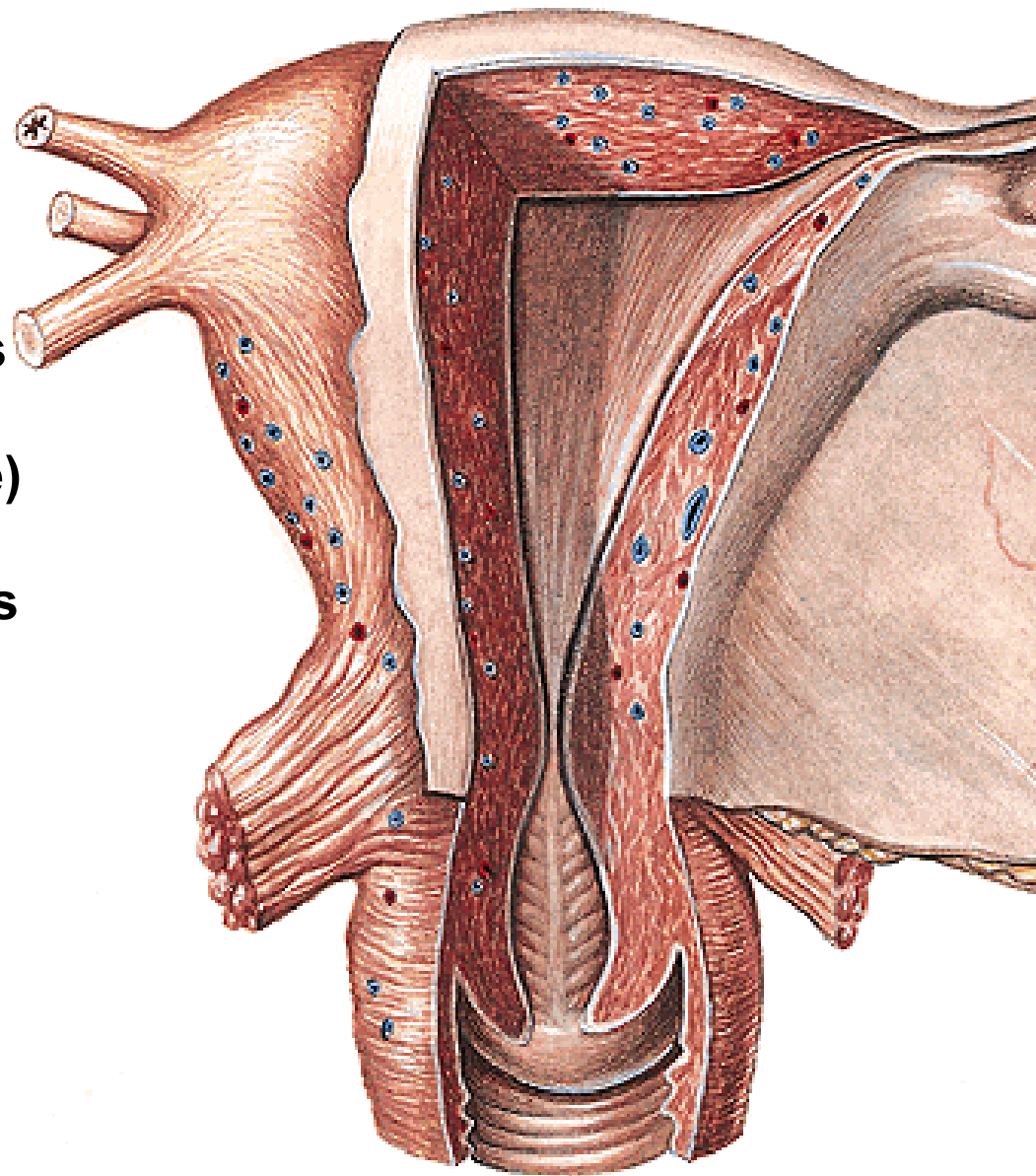
**Ostium externum canalis cervicis
(= ostium uteri)**

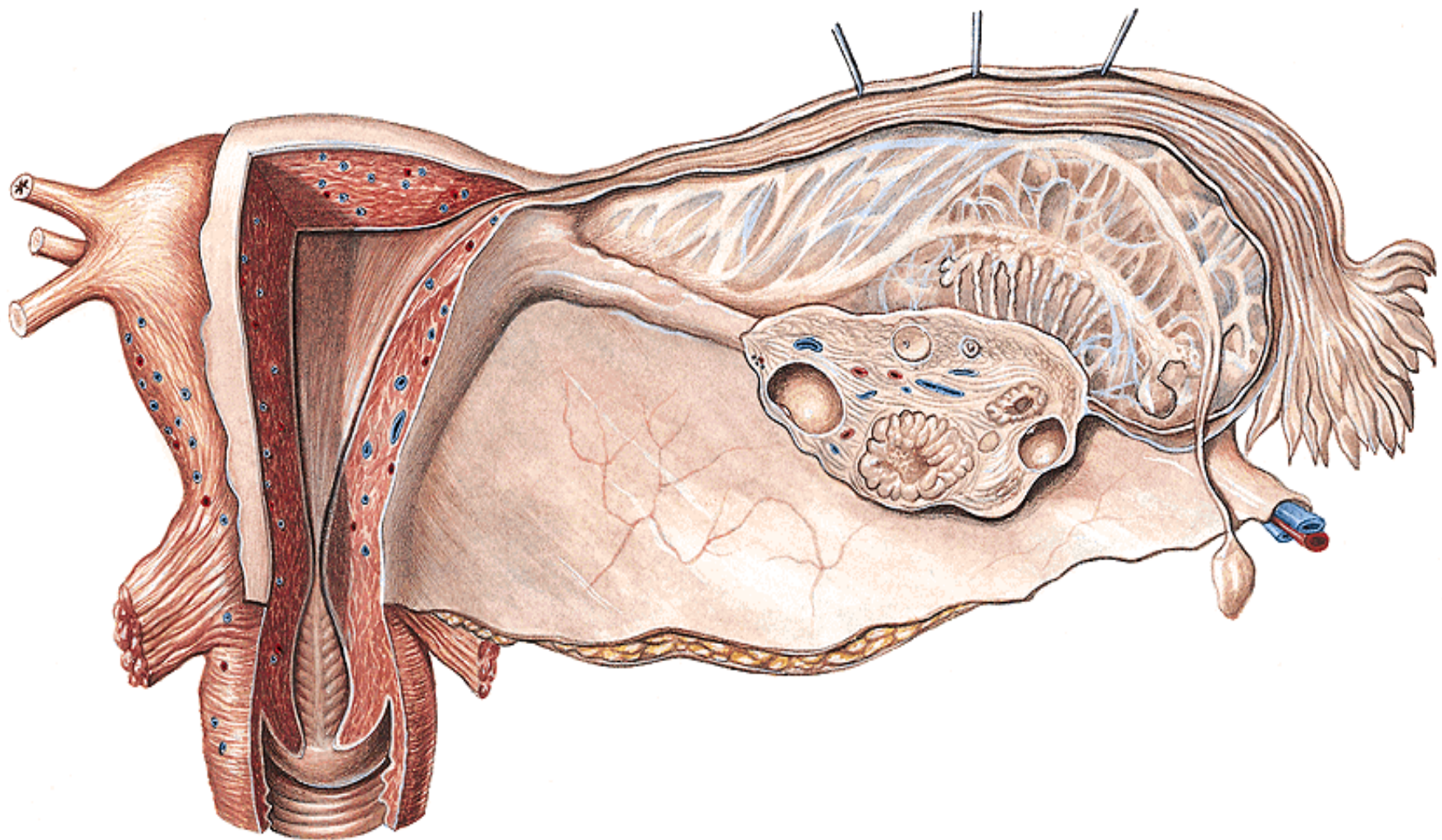
Cervix

portio supravaginalis

portio vaginalis

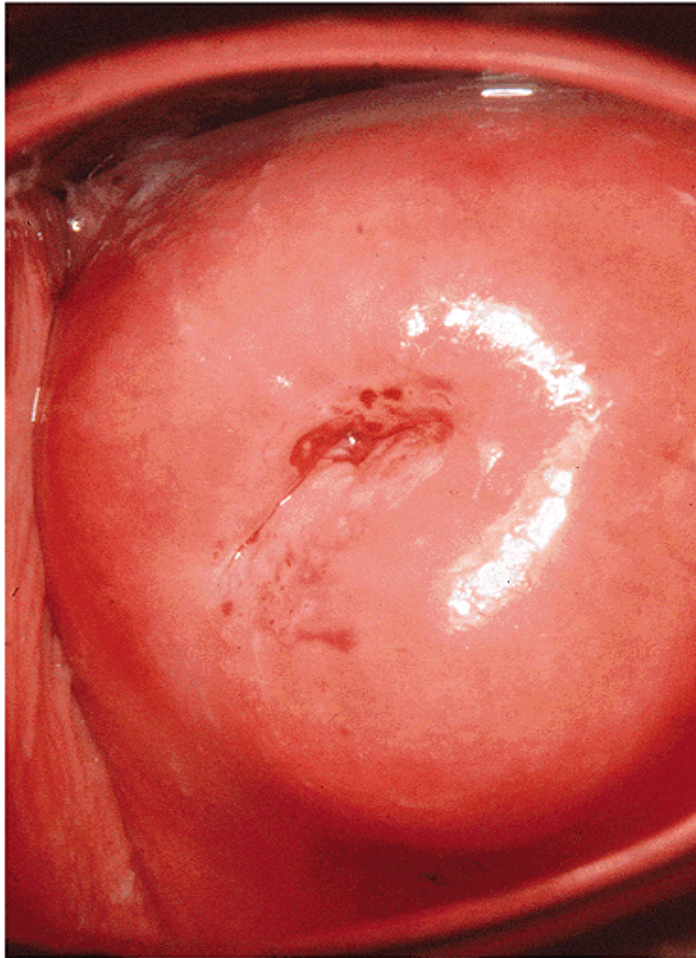
Fornix vaginae



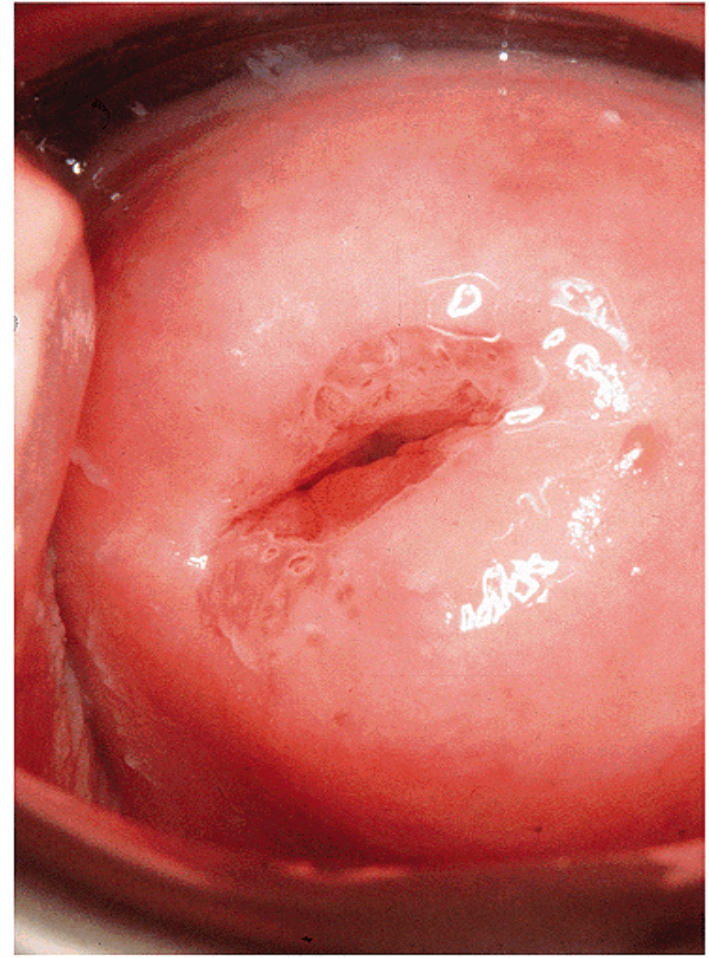


OSTIUM UTERI (OSTIUM EXTERNUM CANALIS CERVICIS)

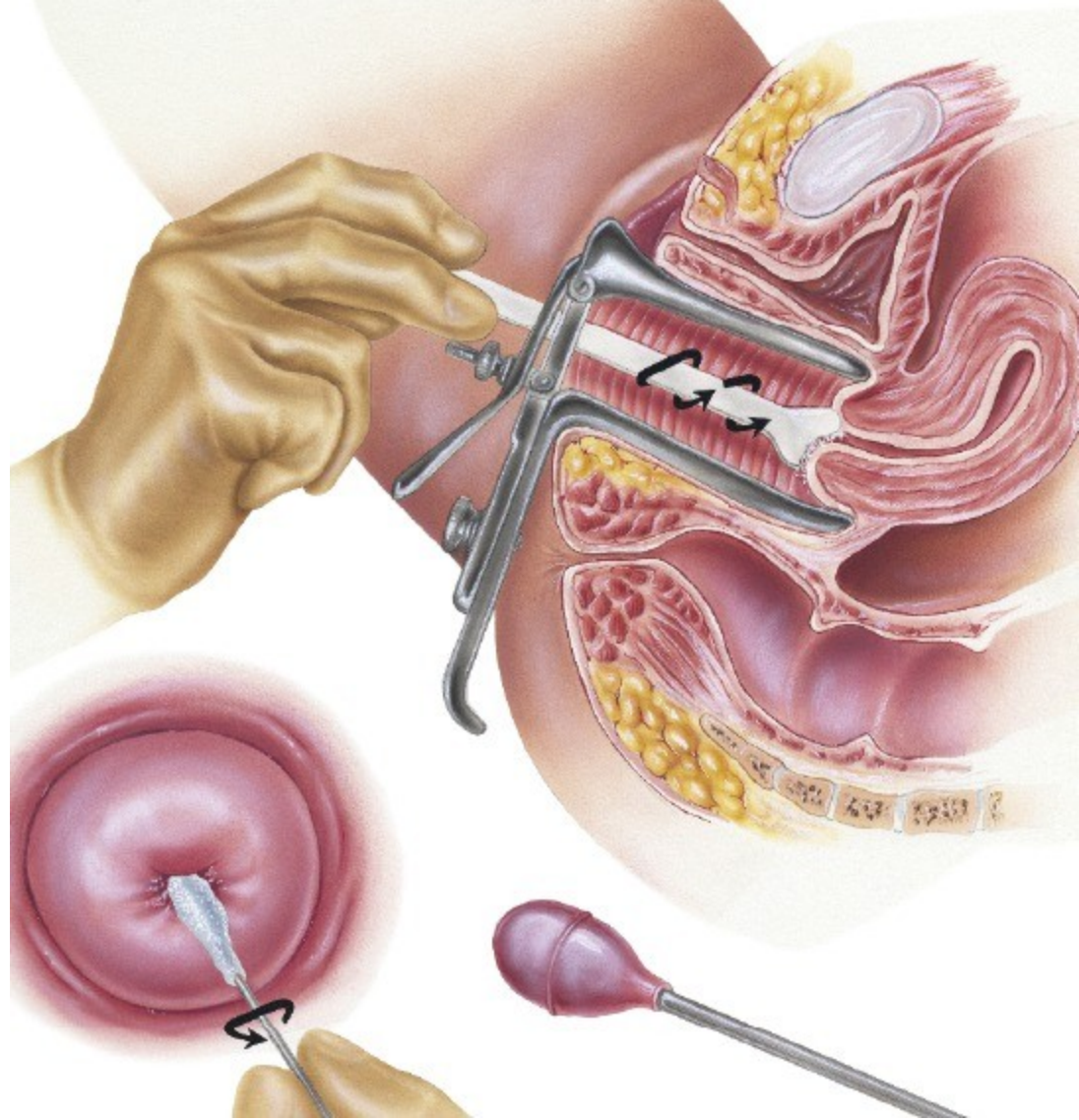
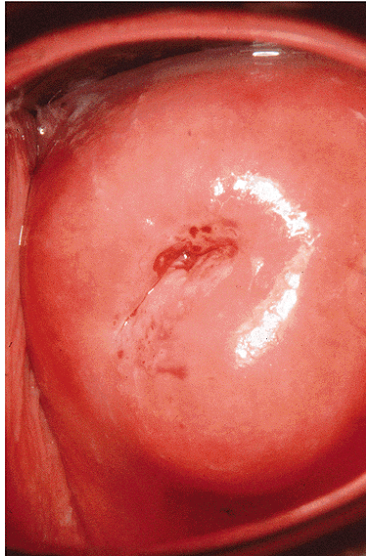
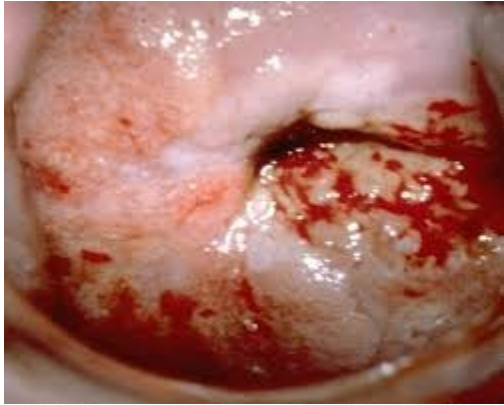NULLIPARA



MULTIPARA



Labium anterius et posterius

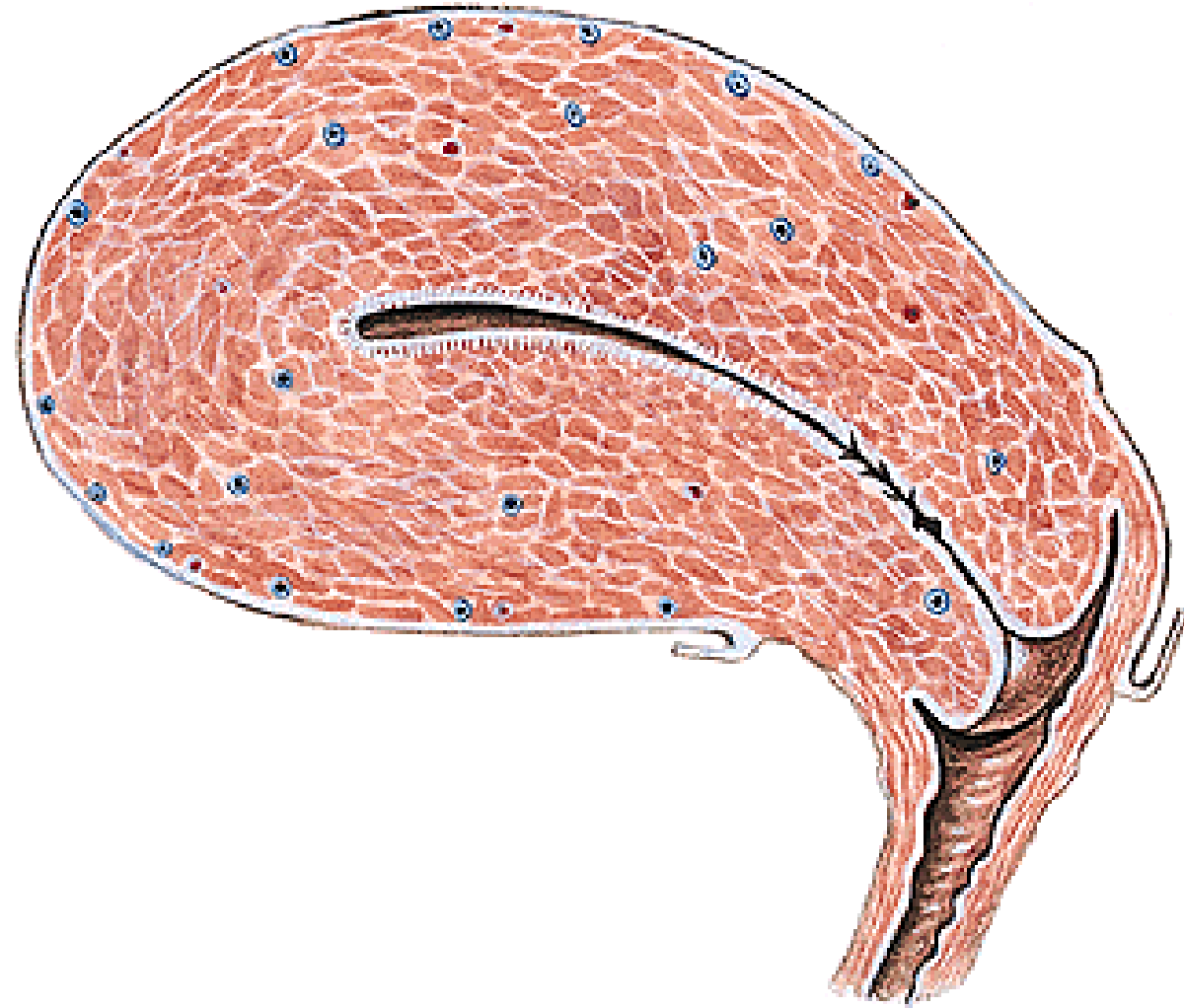


HISTOLOGY OF UTERUS

Endometrium

Myometrium

Perimetrium



ENDOMETRIUM

Simple cylindric epithelium

zona basalis

zona functionalis

glandulae uterinae

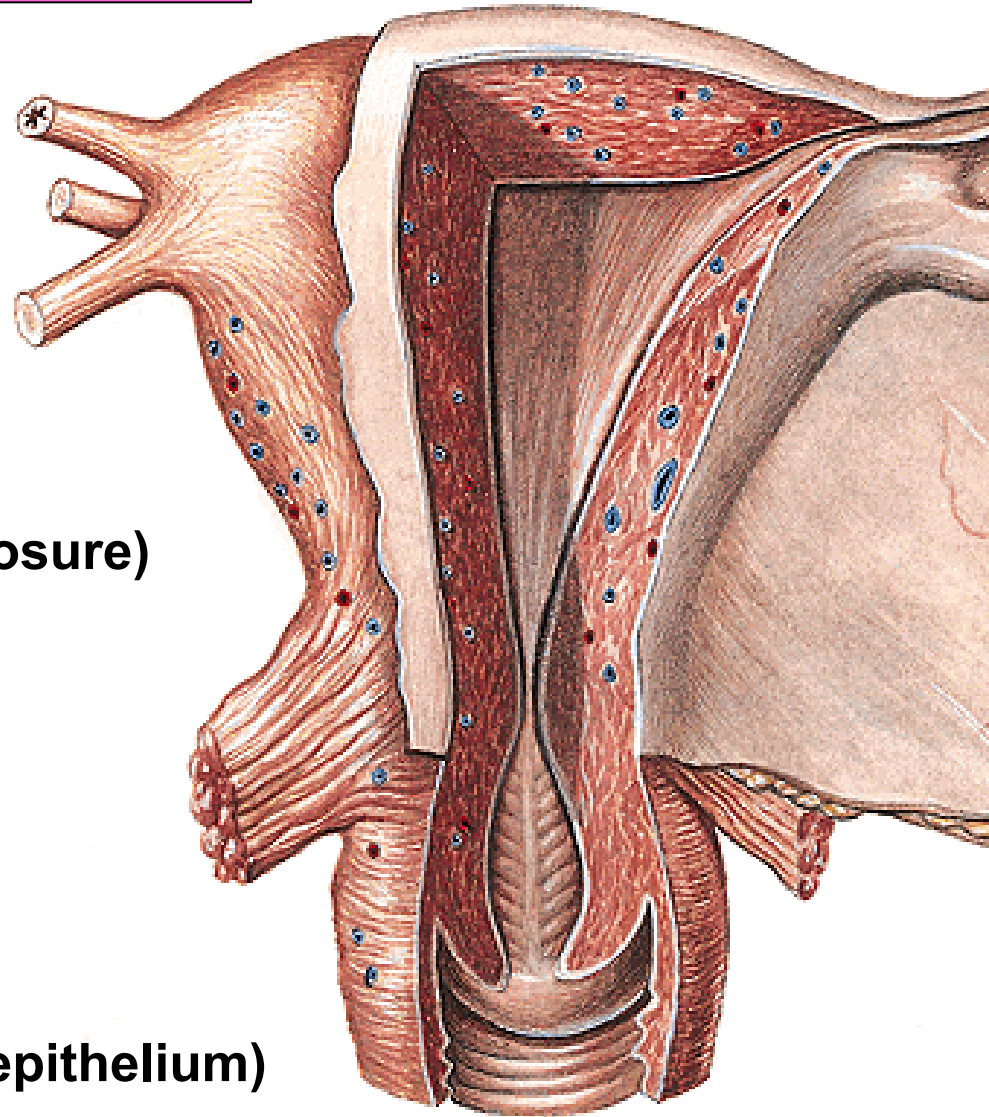
glandulae cervicales (mucose closure)

menstruation cycle

menarche

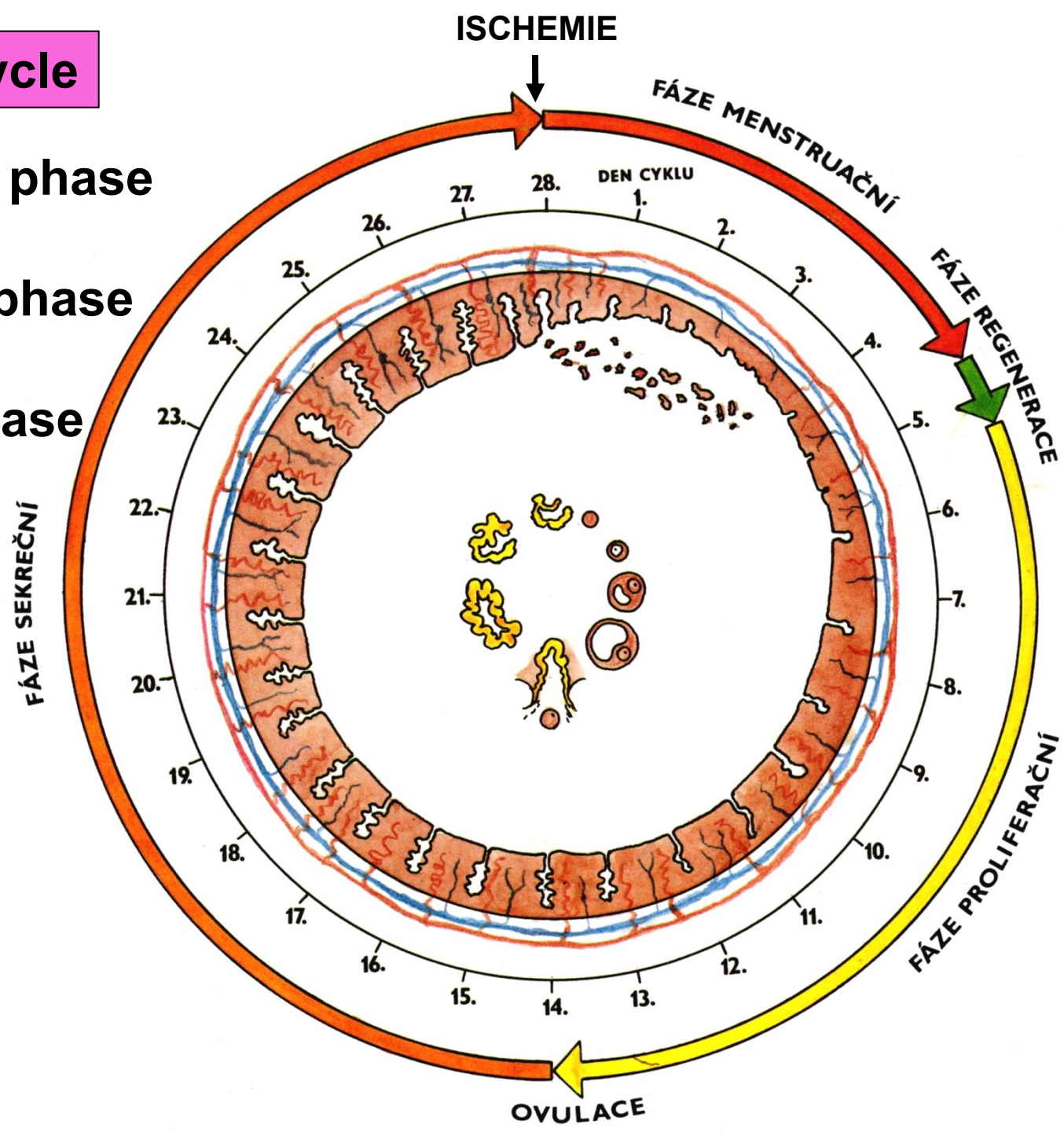
menopausa (climacterium)

ostium uteri (multilayer stratified epithelium)

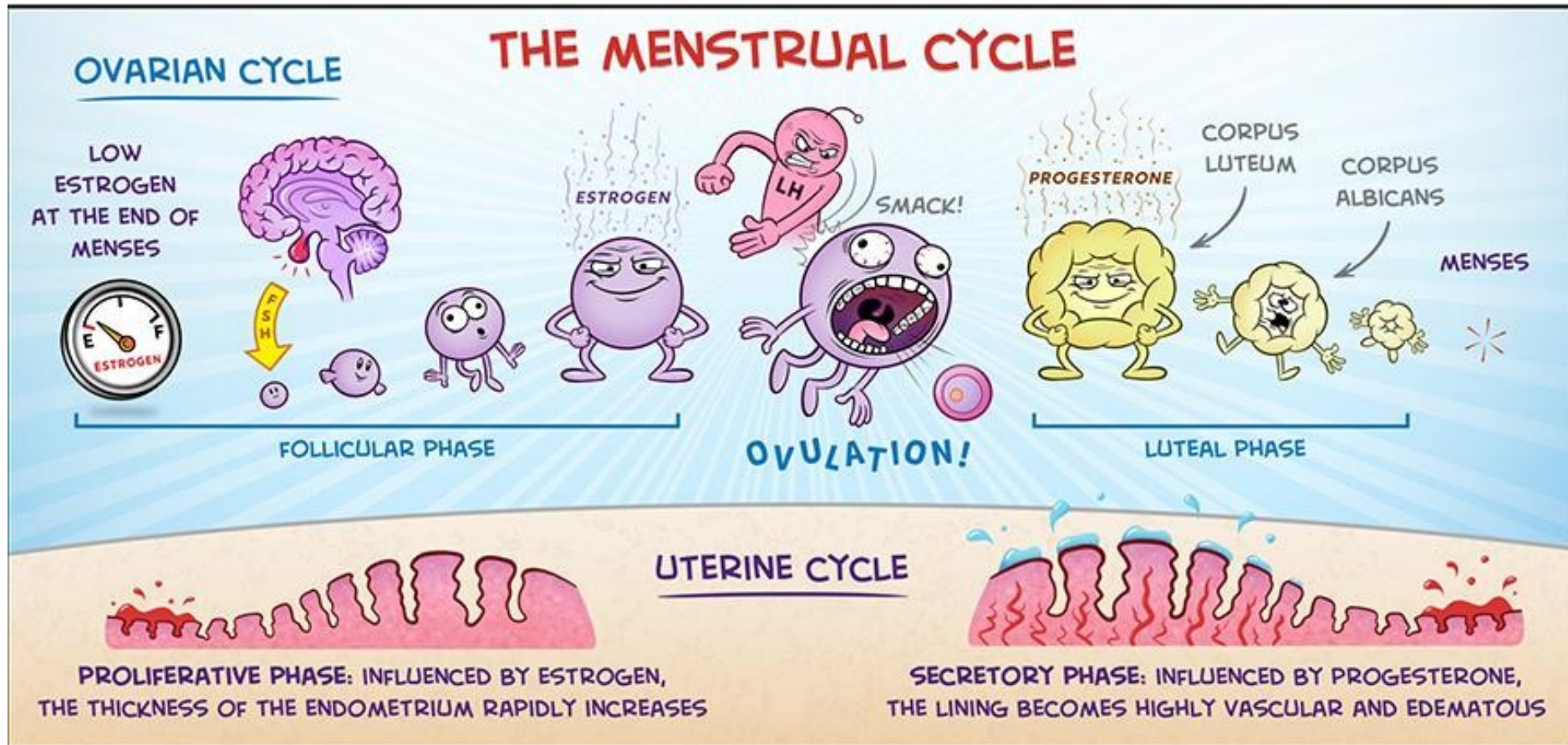


Menstruation cycle

1. Menstruation phase
2. Proliferation phase
3. Secretory phase
4. Ischemia

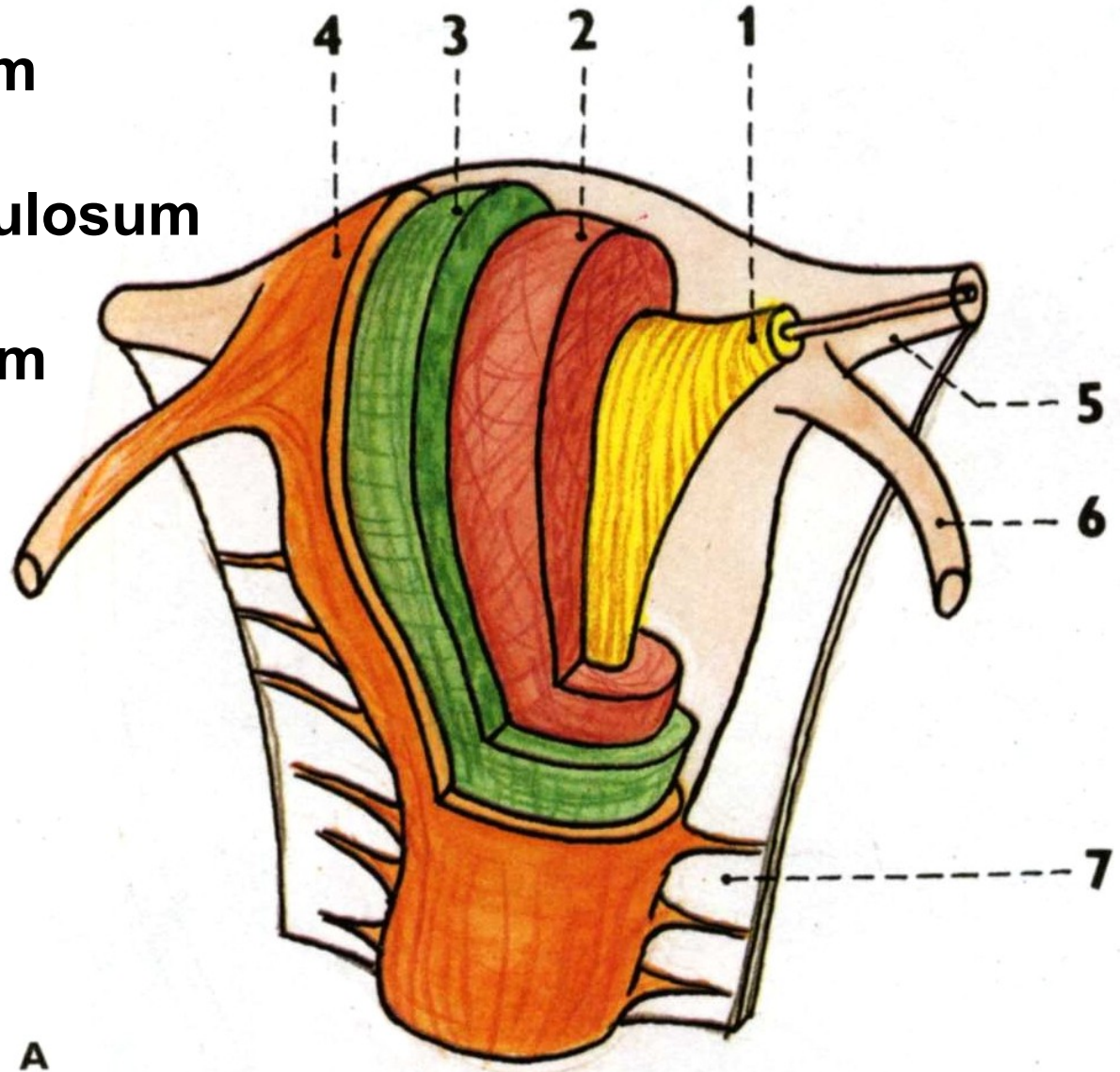


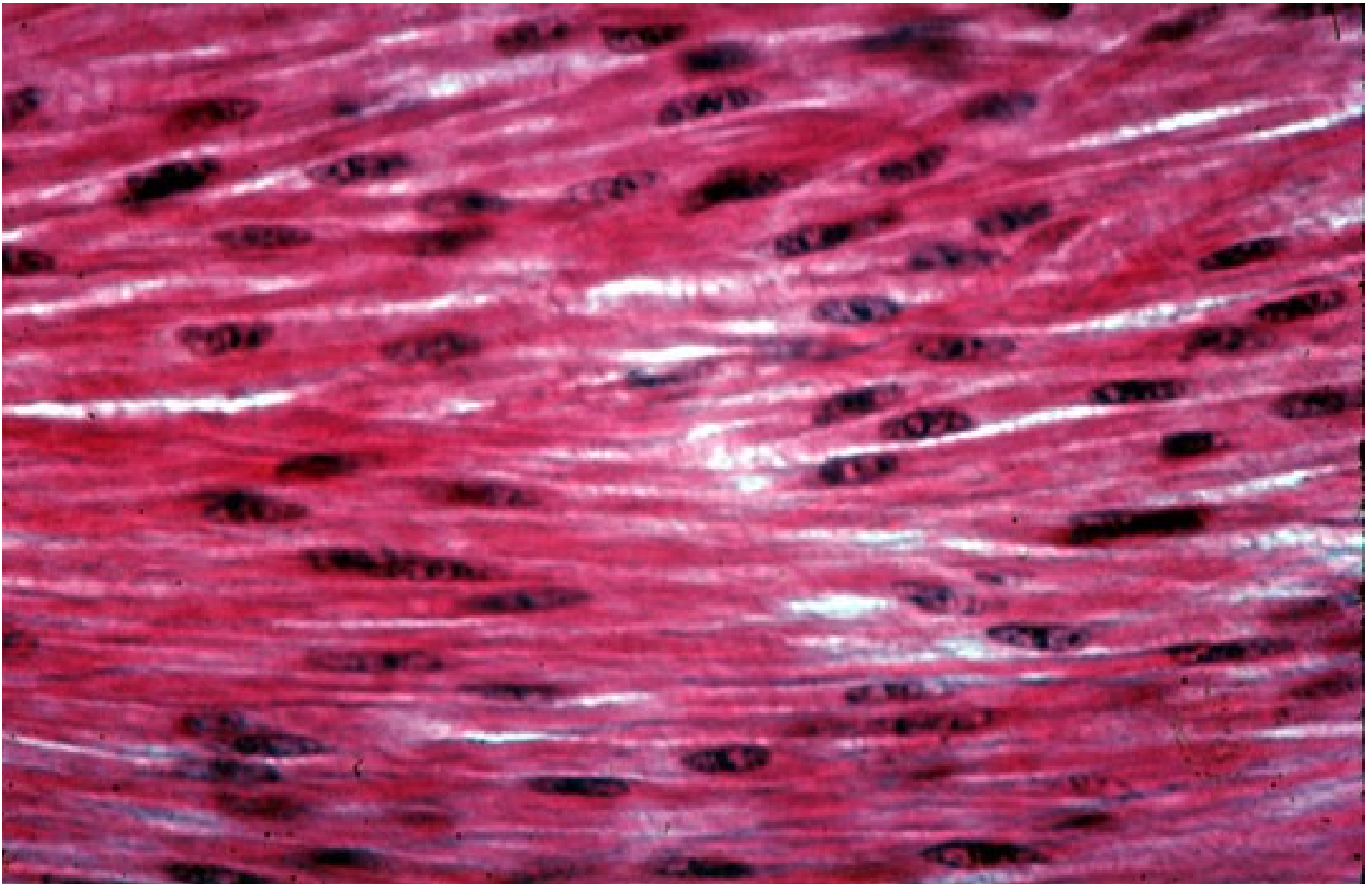
CYCLE	PRE-OVULATION		OVULATION	POST-OVULATION
<i>Ovarian cycle</i>	FOLLICULAR PHASE			LUTEAL PHASE
<i>Uterine cycle</i>	PERIOD	PROLIFERATIVE		SECRETORY



MYOMETRIUM

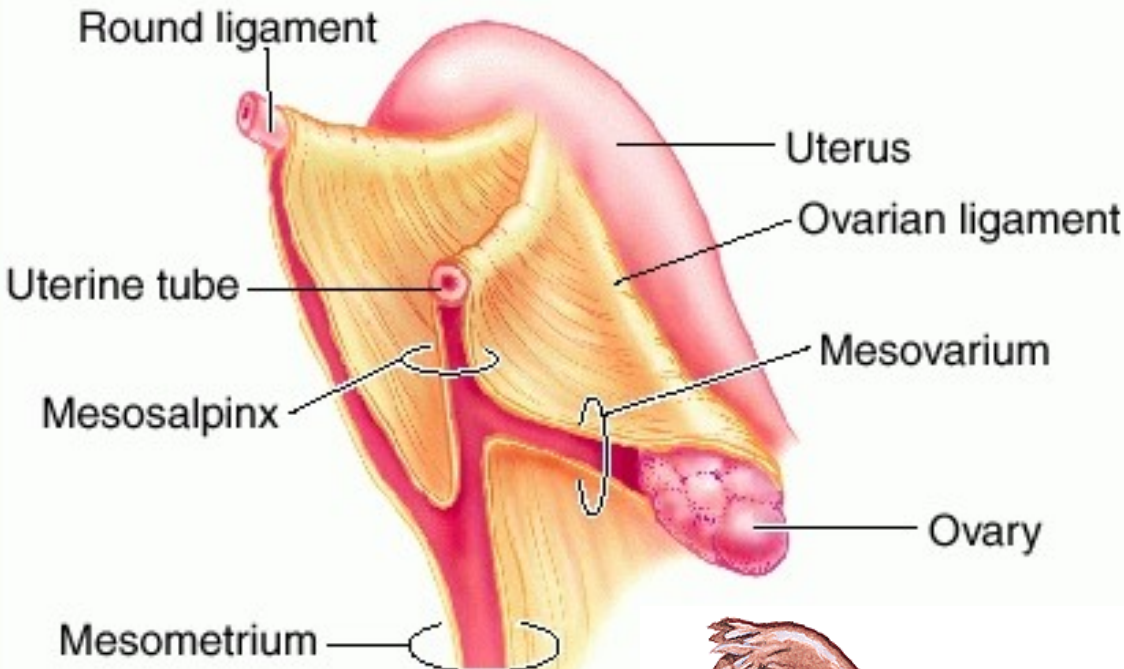
1. stratum submucosum
2. stratum vasculosum
3. stratum supravasculosum
4. stratum subserosum





Myometrium, myocytes – smooth muscles

PERIMETRIUM (VISCERAL PERITONEUM)

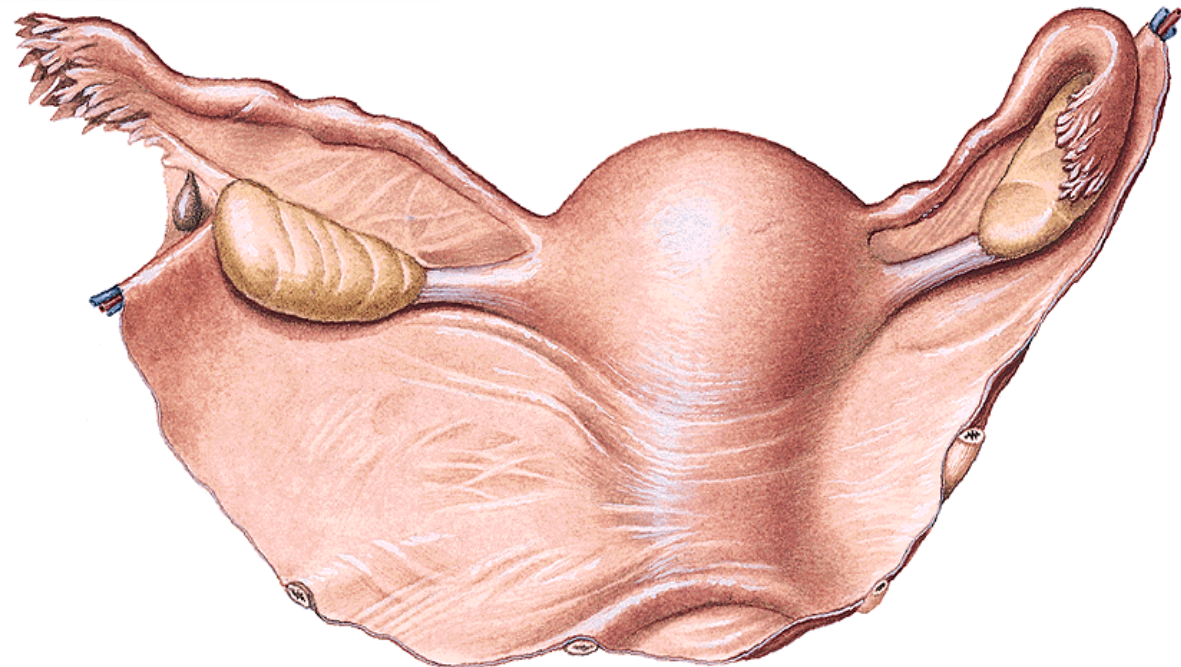


Lig. latum uteri

Mesosalpinx

Mesovarium

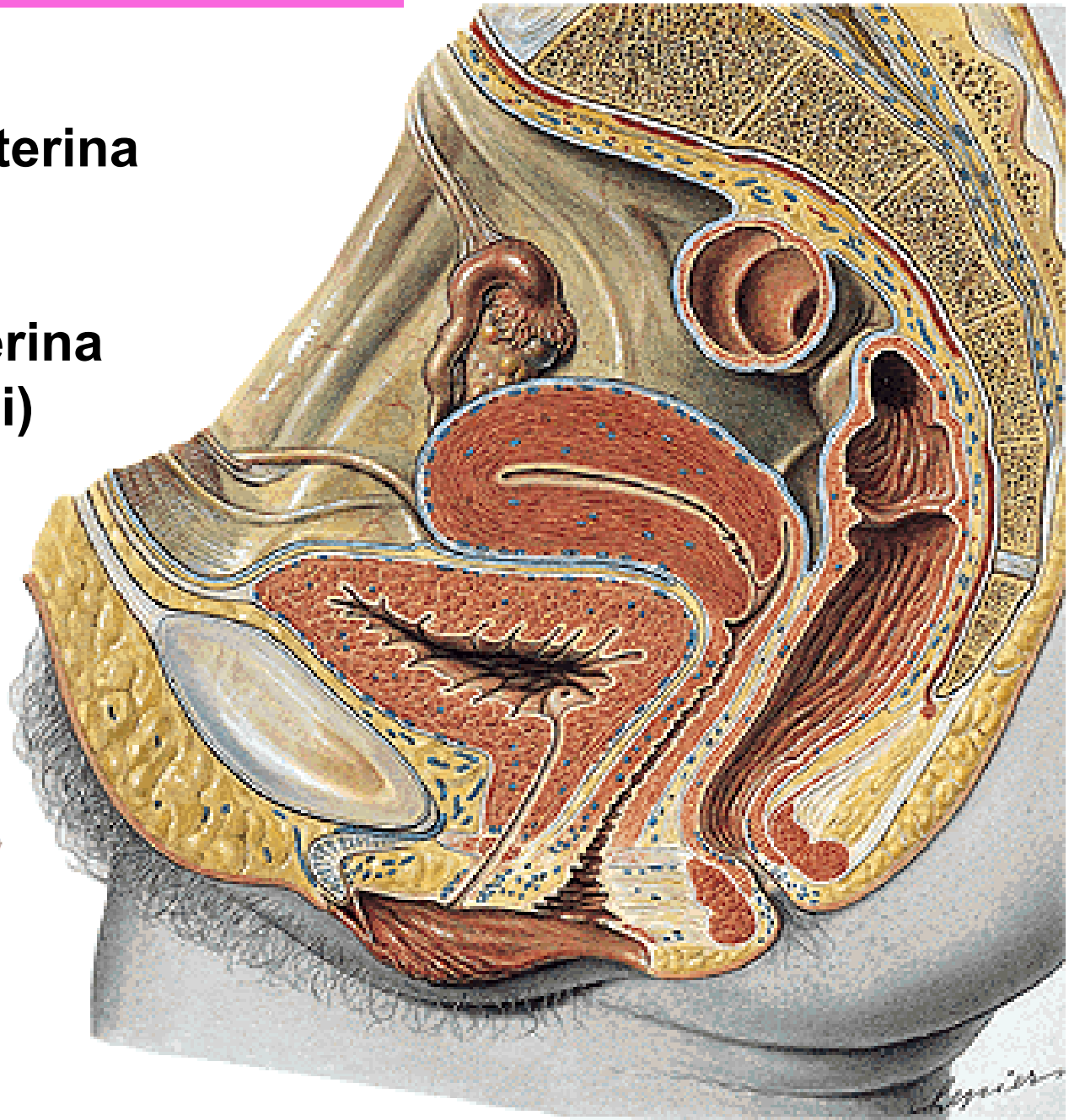
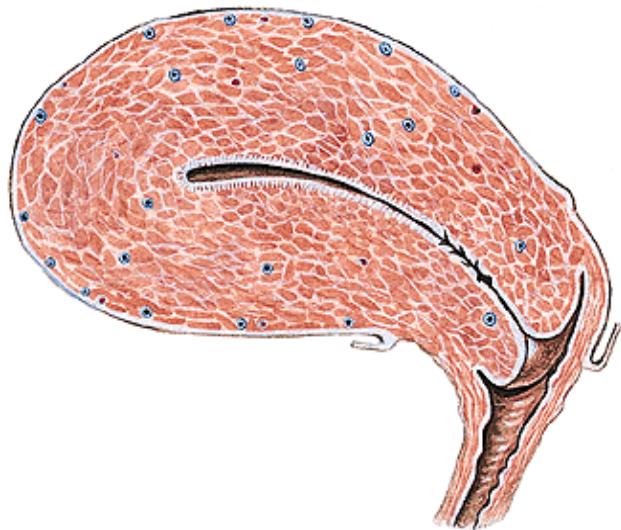
Lig. teres uteri



PERIMETRIUM

Excavatio vesicouterina

**Excavatio rectouterina
(cavum Douglasi)**



PARAMETRIUM

Lig. pubouterinum

lig. pubovesicale

lig. vesicouterinum

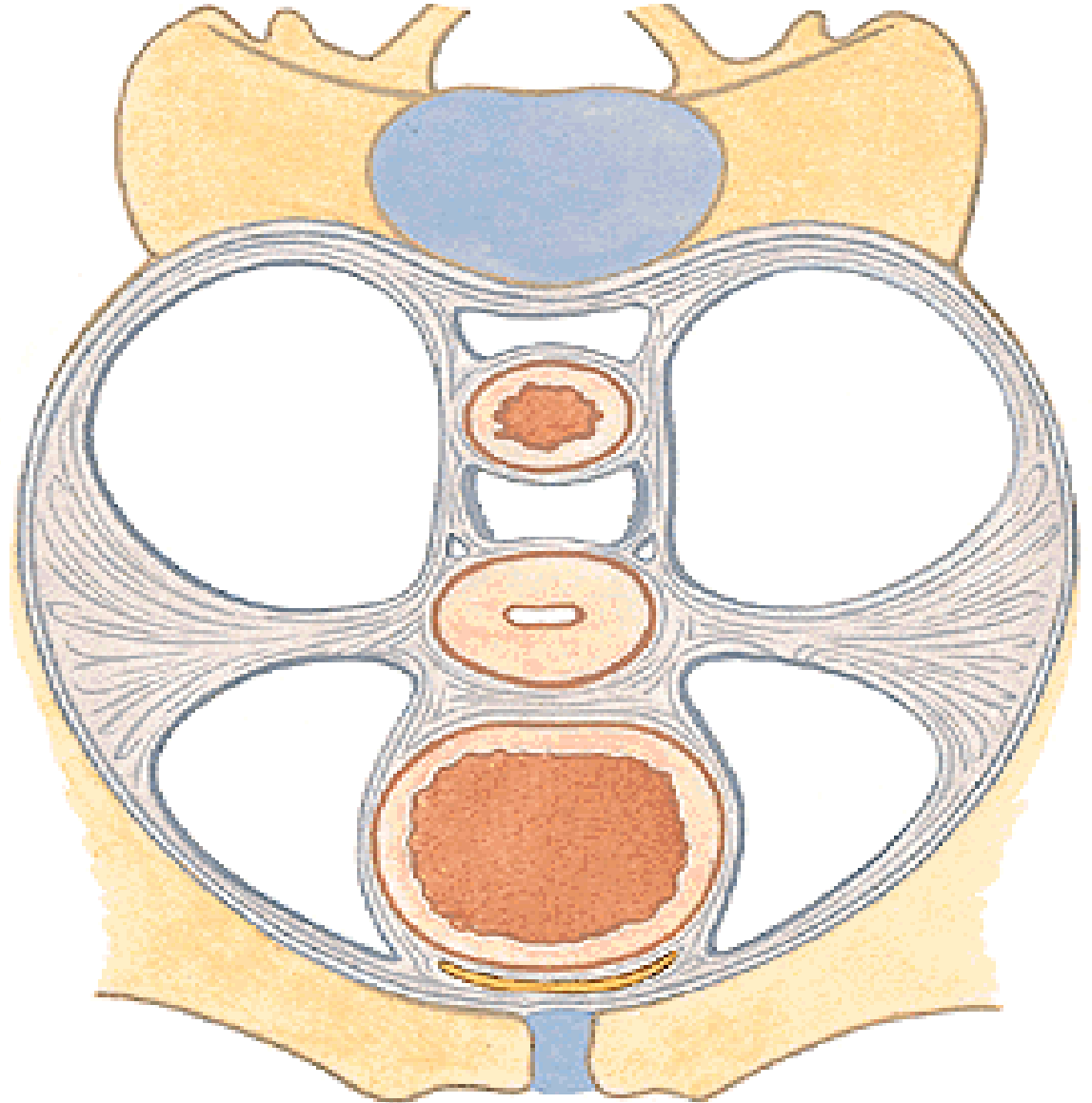
Lig. cardinale uteri

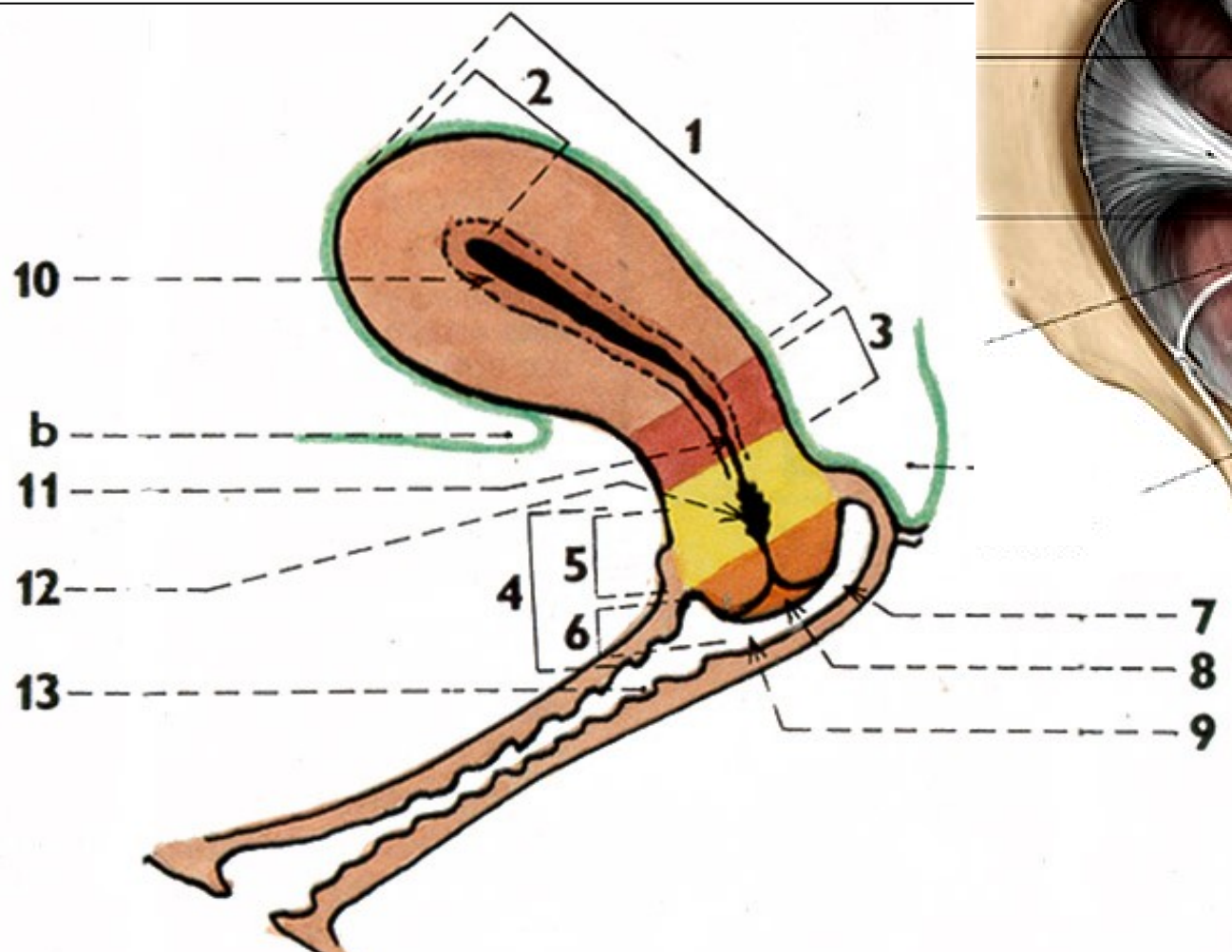
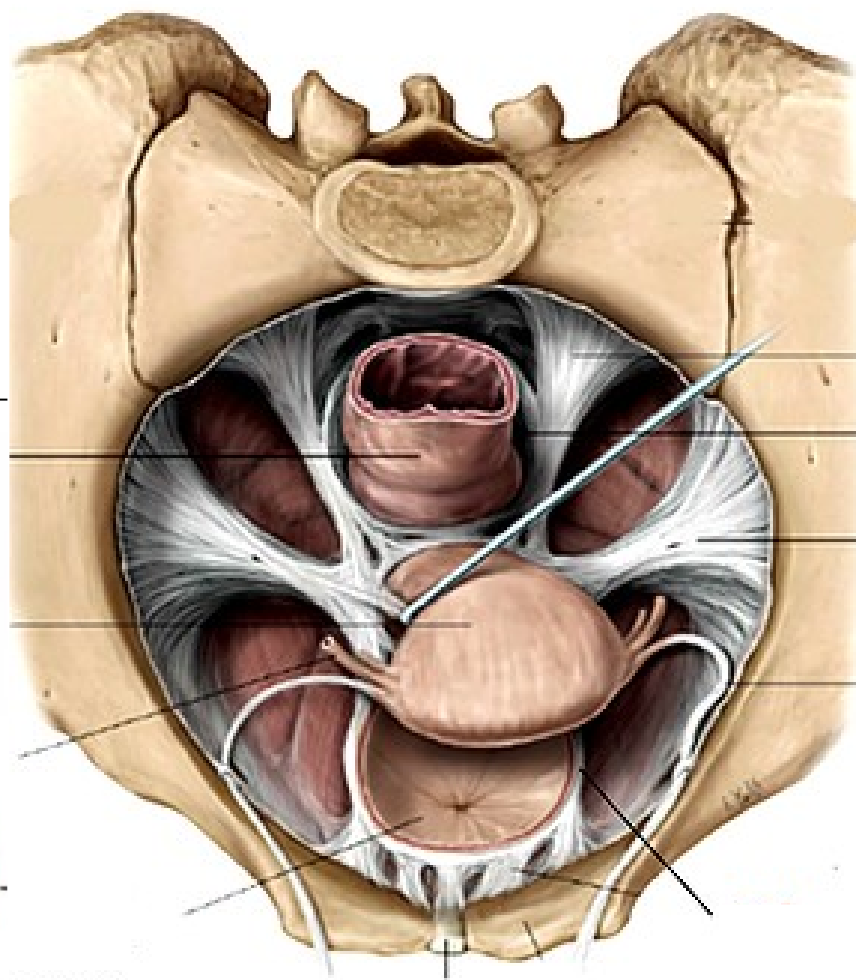
Lig. sacrouterinum

plica sacrouterina

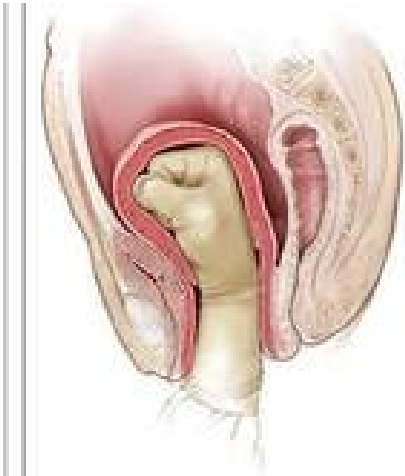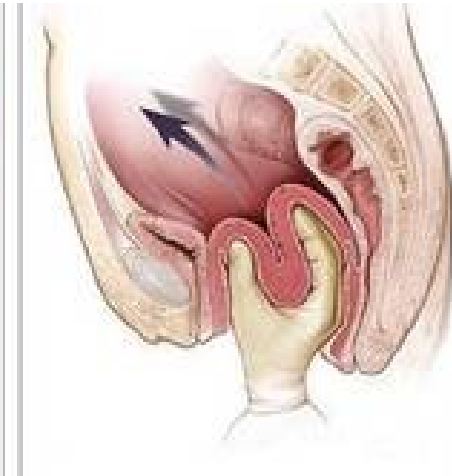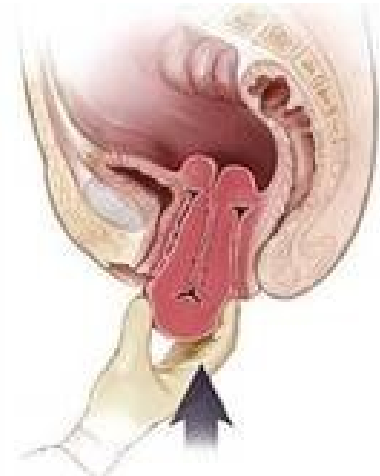
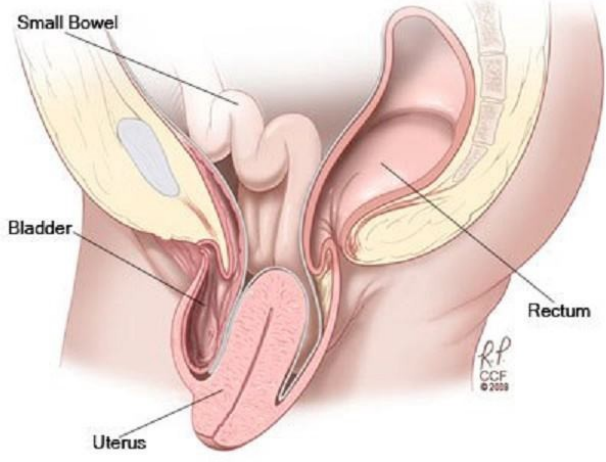
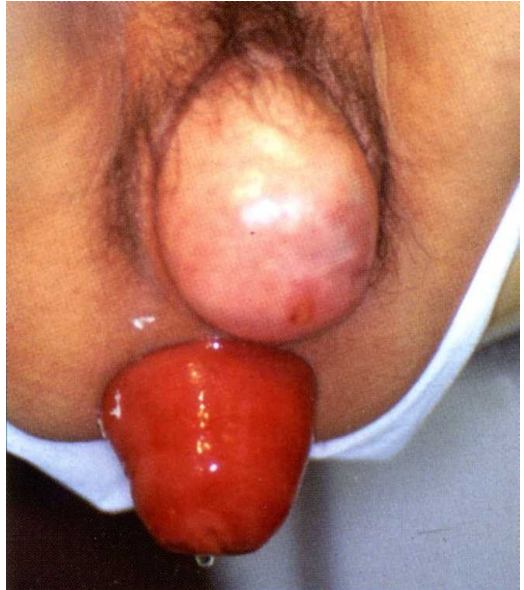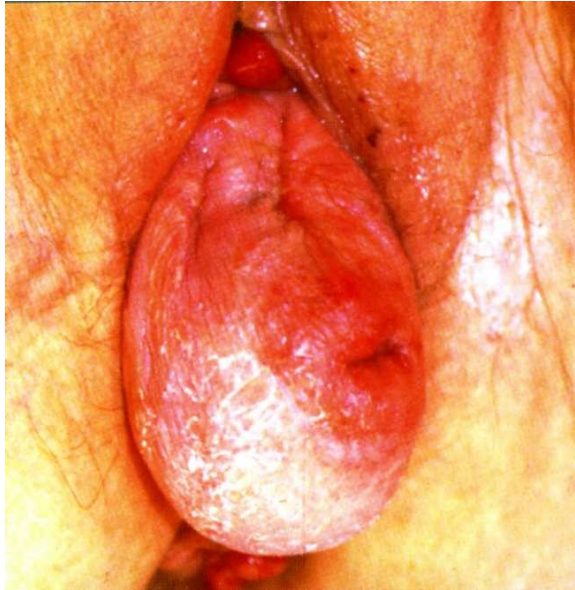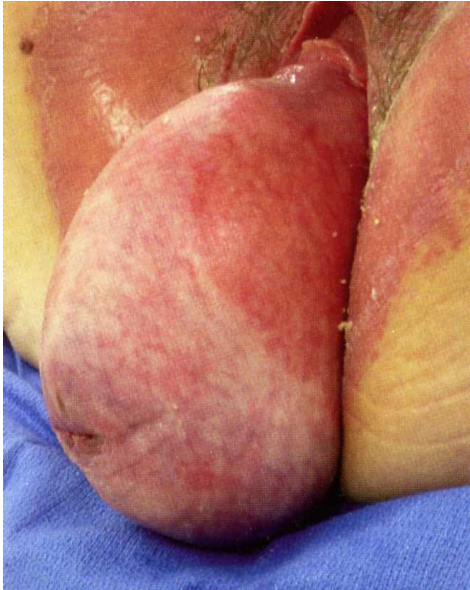m. rectouterinus

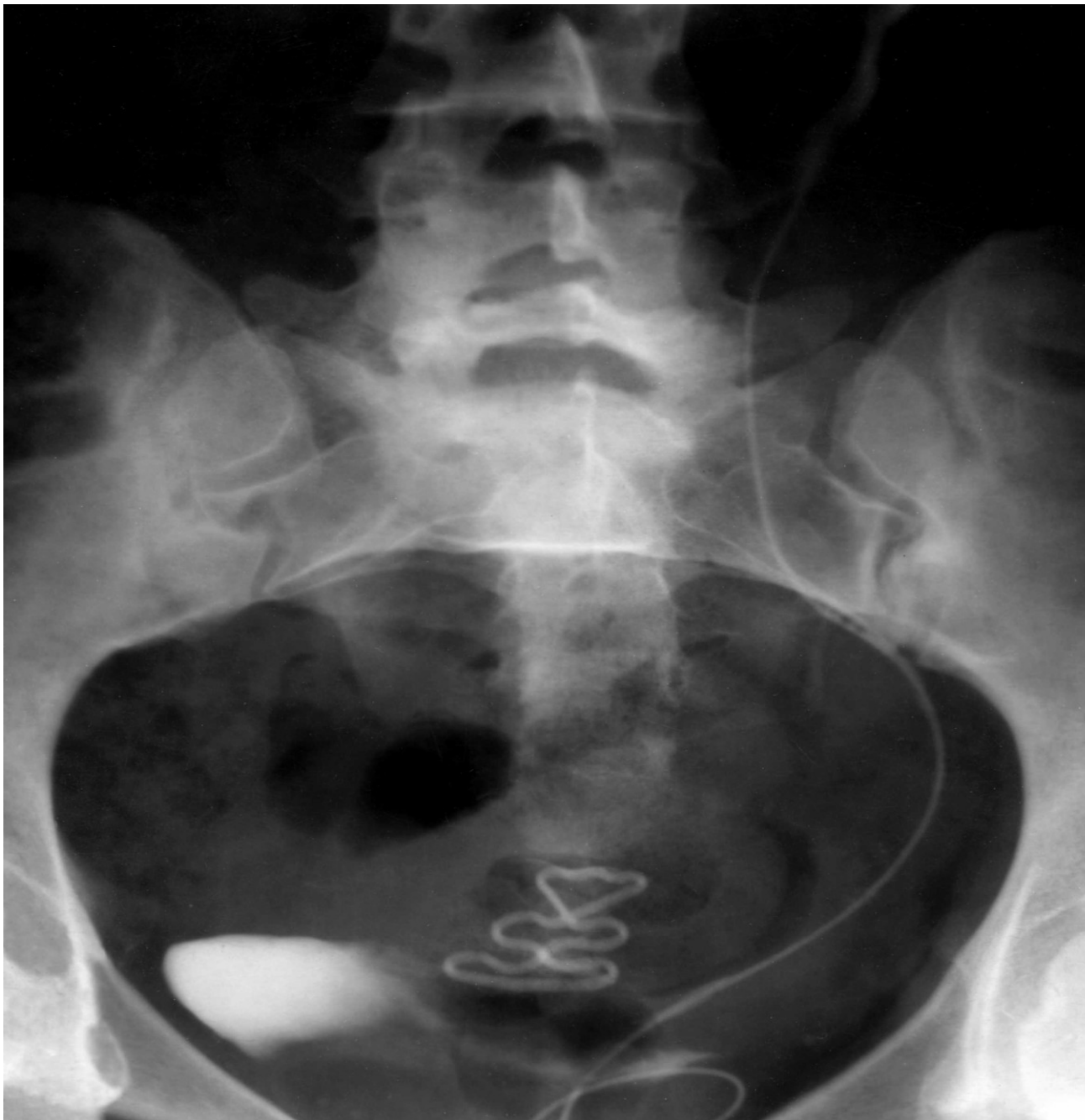Lig. teres uteri





Prolapsus





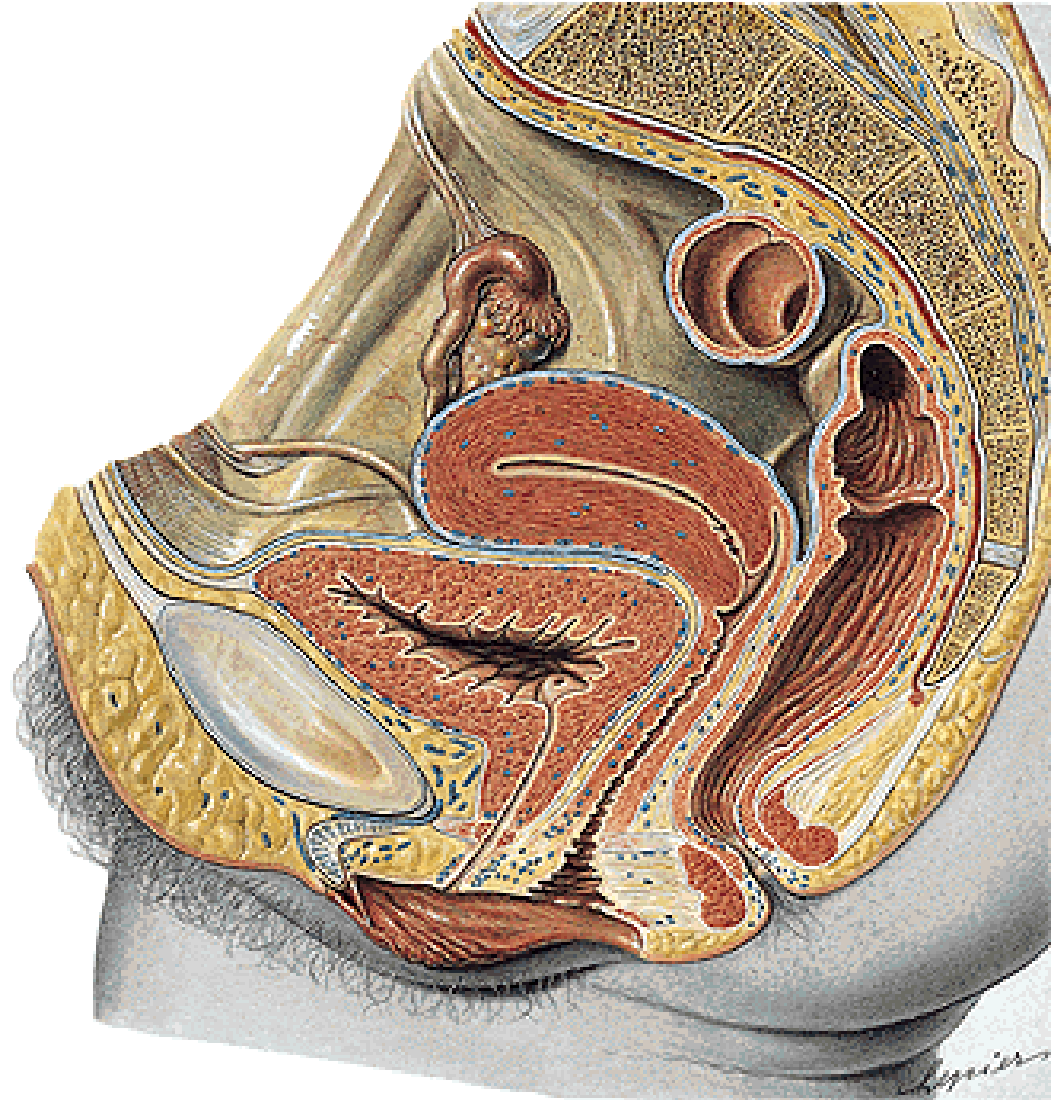
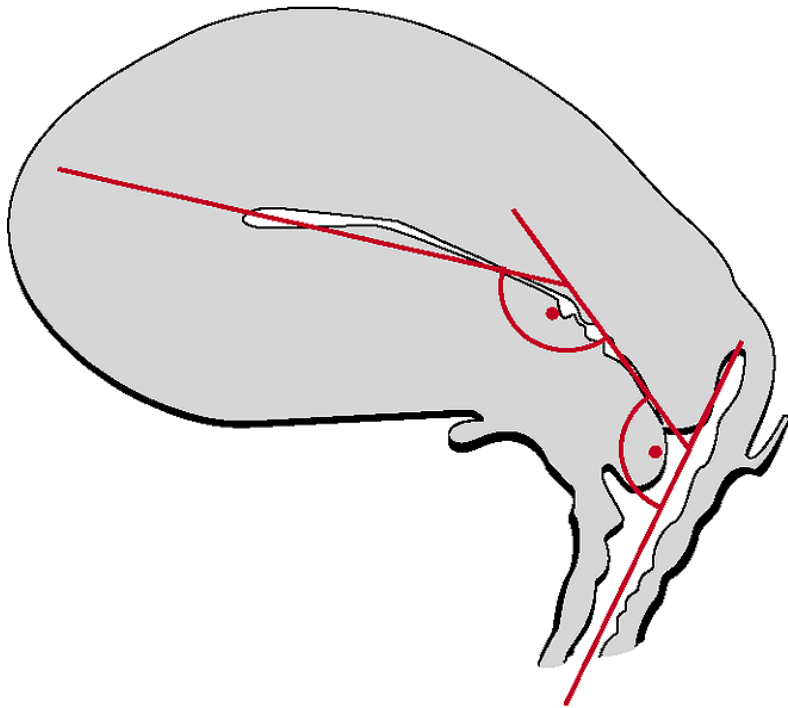
intra
uterine
corpuscle
IUC

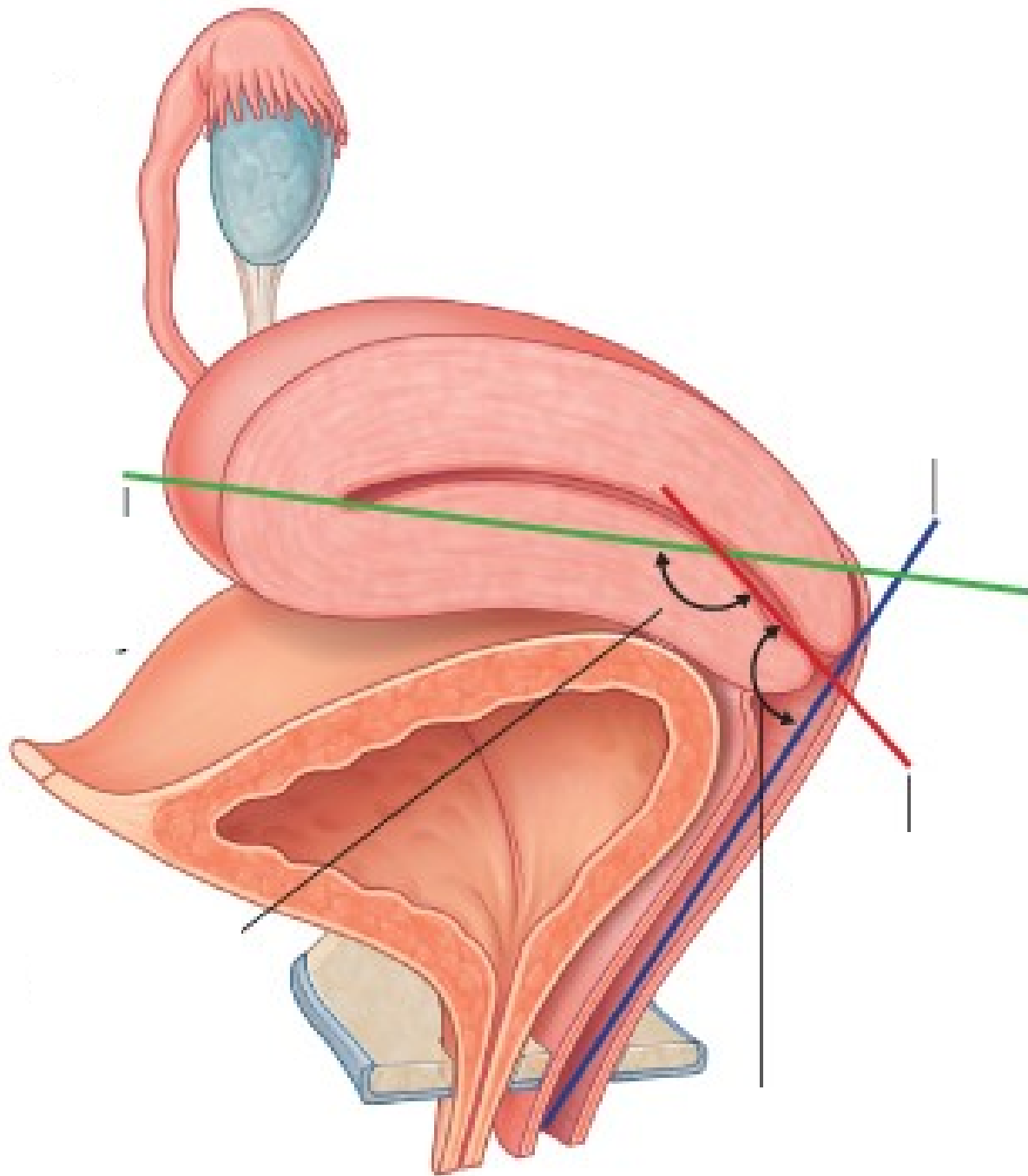
IUD
Intra
uterine
device

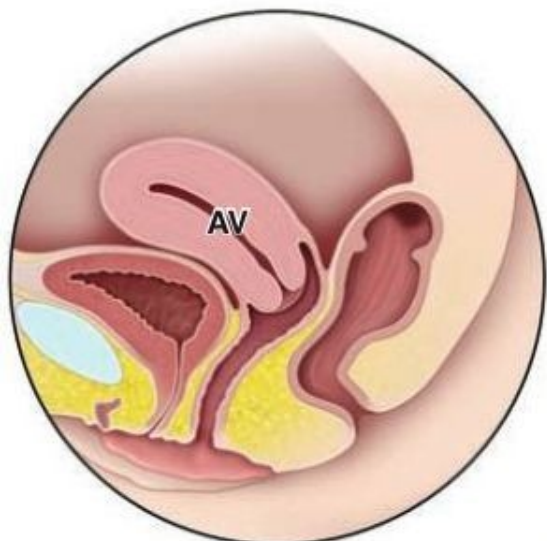POSITION OF UTERUS

Anteversión ($70^{\circ} - 100^{\circ}$)

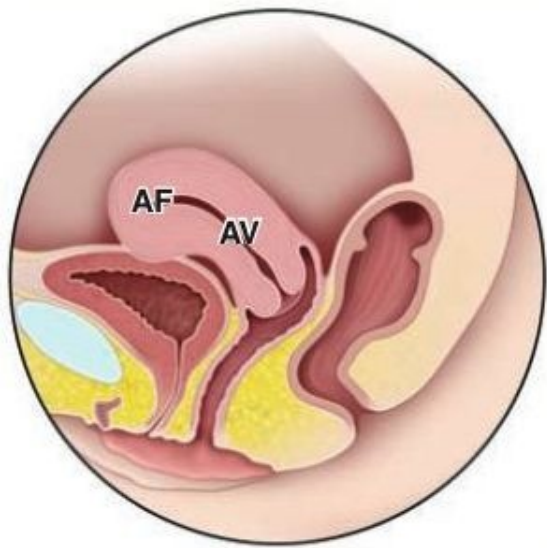
Anteflexión (100°)



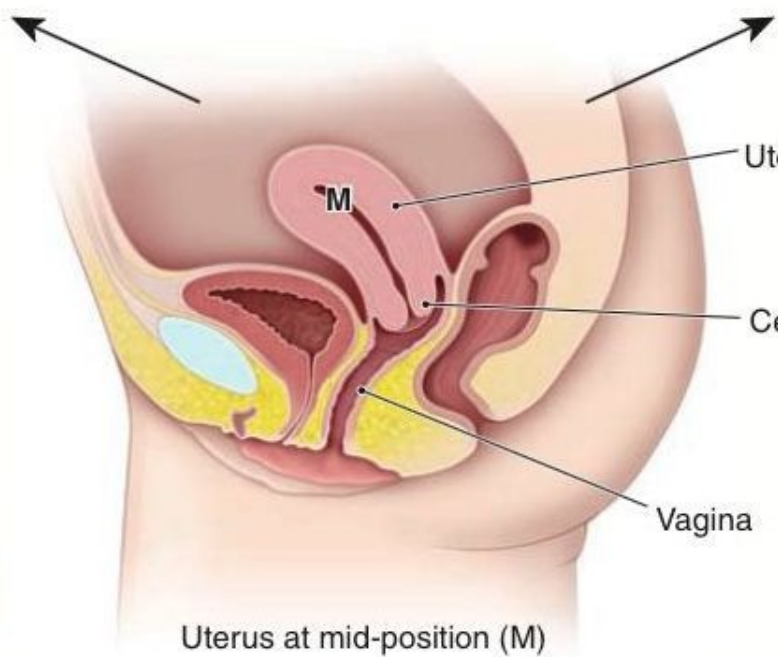




Anteverted (AV)



Anteverted (AV) and anteфлекed (AF)

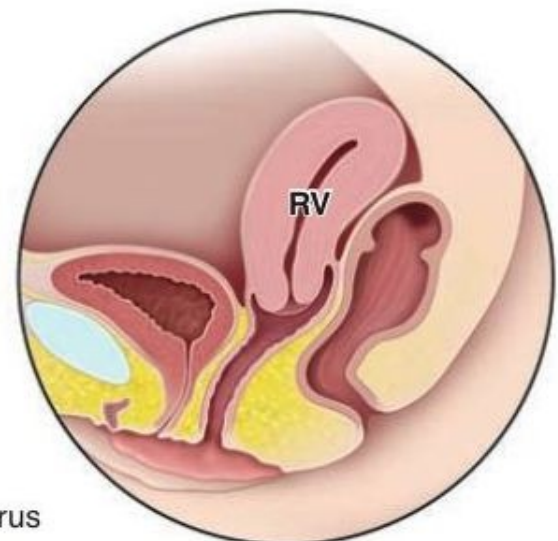


Uterus

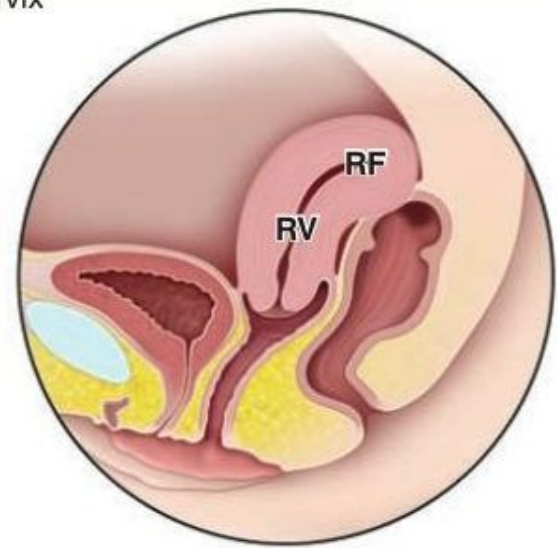
Cervix

Vagina

Uterus at mid-position (M)

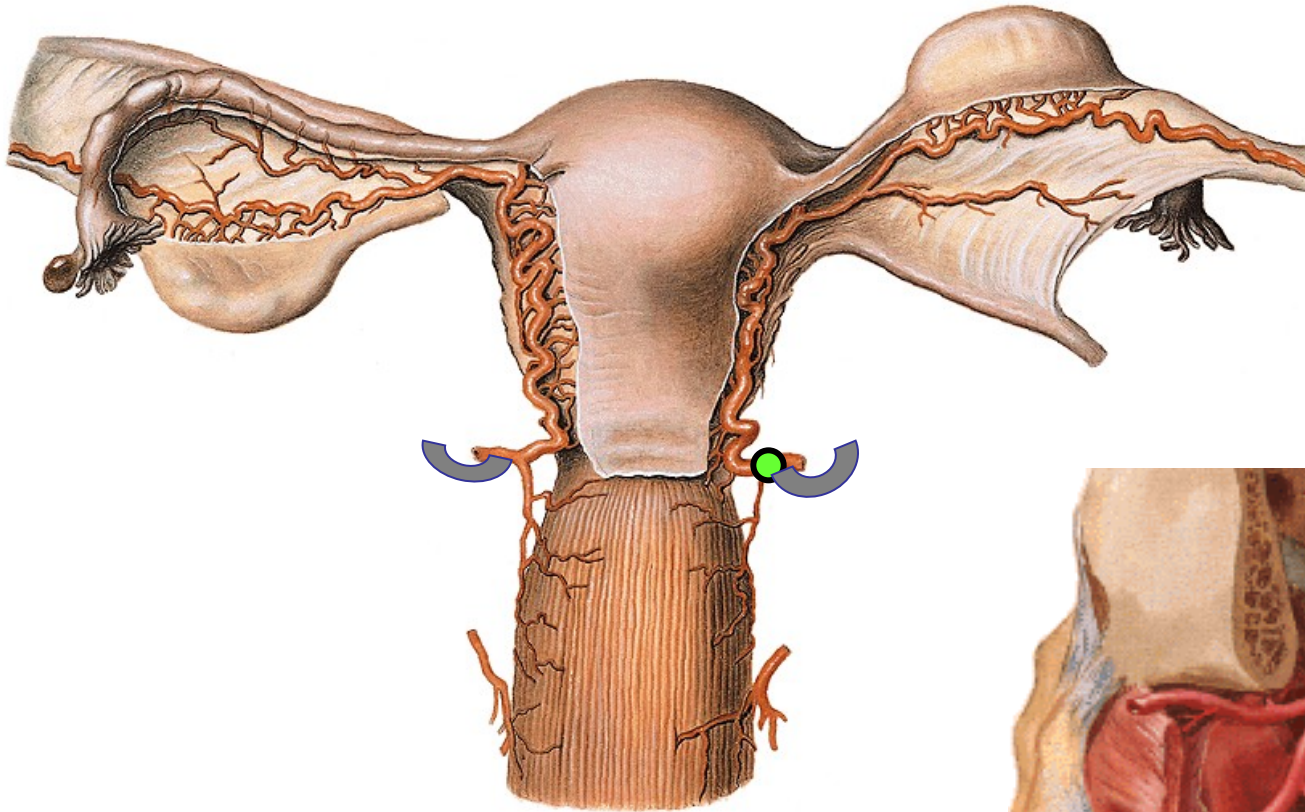


Retroverted (RV)

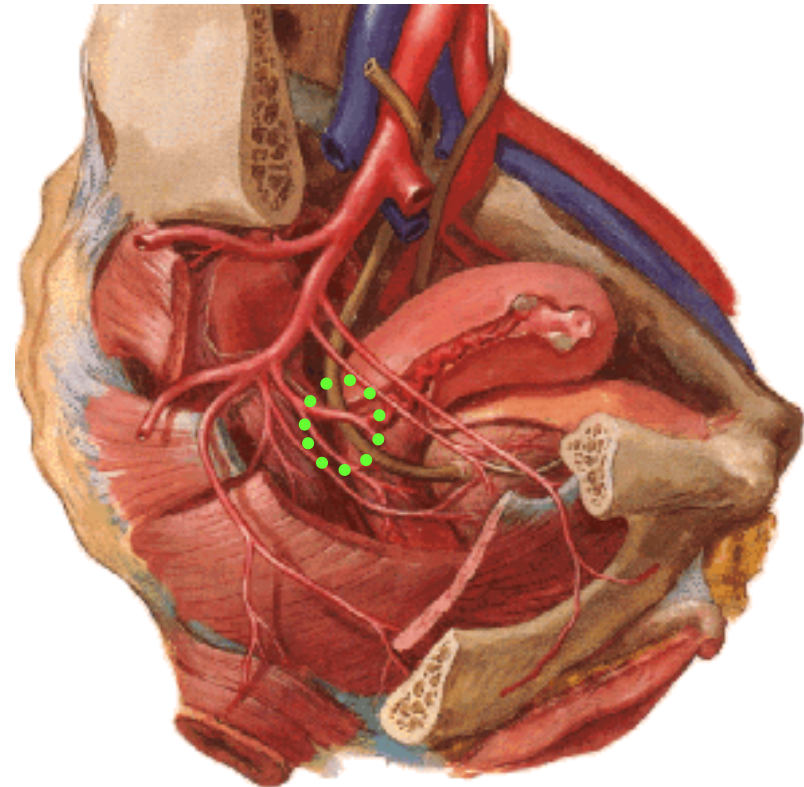


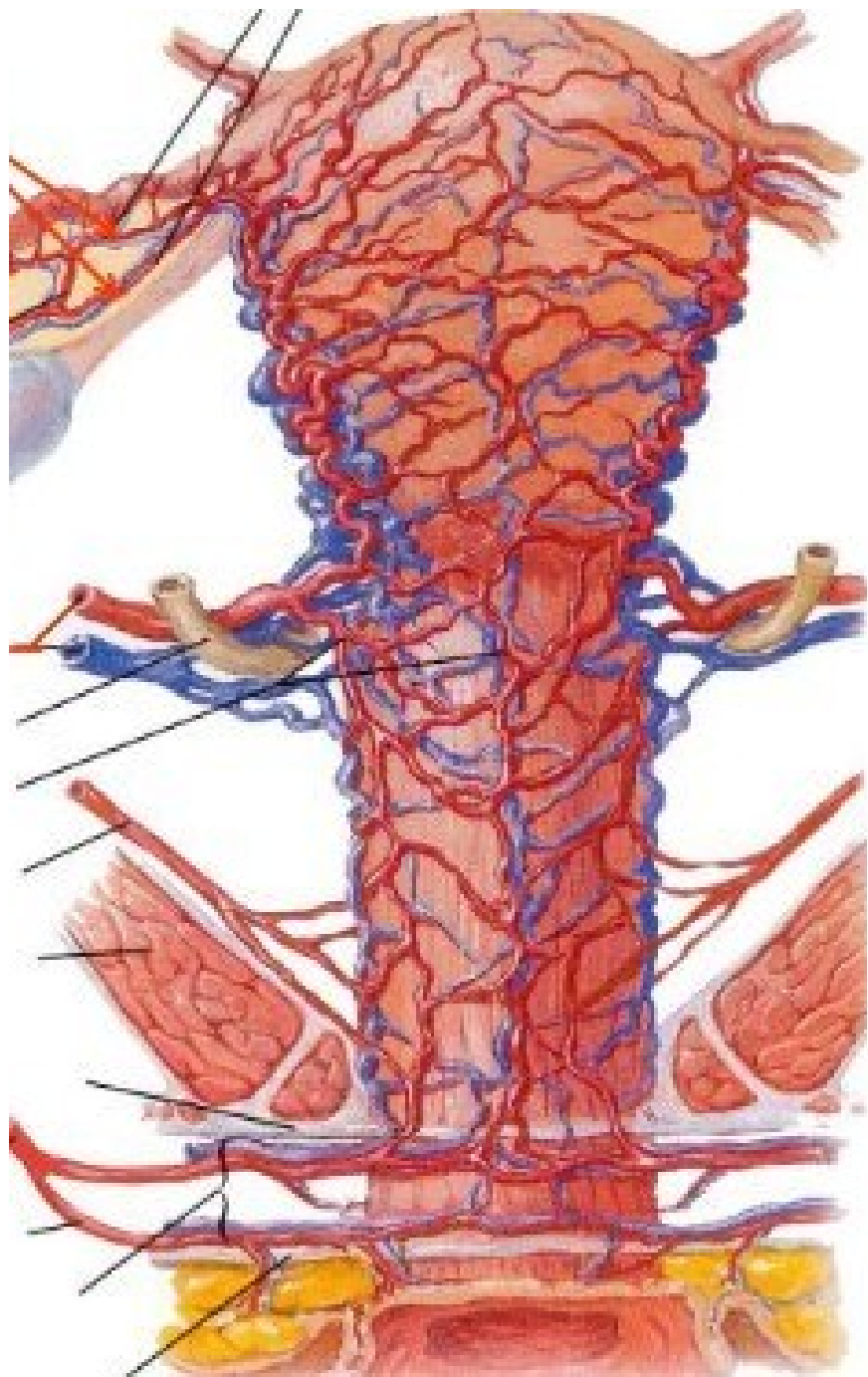
Retroverted (RV) and retroфлекed (RF)

Arteria uterina – anastomosis with a. ovarica (ovarian arcade)



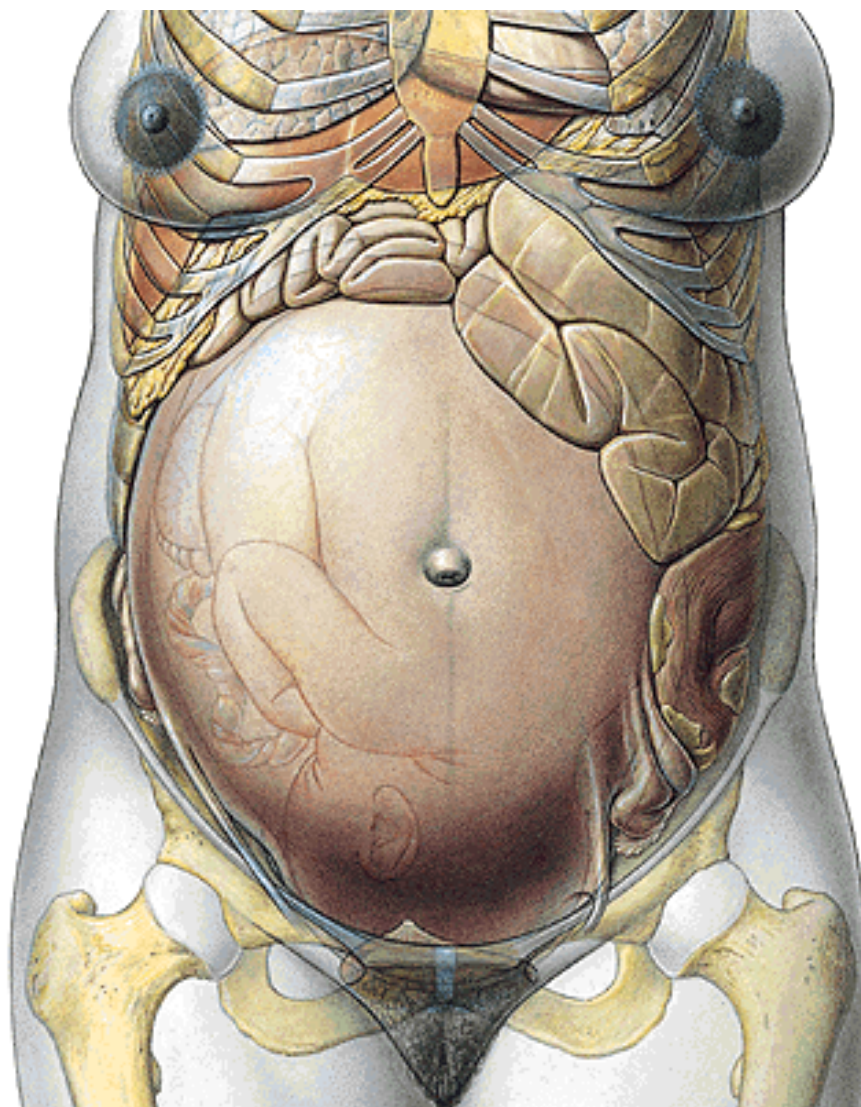
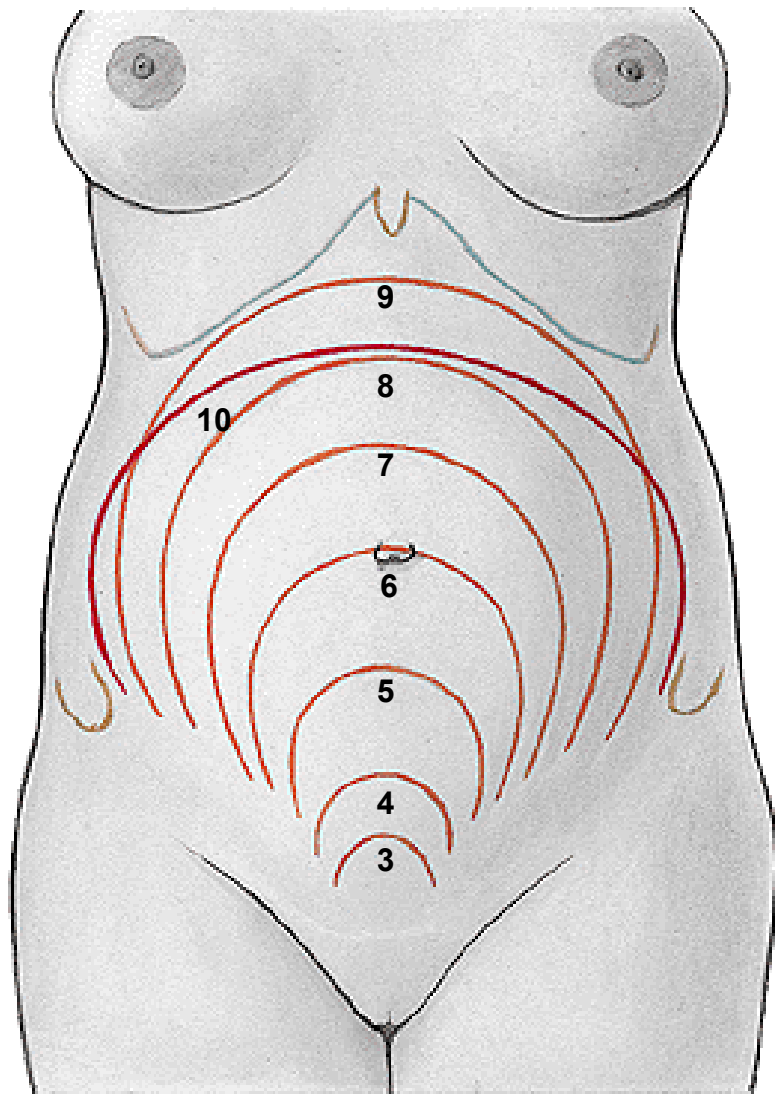
**Uterine artery crosses ureter
(2 cm from uterine margin
1,5 cm from fornix vaginae)**







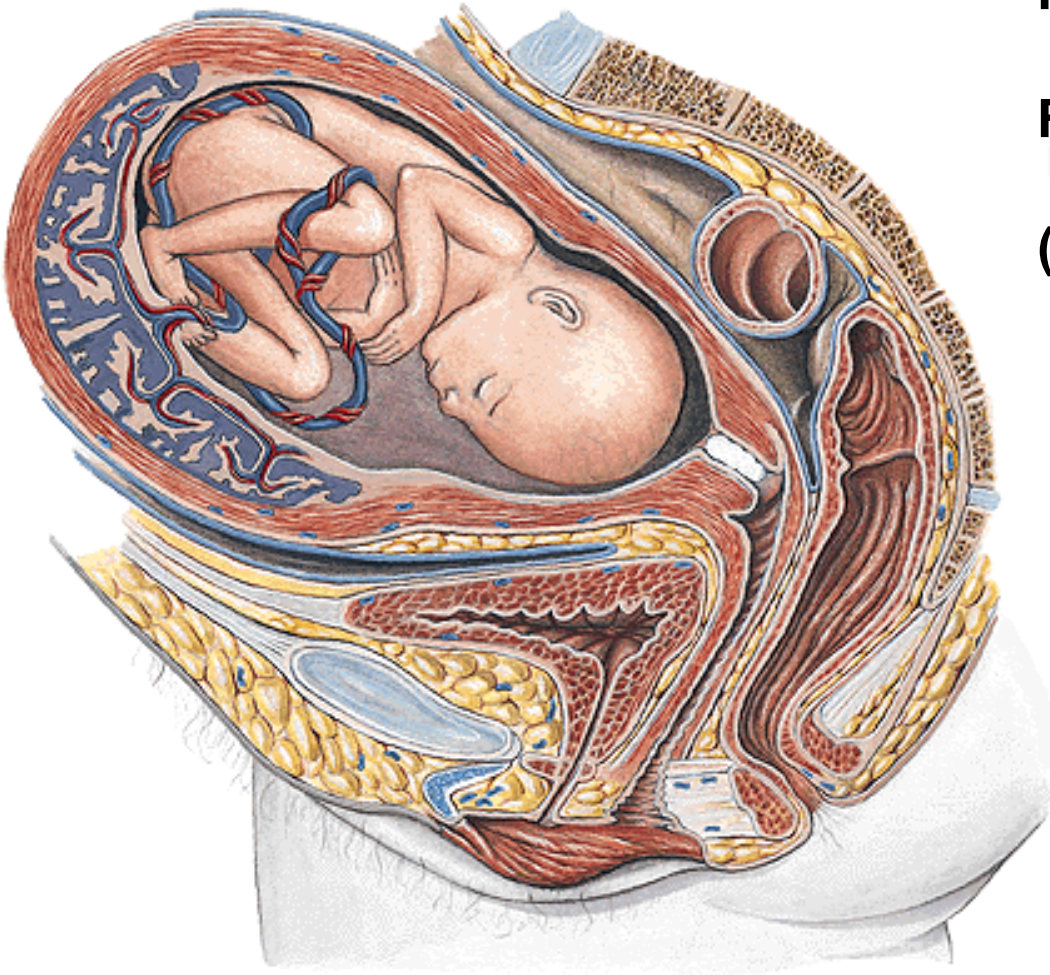GRAVIDITY



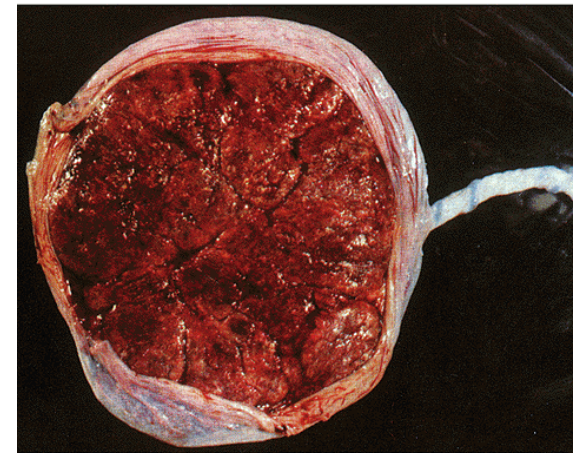
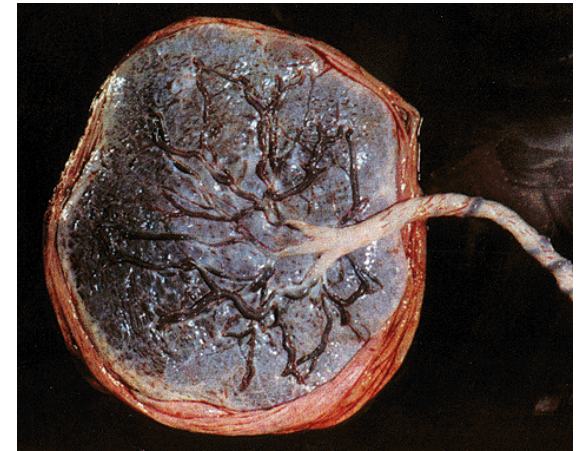Placenta

Funiculus umbilicalis – 50 cm

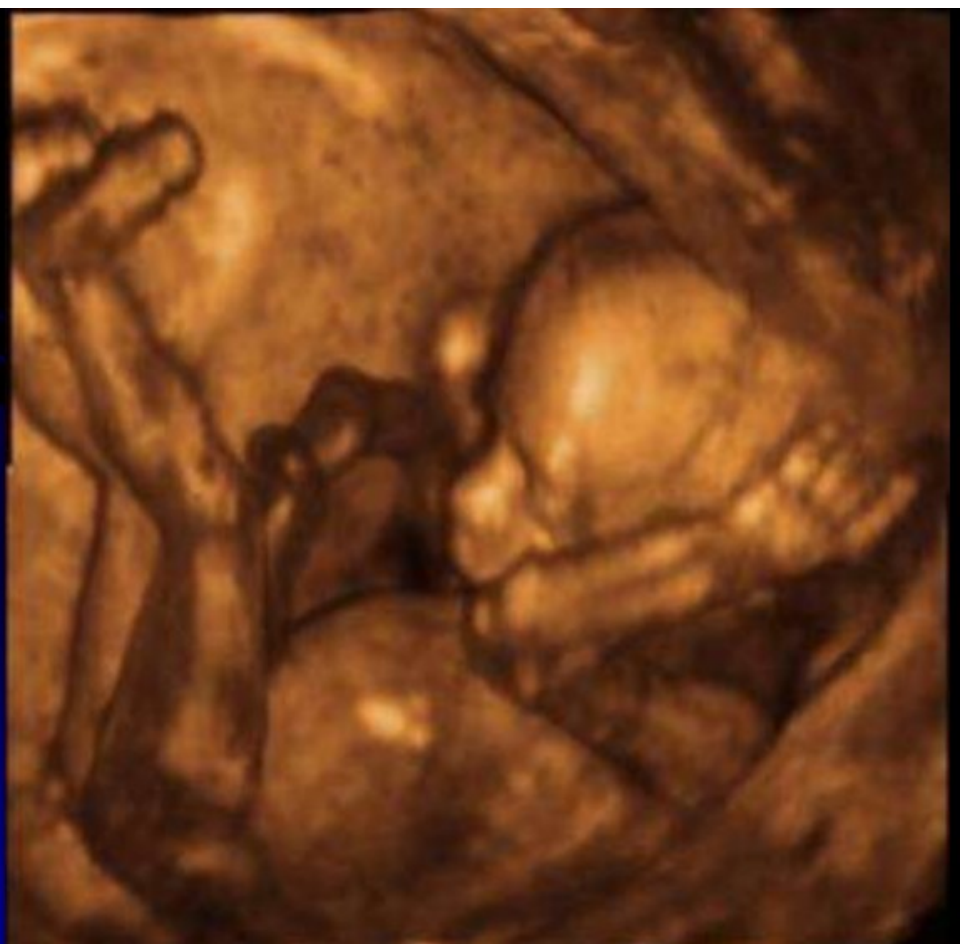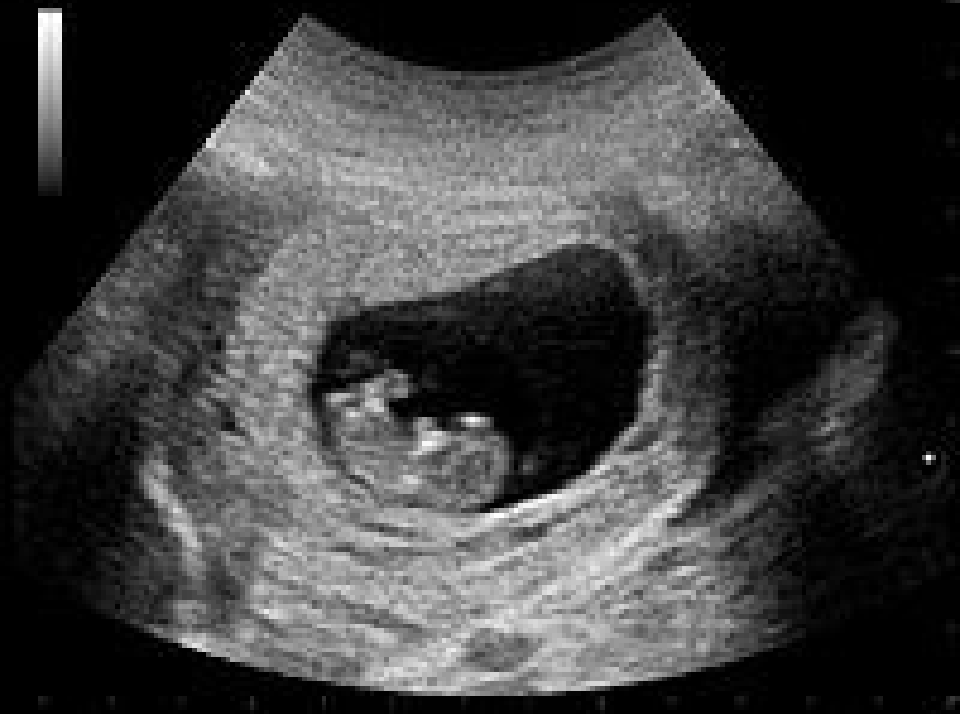(v.umbilicalis, aa. umbilicales)



uterus graviditatis – 1000 g



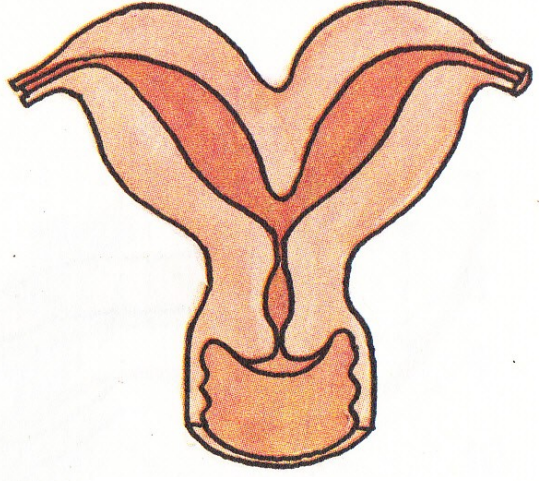
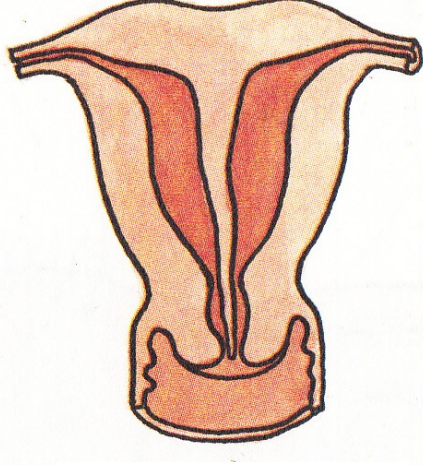
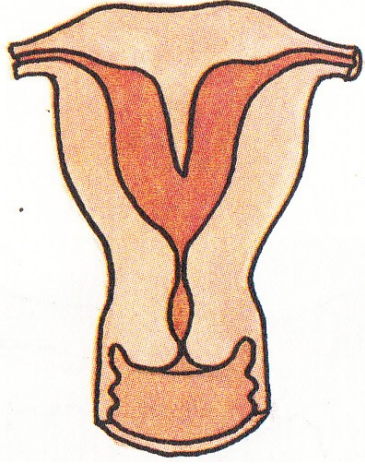
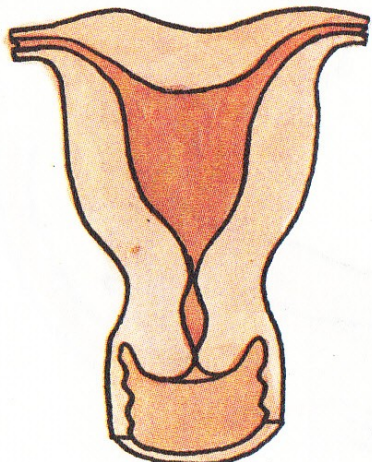
15 CM XV
PAC 11-1-8 PEE
PST 3



[https://www.youtube.com/watch?v=WH9ZJ
u4wRUE](https://www.youtube.com/watch?v=WH9ZJu4wRUE)

Brussels
manuscript
9th century



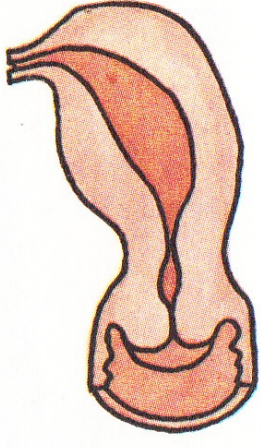
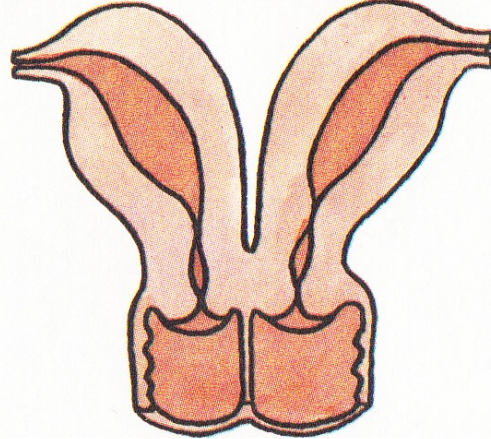
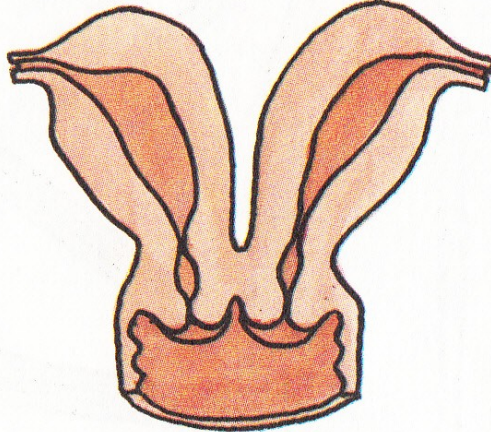
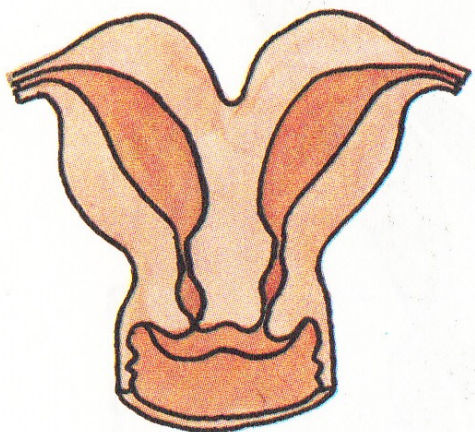


uterus arcuatus

uterus subseptus

uterus septus

uterus bipartitus



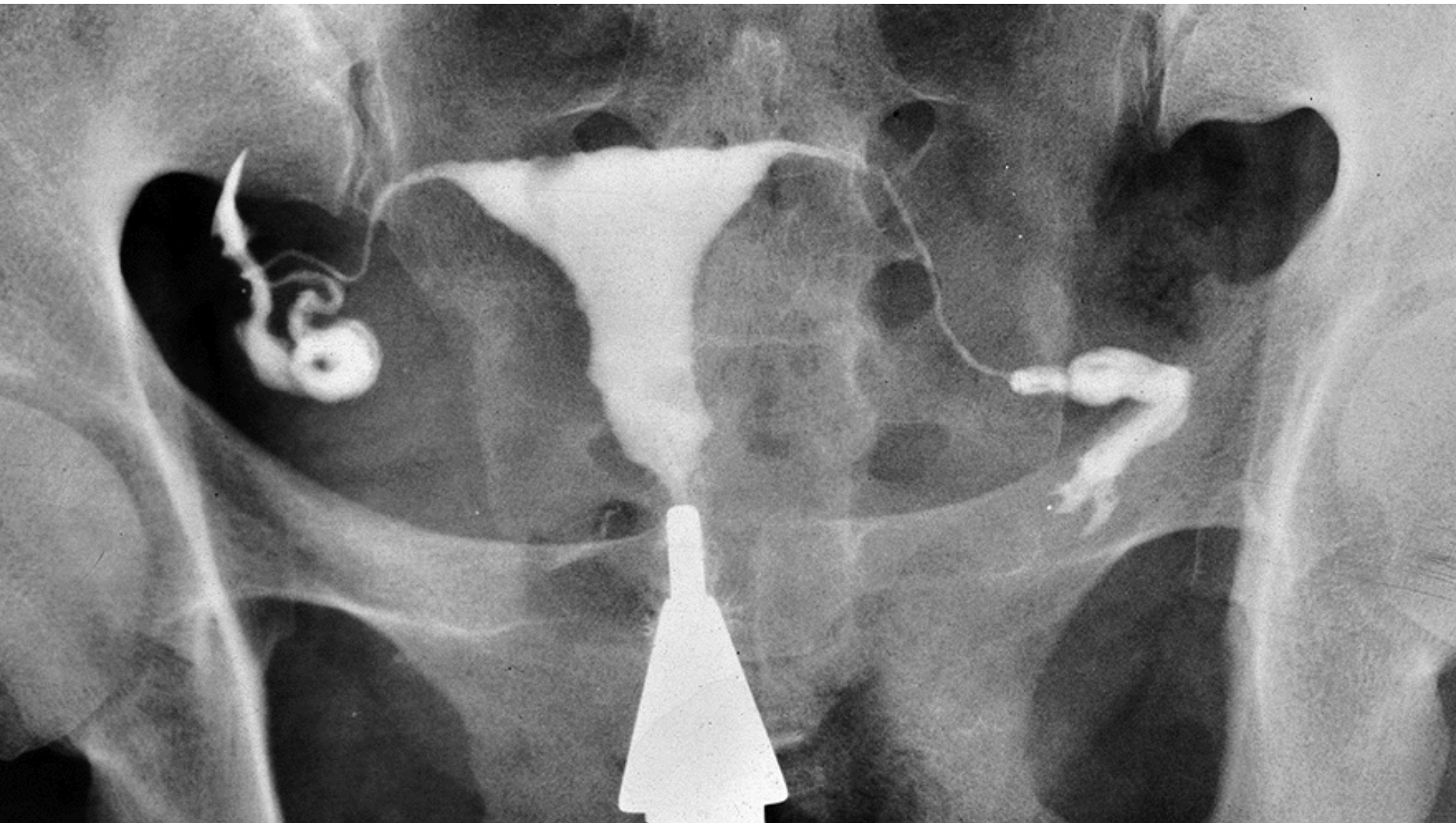
uterus duplex

uterus duplex

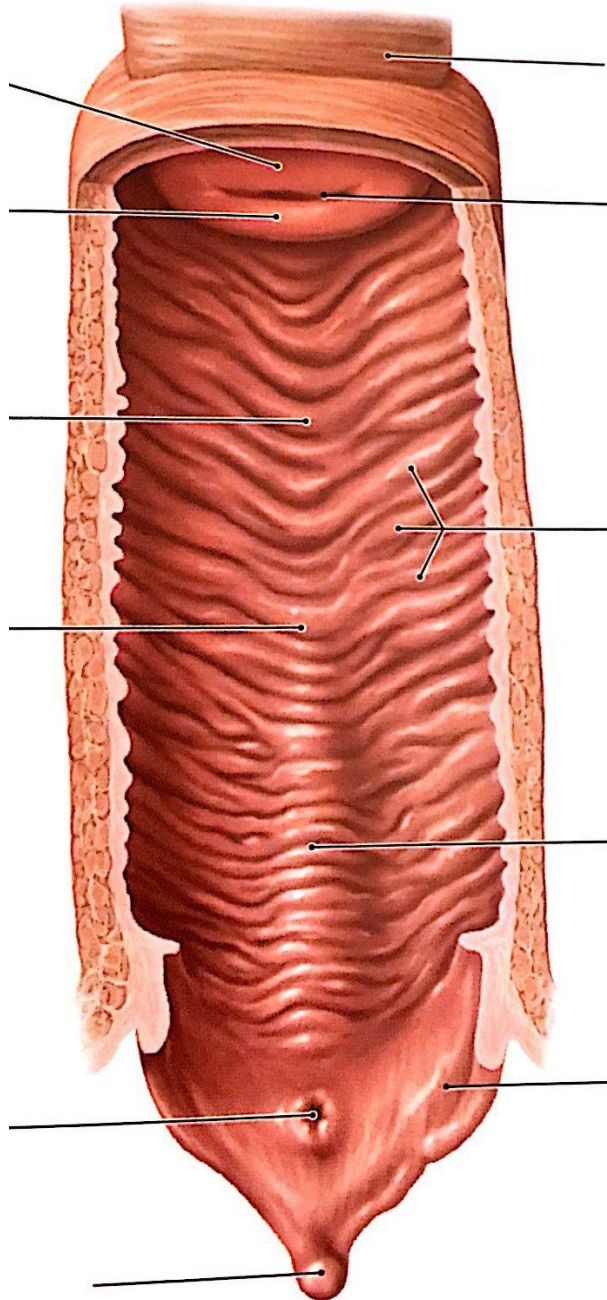
**uterus duplex
cum vagina septa**

uterus unicornis

HYSTEOSALPINGOGRAPHY



VAGINA (KOLPOS)



Fornix vaginae

pars anterior et posterior

receptaculum seminis

Paries anterior

crista urethralis

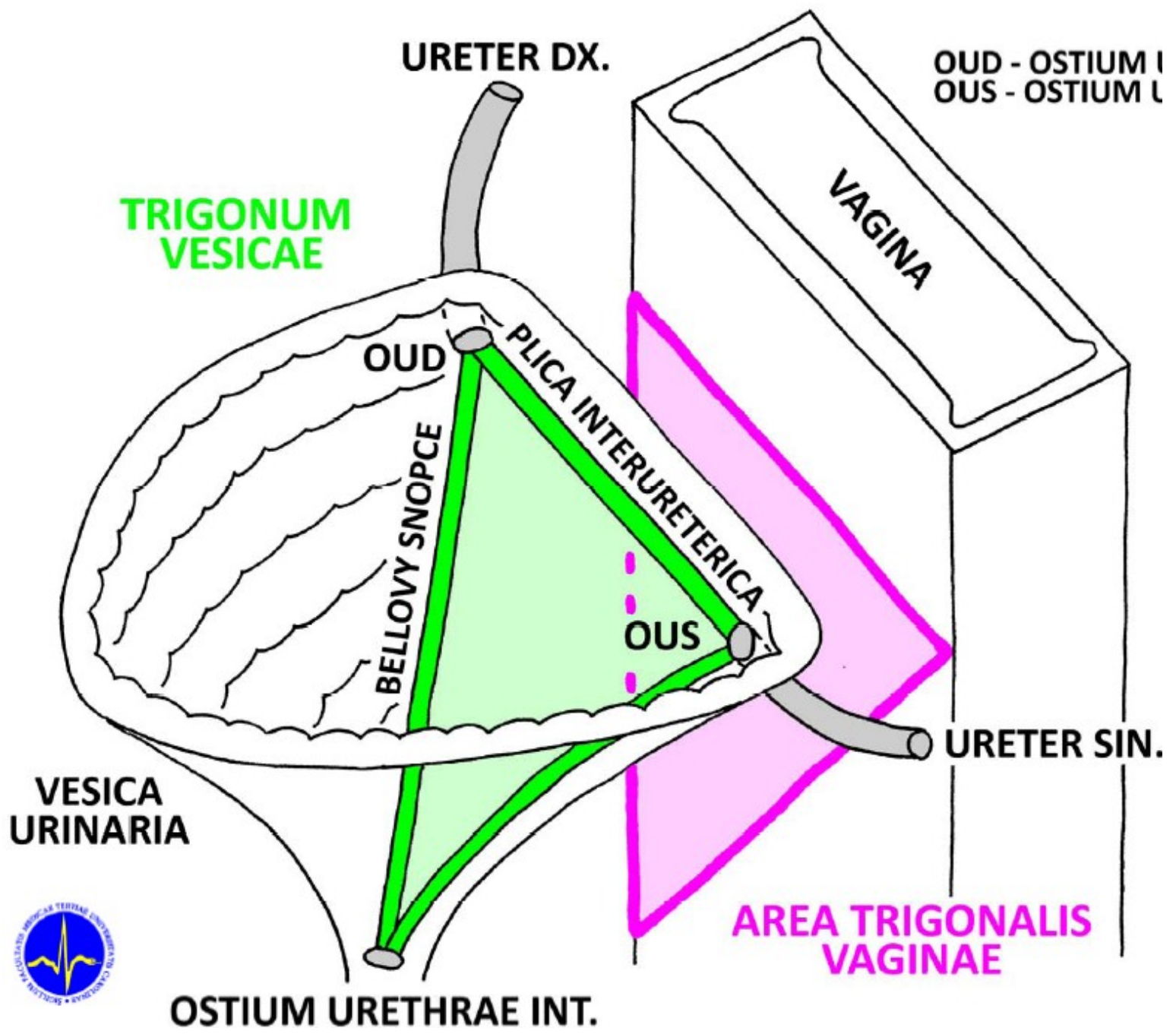
area trigonalis vaginae

Paries posterior

Rugae vaginales

Columna rugarum ant. et post.

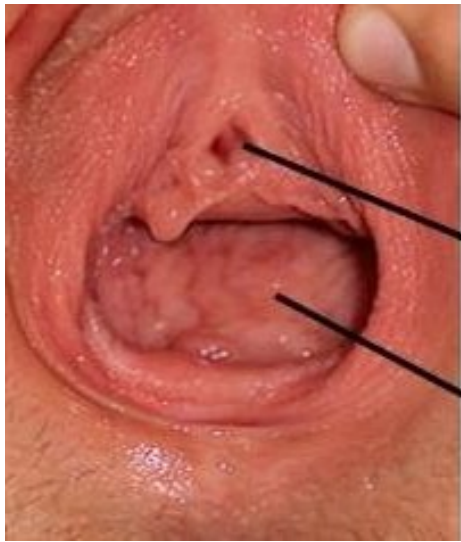**Ostium vaginae
(vestibulum vaginae)**



Ostium vaginae - hymen

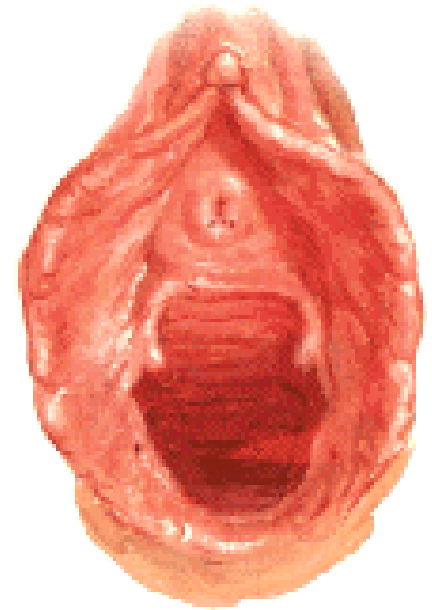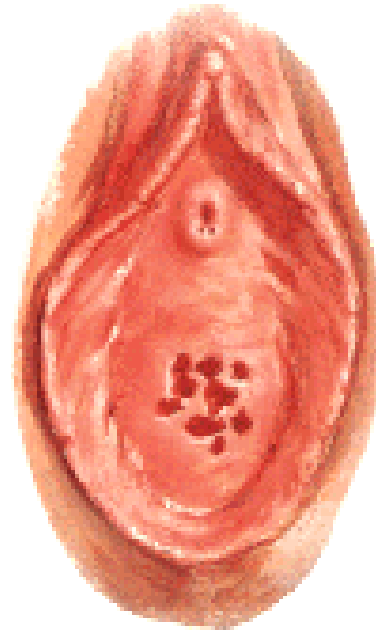
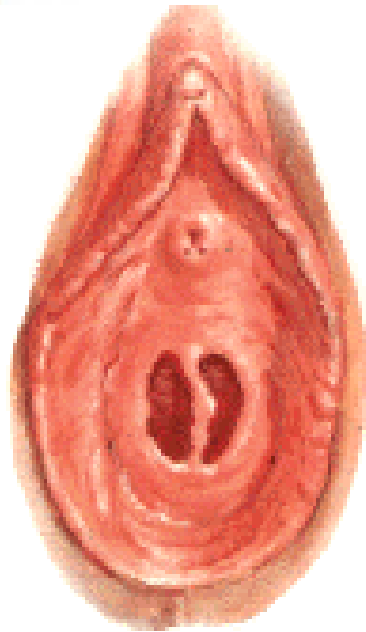
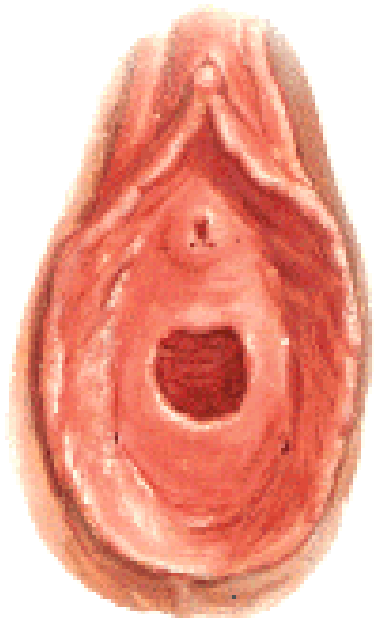
Defloration

Carunculae hymenales



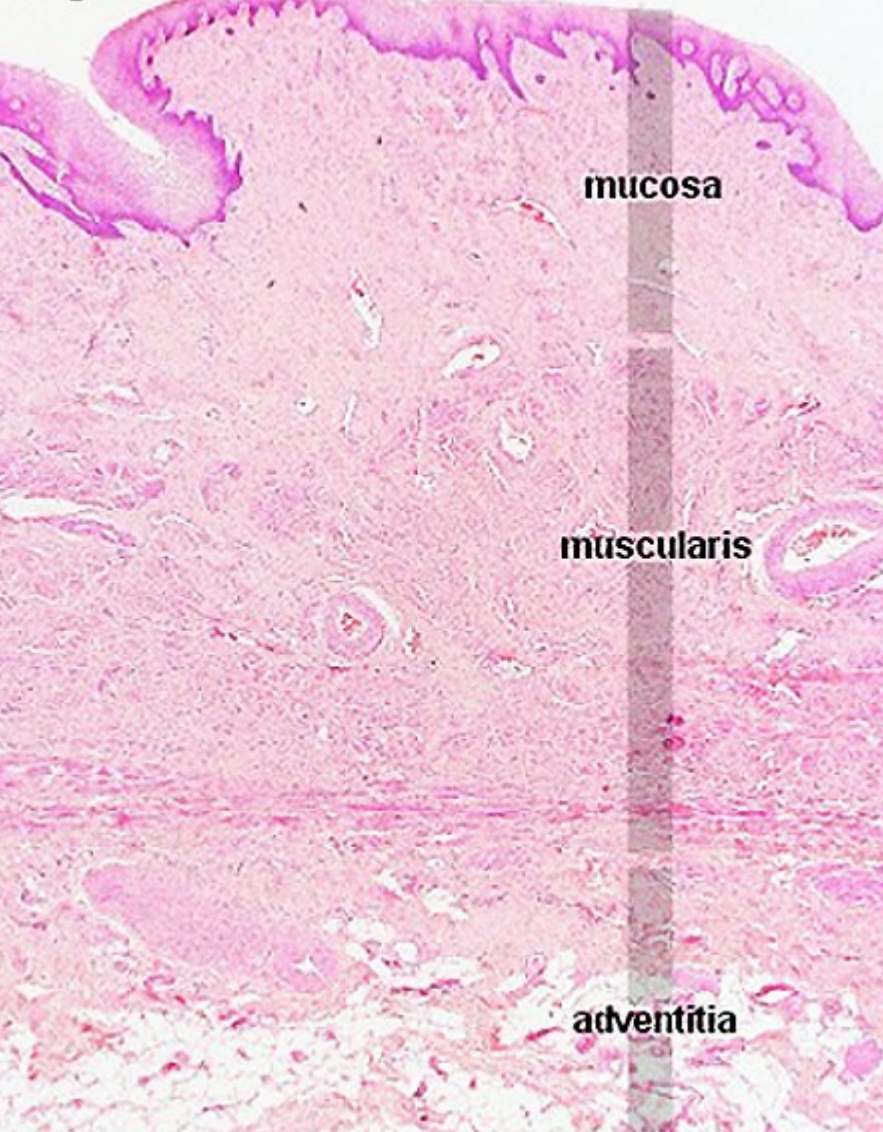
Ostium urethrae ext.

Ostium vaginae



HISTOLOGY OF VAGINA

Vagina H&E



Mucouse membrane

Multilayer squamous epithelium

No glands !!!

submucouse tissue – venous net

Muscular layer

inner - circular

outer - longitudinal

Adventicia

Serosa – excavatio rectouterina

POSITION OF VAGINA

Ventrocaudal direction

Ventrally:

urinary bladder

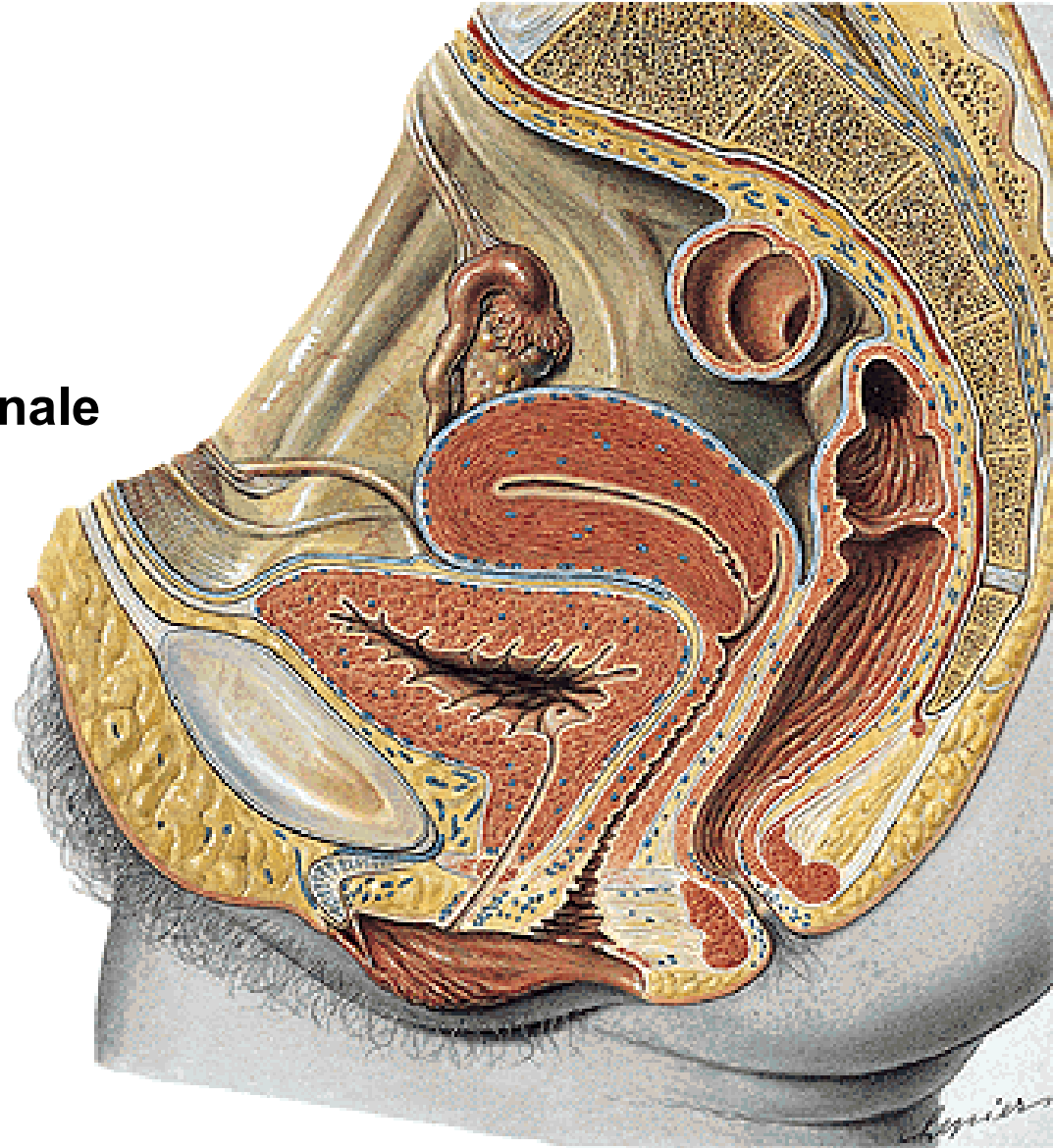
urethra - septum urethrovaginale

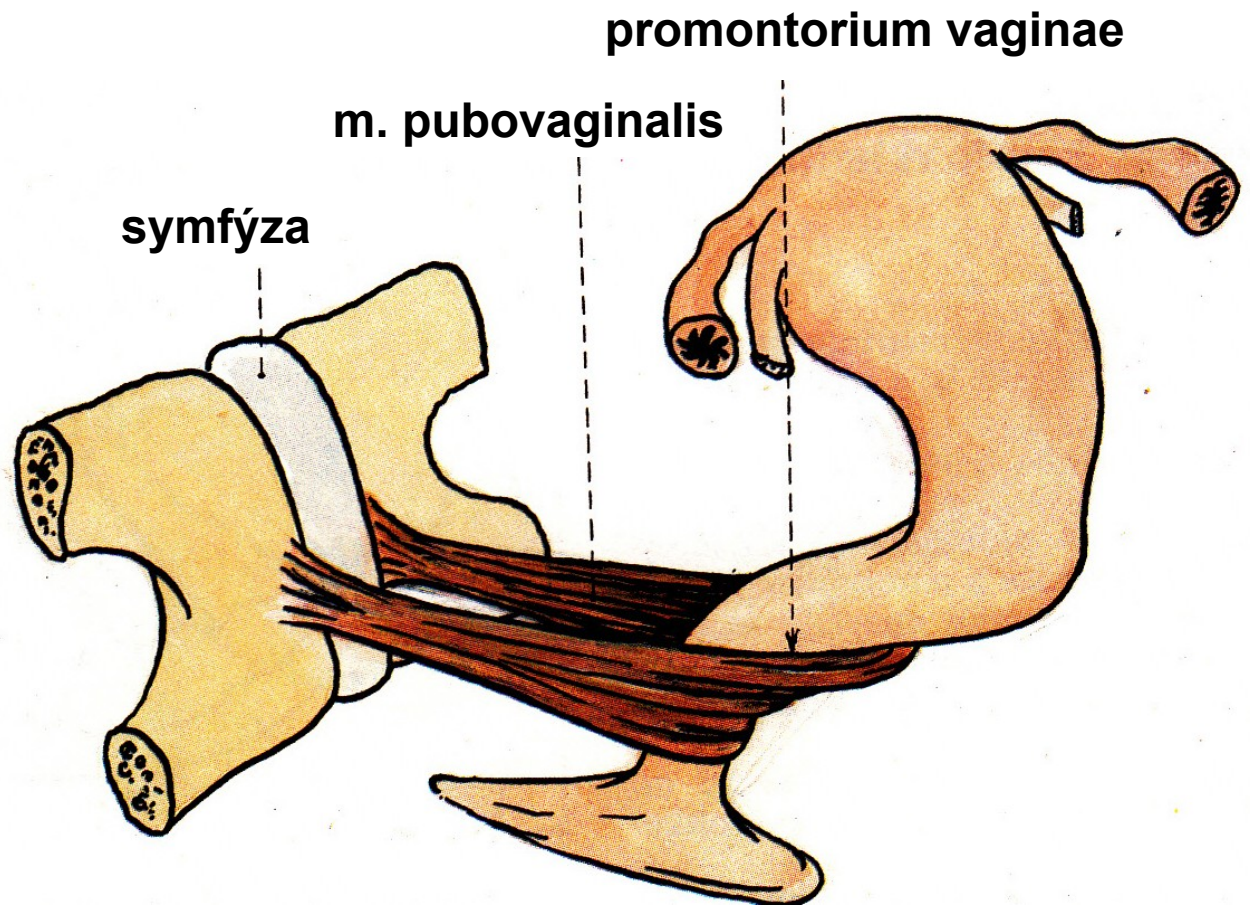
Dorsally:

excavatio rectouterina

rectum - septum rectovaginale

centrum perineale

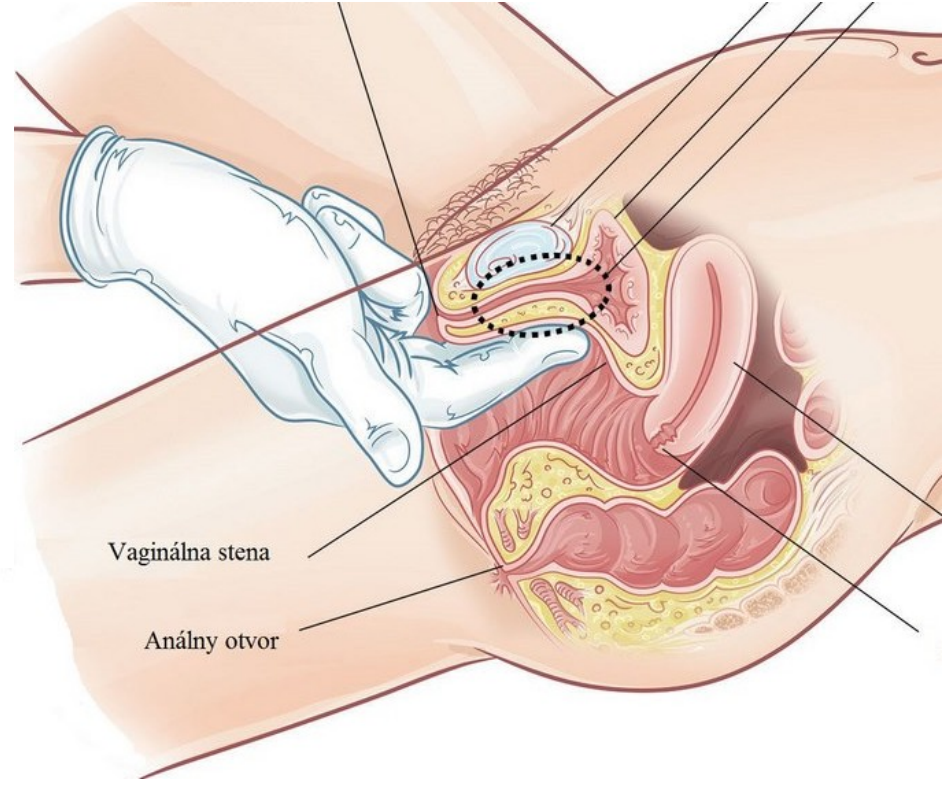
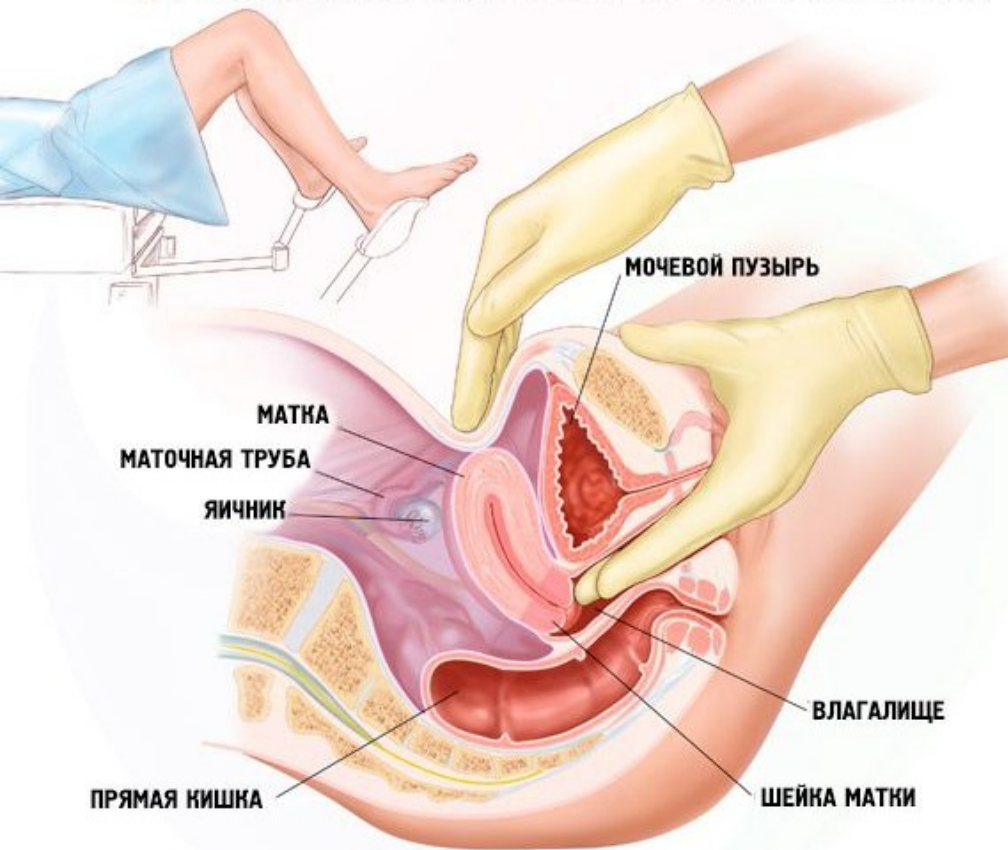




promontorium vaginae

m. pubovaginalis

symfýza



Organa genitalia feminina externa

Labia majora pudendi

Labia minora pudendi

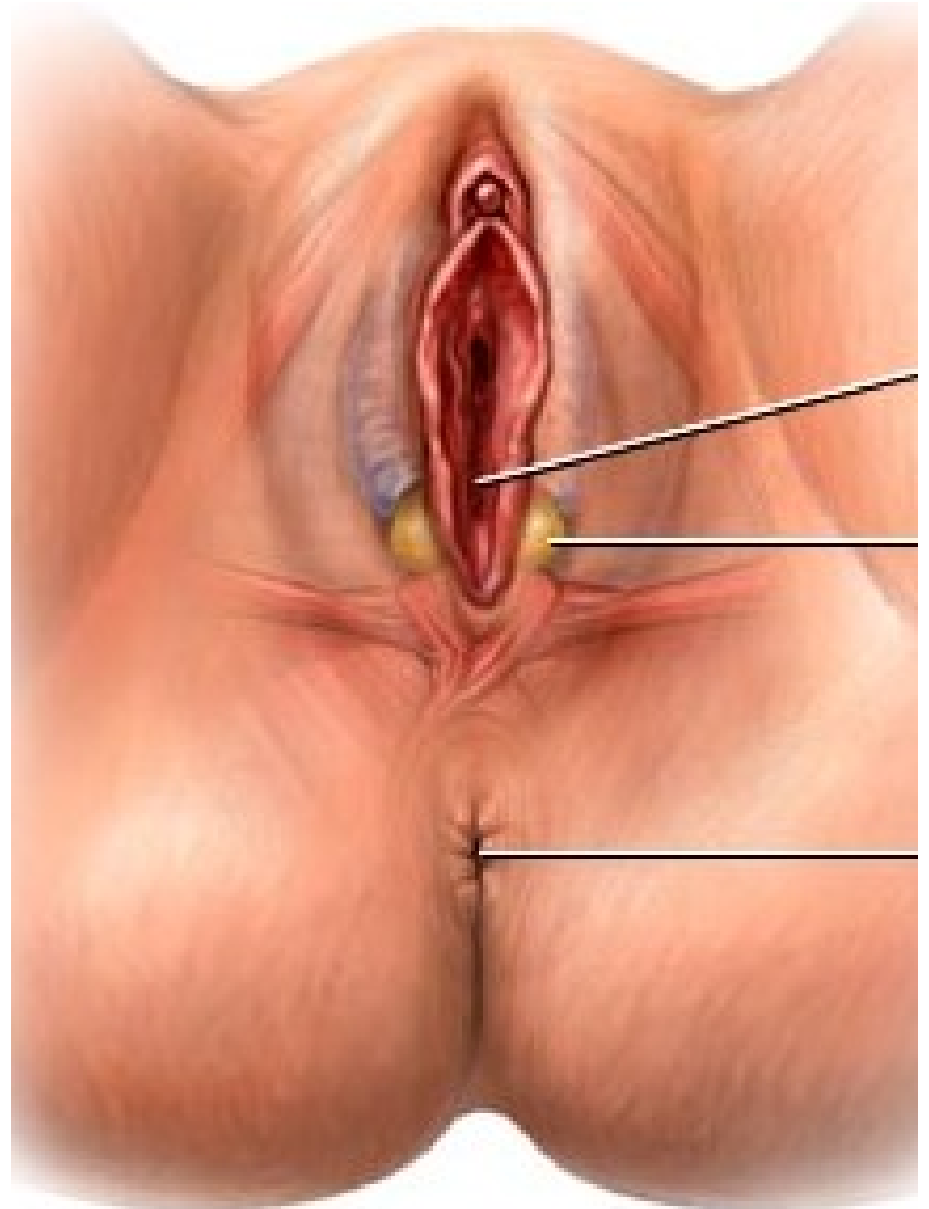
Mons pubis

Vestibulum vaginae

Clitoris

Glandulae vestibulares

Bulbus vestibuli



Labia majora pudendi

Sulcus genitofemoralis

Rima pudendi

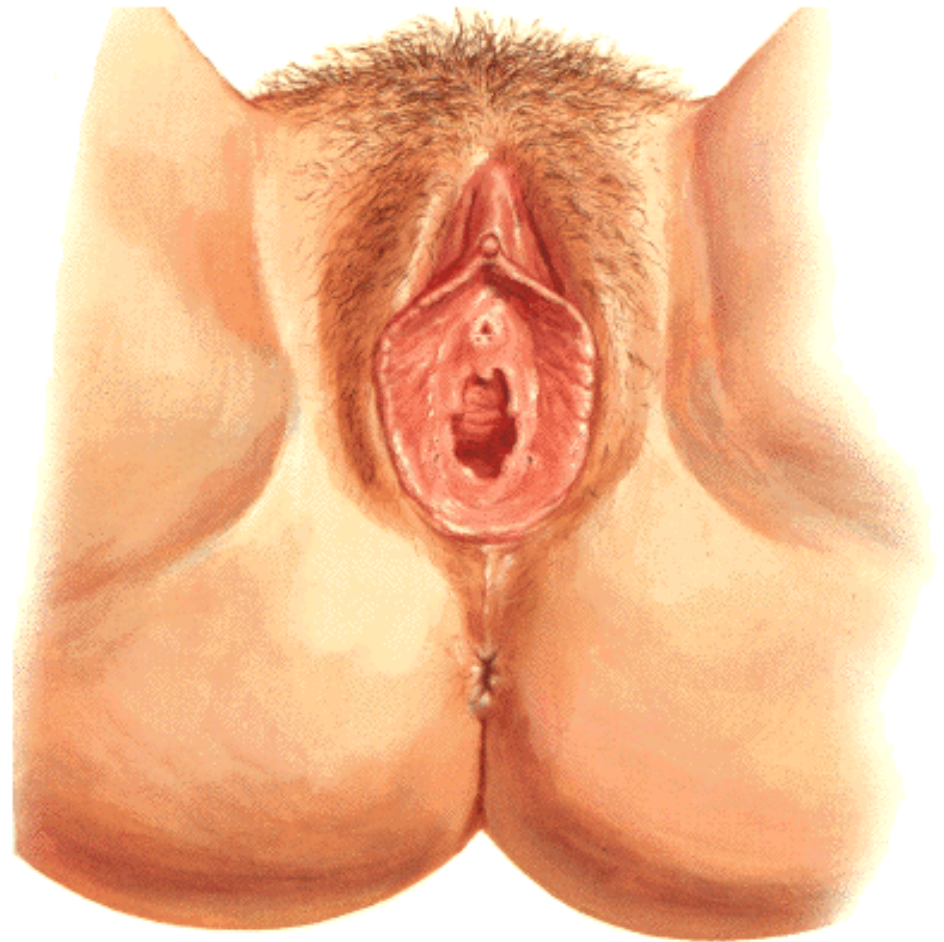Commissura labiorum ant.

Mons pubis

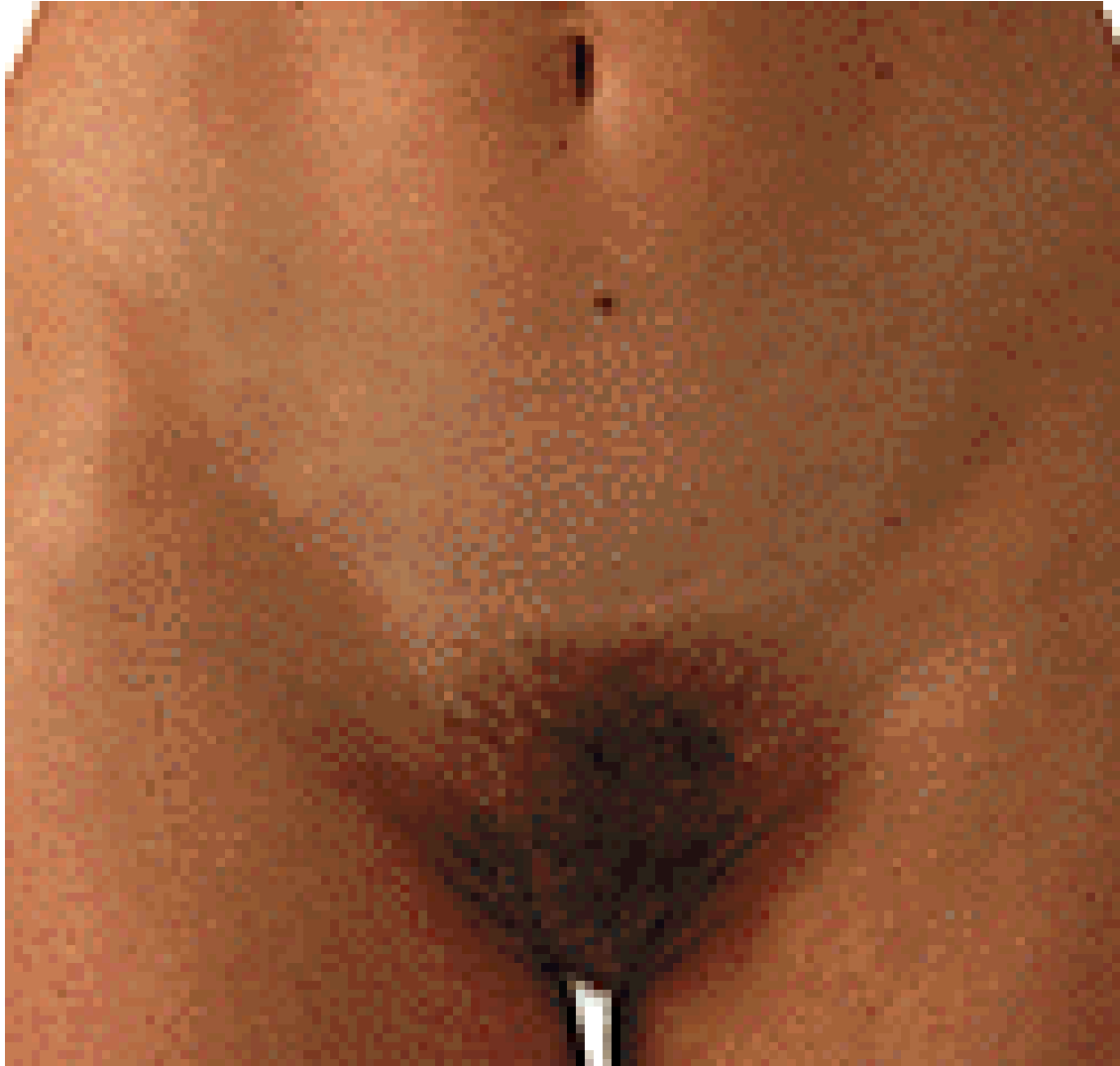Commisura labiorum post.

Pubes

Perineum (raphe perinei)



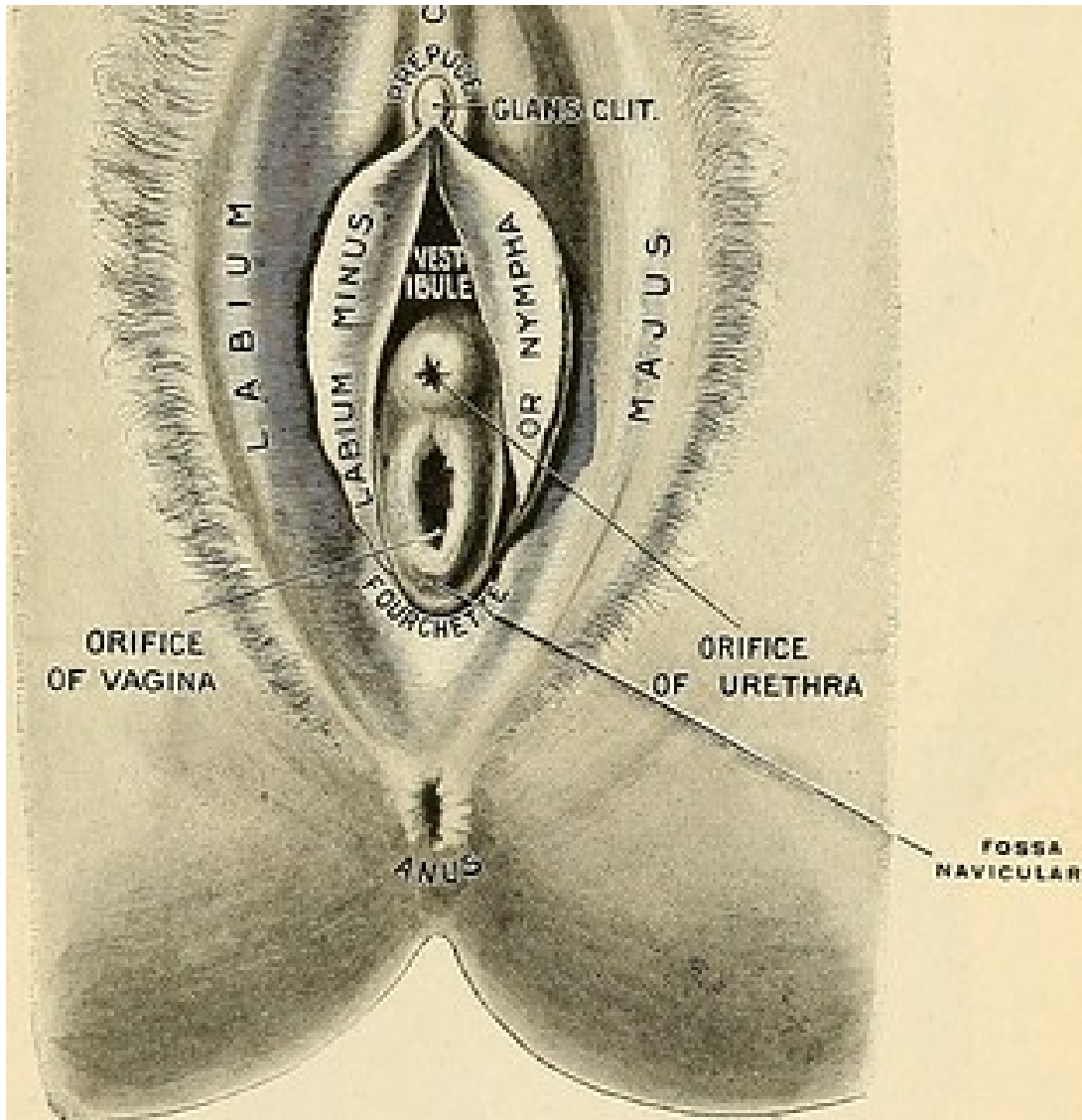
MONS PUBIS



Pubes

Fatty tissue

Labia minora pudendi



Sulcus interlabialis

Vestibulum vaginae

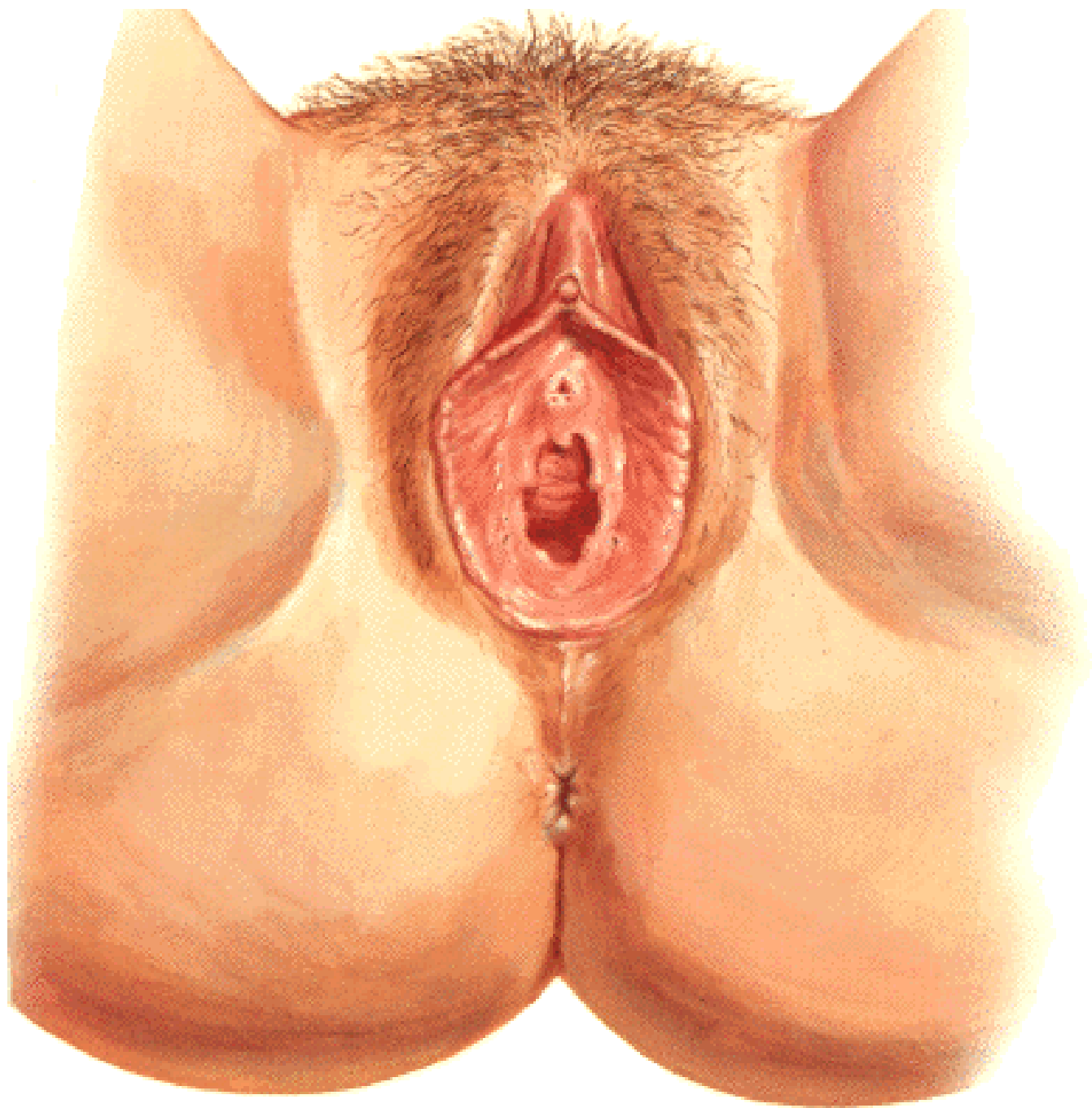Smegma

Frenulum labiorum pudendi

Fossa vestibuli vaginae

Praeputium clitoridis

Frenulum clitoridis



CLITORIS

**Crura clitoridis
(crista phallica)**

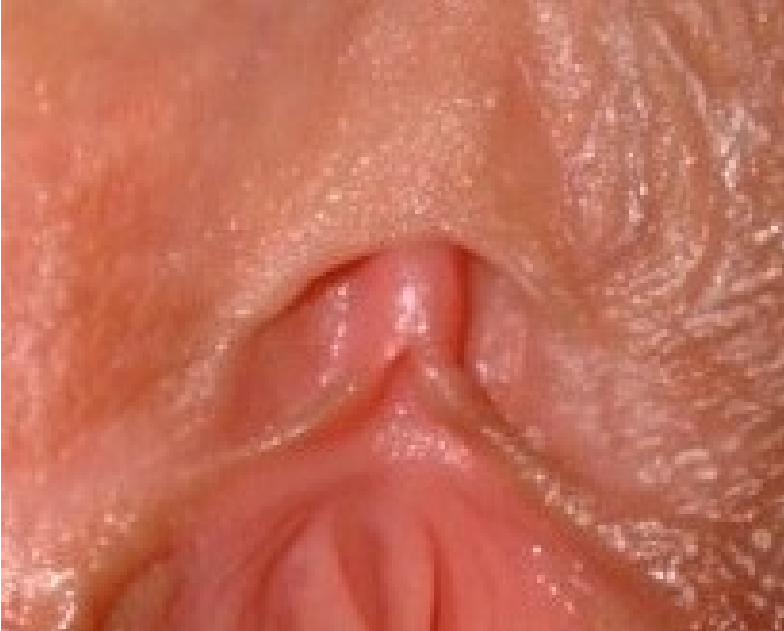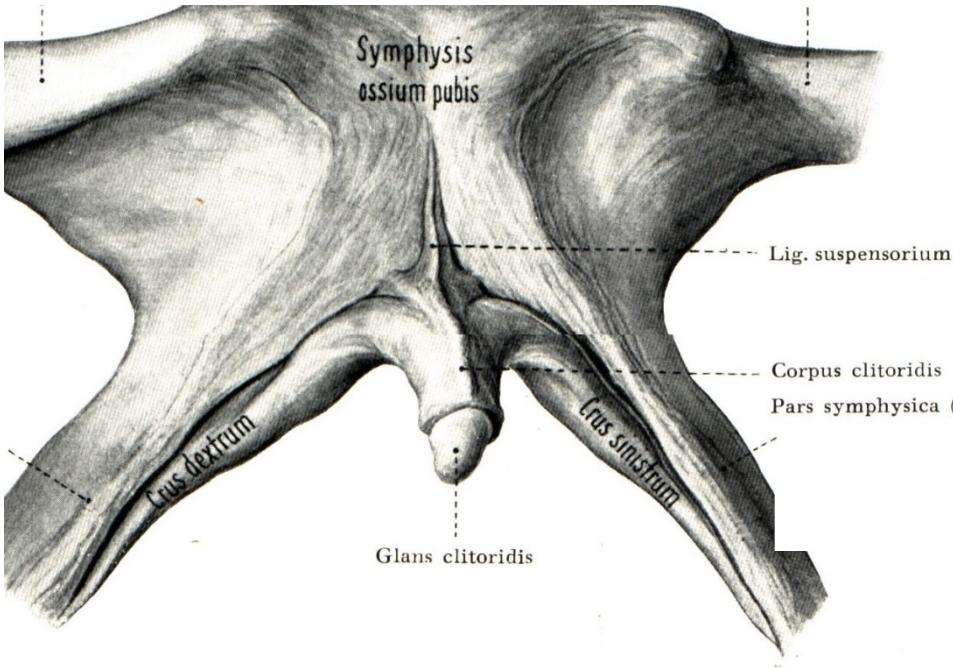
Corpus clitoridis

Glans clitoridis

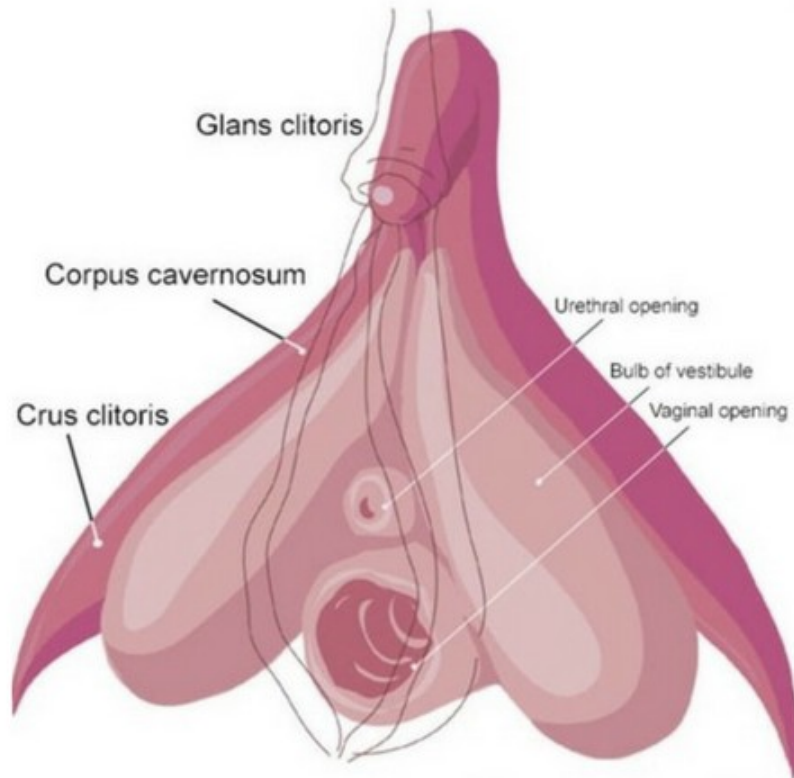
Praeputium clitoridis

Frenulum clitoridis

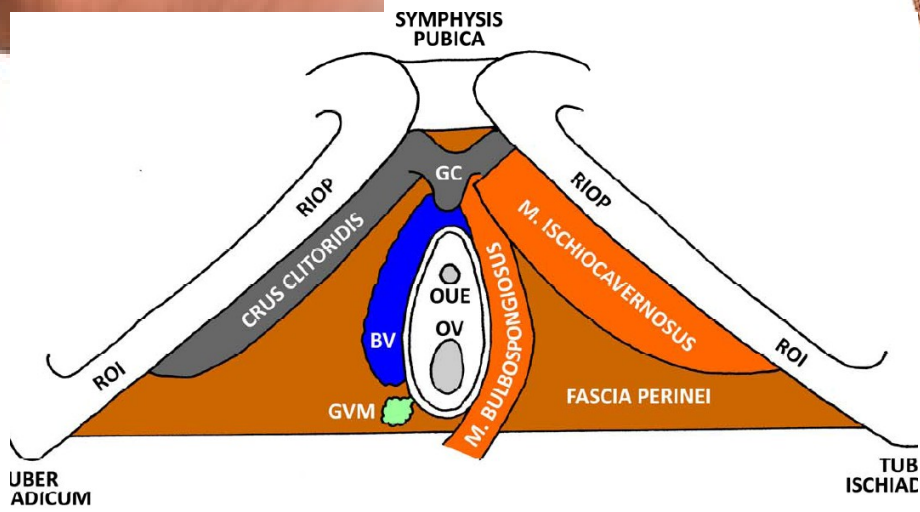
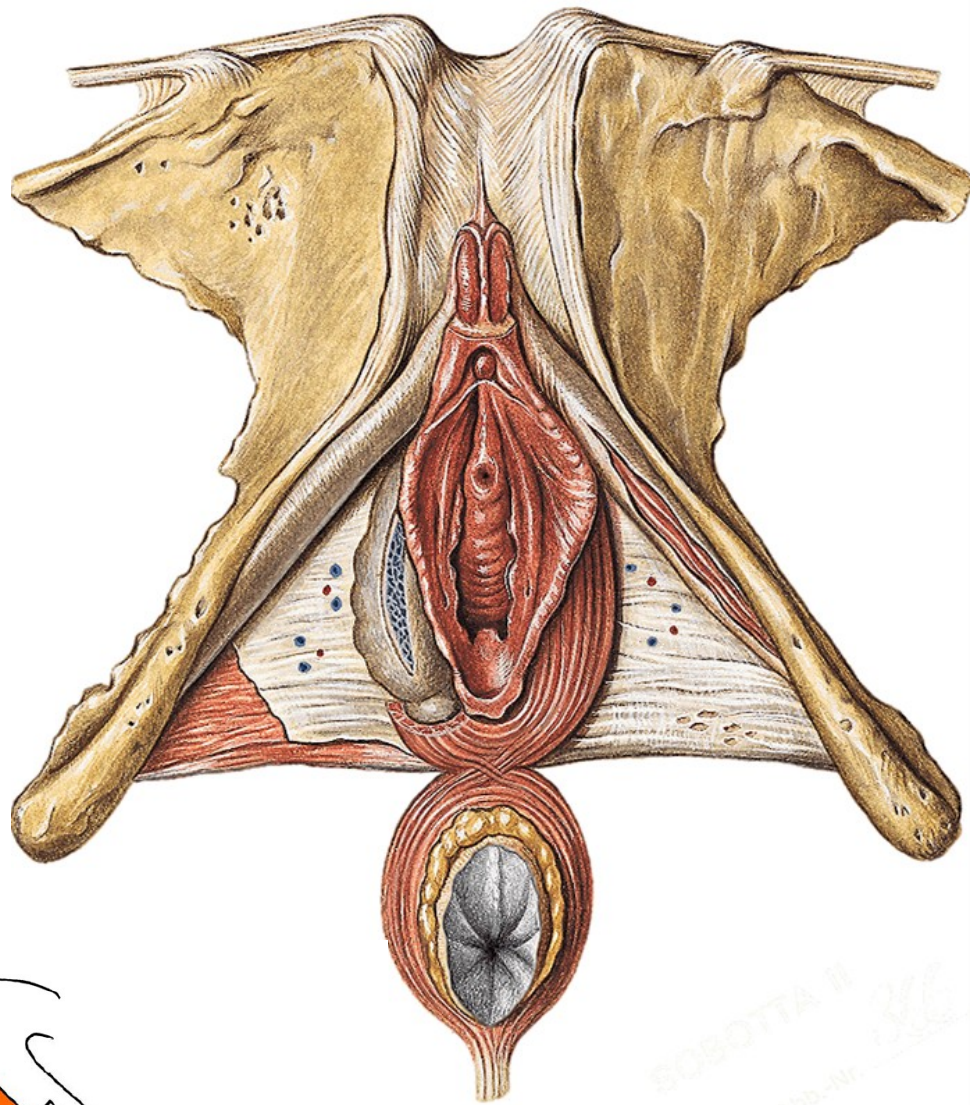
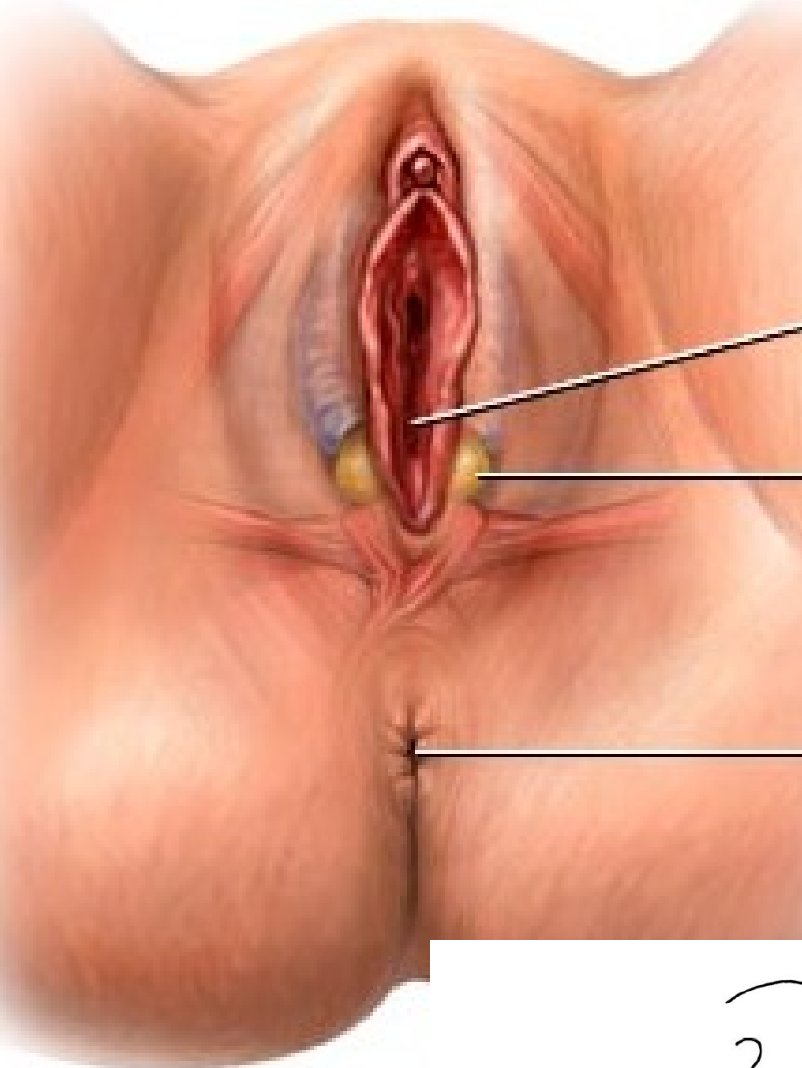
Corpora cavernosa clitoridis



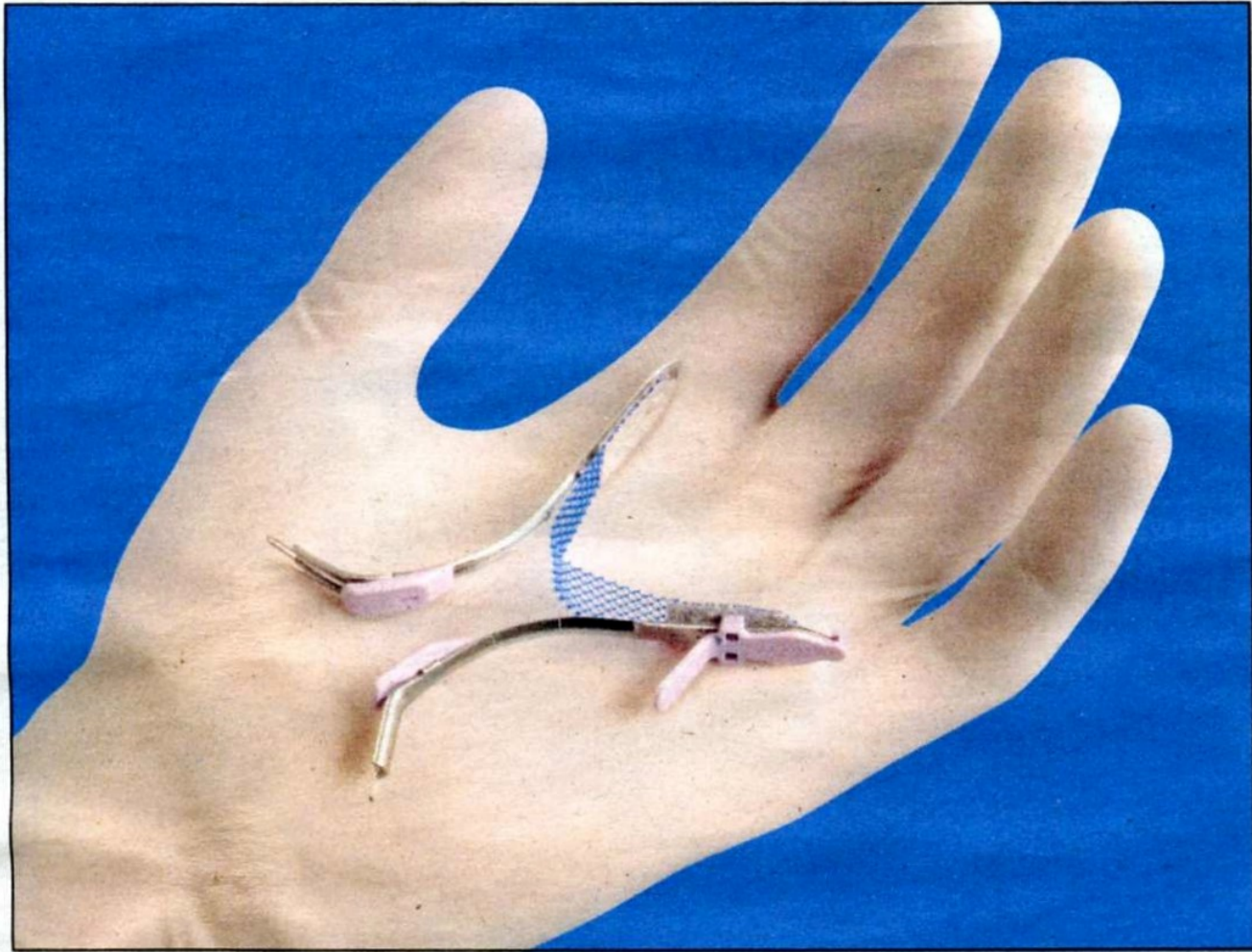
THE CLITORIS HAS 8,000 NERVE ENDINGS



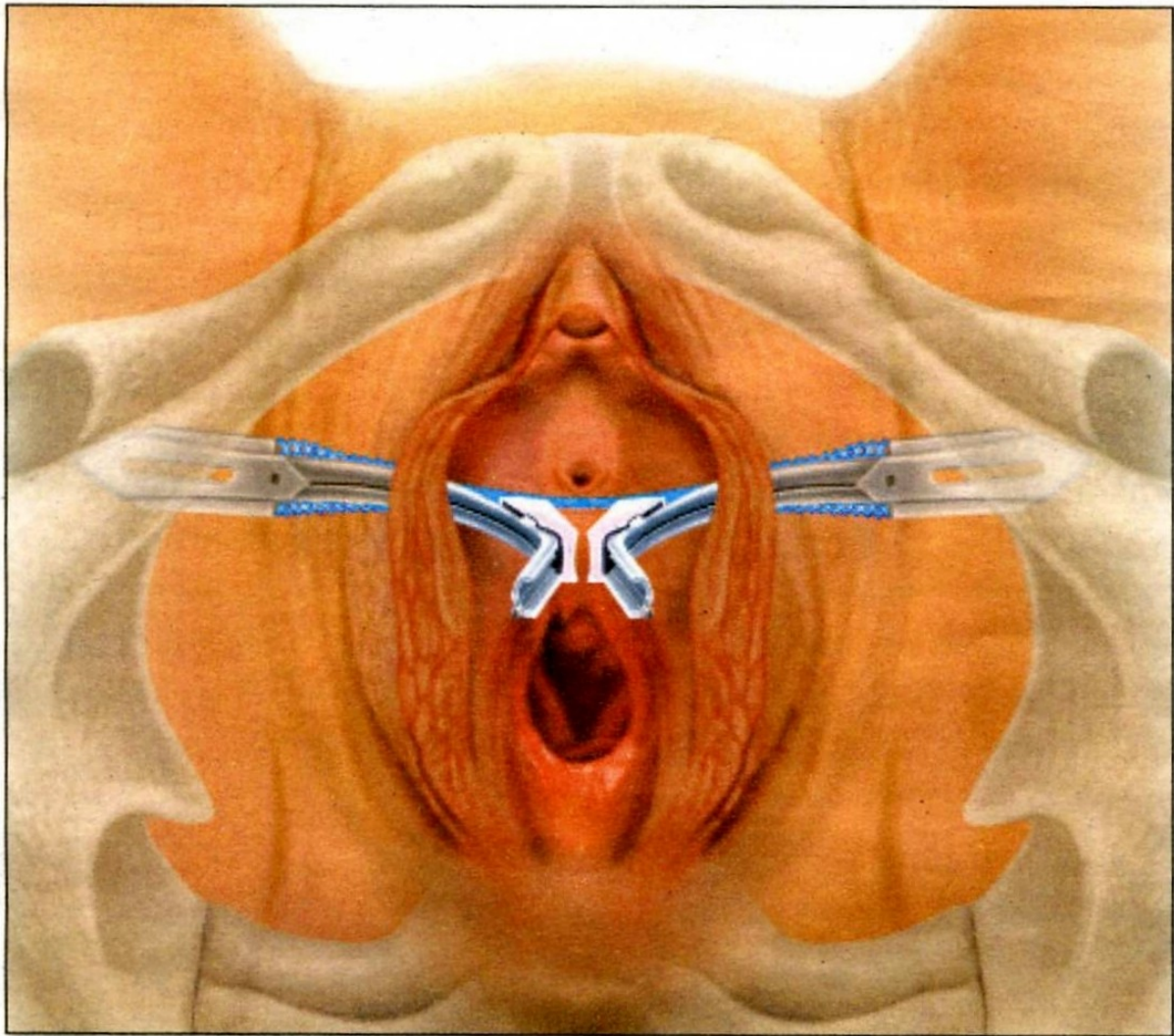
(about twice as many as the penis)



SOBOTTA W
 www.wiley.com



Tension-free vaginal tape



VESTIBULUM VAGINAE

between labia minora pudendi

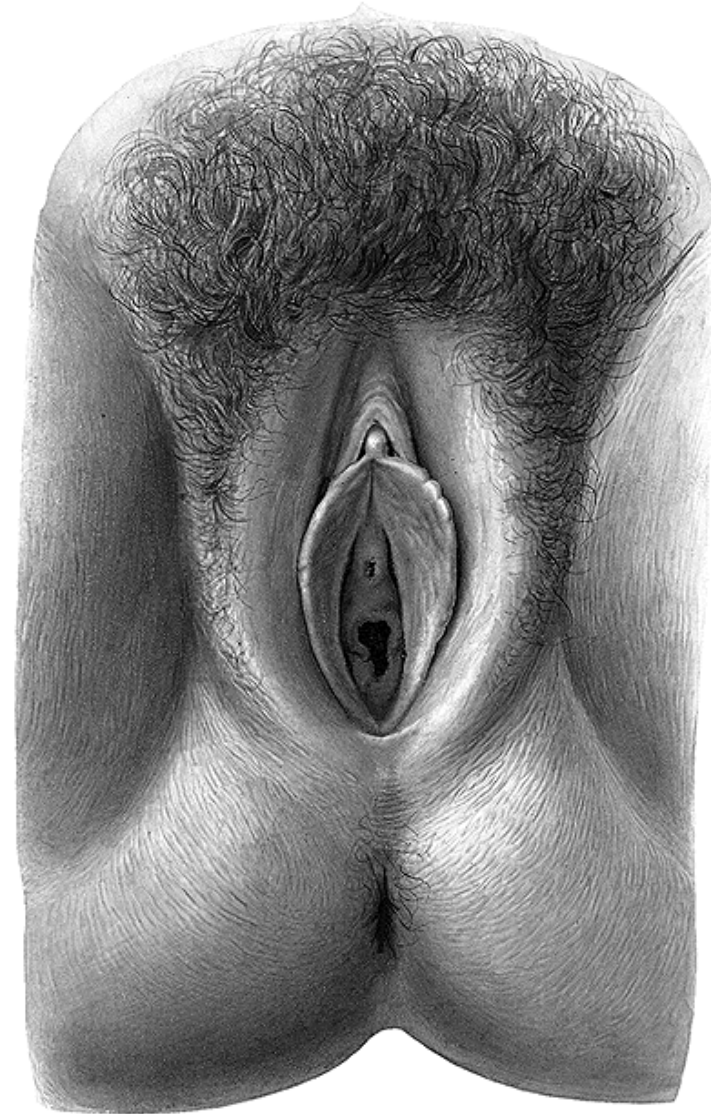Glans clitoridis
(praeputium et frenulum clitoridis)

Ostium urethrae externum
(papilla urethralis, gll. vestib. minores)

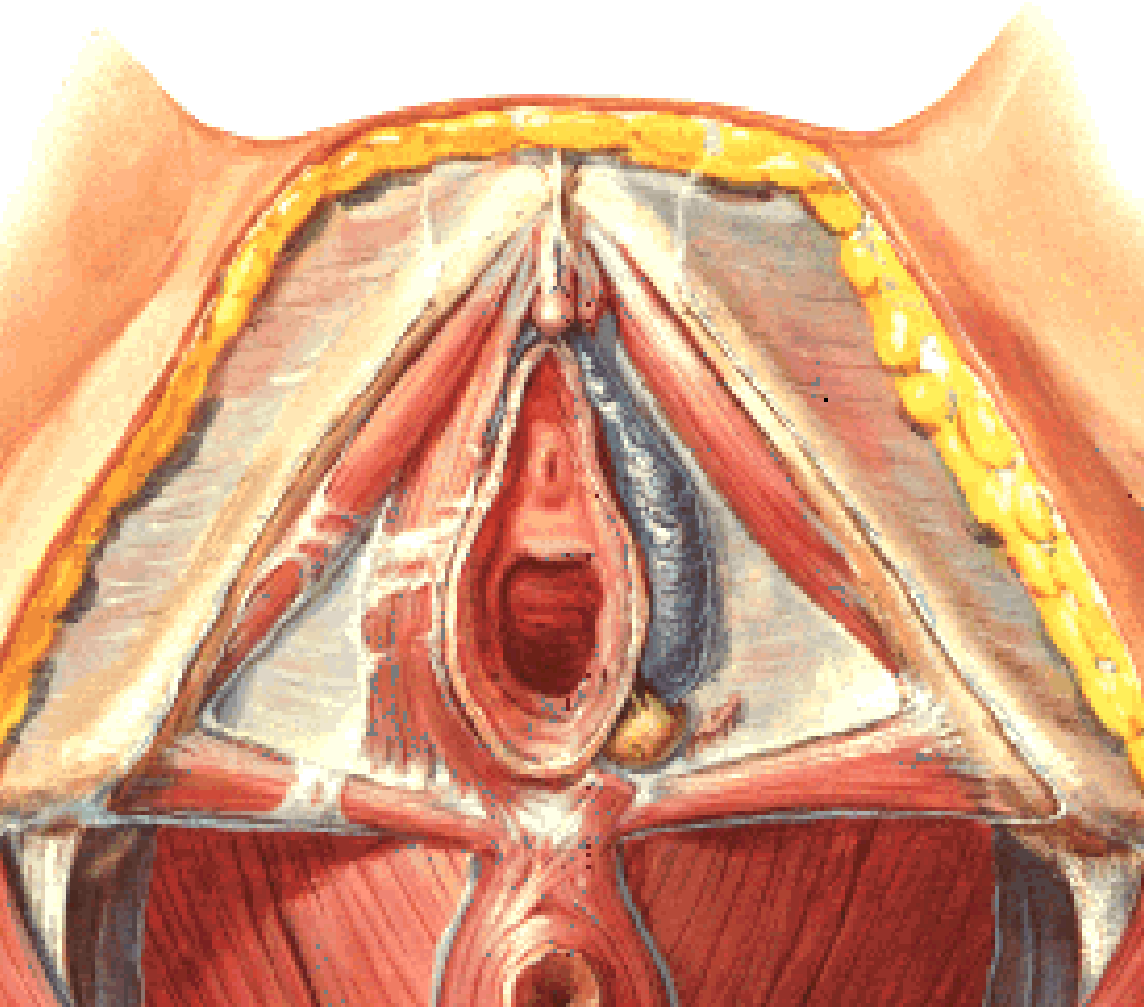
Ostium vaginae (hymen)

Fossa navicularis

Frenulum labiorum pudendi
(commisura labiorum pudendi)



BULBI VESTIBULI

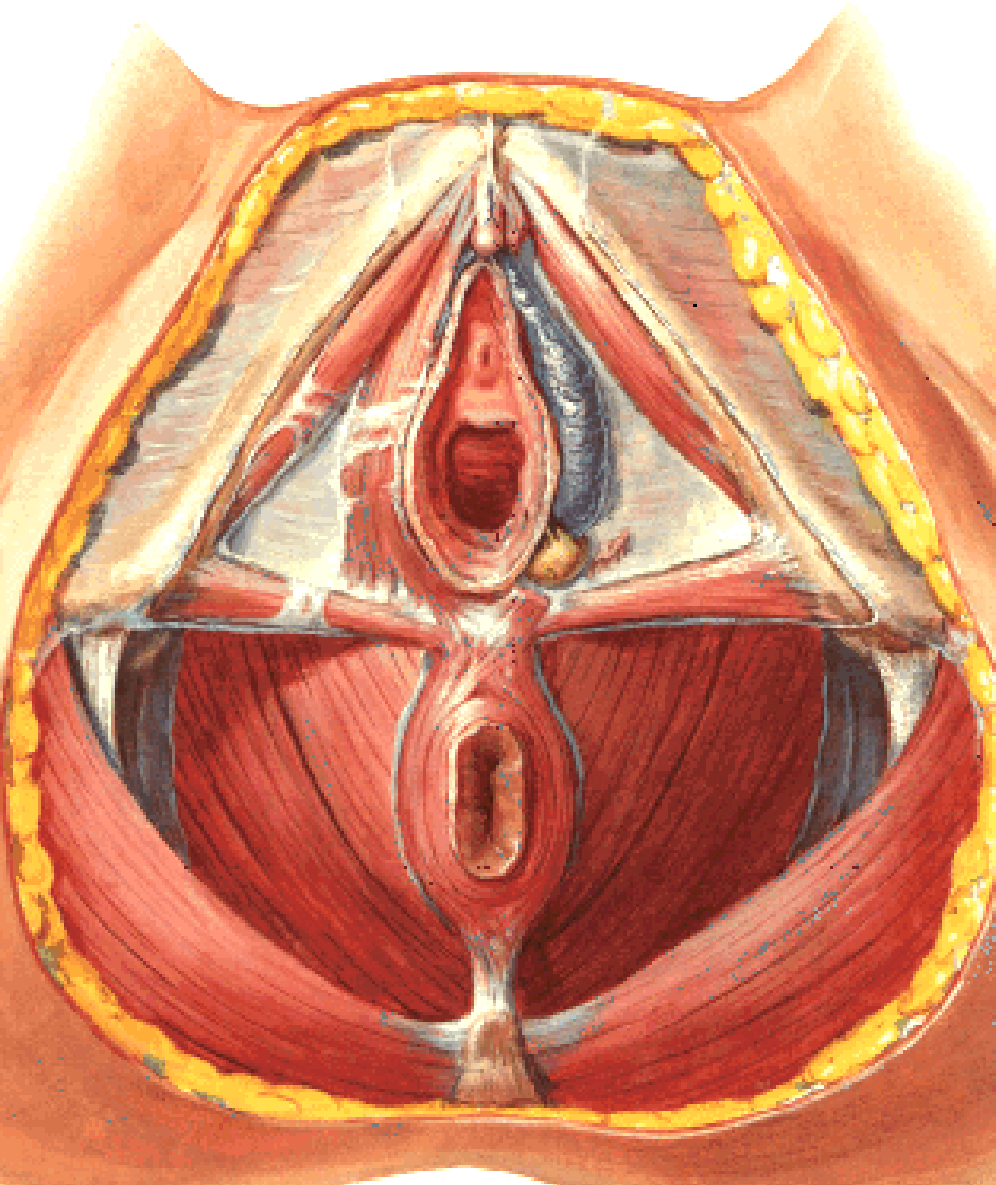


**Erectile bodies
(corpus spongiosum)**

**on diaphragma
urogenitale**

**m. bulbospongiosus
(from centrum
tendineum
perinei to the dorsum
clitoridis)**

GLANDULAE VESTIBULARES MAJORES (BARTHOLINI)



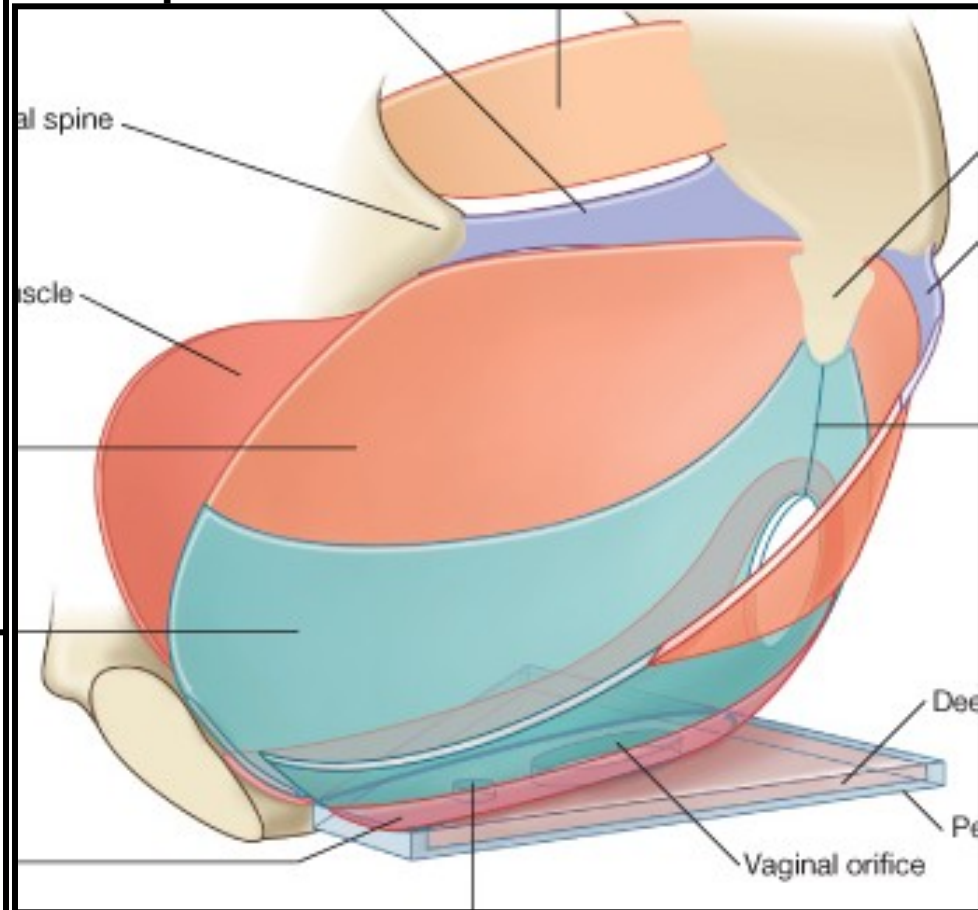
**On the diaphragma
urogenitale
Dorsally from bulbi
vestibuli**

m. bulbospongiosus

**Open to the vestibulum
vaginae**

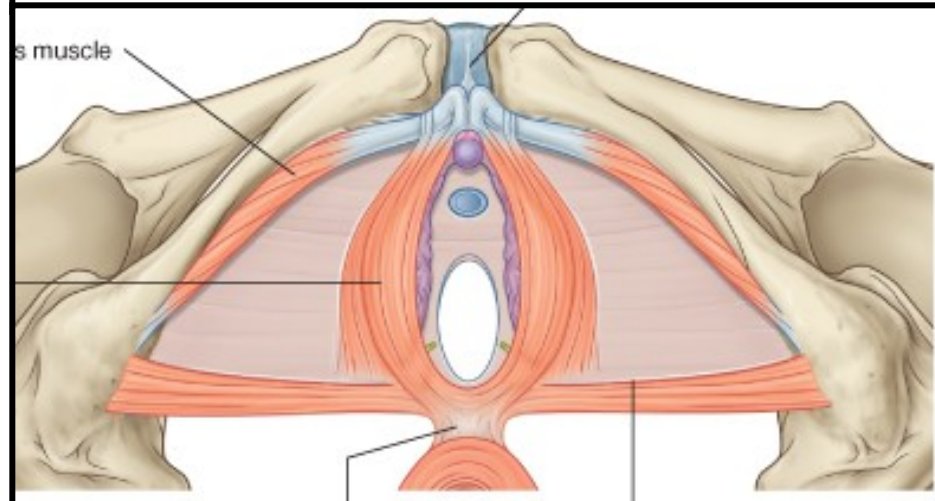
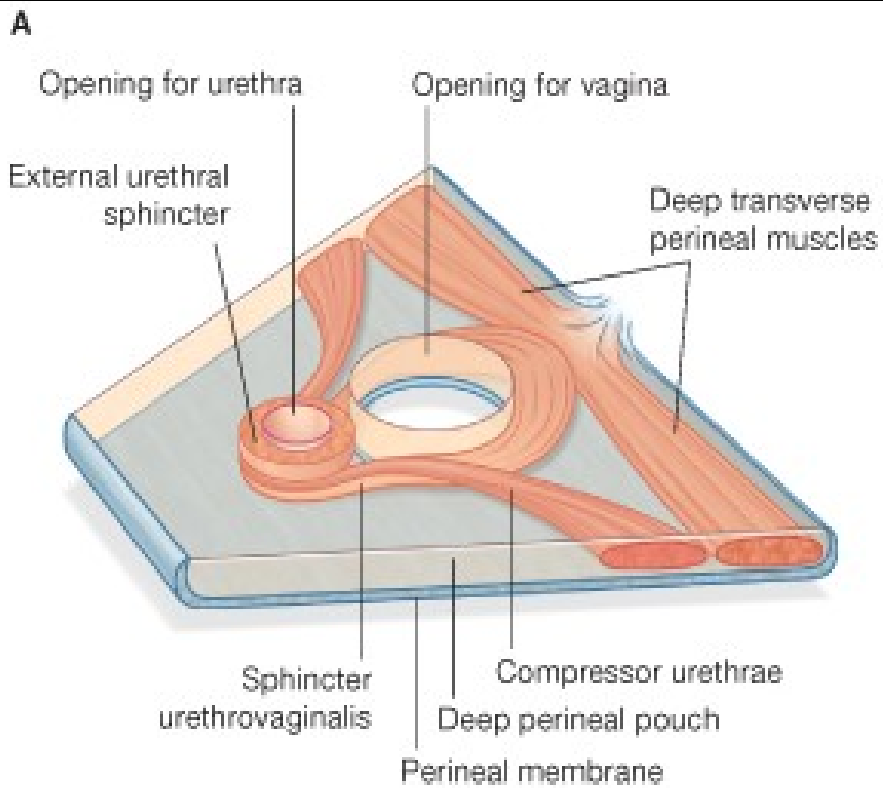
Deep perineal pouch

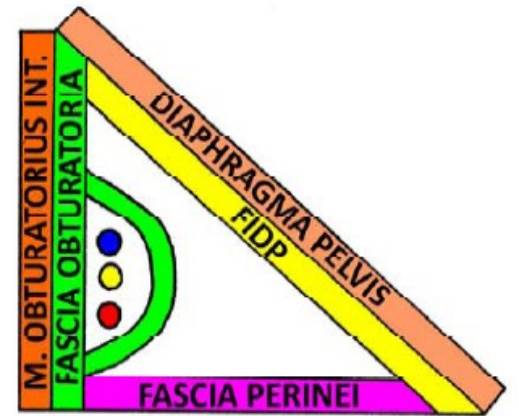
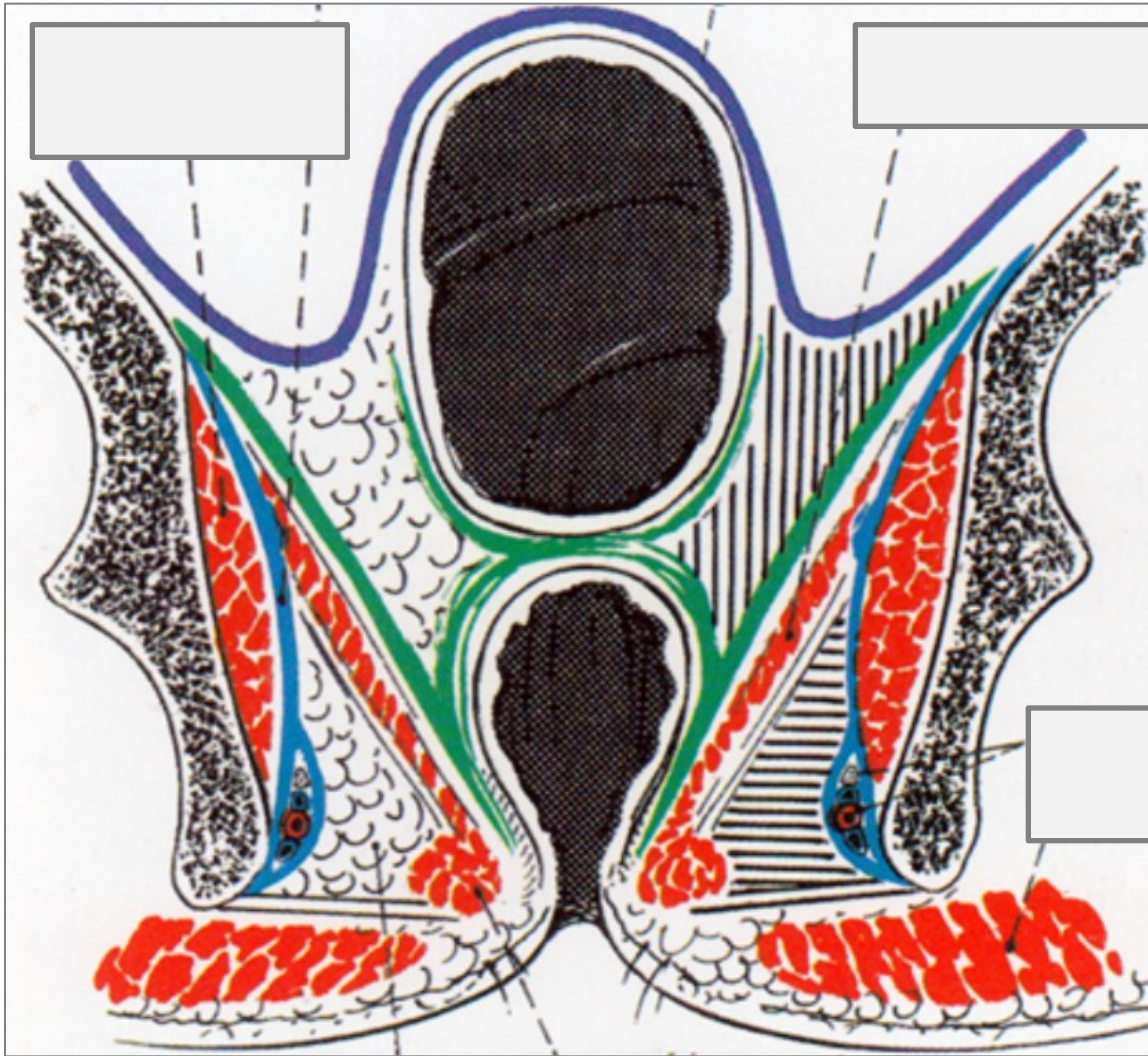
m.transversus perinei prof.
m.sphincter urethrae

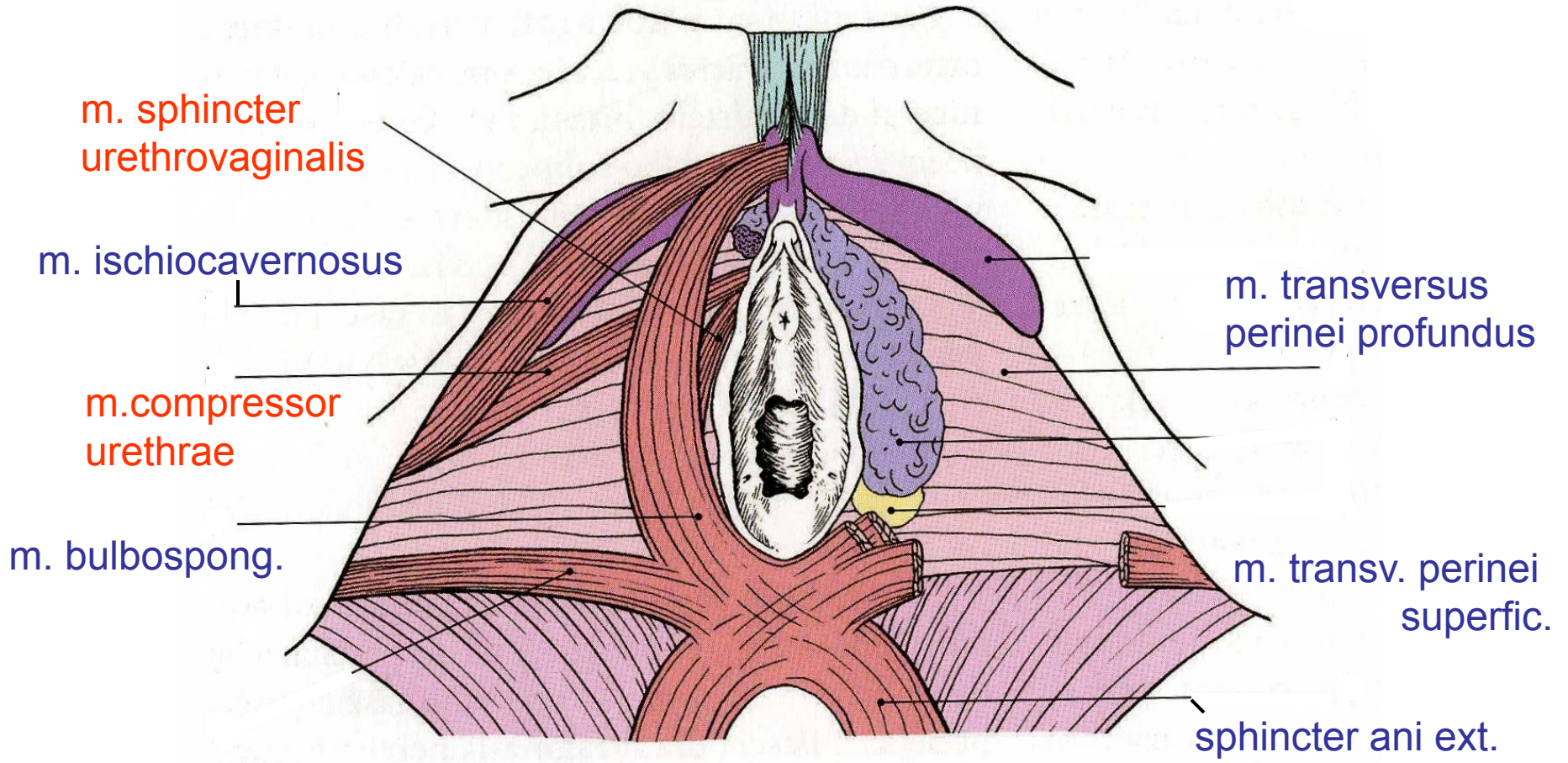


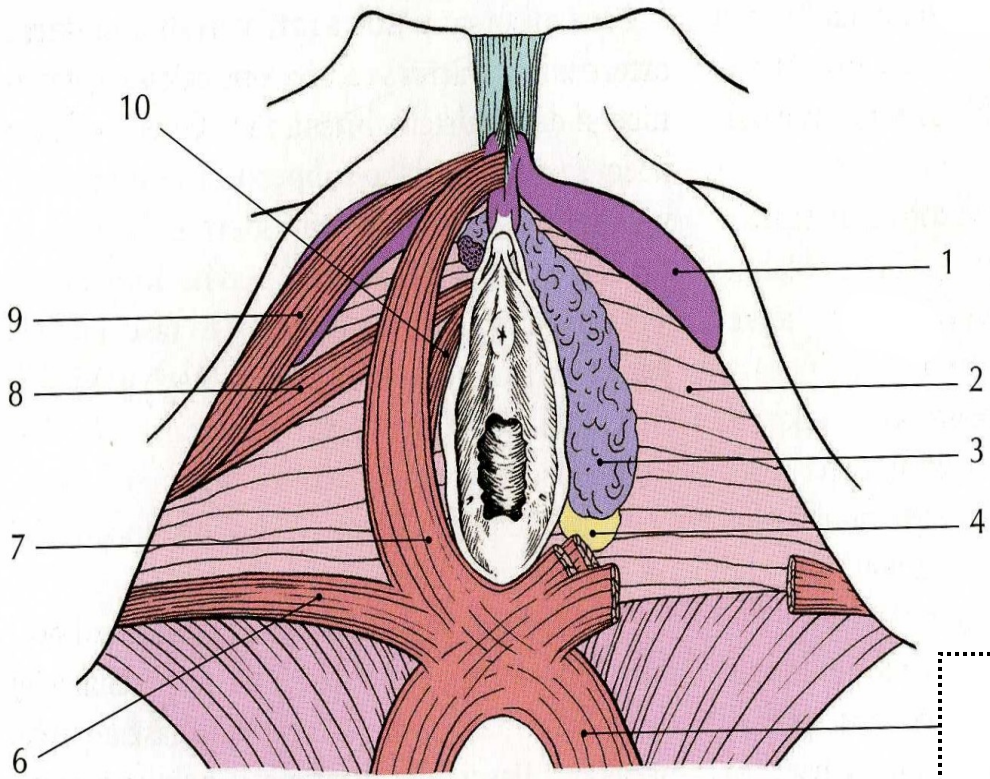
Superficial perineal pouch

m. bulbospongiosus
m. ischiocavernosus
m. sphincter ani ext.

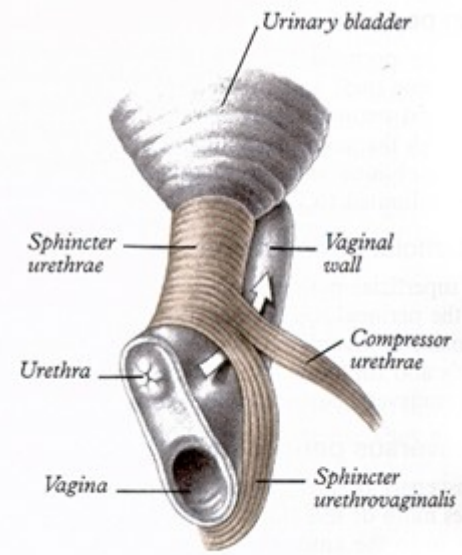








- **m. sphincter urethrae**
- **m. compressor urethrae**
- **m. sphincter urethrovaginalis**



Thank you for attention

