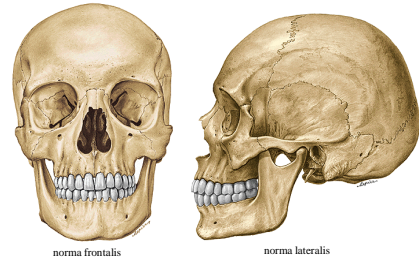


Neurocranium

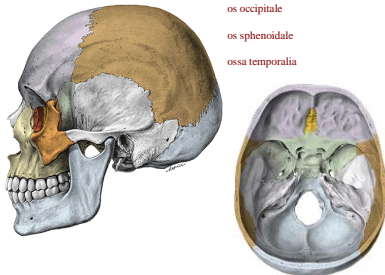
Skull (cranium)

Neurocranium et splanchnocranium



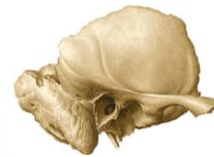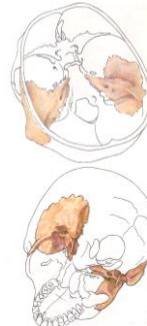
Neurocranium (calvarium et basis cranii)

- os frontale
- ossa parietalia
- os occipitale
- os sphenoidale
- ossa temporalia

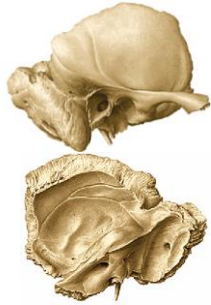

Os temporale

- Pars squamosa
- Pars petrosa (pyramis)
- Pars mastoidea
- Pars tympanica
- Processus styloideus (pars hyoidea)



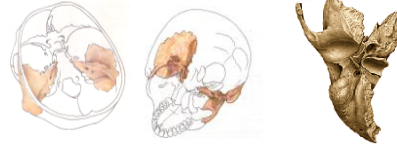Pars squamosa ossis temporalis



- processus zygomaticus
- linea temporalis inferior
- crista supramastoidea
- spina suprameatum
- fossa mandibularis
- tuberculum articulare
- sulci arteriosi
- juga cerebrialia
- impressiones gyrorum

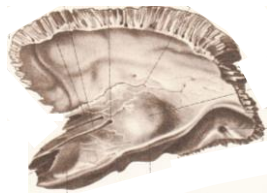
Pars petrosa (pyramis)

- Facies anterior (cerebralis) pyramidis
- Facies posterior
- Facies inferior
- Facies ventrobasis (auditory organ)



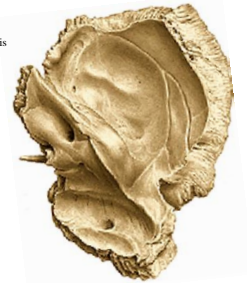
Facies anterior pyramidis

- foramen lacerum
- apex pyramidis
- impressio trigemini
- canalis musculotubarius
- apertura interna canalis carotici
- eminentia arcuata
- tegmen tympani
- hiatus canalis nervi petrosi majoris et minoris
- sulcus nervi petrosi majoris et minoris



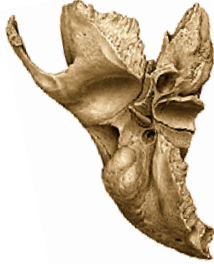Facies posterior pyramidis

- margo superior - crista pyramidis
- sulcus sinus petrosi superioris et inferioris
- porus acusticus internus
- meatus acusticus internus
- fundus meatus acustici interni (introitus canalis nervi facialis)
- fossa subarcuata
- apertura externa aquaeductus vestibuli
- incisura jugularis (foramen jugulare)
- apertura externa canaliculi cochleae
- sulcus sinus sigmoidei



Facies inferior pyramidis

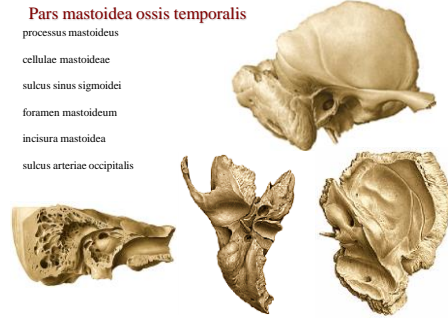
apertura externa canalis carotici
 fossa jugularis
 canaliculus mastoideus
 apertura externa canaliculi tympanici
 (fossula petrosa)

**Processus styloideus**

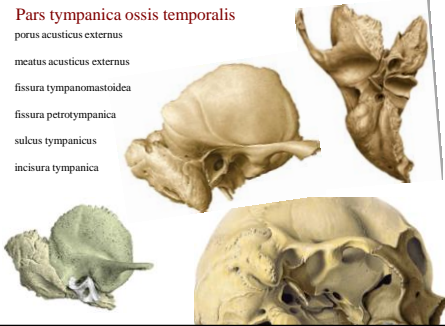
Foramen stylomastoideum

Pars mastoidea ossis temporalis

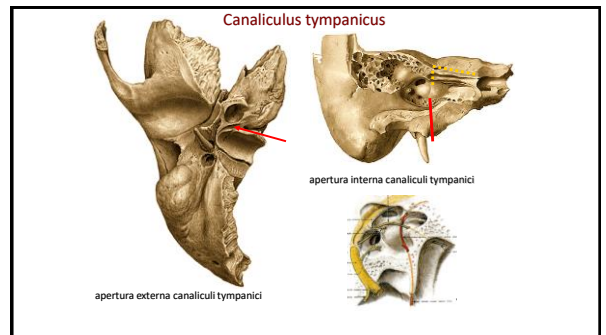
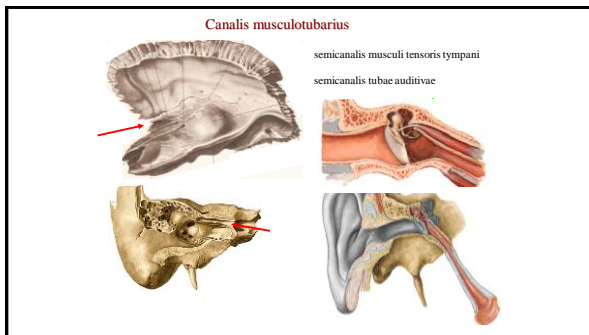
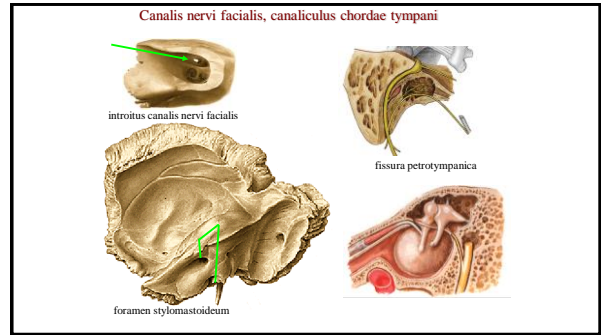
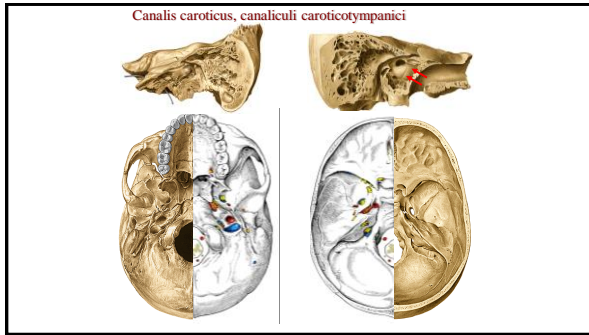
processus mastoideus
 cellulae mastoideae
 sulcus sinus sigmoidei
 foramen mastoideum
 incisura mastoidea
 sulcus arteriae occipitalis

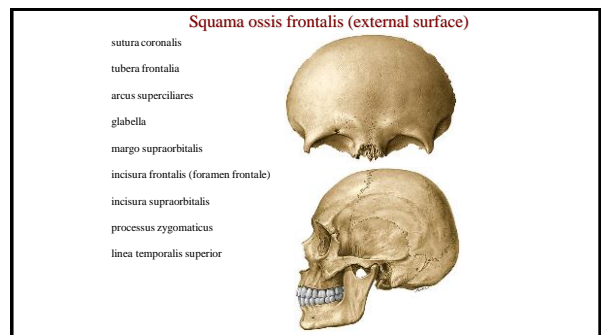
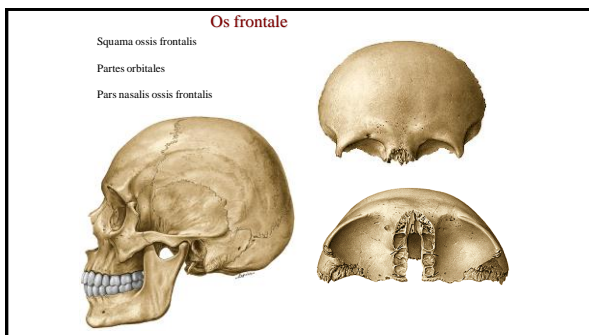
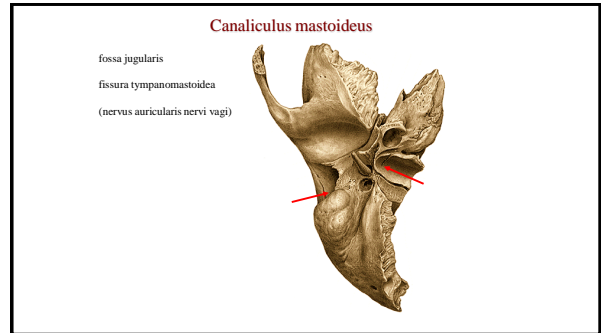
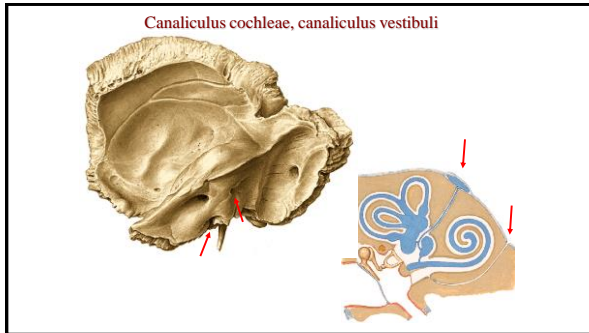
**Pars tympanica ossis temporalis**

porus acusticus externus
 meatus acusticus externus
 fissura tympanomastoidea
 fissura petrotympanica
 sulcus tympanicus
 incisura tympanica

**Temporal bone canals**

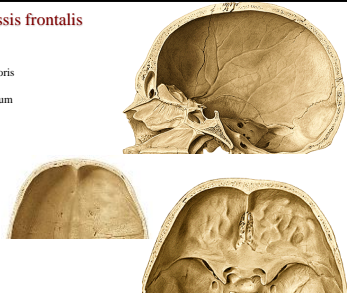
1. canalis caroticus
2. canaliculi caroticotympanici
3. canalis nervi facialis
4. canalis musculotubarius
5. canaliculus chordae tympani
6. canaliculus tympanicus
7. canaliculus cochleae
8. canaliculus vestibuli
9. canaliculus mastoideus





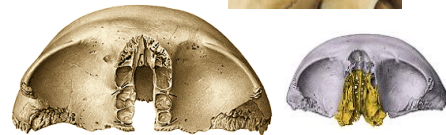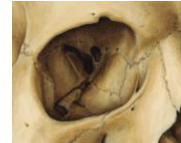Squama ossis frontalis

- crista frontalis
- sulcus sinus sagittalis superioris
- impressiones digitatae/gyrorum
- juga cerebralia
- foramen caecum
- suki arteriosi
- sinus frontalis
- septum sinuum frontaliun
- apertura sinuum frontaliun



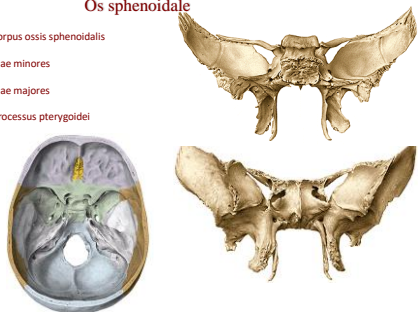
Partes orbitales at pars nasalis ossis frontalis

- fossa glandulae lacrimalis
- spina (fovea) trochlearis
- foramen ethmoidale anterius
- foramen ethmoidale posterius
- incisura ethmoidalis



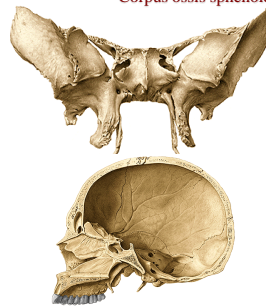
Os sphenoidale

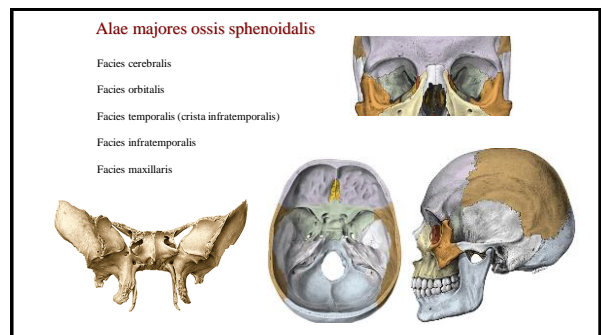
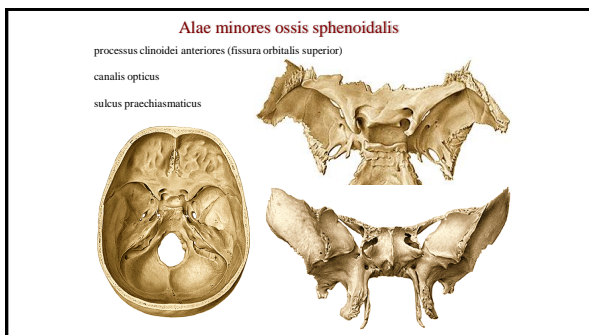
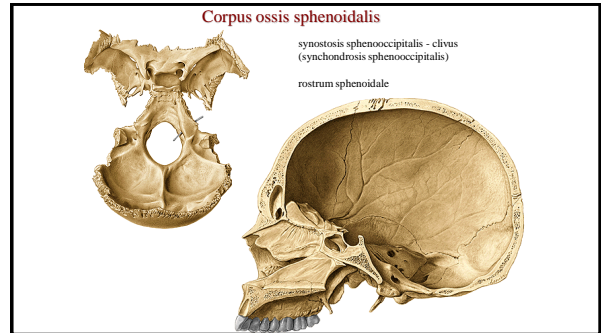
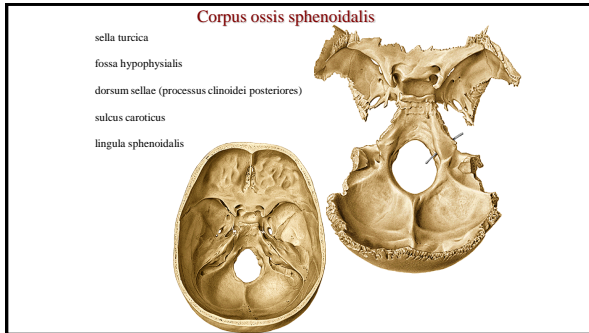
- corpus ossis sphenoidalis
- alae minores
- alae majores
- processus pterygoidei

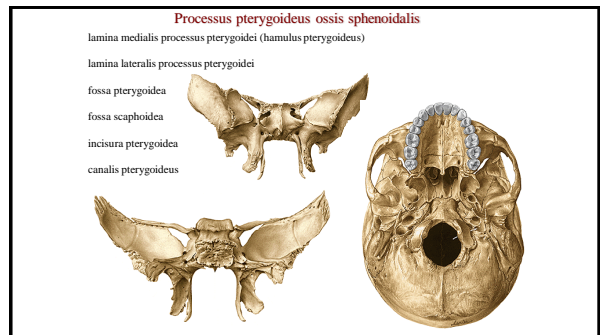
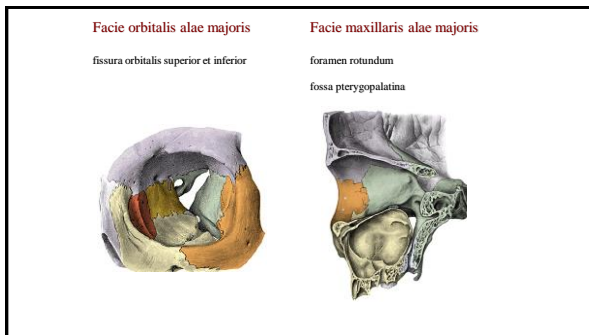
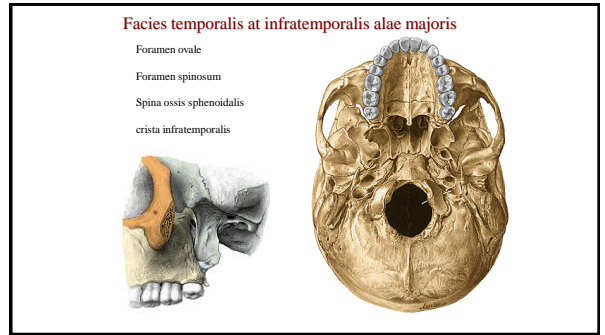
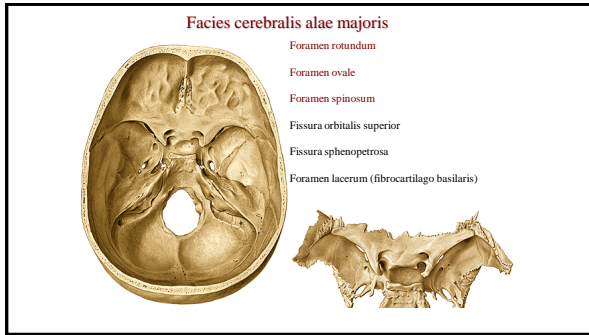


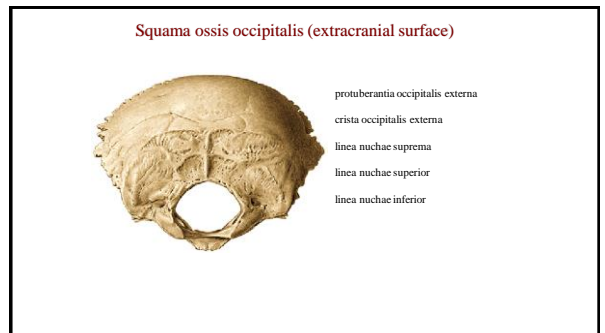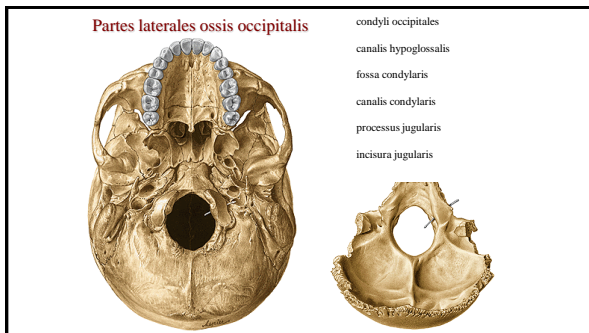
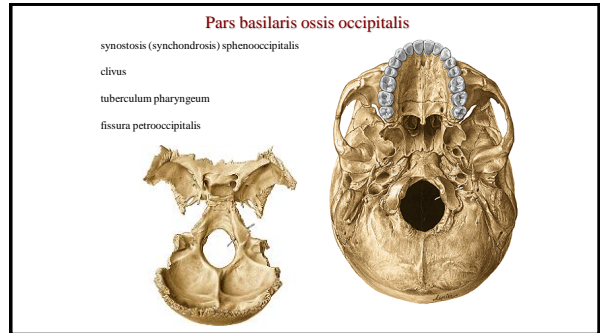
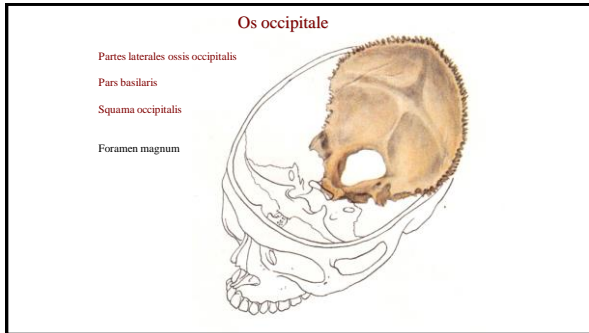
Corpus ossis sphenoidalis

- Ventral:
- sinus sphenoidalis
 - septum sinuum sphenoidalium
 - apertura sinus sphenoidalis
 - conchae sphenoidales
 - crista sphenoidalis
 - rostrum sphenoidale

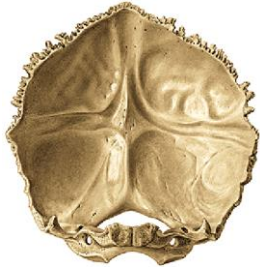







Squama ossis occipitalis (intracranial surface)



protuberantia occipitalis interna
 eminentia cruciformis
 sulcus sinus sagittalis superioris
 sulcus sinus transversi
 sulcus sinus sigmoidei
 crista occipitalis interna
 fossae cerebrales
 fossae cerebellares



angulus frontalis
 angulus sphenoidalis
 angulus occipitalis
 angulus mastoideus

sulci arteriae meningae mediae
 sulcus sinus sagittalis superioris
 foveolae granulares
 sulcus sinus sigmoidei

References:

[Putz, R. \(2008\)](#):
 Atlas of Human Anatomy Sobotta. Elsevier Books.

[Keith L. Moore, Arthur F. Dalley \(2005\)](#):
 Clinically Oriented Anatomy. Williams and Wilkins.

[Platzer, W., Kahle, W., Leonhardt H. \(1992\)](#):
 Locomotor system. Georg Thieme Verlag, Stuttgart,
 New York, 4th edition.

[Čihák, R. \(1987\)](#): Anatomie I. Avicenum, Zdravotnické nakladatelství.