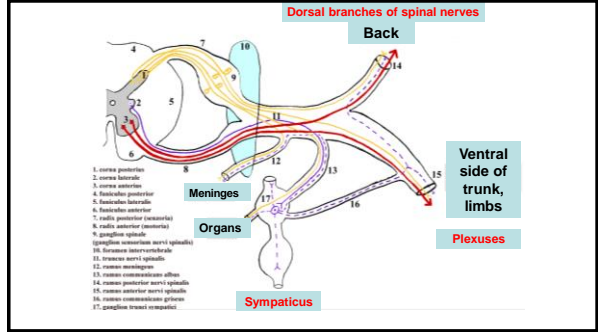


Dissection I

1



2

Dorsal branches of spinal nerves

- Segmental organization
- Medial and lateral branch
- Sensory and motor

3

- N. suboccipitalis – C1
- N. occipitalis major – C2
- N. occipitalis tertius – C3

4

- Nervi clunium superiores
- Nervi clunium medii

5

PLEXUS BRACHIALIS

rami ventrales nervorum spinalium C₅ – Th₁

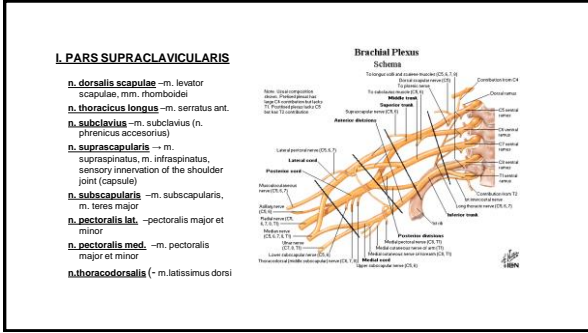
innervation of upper extremity, heterochtonic muscles of thorax and back

Fissura scalenorum

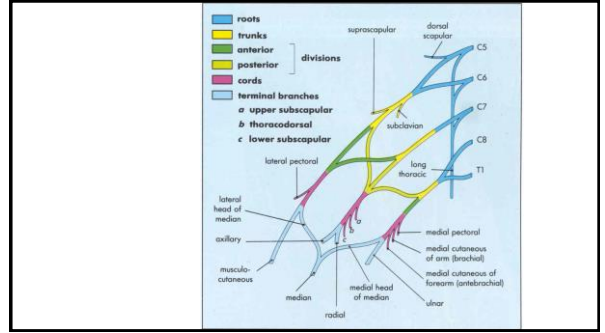
supraclavicular part

infraclavicular part

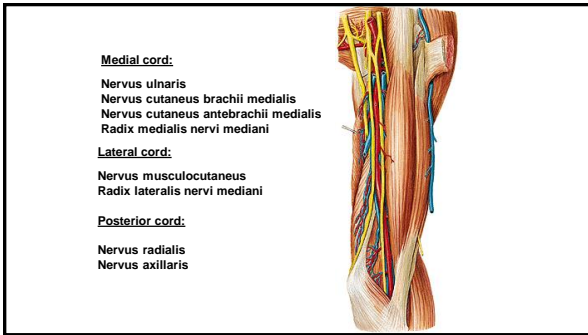
6



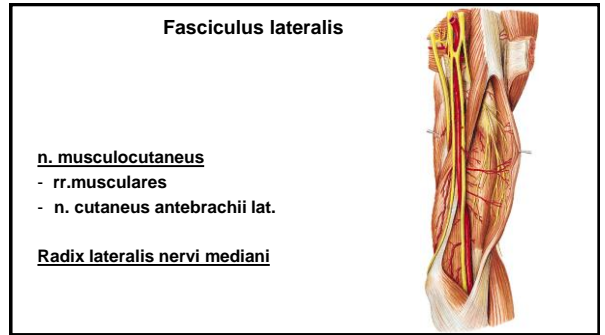
7



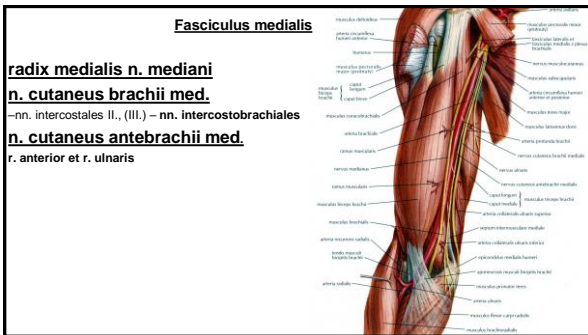
8



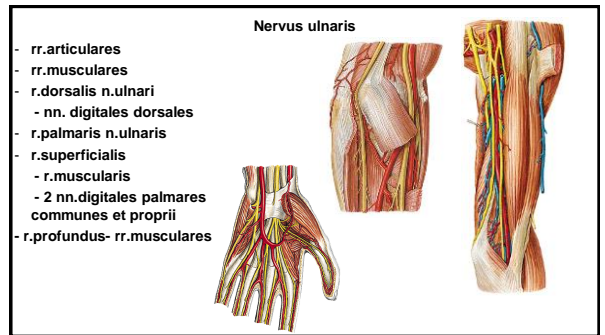
9



10



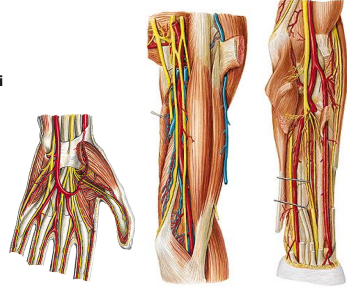
11



12

Nervus medianus

- rr. musculares
- rr. articulares
- n. interosseus antebrachii ant.
- r. palmaris
- r. thenaris
- nn. digitales palmares comm.- nn. digitales palmares proprii
- r. communicans cum n. ulnari



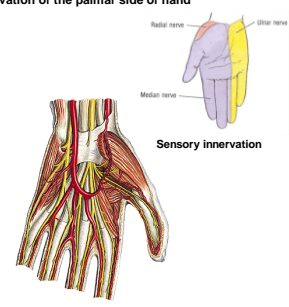
13

Innervation of the palmar side of hand

Nervus medianus:
Muscles of thenar (exceptions)

Nervus ulnaris:
Muscles of hypothenar

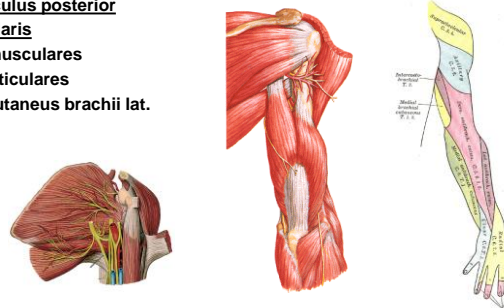
Musculi interossei
Musculi lumbricales 3-4
Musculus adductor pollicis
Caput profundum musculi flexoris pollicis brevis



14

Fasciculus posterior
n. axillaris

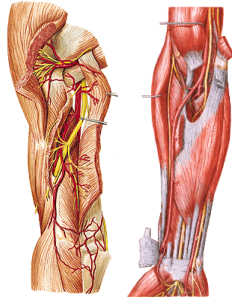
- rr. musculares
- rr. articulares
- n. cutaneus brachii lat. sup.



15

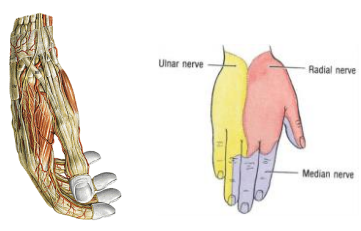
n. radialis

- rr. musculares
- n. cutaneus brachii lat. inf.
- n. cutaneus brachii post.
- n. cutaneus antebrachii post.
- r. profundus
 - n. interosseus antebrachii post.
- r. superficialis
 - n. digitales dorsales



16

Innervation of the dorsal side of hand

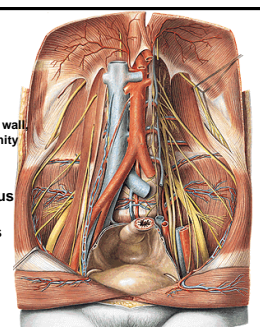


17

PLEXUS LUMBALIS

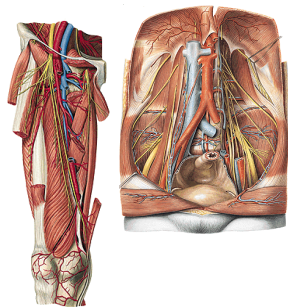
rami ventrales nervorum spinalium L₁ - L₄
innervation of abdominal wall and partially lower extremity

Nervus iliohypogastricus
Nervus ilioinguinalis
Nervus genitofemoralis
Nervus obturatorius
Nervus femoralis



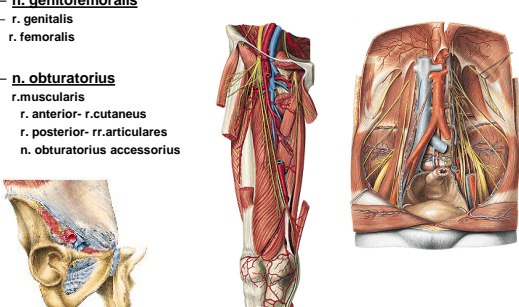
18

- n. iliohypogastricus
r. muscularis
r. cutaneus lat. et anter.
- n. ilioinguinalis
r. muscularis
rr. scrotales (labiales) ant.
- n. cutaneus femoris lat.
- n. femoralis
rr. musculares
rr. cutanei ant.
n. saphenus - r. infrapatellaris,
rr. cutanei cruris med.



19

- n. genitofemoralis
r. genitalis
r. femoralis
- n. obturatorius
r. muscularis
r. anterior- r. cutaneus
r. posterior- rr. articulares
n. obturatorius accessorius

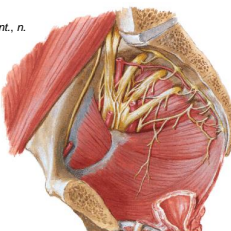


20

PLEXUS SACRALIS

rami ventrales nervorum
spinalium L₄ - S₅

rr. musculares: n. piriformis, n. obturatorius int., n. quadratus femoris, mm. gemelli,
Nervus gluteus superior
Nervus gluteus inferior
Nervus pudendus
Nervus cutaneus femoris posterior
Nervus ischiadicus



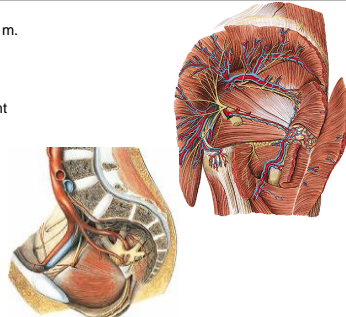
21

n. gluteus sup.
- m. gluteus medius et minimus, m. tensor fasciae latae

n. gluteus inf. - m. gluteus maximus, joint capsule - hip joint

n. cutaneus femoris post.-

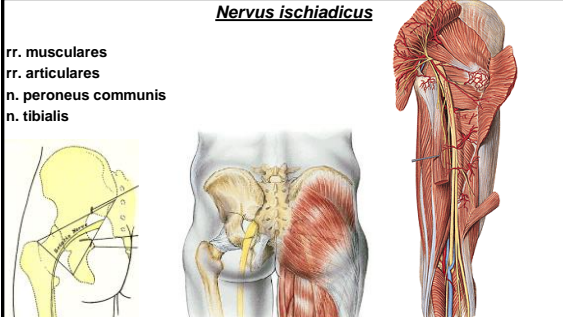
- rr. perineales
- nn. clunium inf.
- rr. cutanei



22

Nervus ischiadicus

rr. musculares
rr. articulares
n. peroneus communis
n. tibialis



23

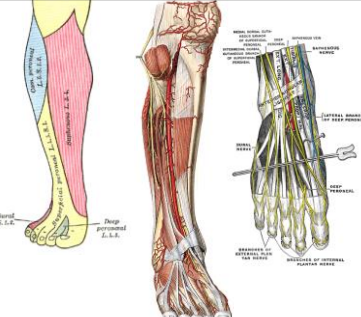
n. peroneus comm.

rr. articulares
n. cutaneus surae lat.-

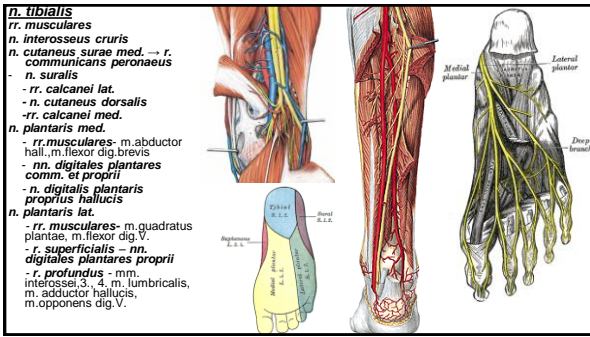
r. communicans peroneus -> n. suralis

n. peroneus spfc.
- rr. musculares-
- n. cutaneus dorsalis medialis - nn. digitales dorsales pedis.
- n. cutaneus dorsi pedis intermedius - nn. digitales dors. ped.

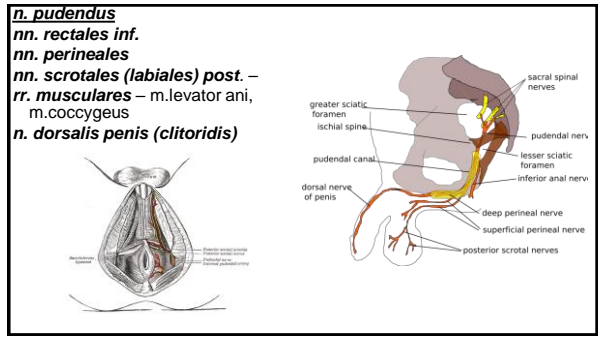
n. peroneus prof.
- n. digitalis dorsalis hallucis lat.
- n. digitalis dorsalis digiti secundi medialis
- rr. musculares



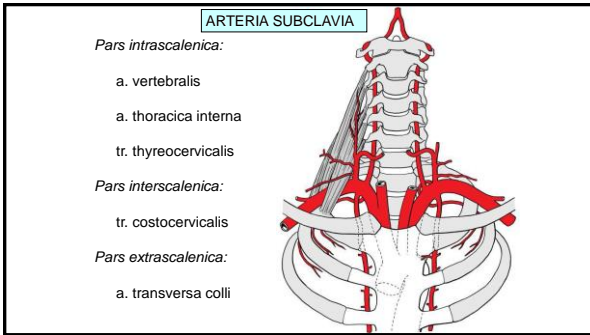
24



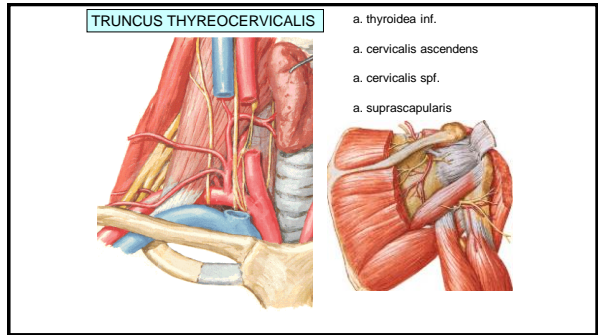
25



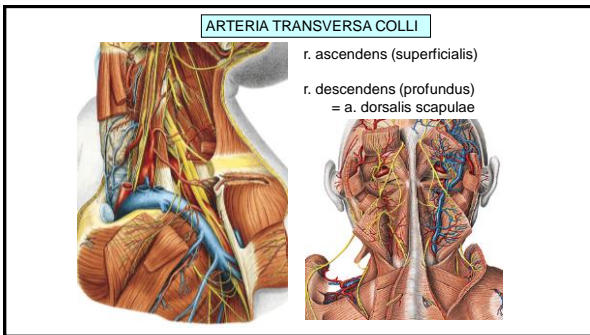
26



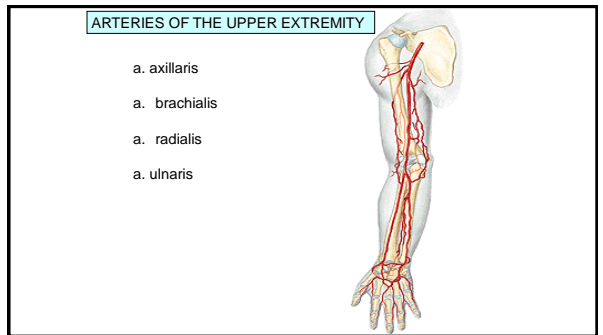
27



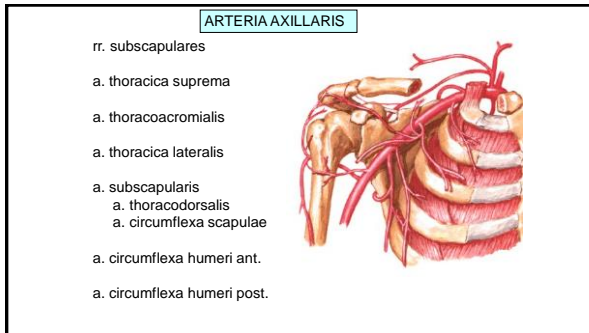
28



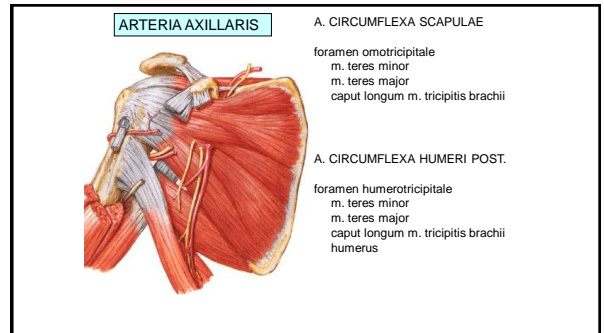
29



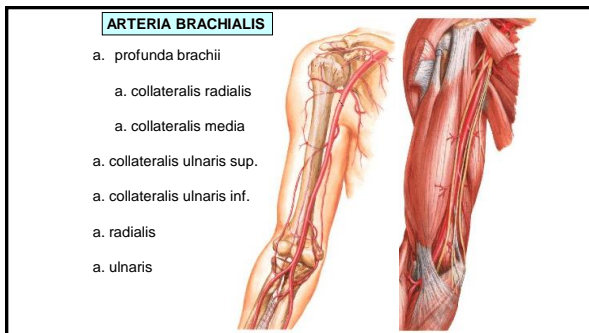
30



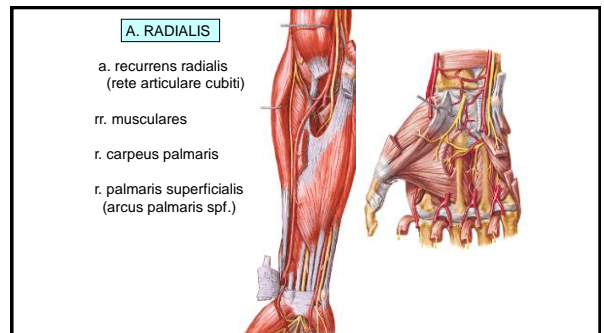
31



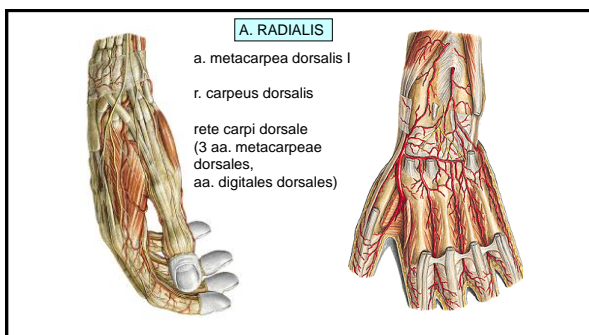
32



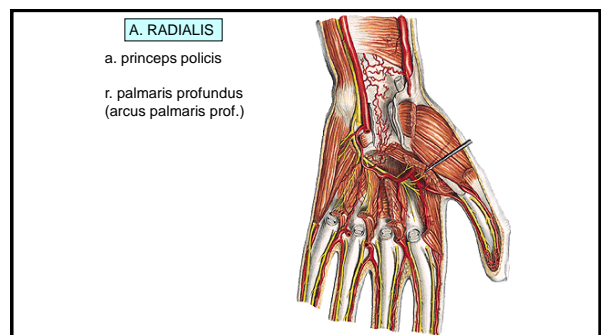
33



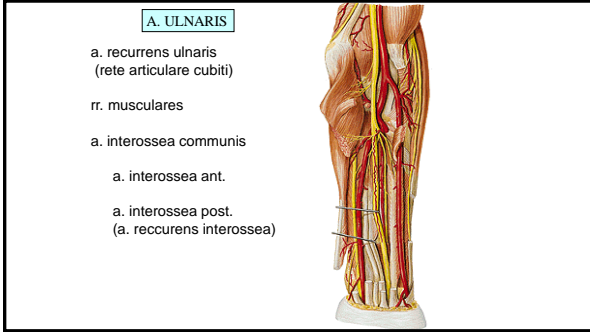
34



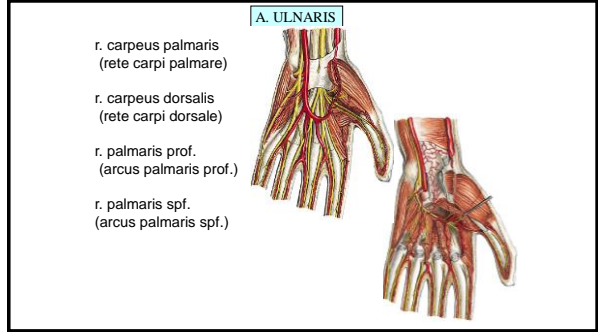
35



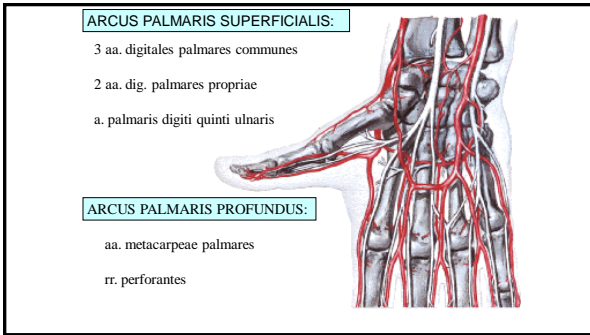
36



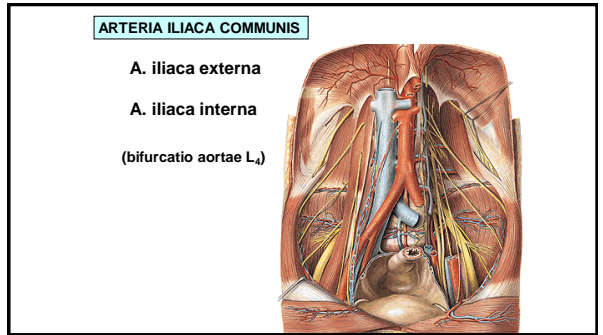
37



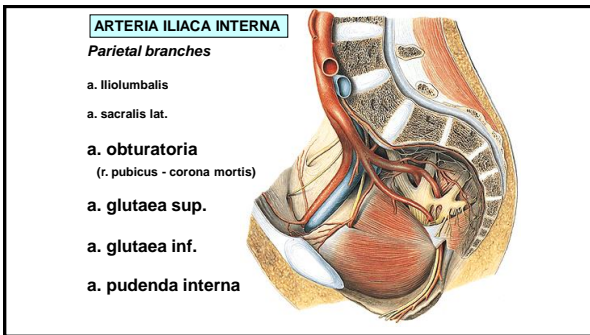
38



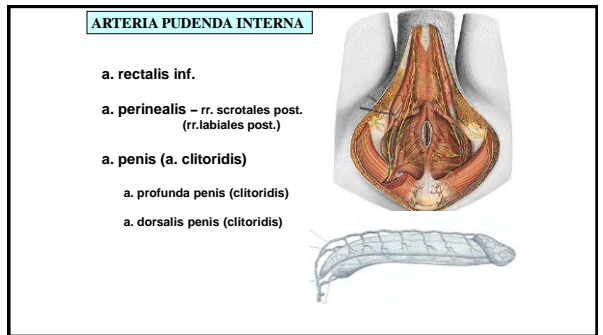
39



40



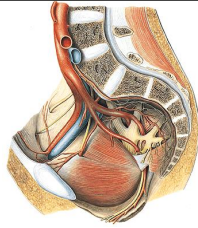
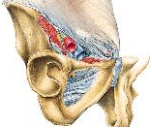41



42

ARTERIA ILIACA EXTERNA

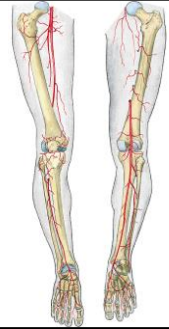- a. epigastrica inf.
- r. pubicus (corona mortis)
- a. cremasterica
(a. ligamenti teretis)
- a. circumflexa ilium profunda



43

ARTERIES OF THE LOWER EXTREMITY

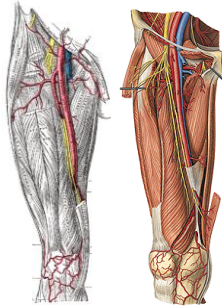
- a. femoralis
(lacuna vasorum, trigonum femorale, canalis adductorius, hiatus tendineus)
- a. poplitea
(fossa poplitea)
- a. tibialis anterior
(a. dorsalis pedis)
- a. tibialis posterior
(malleolus medialis, a. plantaris medialis, a. plantaris lateralis)



44

ARTERIA FEMORALIS

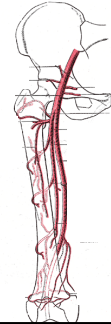
- A. epigastrica spf.
- A. circumflexa ilium spf.
- Aa. pudendae ext.
- A. profunda femoris
- Rr. musculares
- A. genus descendens



45

ARTERIA PROFUNDA FEMORIS

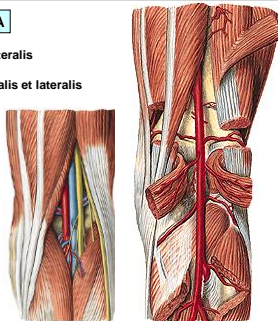
- A. circumflexa femoris medialis
(r. superficialis et profundus)
- A. circumflexa femoris lat.
(r. ascendens et descendens)
- A. perforans prima
(a. nutritia femoris sup.)
- A. perforans secunda
- A. perforans tertia
(a. nutritia femoris inf.)



46

ARTERIA POPLITEA

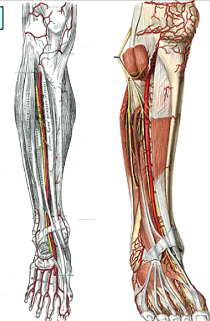
- A. suralis medialis et lateralis
- A. genus superior medialis et lateralis
- A. genus media
- A. genus inferior medialis et lateralis
- A. tibialis ant.
- A. tibialis post.



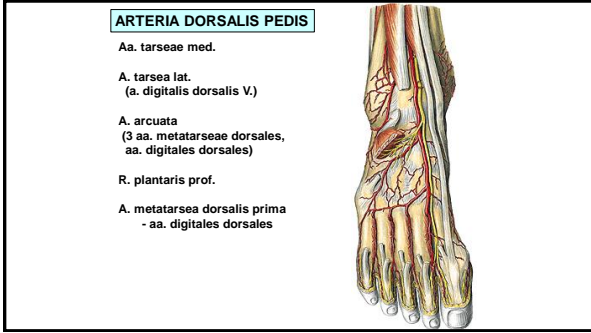
47

ARTERIA TIBIALIS ANTERIOR

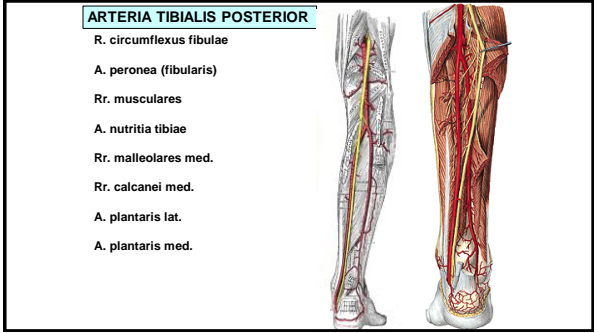
- A. recurrens tibialis post.
- A. recurrens tibialis ant.
- Rr. musculares
- A. malleolaris ant. med. et lat.
- A. dorsalis pedis



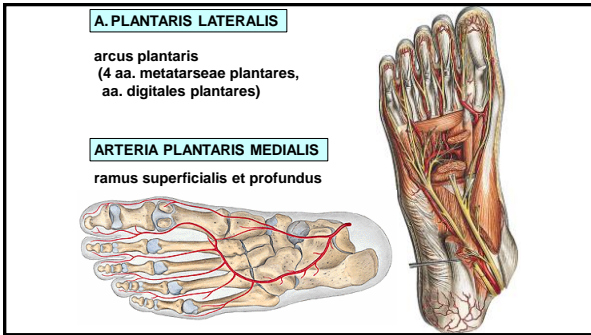
48



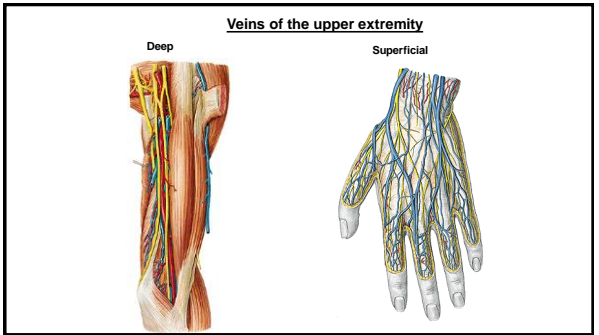
49



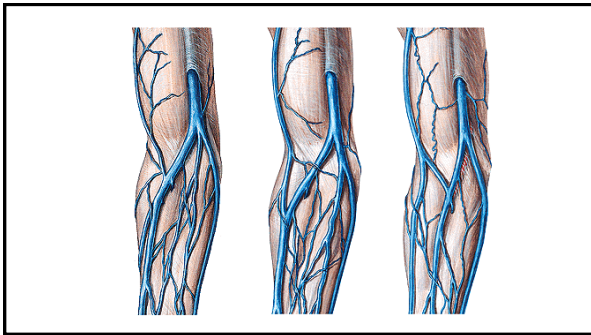
50



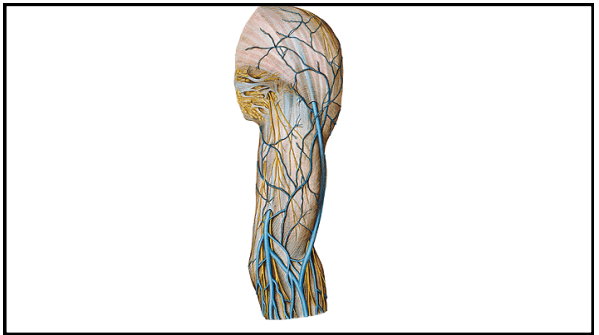
51



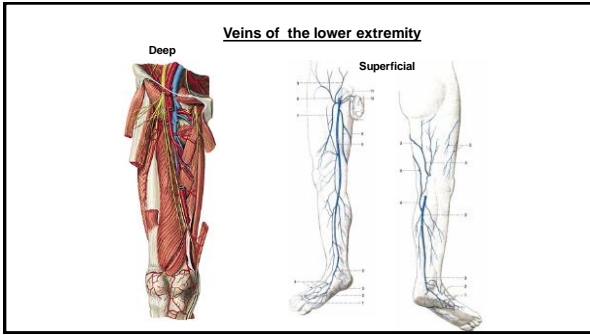
52



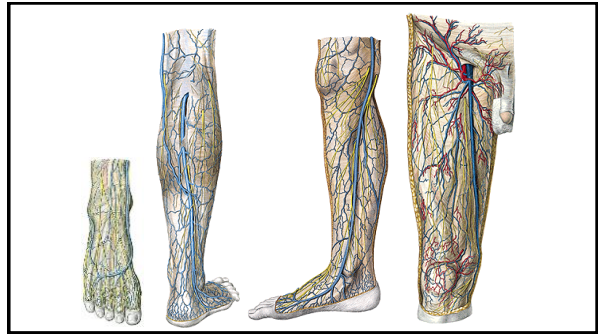
53



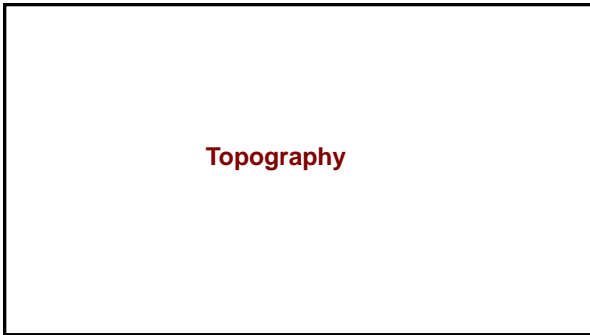
54



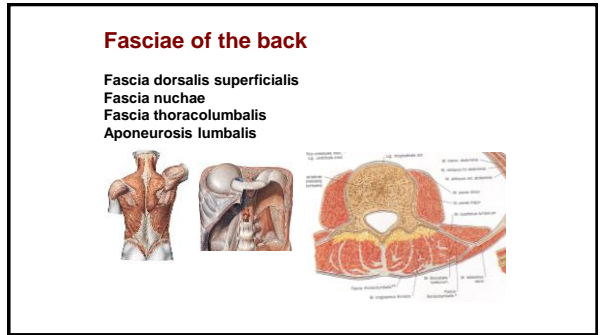
55



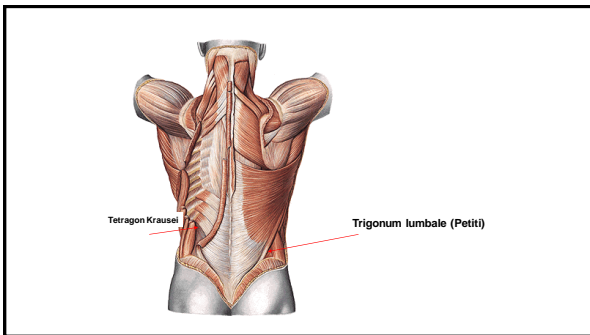
56



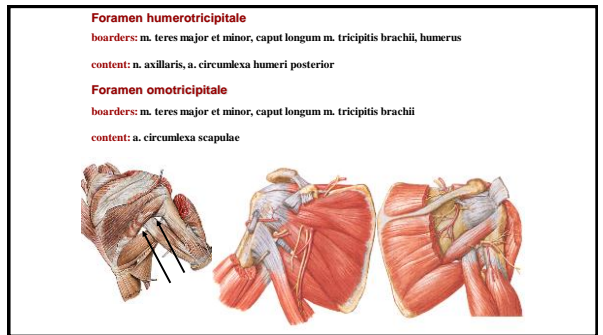
57



58



59



60

Fossa axillaris

Ventral wall:
Tendon of the m. pectoralis major

Dorsal wall:
m. latissimus dorsi and m. teres major

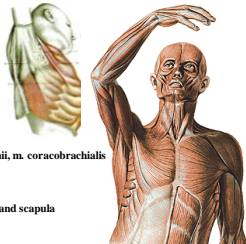
Medial wall:
Chest and m. serratus anterior

Lateral wall:
humerus, caput breve m. bicipitis brachii, m. coracobrachialis

Base - fascia axillaris

apex- 1. rib, lateral part of the clavicle and scapula

Content: plexus brachialis, a. axillaris



61

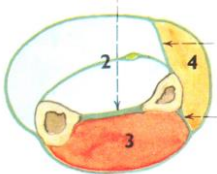
Fascia antebrachii

Connected with dorsal side of ulna

septum intermusculare ant.

septum intermusculare post.

retinaculum flexorum et extensorum



64

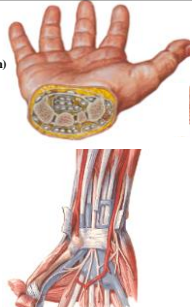
Eminentia carpi radialis et ulnaris

Retinaculum flexorum (lig. carpi transversum)

Canalis carpi:

Radial part: m. flexor carpi radialis

Ulnar part: m. flexor digitorum superficialis
m. flexor digitorum profundus
m. flexor pollicis longus
nervus medianus



65

Vaginae synoviales of flexors

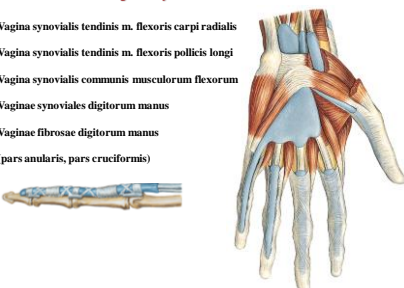
Vagina synovialis tendinis m. flexoris carpi radialis

Vagina synovialis tendinis m. flexoris pollicis longi

Vagina synovialis communis musculorum flexorum

Vaginae synoviales digitorum manus

Vaginae fibrosae digitorum manus (pars annularis, pars cruciformis)

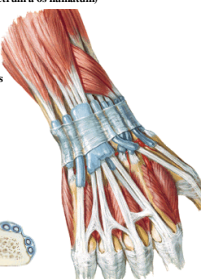


66

Vaginae synoviales of the extensors

Retinaculum extensorum (radius - os triquetrum a os hamatum)

- m. abductor pollicis longus
m. extensor pollicis brevis
- m. extensor carpi radialis longus et brevis
- m. extensor pollicis longus
- m. extensor indicis
m. extensor digitorum communis
- m. extensor digiti minimi
- m. extensor carpi ulnaris



67

Fasciae manus

Fascia dorsalis manus superficialis

Fascia dorsalis manus intertendinea

Fascia dorsalis manus interossea

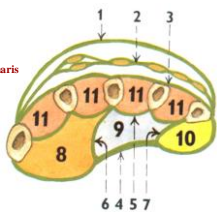

Fascia palmaris superficialis - **aponeurosis palmaris**

Fascia palmaris interossea

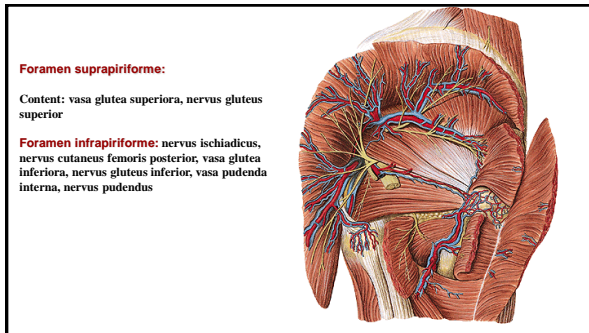
Septum palmare radiale (3rd metacarpal bone)

Septum palmare ulnare (5th metacarpal bone)

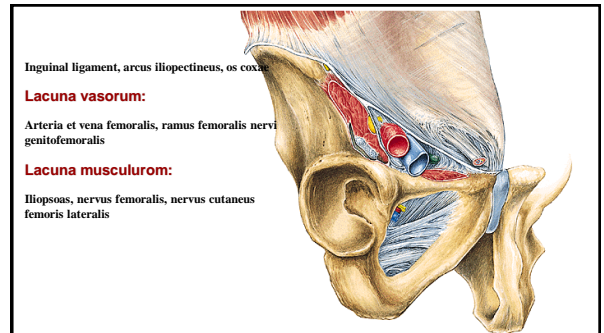
Spatium palmare radiale, ulnare, medium

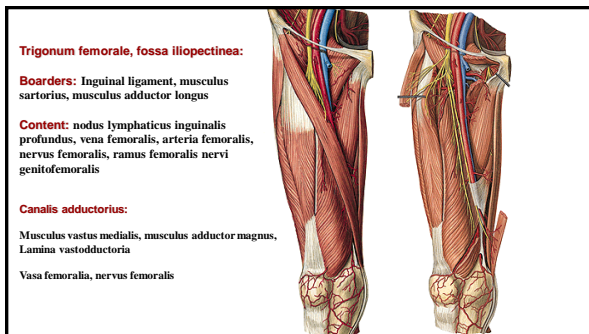
68



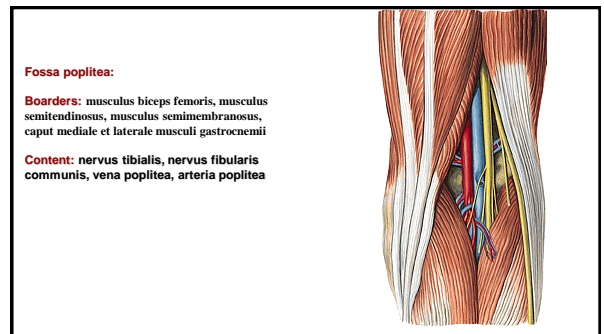
69



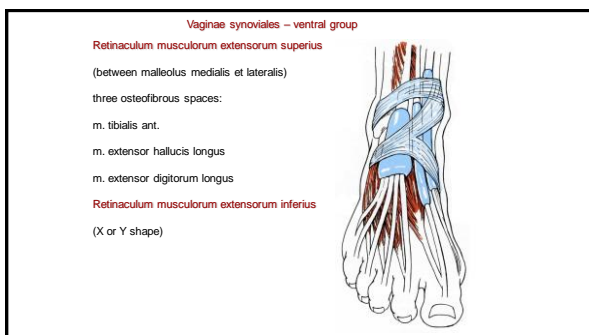
70



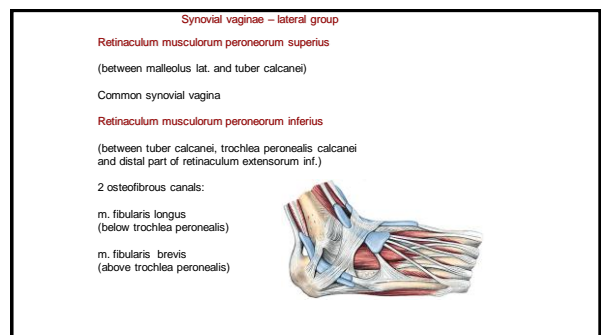
71



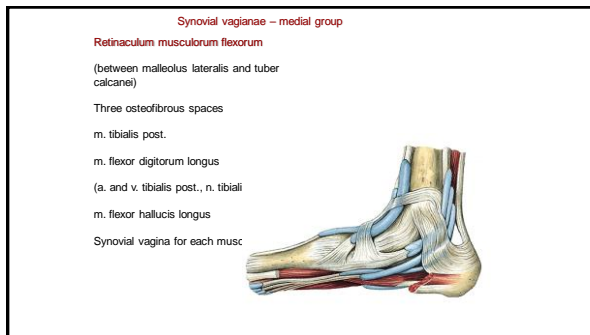
72



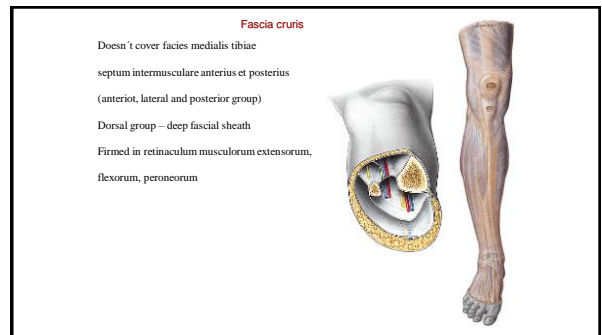
73



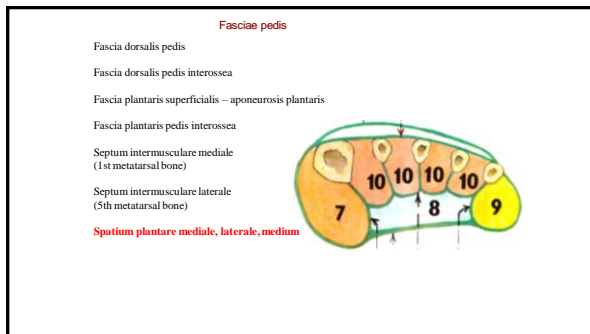
74



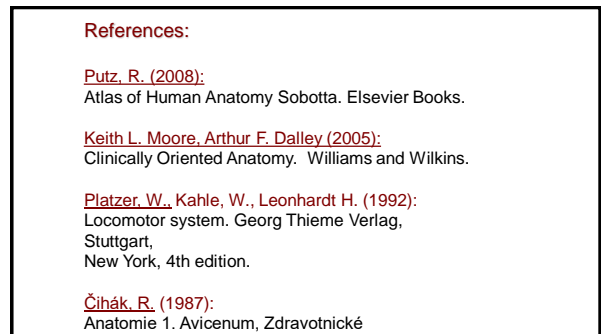
75



76



77



78