

M U N I

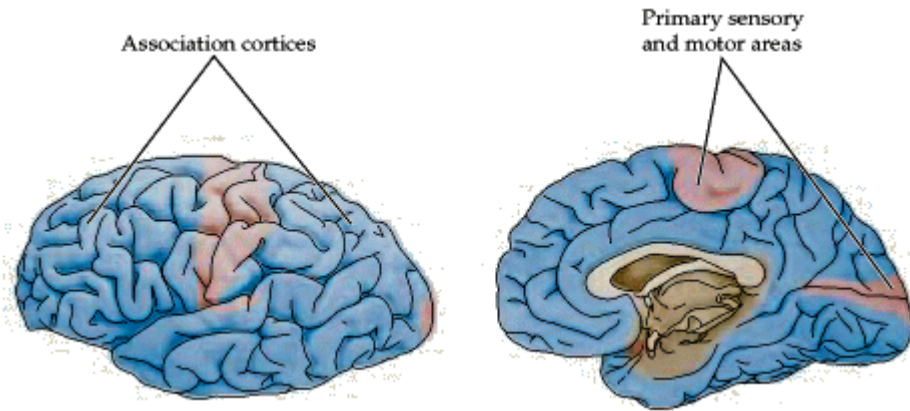
M E D

M U N I
M E D

16

Neocortex II

Neocortex

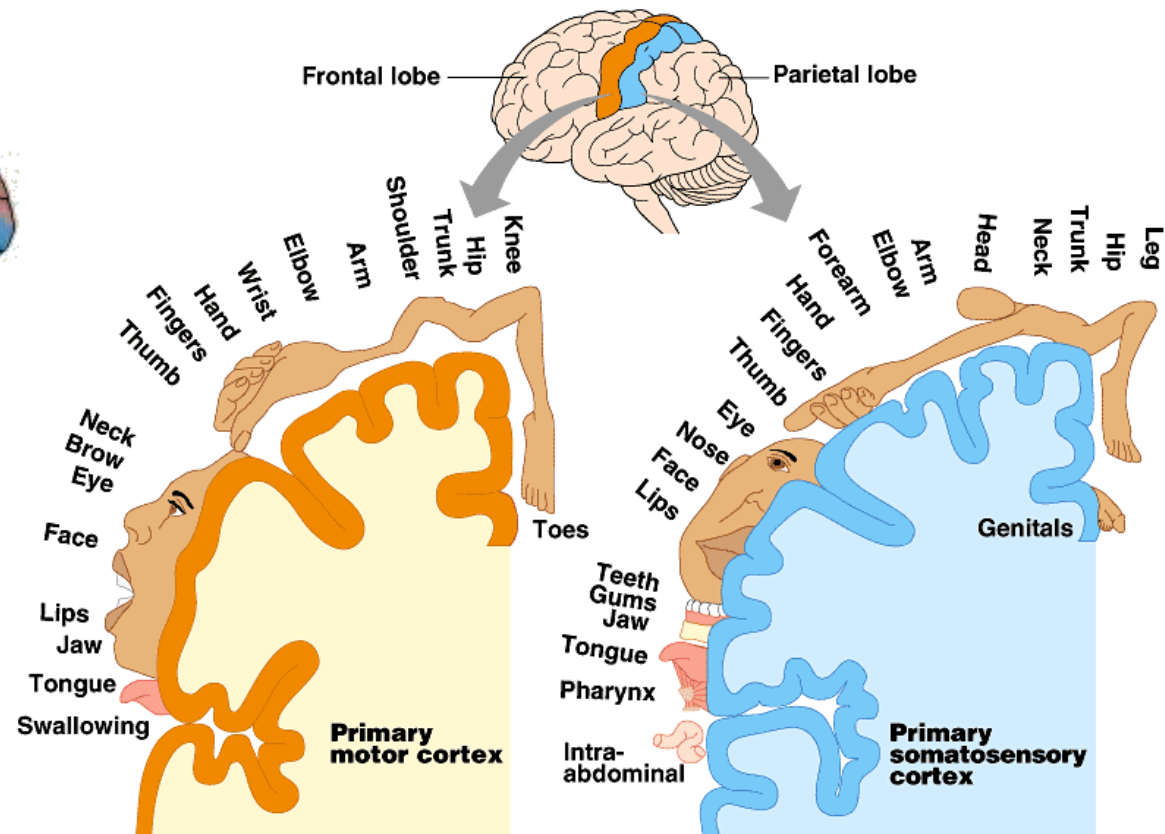
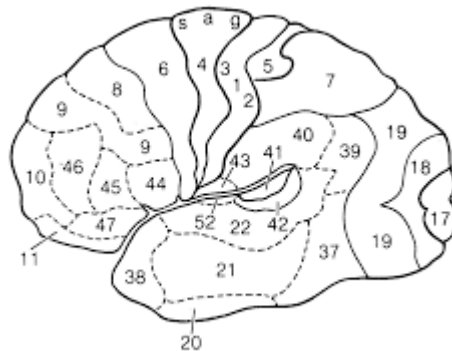


Primary areas

- ✓ Somatotopic organization

Association areas

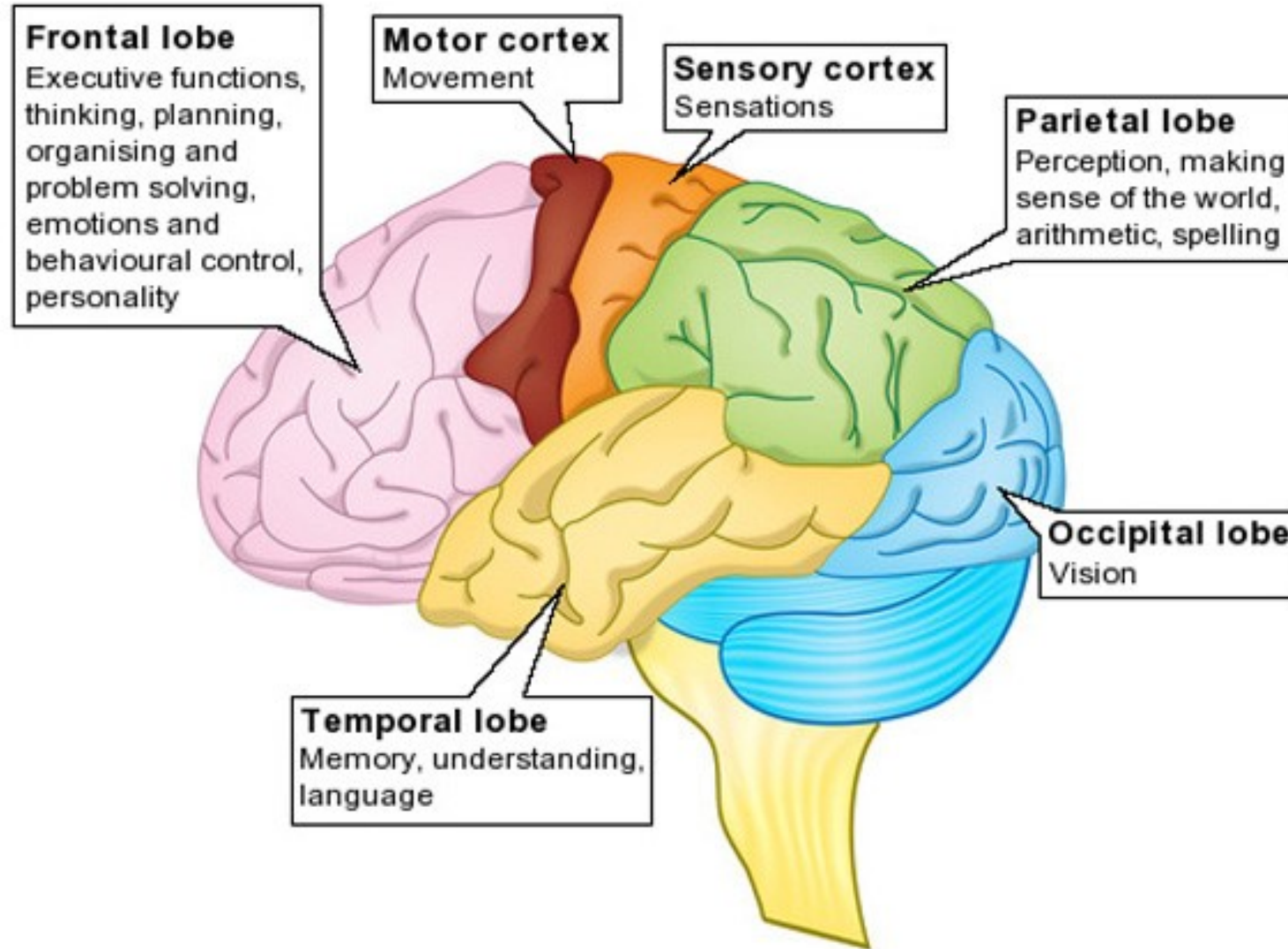
- ✓ No somatotopic organization



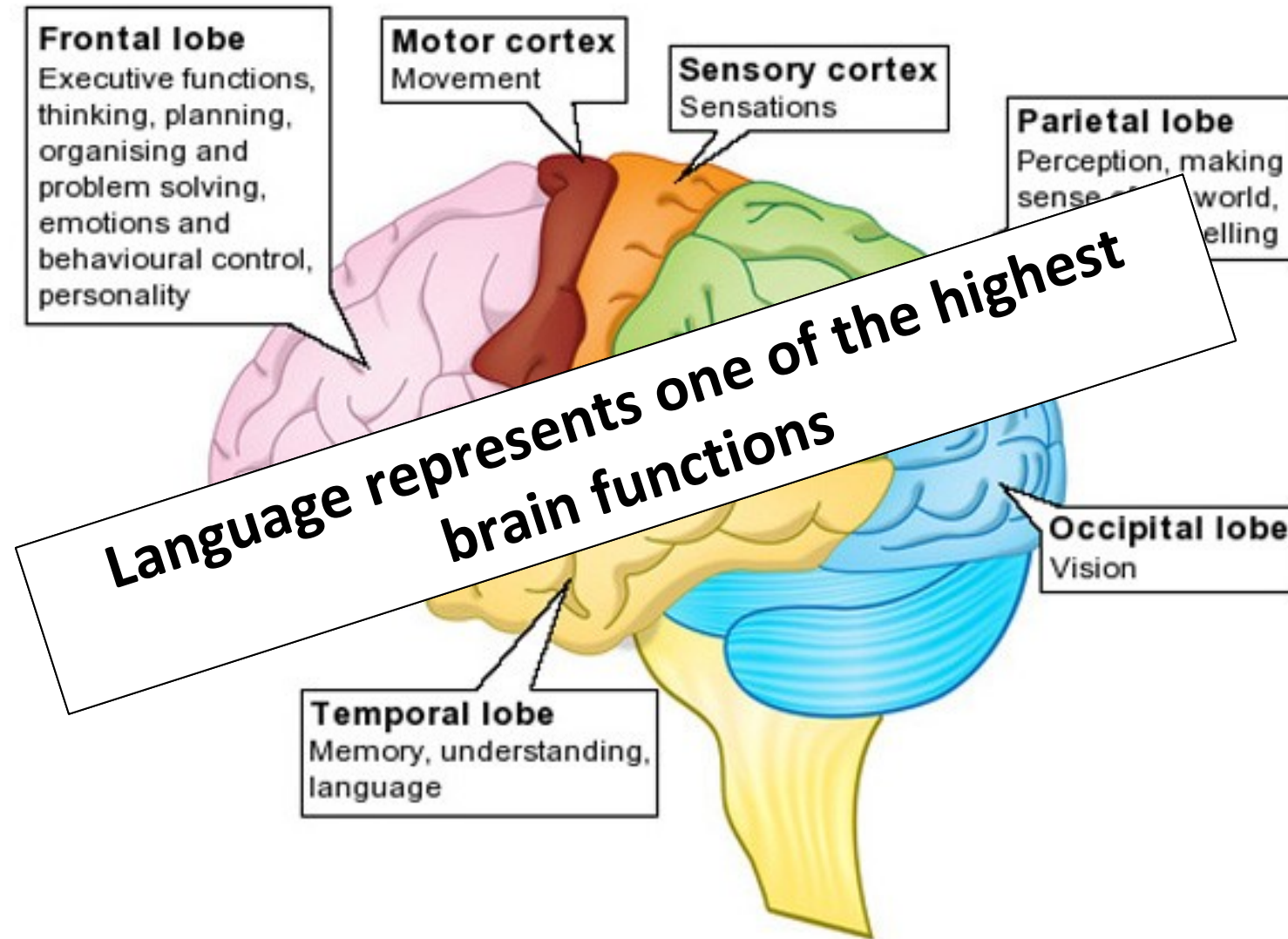
Copyright © Pearson Education, Inc., publishing as Benjamin Cummings.

<http://www.emunix.emich.edu>

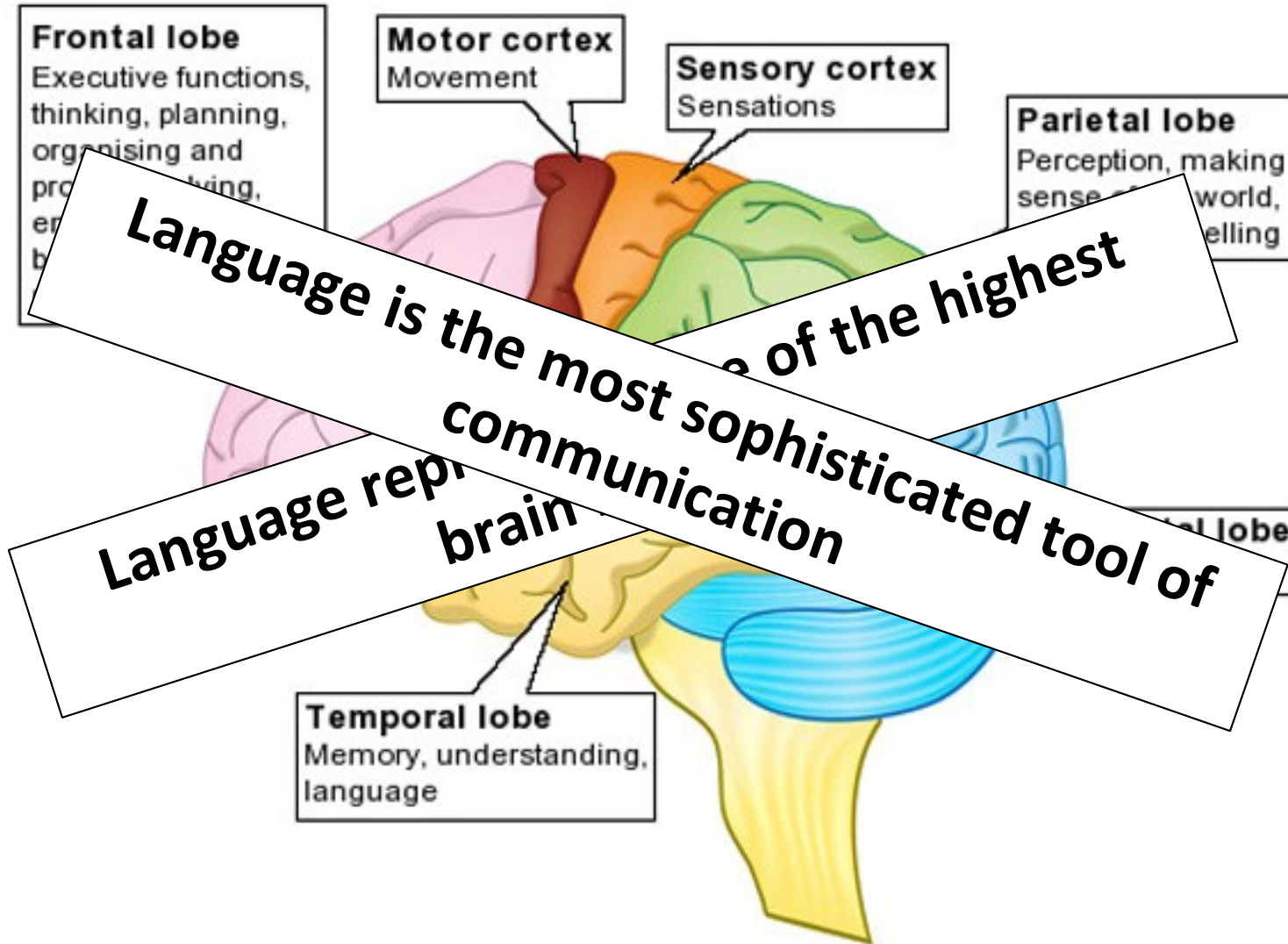
Cortical functions



Cortical functions

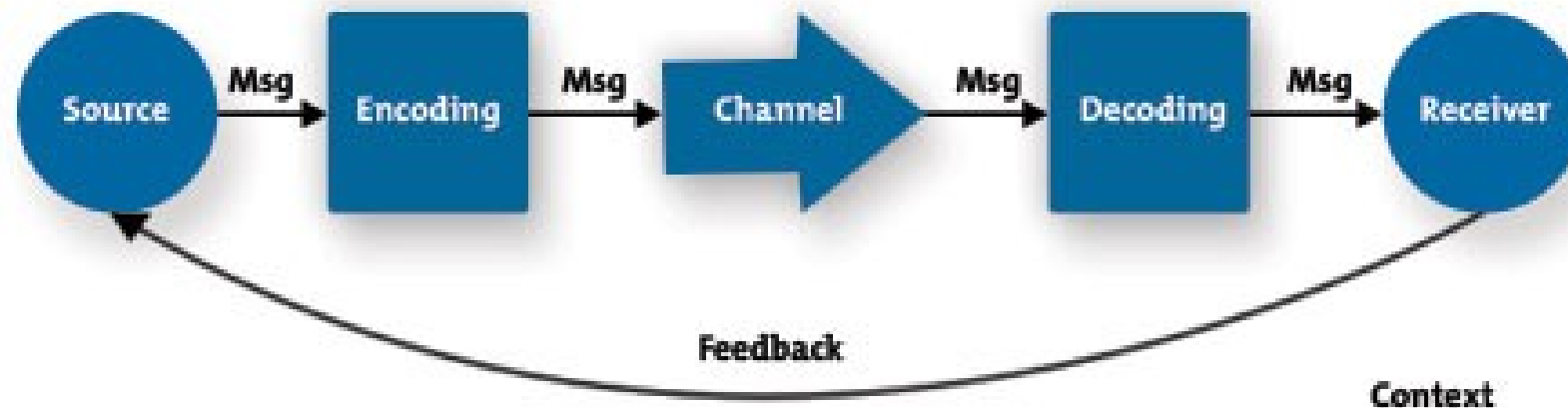


Cortical functions



Communication

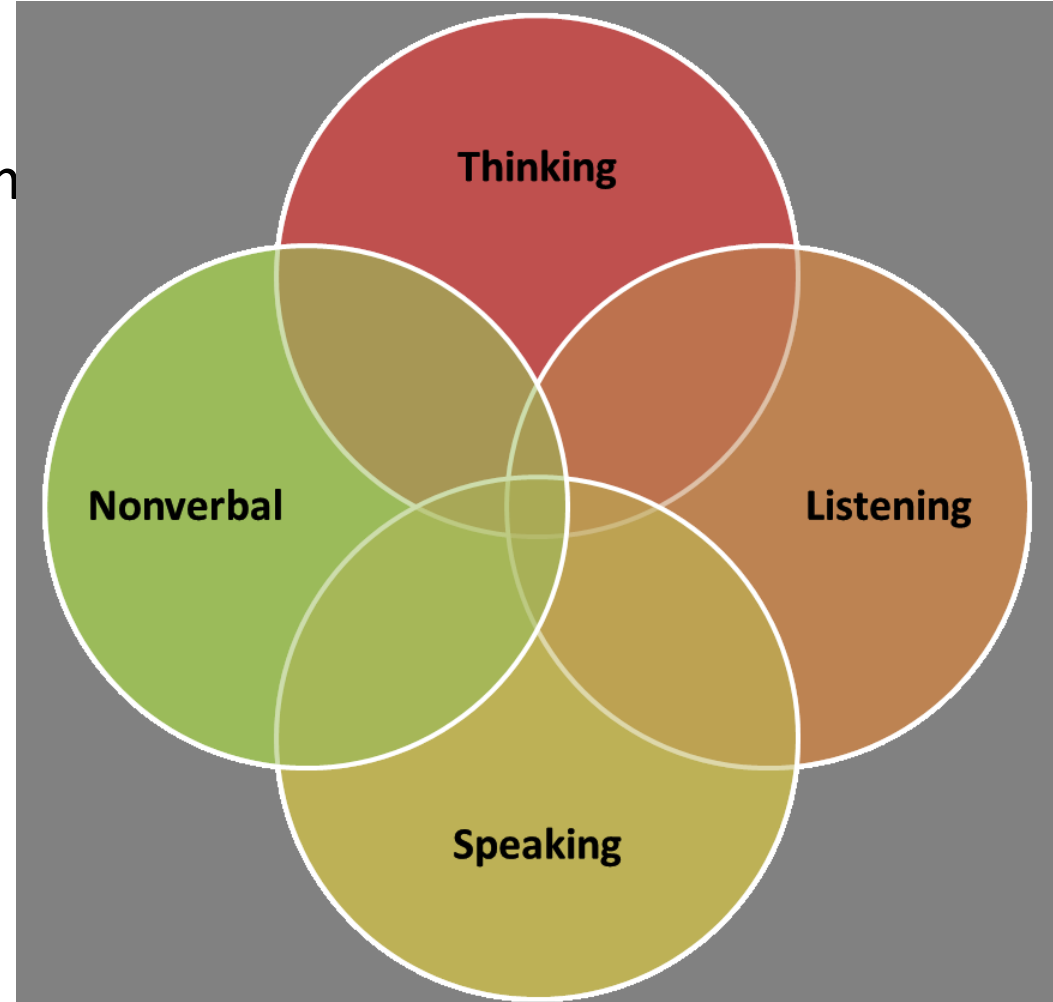
- Signal exchange
 - ✓ Smell
 - ✓ Visual
 - ✓ Acoustic
- Encoding
 - ✓ Simple – body size
 - ✓ Complex – dance of the honey bee
- Between individuals of
 - ✓ Same species
 - ✓ Different species



<https://www.mindtools.com/media/Diagrams/CommunicationsProcess.jpg>

Communication in human society

- Non-verbal
 - Hard to control
 - Influence of limbic system
- Verbal
 - Fully controllable
 - Neocortex



<https://s-media-cache-ak0.pinimg.com/originals/93/dc/42/93dc4240059a0635eed4d672c98c343c.png>

Language

- The most sophisticated tool of communication
- Language is characteristic that defines the human species
 - No human society without language
 - No other species that have a language
- Language was a precondition for development of complex society and development of culture



Language

- The ability to acquire and use complex systems of communication, particularly the human ability to do so



<http://parsleysinmissions.org/images/postimages/language.jpg>

Language

- The ability to acquire and use complex systems of communication, particularly the human ability to do so
- Complex hierarchic code
- Syllable
 - Unit of organization for a sequence of speech sounds



<http://parsleysinmissions.org/images/postimages/language.jpg>

Language

- The ability to acquire and use complex systems of communication, particularly the human ability to do so
- Complex hierarchic code
 - Syllable
 - Unit of organization for a sequence of speech sounds
 - Word
 - Symbol with a meaning



<http://parsleysinmissions.org/images/postimages/language.jpg>

Language

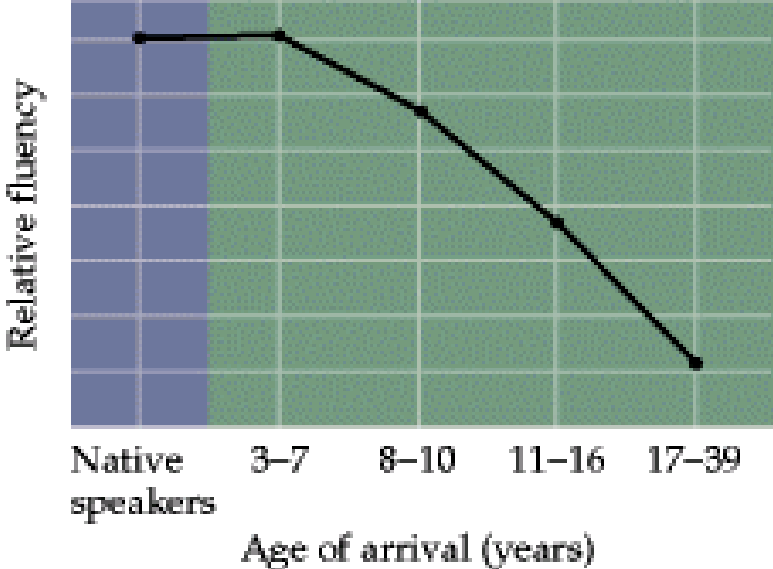
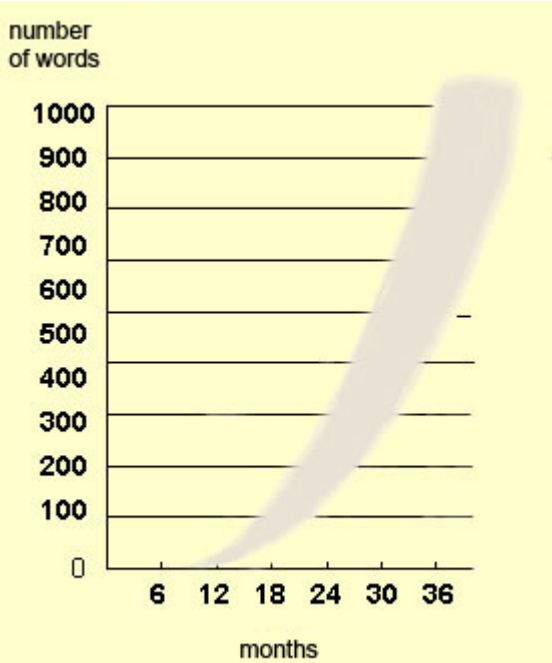
- The ability to acquire and use complex systems of communication, particularly the human ability to do so
- Complex hierarchic code
 - Syllable
 - Unit of organization for a sequence of speech sounds
 - Word
 - Symbol with a meaning
 - Sentence
 - A group of words organized according to the rules of syntax



<http://parsleysinmissions.org/images/postimages/language.jpg>

Learning to speak

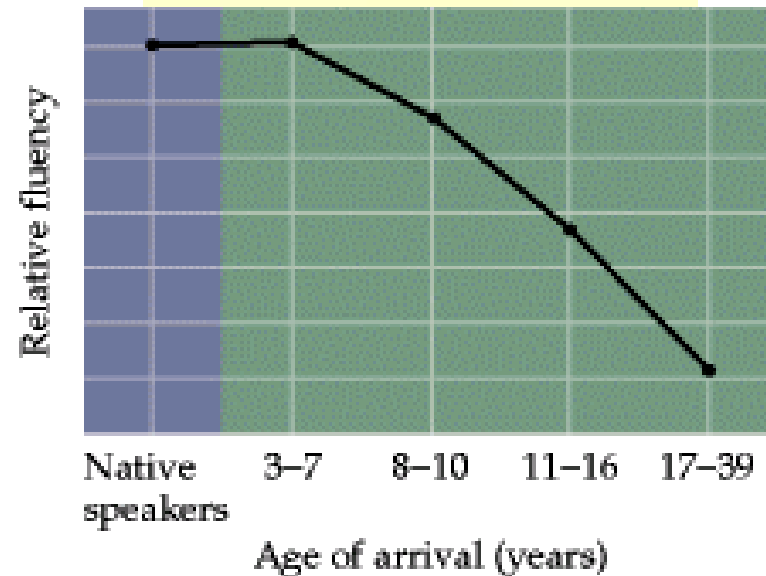
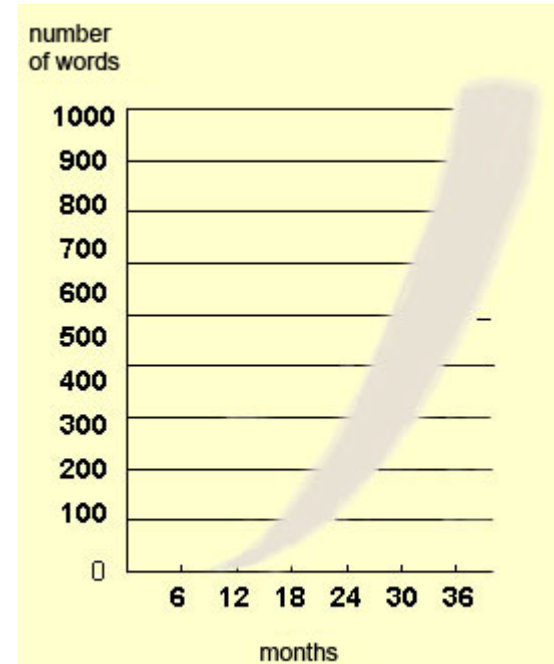
- Learning to speak takes a long time period
 - Understanding – „sensoric“
 - Speaking – „motor action“



<http://www.slideshare.net/drpsdeb/presentations>

Learning to speak

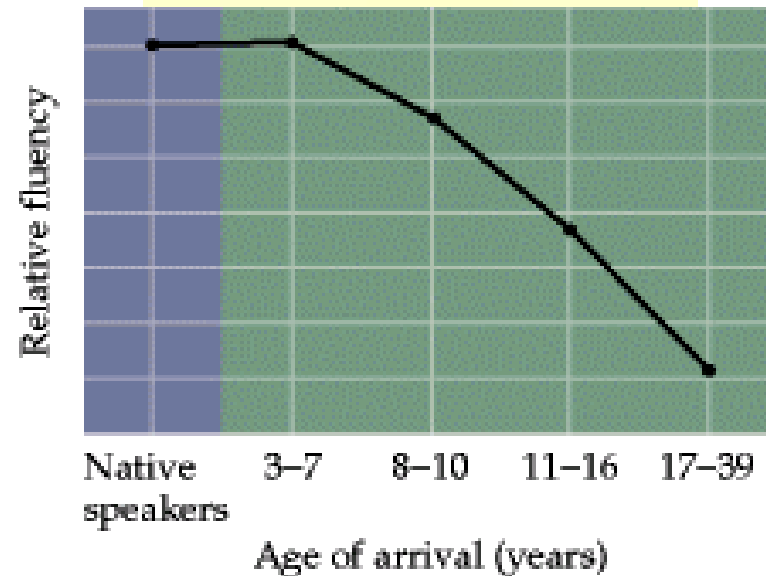
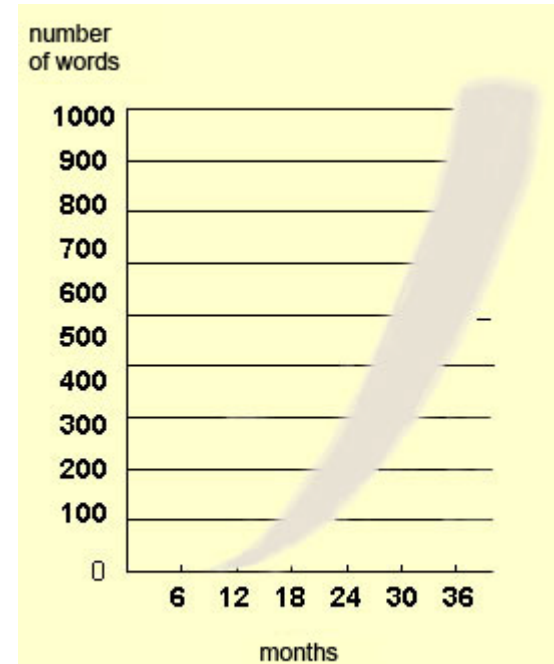
- Learning to speak takes a long time period
 - Understanding – „sensoric“
 - Speaking – „motor action“
- 7.-12. month – baby begins to understand simple orders
- 1. year – baby uses a couple of words
- 2.-5. years – baby masters syntax rules
- 6. years – child uses around 2500 words



<http://www.slideshare.net/drpsdeb/presentations>

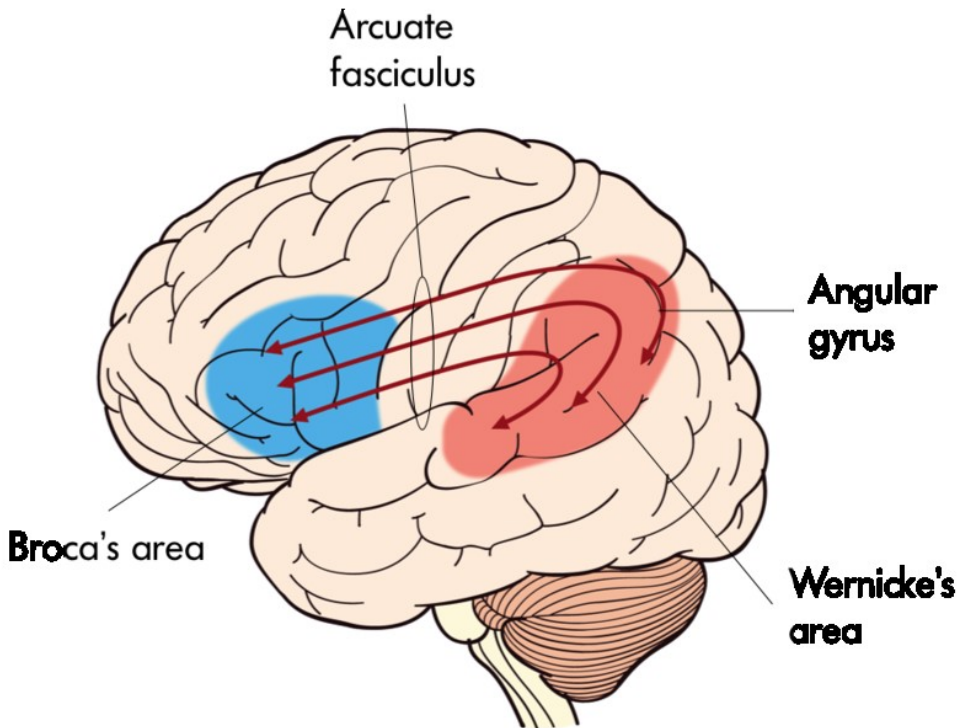
Learning to speak

- Learning to speak takes a long time period
 - Understanding – „sensoric“
 - Speaking – „motor action“
- 7.-12. month – baby begins to understand simple orders
- 1. year – baby uses a couple of words
- 2.-5. years – baby masters syntax rules
- 6. years – child uses around 2500 words
- Adult vocabulary
 - Active: 3000 -10 000 words
 - Passive: 3-6x higher than active v.



<http://www.slideshare.net/drpsdeb/presentations>

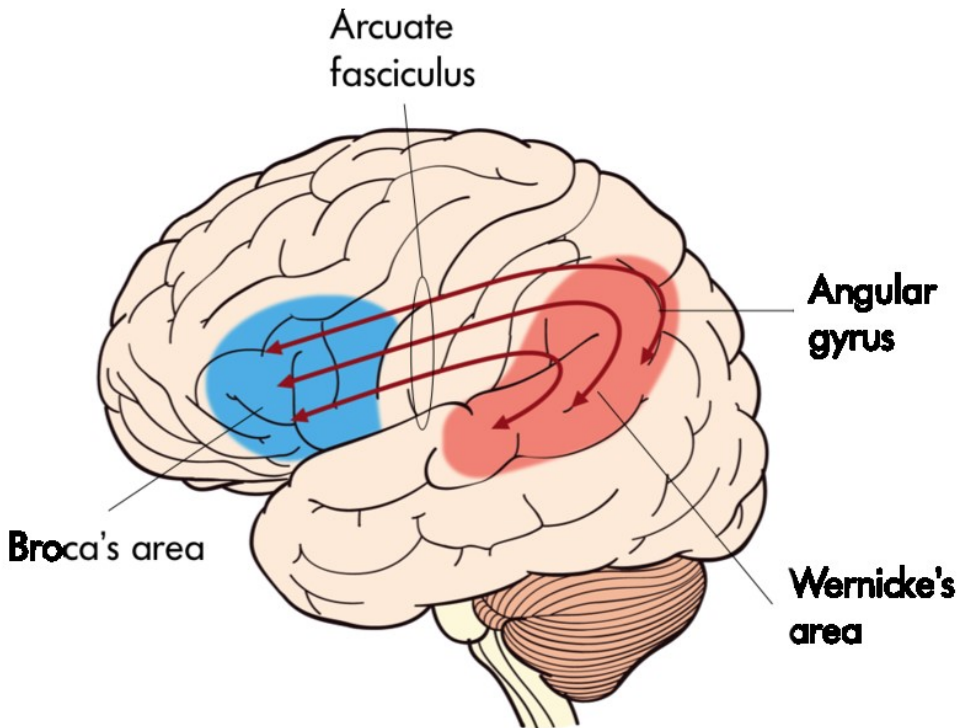
language areas



<http://www.slideshare.net/CsillaEgri/presentations>

There are two main language areas

- Broca's area (motor)
 - ✓ Close to motor cortex
- Wernicke's area (sensor)
 - ✓ Close to auditory cortex
- Fasciculus arcuatus



<http://www.slideshare.net/CsillaEgri/presentations>

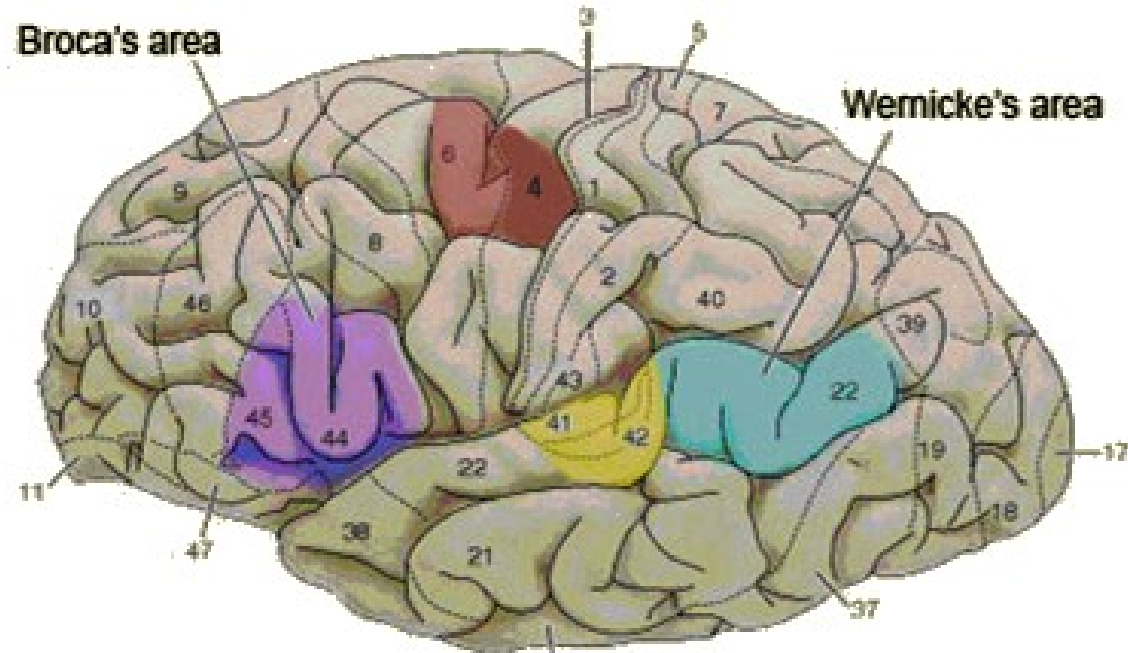
language areas

- Broca's aphasia
 - ✓ Motor, expressive
 - ✓ Comprehension preserved, speech unarticulated
- Wernicke's aphasia
 - ✓ perceptive, sensor
 - ✓ Comprehension damaged, speech fluent, but not meaningful
- Conduction aphasia
 - ✓ Damage of fasc. arcuatus
 - ✓ Speech fluent, comprehension preserved
 - ✓ Problem with repeating words and sentences
- Dysarthria
 - ✓ Problem with articulation
 - ✓ For example, damage of vocal cord ...

There are two main language areas

- Broca's area (motor)
 - ✓ Close to motor cortex
- Wernicke's area (sensor)
 - ✓ Close to auditory cortex
- Fasciculus arcuatus

Broca's area



<http://www.slideshare.net/drpsdeb/presentations>

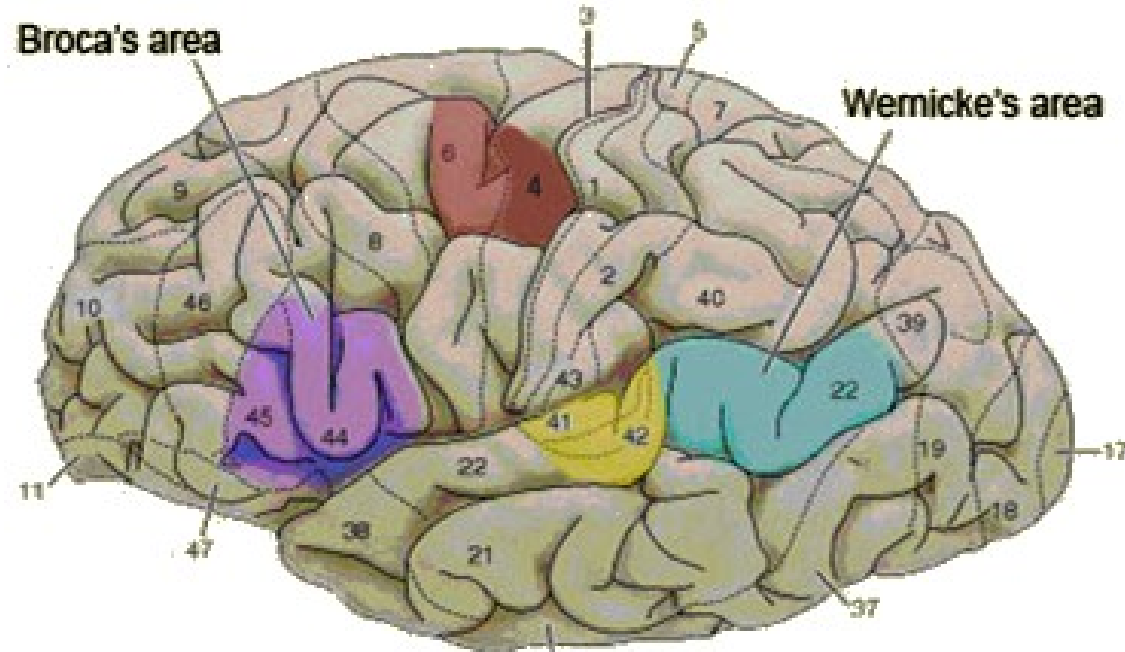
Area 45

- ✓ Semantic processing
„selection and manipulation with appropriate words“

Area 44

- ✓ Phonological processing and language production
„selection and activation of particular motor centers“

Wernicke's area



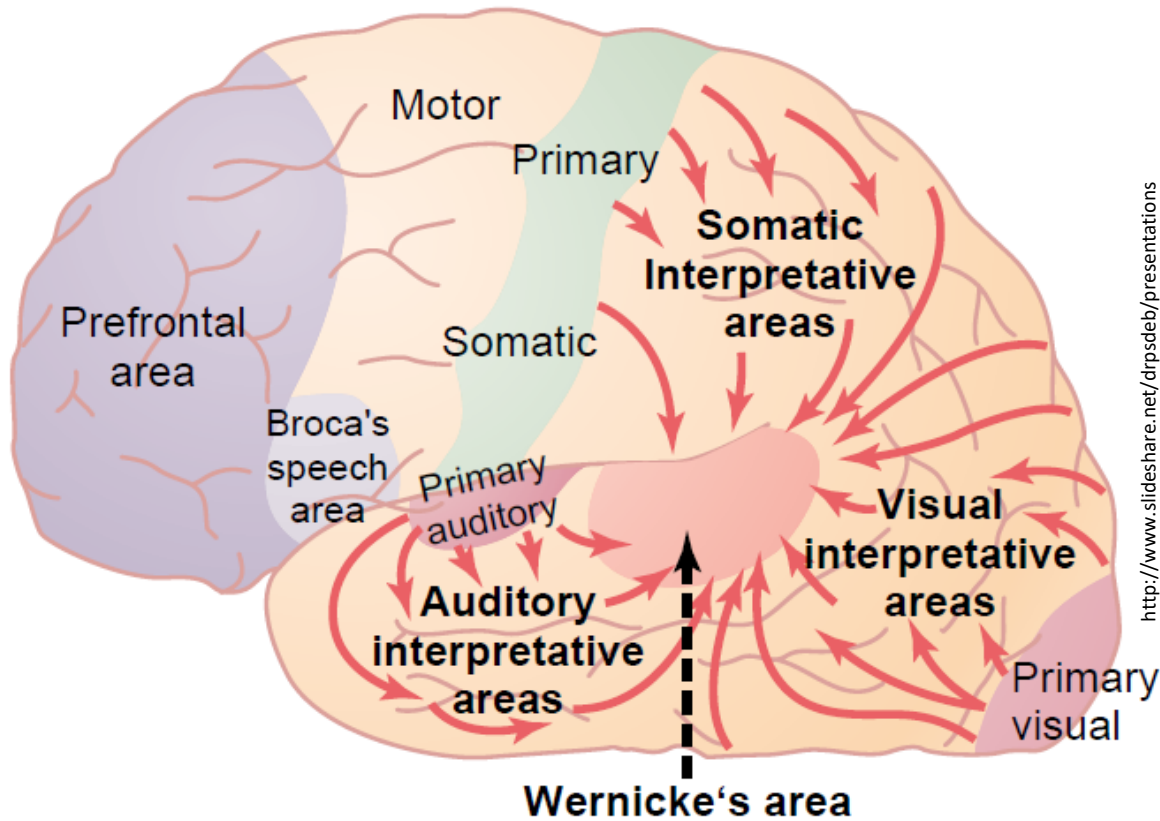
<http://www.slideshare.net/drpsdeb/presentations>

Area 22

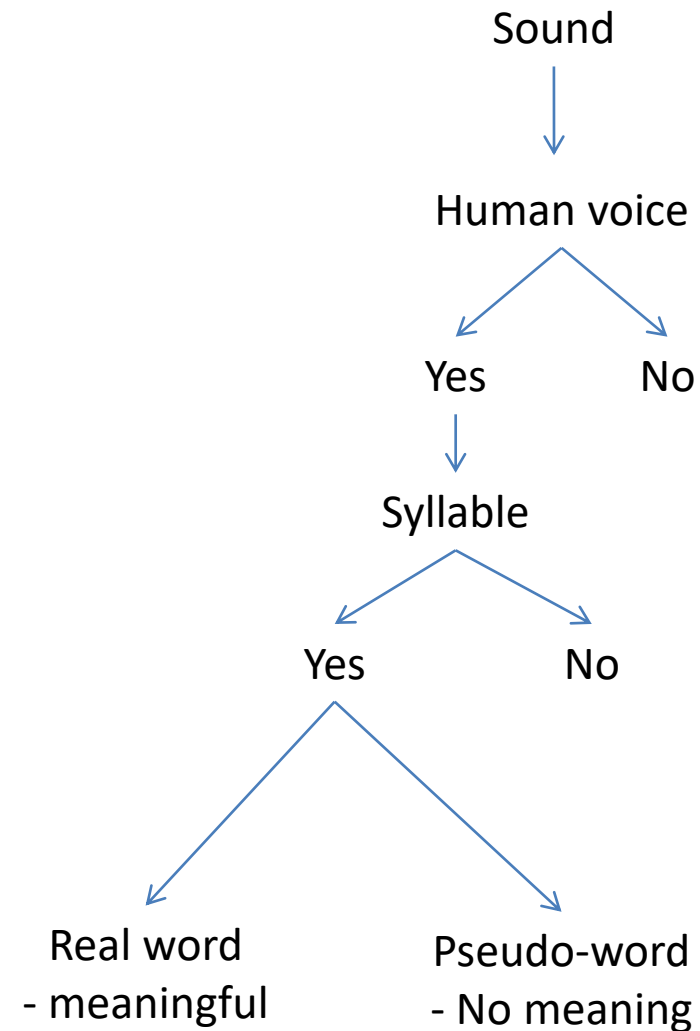
✓ Three subdivisions

1. The first responds to spoken words (including the individual's own) and other sounds
2. The second responds only to words spoken by someone else but is also activated when the individual recalls a list of words.
3. The third sub-area seems more closely associated with producing speech than with perceiving it

Algorithm of sound processing

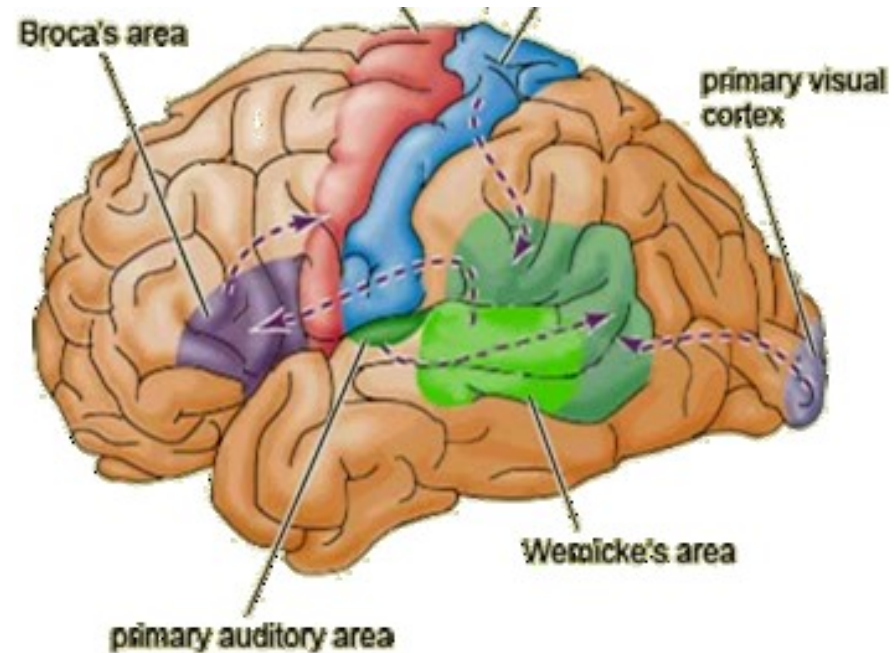
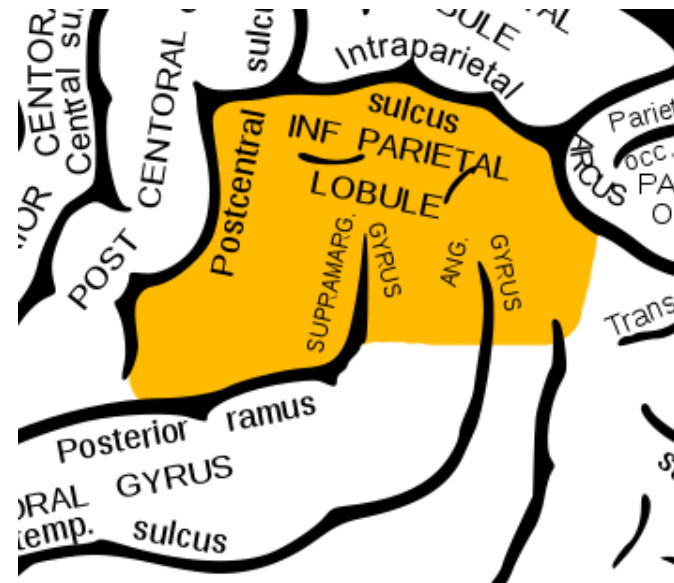


- ✓ Wernicke's area
- ✓ Broca's area
- ✓ P-O-T association cortex



Lobulus parietalis inferior

https://en.wikipedia.org/wiki/Inferior_parietal_lobe#/media/File:Gray726_inferior_parietal_lobe.png



<http://www.slideshare.net/CsillaEgri/presentations>

Gyrus supramarginalis (Area 40)

- ✓ Phonological and articulatory processing of words

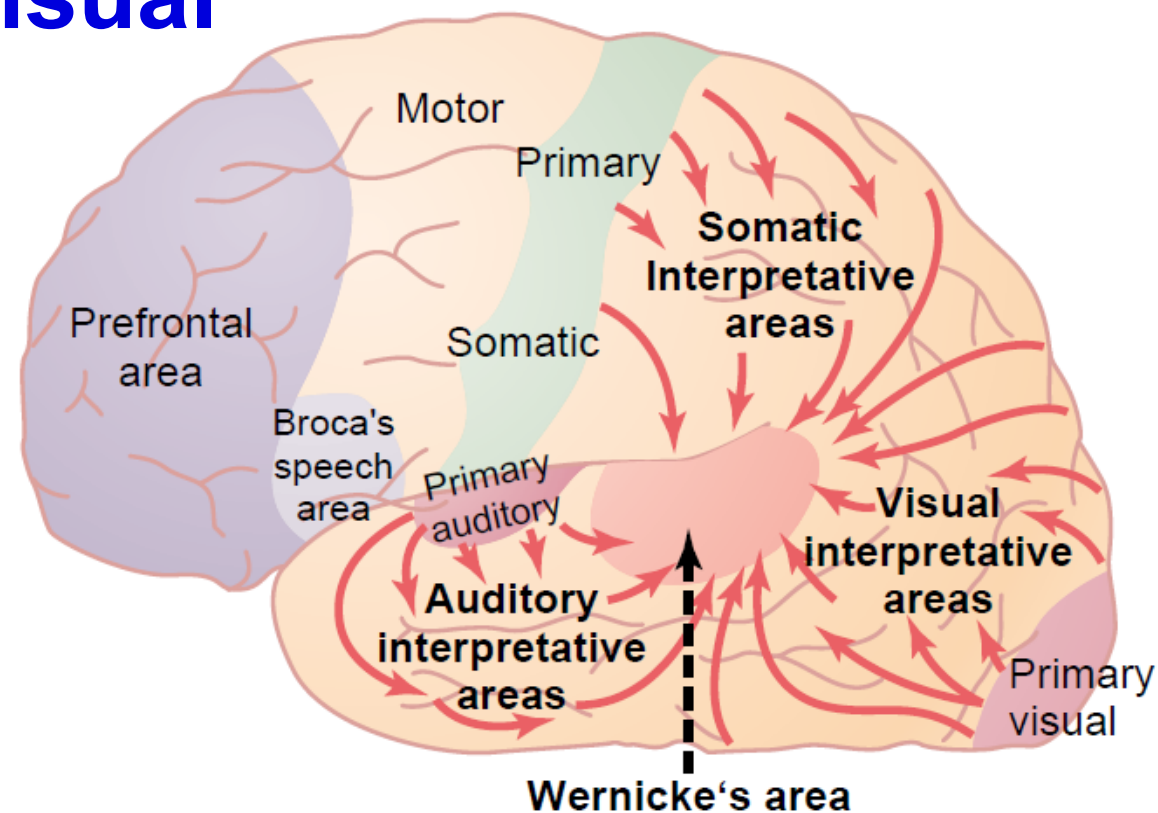
Gyrus angularis (Area 39)

- ✓ Semantic processing

Rich communication with Broca's and Wernicke's areas (triangular communication)

Integration of auditory, visual and somatosensory information

Integration of auditory, visual and somatosensory information



P - O - T association cortex

Lobulus parietalis inferior

- Interpretation of sound
- Interpretation of visual signal
- Interpretation of somatosensation
- Interpretation of spoken/read word

Lobulus parietalis inferior

- Late evolutionary as well as ontogenic development
- Fully developed at the age of 5 – 6 years
 - Children usually cannot „actively“ read before this age (understand the meaning of the text which he/she reads)

Lobulus parietalis inferior

- Late evolutionary as well as ontogenic development
- Fully developed at the age of 5 – 6 years
 - Children usually cannot „actively“ read before this age (understand the meaning of the text which he/she reads)
- The language functions algorithms are also involved in complex „inner“ categorization
- The language („both spoken and inner“) enabled development of complex (abstract) thinking and development of culture

Lobulus parietalis inferior

- Late evolutionary as well as ontogenic development
- Fully developed at the age of 5 – 6 years
 - Children usually cannot „actively“ read before this age (understand the meaning of the text which he/she reads)
- The language functions algorithms are also involved in complex „inner“ categorization
- The language („both spoken and inner“) enabled development of complex (abstract) thinking and development of culture
- The human society development is linked to information technology development
 - ✓ Spoken language
 - ✓ A system of writing
 - ✓ Printing
 - ✓ Internet

Language functions lateralization

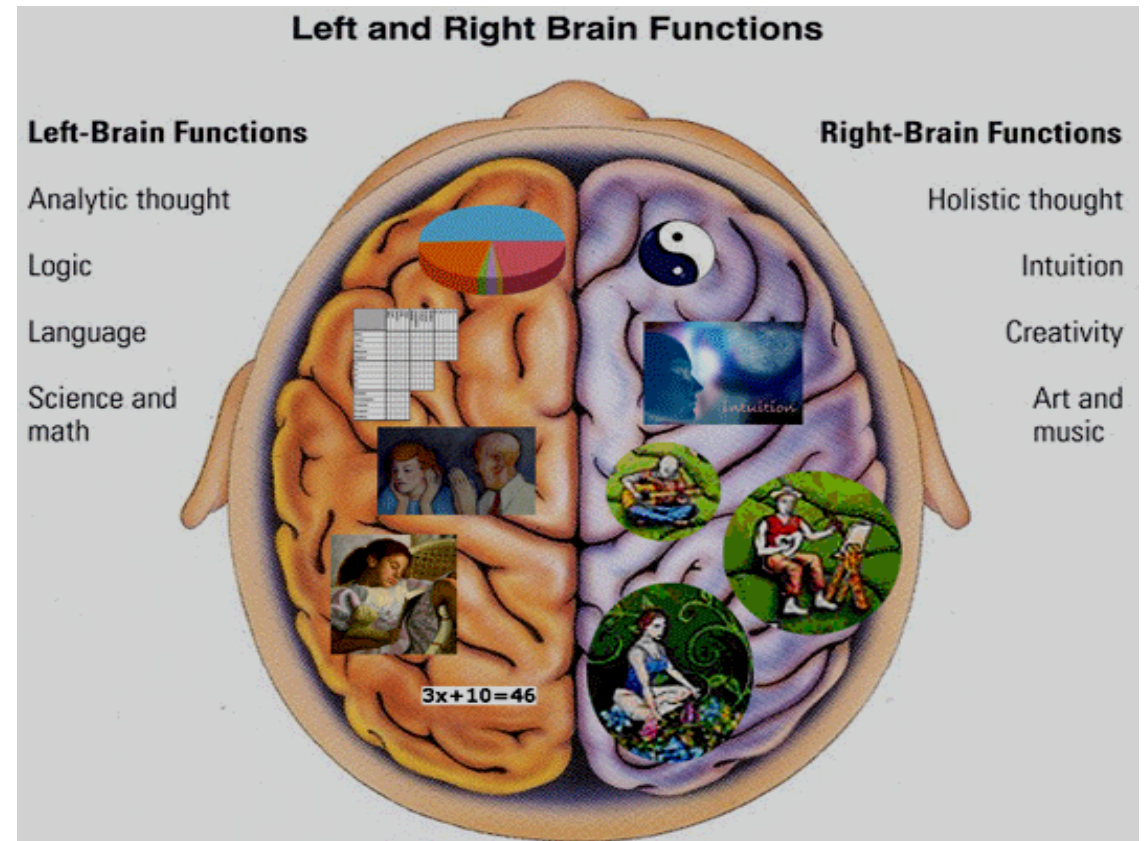
- Broca's and Wernicke's area is localized in the left hemisphere in 97% of people
- Localization of B-W areas is not fully linked to left/right hand lateralization
 - ✓ 90% of people are right handed
 - ✓ 95% of right handed people have B-W area in the left hemisphere
 - ✓ The majority of left handed people has B-W areas also in left hemisphere

Language functions lateralization

- Broca's and Wernicke's area is localized in the left hemisphere in 97% of people
- Localization of B-W areas is not fully linked to left/right hand lateralization
 - ✓ 90% of people are right handed
 - ✓ 95% of right handed people have B-W area in the left hemisphere
 - ✓ The majority of left handed people has B-W areas also in left hemisphere
- Some scientists suggest that the left hemisphere dominance for language evolved from this hemisphere's better motor control
- The language specialization develops in the left hemisphere, which matures slightly earlier

Right hemisphere language functions

- Non-verbal aspect of language
 - ✓ Prosody – intonation, stress...
- Non-literal language aspects
 - ✓ Irony
 - ✓ Metaphors
- Understanding to discourse / complex speech
 - ✓ Lecture, discussion



<http://www.slideshare.net/drpsdeb/presentations>

Women and language

- Females' speech is more fluent
 - they can pronounce more words or sentences in a given amount of time

Women and language

- Females' speech is more fluent
 - they can pronounce more words or sentences in a given amount of time
- Women have the reputation of being able to talk and listen while doing all sorts of things at the same time
- Women language is more widespread in both hemispheres while in men more left lateralized
 - more nerve fibers connecting the two hemispheres of their brains, which also suggests that more information is exchanged between them.

Women and language

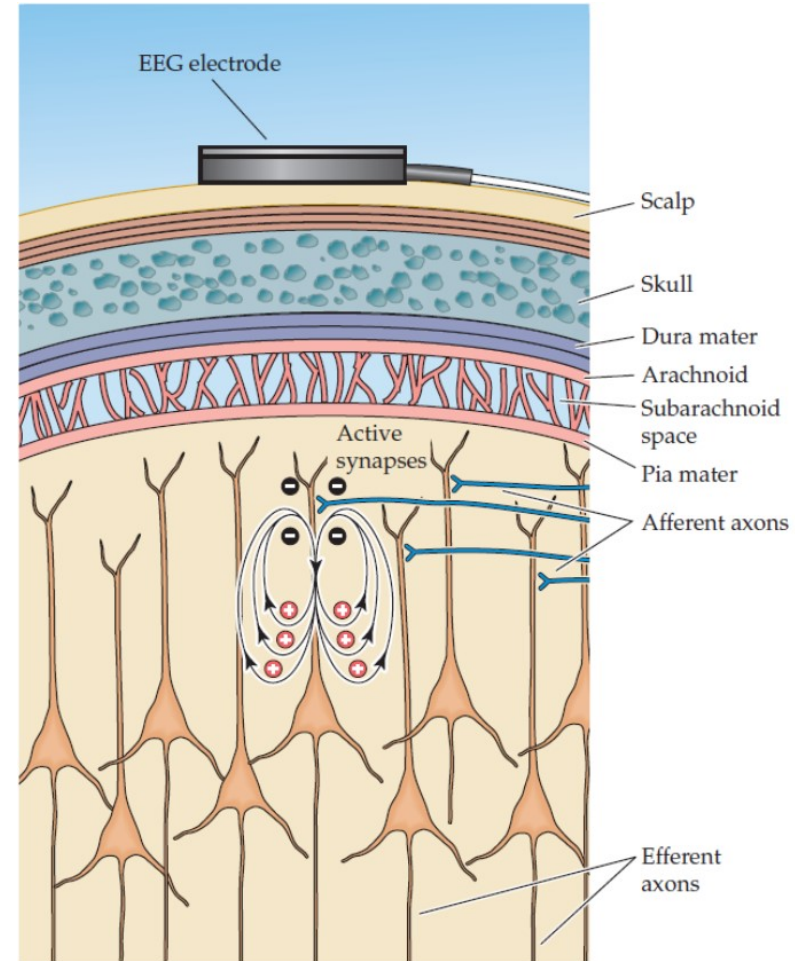
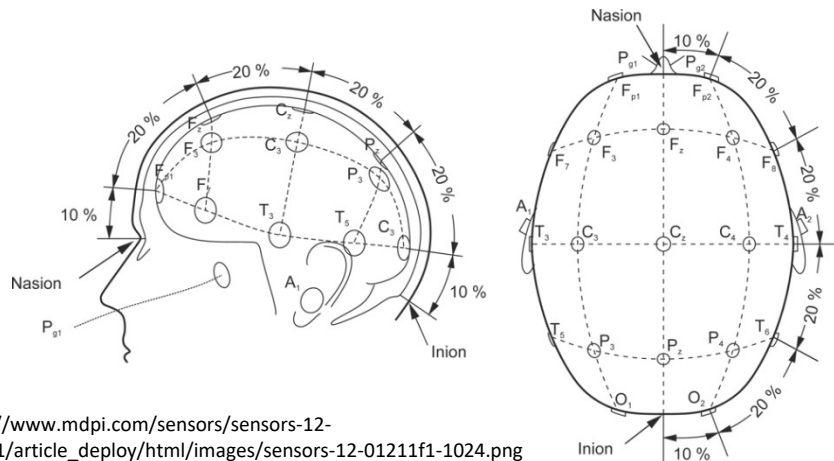
- Females' speech is more fluent
 - they can pronounce more words or sentences in a given amount of time
- Women have the reputation of being able to talk and listen while doing all sorts of things at the same time
- Women language is more widespread in both hemispheres while in men more left lateralized
 - more nerve fibers connecting the two hemispheres of their brains, which also suggests that more information is exchanged between them.
- The males' higher levels of testosterone, which delays the development of the left hemisphere
 - 4 times more boys than girls suffer from stuttering, dyslexia

Functional diagnostic methods

- Detection of electrical activity
 - Higher neuronal activity - higher electrical activity
 - Electroencephalography (EEG)
- Detection of regional blood flow
 - Higher neuronal activity – increased blood flow
 - Single photon emission tomography (SPECT)
 - Positron emission tomography (PET)
 - Functional magnetic resonance imaging (fMRI)

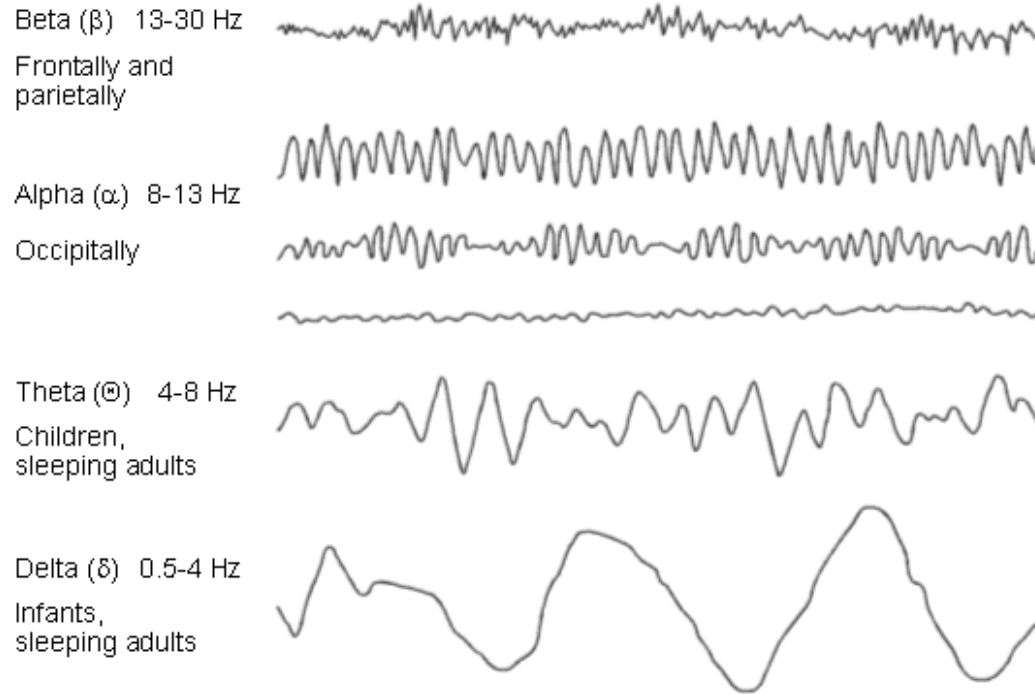
EEG

- Detection of neuronal electrical activity
- monopolar arrangement:
 - active electrode
 - indifferent electrode= referential recording
- bipolar recording
 - lead (channel)
 - ground electrode
- EEG voltage in microvolts (vs. in mV in neurons)

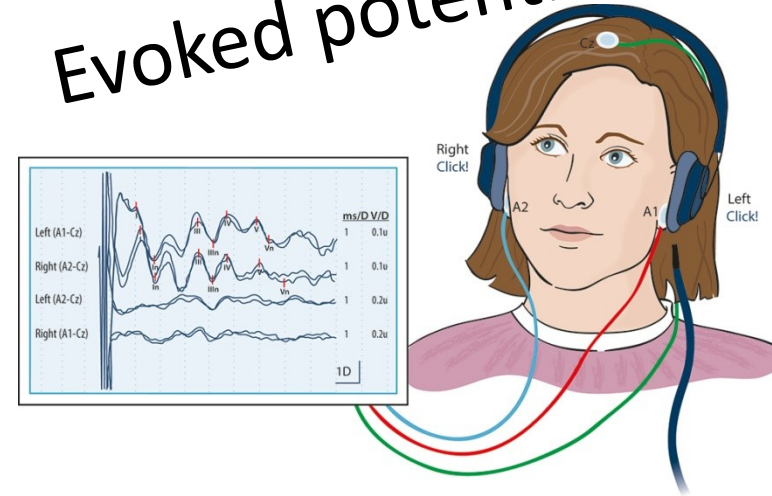


http://www.slideshare.net/kj_jantzen/biophysical-basis-of-eeeg

EEG

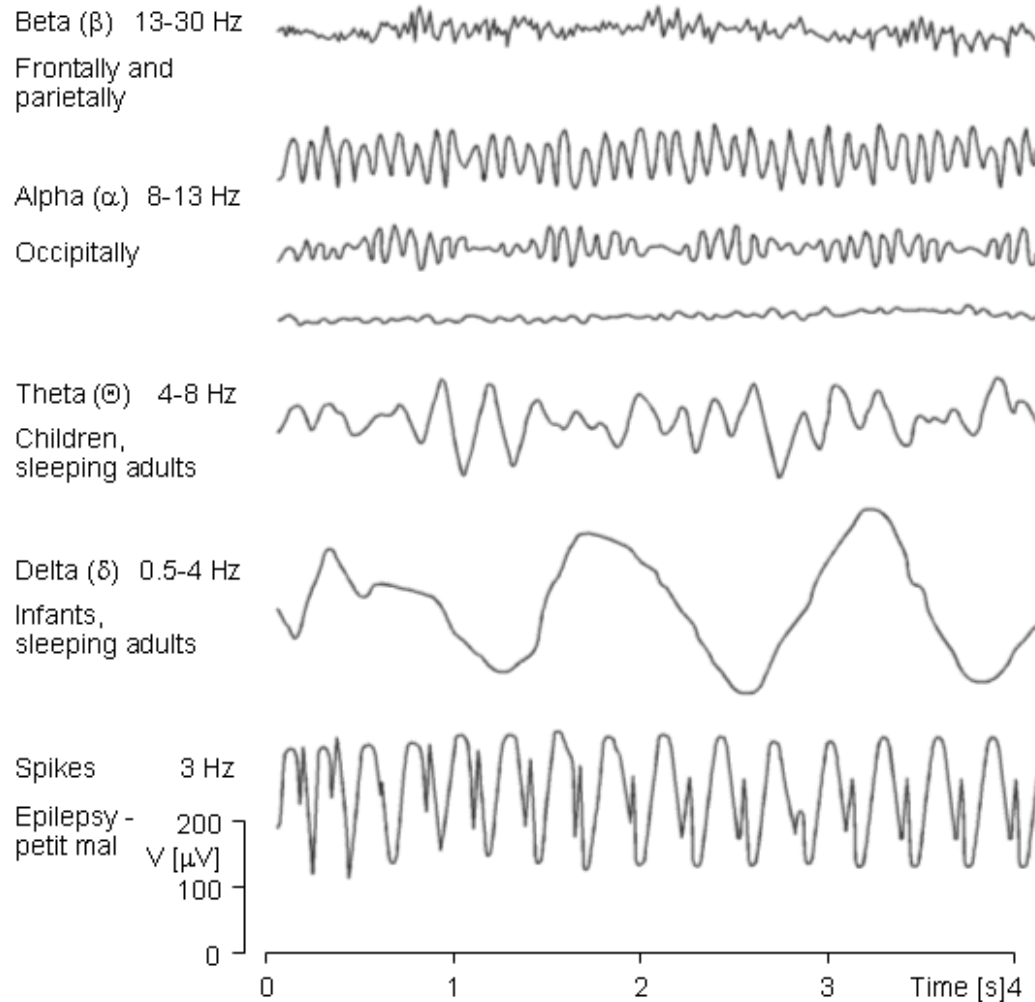


Evoked potentials



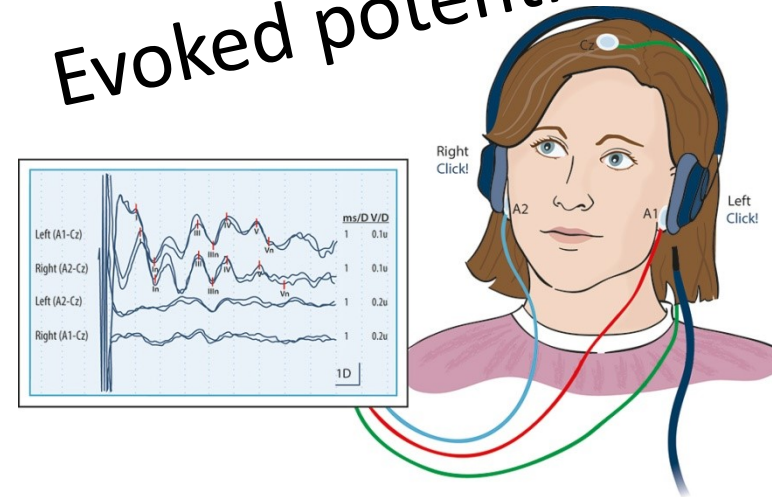
<http://tidsskriftet.no/2013/05/evoked-potential-tests-clinical-diagnosis>

EEG

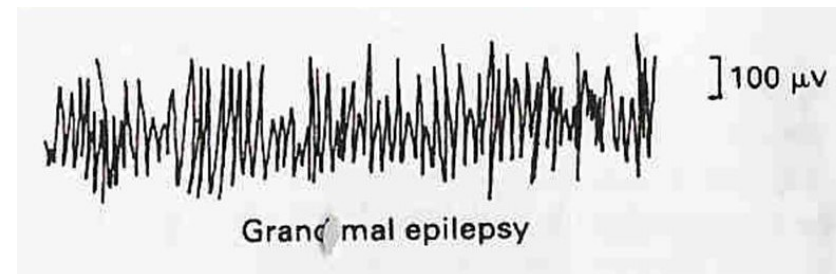


<http://www.slideshare.net/akashbhoi12/eeg-53489764>

Evoked potentials



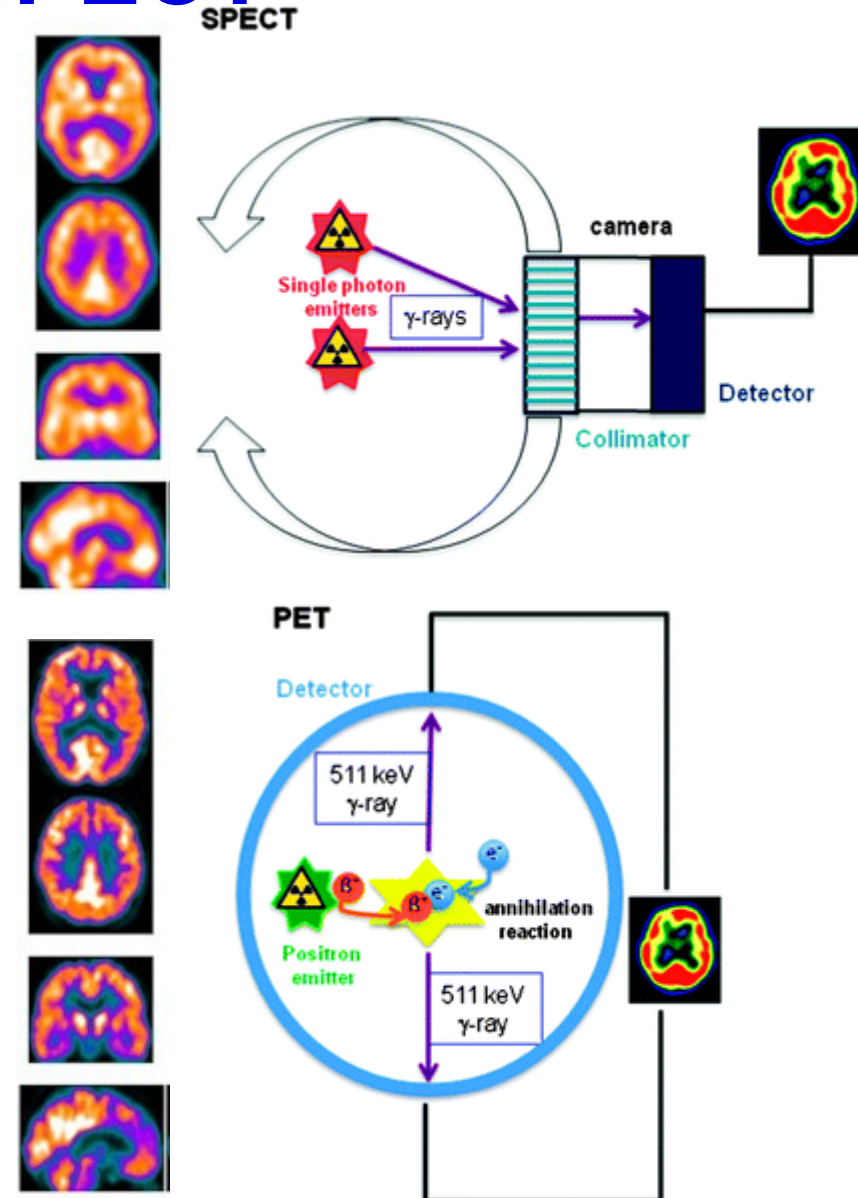
<http://tidsskriftet.no/2013/05/evoked-potential-tests-clinical-diagnosis>



https://www.google.com/search?q=GRAND+MAL+EEG&source=Inms&tbn=isch&sa=X&ved=0ahUKewjyr82Im6veAhUliaYKHfquClkQ_AUIDigB&biw=1222&bih=574#imgrc=nCNGCX88H3K7ZM

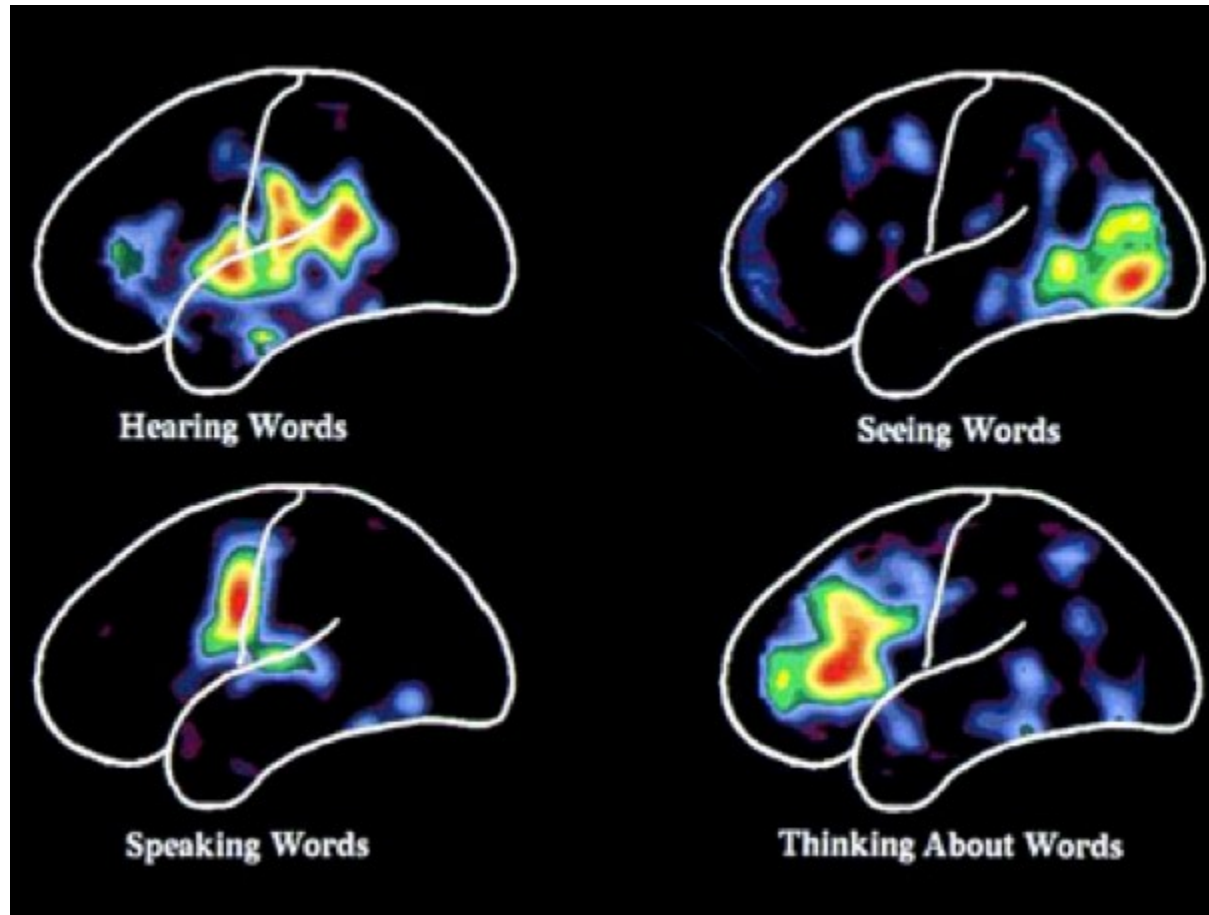
PET a SPECT

- Injection of radionuclide labeled substances
- Short half live of radionuclide
 - Necessary to prepare shortly before application
 - Nuclear medicine department
- SPECT
 - Single photon emission computer tomography
 - radionuclide is the source of gamma rays
 - Low resolution (around 1 cm)
- PET
 - Positron emission tomography
 - radionuclide is the source of positrons
 - Positron annihilation produces two gamma photons – higher resolution (around 2mm)



<http://pubs.rsc.org/services/images/RSCpubs.ePlatform.Service.FreeContent.ImageService.svc/ImageService/ArticleImage/2013/CS/c3cs60086f/c3cs60086f-f4.gif>

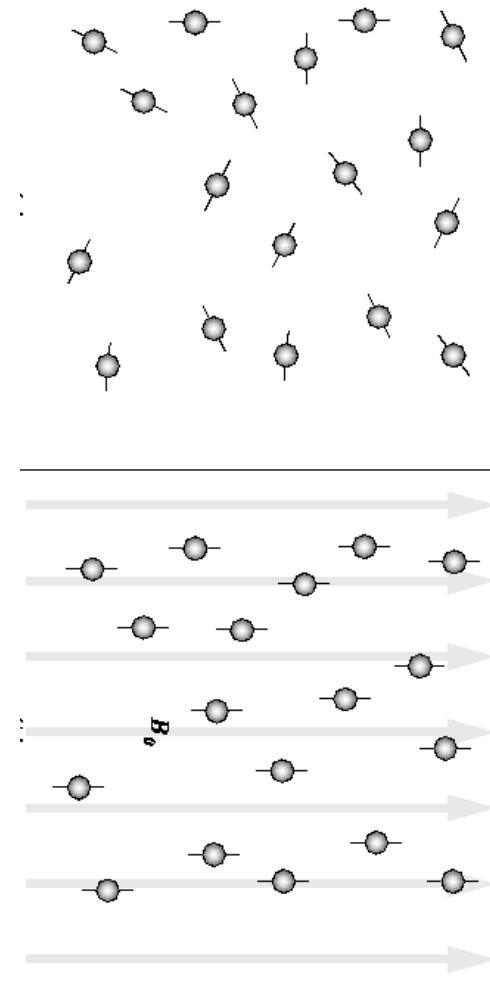
Functional regions of the brain



<http://www.chroniclebooks.com/blog/wp-content/uploads/brain-scan.png>

fMRI

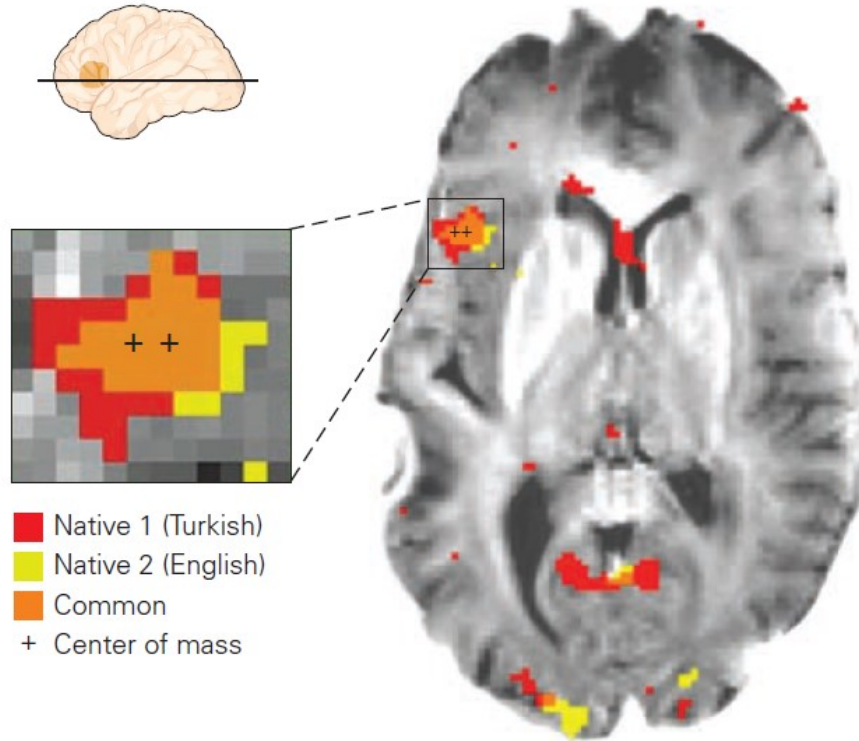
- Different atoms (nuclei) have various magnetic properties when exposed to strong magnetic field
- Hydrogen
- fMRI uses different magnetic properties of oxy- and deoxyhemoglobin
- reduced hemoglobin becomes paramagnetic, change the signal emitted by blood, we can measure the amount of oxy- and deoxyhemoglobin as an indicator of the blood flow
- High resolution (up to 1mm)
- No radiation



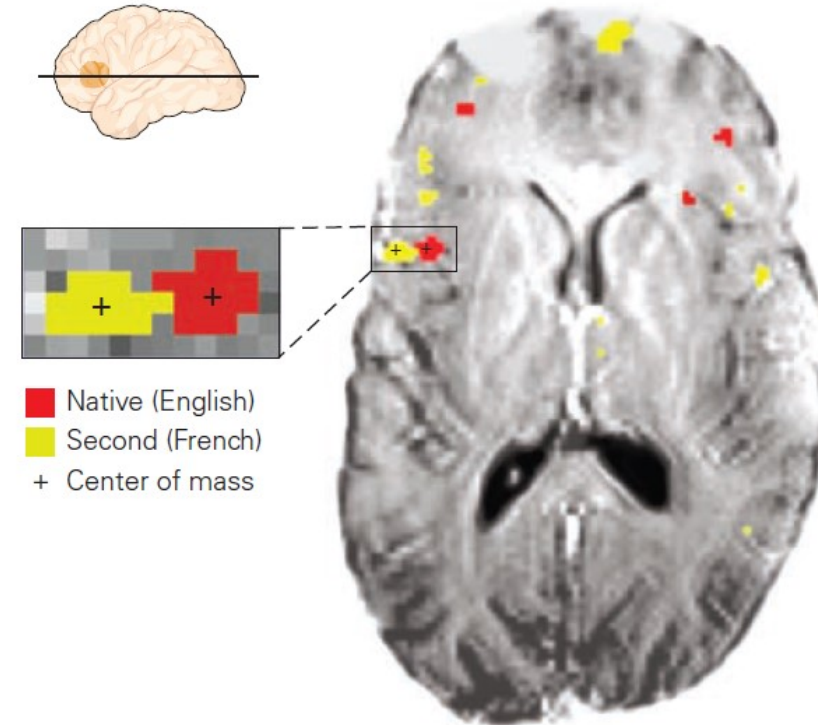
<https://www.cs.sfu.ca/~stella/papers/blairthesis/main/node11.html>

fMRI

A Early bilingual



B Late bilingual



Kim, K. H. S., Relkin, N. R., Lee, K.-M. & Hirsch, J. Distinct cortical areas associated with native and second languages. *Nature* **388**, 171–174 (1997).

86. The basic characterization of neocortical functions – language and social brain, basic overview of functional diagnostic methods used in neurology

- Communication and language
 - Language areas – localization and function including lobulus parietalis inferior, aphasia...
 - Lateralization of language functions, gender differences
- Social brain
 - Human is a social being, so the brain has to be designed accordingly
 - Frontal lobe and limbic system in behavioral control
 - Triune brain theory, whole brain model, mentalization, dehumanization
- Functional diagnostic methods (EEG, SPECT, PET , fMRI)

M U N I

M E D