


Institute of Microbiology shows:



TRACING THE CULPRIT

Part three: More G+ culprits

Survey of G+ bacteria

Story	Shape	In police evidence written as
<i>P01</i>	Medically important Cocci	Staphylococci (<i>S. aureus</i> , CONS)
<i>P02</i>		Streptococci (viridating, haemolytic)
1.		Enterococci (<i>E. faecalis</i> , <i>E. faecium</i>)
2.	Medically important Rods	Listerias (<i>L. monocytogenes</i>)
3.		Corynebacteria
4.		Bacilli

Listeriae a coryneforms do not sporulate, unlike Bacilli

Contents

Clinical characteristics – enterococci

Clinical characteristics – G+ rods

Enterococci and G+ rods: therapy

Diagnostics of enterococci and G+ rods (+ pictures)

Differential diagnostics of enterococci and G+ rods

Clinical characteristics - enterococci


Story 1

- Lucy has problems with urination. Doctor prescribed Zinnat, but problems did not change. On the next visit, he let Lucy to urinate in a glass and sent her urine sample to microbiology. But the specimen could not be examined: urine was contaminated. Finally, it was possible to take urine aseptically and to change the therapy.

Culprit No 1

- *Enterococcus faecalis*
- As the „entero-“ in his name tells us, it is a bug **normally present in the intestine**. Nevertheless, it is also a **common UTI pathogen**.
- The doctor is guilty, too – prescribed antibiotics before knowing microbial susceptibility. **Enterococci are resistant to all cephalosporin atb**. And he did not perform aseptic urine sampling in the first phase.
- *UTI (urinary tract infections) are mostly bacterial, and many pathogens are primarily or secondarily resistant to some atb-s. So bacteriological examination of urine is recommended, although often not done in practice.*

More about enterococci



- There are **tens of species** of them today
- All of them may be found
 - **in stool** (as a normal flora)
 - in the **urinary bladder** (as pathogen)
 - in the **vagina** (both symptomatically and asymptotically)
 - sometimes in **other sites** (wounds, bloodstream)
- Among two most common species, *E. faecalis* is slightly more often a pathogen, *E. faecium* is more often part of normal intestinal flora
- **Vancomycin-resistant enterococci (VRE)** are dangerous
- One of Enterococci, found in Brno, is named *Enterococcus moraviensis*

Clinical
characteristics –
G+ rods

Story 2

- European commission had to solve one more problem. French farmers protested against several EU-members, that do not want to import some **delicates French cheese specialities** to their area.
- German officials stated, that one pregnant woman, Mrs. Hildegarda Messerschmidt, after having eaten the cheese had **elevated body temperature** and after delivery, her baby suffered **newborn meningitis** that needed prolonged and complicated treatment

Culprit No 2

- *Listeria monocytogenes* is a G + rod, able to grow at low temperatures and high NaCl concentrations, typically in cheese storehouses. Nevertheless, people may get infected also by eating other food (salads, sausages, delicatessens, not properly cleaned vegetables)

Listeria – more info

- In adults, symptomatic infections are rare. In pregnant women there is a risk of congenital infection of the fetus through placenta with abort of foetus infection (in the last three months) as a result, or also perinatal infection during delivery (infection by contaminated vaginal secretion). In newborns, meningitis or septicaemia are common
- Infection is not very frequent, but it has high lethality (% of dead people of all infected people)
- Sometimes it is used as a pretence for import limitation – it should be always decided individually according to real risk in a specific case

Story 3

- Mr. Ulcerous, chronic diabetic, treated for ulcerations on his legs. He is often infected by various pathogens. What will be the newest one?

Culprit No 3

- *Corynebacterium jeikeium*, the worst among non-diphtheria coryneforms. Its name is derived from „corynebacterium group JK“.
- Corynebacteria are gram-positive rods, sometimes pleomorphic, usually arranged in palisades (see later).
- In the same genus, we have also causative agent of serious disease – diphtheria. Actually, it is rare in Europe, because of vaccination: *Corynebacterium diphtheriae*.
- The name is derived from „being club-shaped“ (*koryné* = club), but this morphology is typical for *C. diphtheriae* rather than for non-diphtheric corynebacteria

More about non-diphtherical corynebacteria

- Part of **normal flora of skin**, together with staphylococci and yeast. Pathogens in wounds. In microscopy, they form „**palisades**“ – like the early medieval wooden fortifications

File:St Fagans Celtic village palisade.jpg, From Wikipedia, the free encyclopedia, available at http://en.wikipedia.org/wiki/File:St_Fagans_Celtic_village_palisade.jpg, visited 2012-10-02



What are „coryneform rods“

- „Coryneform rods“ (eventually „diphtheroids“) are various rods that share similar morphology (although size of rods may vary considerably).
- All of them are rare causative agents of various human infections.
- *Arcanobacterium haemolyticum* is a rare causative agent of pharyngitis
- Other genera: *Dermatophilus*, *Rhodococcus**, *Turicella* etc.
- Similar is also *Erysipelothrix rhusiopathiae* – causative agent of a zoonosis (erysipeloid)

Rhodococcus jostii was found on the body of the Moravian Marquis and uncrowned Roman Emperor Jodocus (Jošt), that died 1411. The body is buried in St. Thomas church in Brno.

Story 4

- Nurse Eileen was shocked: microbiology examination of ward furniture, week ago taken by hospital epidemiologists, were released, and in half of them contained some bacteria, even **BACILLI!** Yes, it is here – *Bacillus* sp. Poor Eileen was worrying all the night about it and slept badly. In the morning, she asked microbiologists, what type of bacterium the „*Bacillus*“ is...

And she was very glad:


- it is no culprit! Usual members of *Bacillus* genus are harmless microbes from external environment. When found in clinical material, it is usually a contamination. So, the finding was not a problem – problem would be only when a *Bacillus* would be found from a site that is supposed to be sterile.

But some Bacilli are important

- *Bacillus anthracis* causes a veterinary disease – anthrax. It was one of first diseases where vaccination was attempted (already by Louis Pasteur). Its spores are abusable for biological war or bioterrorism (about a case of leak of anthrax spores in the Soviet Union in 1979 see: http://en.wikipedia.org/wiki/Sverdlovsk_anthrax_leak)
- *Bacillus cereus* is causative agent of intoxications coming from cereals
- *Geobacillus* (formerly *Bacillus*) *stearothermophilus* & *Bacillus subtilis* are able to survive hot temperatures → we use them as control organisms for hot air and steam sterilisers.

Bacillus and its spores

Spores of *Bacillus* sp. are sometimes larger than the vegetative cell, sometimes not; sometimes they are terminal, in other species they are subterminal or central




Enterococci and
G+ rods: therapy

Therapy of infections caused by enterococci and G+ rods

- No cephalosporins to fight enterococci and listerias! In *E. faecalis*, ampicillin, is good, but in *E. faecium* there is a primary resistance. More atb's are co-trimoxazol, doxycyklin, and, as a reserve, vankomycin. In haematooncological patients we can find epidemiologically serious vancomycin resistant strains – VRE. In such strains, only a new atb – linezolid – is effective

Reference zones for the most common antibiotics



Enterococci: tested on MH. G+ rods: tested on MH + red blood cells.

Antibiotic	Abb.	„S“ if \geq than (mm)	„I“ if between (mm)	„R“ if $<$ than (mm)
Ampicillin (aminopenicilin)	AMP	≥ 10	8–9	< 8
Nitrofurantoin (nitrofuran)	F	≥ 15	8–9	< 15
Vancomycin (glycopeptide)	VA	≥ 12	8–9	< 12
Tetracycline*	TE	≥ 19	15–18	< 15
Quinu-/dalfopristine**	QD	≥ 22	20–22	< 20
Gentamicin (aminoglykoside)***	CN	≥ 8	8–9	< 8

*valid also for doxycycline **mixture of two streptogramins ***only for combination with beta-lactams

Diagnosatics of
enterococci and
G+ rods
(+ pictures)

Description of culprits (diagnostics 1)

	Enterococ.	Listeria	Coryneform	Bacillus
Microscopy	<p>G+ cocci short chains</p> <p>http://textbookofbacteriology.net</p>	<p>G+ rods chains or palisades</p>	<p>G+ rods palisades</p>	<p>G+ robust rods, sporulating (sometimes non visible)</p>
Cultivation	<p>greyish, as large as that of <i>S.</i> <i>agalactiae</i>, various types of haemolysis</p>	<p>like enterococci of <i>Strep.</i> <i>agalactiae</i></p>	<p>very tiny colonies, like flour</p>	<p>large colonies, sometimes intensive haemolysis</p>

Description of culprits (diagnostics 2)


Enterococci

- **Biochemical tests:** catalase negative, possible biochemical determination, **arabinose splitting** (*E. faecalis* does not split, green medium, *E. faecium* makes it yellow)
- **Antigen analysis** used rarely. (Originally „group D streptococci“ according to Lancefield, as genus *Enterococcus* did not exist in time of Lancefield research)
- **Atb testing** on common MH agar. There exist also screening media for VRE.

Description of culprits (diagnostics 3)

G+ rods

- Biochemical tests: catalase positive in all three of our genera. But e. g. genus *Arcanobacterium* (not member of *Corynebacterium* genus, but nevertheless a coryneform) is CAT neg. Biochemical detection possible (API Coryne, Remel)
- Growth at low temperatures, high NaCl concentrations etc. used in *Listeria* dg.
- Biochemical dg. and atb testing are also a part of the diagnostics
- Antigen analysis – e. g. searching diphtheria toxin



Differential
diagnostics of
enterococci and
G+ rods

Differential diagnostics: enterococci

- Gram staining differentiates Gram + cocci, Gram + rods and other bacteria.
- Catalase of NaCl differentiates staphylococci
- Slanetz-Bartley / Bile-aesculin, PYR test differentiates enterococci from streptococci
- Arabinose test/other biochemical tests – mutual differentiation of Enterococci

Differentiation of *Enterococcus*



- **Arabinose test:** colonies are mixed with arabinose and indicator, and let to incubate

Green	negative	<i>E. faecalis</i>
Yellow	positive	<i>E. faecium</i>

- ENCOCCUStest has only 8 reactions, but otherwise it is like other similar tests

Differential diagnostics – *Bacillus*

- **Gram staining** differentiates **G+ rods** from other bacteria
- *Bacillus* has typical **Gram staining result** – long and large rods; sometimes (not always) also endospore formation may be seen (empty places in the rod)
- **Cultivation** is also characteristic (large, felt-like colonies)
- **Species determination** available by biochemical tests, susceptibility to antibiotics etc.

There is no clear algorithm for G+ rods!

Differential diagnostics – *Listeria* and coryneforms

- Gram staining differentiates G+ rods from other bacteria
- In case of spore-non forming, non-robust rods the microbe is likely *Listeria* or one of coryneform rods (mere absence of endospore is not sure!) Further diagnostics is available by means of biochemical methods, growth at various temperatures, tests of haemolytic interactions (synergisms, antagonisms) etc.

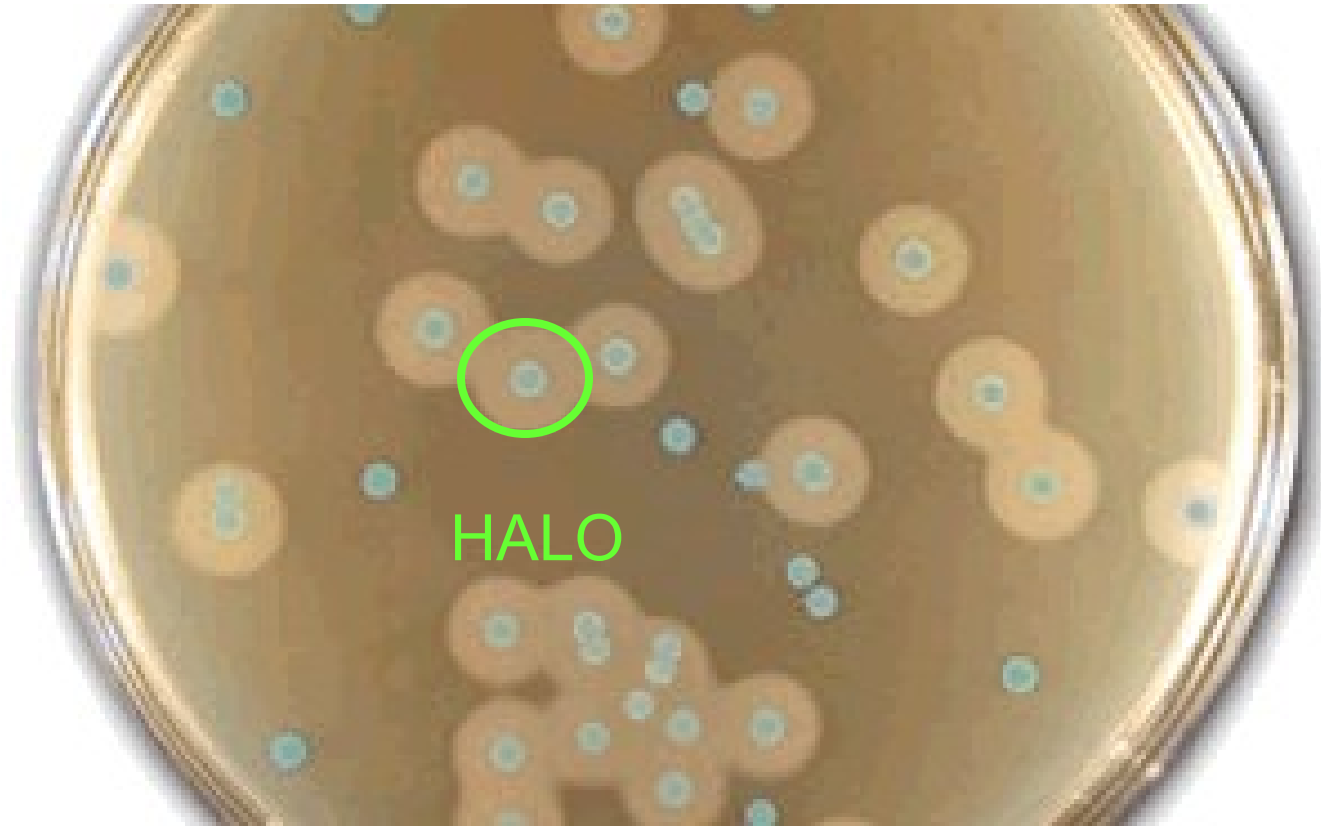There is no clear algorithm for G+ rods!

Listeria growth at 4 °C

- Among Gram positive rods, only *Listeria* is able to grow in low temperatures. This enables it to spread in cheese factories
- Among other bacteria (not being G+ rod), there are some more species able to grow at such low temperatures (*Yersinia*, some *Pseudomonas* sp.)

Chromogenic medium for Listeria

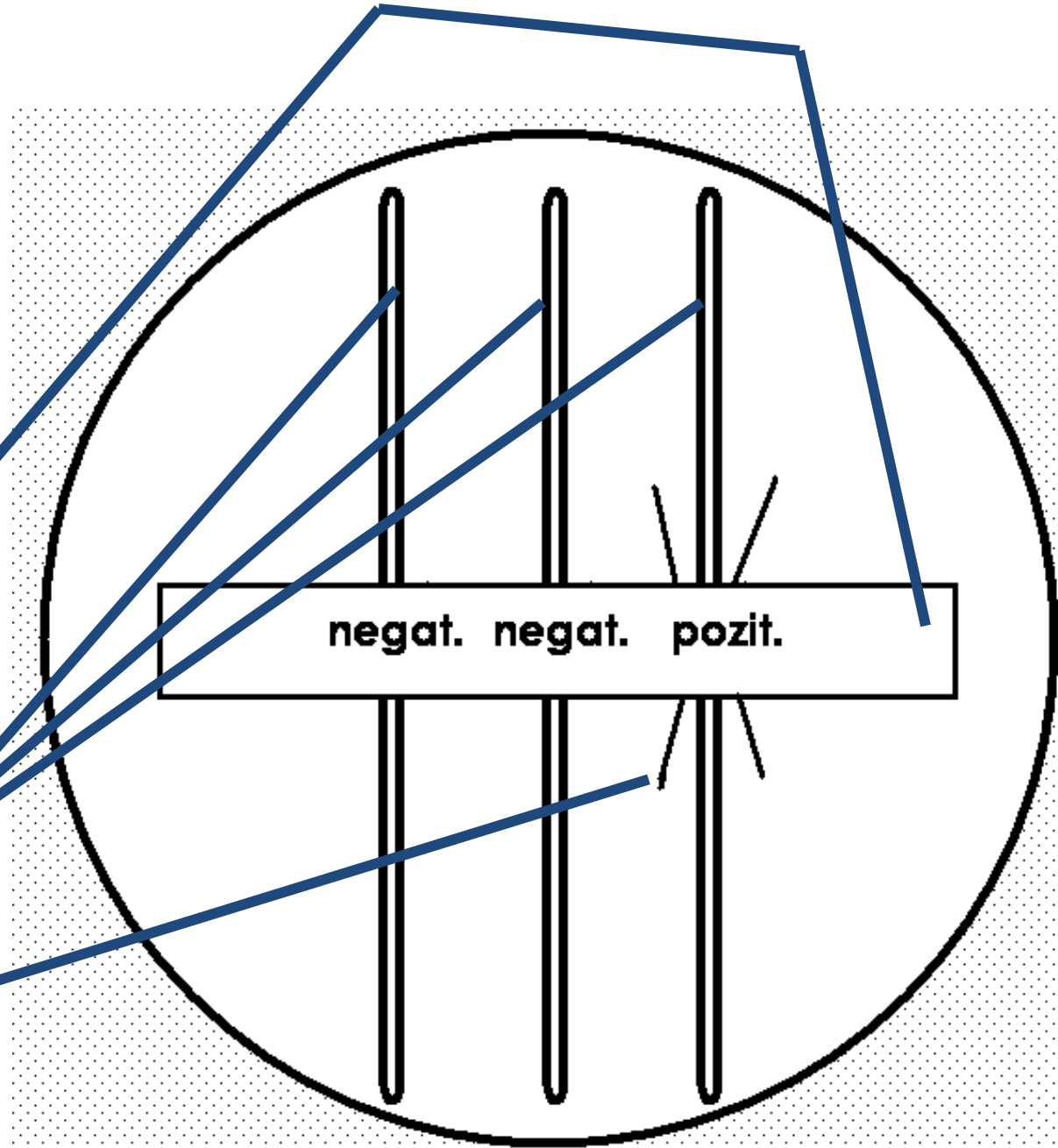
www.oxid.com





There exist various chromogenic media to *Listeria* diagnostics. The one on the picture is called ALOA and it is typical by **o blue colour of all *Listeria* colonies**, furthermore, **pathogenic species have also halo around them** (halo = differently coloured surrounding).

Elek test

It is a detection of a toxin of *Corynebacterium diphtheriae*. We use a paper with specific antitoxin, that is put on the surface of the agar, then tested strains are inoculated. Positive result = precipitation lines.



The end



Hemolytic antagonism („reverse CAMP test“) in *Arcanobacterium haemolyticum*)