


Institute for microbiology shows

TRACING THE CULPRIT



Part nine:
Culprits in spiral form

Survey of topics

Clinical characteristics of spiral bacteria

Microbiological characteristics & dg. of spirochets

Bonus: More about microscopy

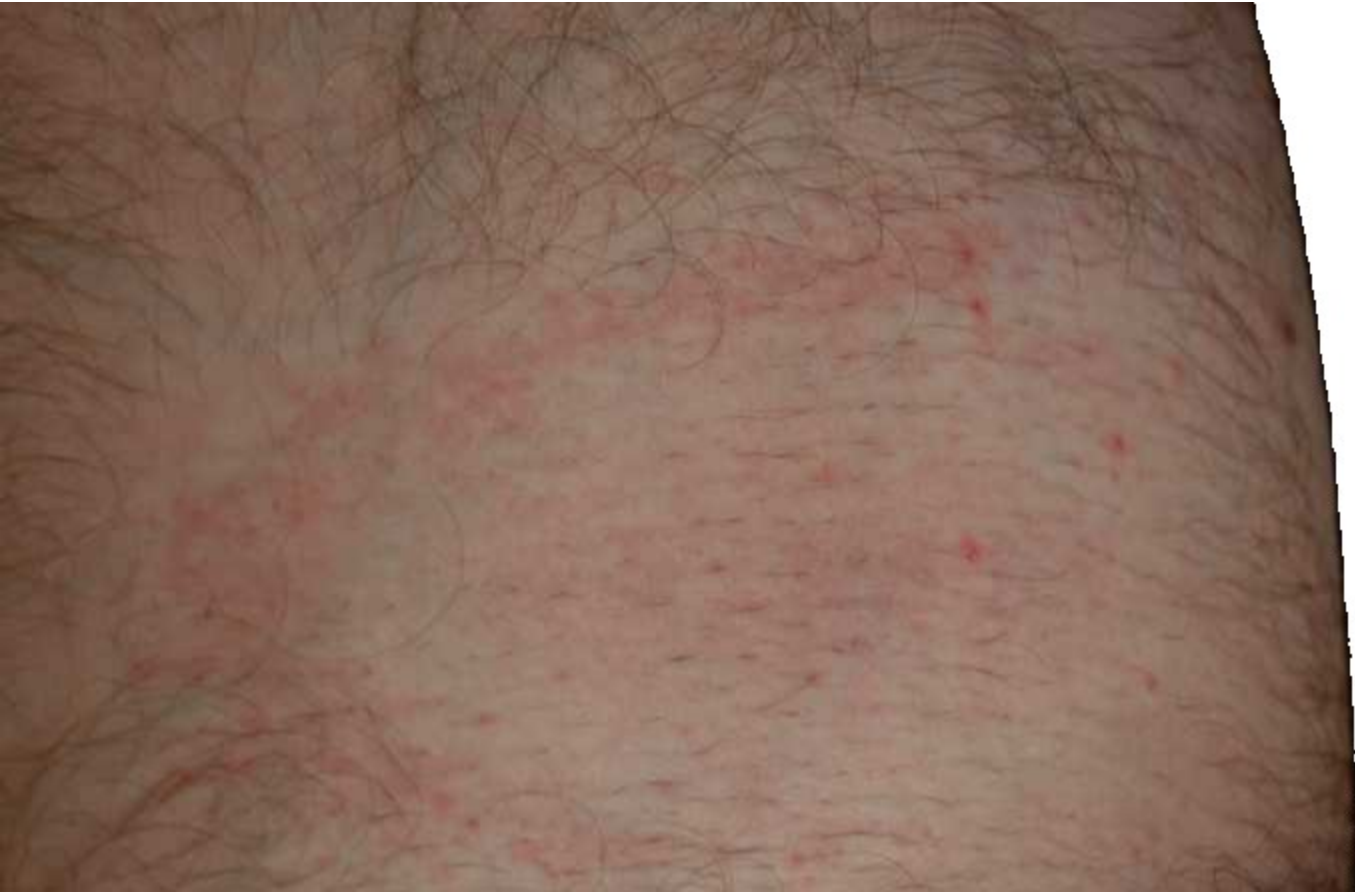Clinical characteristics of spiral bacteria

Story one

- Roseanne Pinkspot started to have pink spots on her body. She thought, that probably... Oh yes, several weeks ago she participated on a girl scout camp and several times during the camp she had a tick.
- Her GP sent her to children infection clinic, and experienced infection disease expert confirmed, that most likely it is the disease that Roseanne supposed. For sure, she took serum for antibody detection...

Erythema migrans

- This is a picture of Erythema migrans of student M. M., who kindly agreed to let it for use in education



The causative agent was

- *Borrelia afzelii*, one of borrelias, causing Lyme disease and belonging to the group *Borrelia burgdorferi sensu lato* (= „broad sense of meaning“)
- This species „in broad sense“ is divided into several genomospecies. The most important are *B. garinii*, *B. afzelii* and *B. burgdorferi sensu stricto*
- While in the USA mostly the third of them is common and joint symptomatology is common, in Europe two first borrelias are more common, and the typical disease is neuroborreliosis
- Besides Lyme diseases there exist other species causing recurrent fever (*B. duttoni*, *B. recurrentis*)

Story two (virtual, but basis is from a real story)

- When Phyllis found, that she really needs pervitin, and more and more, she decided to earn money by her own body.
- When the client paid more, she went with him without a preservative, she used contraception and she felt more OK
- Then she fell in love and decided to have a child. She stopped the contraception and was happy. Helmut will be a good father...

Story two – continuing

- So Phyllis was pregnant. But she found herself a genital ulcer and her gynaecologist took blood for serological examination. It was positive. Phyllis did not want interruption, it was too late and she wanted her child.
- Phyllis was treated, but the antibiotic was not chosen properly. The child was born ill and after two weeks it died because of a secondary *Klebsiella* septicaemia


The culprit was

- *Treponema pallidum ssp. pallidum*, causing syphilis (lues)
- Syphilis is a classic sexual disease. It is transmitted sexually only. But it is a systemic disease – in developed stages the whole body is affected (gummas, aortal dissection, neurosyphilis, psychical symptoms)
- Besides *T. p. ssp. pallidum*, genus *Treponema* contains these important species and subspecies, not causing STIs:
 - *T. p. ssp. endemicum*, which causes bejel or endemic syphilis
 - *T. p. ssp. pertenue*, which causes yaws (framboesia)
 - *Treponema carateum*, which causes pinta (carate)
 - *T. denticola*, *T. socranskii* and some more participating on some cases of periodontitis

Story three

- **Mr. Ratter** was an employee of NWPS Ltd. (Nowhere Water Pipes and Sewage)
- His job was **sewage cleaning**. He knew all sewage corridors. He also knew **rat habits**, he liked rats and he understood them.
- Nevertheless, once there was some misunderstanding between him and the leader of rat group and **Mr. Ratter was bitten to his leg**.
- Some time after this, Mr. Ratter was hospitalized with **icterus and bleeding...**

The disease is caused by...



- *Leptospira interrogans* ser. Icterohemorrhagiae
- Formerly individual serovars of *Leptospira* were considered to be individual species, now all pathogenic ones are taken as a part of species *Leptospira interrogans* (second species *Leptospira biflexa* is non-pathogenic)
- Symptomatology varies, from „flu-typhoid“ symptoms of serovar Grippotyphosa (field fever, canefield fever) to jaundice and bleeding (Weil disease, as in Mr. Ratter) in serovar Ictero-hemorrhagiae.
- (At least these two serovars are quite simple for remembering, try to remember at least them 😊)

Microbiologic
characteristics
and diagnostics
of spirochetes

Spirochets

- borrelias (but also treponemas and leptospiras) are spirochets, i. e. spiral rods.
- Their is close to a gram-negative one, but they do not stain by Gram's method because they cell wall is very thin.
 - So we microscopy them only using dark-field or fluorescence microscopy, or imunofluorescence (≠ fluorescence)
- The cultivation of spirochets is very difficult (we use special culture media, or we use other tests)
- *T. pallidum* cannot be cultivated in artificial media

Treponema: direct methods

- **Direct diagnostics** is rare, also because often there is hardly something to take. Only patients with chancre are available for scrapping.
- **Microscopy**: It is possible to use **wet mount – dark field**. It is strange, that although it is a wet mount, immersion is used (treponemas are very subtle). Besides that, **fluorescence staining can be used**
- **Neither culture nor biochemical methods** are used
- **Antigen detection** can be performed by direct IMF
- **Animal experiment**: There exist so named RIT – Rabbit infectivity test
- **PCR diagnostics** is more and more important. *This is an exception – besides chancre scrapping, it is also possible to send full blood for examination.*

Direct syphilis diagnostics – survey

- RIT – Rabbit infectivity test. For ethical reasons, but also as it is too much work, the RIT is minimized today.
- Dark field – shining *Treponema pallidum* is observed against the dark field
- Direct IMF – another direct, but difficult method
- PCR – also from blood

New Zealand Rabbit used for RIT


<https://upload.wikimedia.org/wikipedia/commons/2/24/NewZealandWhiteRabbit.jpg>

Gb1 at English Wikipedia [CC BY-SA 3.0 (<https://creativecommons.org/licenses/by-sa/3.0>)



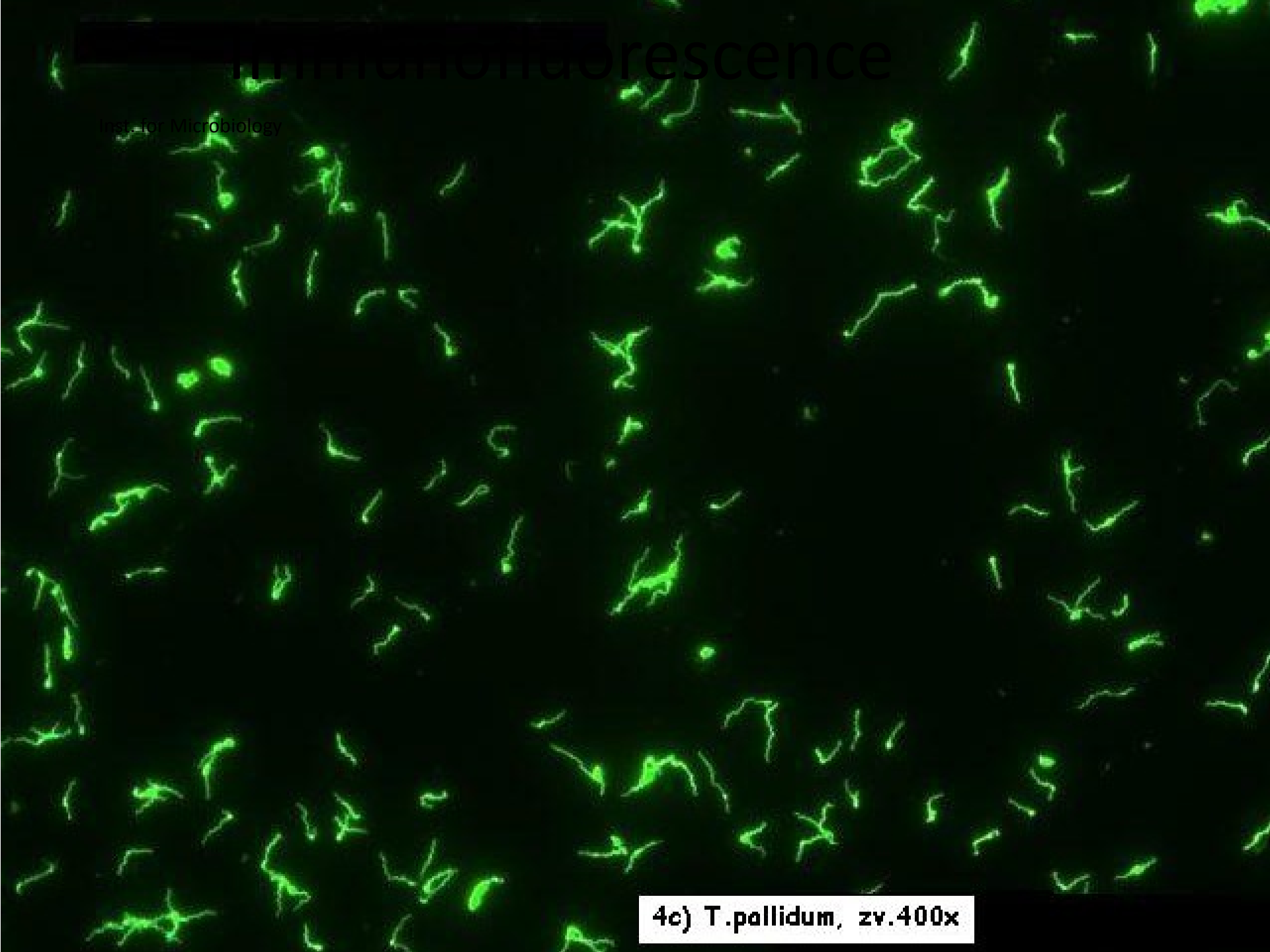
Notes to microscopy

- There exist different types of microscopy
- **Wet mounts** – we use a cover slip, there is no fixation, usually immersion system is not used
- **Stained preparations** – are fixated, after staining they are usually observed in the immersion system
- **Dark field microscopy** – a special case of the wet mount; immersion system is usually used
- **Fluorescence microbiology**; if the fluorescence dye is connected to an antibody or antigen, it is no more fluorescence, but immunofluorescence (a combination of microscopy and serology)
- *More in the bonus material*



Fluorescence

Inst. for Microbiology



4c) *T. pallidum*, zv. 400x

Treponema: indirect methods

- We use **non-treponema tests**, which usually plays the role of antigen cardiolipin from bovine heart, and **treponema tests**, where we have a real antigen from *Treponema pallidum*
- **Diagnostics is composed of screening and confirmation.** We confirm everything that was positive or at least borderline at screening, in reasonable cases even negative results.
- **Screening** usually consists of a non-treponema and a treponema test
- **Confirmation** is performed by highly specific treponema tests

The most important indirect tests for lues

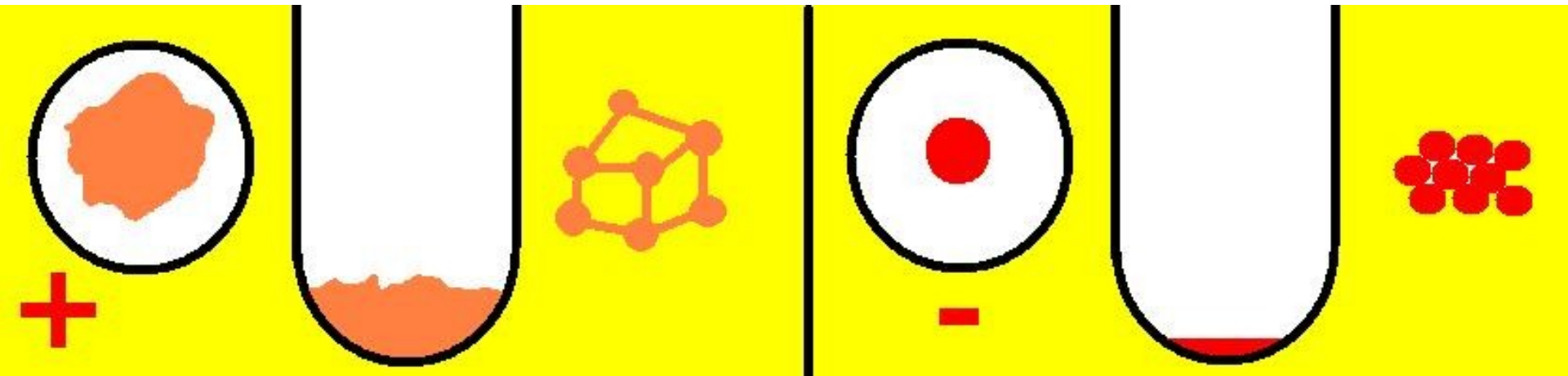
Historic	BWR – Bordet Wassermann	Nontr.
Screening	RRR – Rapid Reagin Test <i>or RPR</i> <i>or VDRL test</i>	
	MHA-TP (TPHA)*	Treponema
Confirmatory	ELISA	
	FTA-ABS (indir. imunofluor.)	
	Western Blotting	
<i>Historic, or superconfirmation</i>	<i>TPIT (Treponema Pallidum Immobilisation Test) = Nelson</i>	

* MHA-TP – test for passive haemagglutination; now RBC use replaced by polycellulose

RRR and MHA-TP

- In **RRR**, the well with turbidity is positive (it looks like the positive control). It is necessary to shake the panel, otherwise the reaction would not be visible.
- **MHA-TP** is an agglutination on carrier (RBC). A „potato shaped formation“ is positive, a dense dot is negative

MHA-TP – to remember



- Positive – agglutinate formed, viewed from up as clot of irregular shape
- Negative – RBC (polycellulose particles in newer variant) fall to bottom forming a regular dense dot viewed from up

MHA-TP to remember II

(Institute for microbiology)

Positive control (various level of positivity)


Negative control

Patients (1, 2, 3)

Technical wells

Control

Proper reaction

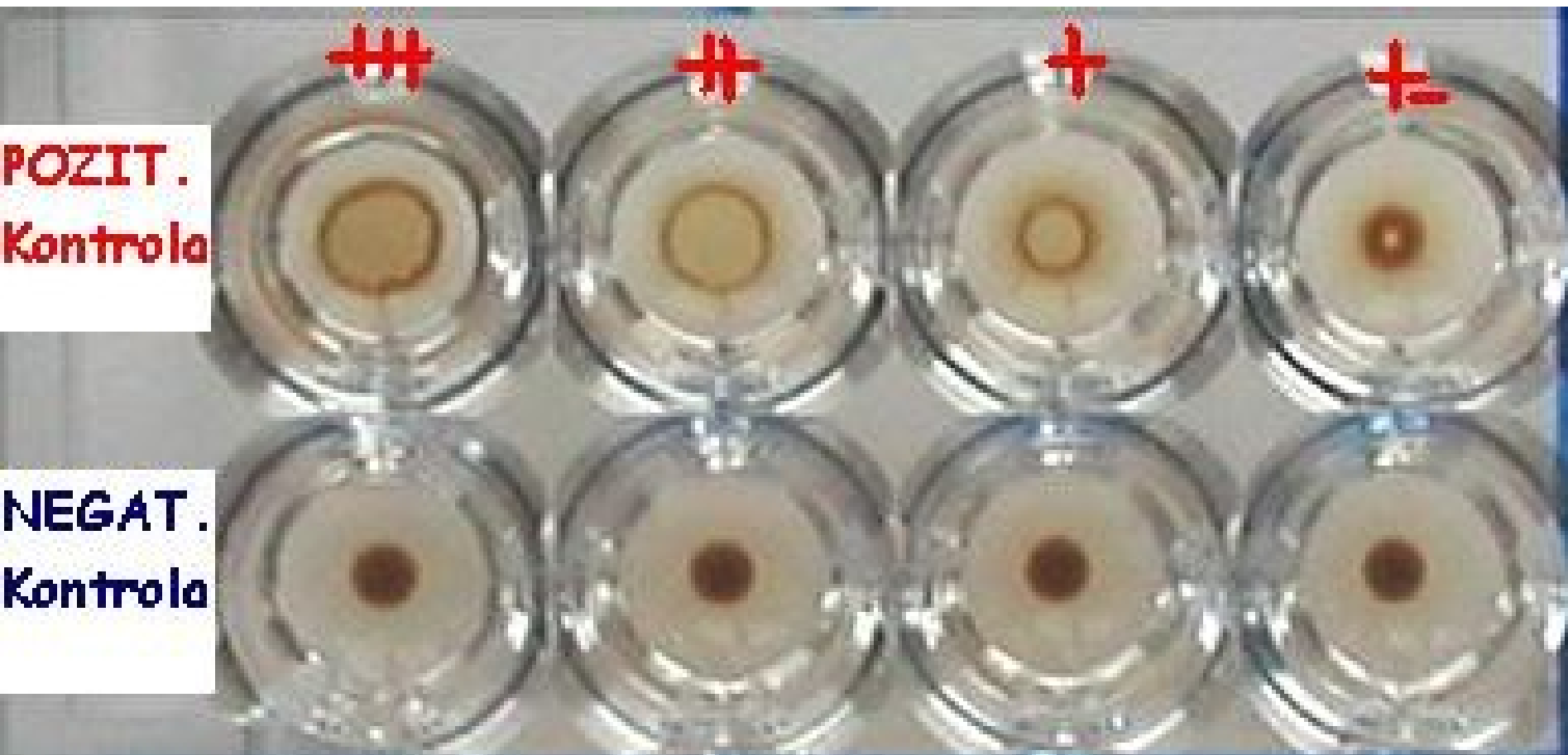


Remark that we have 1) positive controls, 2) negative controls, 3) negative controls to the individual wells

RRR – reading: turbidity = positive,
no turbidity = negative

MHA-TP – reading:

Inst. for Microbiology



Indications for confirmation

- Screening reactions are performed always, when somebody is to be tested for syphilis (including e. g. pregnant women that are not at all supposed to be positive). Screening reactions are usually performed only **qualitatively or semiquantitatively** (although it would not be a problem to do them quantitatively)
- Indication for confirmation is:
 - any **positive or at least borderline result** in RRR and/or MHA-TP reaction, OR
 - presence of **suspicious lesions on body**, or **anamnesis** of risky sexual intercourse – here even in case of negativity of both reactions

ELISA, Western blotting and PCR in spirochetal diagnostics

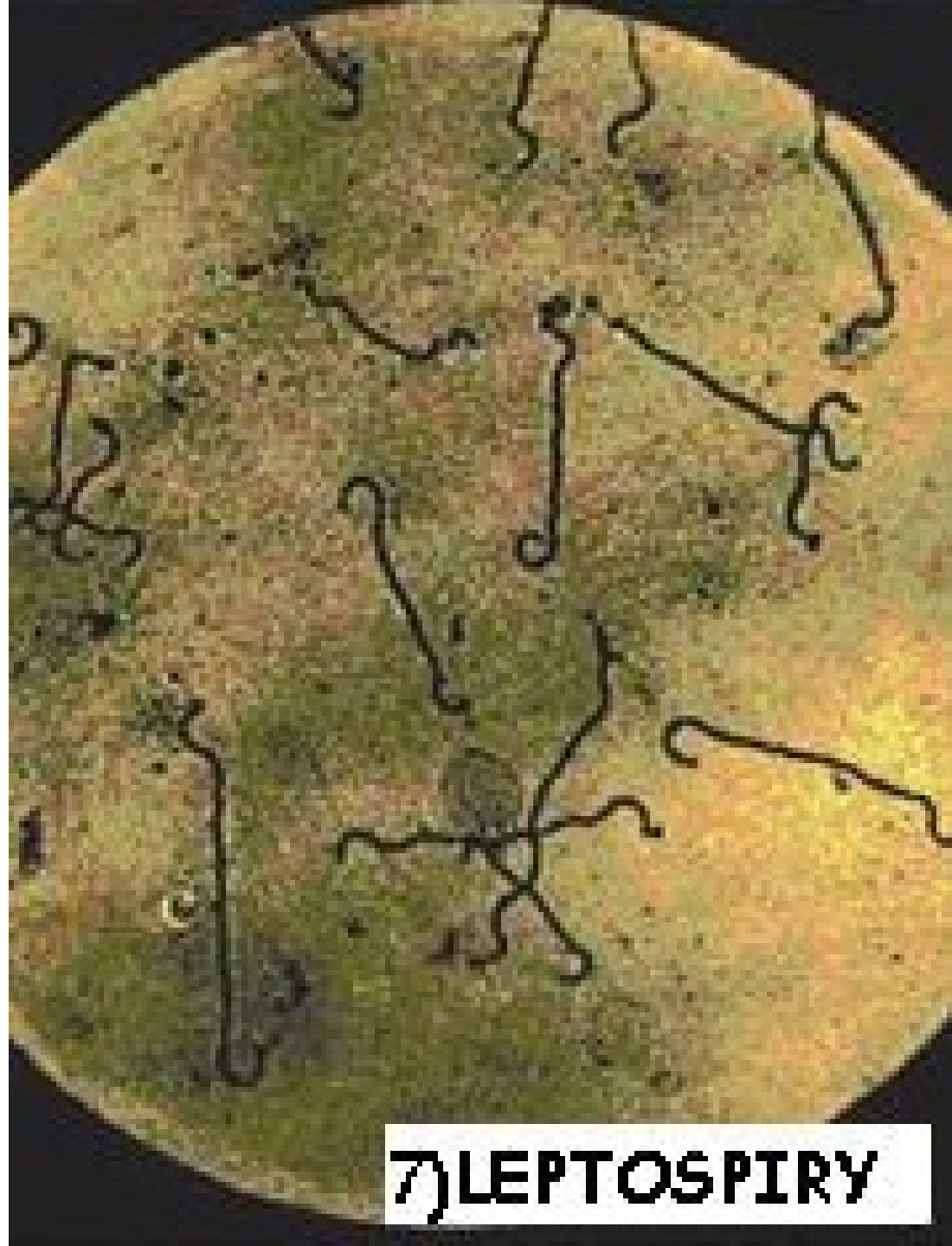- ELISA, Western blotting and PCR – all of them are used in spirochets similarly as in other microbes – see J08 and J09 topics in spring term.
- Positive are patients with values of absorbance higher than a given value (CAL – calibration well, cut off etc.)
- Examination of IgG and IgM antibodies is important, mere IgG positiveness is just a proof of a previous infection.
- PCR is used in diagnostics of syphilis and Lyme disease. It is usually positive sooner than methods detecting antibodies.

Borrelia and leptospira – course of investigation

- **Borrelia:** Mostly serology, event. PCR. In serology, IgM (typical for an early infection) and IgG antibodies are detected using ELISA method, positive finding is confirmed by Western blotting. Western blotting is more specific.
- **Leptospira:** Dark field microscopy and culture in special medium are used

Leptospira diagnostics

- Microbiological
proof of
leptospira

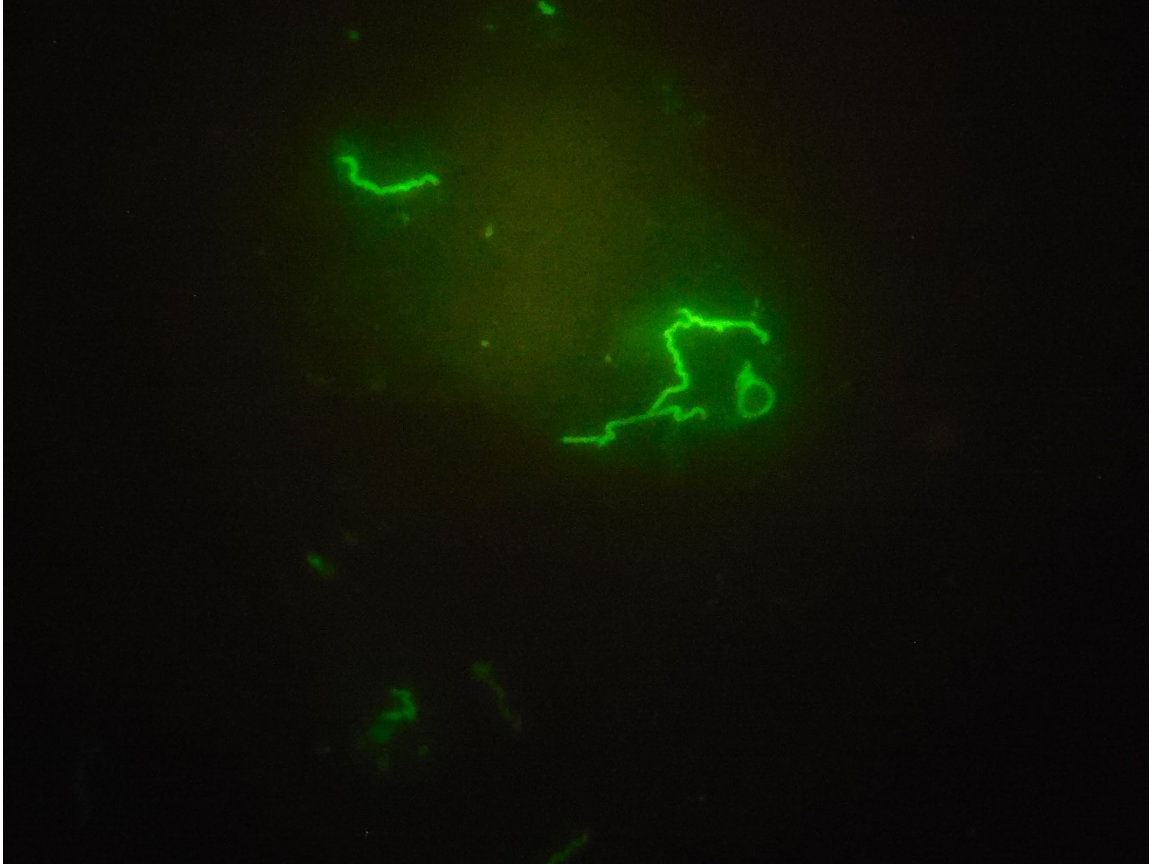


LEPTOSPIRY


Leptospira diagnostics

- Leptospirosis are usually diagnosed by serology
 - Microscopic agglutination test (MAT)
 - Patient sera are reactive with live antigen suspensions of leptospiral serovars
 - After incubation the samples are examined microscopically for agglutinations
 - Other serological tests are ELISA methods


The End



Treponema pallidum – immunofluorescence. Photo: inst. for Microbiology



BONUS: More about microscopy of bacteria



- Bacteria are **well visible in the electron microscope**, they are not used in practice
- **They are poorly visible in an optical microscope.** We can see them better if they move
- However, we cannot rely on the mobility of bacteria. Therefore, we make them visible differently: **fixate them and colour with one of the staining methods**
- **Light-refractory bacteria**, in particular spirochetes, are preferably observed by **dark-field microscopy**

Preparing a preparation




- For successful microscopy it is necessary to prepare **a quality preparation**.
- The preparation should be prepared so that bacteria and other objects are **clearly visible**. The coating must not be too thin, too dense, it must not burn (but not fix enough) during fixation, etc. For a **wet mount**, including dark-field microscopy, it is necessary to maintain **viable microorganisms**.
- Poorly prepared paint contains various artifacts (dye crystals, impurities...) – nevertheless, these can also occur in a smear prepared correctly

Parts of the microscope – light




- **The light** passes from the light source through the collector and condenser. It affects the quality and quantity of rays
 - light source voltage intensity
 - collector iris diaphragm (at the bottom of the microscope)
 - condenser height adjustment
 - condenser aperture adjustment
- **The height of the condenser** is usually adjusted when shading. At one point, the aperture edge becomes blue and becomes red – that is the right moment. Then the shutter opens again.
- Care should also be taken to ensure that the image is **centered correctly**. The centering uses two small screws, which are 90° from the side of the condenser

Condenser at normal and dark-field microscopy




- In a **normal microscope**, the aim of the condenser is to merely concentrate the beams so that they strike the specimen in an ideal manner and in an ideal amount
- In **dark-field microscopy**, the condenser is specially designed so that the light falls obliquely. The rays which are parallel to the optical axis are obscured by the orifice plate.

Magnifying optics




- In microbiology we usually use binocular microscope with removable **eyepieces** magnifying 10 ×
- **Lenses** are used 4 ×, 10 ×, 20 ×, 40 ×, 60 × and immersion lens magnifying 100 ×. "Immersion" means immersion oil dropping between the specimen and the lens, whose refractive index is closer to that of glass than in the case of air
- Each lens is equipped with a newer microscope not only with a magnification number, but also with a number that indicates what value the **condenser aperture** should be adjusted when using

Focusing and proper microscopy



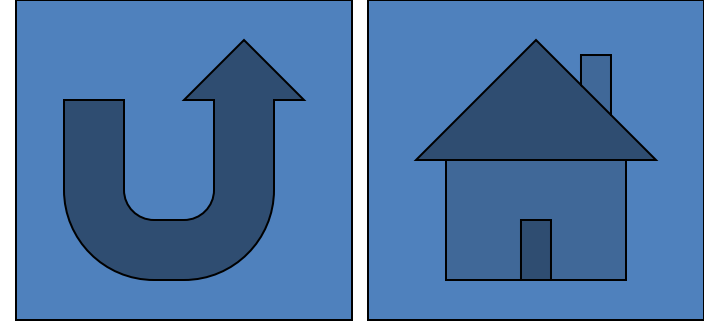
- Without looking through the eyepiece, we **approximate** the specimen to the lens as close as possible
- Now, under eye control, we **carefully put the specimen back**, first with the macro screw, then with the micro screw until we reach the appropriate level of sharpness
- In some cases (mainly wet mounts) there is no single level of sharpness, but it is still necessary to **refocus** to the “bottom” and “level” of the space filled with liquid. This is more difficult than to microscope one plane (for fixed and stained slides)

Special microscopical techniques



- **Dark-field microscopy** – used for light-refractive objects (e. g. spirochetes). Beams fall obliquely on the object and ONLY those that break on it hit the eye. The background is dark, the bacteria are light
- **Phase contrast microscopy** utilizes the phase shift of the beam
- **Fluorescence microscopy** itself should not be confused with immunofluorescence (classical fluorescence microscopy is not an antigen-antibody reaction at all)

Microscope cleaning



- After each use of immersion oil it is necessary to **clean the lens with gauze with alcohol ether** (less suitable, but usable, benzine/petrol)
- Sometimes it is necessary **to clean non-dimensional lenses**, especially if they are contaminated by oil
- When staining is also necessary to wipe the **stage**, here just a square of cellulose cotton with gasoline. Dirt often adheres under the slide retaining device, so it is sometimes necessary to remove and clean this part.