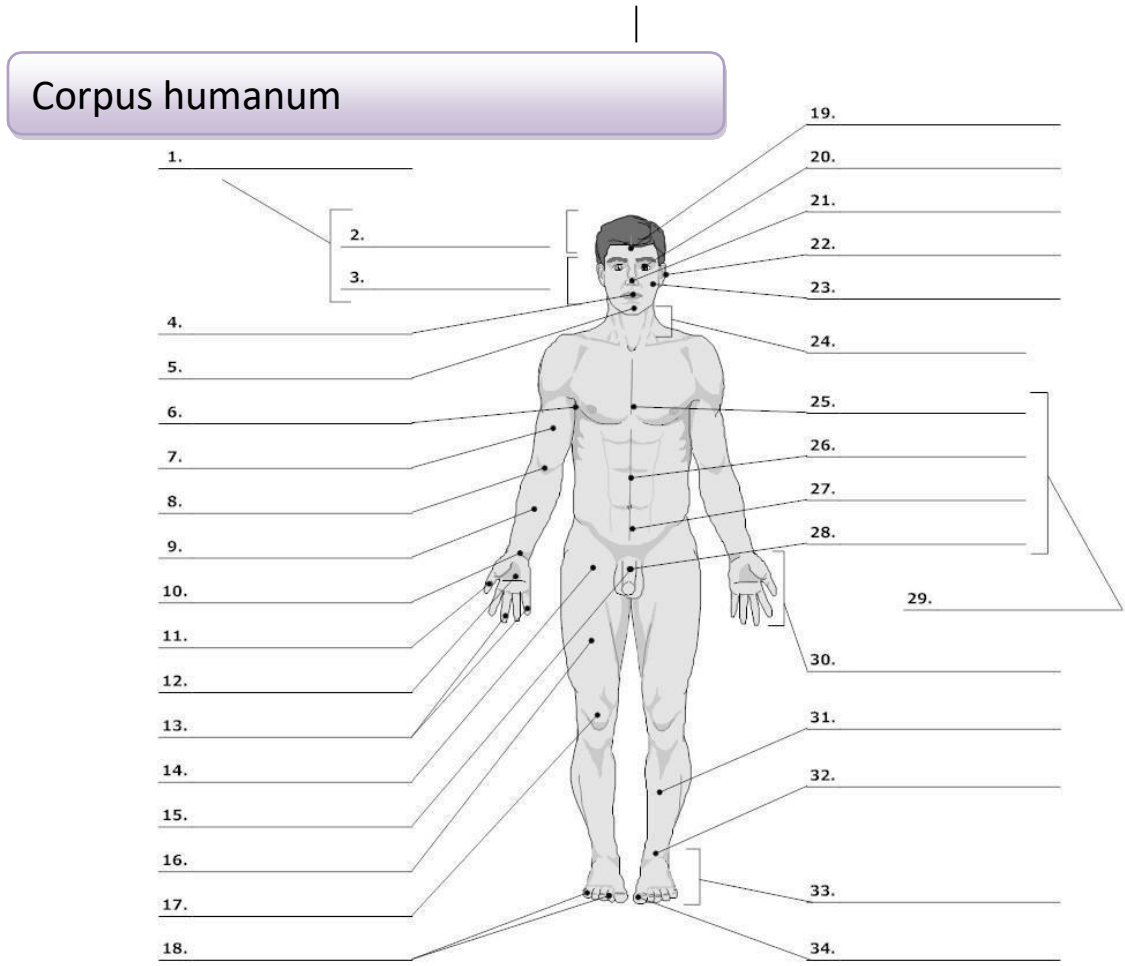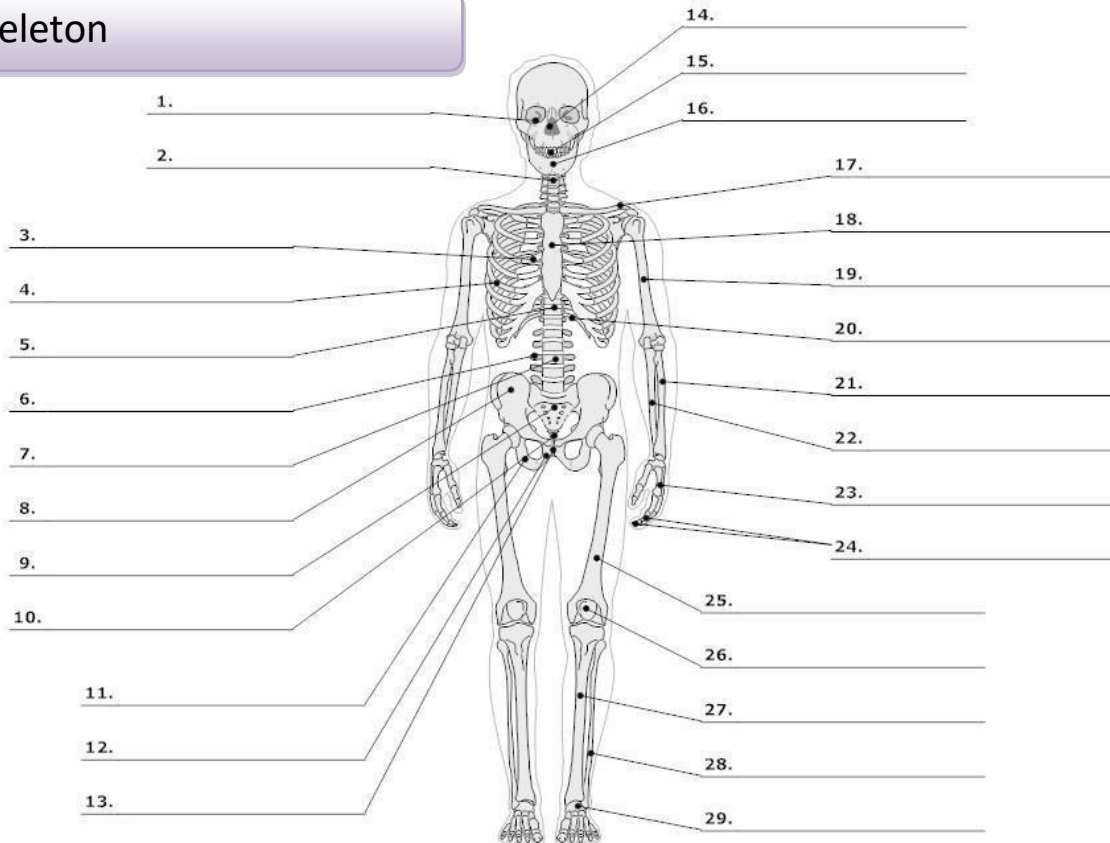


LIFEART Collection Images Copyright © 1999-2001 by Uppincott Williams & Wilkins, Baltimore, MD

- |                                       |                     |                                 |                          |
|---------------------------------------|---------------------|---------------------------------|--------------------------|
| 0. <b>corpus, oris, n.</b>            | body                | 16. <b>femur, oris, n.</b>      | thigh, femur             |
| <b>cutis, is, f.</b>                  | skin                | 17. <b>genu, us, n.</b>         | knee                     |
| 1. <b>caput, itis, n.</b>             | head                | 19. <b>frons, frontis, f.</b>   | forehead                 |
| 2. <b>capilli, orum, m.</b>           | hair                | 20. <b>oculus, i, m.</b>        | eye                      |
| 3. <b>facies, ei, f.</b>              | face                | 21. <b>nasus, i, m.</b>         | nose                     |
| 4. <b>os, oris, n.</b>                | mouth, opening      | 22. <b>auris, is, f.</b>        | ear                      |
| <b>lingua, ae, f.</b>                 | tongue              | 23. <b>bucca, ae, f.</b>        | cheek                    |
| 5. <b>mentum, i, n.</b>               | chin                | 24. <b>collum, i, n.</b>        | neck (mostly with bones) |
| 6. <b>axilla, ae, f.</b>              | armpit, axilla      | <b>cervix, icis, f.</b>         | neck (with soft tissues) |
| 7. <b>brachium, ii, n.</b>            | upper arm, brachium | 25. <b>pectus, oris, n.</b>     | chest                    |
| 8. <b>cubitus, i, m.</b>              | elbow               | 26. <b>abdomen, inis, n.</b>    | belly, abdomen           |
| 9. <b>antebrachium, ii, n.</b>        | forearm             | 27. <b>hypogastrium, ii, n.</b> | hypogastrium             |
| 10. <b>carpus, i, m.</b>              | wrist               | 29. <b>truncus, i, m.</b>       | trunk                    |
| 11. <b>pollex, icis, m.</b>           | thumb               | 30. <b>manus, us, f.</b>        | hand                     |
| 12. <b>palma, ae, f.</b>              | palm (of the hand)  | 31. <b>crus, cruris, n.</b>     | lower leg, calf          |
| 13., 18. <b>digitus, i, m.</b>        | finger              | 32. <b>tarsus, i, m.</b>        | tarsus                   |
| 14. <b>sulcus, i, m.</b> <sup>1</sup> | groove, furrow      | <b>talus, i, m.</b>             | anklebone, talus         |
| 15., 28. <b>penis, is m.</b>          | penis               | 33. <b>pes, pedis, m.</b>       | foot                     |
|                                       |                     | 34. <b>hallux, ucis, m.</b>     | big toe                  |

<sup>1</sup> sulcus glutealis

# Skeleton



LifeART Collection Images Copyright © 1989-2001 by Lippincott Williams & Wilkins, Baltimore, MD

0.	<b>skeleton, i, n.</b>	skeleton	<b>scapula, ae, f.</b>	shoulder blade
	<b>os, ossis, n.</b>	bone	18. <b>sternum, i, n.</b>	breastbone
	<b>cranium, ii, n.</b>	skull	19. <b>humerus, i, m.</b>	arm bone, humerus
1.	<b>orbita, ae, f.</b>	orbit	20. <b>arcus, us, m.<sup>2</sup></b>	arch
2.	<b>collum, i, n.</b>	neck (mostly with bones)	21. <b>radius, ii, m.</b>	radial bone, radius
	<b>cervix, icis, f.</b>	neck, cervix (with soft tissues)	22. <b>ulna, ae, f.</b>	elbow bone
3.	<b>thorax, acis, m.</b>	thorax (chest with ribs)	23. <b>metacarpus, i, m.</b>	metacarpus
4.	<b>costa, ae, f.</b>	rib	24. <b>phalanx, gis, f.</b>	wrist
5.	<b>discus, i, m.</b>	(vertebral) disc	25. <b>femur, oris, n.</b>	finger bone
6.	<b>processus, us, m.</b>	process (protuberance)	26. <b>patella, ae, f.</b>	thighbone, femur
7.	<b>vertebra, ae, f.</b>	vertebra	27. <b>tibia, ae, f.</b>	kneecap
8.	<b>pelvis, is, f.</b>	pelvis	28. <b>fibula, ae, f.</b>	shinbone
	<b>coxa, ae, f.</b>	hip, hip joint	29. <b>metatarsus, i, m.</b>	calf bone
	<b>ilium, ii, n.</b>	ilium		metatarsus
9.	<b>os sacrum*</b>	sacral bone		
10.	<b>coccyx, gis, f.</b>	tailbone, coccyx		
11.	<b>ischium, ii, n.</b>	ischium		
12.	<b>os pubis*</b>	pubic bone		
13.	<b>symphysis, is, f.</b>	symphysis		
14.	<b>nasus, i, m.</b>	nose		
15.	<b>dens, ntis, m.</b>	tooth		
16.	<b>mandibula, ae, f.</b>	lower jaw		
17.	<b>clavicula, ae, f.</b>	collarbone, clavicle		

<sup>2</sup> arcus costalis

## INTRODUCTION TO LATIN GRAMMAR

LATIN (inflectional language) vs. ENGLISH (analytic language)

### Inflection vs. Word Order

Unlike English, where it is the fixed word order (SWOMPT) that tells us how the words are related to each other in a sentence (i.e. what is a subject, object, etc.), Latin conveys such information by the endings of individual words (i.e. via inflection). Therefore, the word order is much looser in Latin and it may differ significantly from the English one.

e.g. complicated fracture of the left humerus = *fractura complicata humeri sinisteri* /  
*fractura humeri sinistri complicata*

### Gender and Adjectives

Every Latin noun is inherently masculine, feminine, or neutral, even though it denotes a non-living object. **REMEMBER** to learn each noun together with its gender, since adjectives assume the same gender as the nouns they modify. Unlike English, adjectives usually stand right after the noun they modify, or somewhere further in the sentence. In other words, you often cannot tell which noun an adjective goes with, unless you know the noun's gender.

\*If we describe an anatomical structure with more than one adjective, the most specifying one is used last (i.e. unlike English where the most specifying adjective comes first):

e.g. superior deep lymph nodes = *nodii lymphatici profundi superiores*

### Genitive Case

expresses possession; in anatomy, it is used to denote **parts of structures** – **REMEMBER!** the word that would have 's or comes after the preposition *of* in English has a Genitive form in Latin, e.g. *caput tibiae* = head *of* tibia / tibia's head

\*In English medical terminology, you may sometimes come across an adjective phrase instead of an *of*-phrase; however, if the term denotes a part of a structure, we still have to use Genitive in Latin; e.g. *scapular notch* is a part of scapula (= notch of scapula/scapula's notch); therefore, the Latin term uses Genitive to describe the structure (just like in the previous example): i.e. scapular notch = incisura *scapulae*

## DICTIONARY ENTRY (vocabulary format)

Dictionary entry of each noun includes three pieces of information:

- 1) basic form of the noun in Nominative singular (i.e. functioning as a subject)
- 2) Genitive ending (i.e. declension clue) \* full Genitive with short nouns (e.g. os, *ossis*, n.)
- 3) gender (necessary for the correct form of an adjective)

**It is necessary to memorize this information along with the noun itself!**

*Without learning Genitive form, you cannot classify the noun into a proper declension (Nominative form is not conclusive); thus, you cannot use the word properly in a sentence; without learning the gender, you cannot attach correct forms of adjectives to describe the nouns; besides, the nouns of neutral gender have a special set of endings.*

*fibula, ae, f.* > 1<sup>st</sup> declension noun of female gender: *fractura fibulae*; *fibula dextra*

*humerus, i, m.* > 2<sup>nd</sup> declension noun of male gender: *fractura humeri*; *humerus dexter*

*corpus, oris, n.* > 3<sup>rd</sup> declension noun of neutral gender: *fractura corporis humeri*; *corpus alienum*

*ductus, us, m.* > 4<sup>th</sup> declension noun of male gender: *obstructio ductus venosi*; *ductus venosus*

*facies, ei, f.* > 5<sup>th</sup> declension noun of female gender: *deformitas faciei*; *facies lunata*

\*Dictionary entry of adjectives includes the Nominative sg. forms/endings of all three genders (in the order m., f., n.). E.g. *longus, a, um* > all three forms mean ‘long’, but the choice of the form depends on gender of the noun it modifies.

## BASIC GRAMMATICAL CATEGORIES

1) **number**: singular (i.e. one) / plural (i.e. two and more)

2) **gender**: male / female / neutral

3) **case**: a form of a noun that indicates its grammatical role in a sentence; used to express relations of words in a sentence

Nominative (i.e. subject) / 1<sup>st</sup> case: *corpus ulnae*

Genitive (i.e. possession, like in English “of” phrases) / 2<sup>nd</sup> case: *fractura corporis ulnae*

Accusative (after certain prepositions) / 4<sup>th</sup> case: *status post operationem*

Ablative (after certain prepositions) / 6<sup>th</sup> case: *fractura sine dislocatione*

\* 3<sup>rd</sup> and 5<sup>th</sup> case are not used in medical terminology; therefore, they are omitted from the list

4) **declension**: a group of nouns declined in the same way (i.e. taking the same set of case endings)

## DECLENSION SYSTEM

DECLENSION	1	2	3	4	5
GENITIVE ENDING	-ae (-es)	-i	-is	-us	-ei
GENDER	F. <i>m.</i>	M., N. <i>f.</i>	M., F., N.	M., N. <i>f.</i>	F. <i>m.</i>
<i>exceptions</i>					
EXAMPLE	coxa, ae, f. chole, es, f. diabetes, ae, m.	humerus, i, m. cancer, i, m. diameter, tri, f. cranium, ii, n.	coccyx, gis, f. dens, dentis, m. femur, oris, n. pelvis, is, f.	arcus, us, m. manus, us, f. genu, us, n.	facies, ei, f.

## GENITIVE STEM

= a part of the word to which we attach individual case endings, hence of supreme importance for declining Latin words (it may differ significantly from the Nominative form); it is derived from the full Genitive form by removing the genitive case ending:

*vena, ae, f.* > full Genitive *venae* > remove case ending *-ae* > stem: **ven-**

*nervus, i, m.* > full Genitive *nervi* > remove case ending *-i* > stem: **nerv-**

*corpus, oris, n.* > full Genitive *corporis* > remove case ending *-is* > stem: **corpor-**

For instance, if we want to say “veins”, “nerves”, or “bodies” in plural, we attach a case ending (based on the declension table) to the Genitive stem of the word (not to the Nominative form).

> *vena* in Plural: *venae*, not ~~*venae*~~

> *nervus* in Plural: *nervi*, not ~~*nervusi*~~

> *corpus* in Plural: *corpora*, not ~~*corpusa*~~

>>>For the pronunciation rules, see the .ppt in study materials (week 1)<<<

## PREPARATION FOR THE NEXT CLASS

**With the help of the declension table decide on the declension of the given nouns, and write down their full Genitive forms and genitive stems.**

Autumn Term 2019/2020 Handout 1

<i>dictionary entry</i>	<i>declension</i>	<i>full genitive</i>	<i>stem</i>
corpus, oris, n			
caput, itis, n			
os, ossis, n			
collum, i, n			
cervix, icis, f			
abdomen, inis, n			
vena, ae, f			
humerus, i, m			
femur, oris, n			
facies, ei, f			
arcus, us, m			
manus, us, f			
pes, dis, m			
genu, us, n			
pectus, oris, n			
capilli, orum, m			
os, oris, n			
antebrachium, ii, n			
coxa, ae, f			
dens, ntis, m			
sternum, i, n			
thorax, acis, m			
costa, ae, f			
cranium, ii, n			
coccyx, gis, f			
radius, ii, m			
pelvis, is, f			
vertebra, ae, f			
nasus, i, m			
oculus, i, m			
cutis, is, f			
clavicula, ae, f			