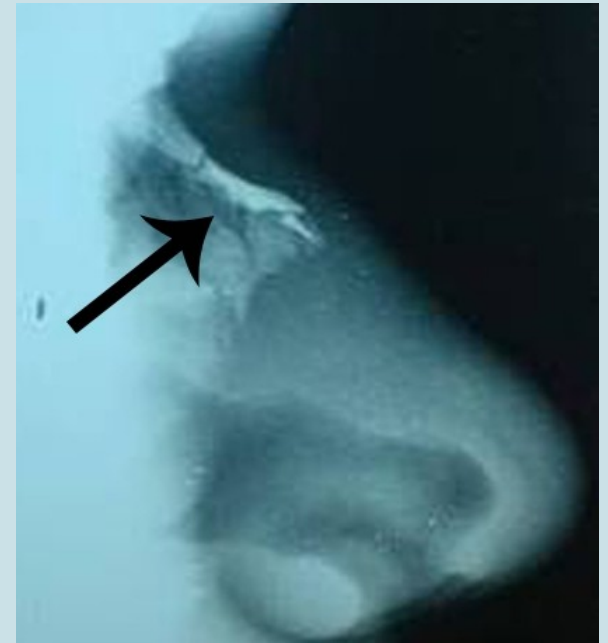
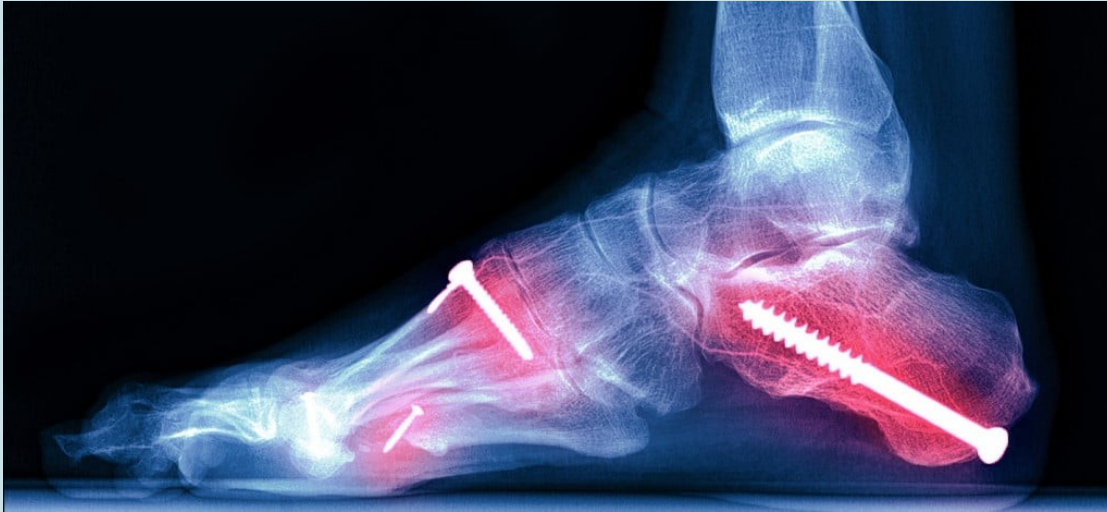

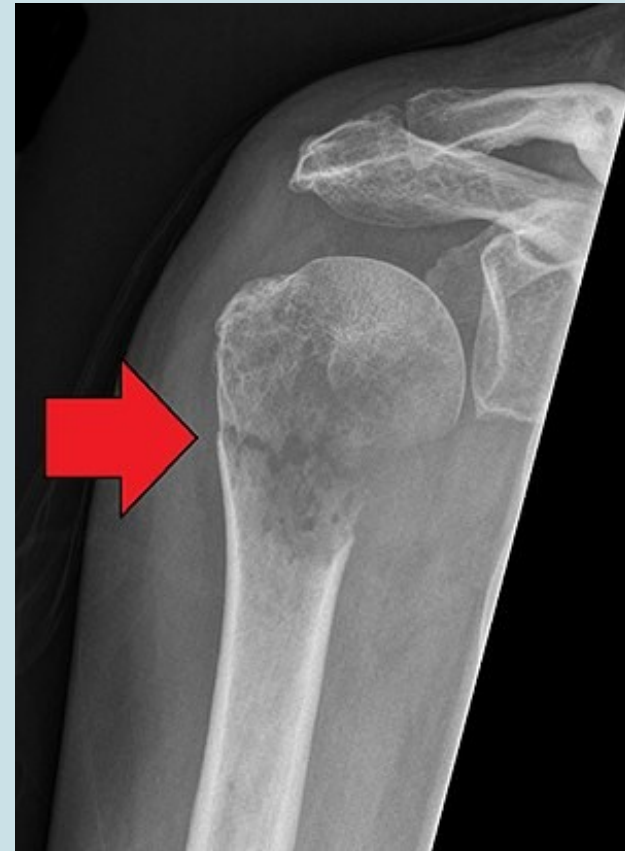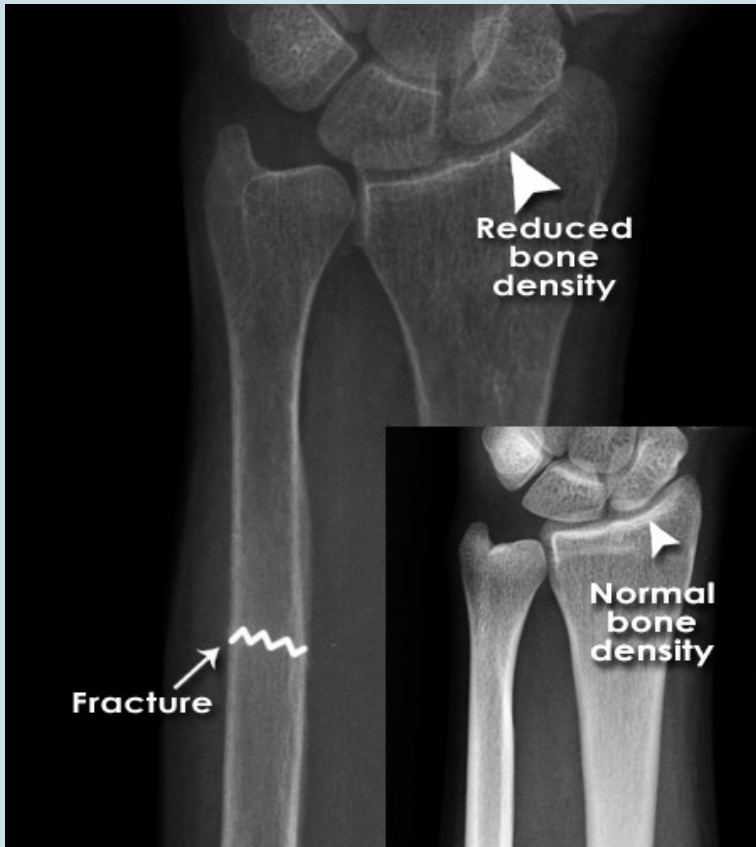Fractures

Fractura traumatica



trauma, atis, n. > traumaticus, a, um
i.e. caused by injury

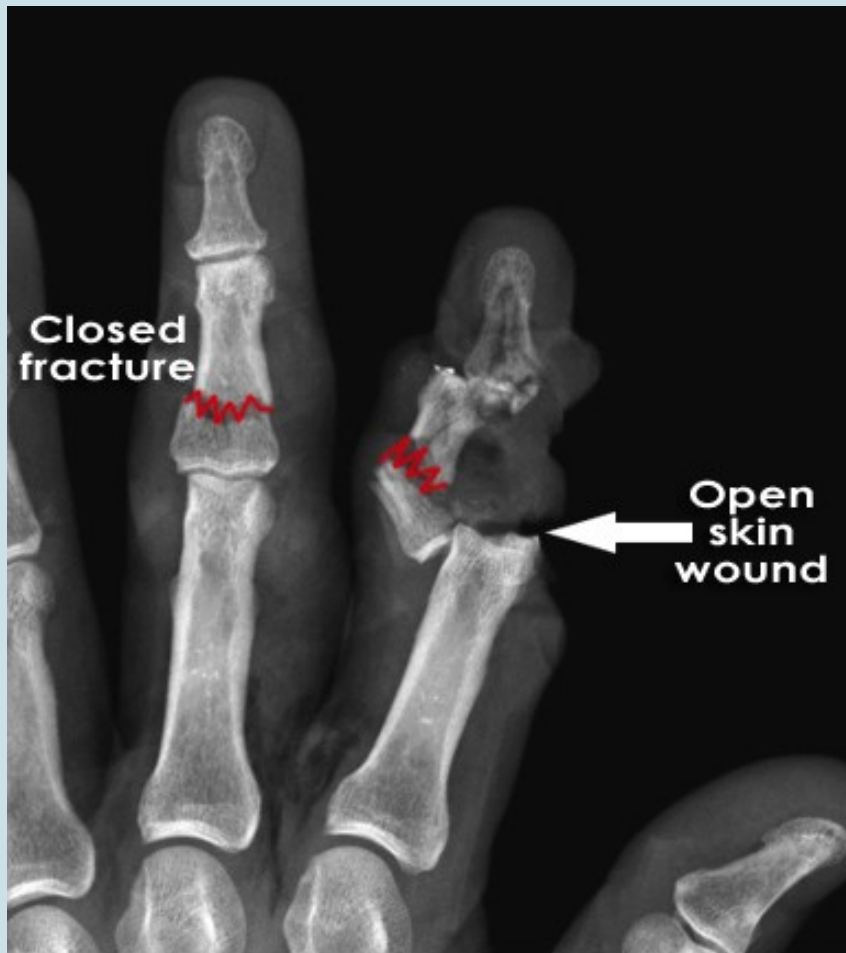Fractura pathologica



pathologia, ae, f. > pathologicus, a, um
i.e. caused by a disease

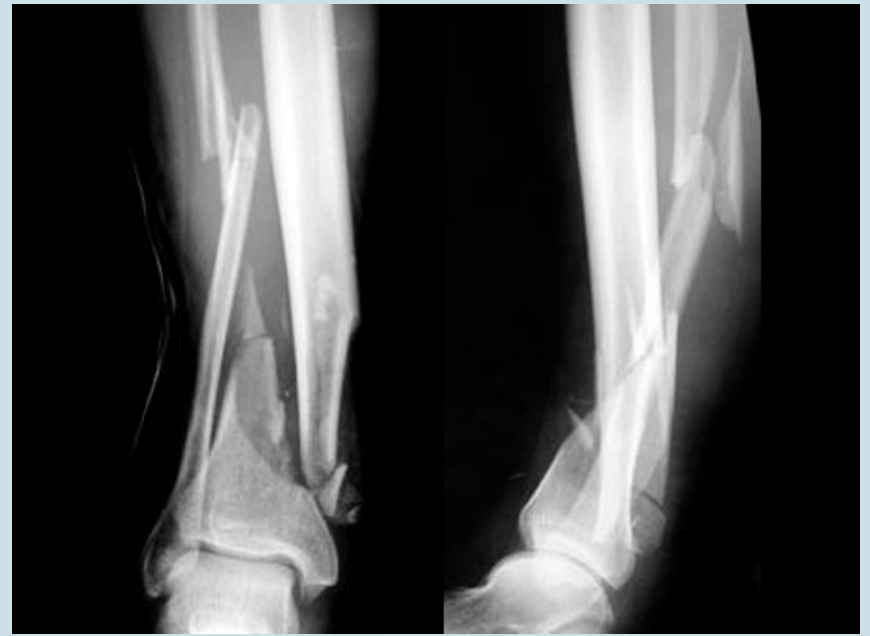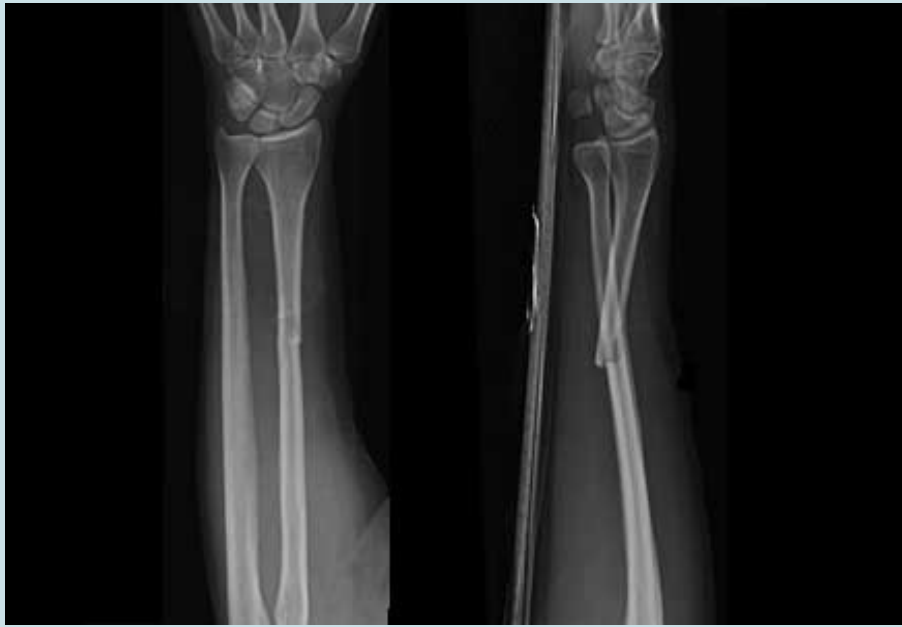Fractura aperta v clausa

NOTE!!! APERTURA, AE, F. X APERTUS, A, UM



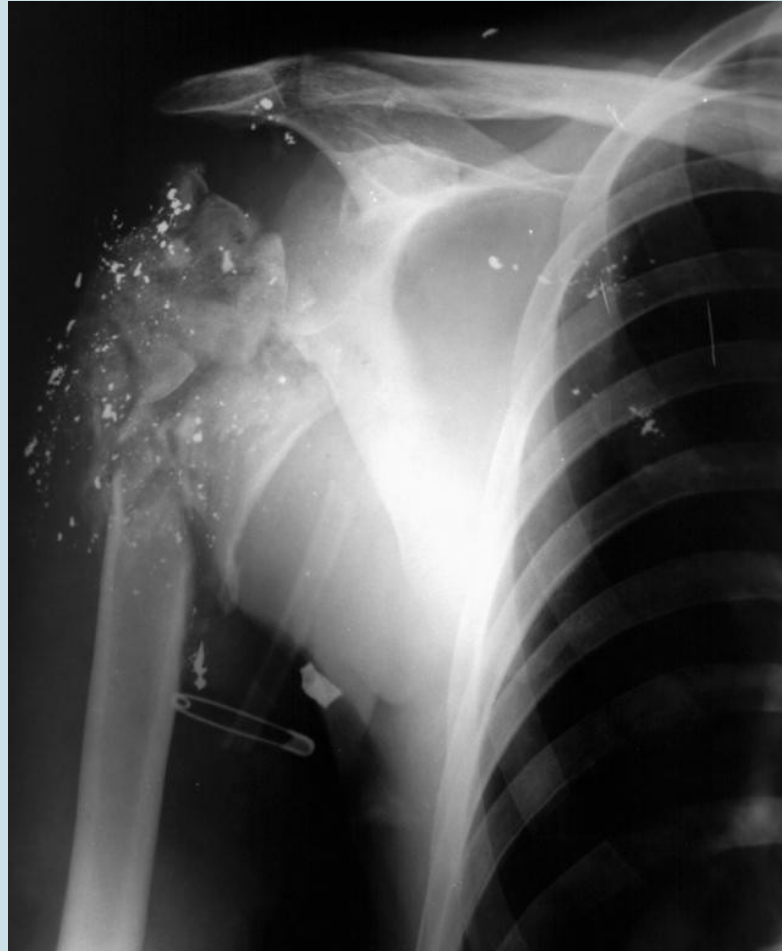
Write a medical record for the picture!

Fractura simplex v multiplex

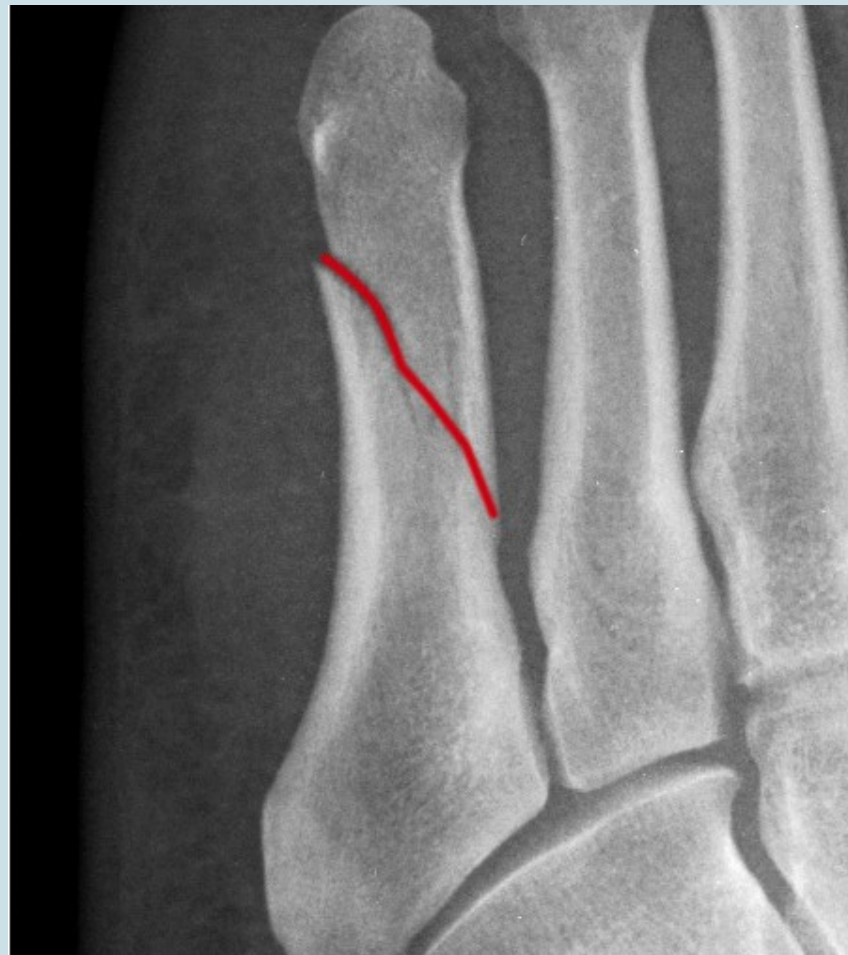
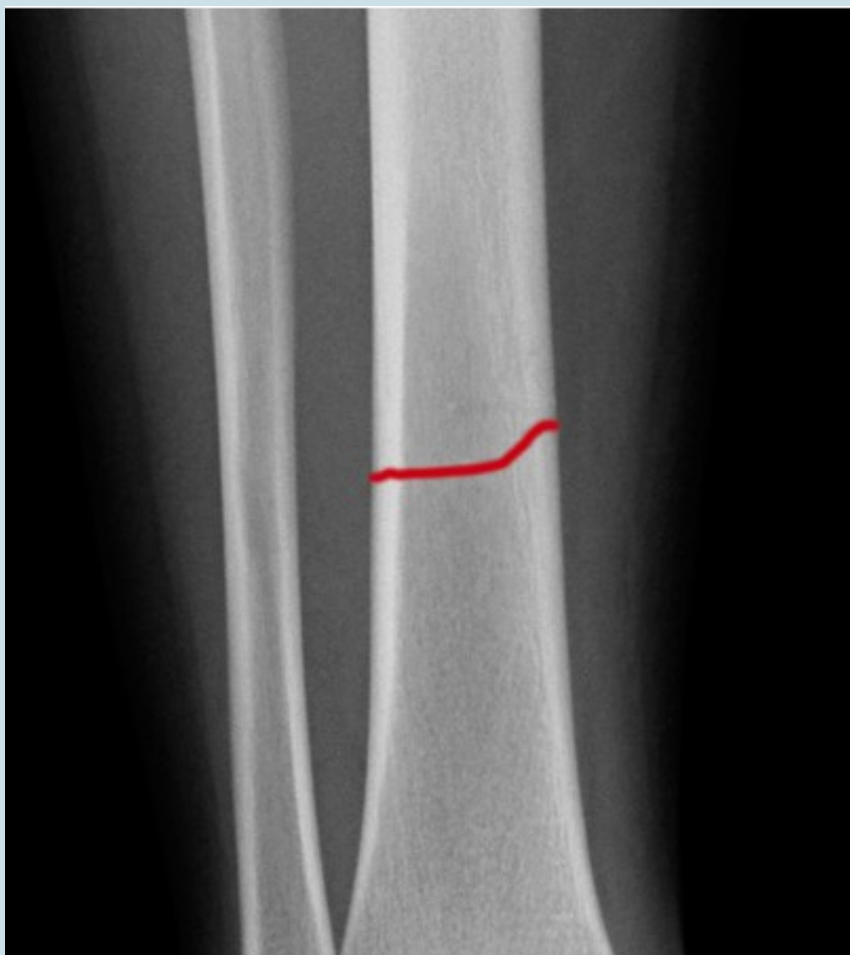
Write medical records for the pictures!

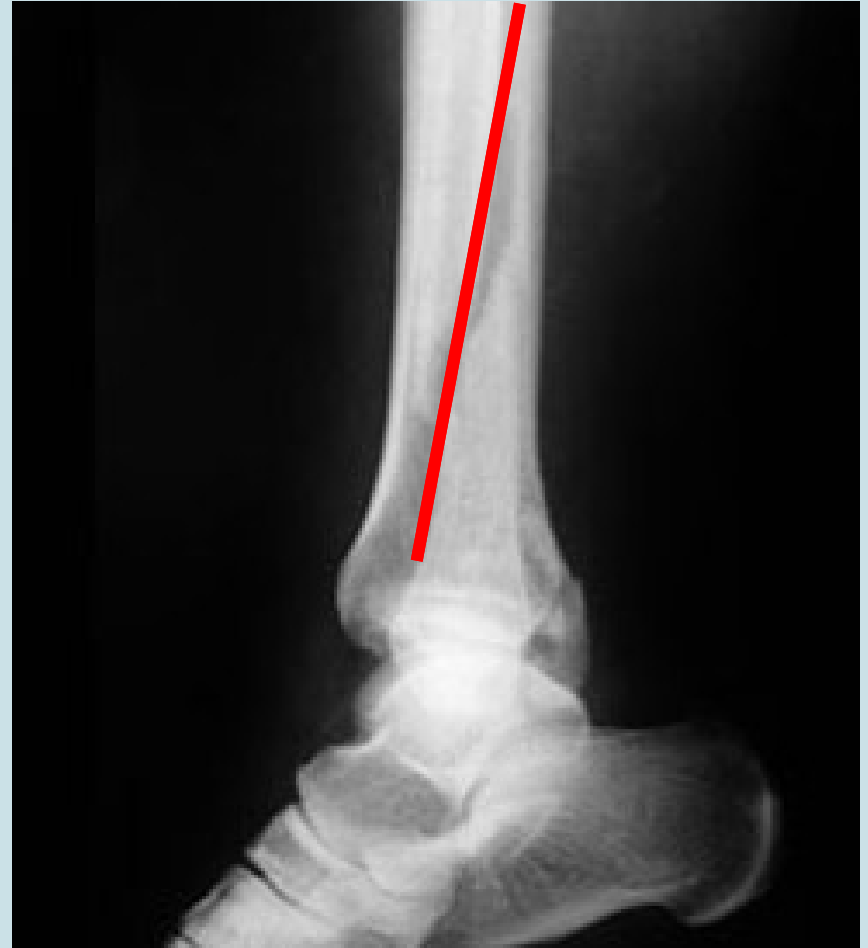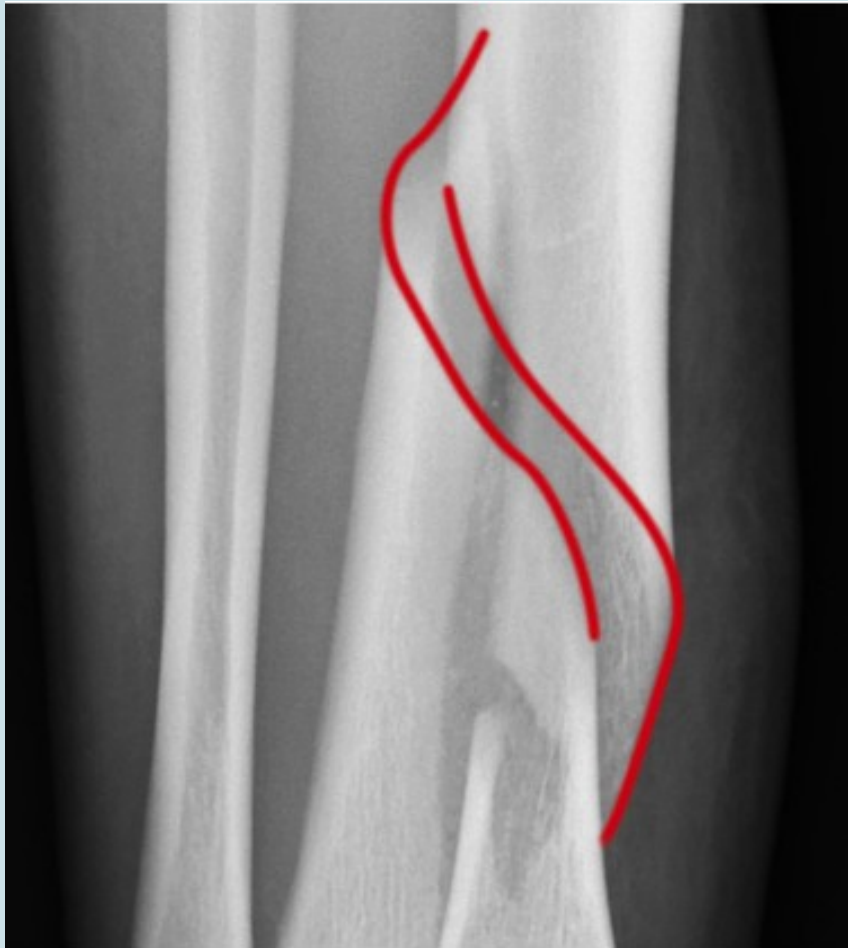Fractura comminutiva



Fractura transversa v obliqua

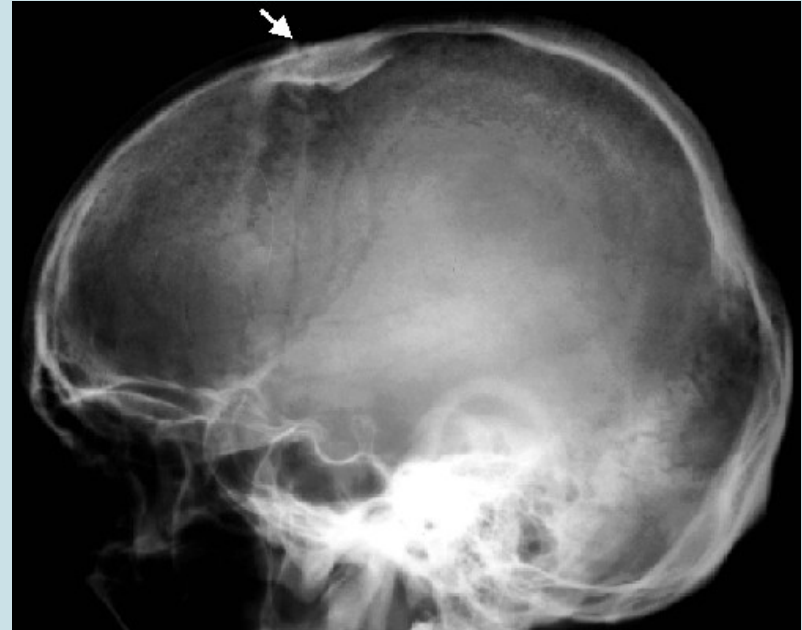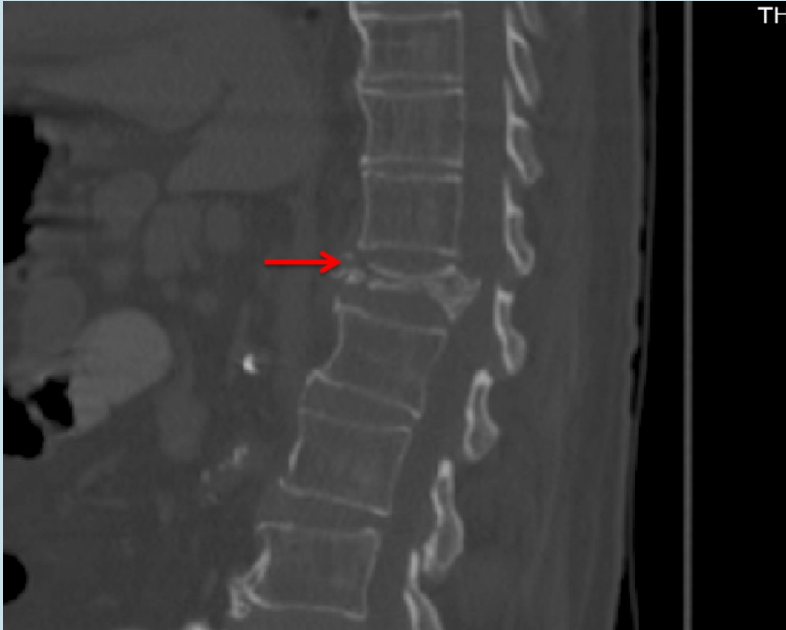


Fractura spiralis v longitudinalis

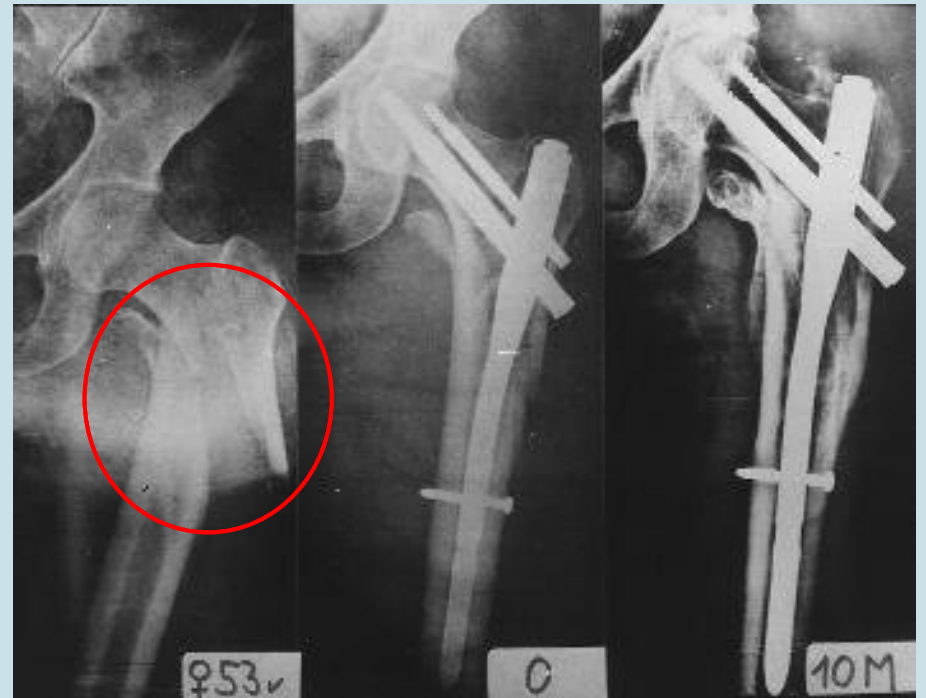
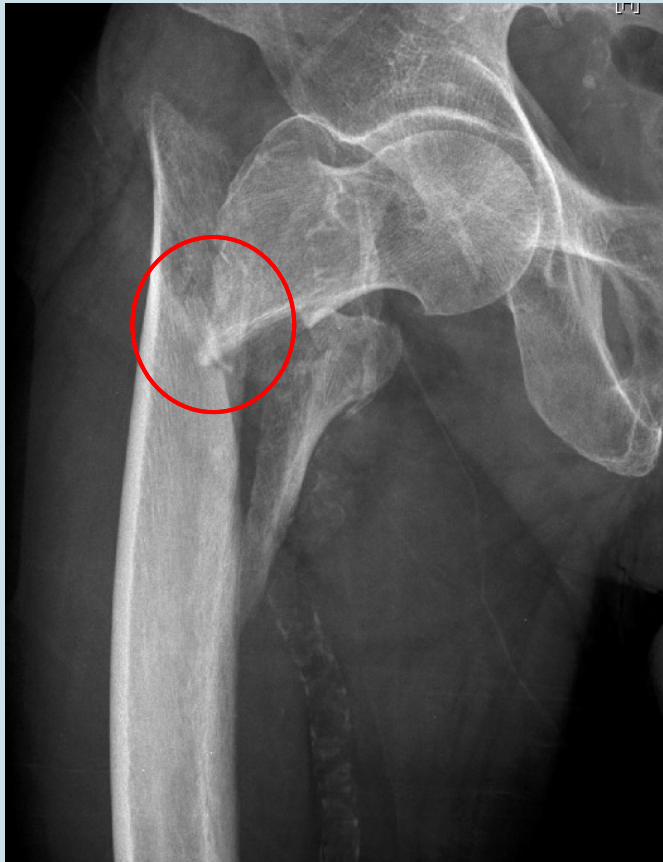

Fractura *compressiva* v *impressiva*

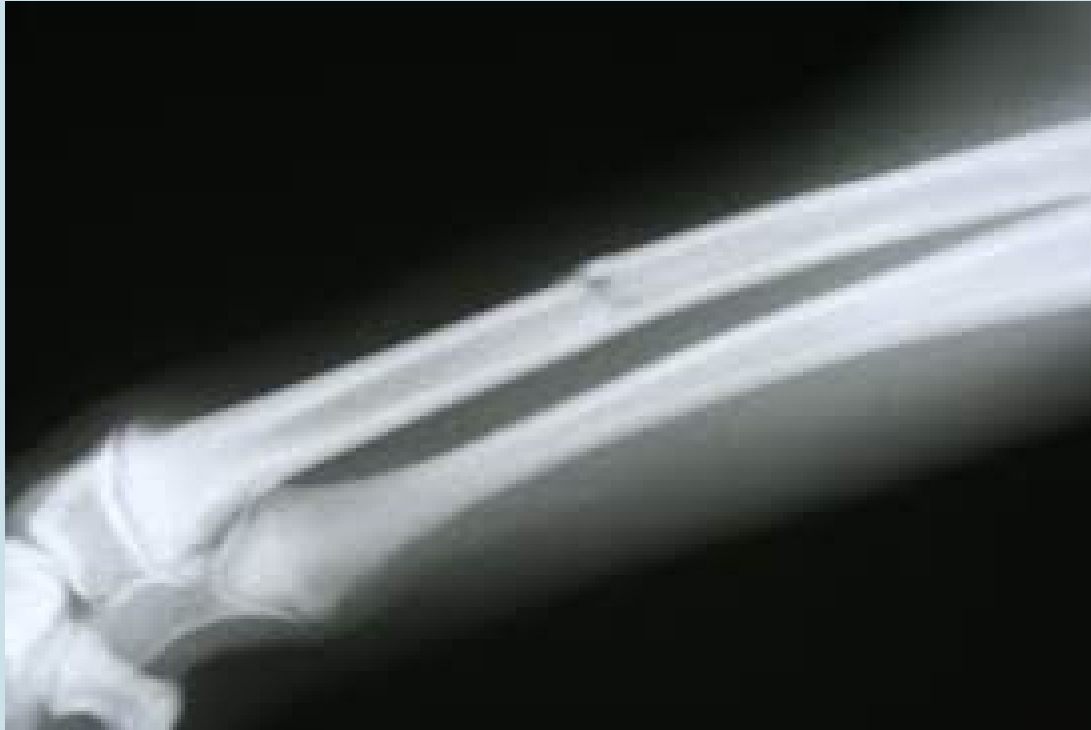~ pressure caused



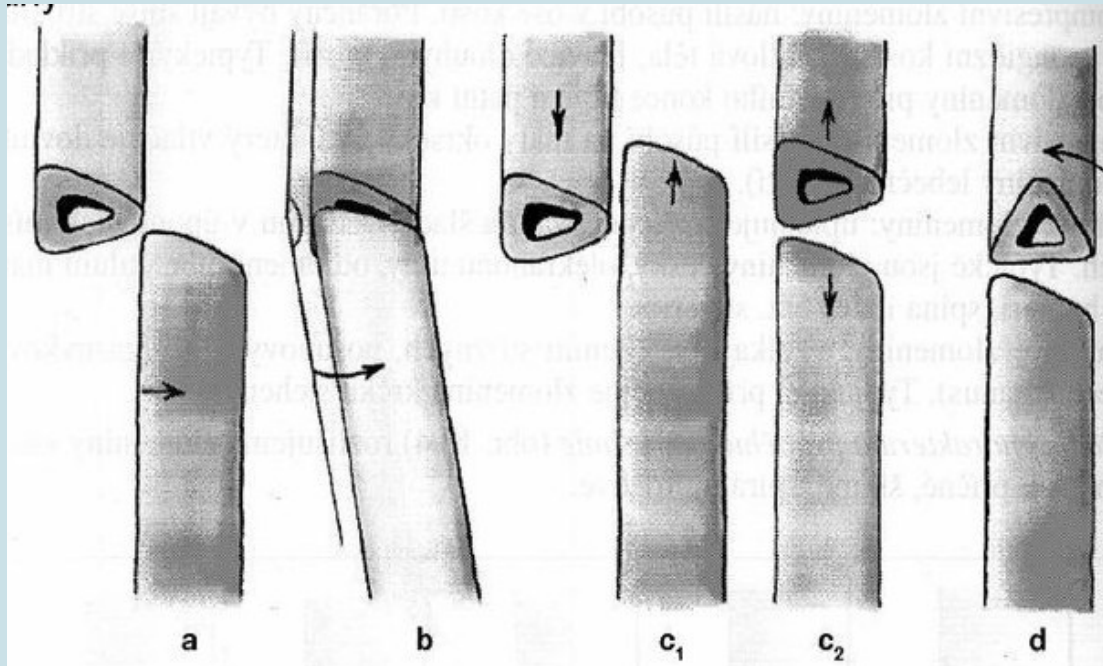
Fractura incuneata



Infractio, onis, f. = f. partialis =
f. incompleta

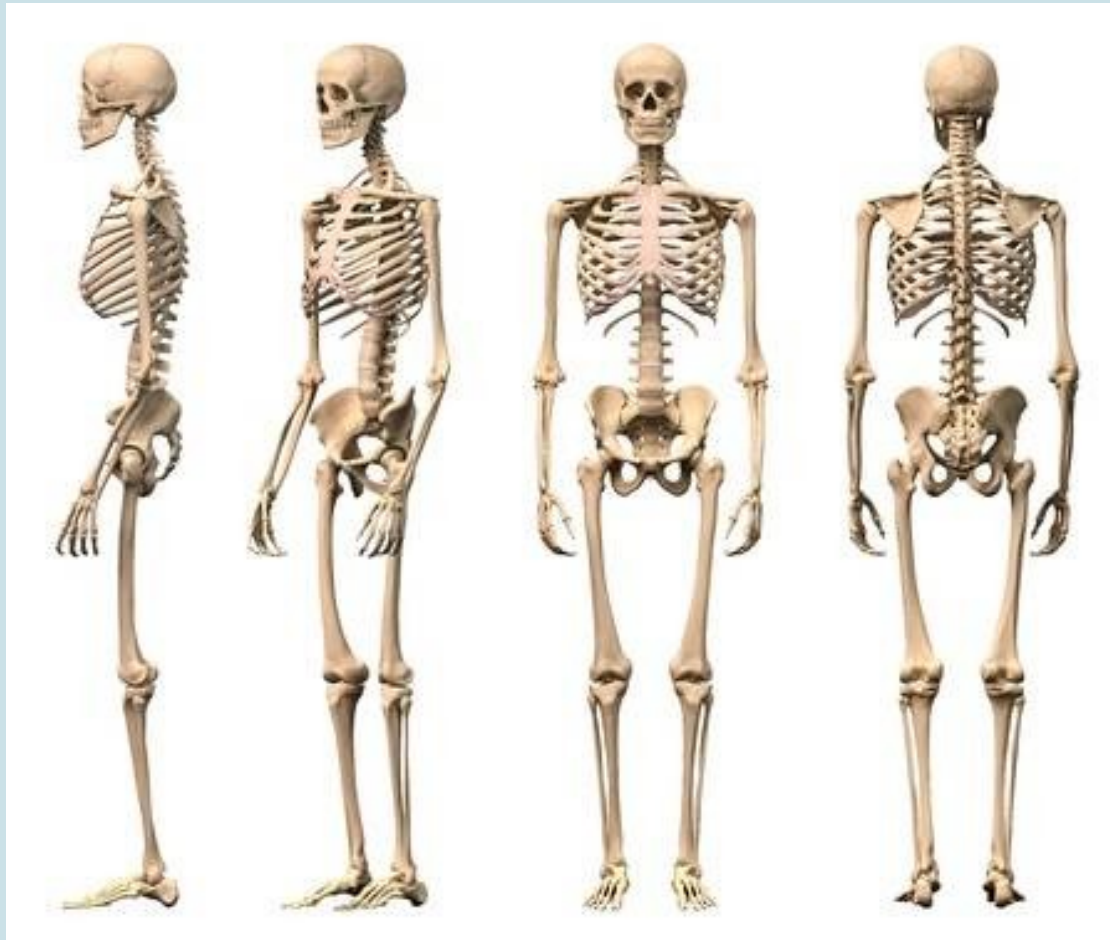


Fractura cum dislocatione ad...



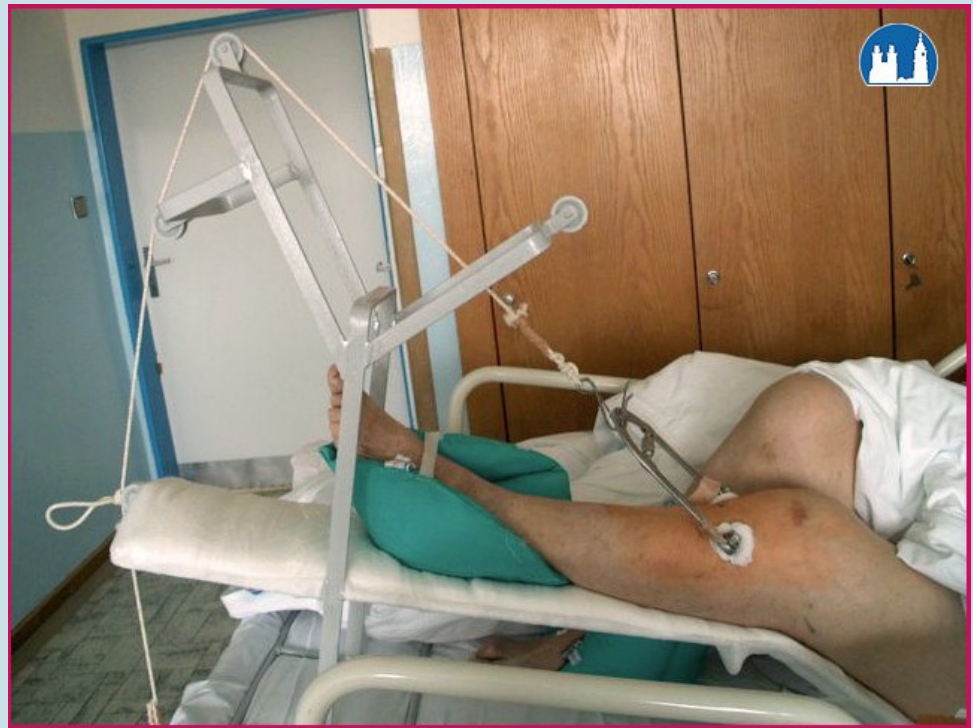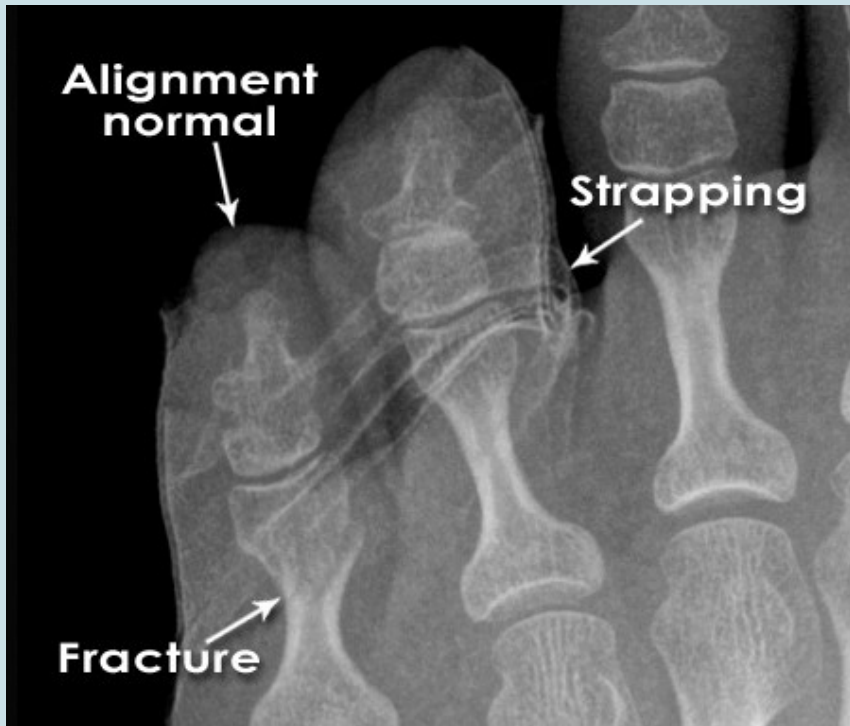- a) **ad latus**
- b) **ad axim**
- c₁) **ad longitudinem cum contractione**
- c₂) **ad longitudinem cum distractione**
- d) **ad peripheriam**

Choose a bone and break it. Try to write as much detailed diagnosis as possible.



Fracture Healing:

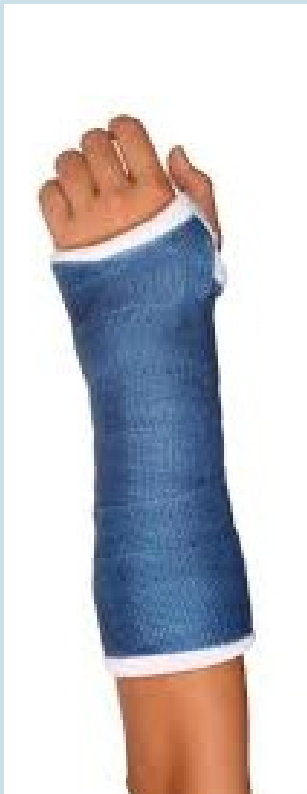REPOSITIO = REDUCTIO fragmentorum



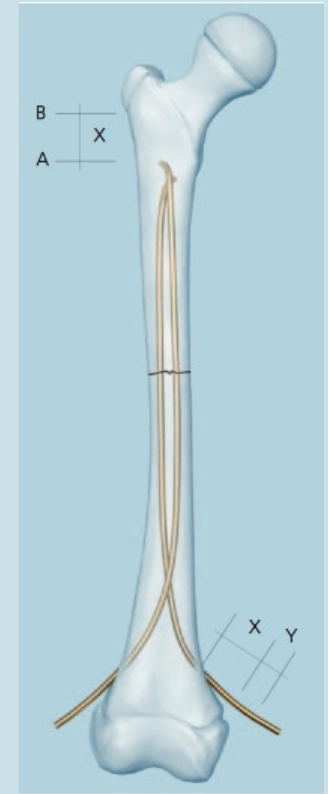
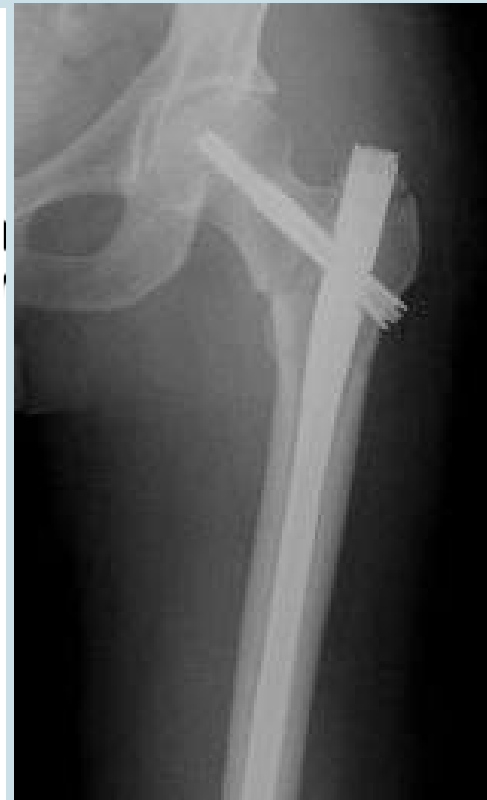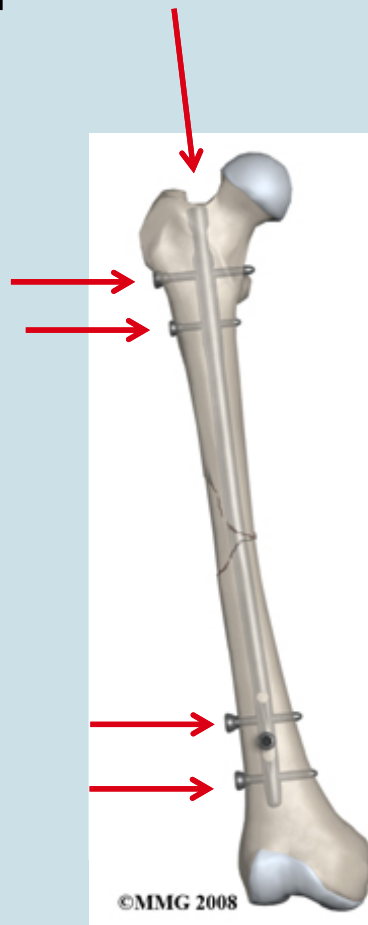
Fracture Healing:

FIXATIO = STABILISATIO fragmentorum

PLASTER CAST



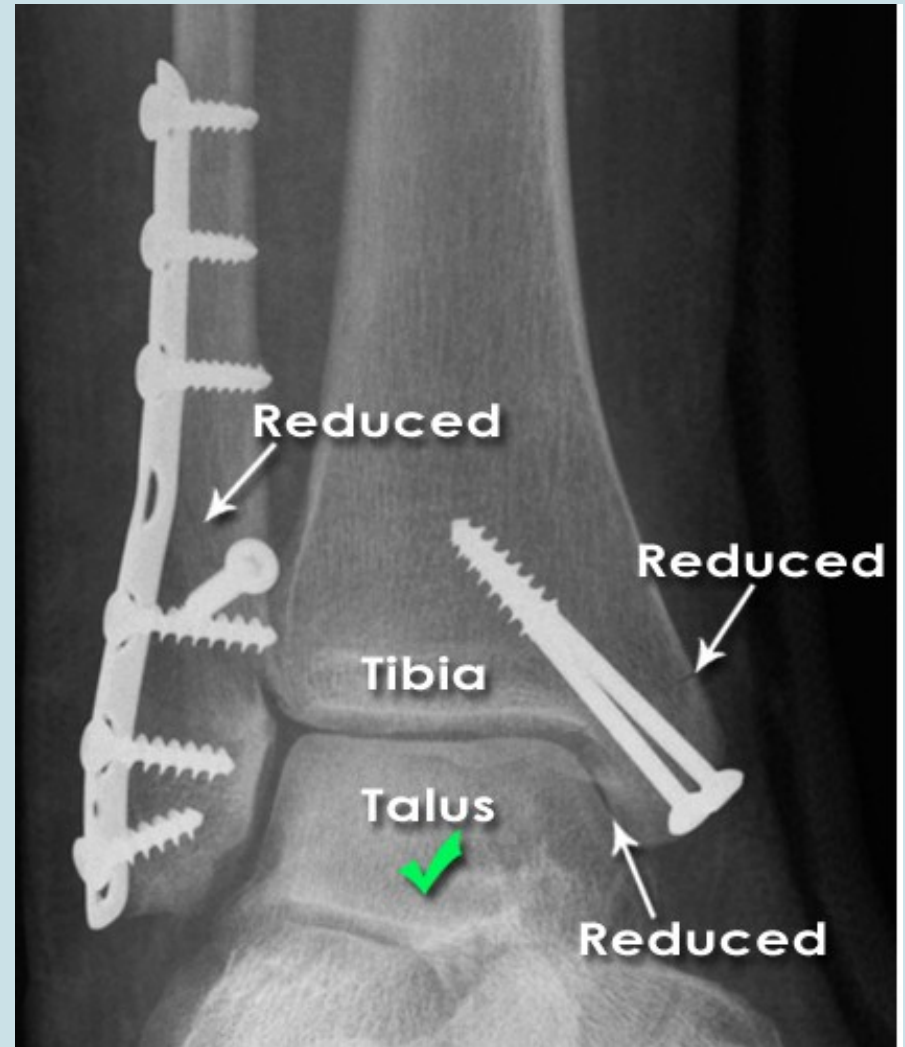
INTERNAL FIXATION



Fracture Healing:

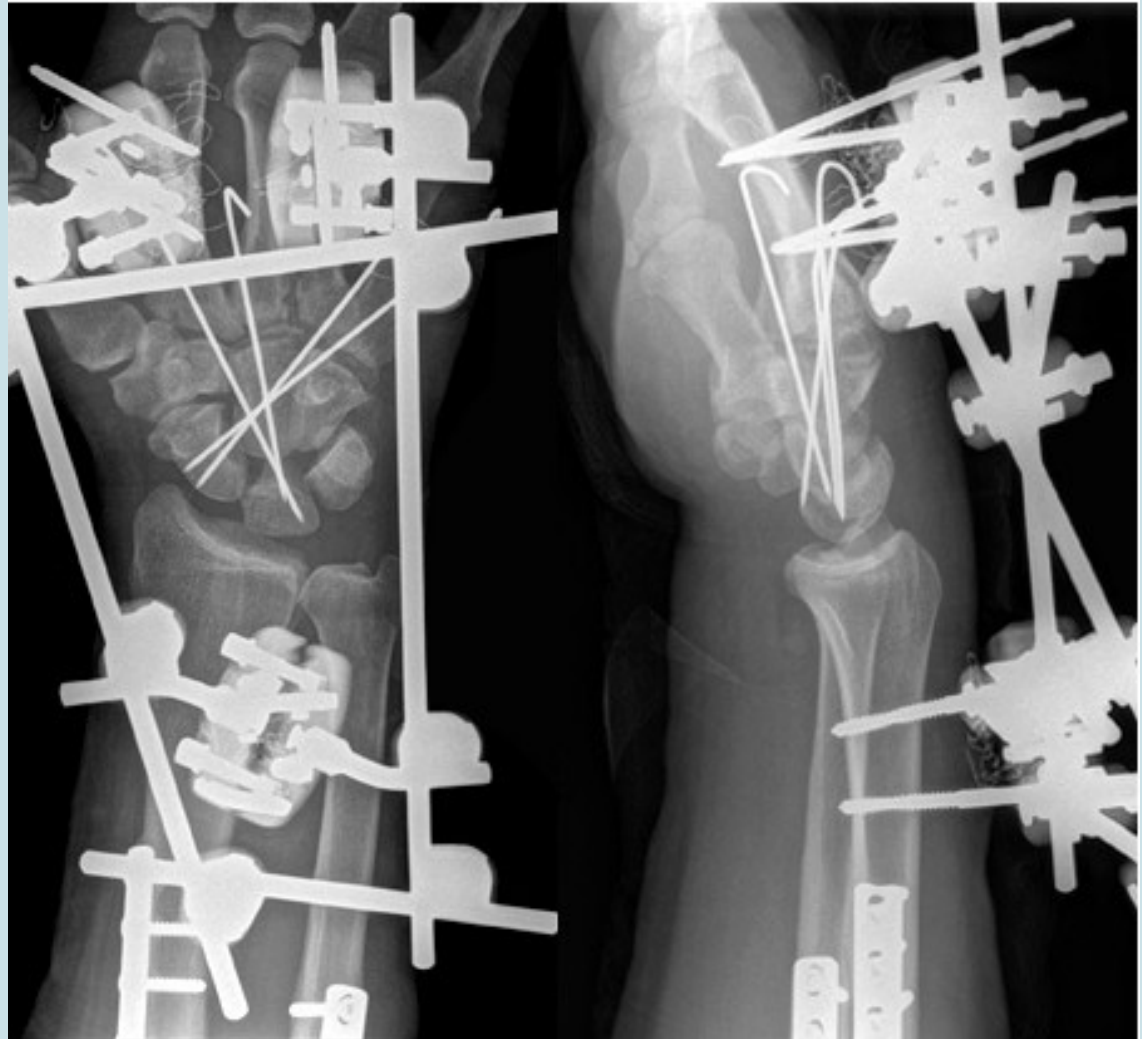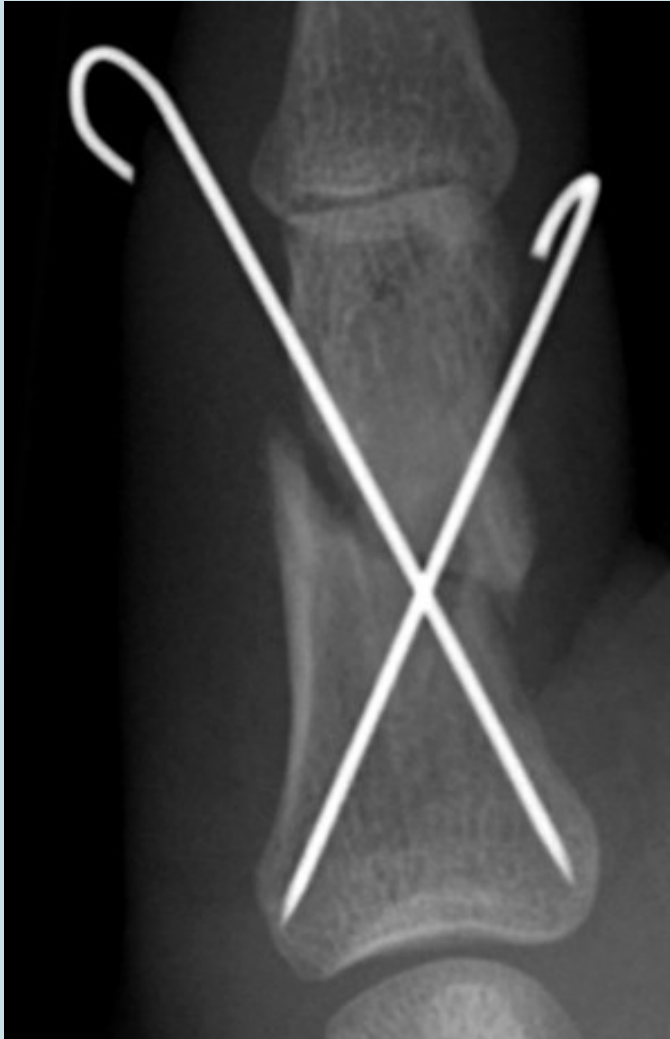FIXATIO = STABILISATIO fragmentorum

INTERNAL FIXATION

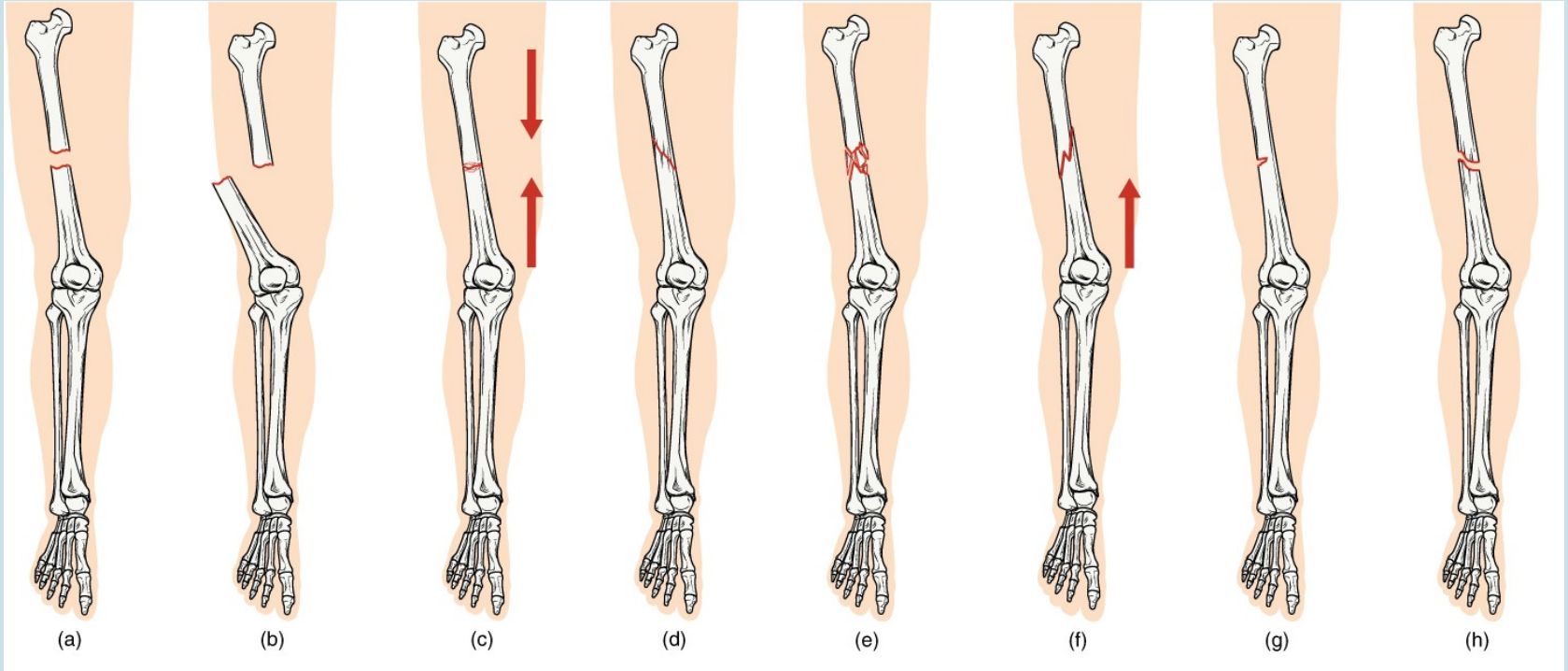


Fracture Healing:

FIXATIO = STABILISATIO fragmentorum



Name the types of fractures



Authentic report 1

Dg:

S8220 Fr. cruris l.sin cum fr.fibulae duplex disloc.aperta
stp. OS FE 17.7. 2010
V2331 Mot.x auto,;zra.při nás.,výt.;volný čas
S730 Luxatio coxae l.sin centralis stp. repositionem 17.7
S332 Luxatio art. SI l. sin stp. reposit. 17.7.
S3240 Fr. acetabuli l.sin transv.disloc. stp. OS 19.7.
S818 Decollement partis proximalis cruris l.sin.
S711 Vulnus lacerum reg. femoris l.sin.

* **collement** = severe damage of soft tissues

Mark all adjectives and distinguish their type!

Authentic report 2

Dg: T068 Polytrauma
I259 Srdeční selhání
S3200 Fractura corporis vertebrae lumbalis II.
S2240 Fractura costarum IV.-XII. l.sin.
S2700 Pneumothorax l.sin.
S2710 Haemothorax l.sin.
S3240 Fractura acetabuli l.sin.
S3210 Fractura massae later. l.sin. ossis sacri
S3250 Fractura rami superior et inferior ossis pubis l.sin.
S7200 Fractura subcapitalis femoris l.sin.
S4241 Fractura epicondyli ulnaris humeri l.sin. aperta Tscherne I
W1311 Pád z bud.,konstr.n.propad.;obytné instituce;volný čas



*Fr. aperta TSCHERNE I

- open fracture with small skin injury without its contusion
- negligible bacterial contamination

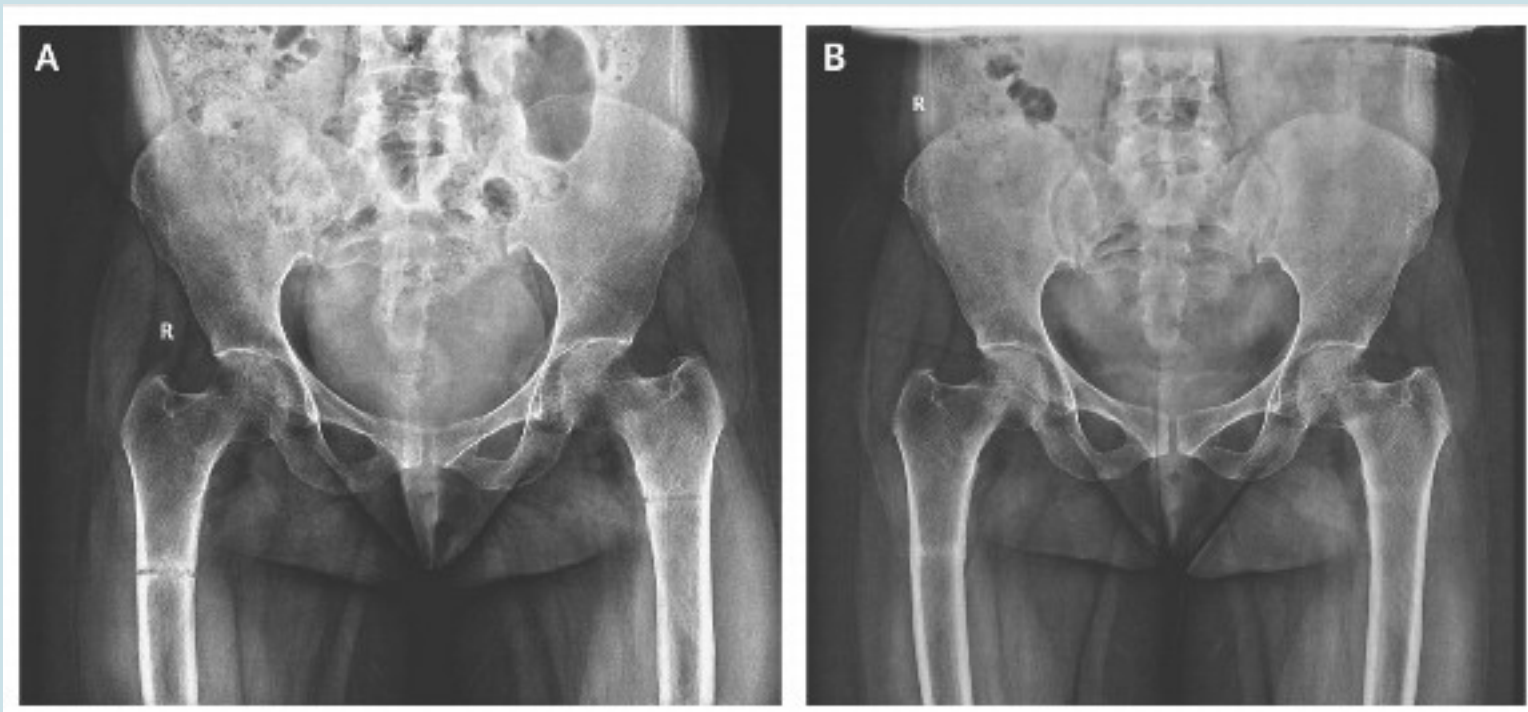
Profesor Dr. Harald **Tscherne** (1933), Traumatology Clinic, Hannover: *Classification of fractures* published in 1982, T. divides fracture into open and closed. The most important for him is the degree of the soft tissues damage.

Authentic report 3

Dg: T068 Polytrauma
V1701 Cykl.řid.x pev.přek.;neprov.neh.;volný čas
S0640 Haemorrhagia epidurale reg. temporale l.sin
F100 Ebrietas aethylica
S0601 Commotio cerebri
S0240 Fr.compl. zygomaticomaxillaris l.sin cum hemosir
S4201 Fr.claviculae l.sin apeta
S4210 Fr. scapulae l.sin comminutiva
S0210 Fr.allae ossis sphenoidalis l.sin cum hemosinus
S2240 Fr.costarum II-IV hemithoracis l.sin
S2700 Pneumothorax traum. reg. dorsobasale l.sin /dle
S2720 Fluidothorax l.sin. min. dle RTG
S2730 Contuio pulmonisl.sin, reg.dorsobasale
S407 Excoriationes extrem.super. l.sin multipl.
S607 Excoriationes digitorum manuum bilat.
S013 Dilaceratio auriculae l.sin

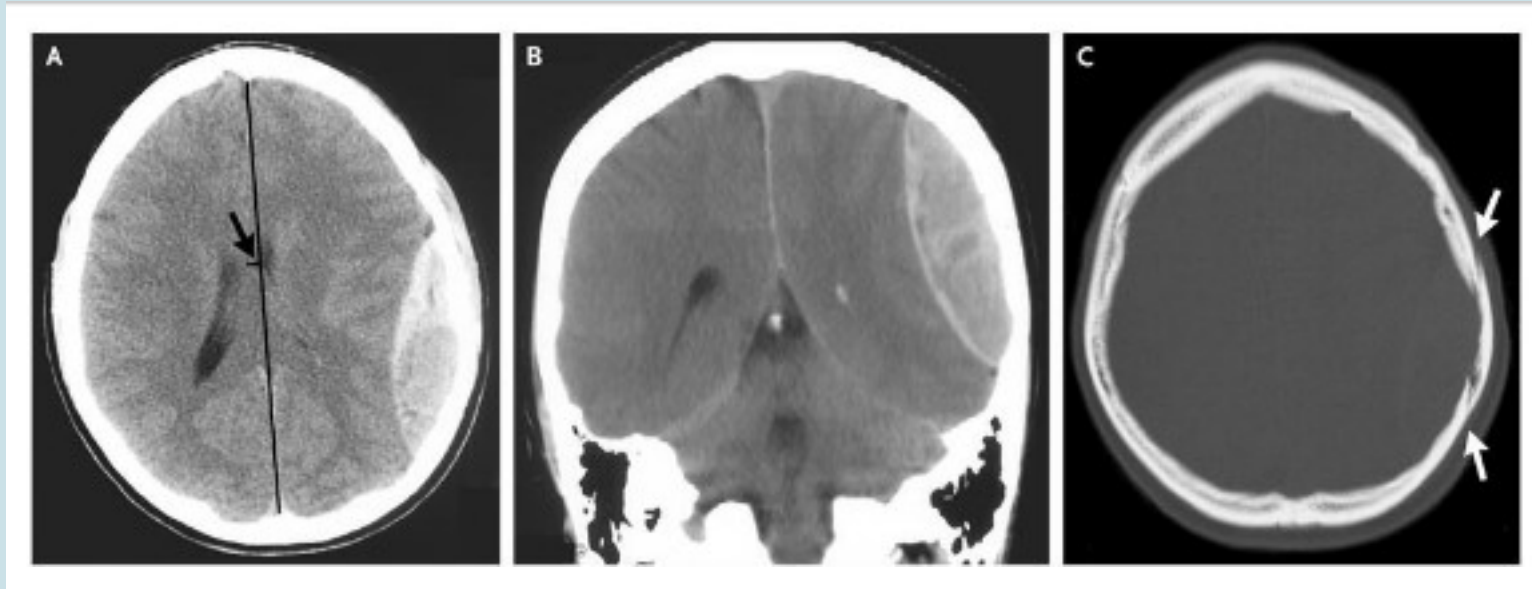
Find mistakes!

1



A 45-year-old woman presented with a 3-month history of generalized body pains nonresponsive to analgesic agents. Along with low back pain, she had progressive difficulty in getting up from sitting and supine positions and in walking. There was no history of trauma or any medication intake. She is an orthodox believer who wears a black veil outdoors and is completely covered, with little exposure to the sun. An anteroposterior radiograph of the pelvis showed an *undisplaced transverse fracture of the shaft of both femurs*. The patient was treated with therapeutic doses of calcium and vitamin D supplements.

2



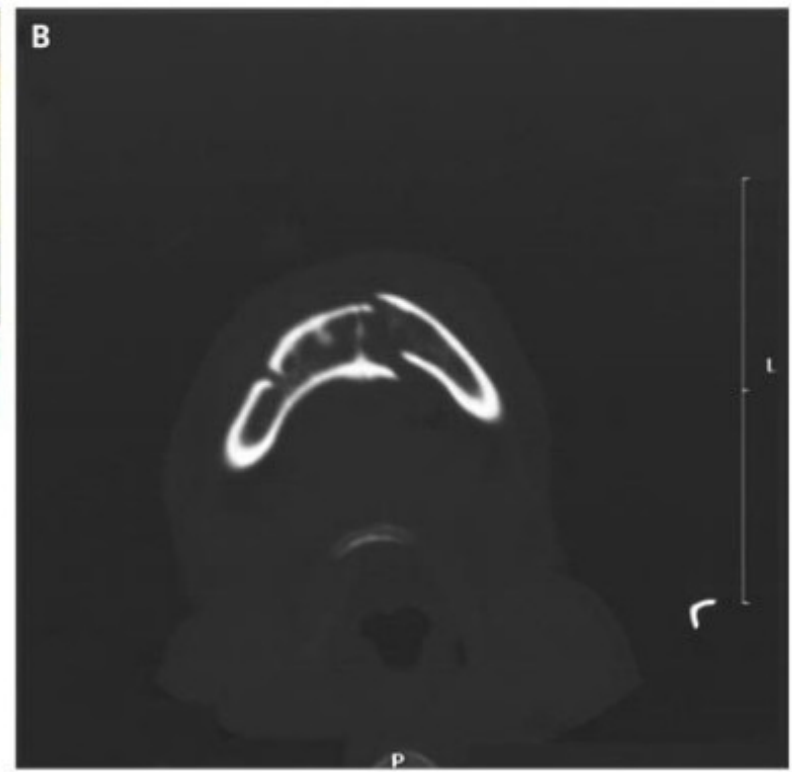
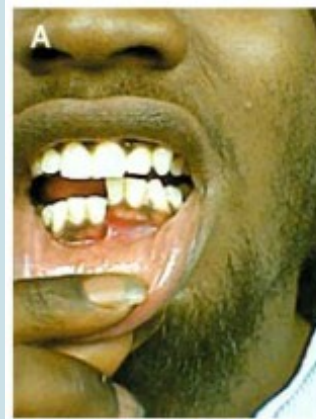
An 18-year-old slightly intoxicated man was assaulted with a glass bottle on the left parietal region of his head and had a 5-minute loss of consciousness. Two hours after the injury he was presented to a local emergency with severe headache, nausea, and repeated vomiting. Computed tomography of the head revealed a 2.5-cm *epidural hematoma in the left parietal region* (Panels A and B) underlying *a linear nondisplaced skull fracture* (Panel C, arrows).

3

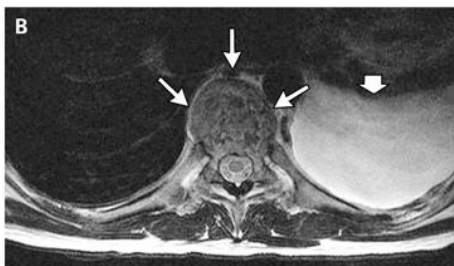
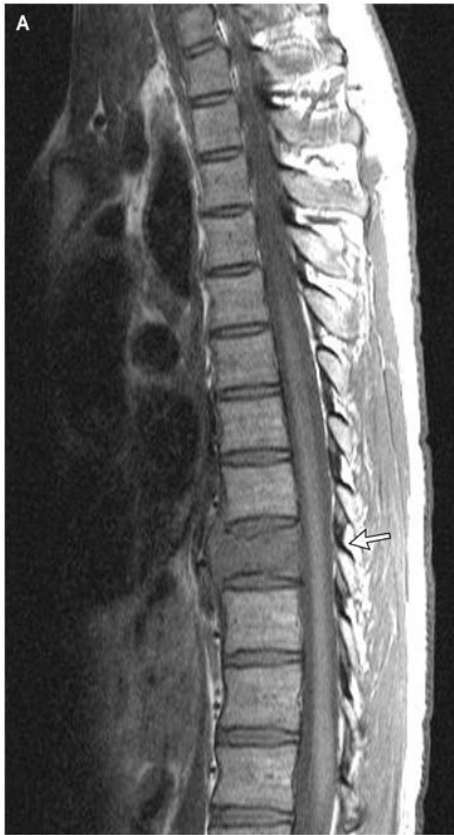A 21-year-old man presented after being struck with a gun on his right lower jaw.

Examination revealed displacement of the

left half of his mandible with malocclusion on biting (Panel A). Computed tomography showed a *fracture of the left mandible and a fracture of the right mandibular body and angle* (Panel B). Given the U shape of the mandible, it is common for contralateral fractures to result from major injury. Intravenous analgesics and antibiotics were given; the patient underwent *open reduction with internal fixation of his fractures*.

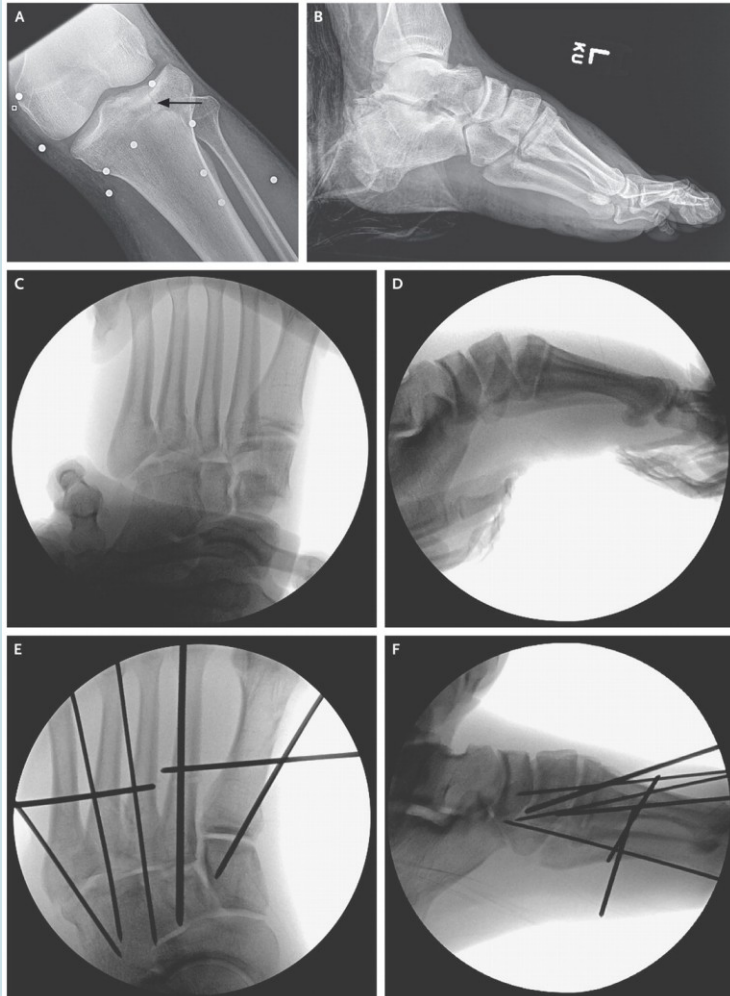

4



A 26-year-old man was admitted to this hospital because of back pain and a mass in the lung. He had been well until 17 days before admission, when he bent down to lift something and felt a sudden snap in his back, followed by pain that was associated with profuse diaphoresis and muscle spasms that extended from the left shoulder to the buttocks but did not radiate to the legs. He was unable to stand up straight and had difficulty breathing and sleeping because of the pain. The next day, magnetic resonance imaging (MRI) of the spine at that facility revealed *a pathologic T9 vertebral fracture* with soft-tissue extension beyond the vertebral body, *a chronic anterior wedge-compression fracture of the L1 vertebra*, degenerative changes in the L5–S1 intervertebral joint, and a large pleural effusion on the left side.

5



A 34-year-old man was brought to the emergency department at the hospital because of multiple traumatic injuries that he sustained when a bomb exploded while he was watching the 2013 Boston Marathon. At the scene, the patient reportedly lost consciousness, had a complete amputation of his right leg directly below the knee, and had copious blood loss. A plain radiograph of the left tibia and fibula (Figure 3A Radiographs of the Injuries of the Left Leg.) revealed *multiple metallic foreign bodies around the knee and a nondisplaced fracture of the lateral tibial plateau*. Plain radiographs of the left foot and ankle revealed *a comminuted fracture of the calcaneus* (Figure 3B), minimally displaced cuboid and cuneiform fractures, and subluxation of multiple tarsometatarsal joints, evidence of a ligamentous Lisfranc injury (dislocation of the tarsometatarsal joints due to midfoot trauma; named after the military surgeon in Napoleon's army) (Figure 3C).