

Basic Medical Terminology

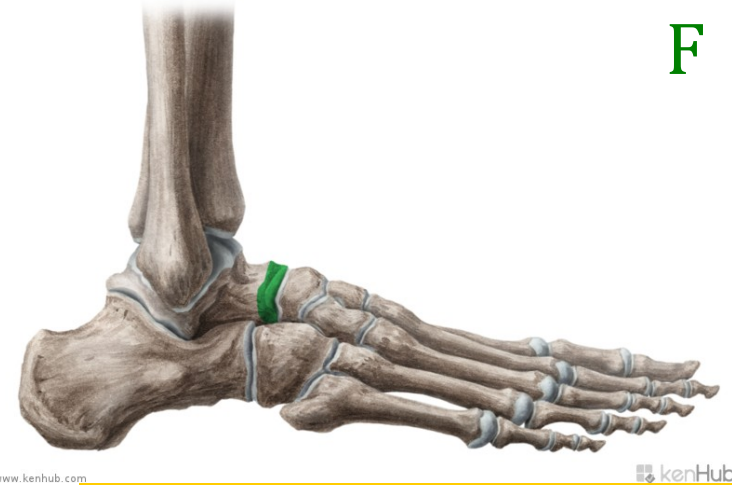
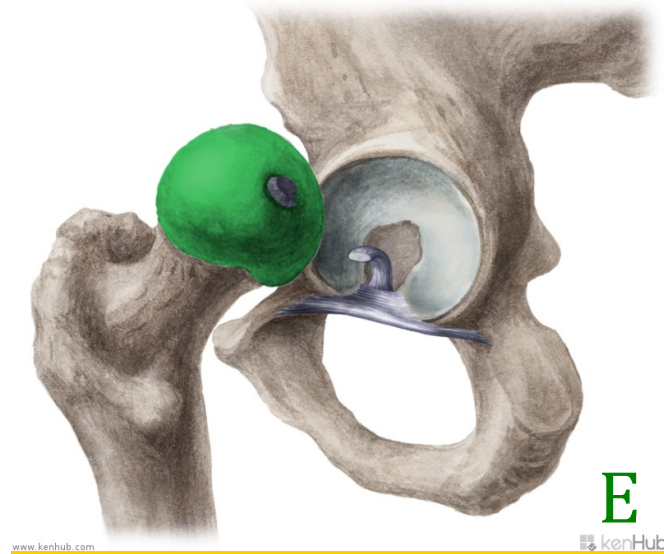
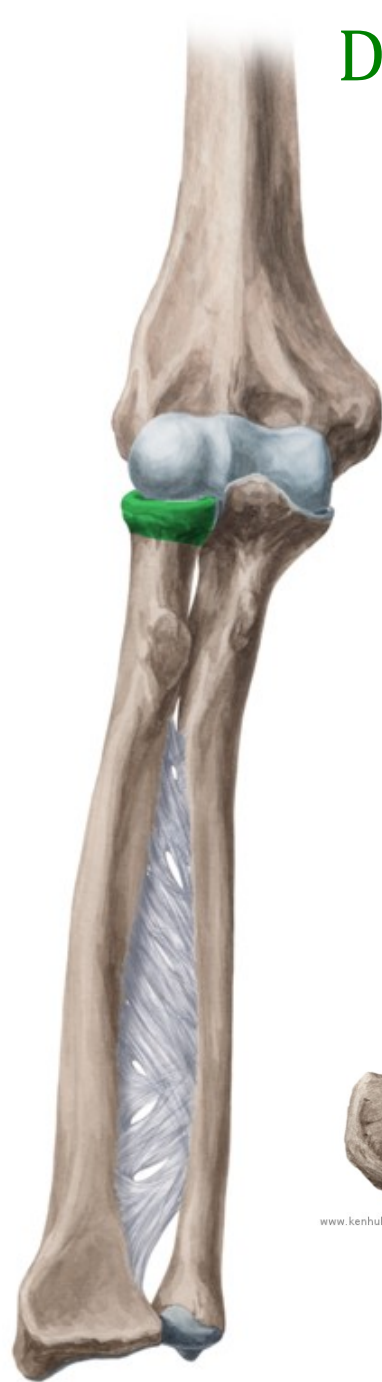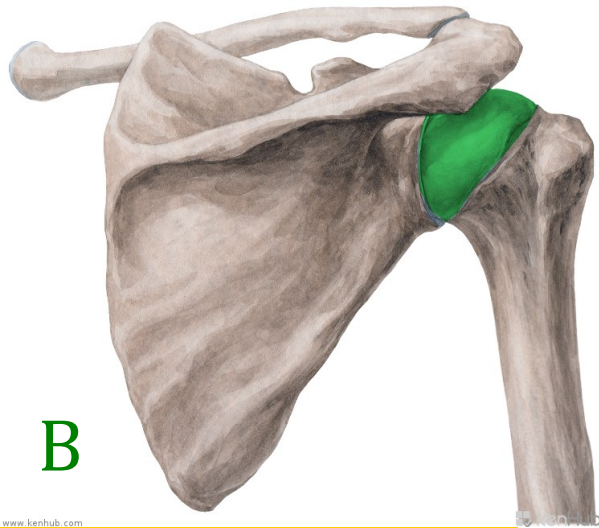
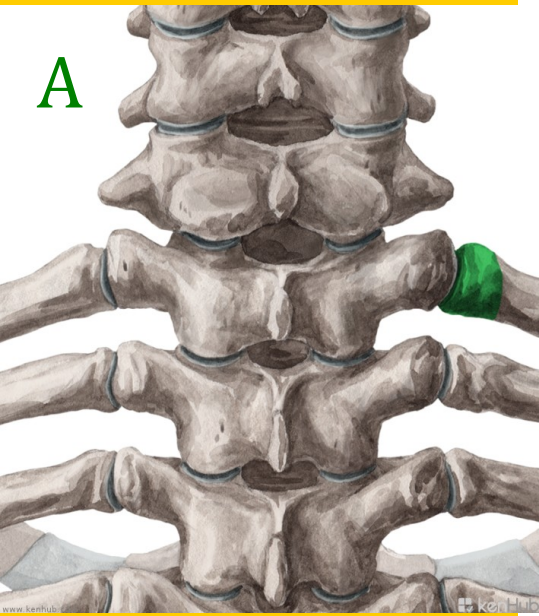
Seminar 3

Pronunciation practice

- Musculus latissimus dorsi
- Pars respiratoria tunicae mucosae nasi
- Vena aquaeductus cochleae
- Hiatus oesophageus
- Protuberantia occipitalis externa
- Cum anaemia perniciosa
- Nucleus ruber

Revision

- What is a non-agreed attribute?
Give an example.
- Which cases are used with Latin prepositions?
- Explain the difference in meaning between *in venam* and *in vena*.
- Which Latin prepositions require the use of the ablative case?



Head of... ?

Create meaningful diagnoses!

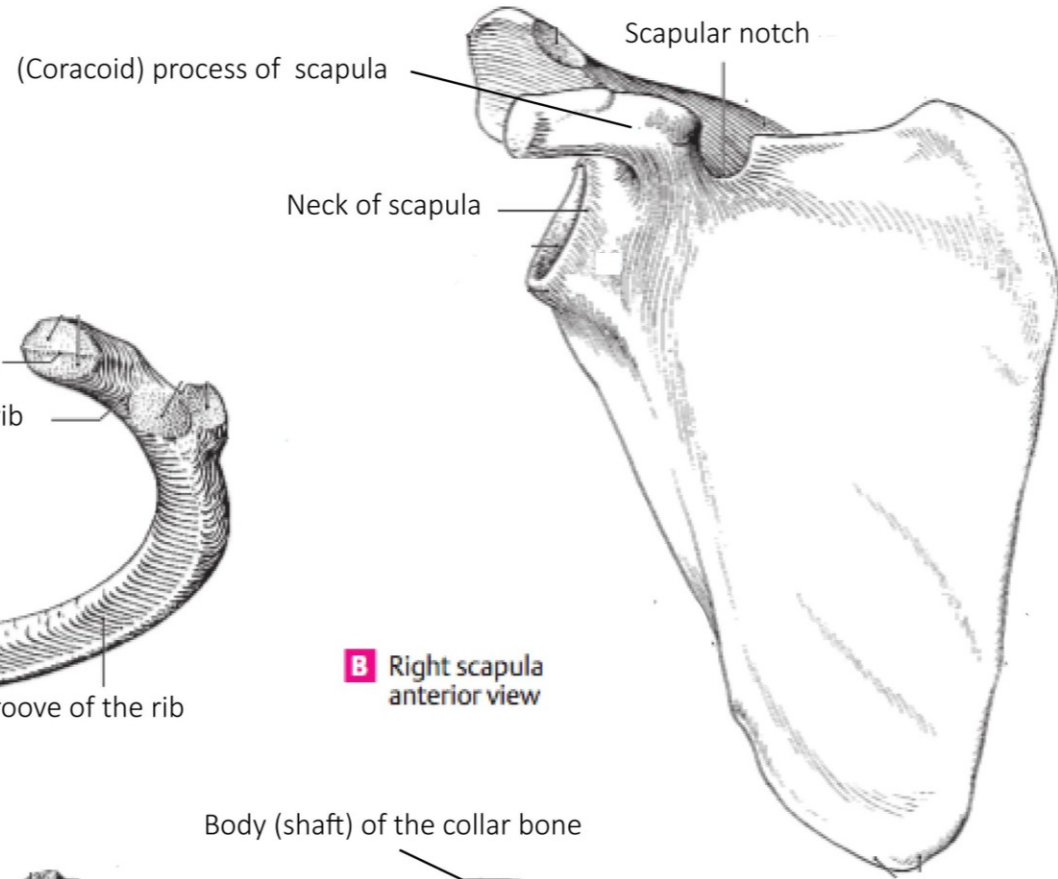
aorta ~ sclera ~ ulna ~ digitus ~ maxilla ~ ligamentum ~ trachea ~ tibia

RUPTURA

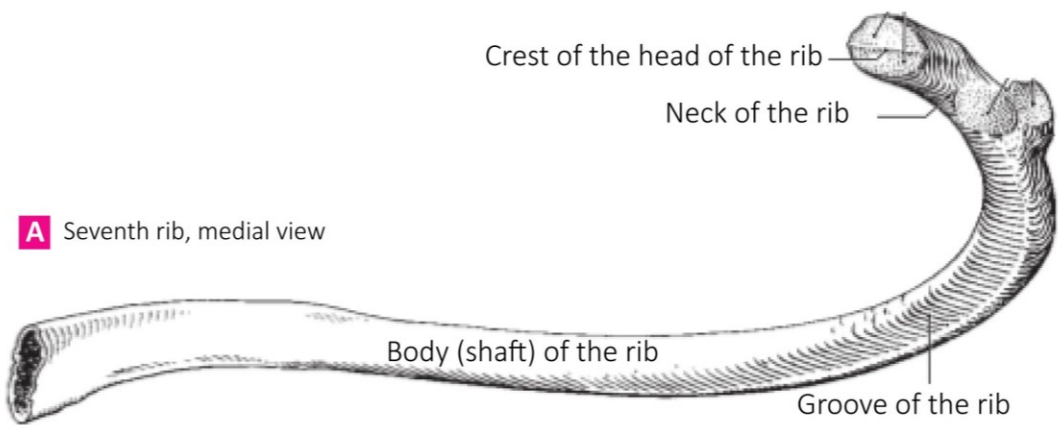
FRACTURA

Translate into Latin

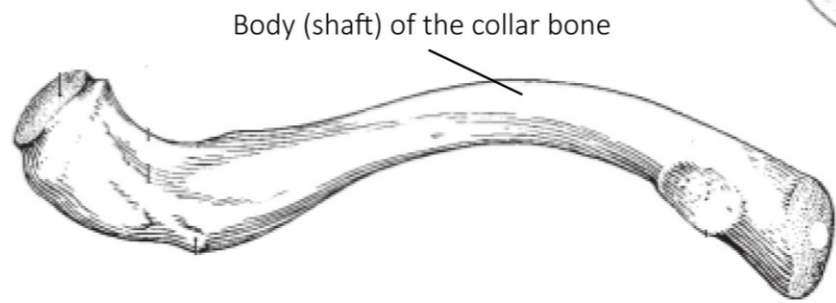
(Handout 3, task 2)



B Right scapula anterior view



A Seventh rib, medial view



C Right clavicle, inferior view

Latin adjectives

- their function is to describe a noun
- their form depends on the noun to which they refer >>

NOUN + ADJECTIVE = AGREED ATTRIBUTE
(agreement in gender, case and number)

Example: musculus longus (nom. sg. m.)

vena cava (nom. sg. f.)

ligamentum latum (nom. sg. n.)

Adjectives of the 1st and 2nd declension

magnus, a, um

magnus magna magnum

m.

f.

n.

dexter, tra, trum

dexter dextra dextrum

m.

f.

n.

(* liber, libera, liberum)

Connect the following nouns with the adjectives above:

coxa

oculus

crus

fibula

collum

cervix

nervus

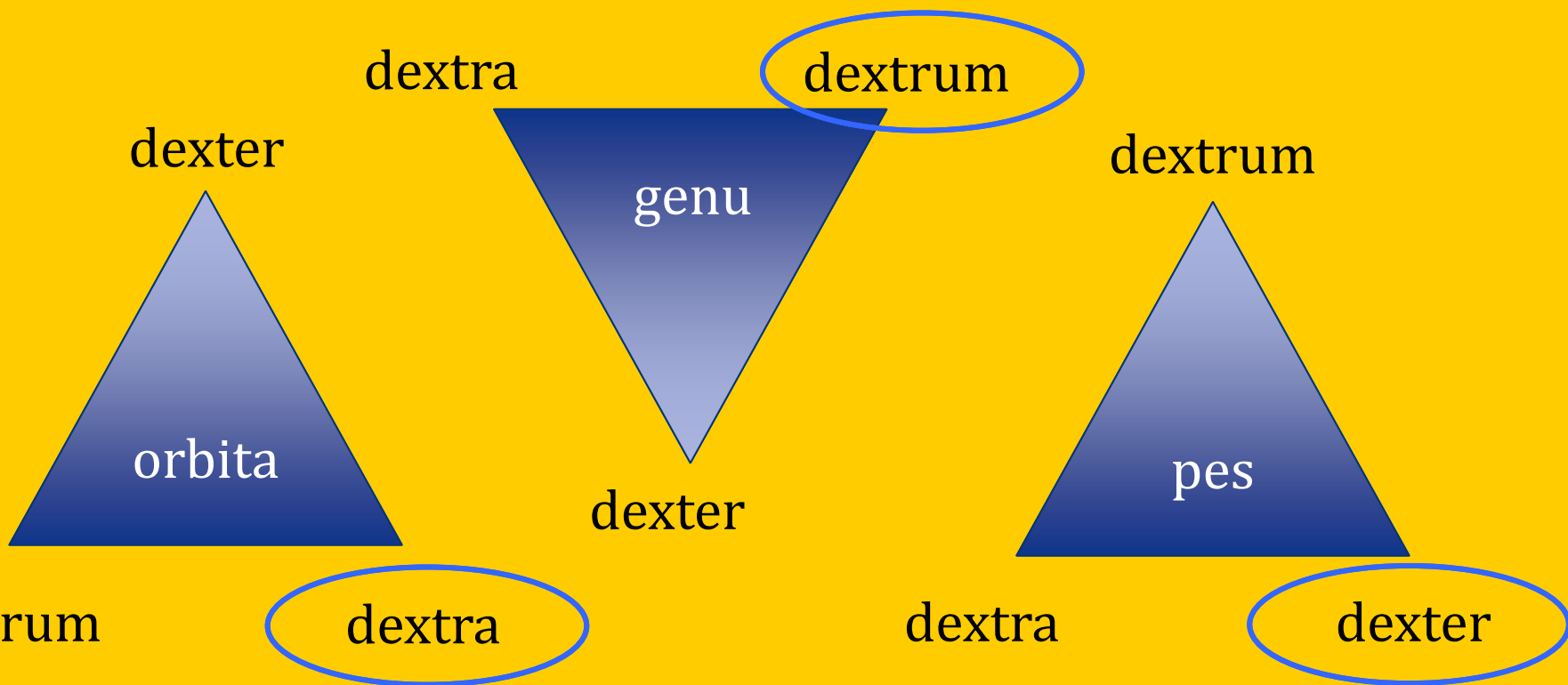
arcus

femur

septum

Agreed-attribute

Find the right adjectives for the nouns in the triangles and change the whole phrases into Gen. sg.



Non-agreed vs. agreed attribute

Singular

1. fractura vertebrae	fractura complicata
2. (causa) fracturae vertebrae	fracturae complicatae
4. (post) fracturam vertebrae	(post) fracturam complicatam
6. (cum) fractura vertebrae	(cum) fractura complicata

Plural

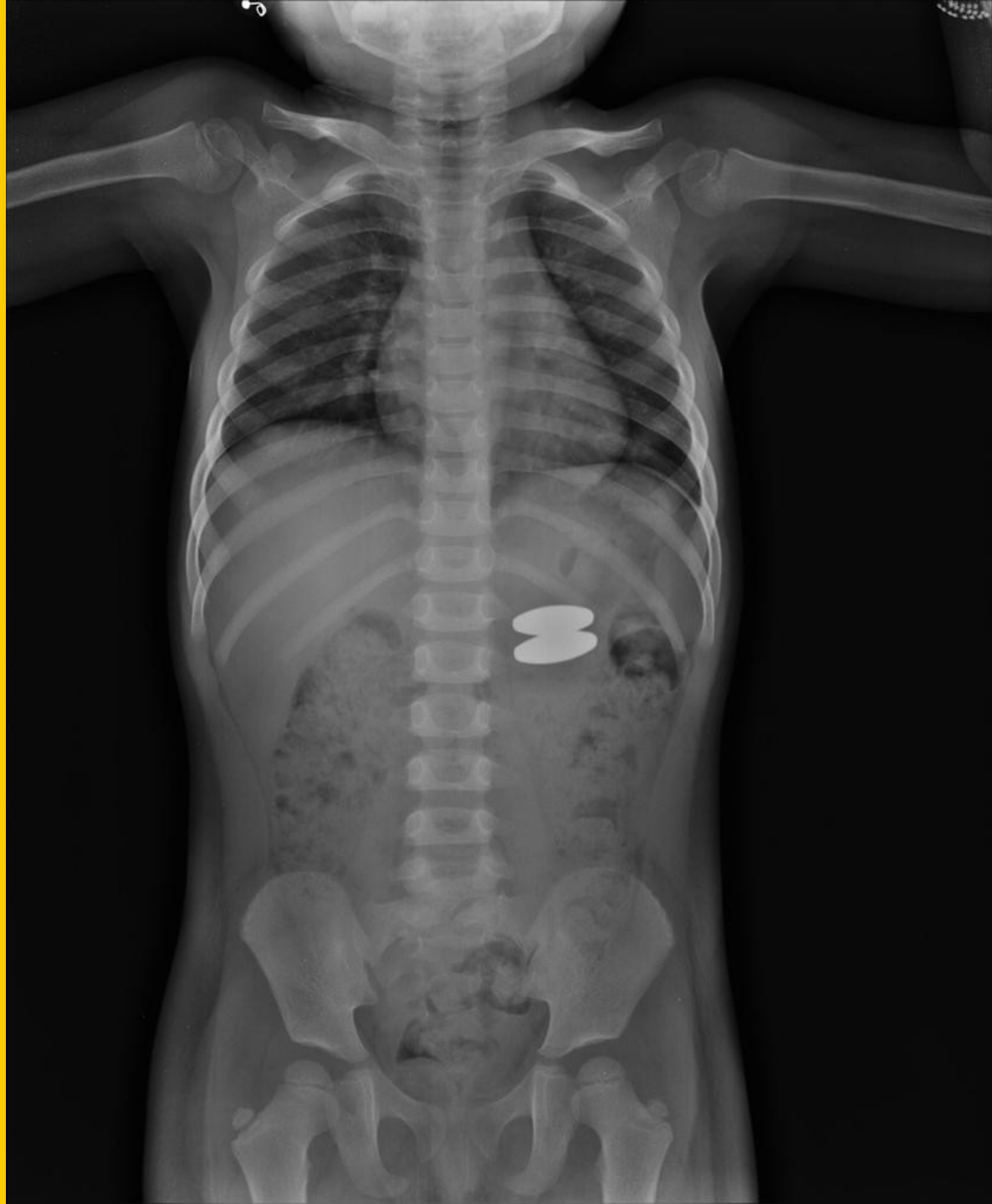1. fracturae vertebrarum	fracturae complicatae
2. (causa) fracturarum vertebrarum	fracturarum complicatarum
4. (post) fracturas vertebrarum	fracturas complicatas
6. (cum) fracturis vertebrarum	fracturis complicatis

What is the difference in declining between the two phrases?


Read and
guess
the meaning:

Dg.:
Corpus alienum trac.
Gl I. sin. sine compl,
sine inflam.

**Corpus alienum
tractus
gastrointestinalis
lateris sinistri sine
complicationibus, sine
inflammatione**



Za správnosť



Lekárska správa - nález

Označenie zdrav. zariadenia, odd., pracovisko

pre

i. p. 25

Priezvisko a meno

Burdinovič Igor

rok nar.

+

č. prot.

Klin. dg

vykonané vyšetrenie

dňa

01 AUG 2010 11:12

Dnes asi o 19.30 pri služobnom zároku úraz v obl. jarmovej kosti vpravo, na okolnosti spomína, v bezvedomí, nebol, nezvracal. I.č. v ÚVTOS.

Vyš: RFG / OPG, PND, Clementschitch - bez traumatických zmien skeletu e.o. hematóm v obl. jarmovej kosti vpravo, pre výraznejší bolestivý opuch v obl. jarmovej kosti vpravo táto nepalpateľná, dolný okraj orbít bilat. bez scjodika, vizus orient. v norme, senzit. inerv. tváre zachovalá

i.o. otváranie úst bez obmedz., sliz. BPN, skelet pevný, záryz v norm

Dg: Contusio faciei l.dx. reg. ossis zygomat.
Haematoma faciei l.dx. reg. ossis et arc. zygo at.
In: ine, len vyšetrenie.

Udp: Chladiť, analgetiká p.p. Vhodné v ÚVTOS predpísať Augmentin 625mg p.o. á 8- hod.

KO: V prípade ťažkostí ihneď

Contusio faciei l.dx. reg. ossis zygomat.

Contusio faciei lateris dextri regionis ossis zygomatici

Haematoma faciei l. dx. reg. ossis et arc. zygomat.

Haematoma faciei lateris dextri regionis ossis et arcus zygomatici