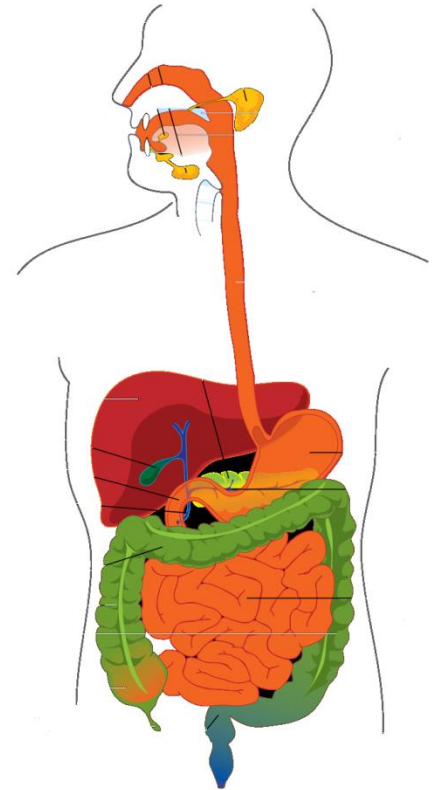


Digestive system

**Microscopic anatomy of pancreas, liver,
overview of GIT embryology**

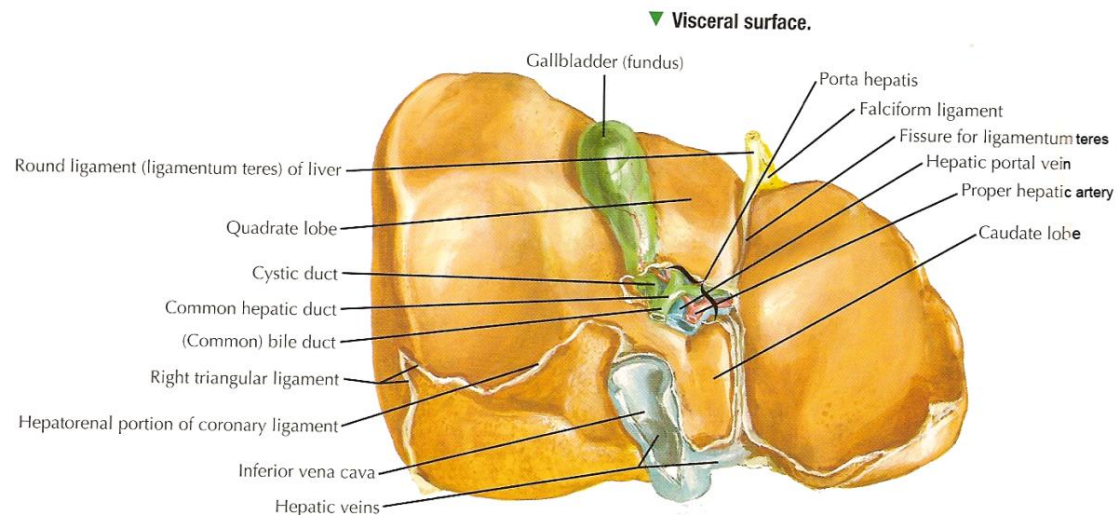
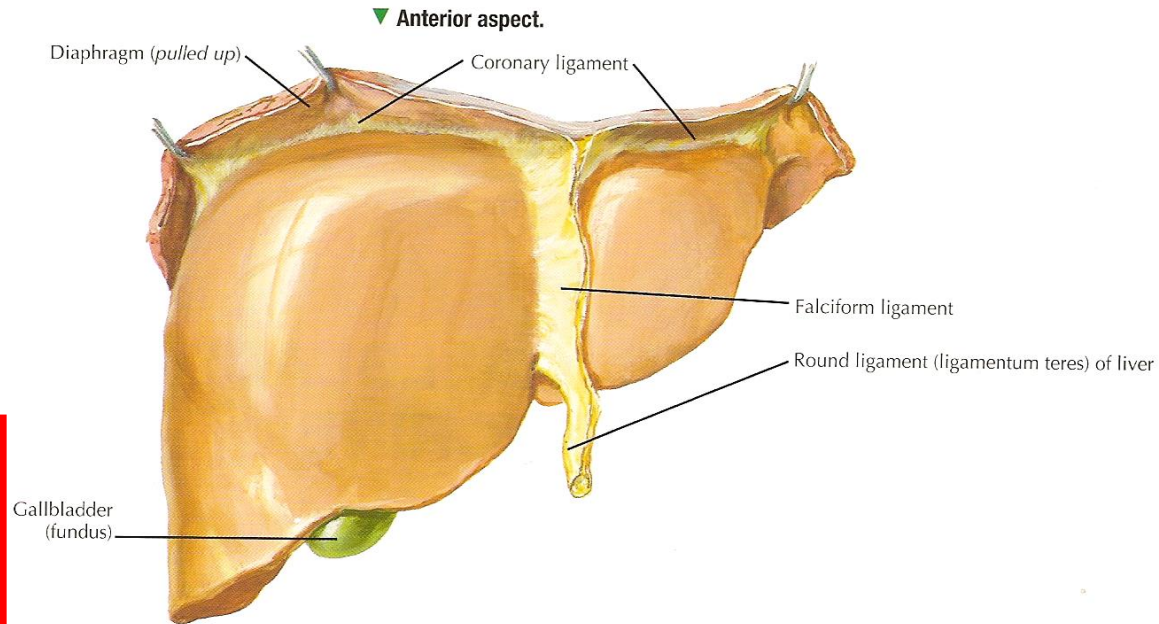


LIVER (HEPAR)

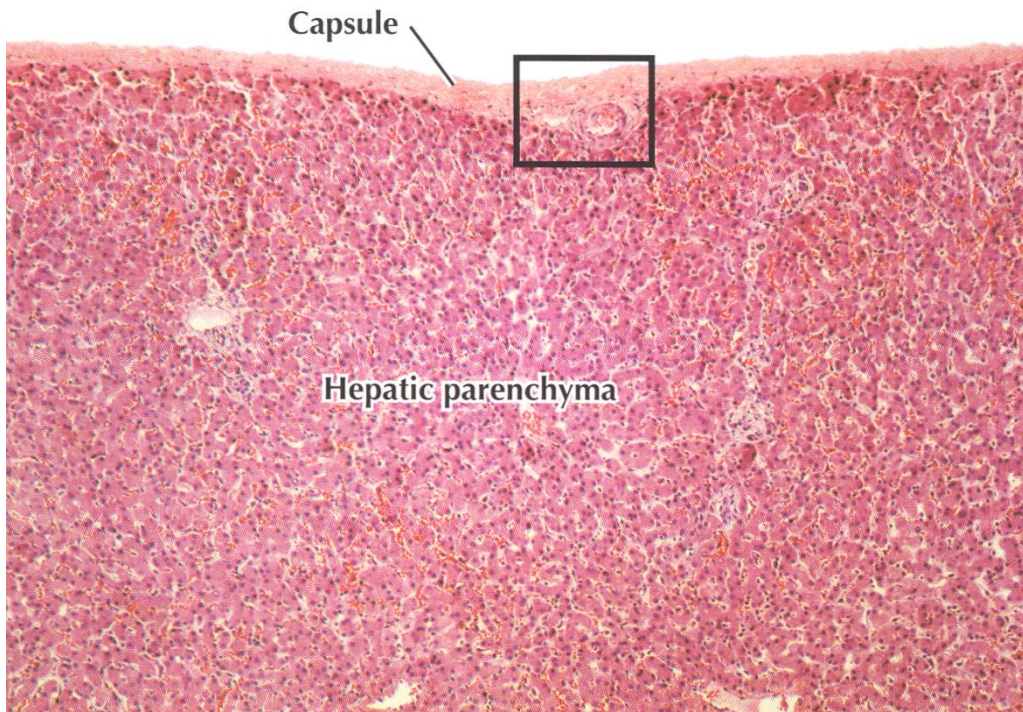
- Liver parenchyma – biggest gland in human body
- C.t. capsule
- Nutritive and functional blood supply
- Endocrine and exocrine function
- Uniform histology of all four major anatomic lobules and segments:

- Hepatocytes and other cell types
- C.t. stroma
- Blood and lymphatic vessels
- Sinusoids
- Innervation

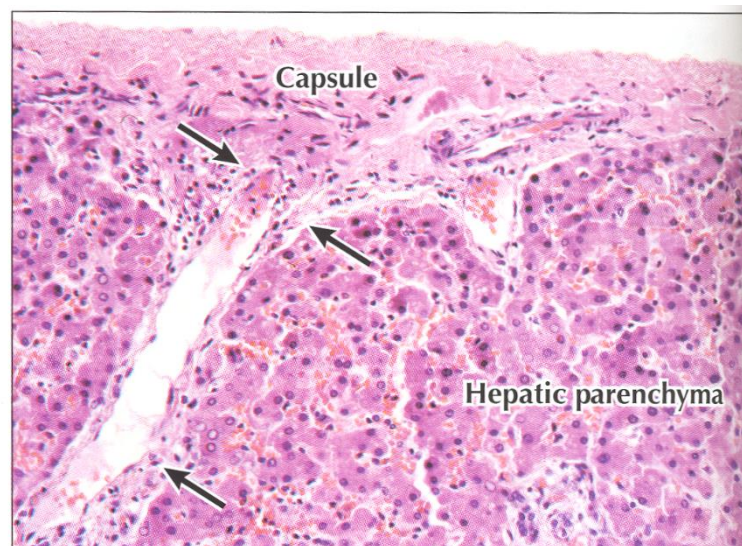
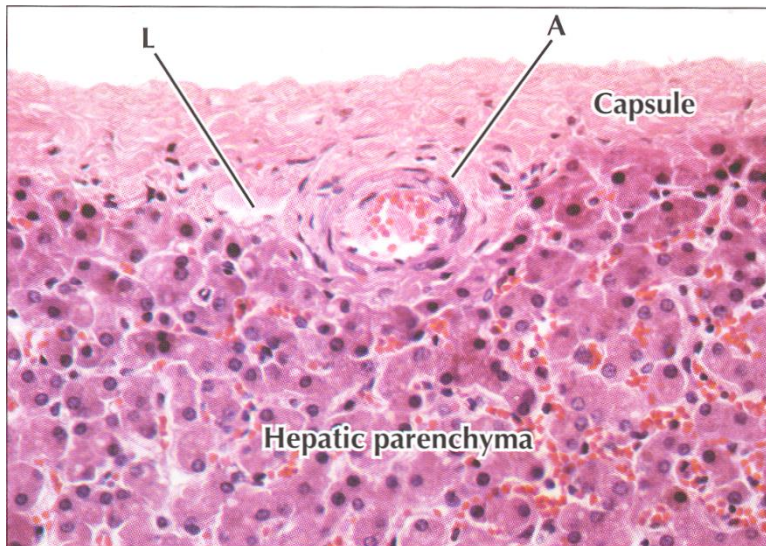
- C.t. capsule
- Serosa



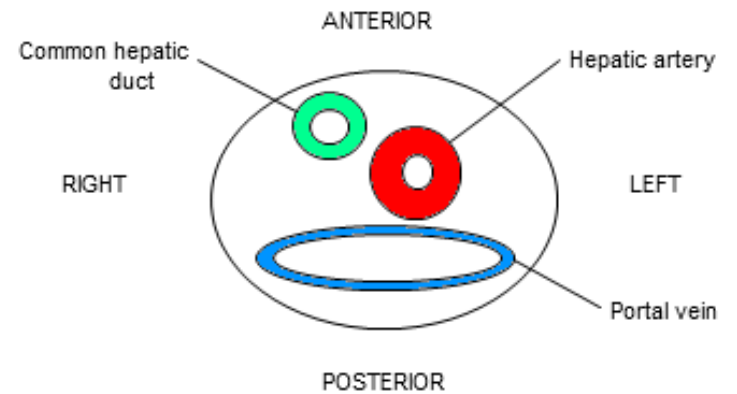
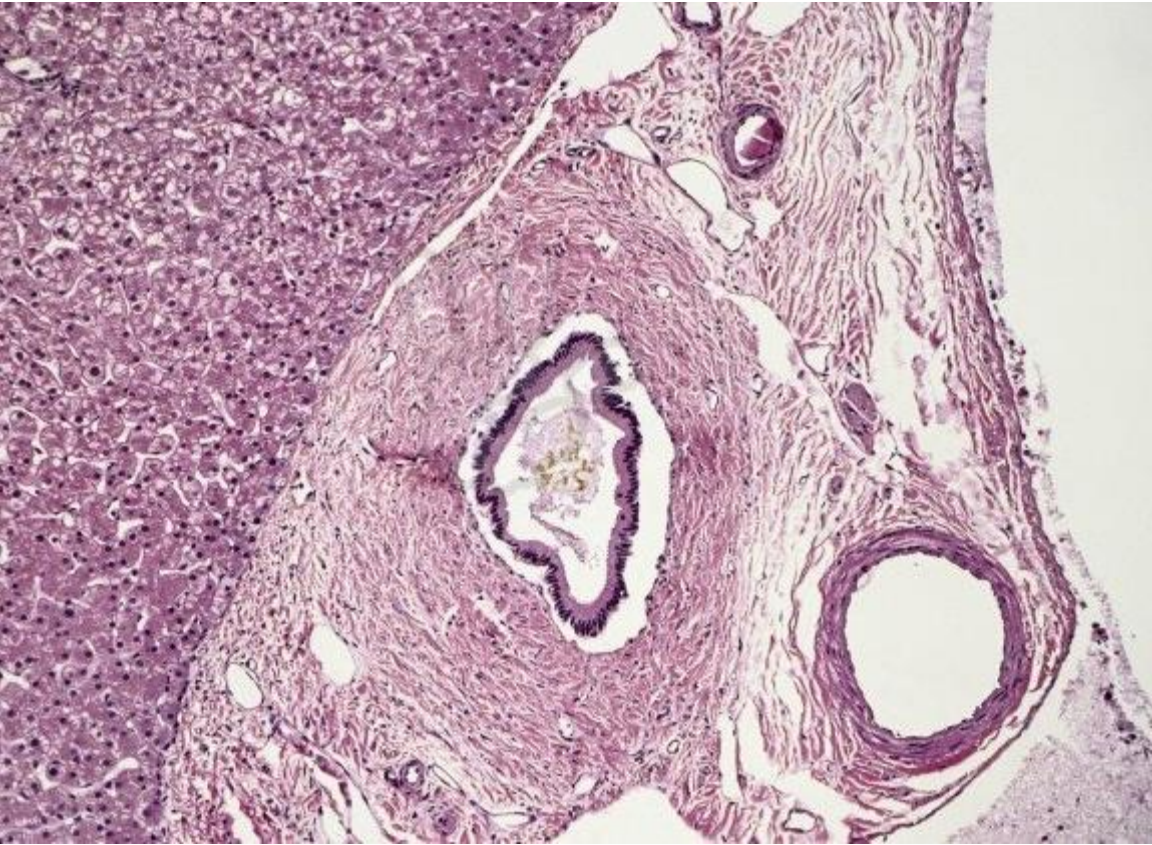
CAPSULA FIBROSA HEPATIS



- Serous mesothelium
- C.t. – collagen and elastic fibers
- 70-100 μ m
- Porta hepatis



CAPSULA FIBROSA HEPATIS



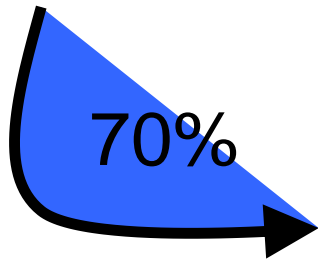
VASCULARISATION

FUNCTION

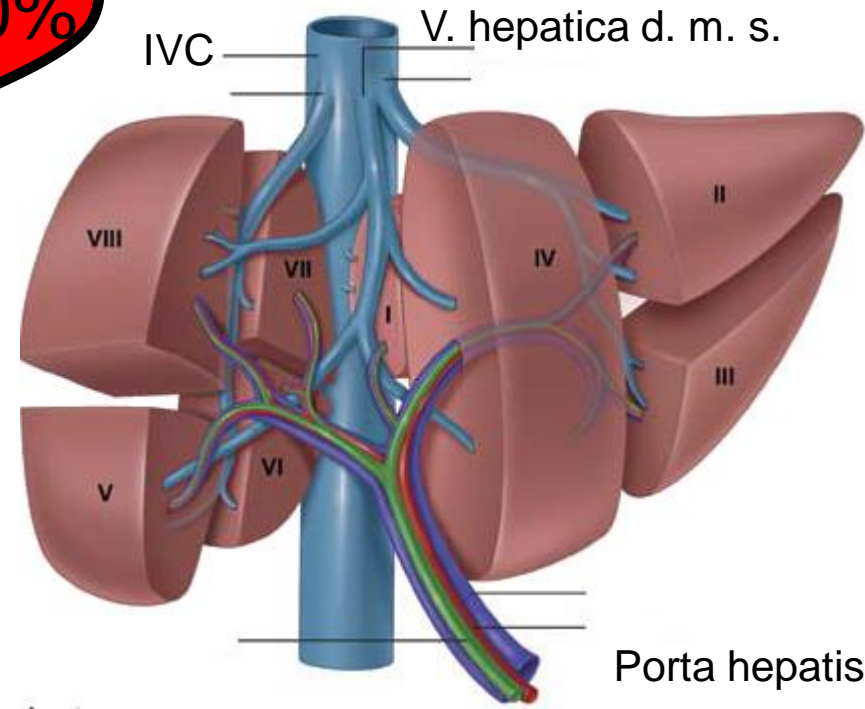
- capillary stream of stomach and intestine
- vena portae
- interlobular veins
- circumlobular venules

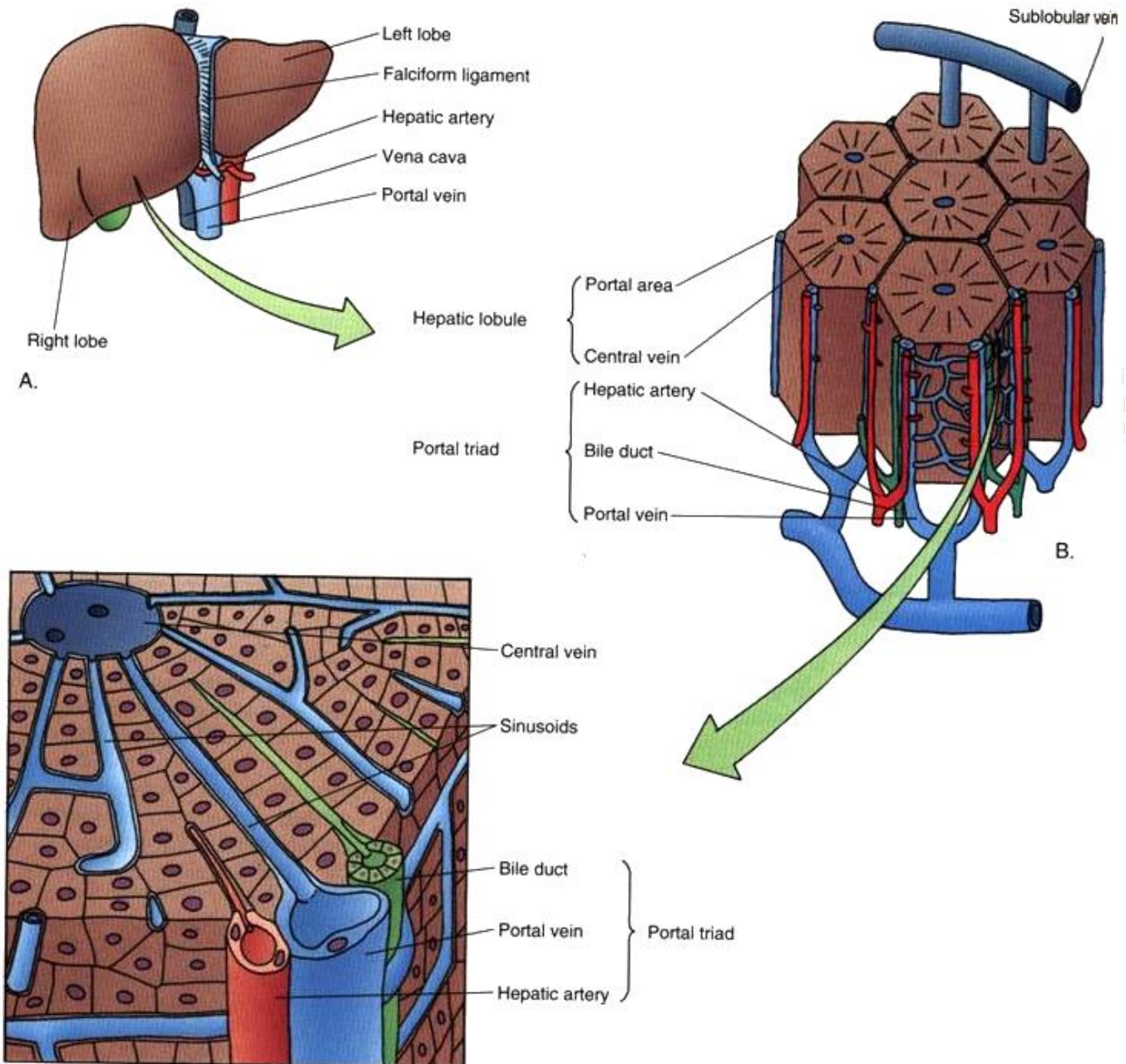
NUTRITIVE

- aorta
- arteria hepatica
- segmental arteries
- interlobular arteries
- circumlobular arteriols

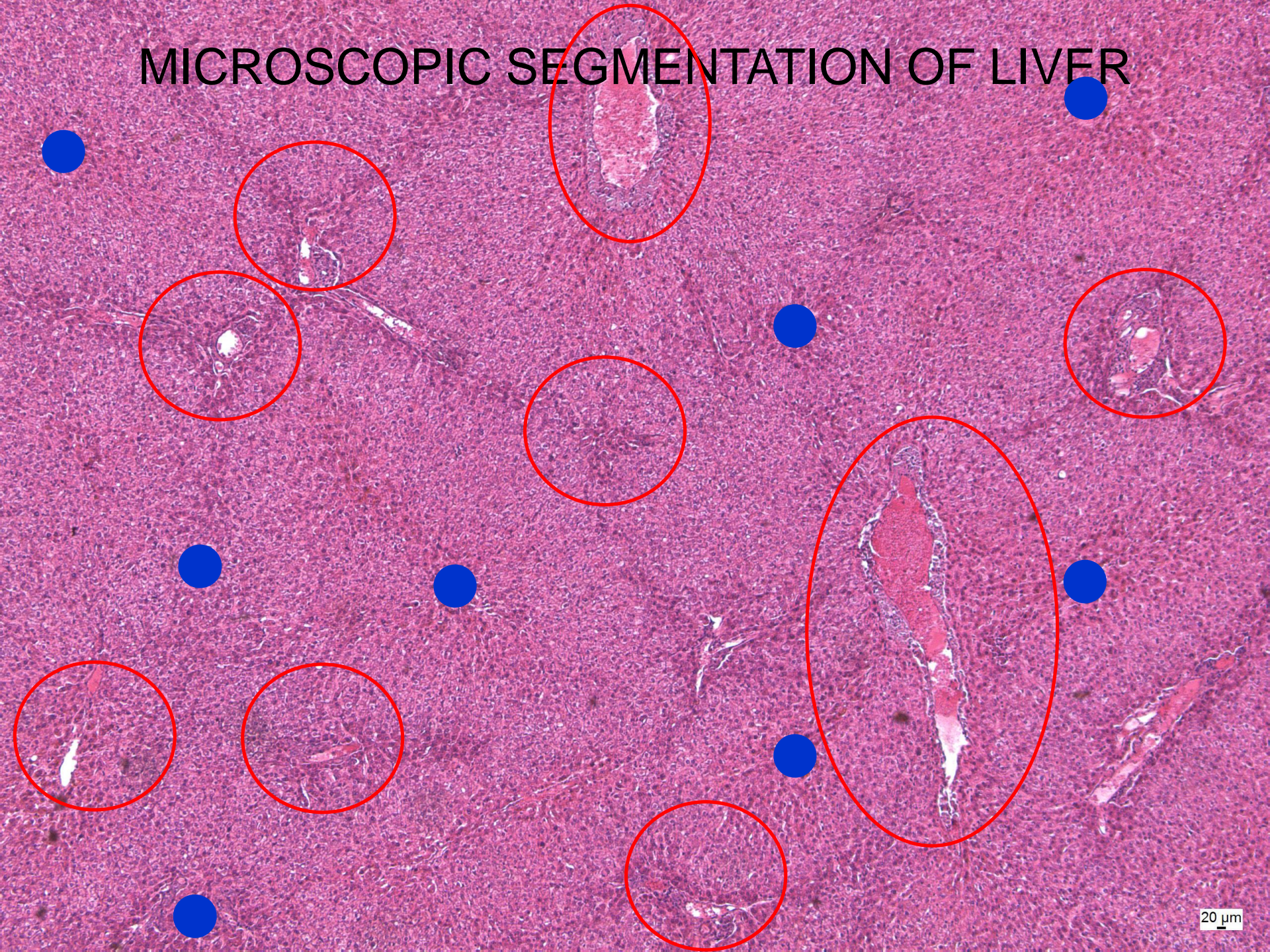


- **hepatic sinusoids**
- venae centrales hepatis
- venae sublobulares
- venae hepaticae
- vena cava inferior



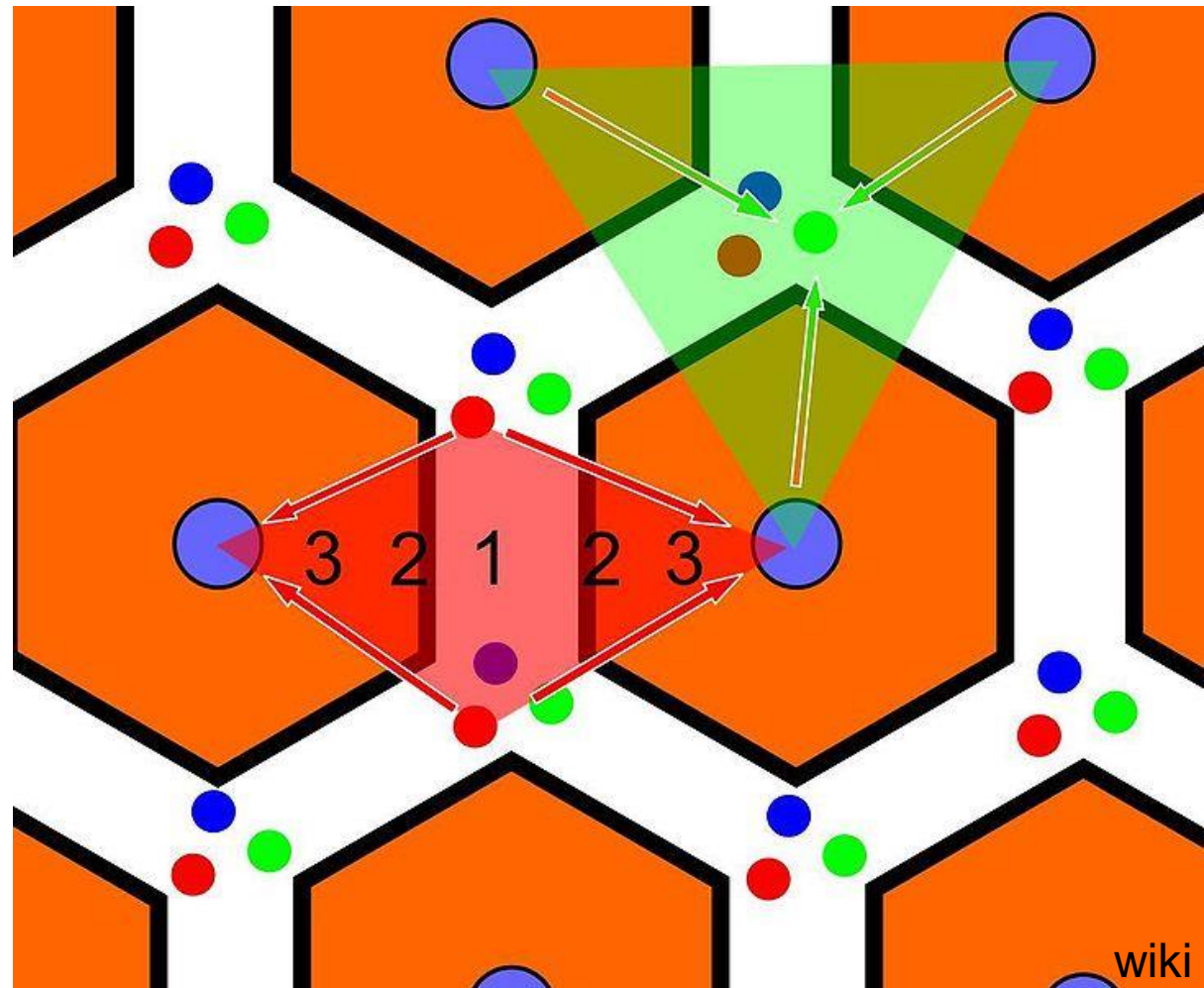
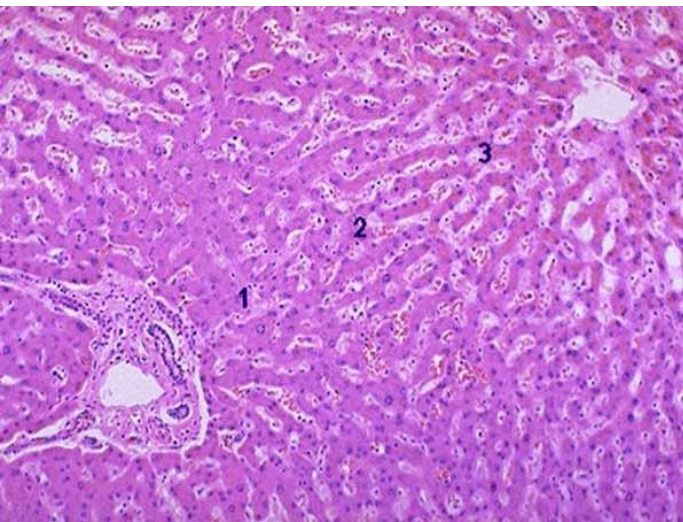


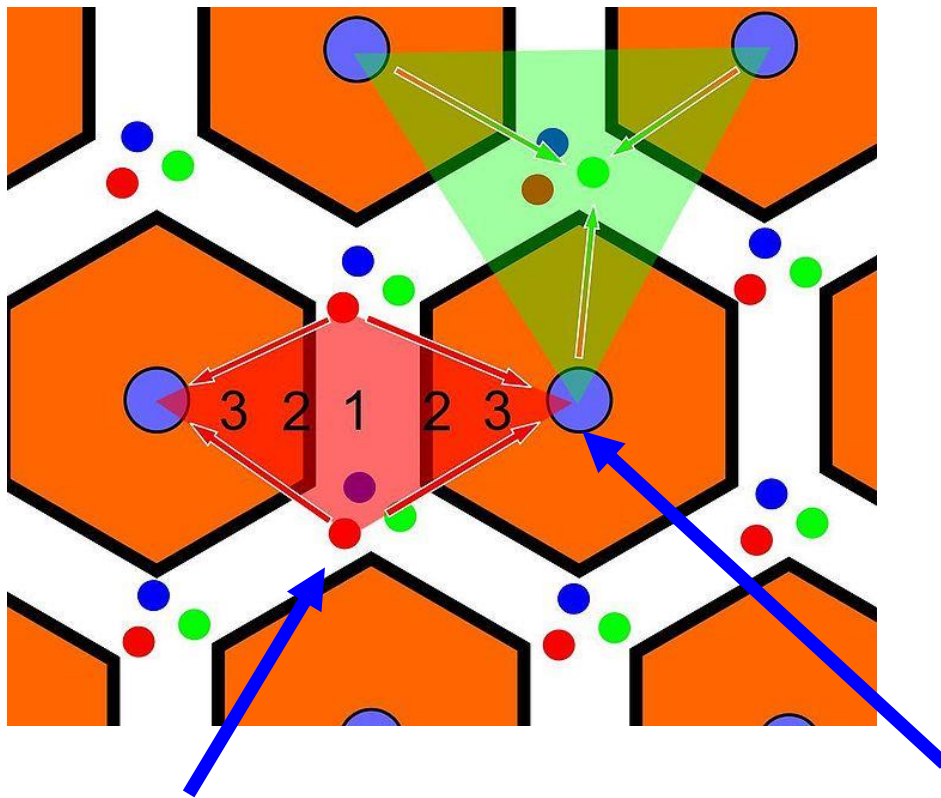
MICROSCOPIC SEGMENTATION OF LIVER



MICROSCOPIC SEGMENTATION OF LIVER

- Three possible definitions
- Histological – **lobulus venae centralis**
- Metabolic – **liver acinus**
 - metabolic zone 1 – 3
 - oxygenation of hepatocytes
- Functional (physiological historical) unit
 - **lobulus venae interlobularis** (portal acinus)





Liver acinus

metabolic divergence dependent on arterio-venous gradients

Zone I (periportal)

oxidative processes

beta-oxidation of fatty acids

catabolism of aminoacids

gluconeogenesis

production of urea

synthesis of cholesterol

glycogenolysis

production of bile

Zone III (perivenous)

glycogen synthesis

glycolysis

lipogenesis

ketogenesis

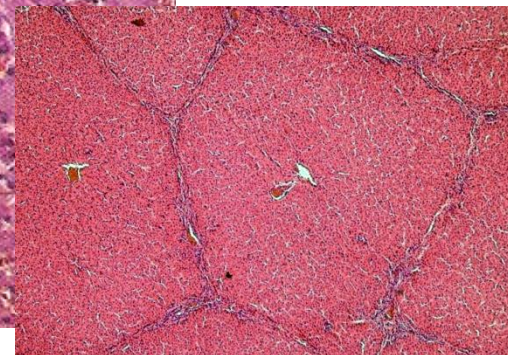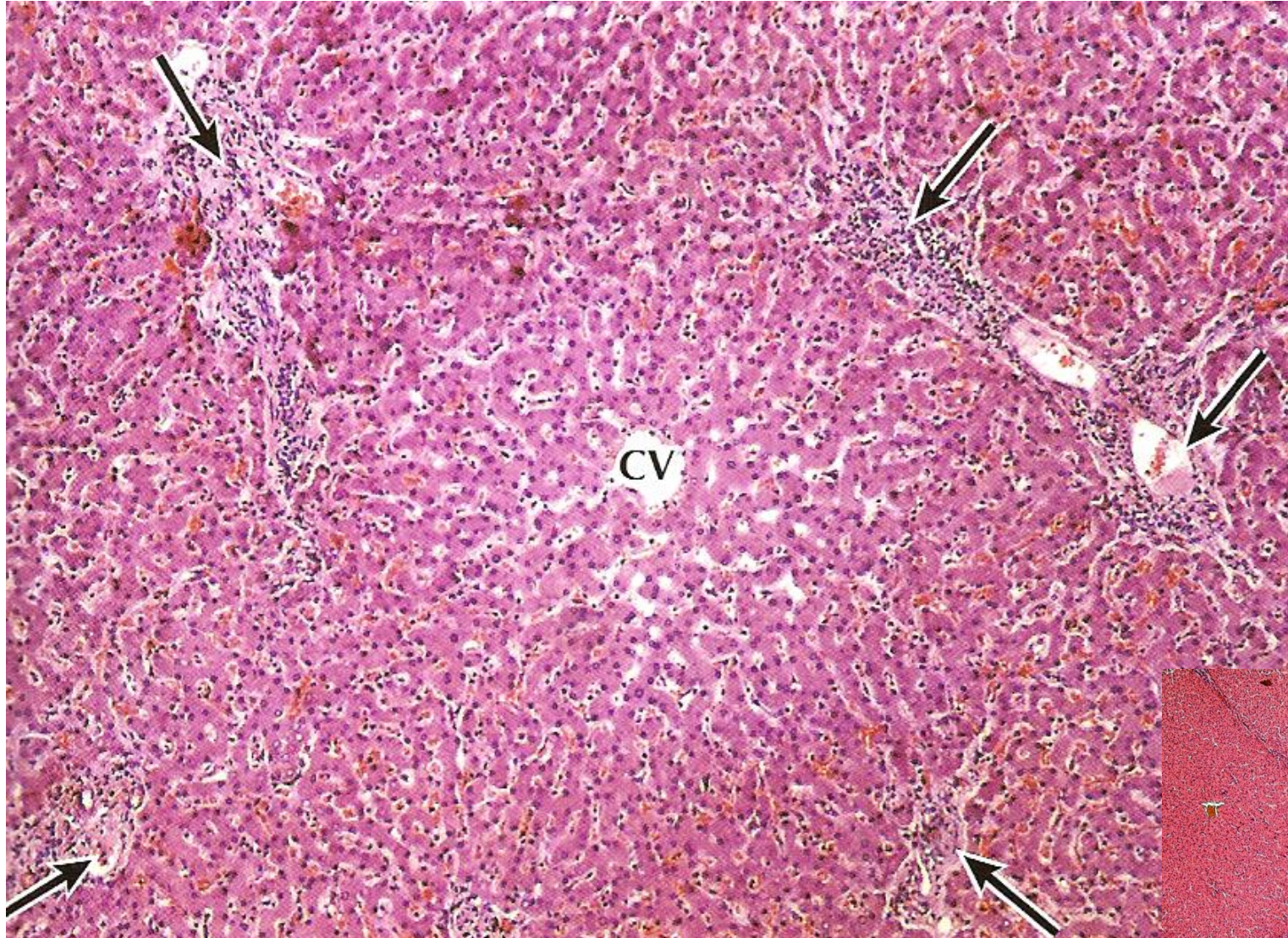
production of glutamine

synthesis of bile acids

biotransformation

CENTRAL VEIN LOBULUS

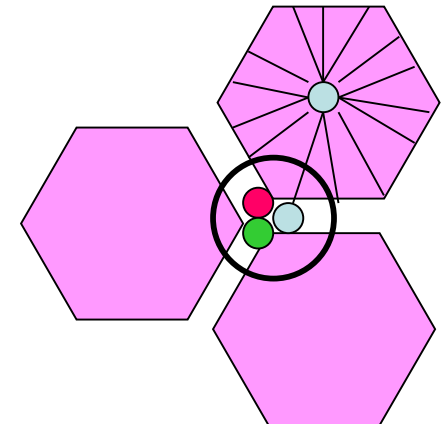
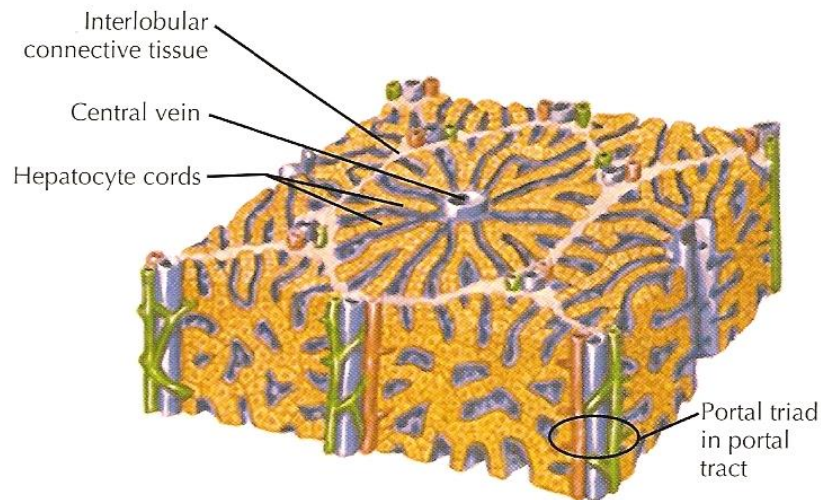
Lobulus venae centralis



CENTRAL VEIN LOBULUS

Lobulus venae centralis

- Classical morphological unit
- Polygonal cells (hexagonal), 0.7 x 2mm
- Central vein
- Radial cords of hepatocytes
- Liver sinusoids
- Portal triad, portobilliary region



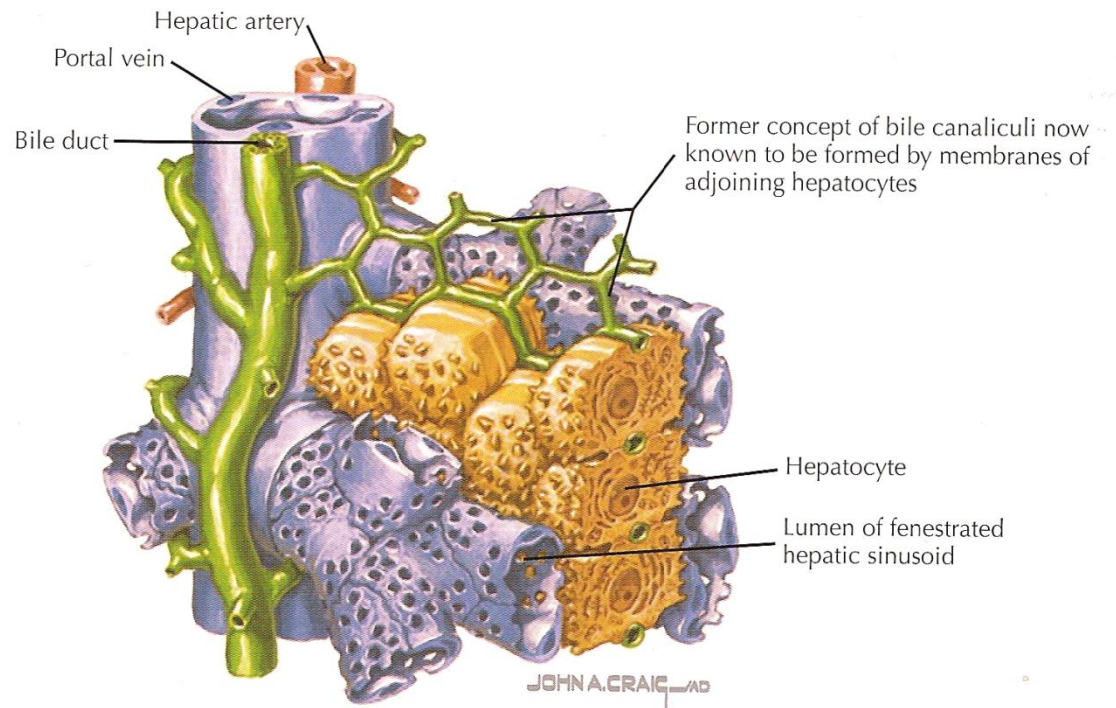
CENTRAL VEIN LOBULUS

Portal triad

Contact of 3-4 neighboring lobuli

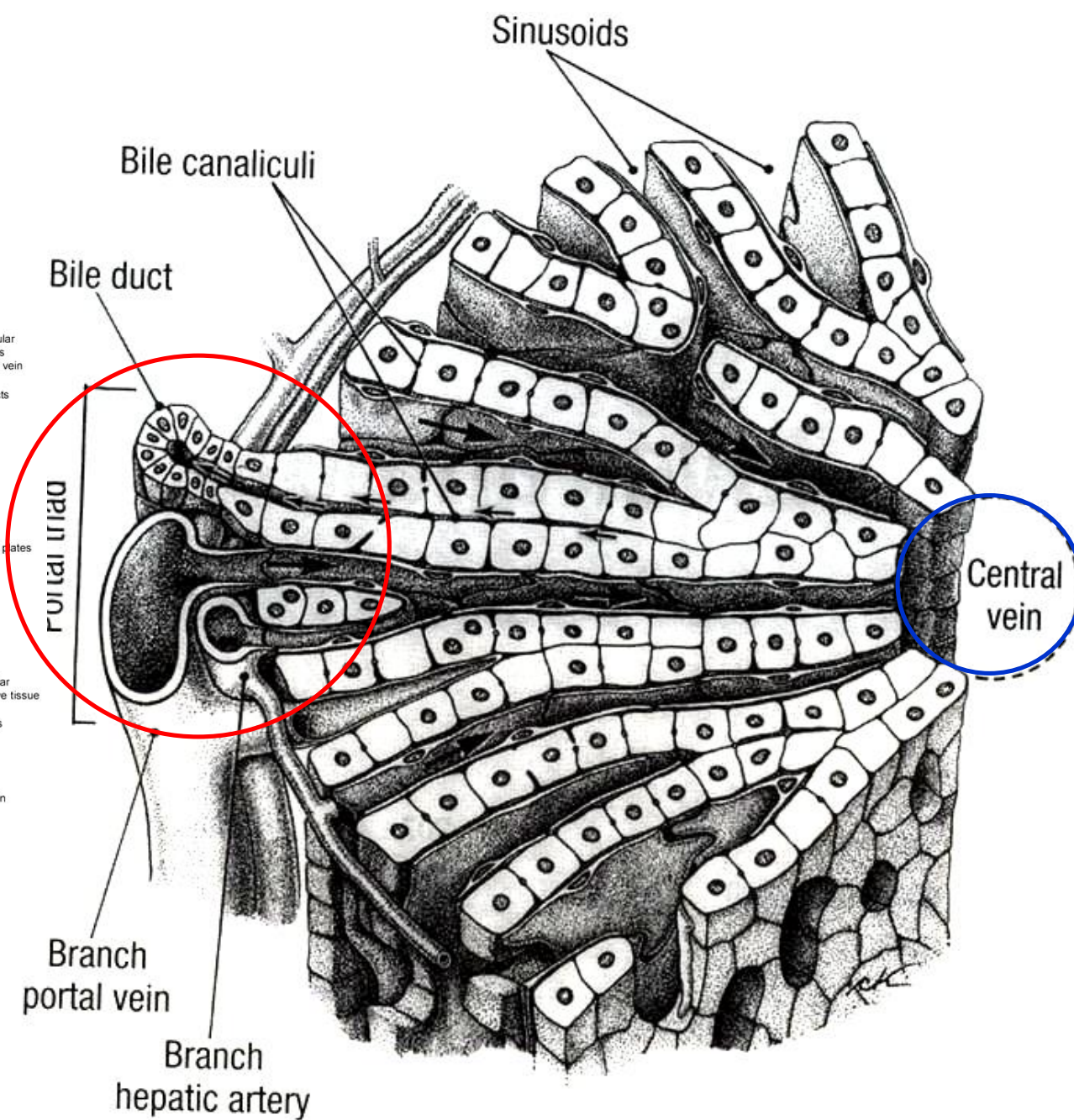
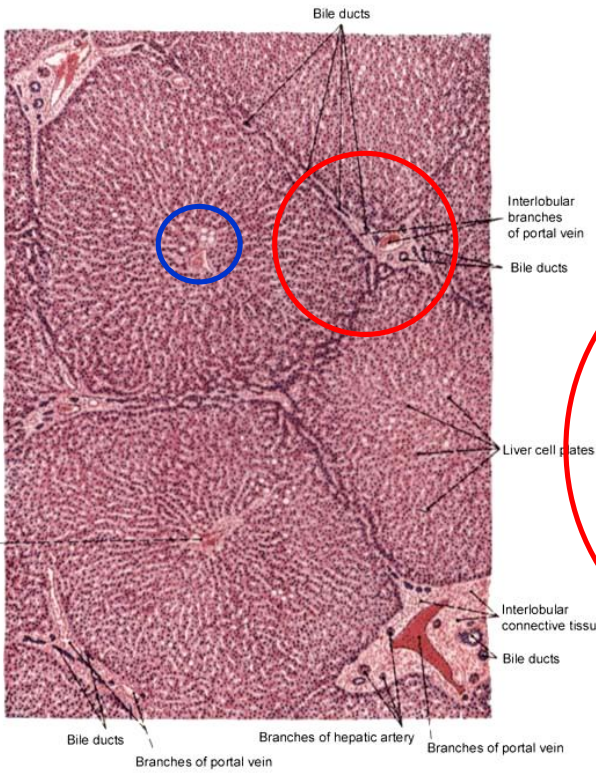
- Interlobular artery (*a. interlobularis*)
- Interlobular vein (*v. interlobularis*)
- Interlobular bile duct (*d. bilifer interlobularis*)
- Lymphatic vessels
- Innervation – *nervus vagus*

Loose interstitial c.t.

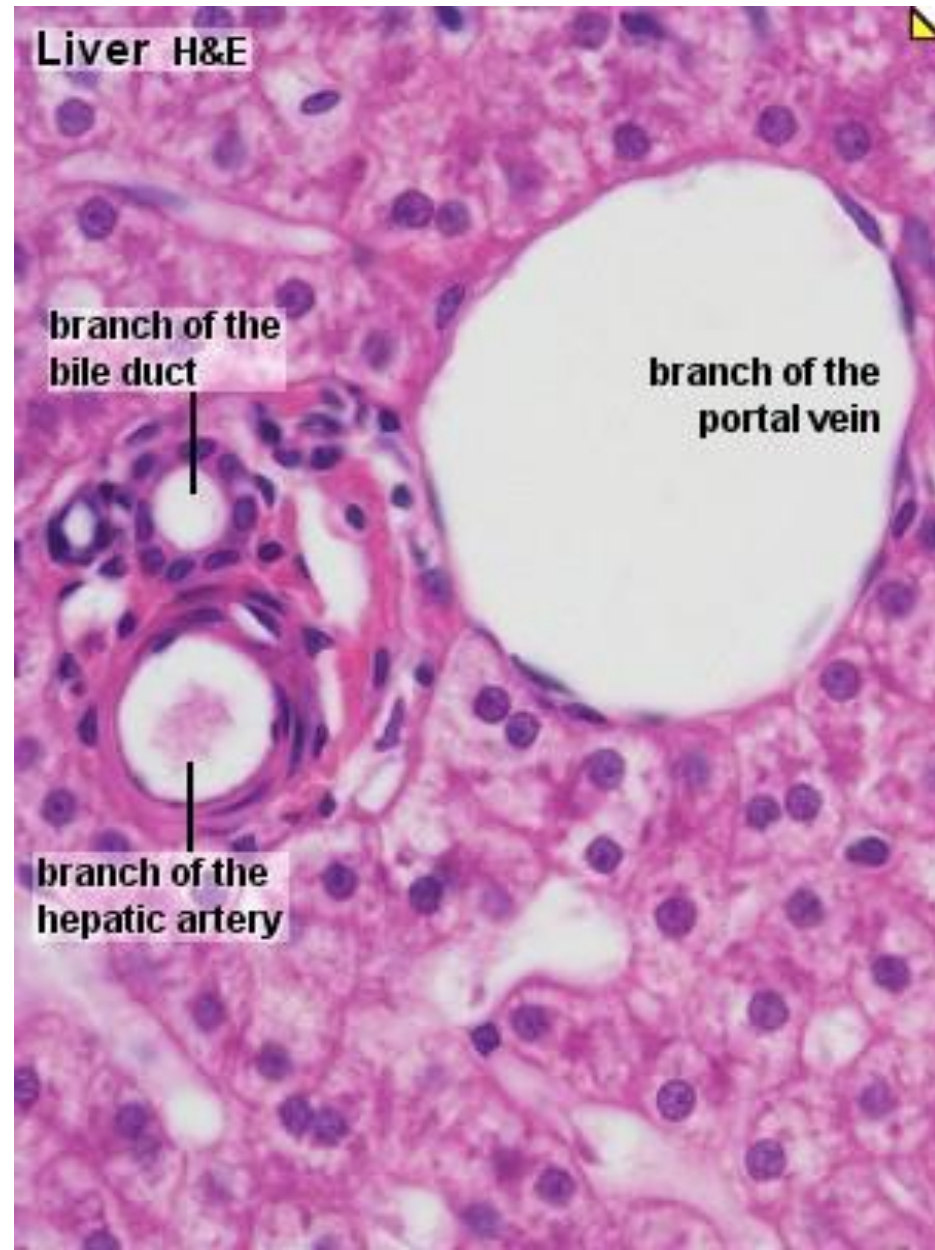
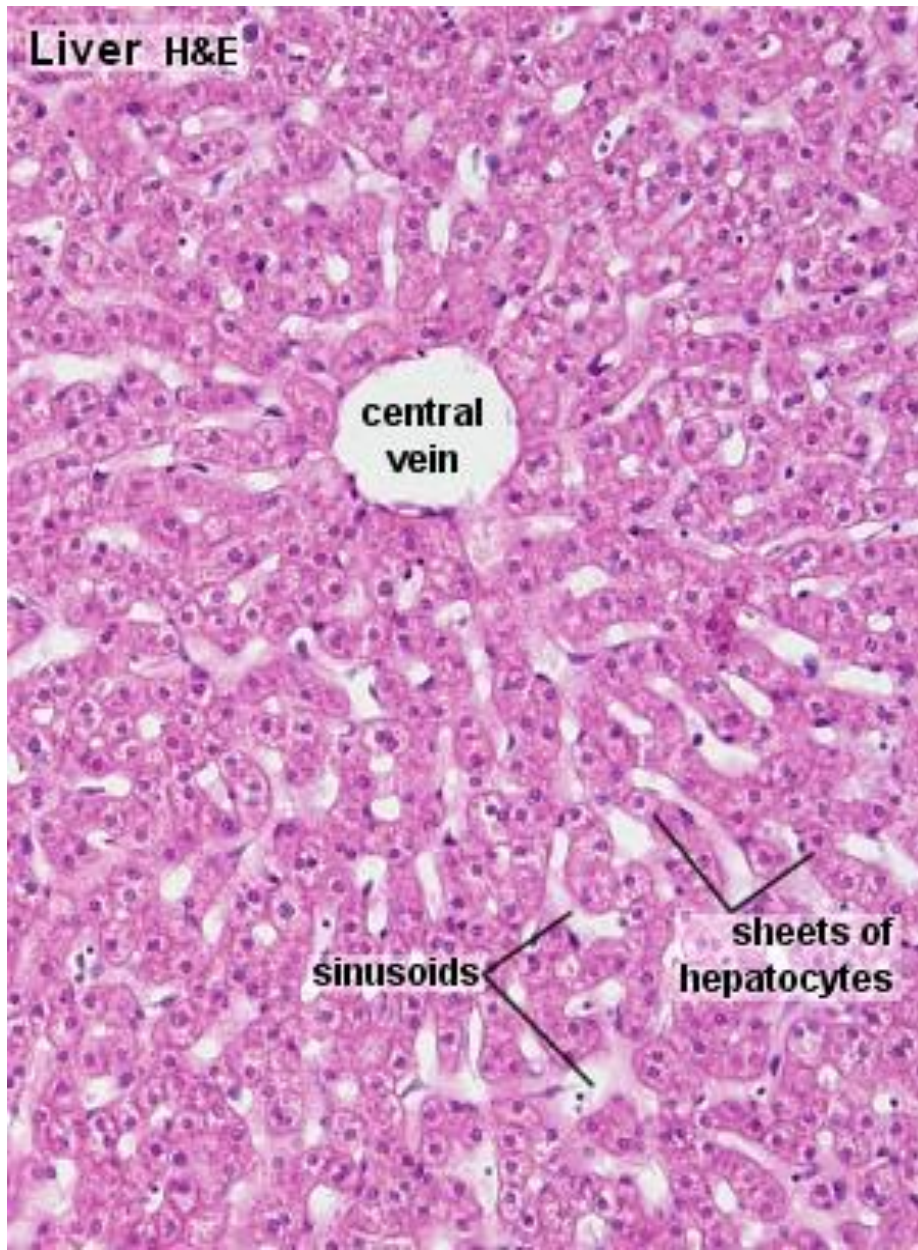


▲ Parts of hepatic lobule at portal triad (high magnification).

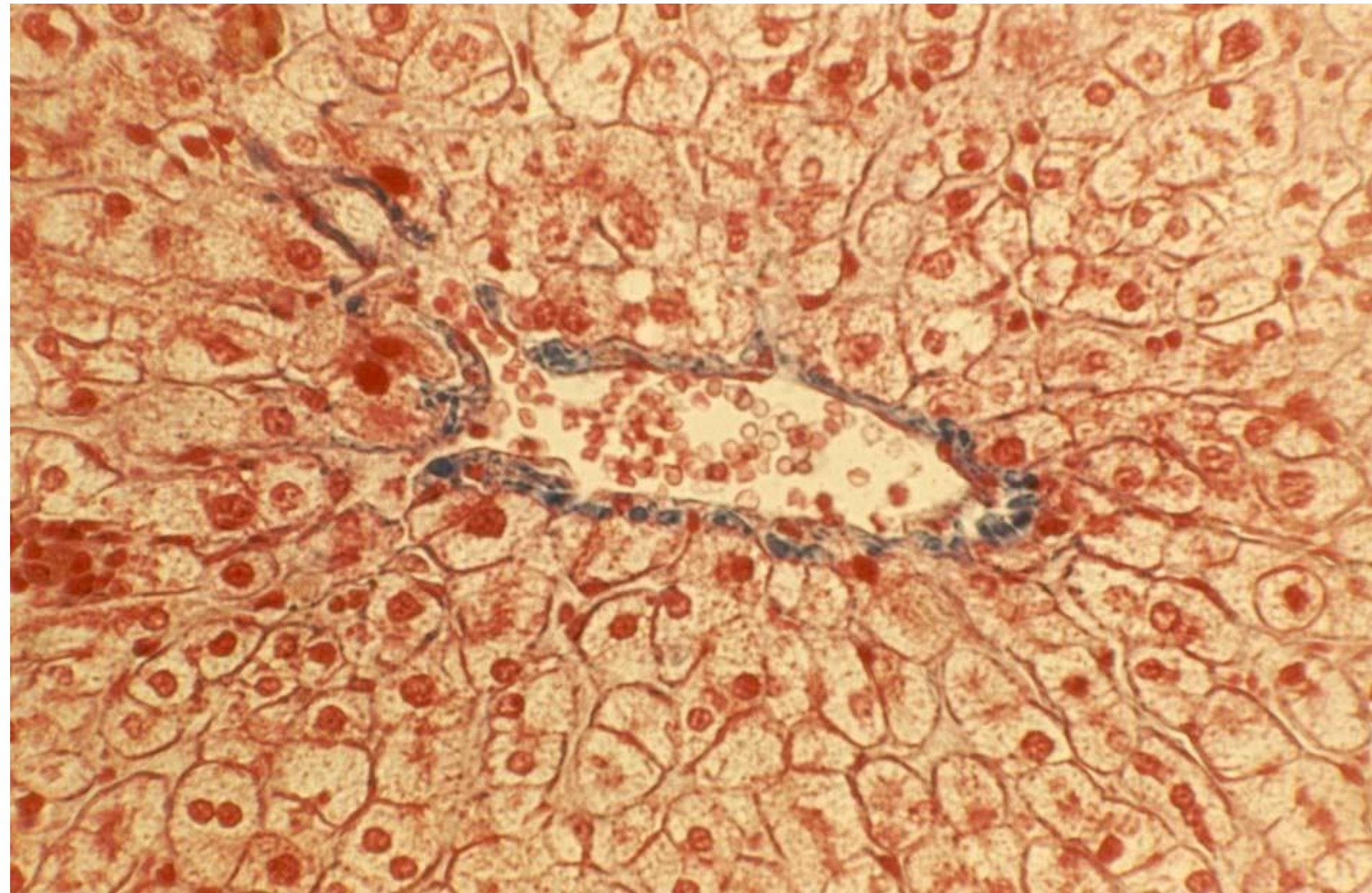
Ham: Textbook of Histology



PORTAL TRIAD

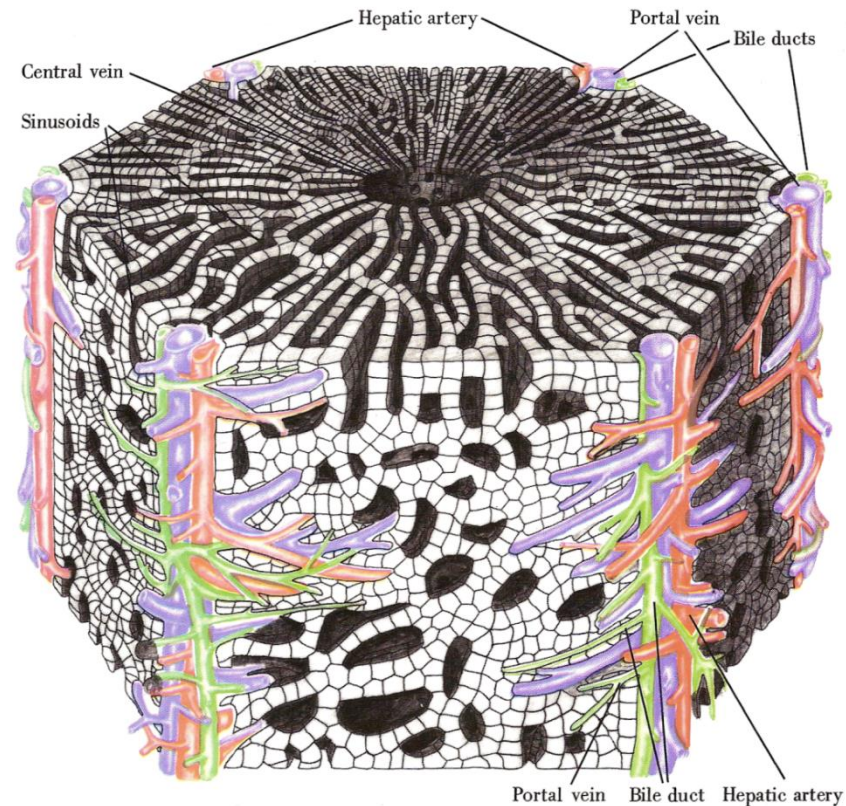


CENTRAL VEIN



HEPATOCYTES AND LIVER SINUSOIDS

- Hepatocytes arranged to cords, width 1-2 cells, often anastomoses
- Sinusoids
 - 9-15 μ m
 - Anastomosing network of flat endothelial cells
 - Basal membrane absent - no diffusion barrier
 - Fenestrations - 100nm, diaphragm absent
 - Intercellular space
 - Perisinusoidal (Dissé) space
 - Reticular fibers, perisinusoidal fibroblasts
 - Dispersed Kupfer cells (monocyte-macrophage system)
 - Perisinusoidal cells of Ito
- Vena centralis – thin-walled vessel, draining blood from sinusoids

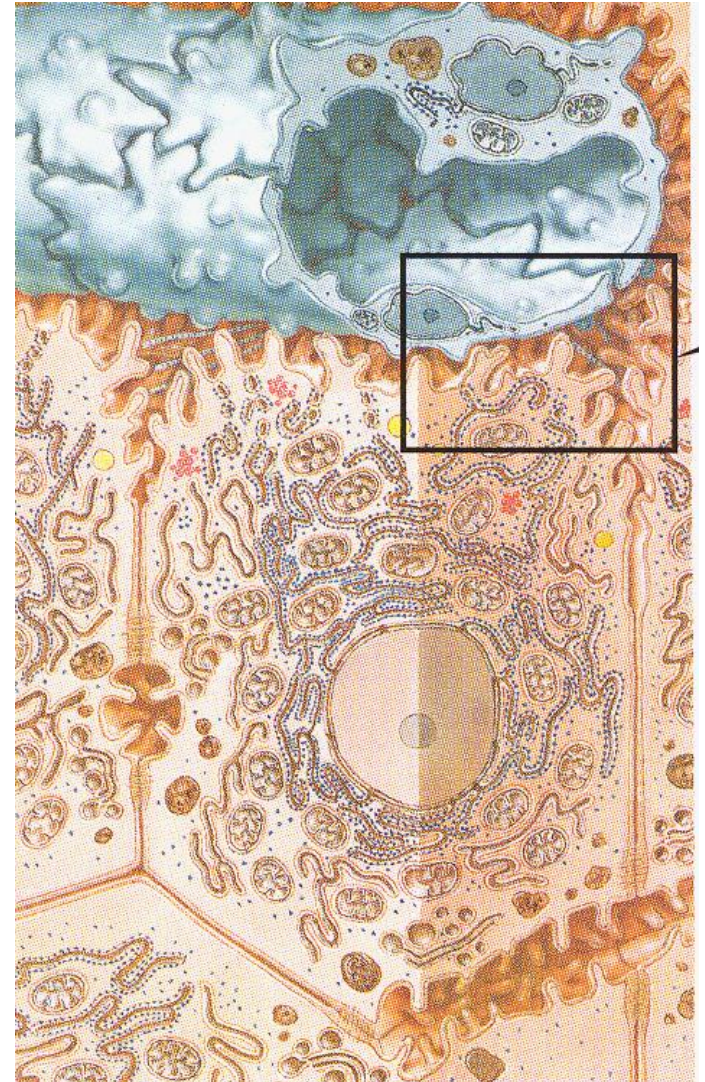
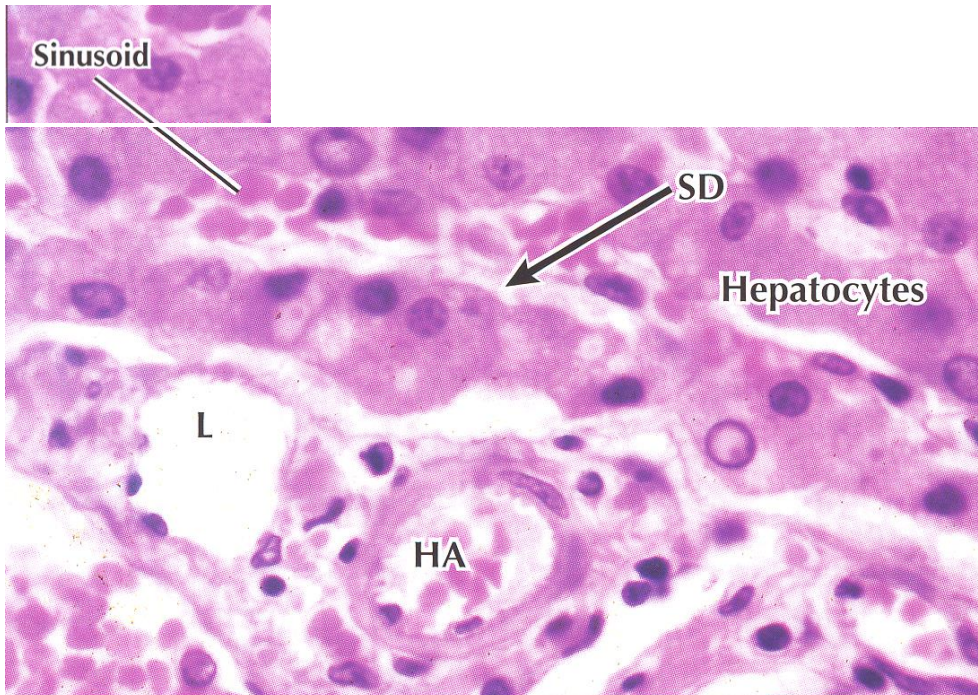


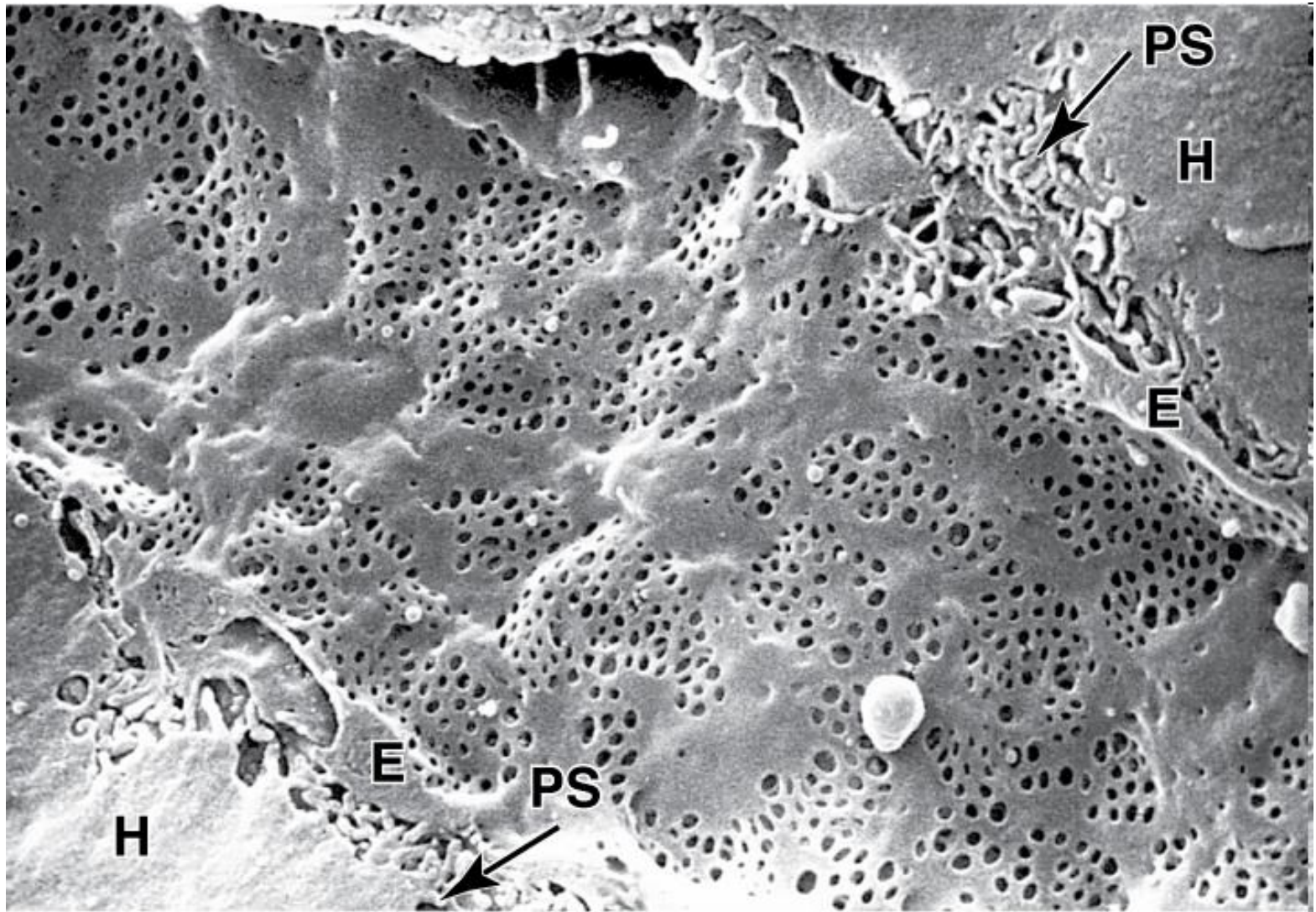
LOBULUS VENAE CENTRALIS

Hepatocytes and liver sinusoids

- Space of Disse

- Connection of space of Disse and sinusoidal lumen by fenestrated endothelium
- Hepatocytes in direct contact with plasma (microvilli)
- Cells of Ito

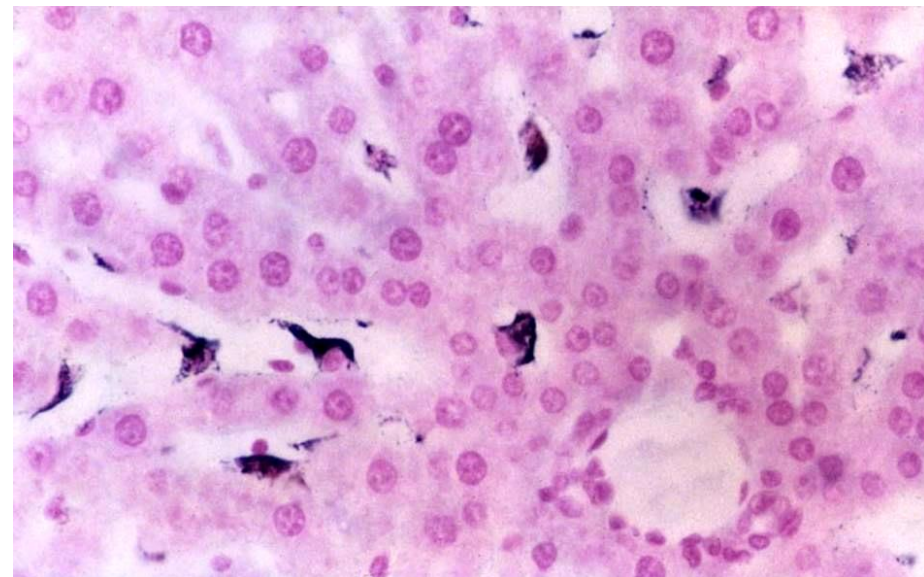
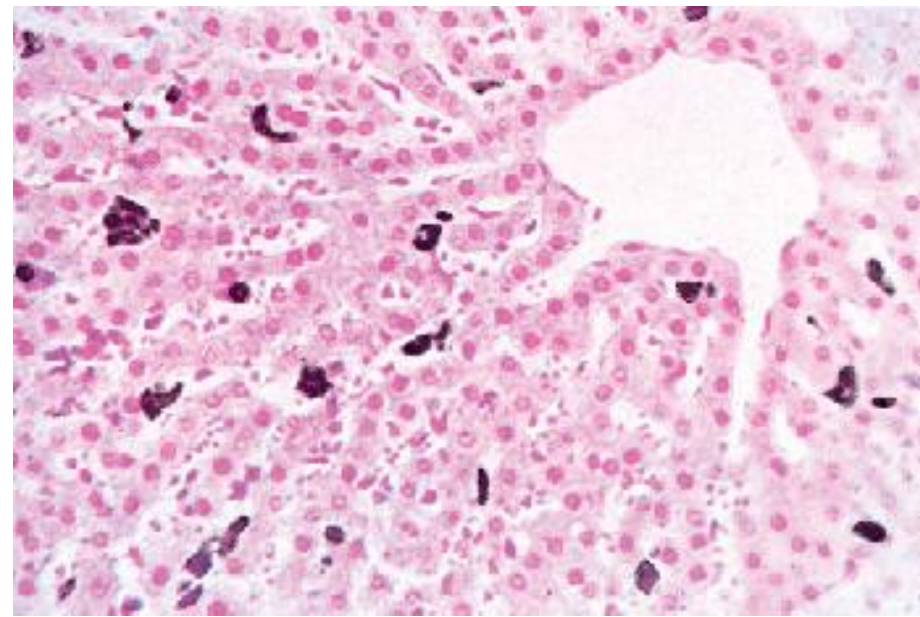




INNER SURFACE OF LIVER SINUSOID – SEM

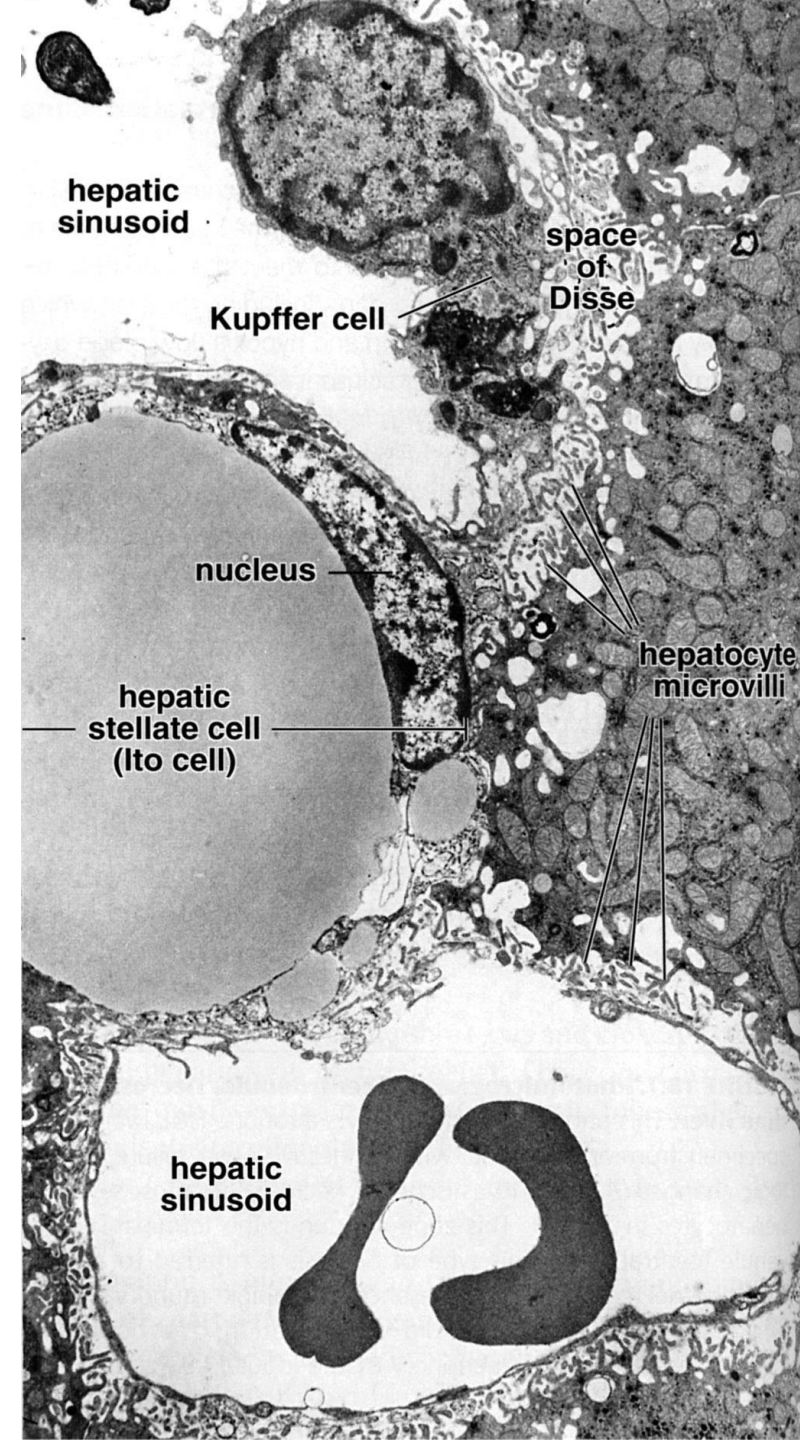
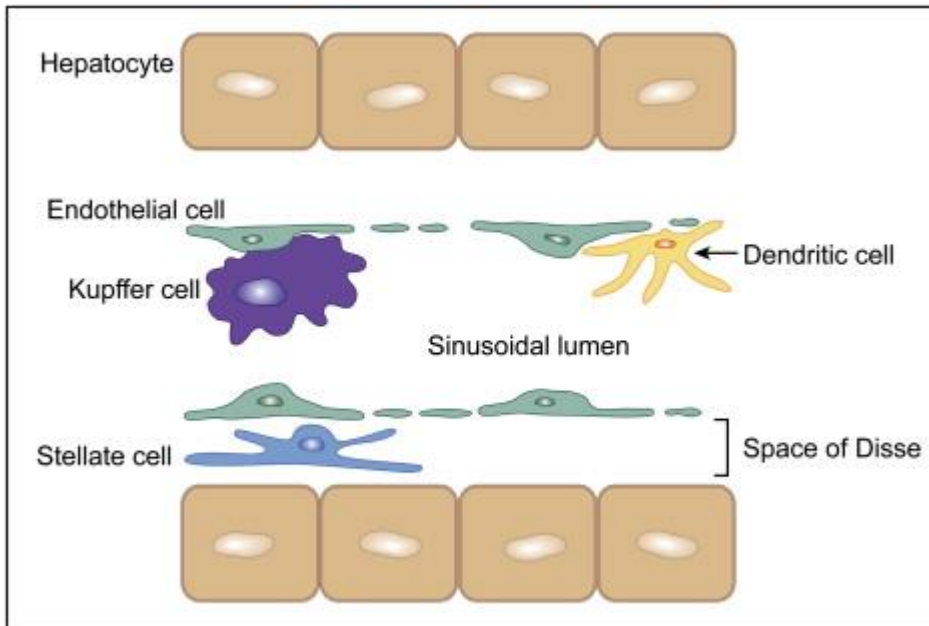
KUPFFER CELLS

- Liver macrophages
- Mononuclear phagocyte system
- Phagocytosis of particles, damaged erythrocytes and pathogens



CELLS OF ITO

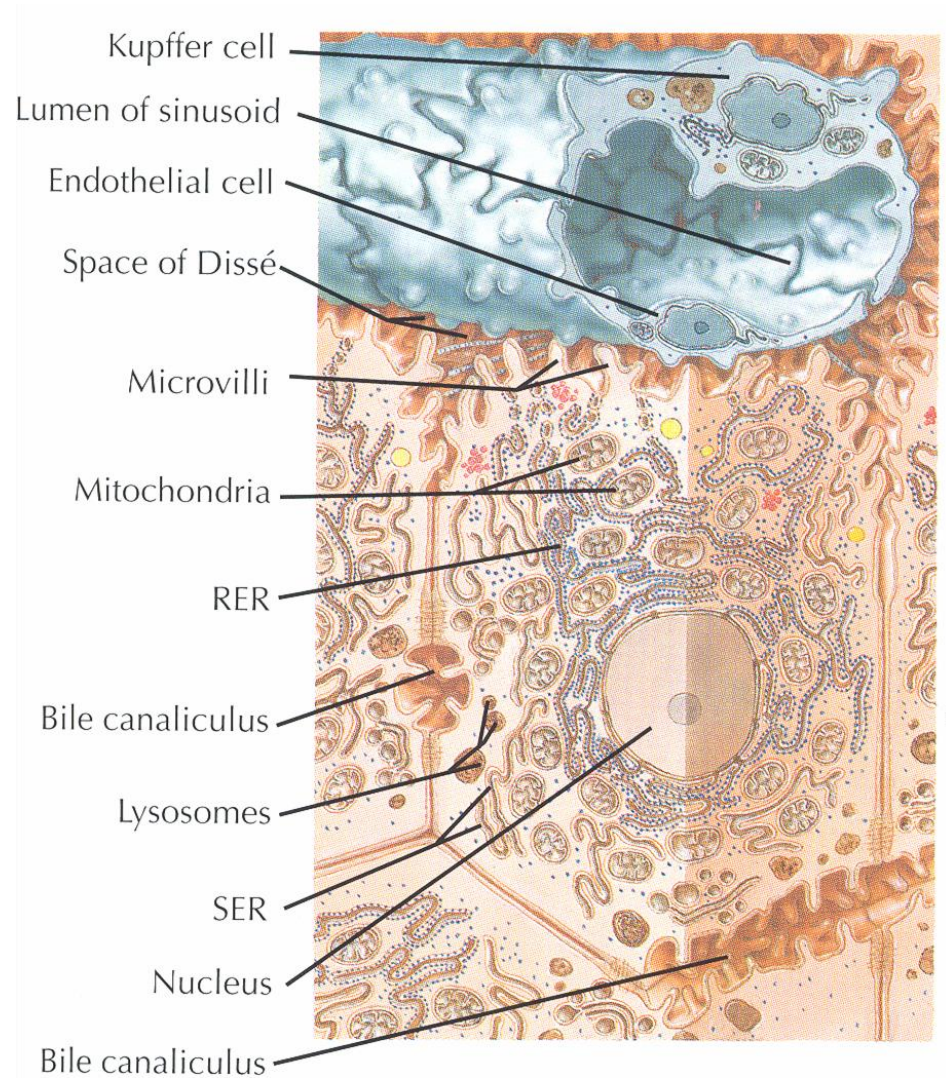
- Star-shape (stellate, perisinusoidal) cells
- Lipid droplets
- Deposition of vitamin A
- fine reticular c.t.
- Antigen presenting cells (lipid antigens)



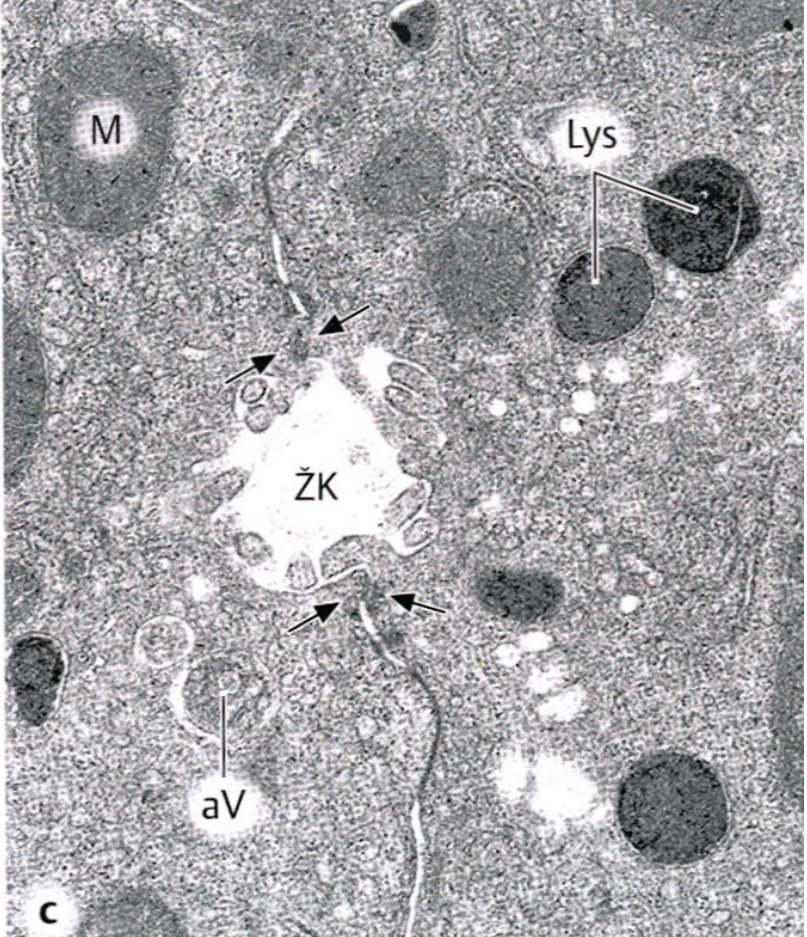
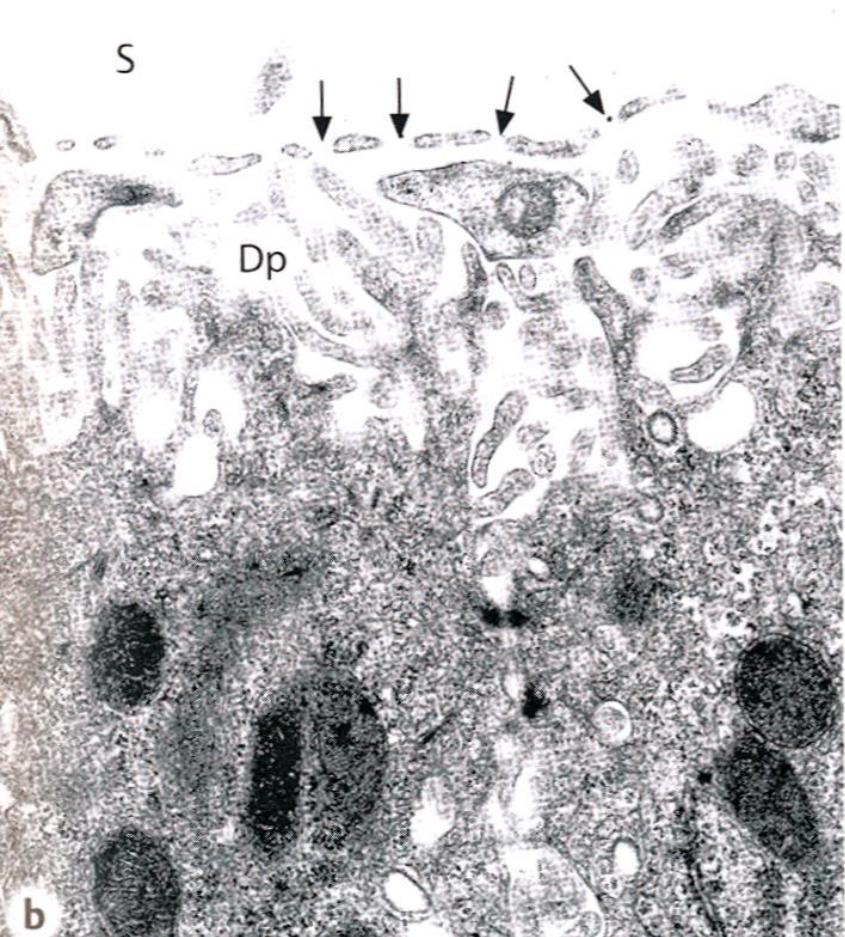
HEPATOCYTES

- Polygonal cells of liver parenchyma
- 20x30µm
- Irregular trabecules between sinusoids
- Usually one central nucleus. Bi- and multi-nuclear cells common (20%)
- Nucleoli
- Lysosomes
- Glycogen

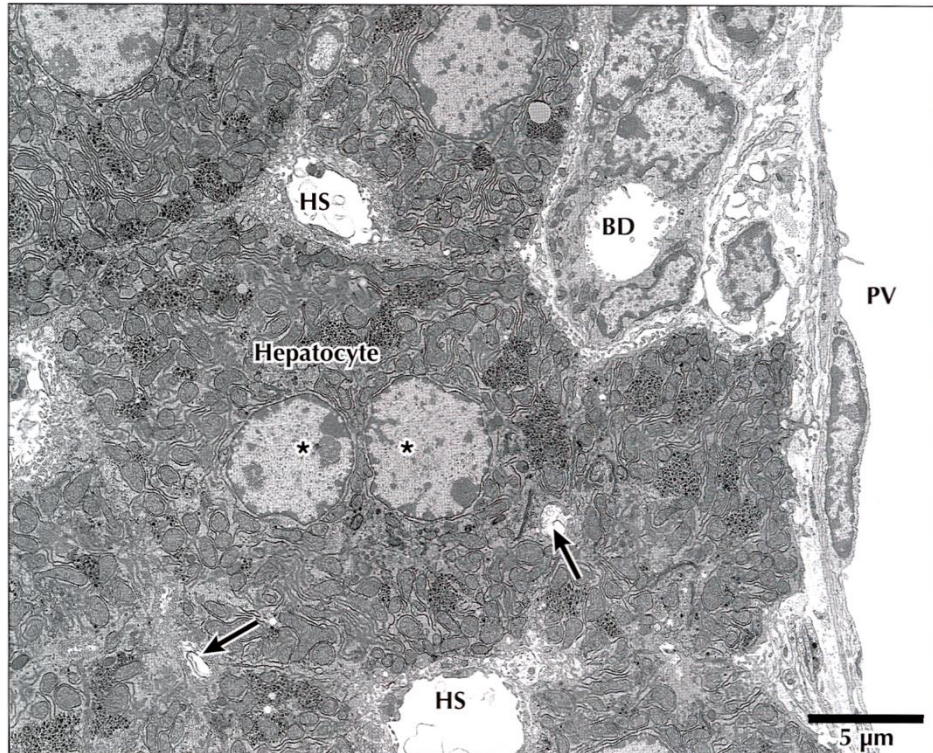
- Functional surfaces:
 - **Bile pole** - secretory– membranes of neighboring hepatocytes form bile capillary
 - **Blood pole** - absorptive - sinusoidal – microvilli oriented to space of Dissé
 - Membranes with intercellular junctions



BILIARY AND BLOOD POLE OF HEPATOCYTE



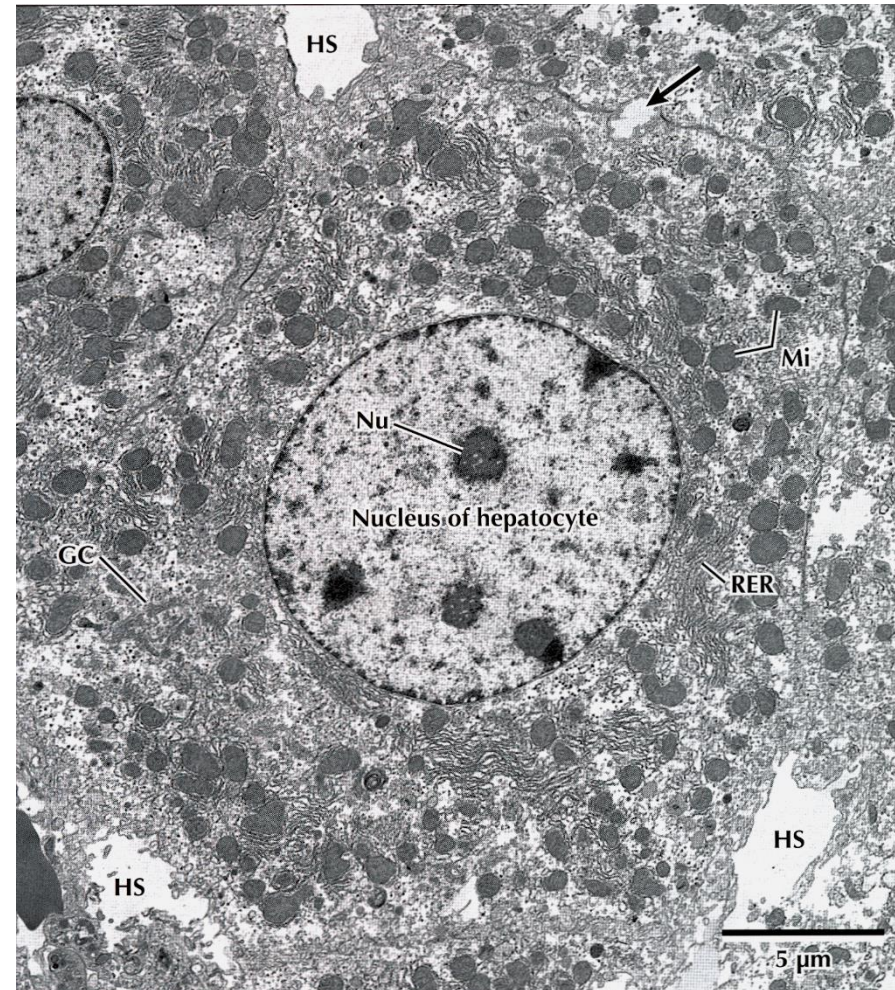
ULTRASTRUCTURE OF HEPATOCYTES



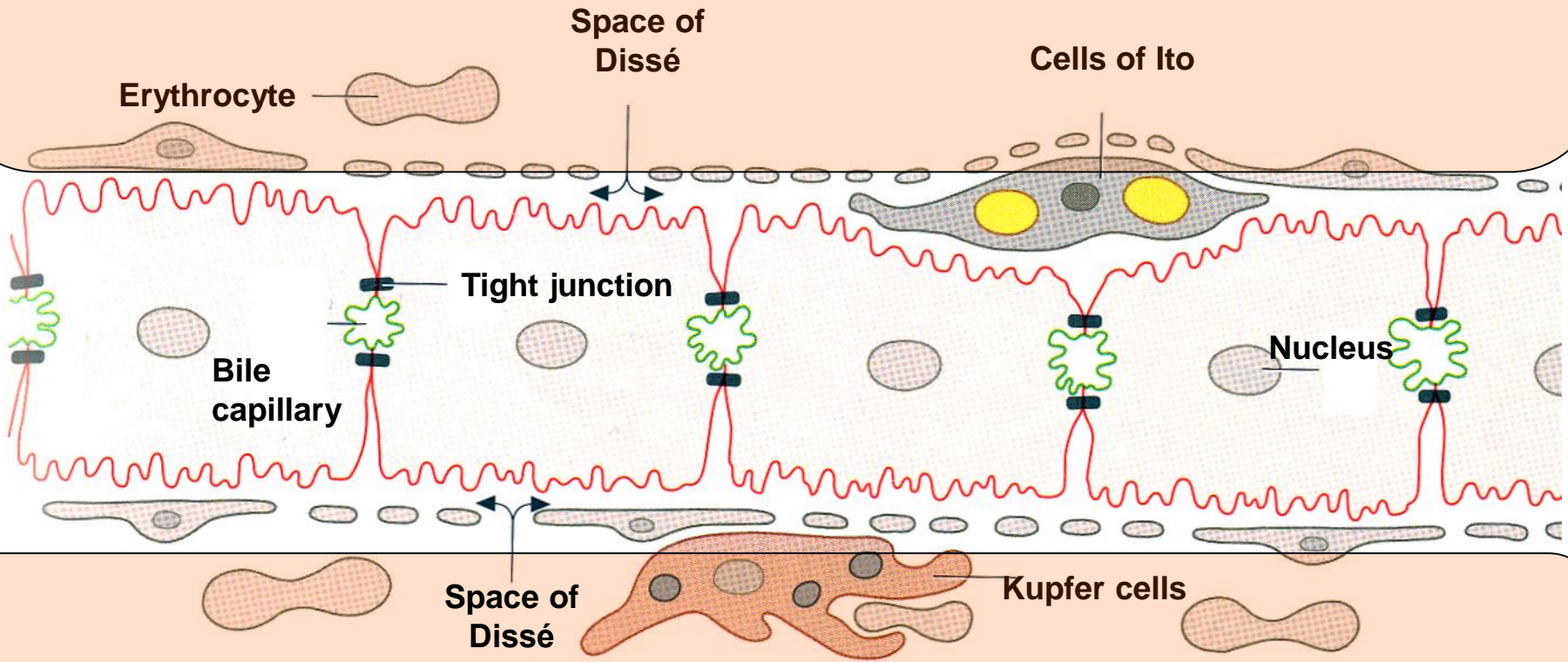
Long mitochondria with flat or tubular cristae

Apparent RER , SER and Golgi

Glycogen, lipid droplets, lysosomes,
peroxisomes



From plasma:
Glucose, aminoacids, bile acids



Blood proteins (serum albumin, fibrinogen, prothrombin, complement, transferrin, etc.)

INTRAHEPATIC AND EXTRAHEPATIC BILE DUCTS

INTRAHEPATIC

Bile capillaries (biliary canaliculi)

- intercellular space between hepatocytes
- 1-2 μ m
- no true wall, formed by membranes of hepatocytes
- intercellular junctions

Canals of Herring

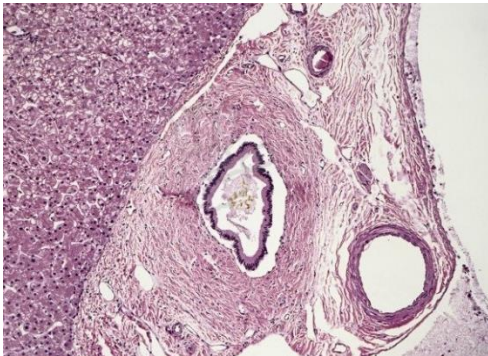
- simple squamous epithelium

Interlobular bile ducts

- cholangiocytes
- cubic or low columnar epithelium + c.t.

Lobar bile ducts


- ductus hepaticus dexter et sinister
- high simple columnar epithelium



EXTRAHEPATIC

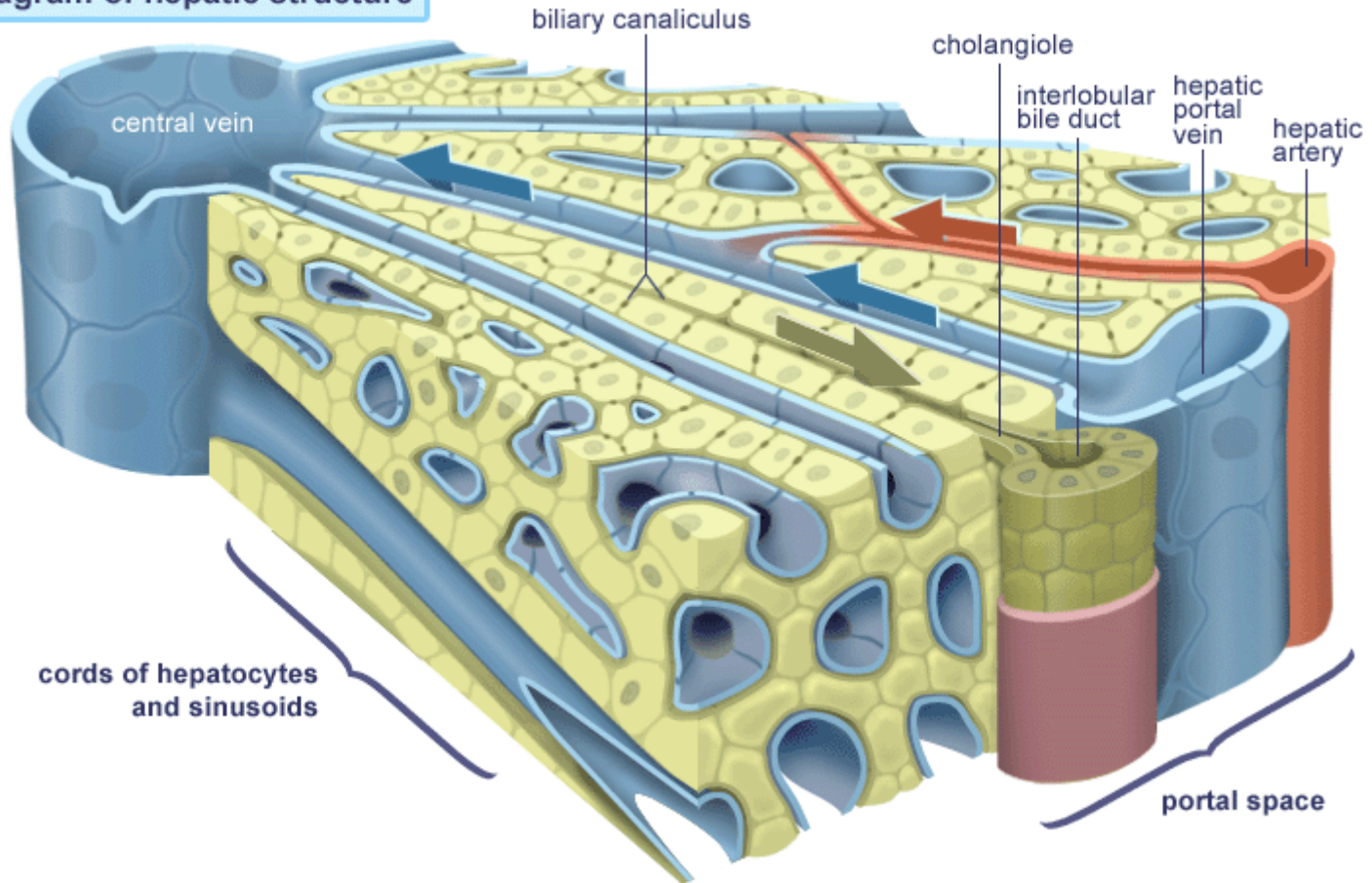
Ductus hepaticus, ductus cysticus, ductus choledochus

- mucosa
- fibromuscular layer



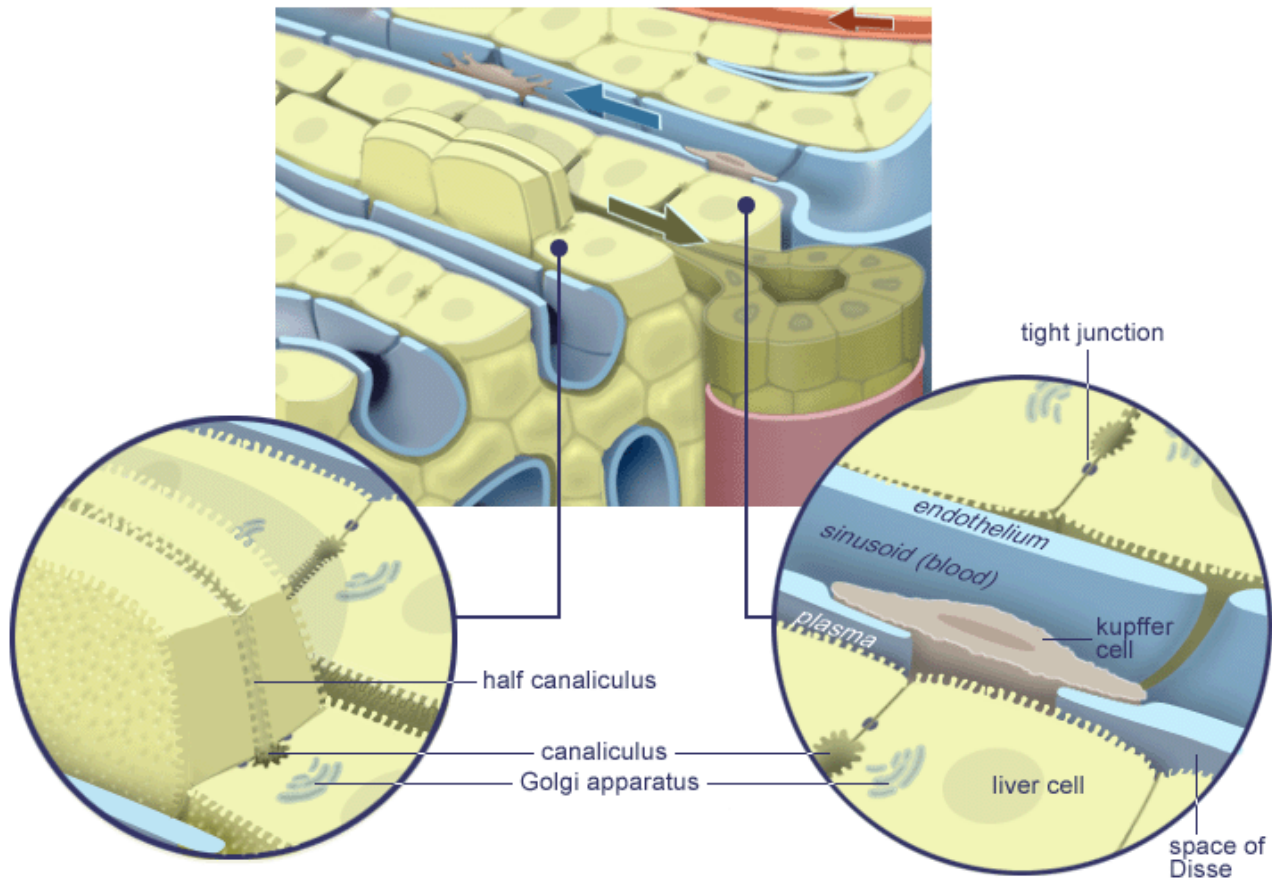
INTRAHEPATIC BILE DUCTS

Diagram of hepatic structure



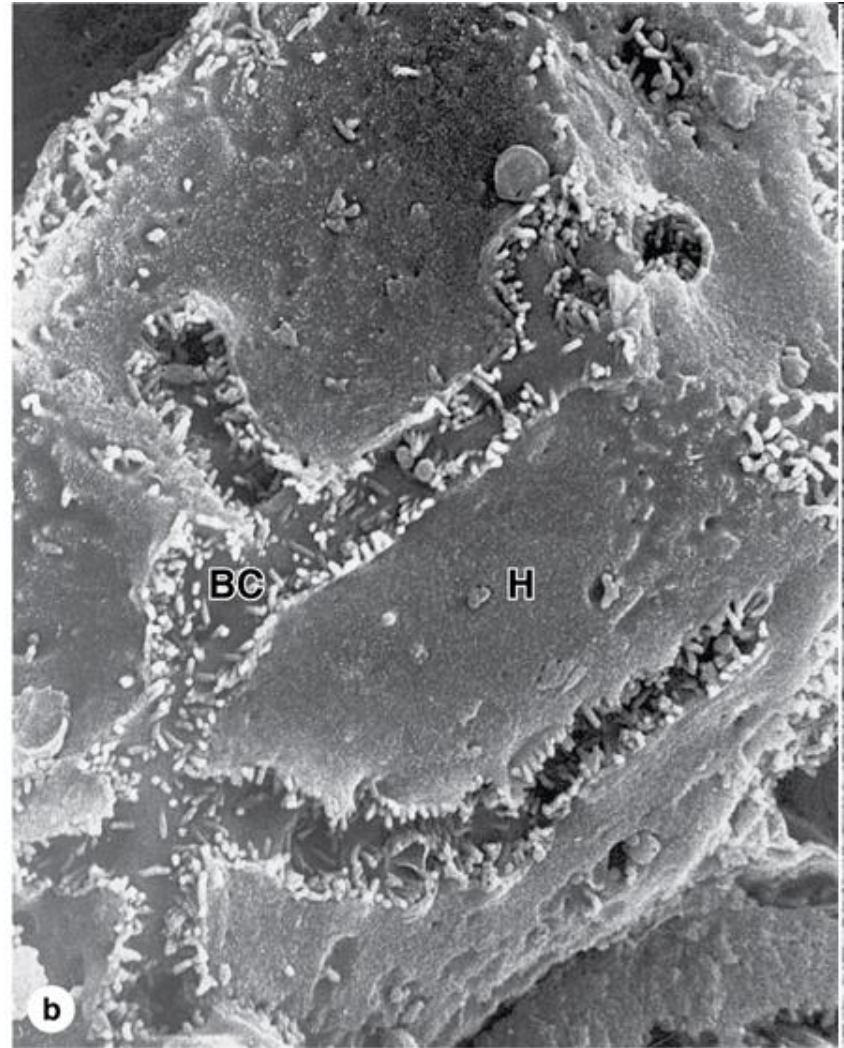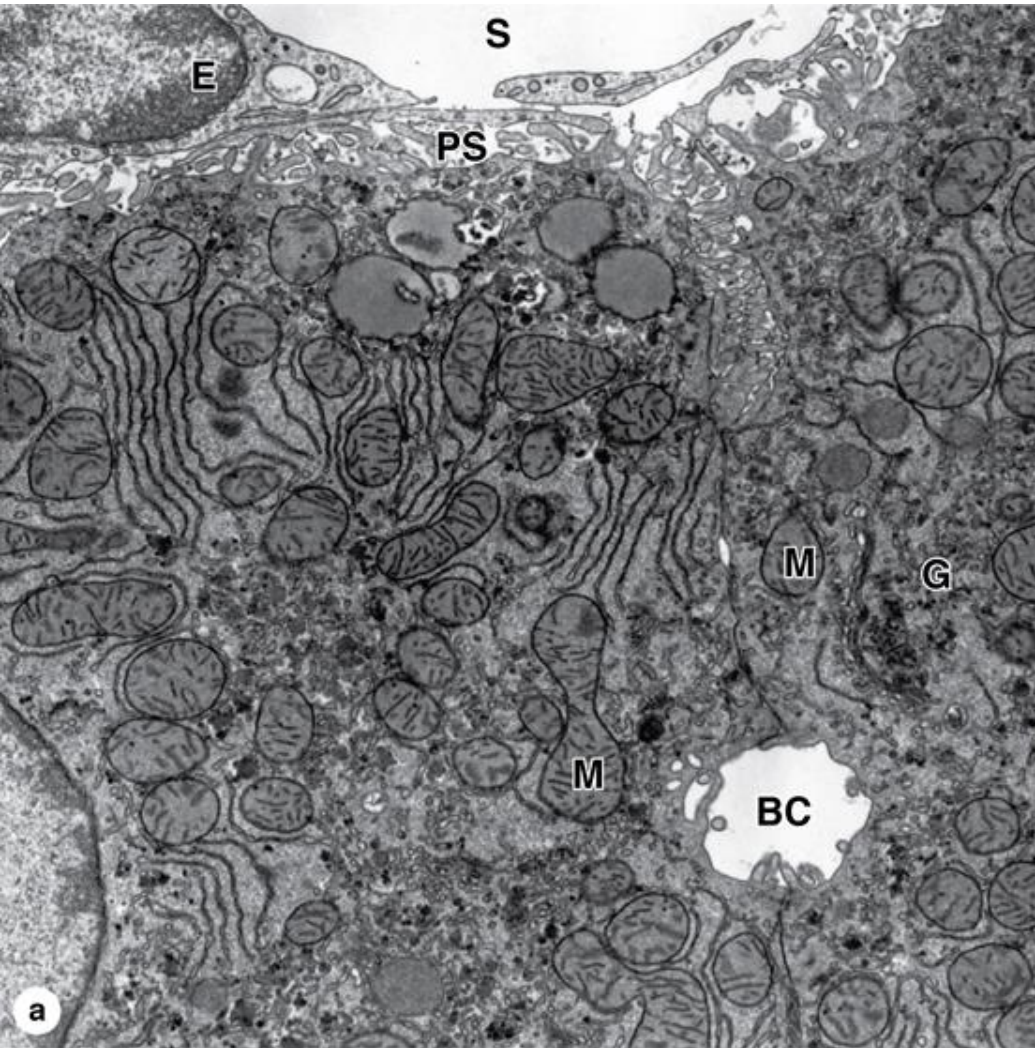
INTRAHEPATIC BILE DUCTS

Hepatic structure (close-up)



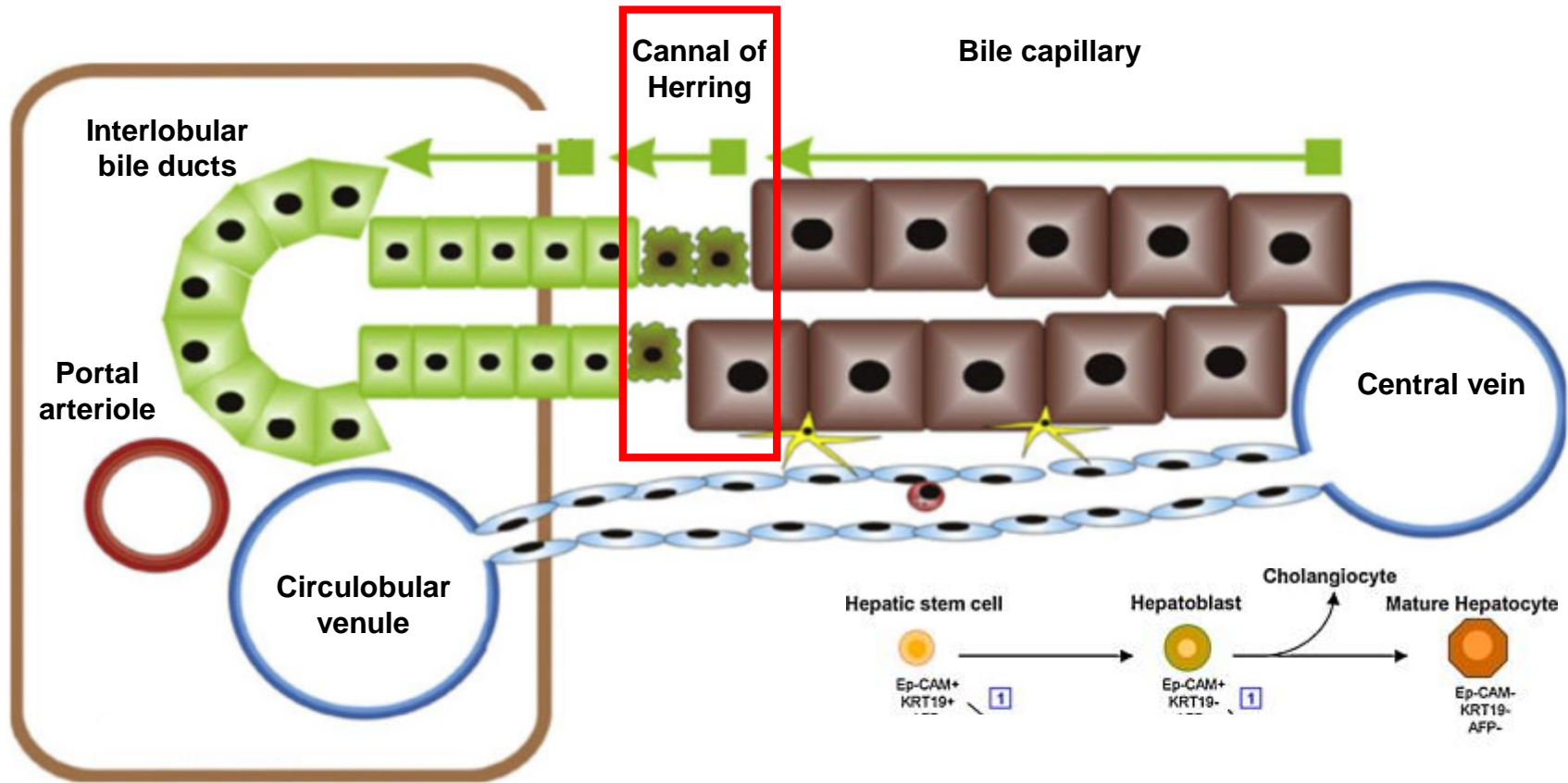
INTRAHEPATIC BILE DUCTS

TEM/SEM



CHOLANGIOCYTES

HEPATOCYTES



EXTRAHEPATIC BILE DUCTS

d. hepaticus communis + d. cysticus → d. choledochus

papilla duodeni major

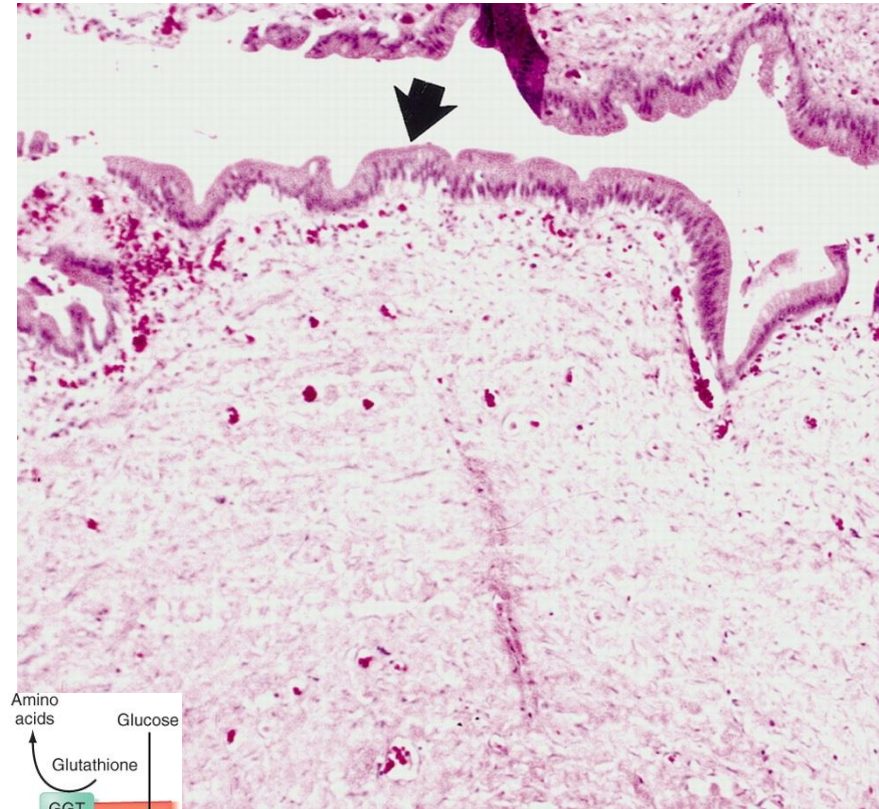
m. sphincter ampullae hepatoduodenalis (sphincter of Oddi)

Mucosa

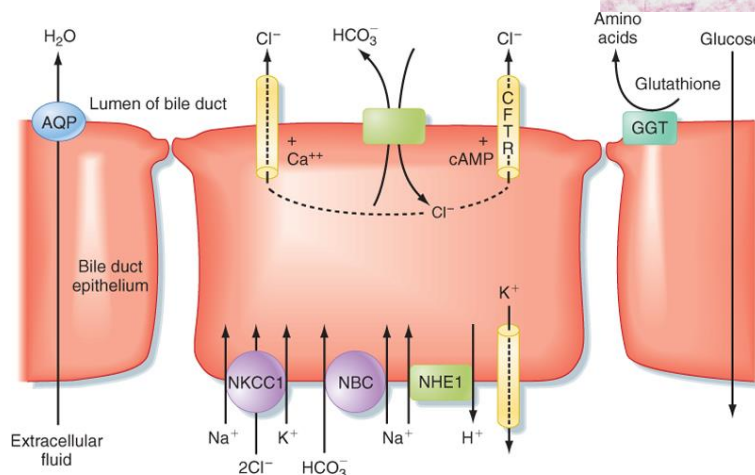
- lateral folds
- simple columnar epithelium (cholangiocytes)
- mucinous glands in c.t., goblet cells

Fibromuscular layer

- dense network of collagen and elastic fibers
- leiomyocytes



Bile modification

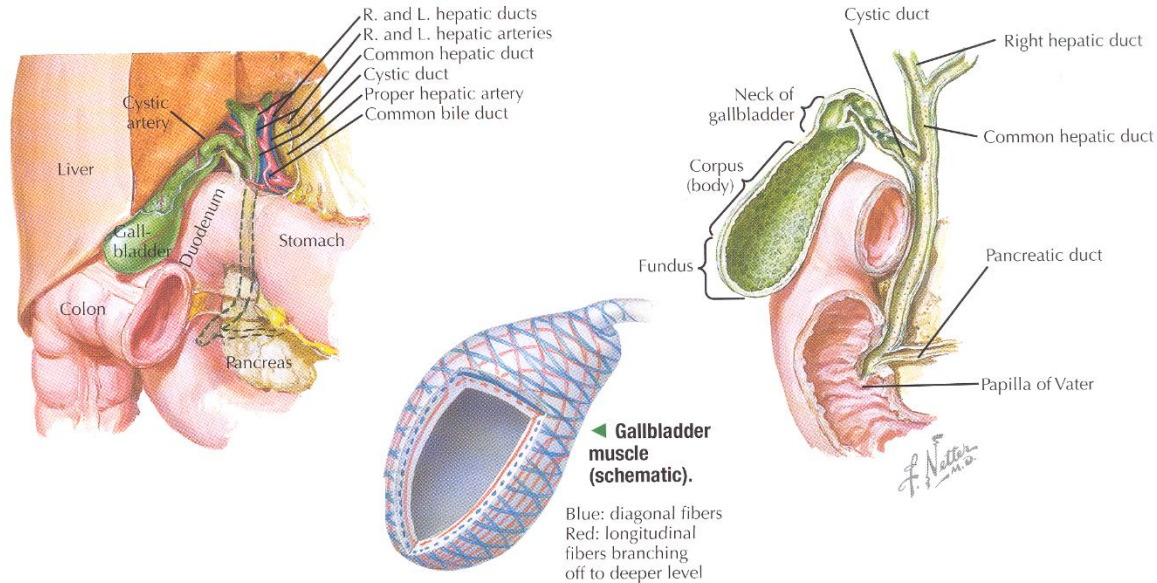


Koeppen & Stanton: Berne and Levy Physiology, 6th Edition.
Copyright © 2008 by Mosby, an imprint of Elsevier, Inc. All rights reserved

GALL BLADDER (VESICA FELLEA)

- Wall 1-2mm

- Mucous coat
- Muscle layer
- Serosa/adventitia



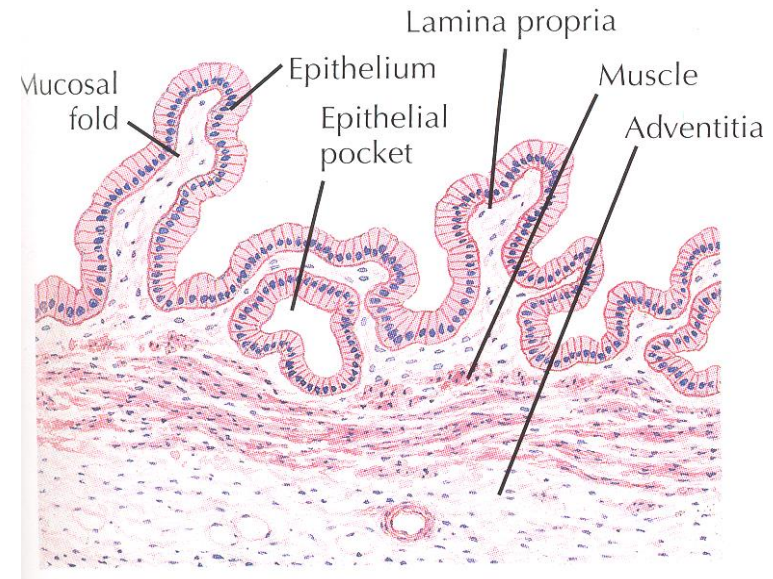
Mucous coat

- mucosal folds
- 20-50 μ m simple columnar epithelium with microvilli
- intercellular junctions
- lamina propria mucosae - loose collagen c.t. with mucinous tuboalveolar glands
- lamina muscularis mucosae absent

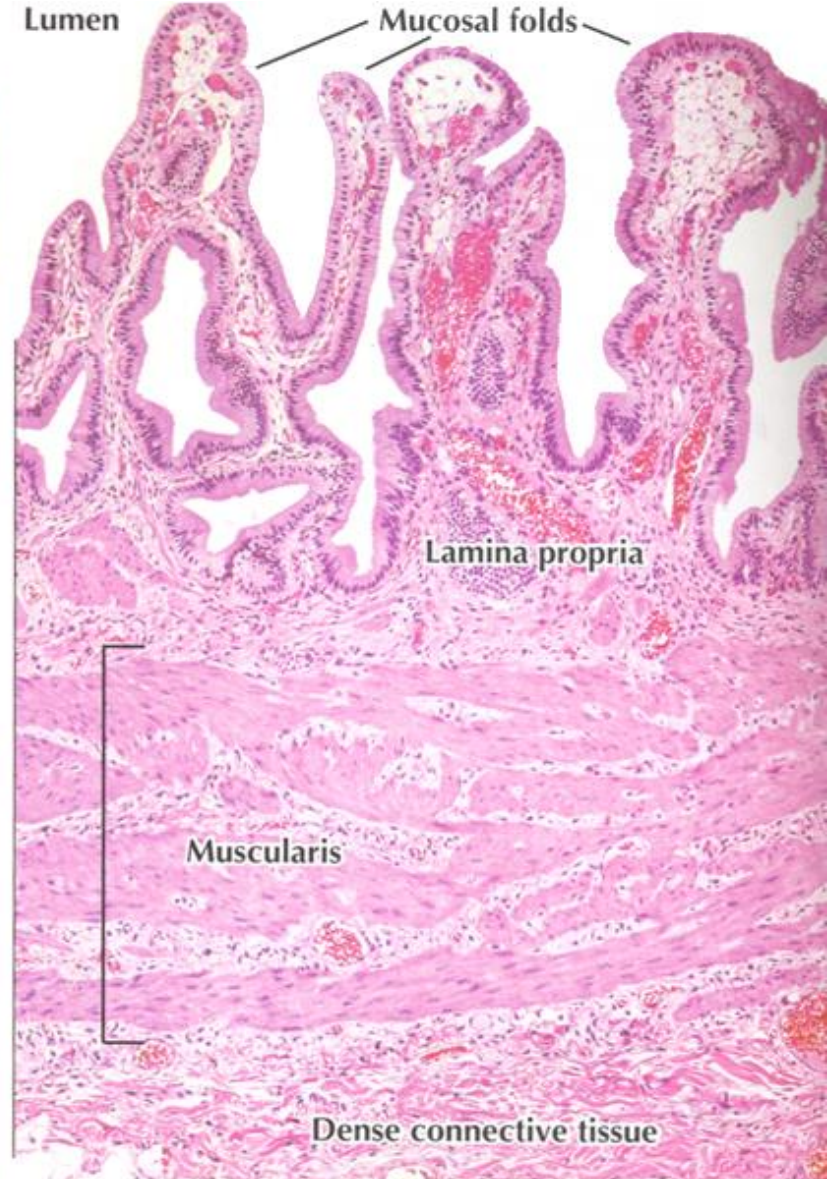
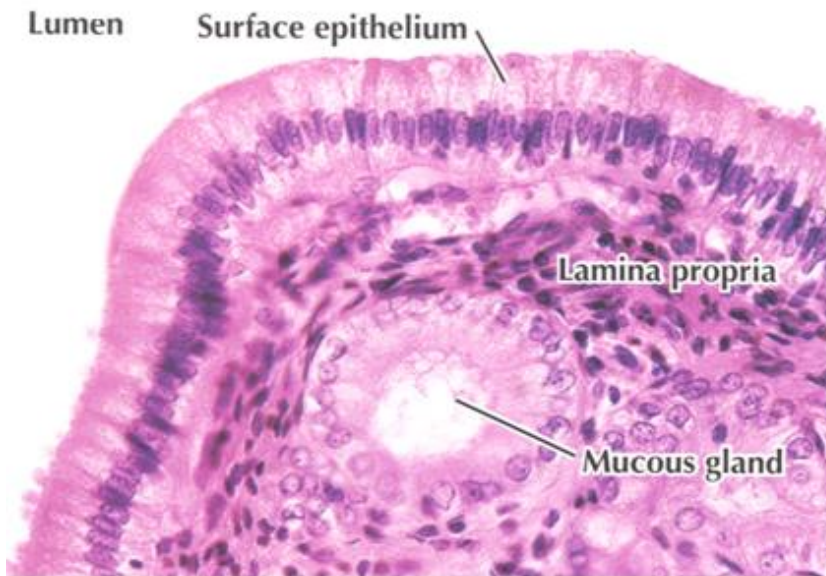
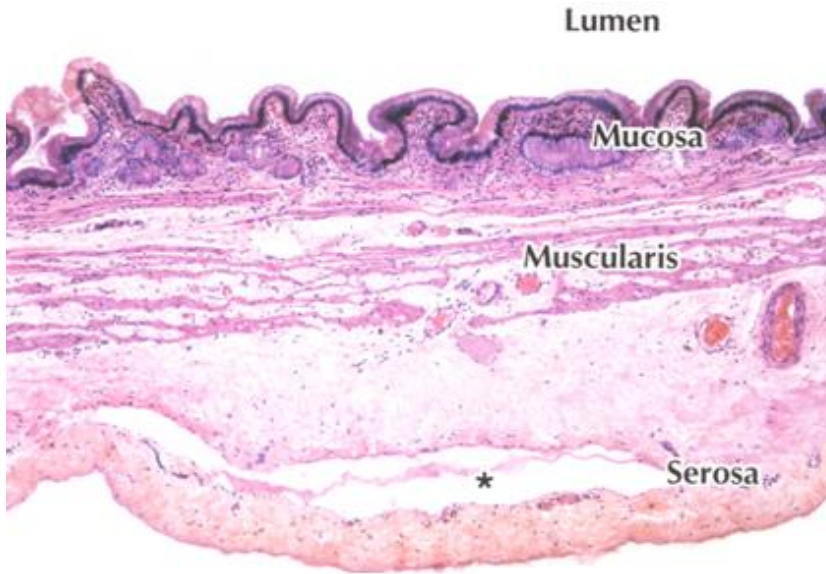
Muscular layer (Muscularis propria)

- 3D network of smooth muscle cells,
- elastic fibers

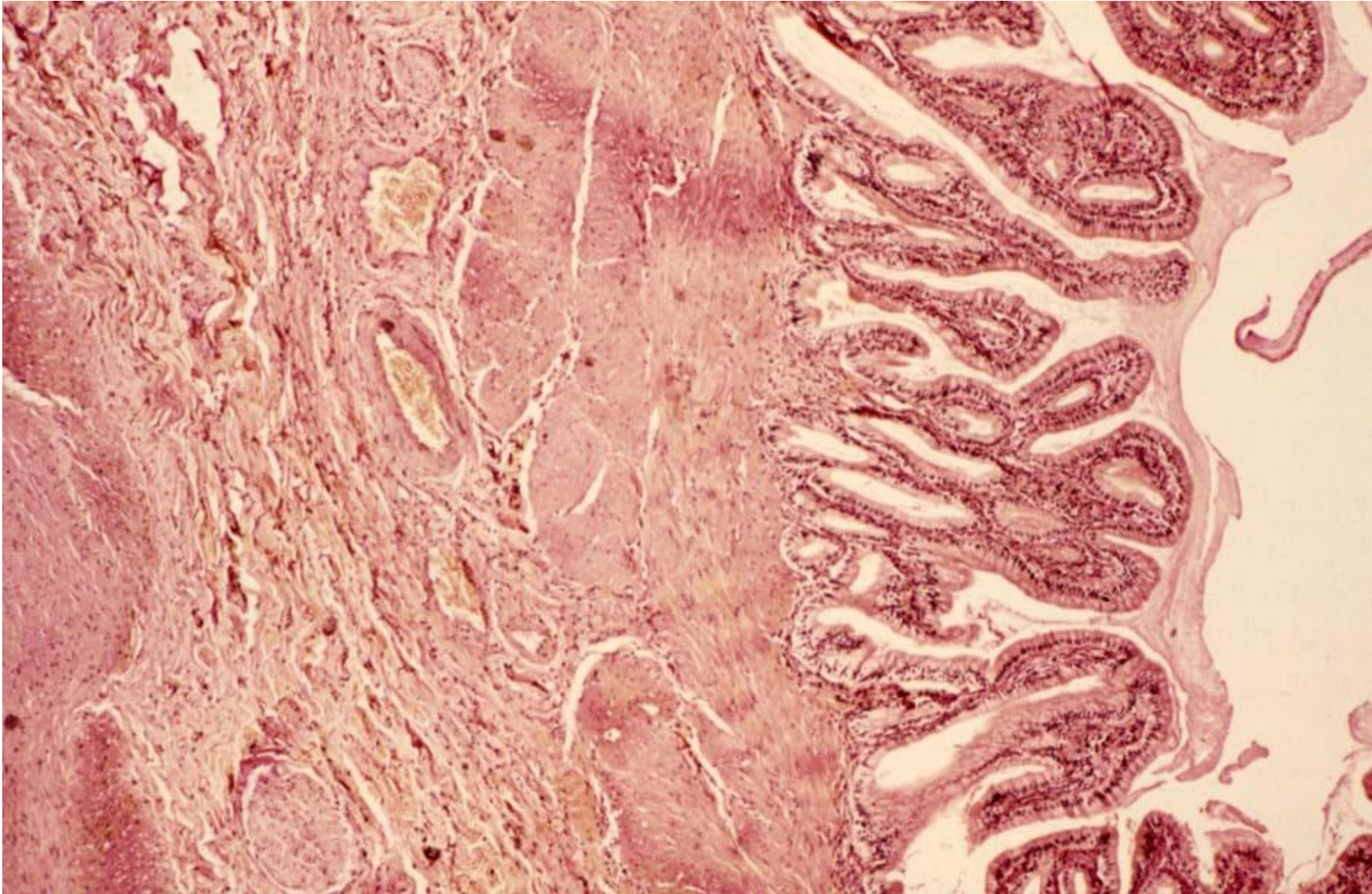
Large layer of **subserous** c.t. (l. propria serosae)



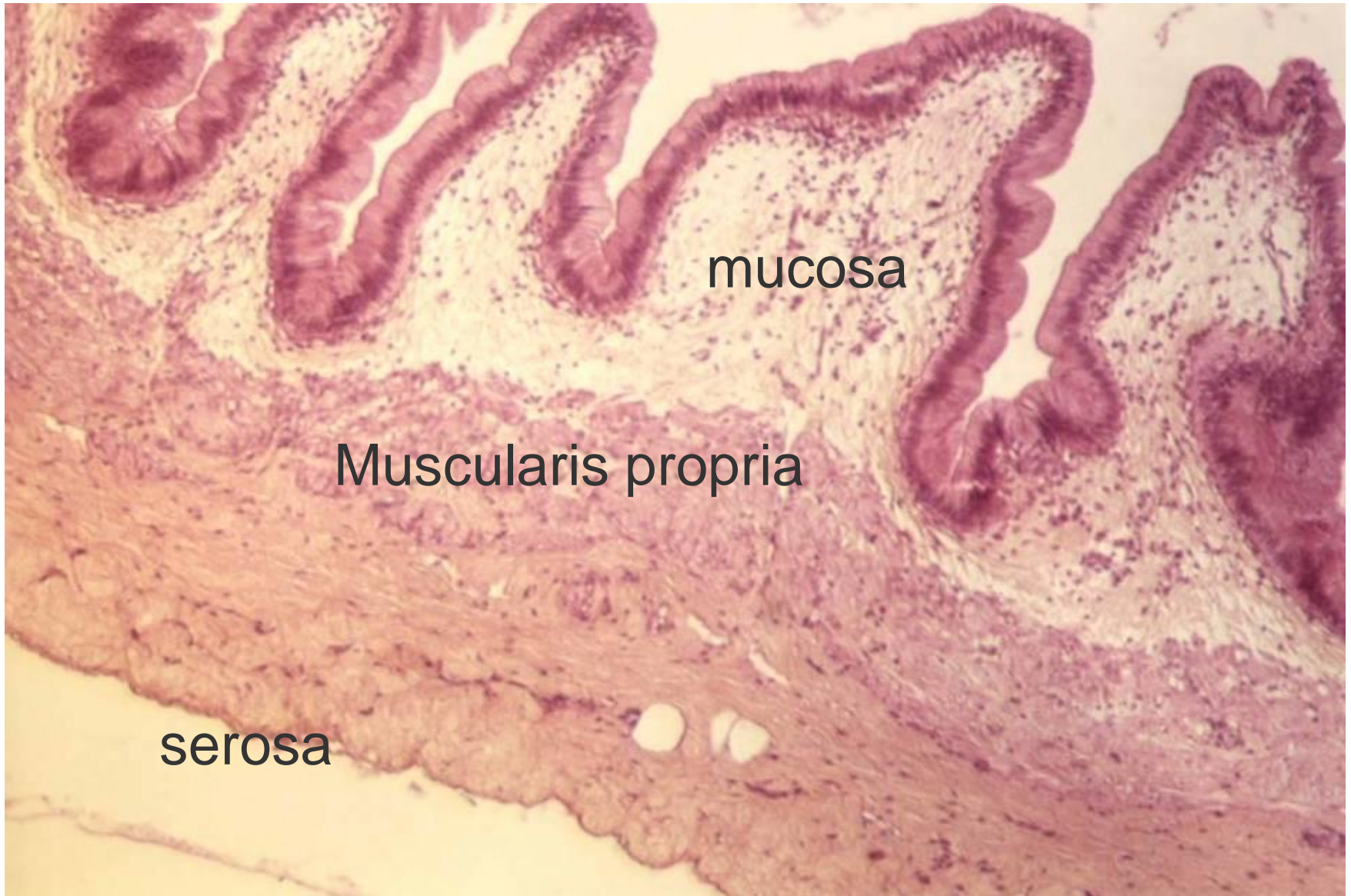
GALL BLADDER (VESICA FELLEA)



GALL BLADDER (VESICA FELLEA)

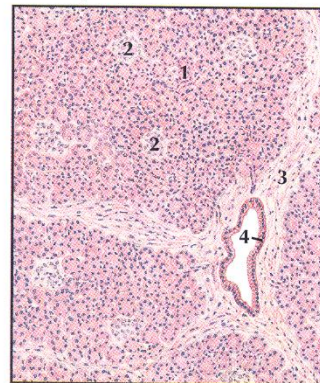
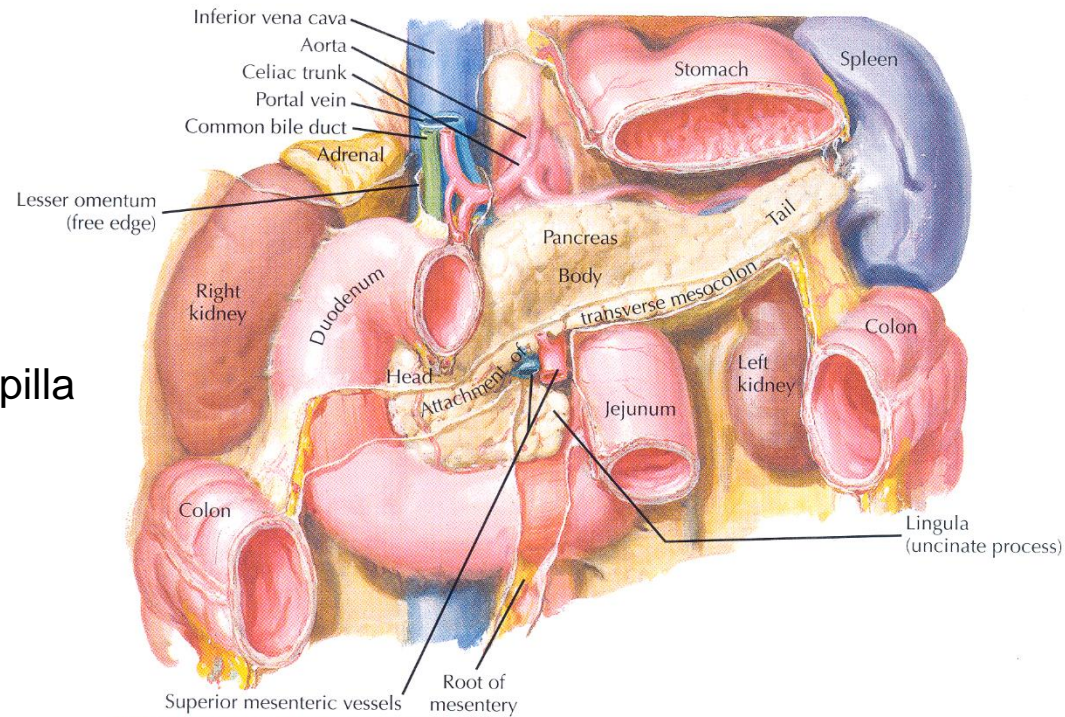


GALL BLADDER (VESICA FELLEA)

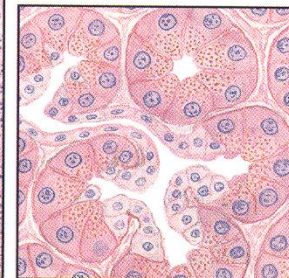


PANCREAS

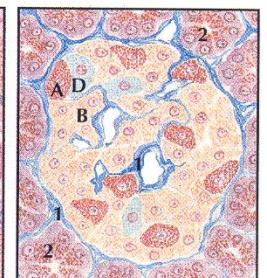
- Compound, serous, tuboalveolar gland
- Exocrine and endocrine character
 - pancreatic acinus
 - Islets of Langerhans
- Major duct (Wirsungi) opens to Vater papilla as a common bile and pancreatic duct
- Dense collagen c.t. capsule
- Septs – blood cells, innervation, and interlobular ducts



Low-power section of pancreas
1. Acini, 2. islet, 3. interlobular septum, 4. interlobular duct



High magnification: acini, intercalated duct and zymogen granules



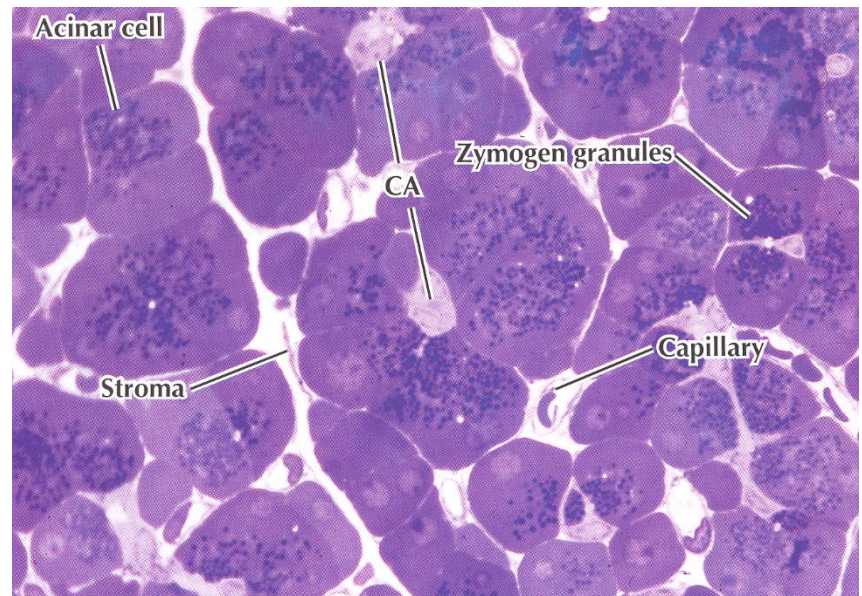
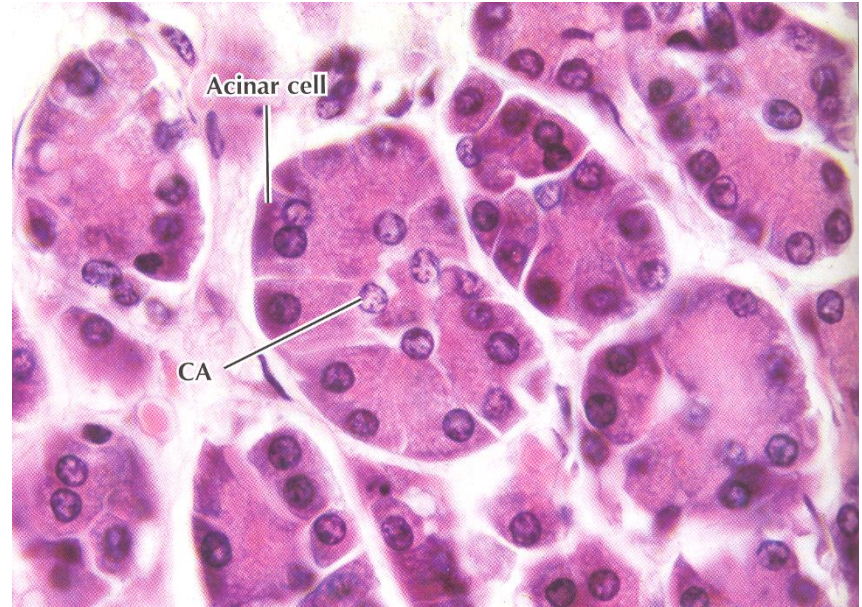
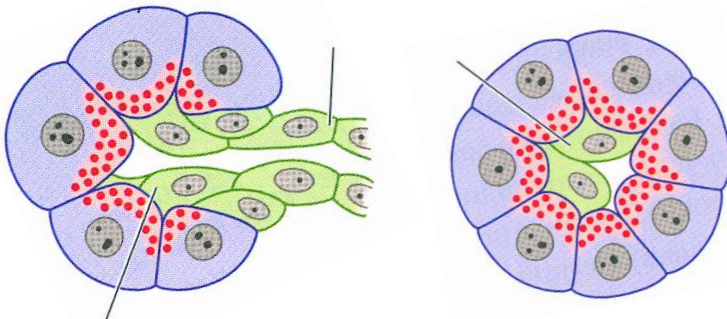
Pancreatic islet: A, B, and D cells. 1. Reticulum, 2. acini

PANCREATIC ACINUS

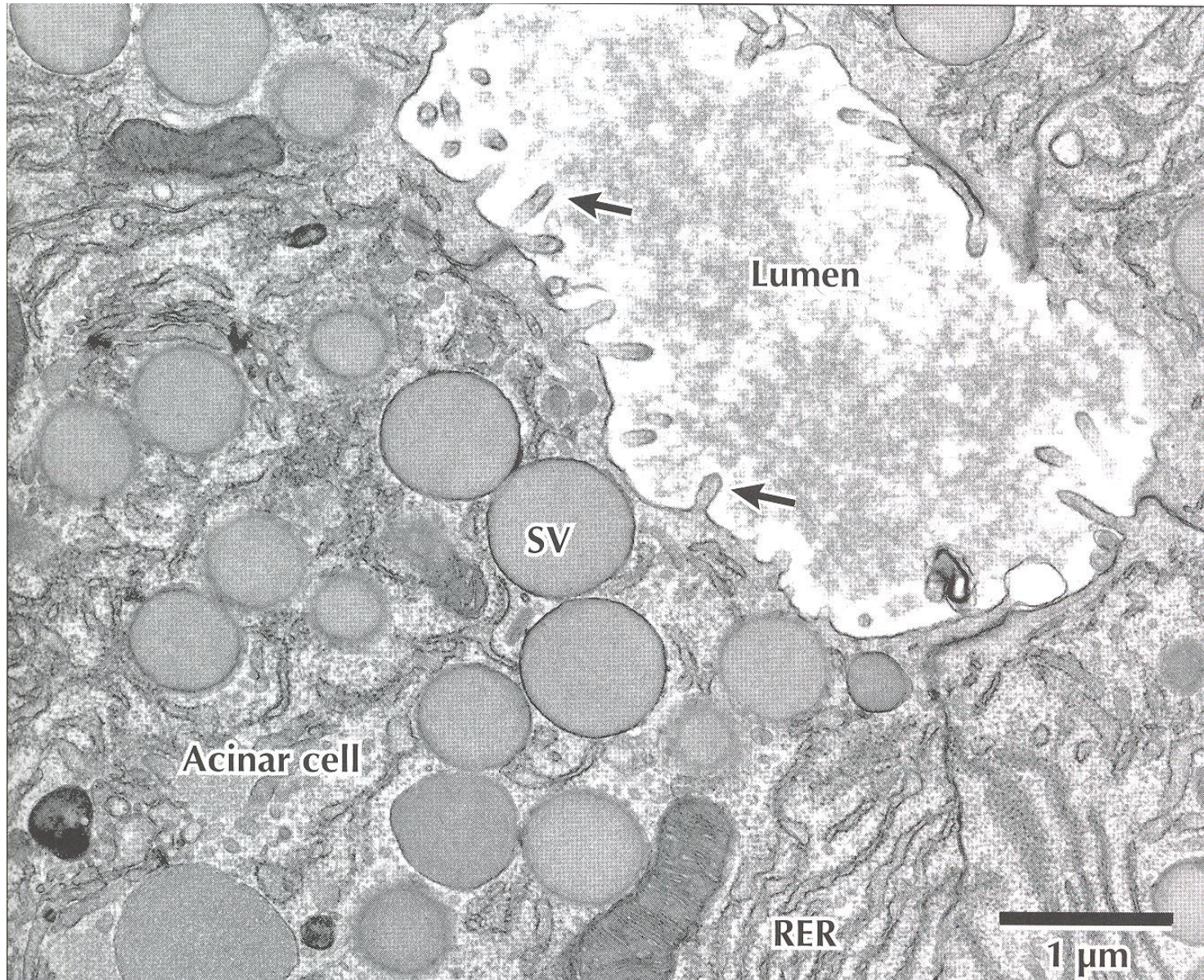
- Pyramidal epithelial cells
- Pancreatic digestive enzymes
- intercalated ducts

- Serous acinar cells
 - Polarized secretory cells
 - Basophilic
 - Apex – Golgi and zymogenic granules
 - Microvilli
 - Intercellular junctions

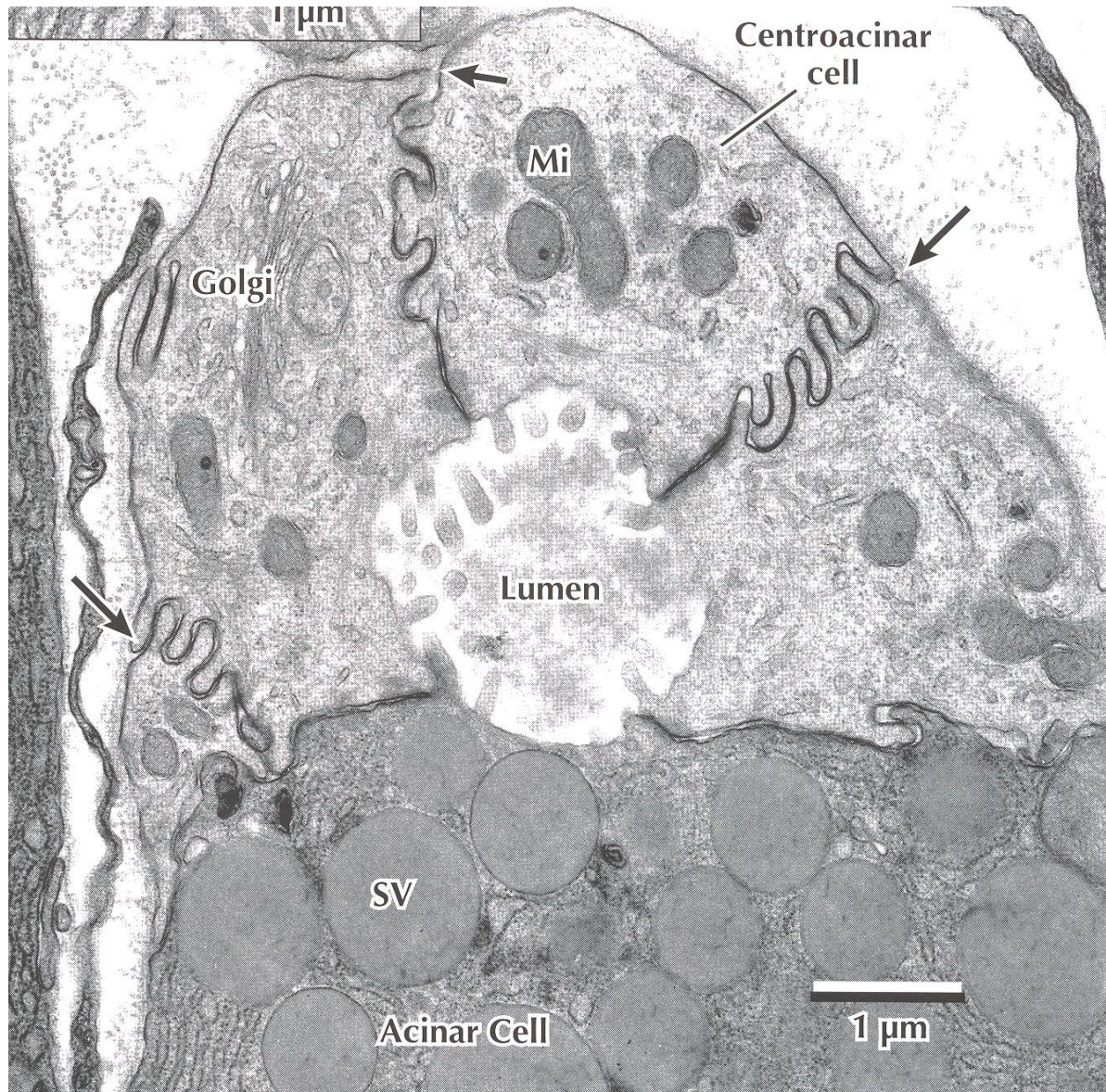
- Centroacinar cells
 - Centrally located nucleus, squamous character
 - Continuous with intercalated ducts



PANCREATIC ACINUS

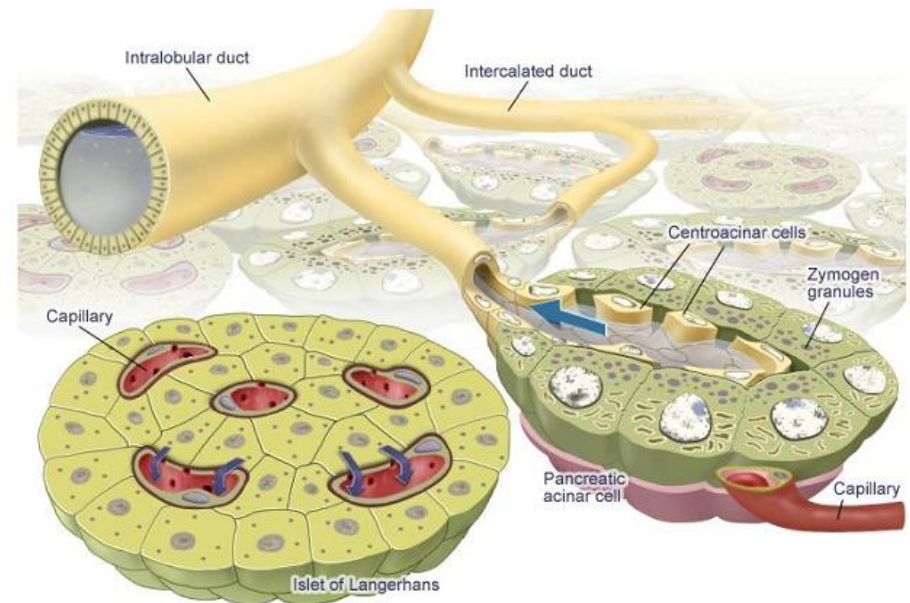
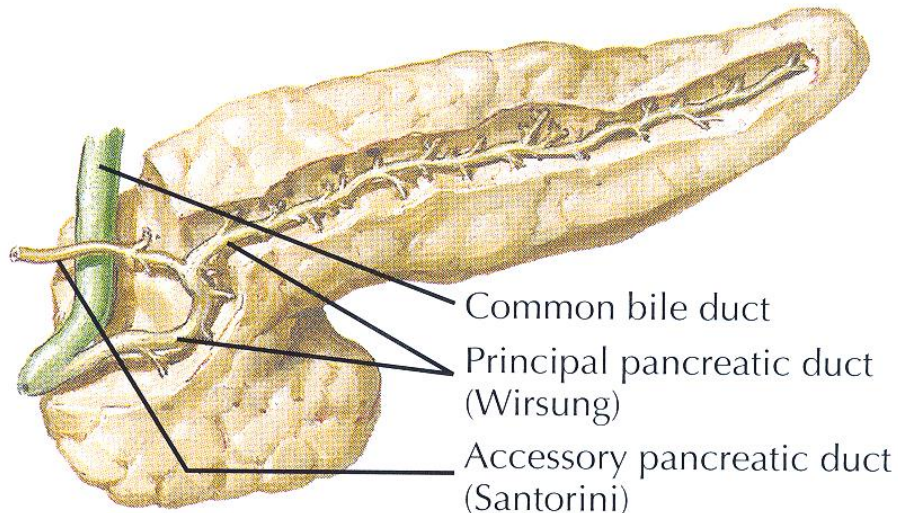


PANCREATIC ACINUS



PANCREATIC DUCTS

- Centroacinar cells
- Intercalated ducts
 - simple squamous epithelium + basal membrane
- Intralobular and interlobular ducts
 - simple cubic – low columnar epithelium
- Major pancreatic ducts
 - D. pancreaticus major – Wirsungi and D. pancreaticus accessorius - Santorini
 - bilayered columnar epithelium and dense collagen c.t.
 - intramural mucinous tubular glands, goblet cells, EC cells

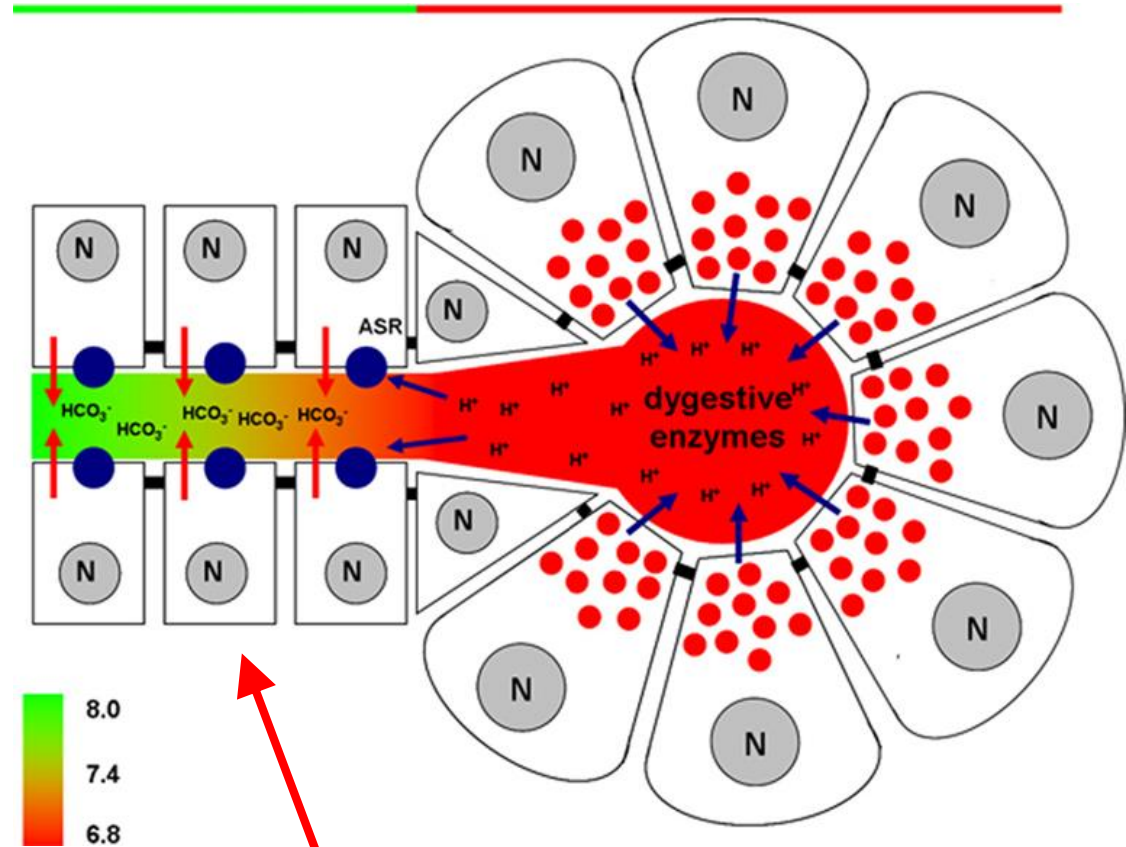
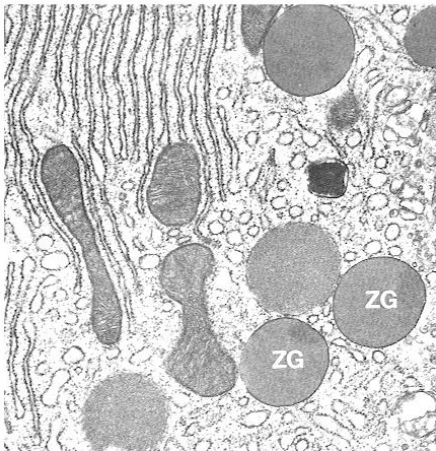


EXOCRINE FUNCTION OF PANCREAS

- ca 1000-2000 ml daily
- alkalic pH (8.8), HCO_3^- (intercalated duct epithelium)
- mucin (epithelium of large ducts)

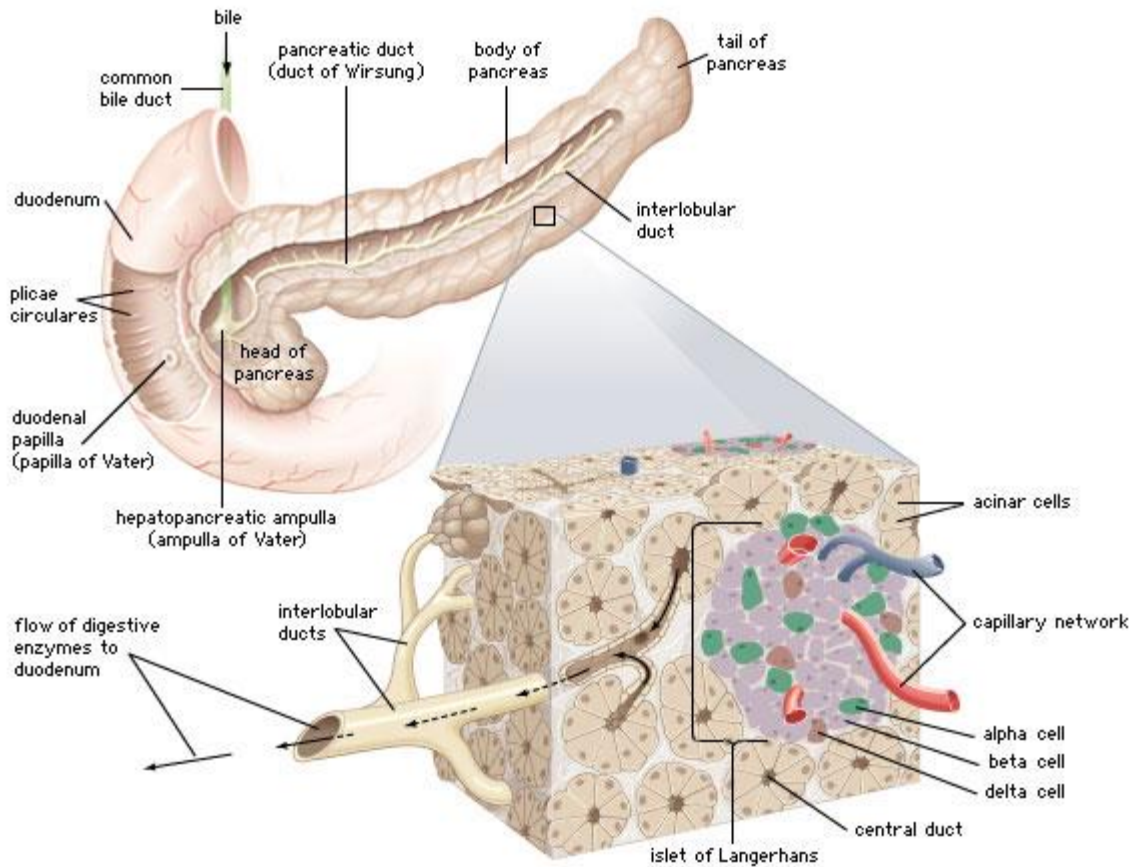
Hydrolases

- Trypsinogen
- Chymotrypsinogen
- Proelastases
- Carboxypeptidases
- Pancreatic lipase
- Amylases
- ...



Hormonal regulation (secretin, cholecystikinin) + parasymphatikus

ENDOCRINE FUNCTION OF PANCREAS



Glucagon

- Glycogen consumption in tissues and muscles
- Increase of blood glucose

Insulin

- Increase of membrane permeability for glucose
- Glucose oxidation in tissues
- Decrease of blood glucose
- Synthesis of glucan in muscles and liver

Pancreatic polypeptide

- Autoregulation of pancreatic secretion

Somatostatin

- Inhibition of GIT hormones

ISLETS OF LANGERHANS

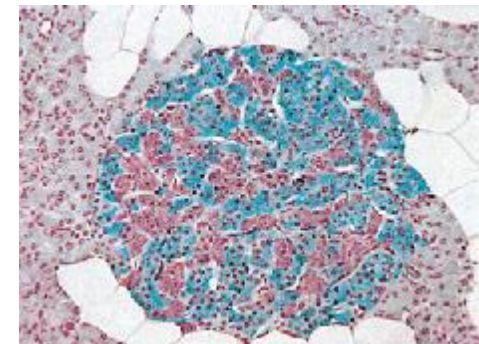
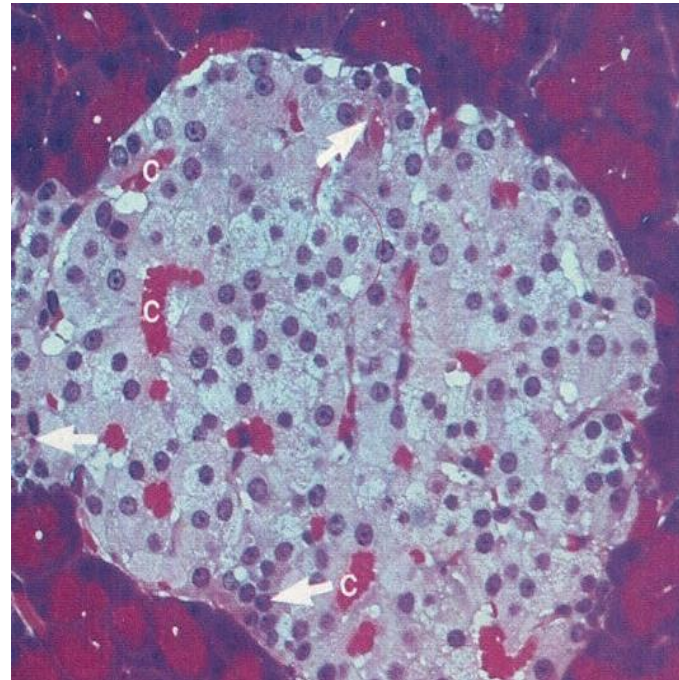
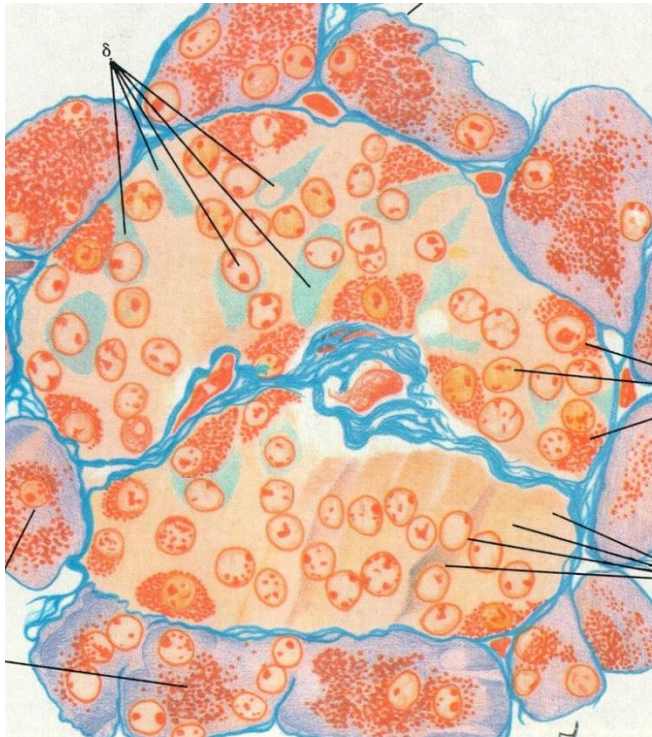
- Clusters of pale cells
- ca $1,5 \times 10^6$
- Thin c.t. capsule
- Cords of epithelial cells
- Sinusoids
- General characteristics of APUD cells
- A, B, D, PP cells

A cells: 20%, glucagon

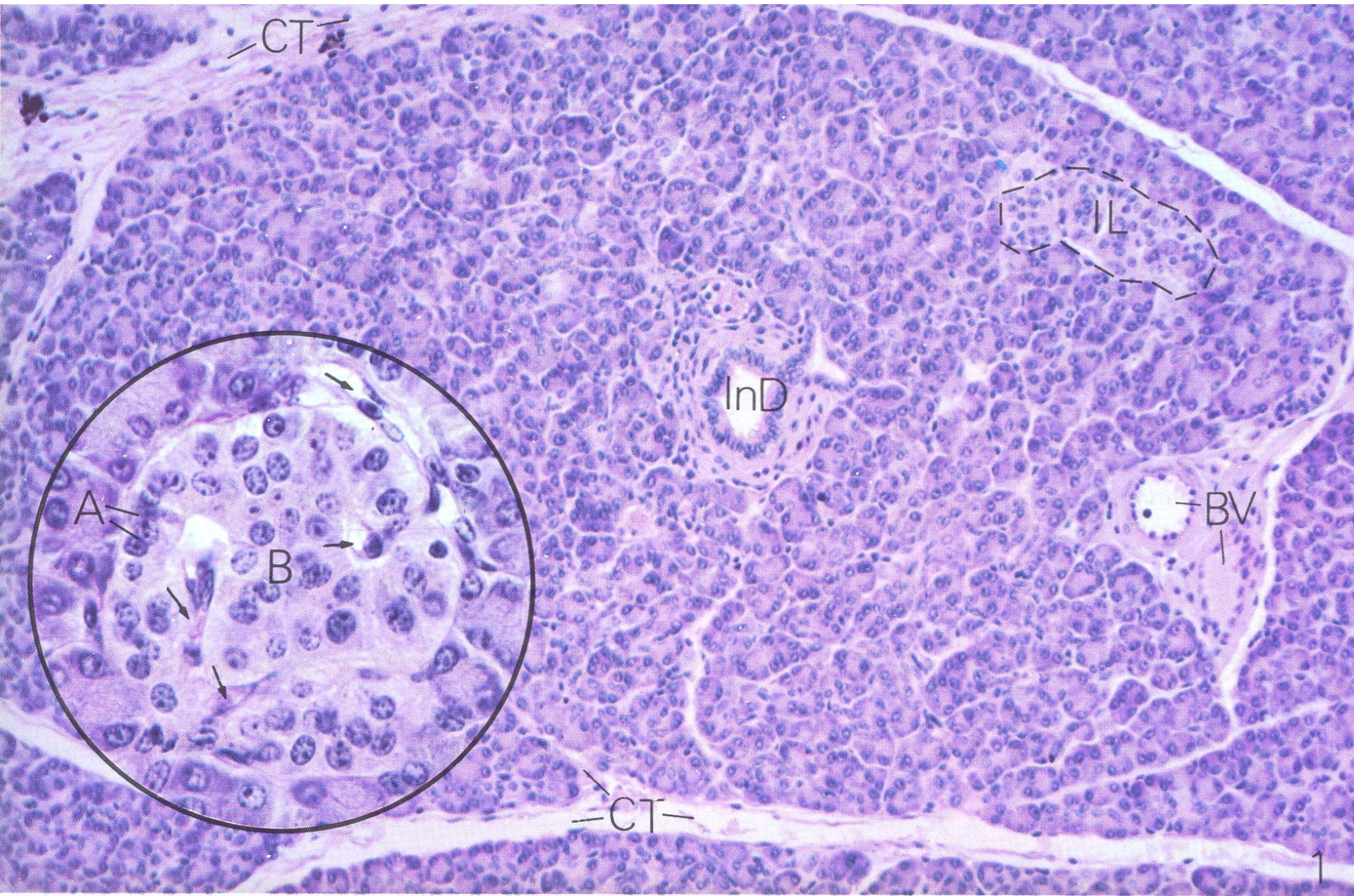
B cells: 60-70%, insulin

D cells: minor, somatostatin

PP cells: minor, pancreatic polypeptide


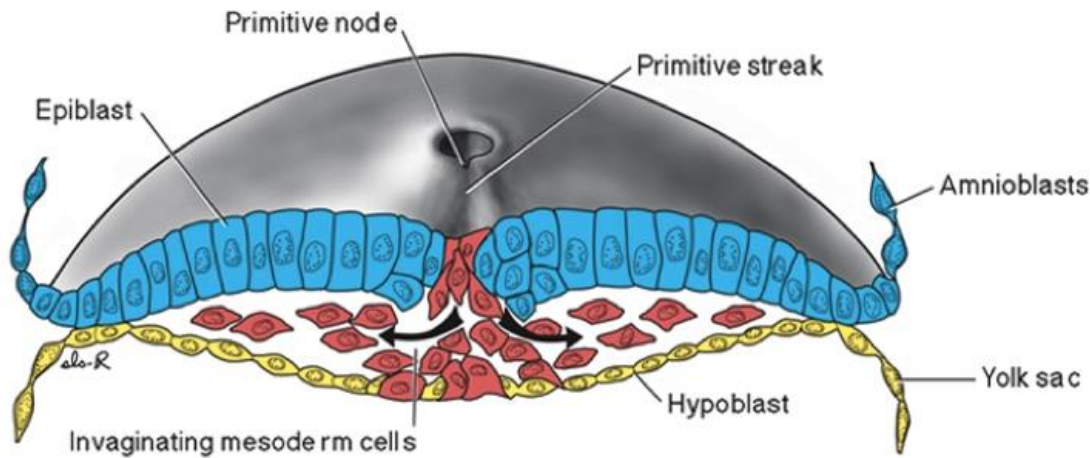
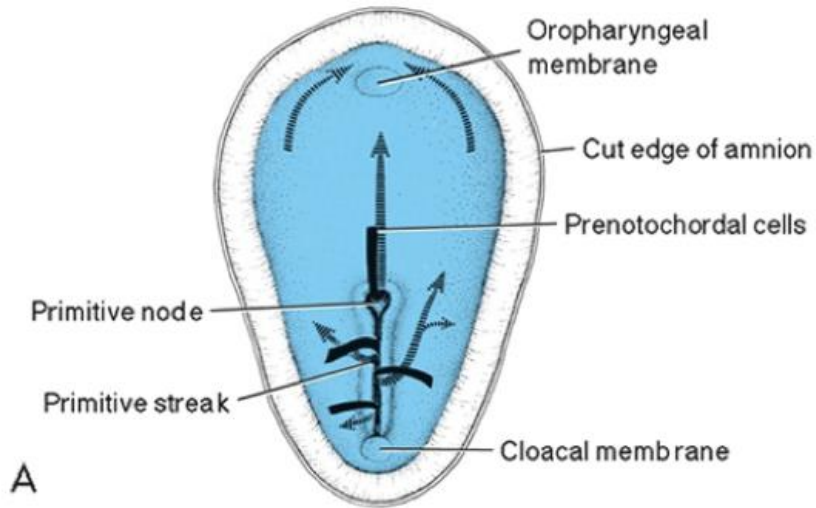


ISLETS OF LANGERHANS

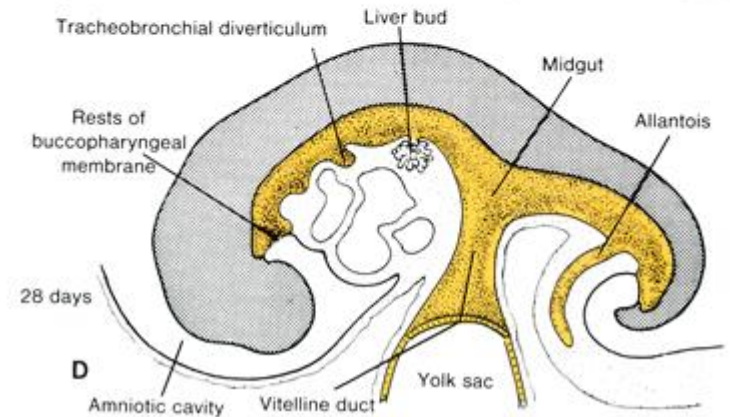
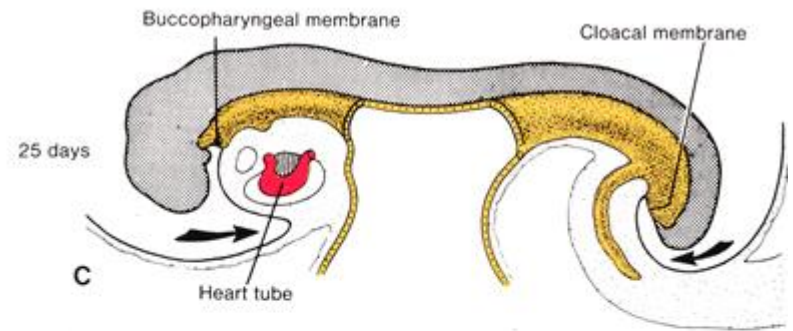
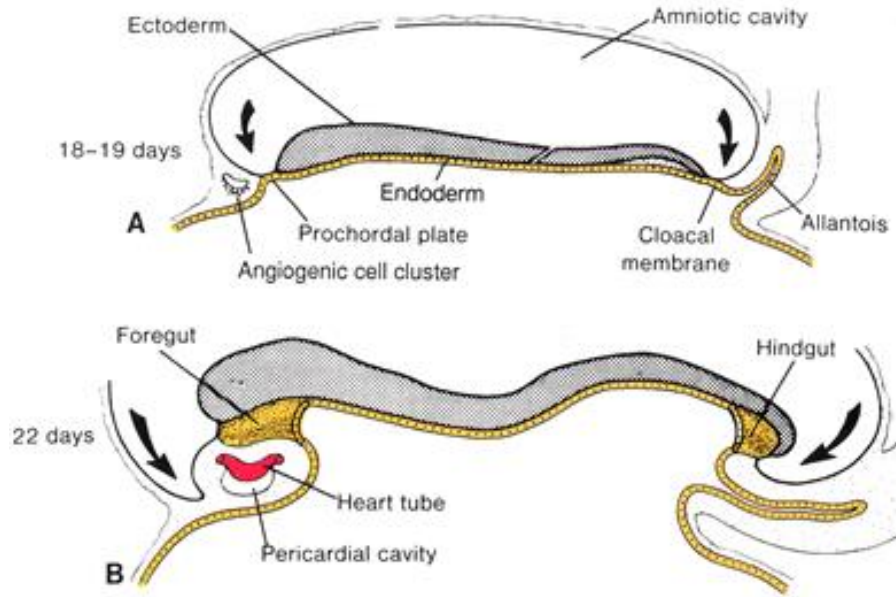


DEVELOPMENT OF GIT

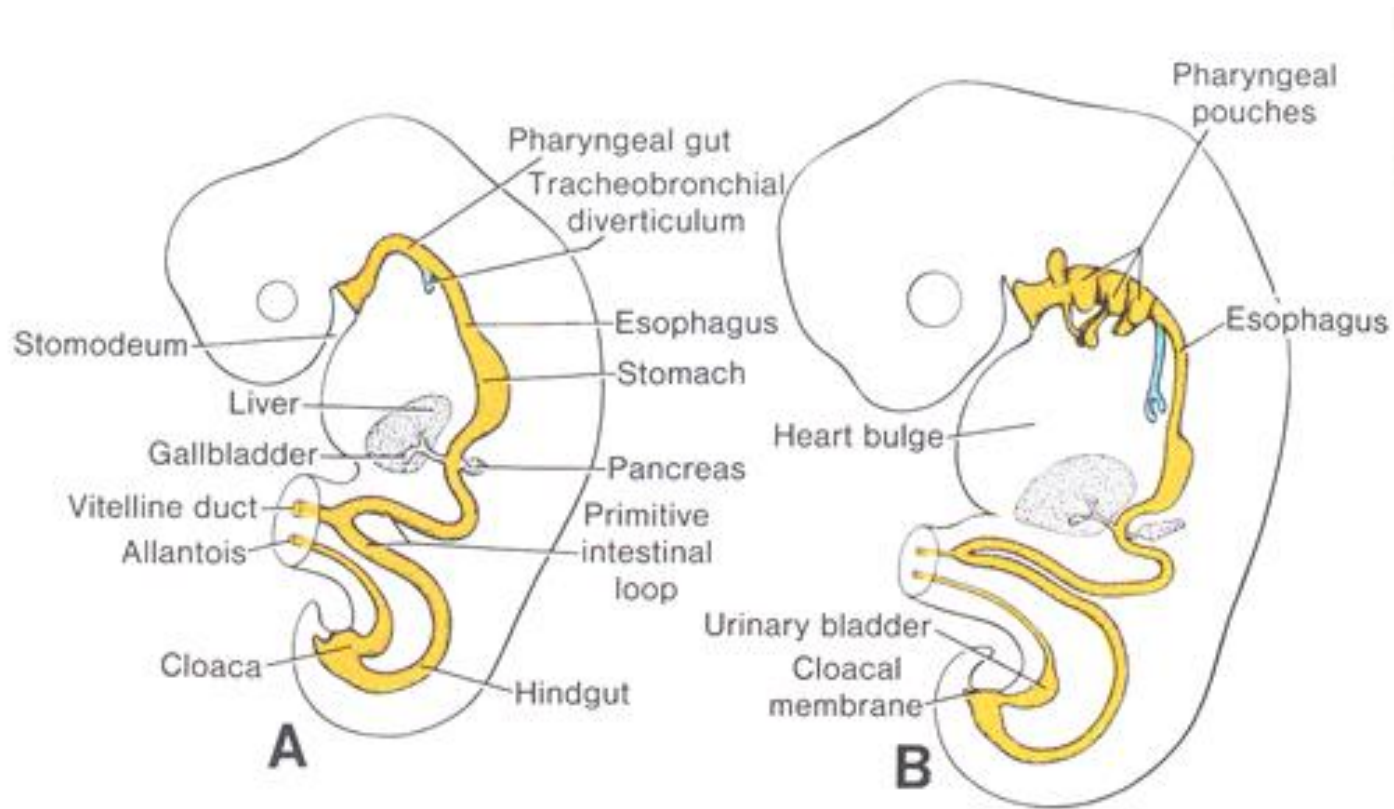
EMBRYONIC DEVELOPMENT 2TH TO 3RD WEEK



EMBRYONIC DEVELOPMENT 3RD TO 4TH WEEK



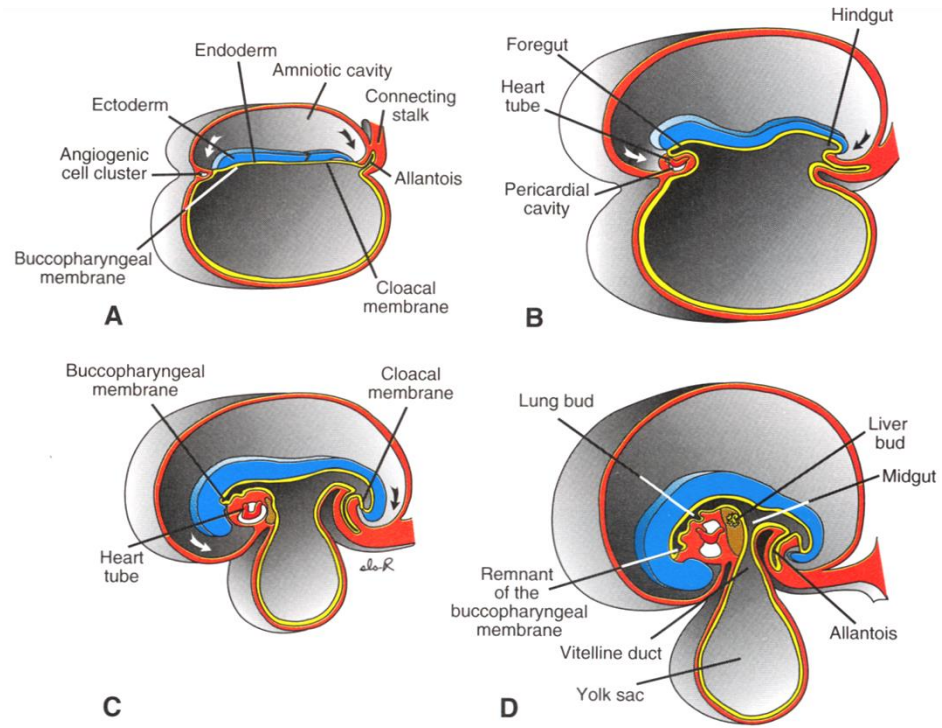
4TH AND 5TH WEEK OF EMBRYONIC DEVELOPMENT



DEVELOPMENT OF PRIMITIVE GUT

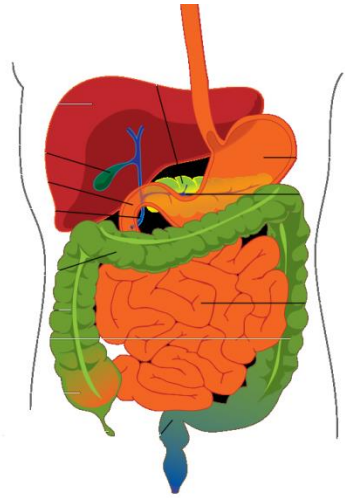
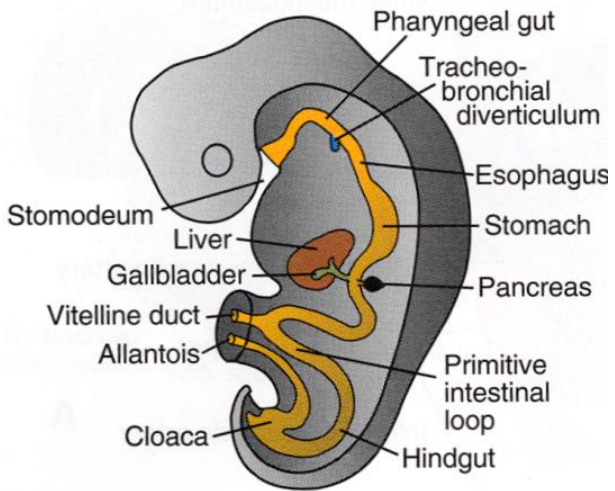
– cephalocaudal and lateral folding in 4th week

– primitive gut from buccopharyngeal membrane to cloacal membrane



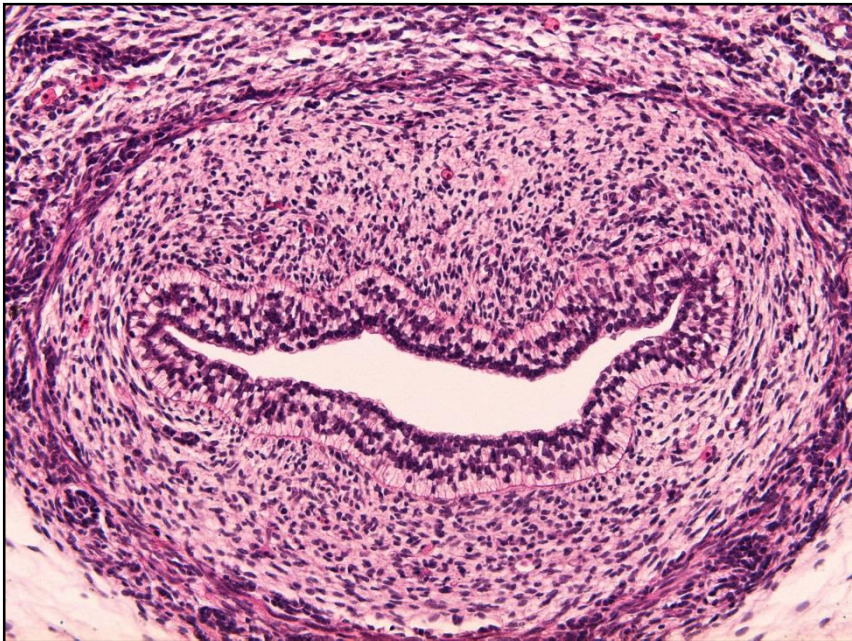
Three regions of primitive gut

- foregut
- midgut
- hindgut

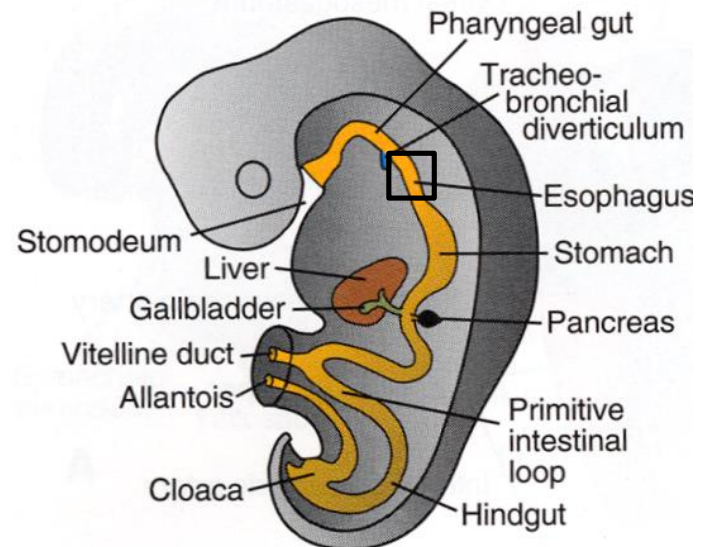


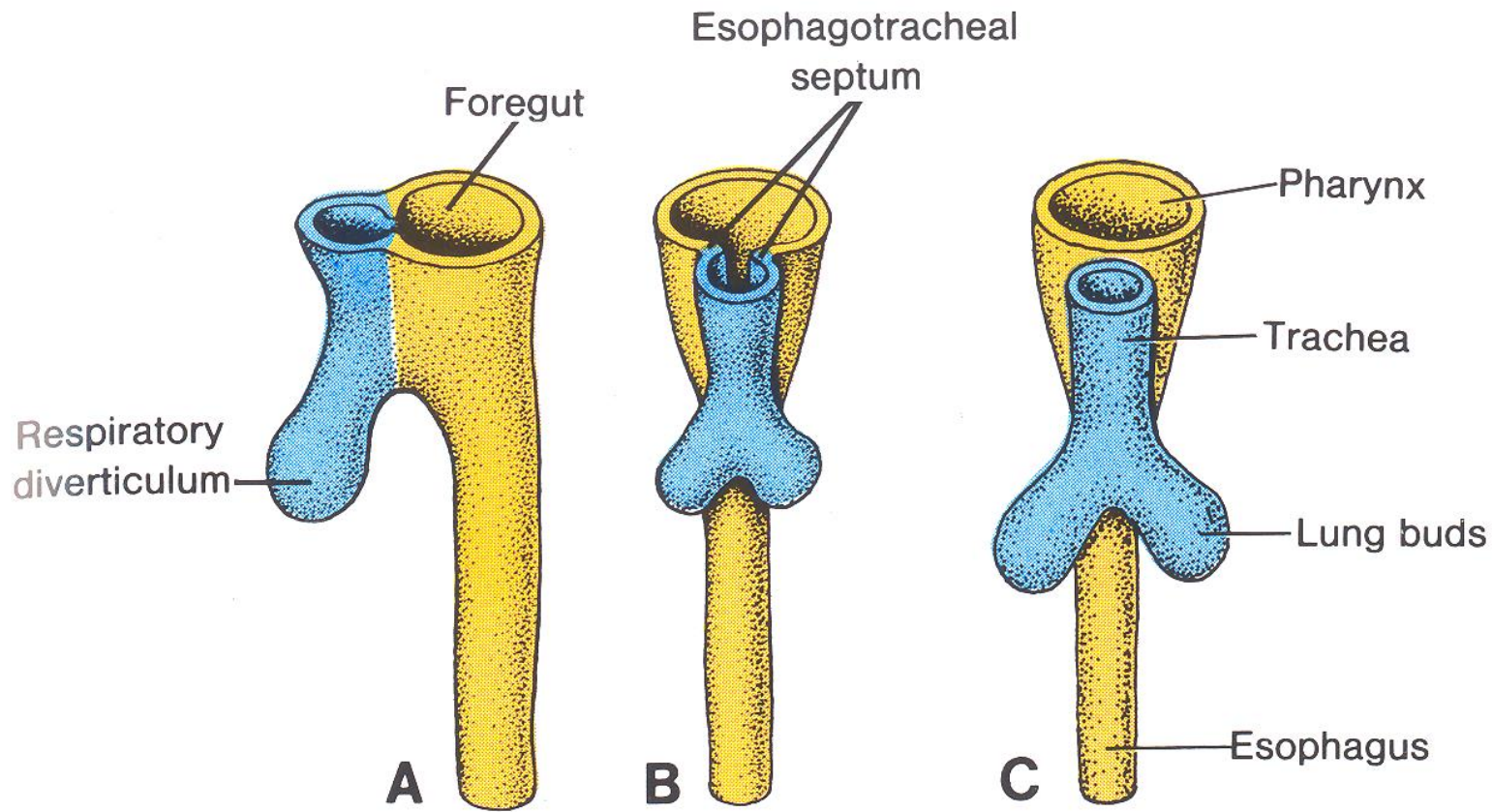
DEVELOPMENT OF ESOPHAGUS

- region of foregut caudal of respiratory diverticulum
- tracheoesophageal septum
- rapid elongation: 7th week - final relative length
- rapid proliferation of endoderm (epithelium and glands) that obliterates lumen – recanalization about 8th week
- connective tissue and muscle tissue – mesenchyme of caudal pharyngeal arches and splanchnic mesenchyme
- innervation by branches of *n. vagus* (caudal pharyngeal arches)

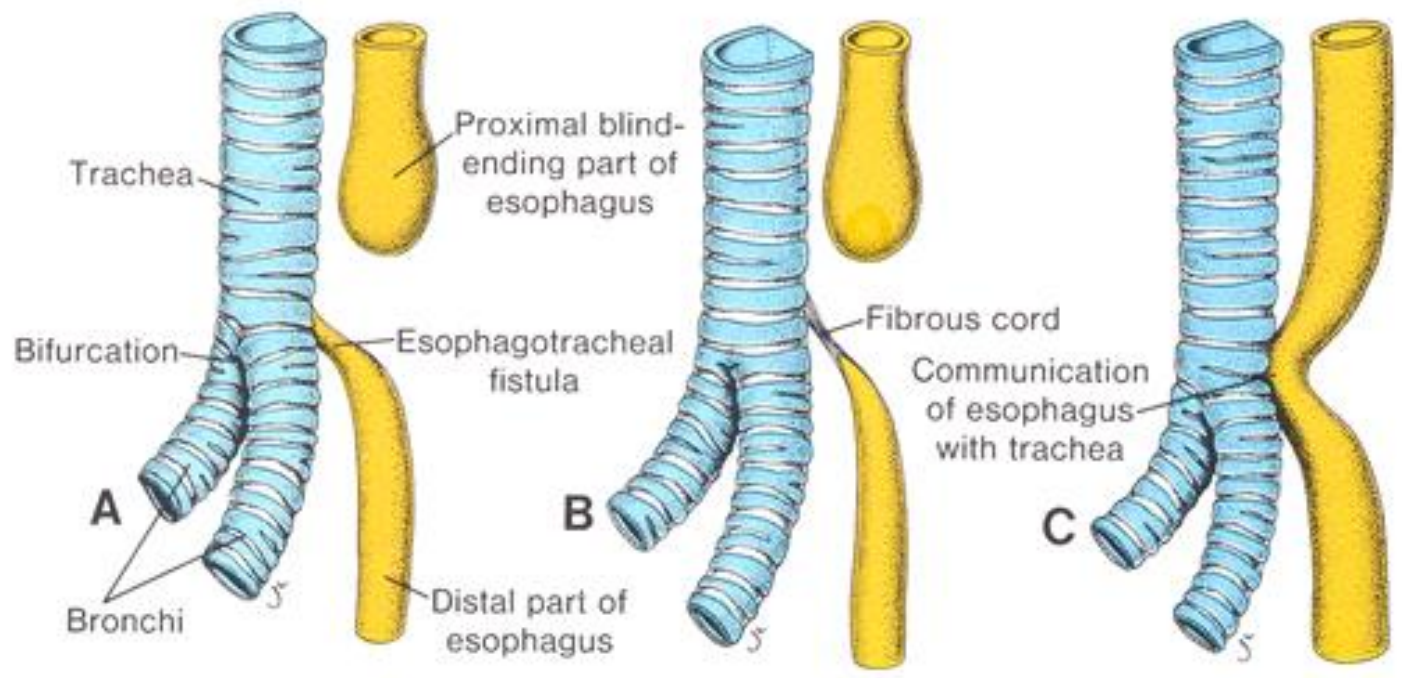


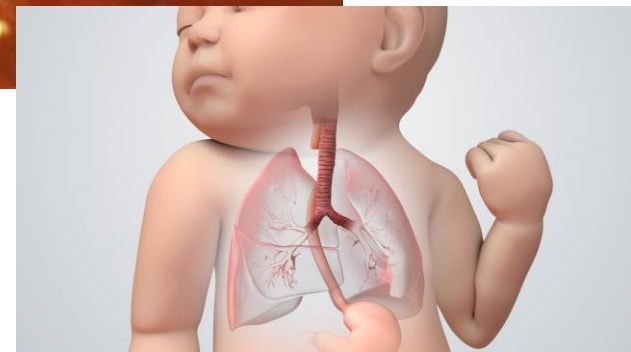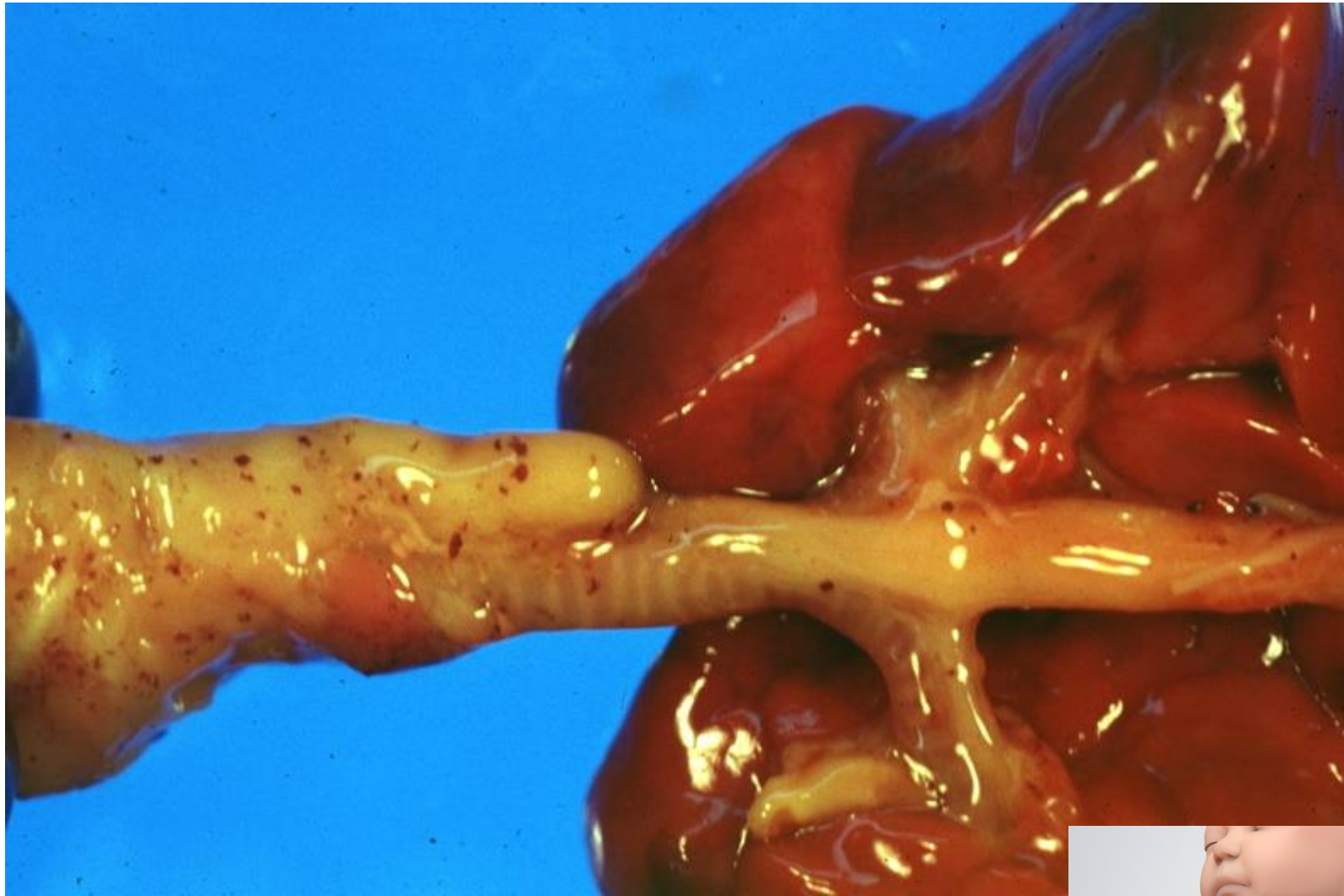
8th week





ABNORMALITIES IN DEVELOPMENT OF ESOPHAGUS

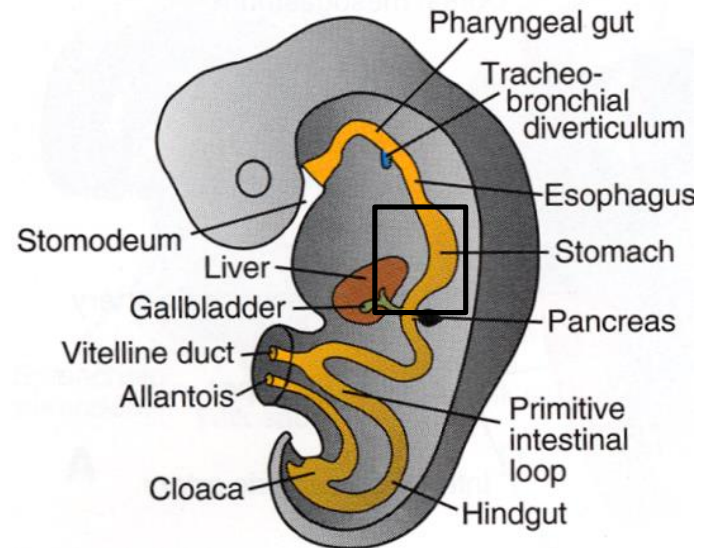
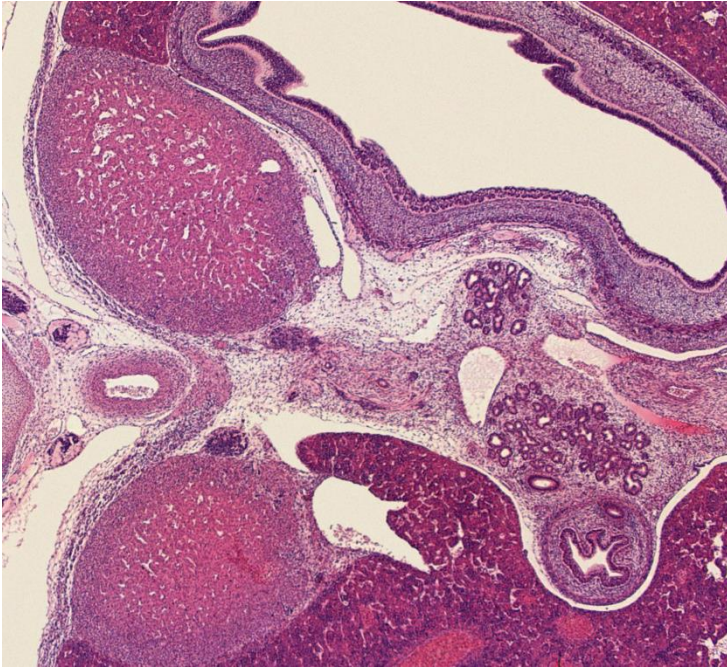




DEVELOPMENT OF STOMACH

- fusiform dilatation of the foregut
- different growth rates in various regions → greater and lesser curvature
- rotation 90° clockwise around longitudinal and anteroposterior axis
- definitive location and shape - 2nd month i.u.

8th week

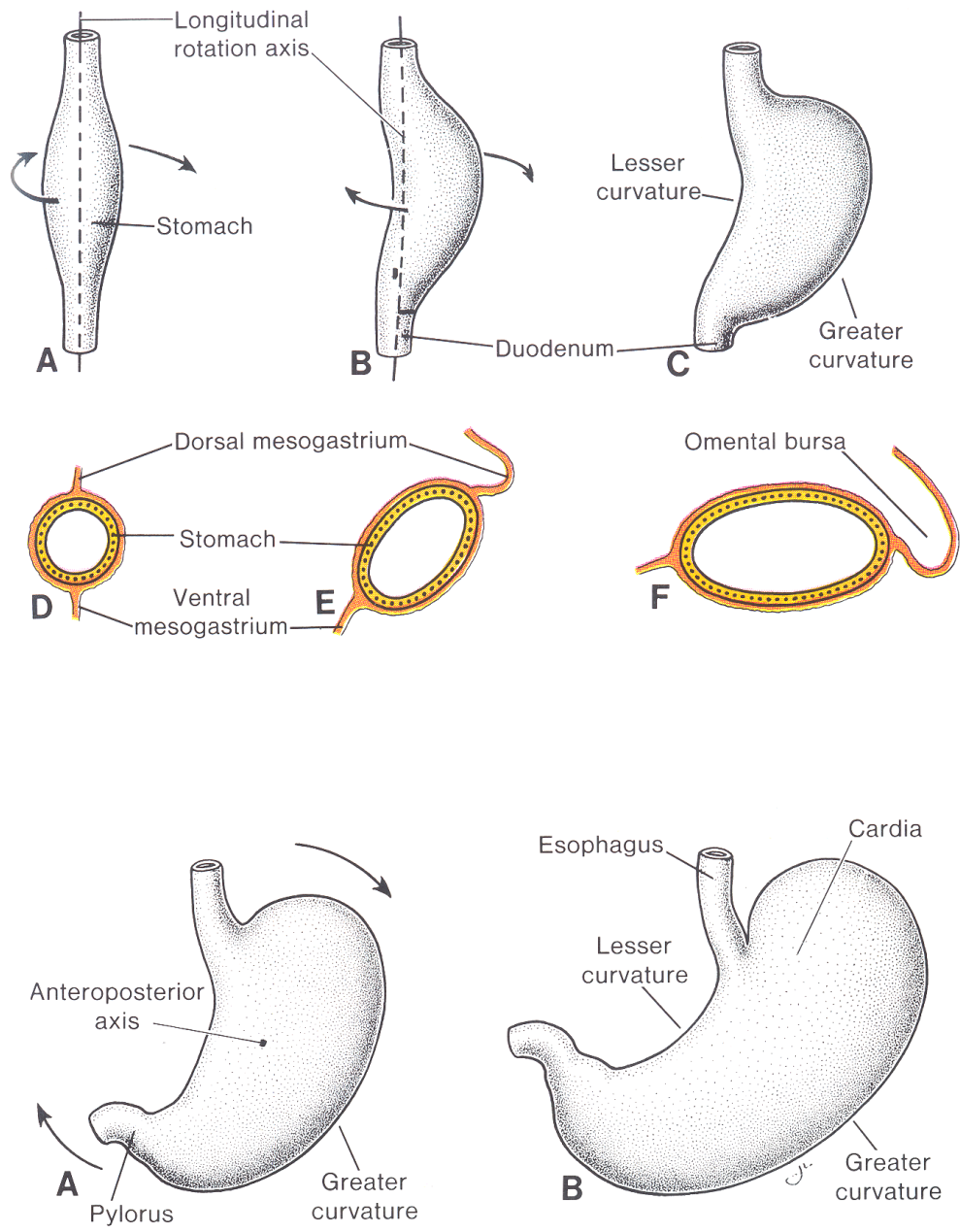


STOMACH ROTATION

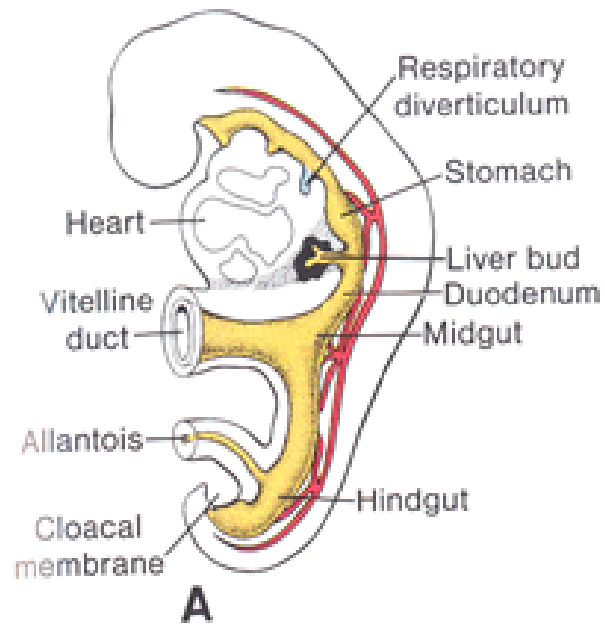
- 90°

ventral lesser curvature → right
 dorsal greater curvature → left
 left side → ventrally
 right side → dorsally
 cranial part → left caudally
 caudal part → right cranially

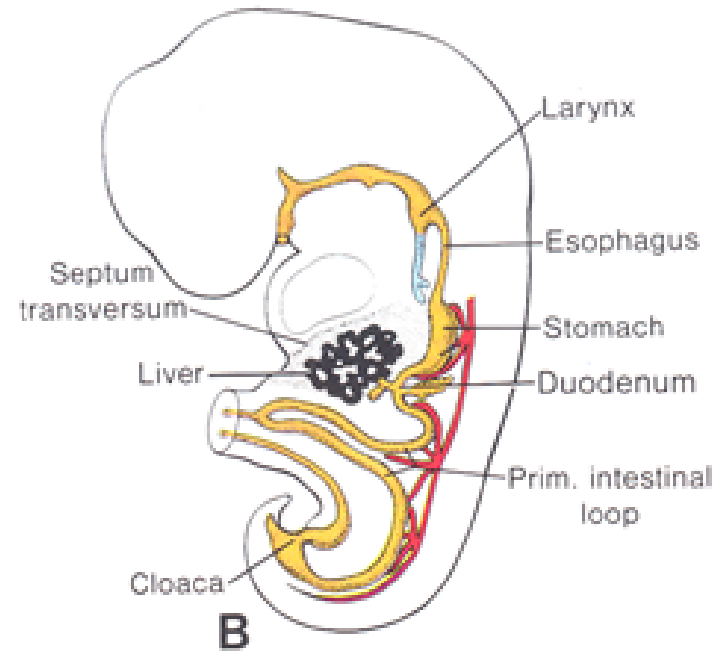
→ definitive anatomical position of
 left and right *nervus vagus*



WEEK cca 4th



5th



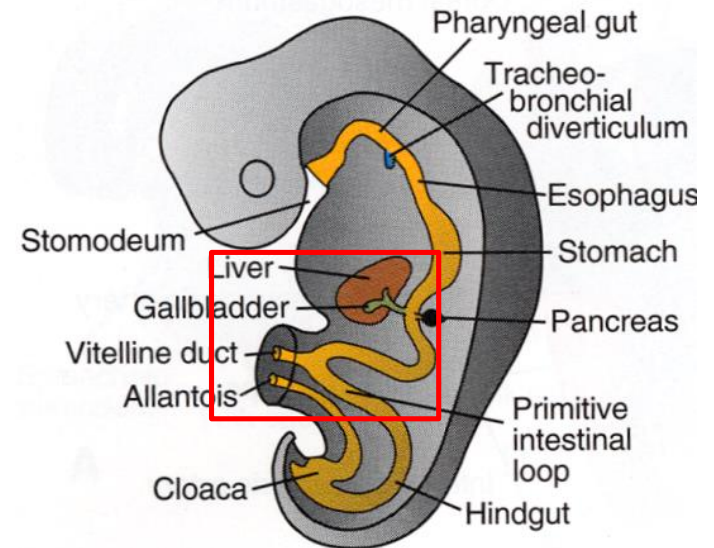
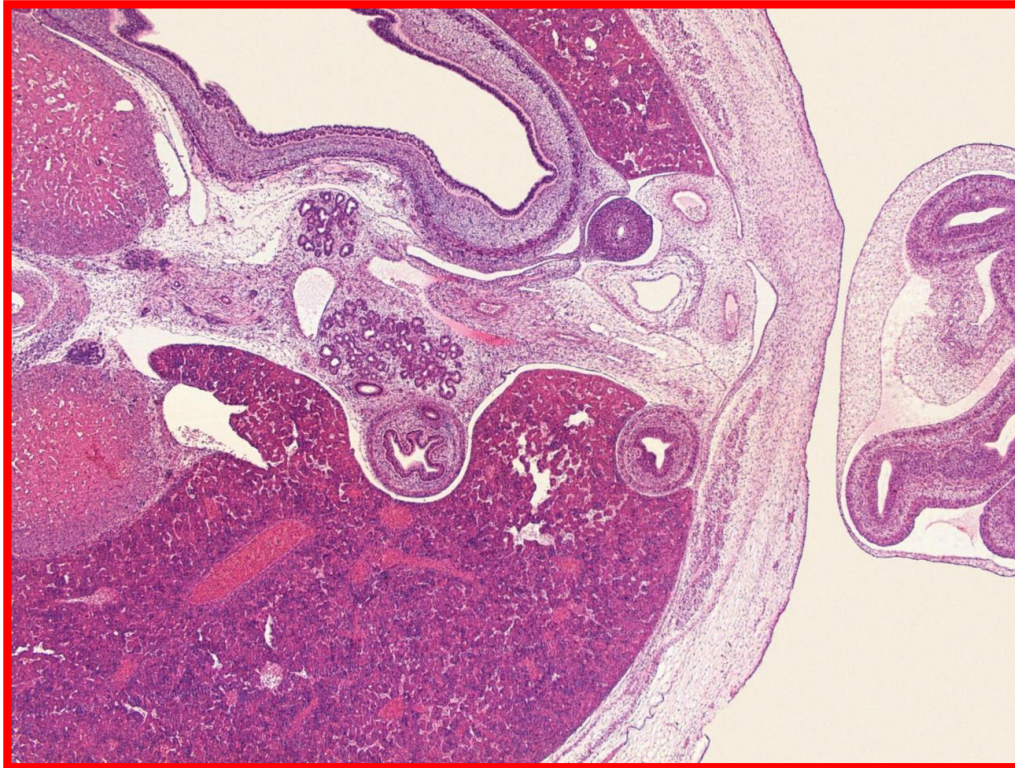
EMBRYO SIZE 3 mm

5 mm

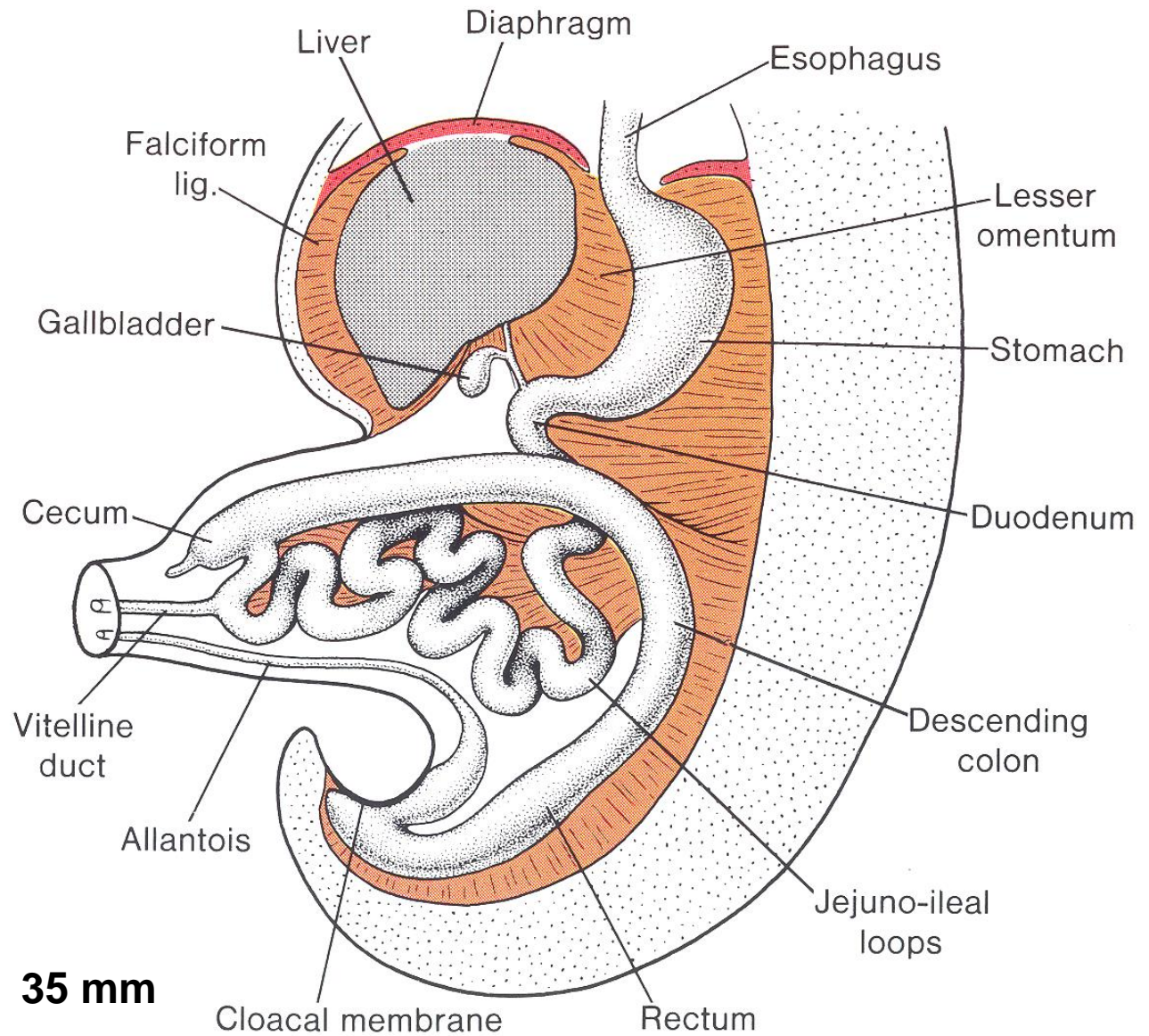
DEVELOPMENT OF INTESTINE

- midgut – primary intestinal loop
- rotation during development
- physiological umbilical herniation

8th week

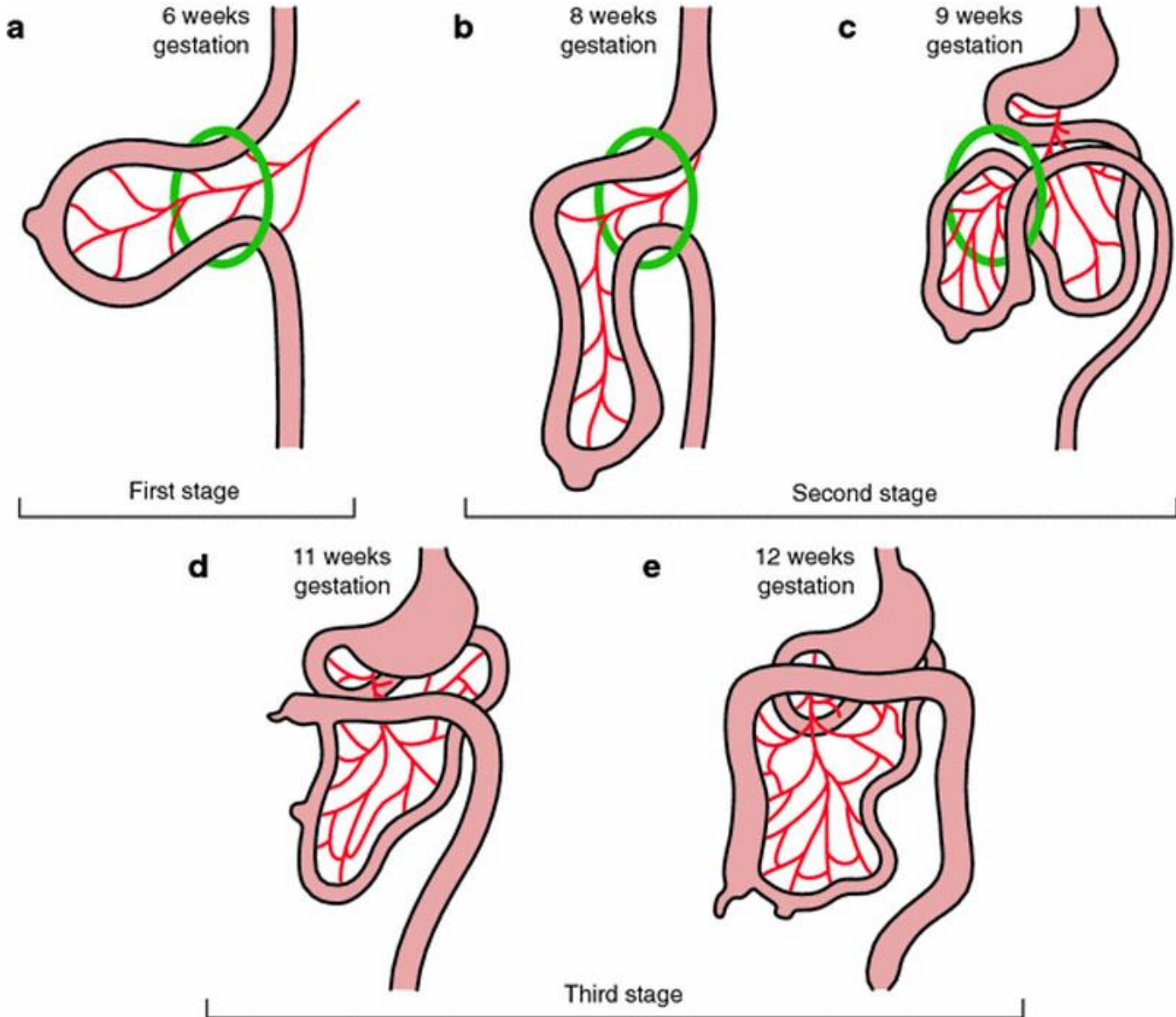


WEEK: late 8th

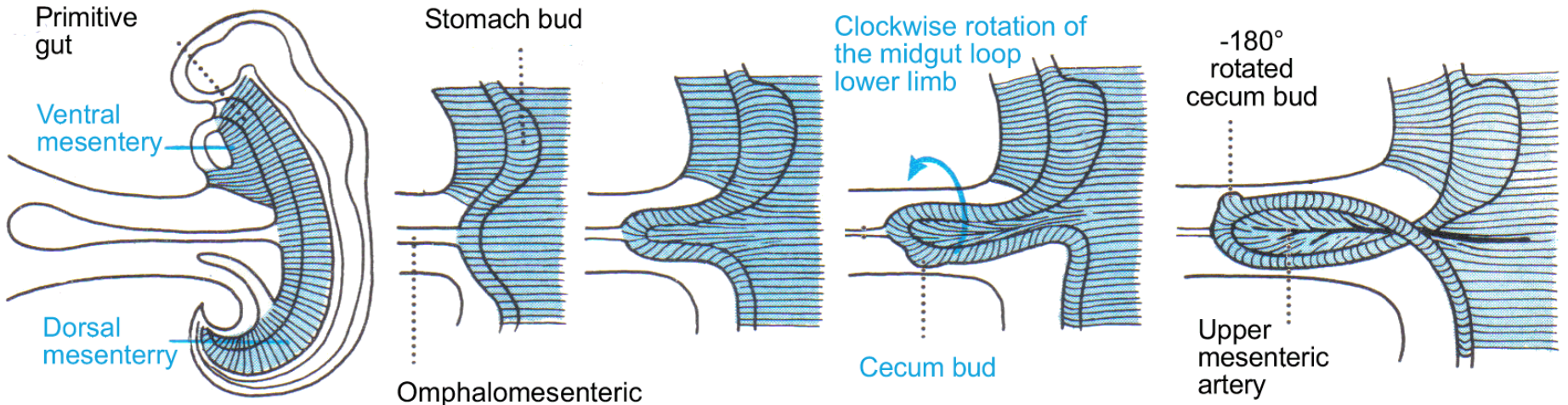


EMBRYO SIZE 35 mm

INTESTINAL ROTATION

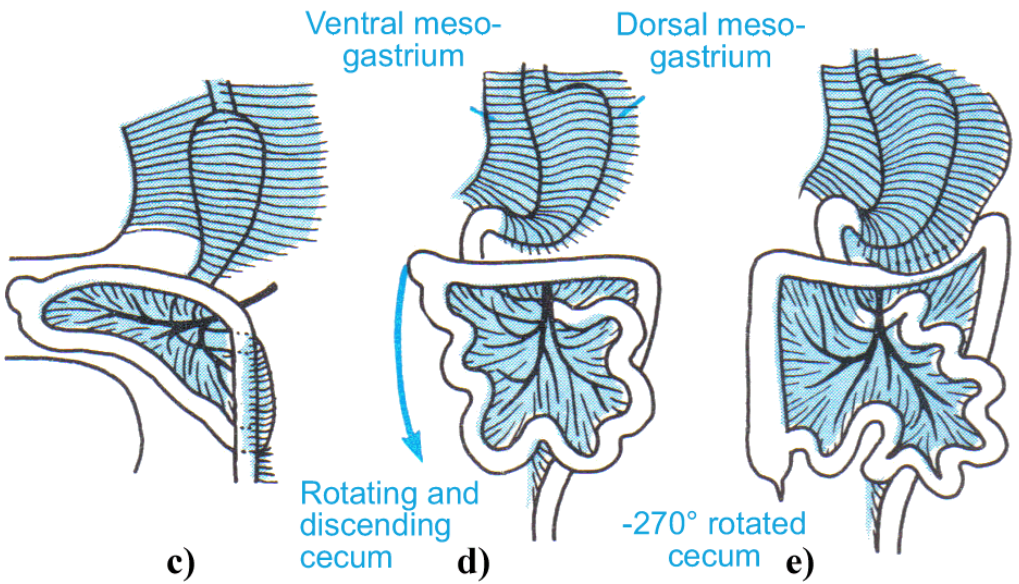


INTESTINAL ROTATION AND ROTATION OF MESENTERIES



a)

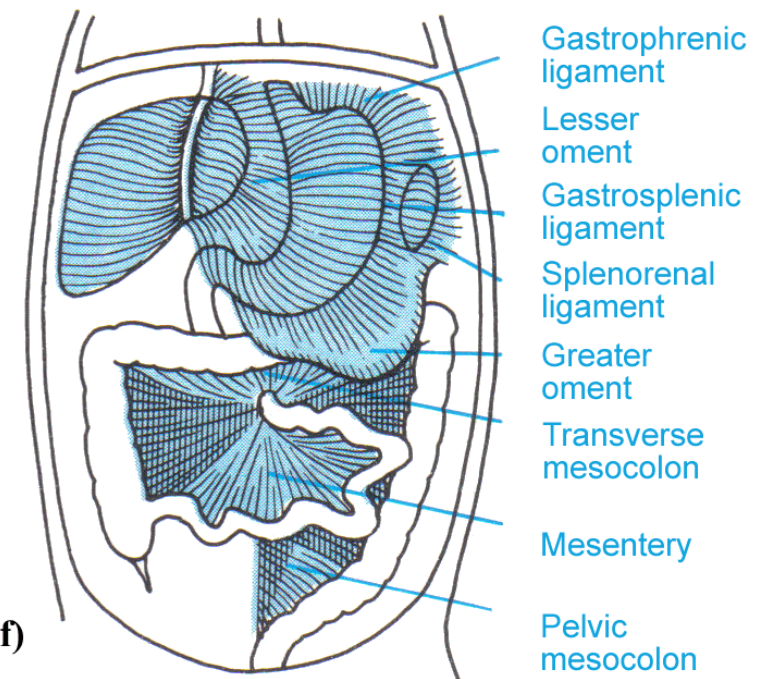
b)



c)

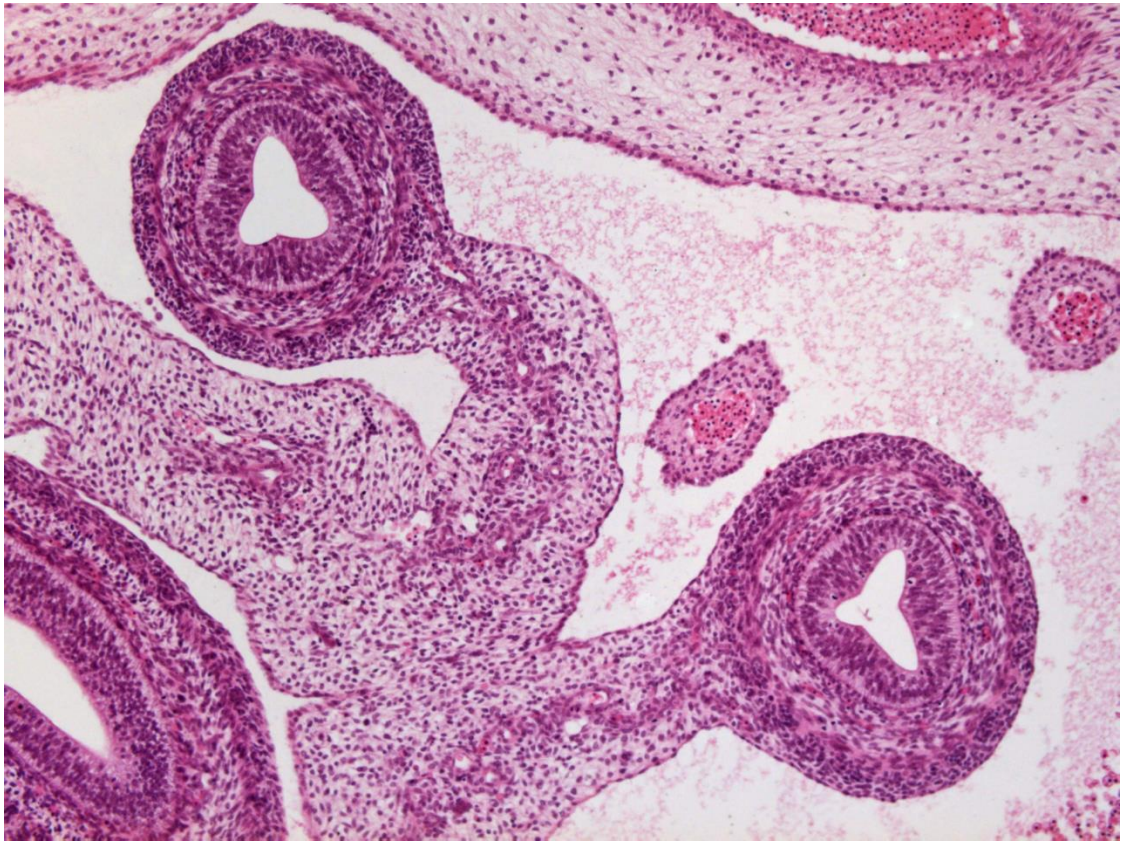
d)

e)



f)

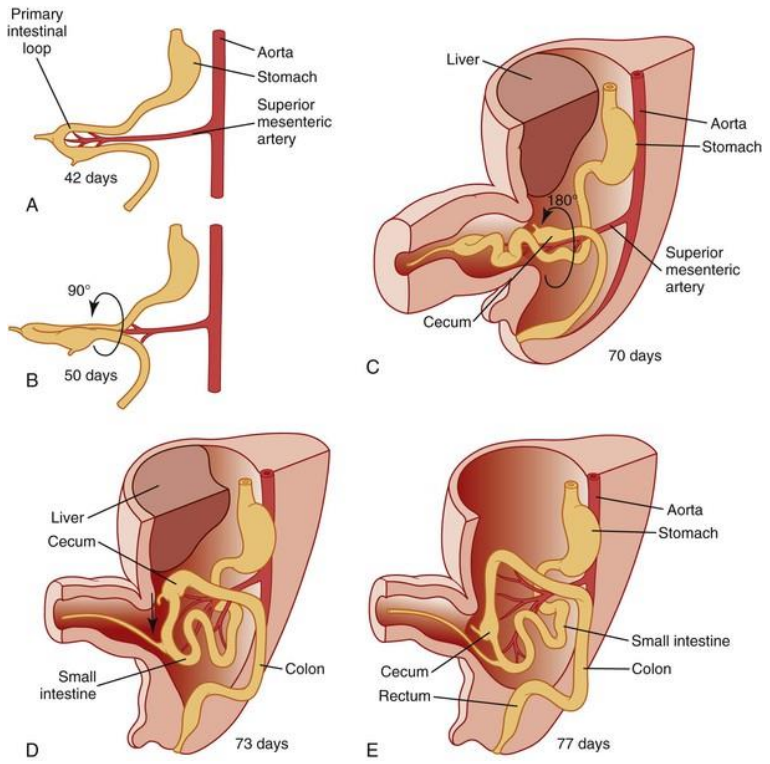
INTESTINAL ROTATION AND UMBILICAL HERNIA



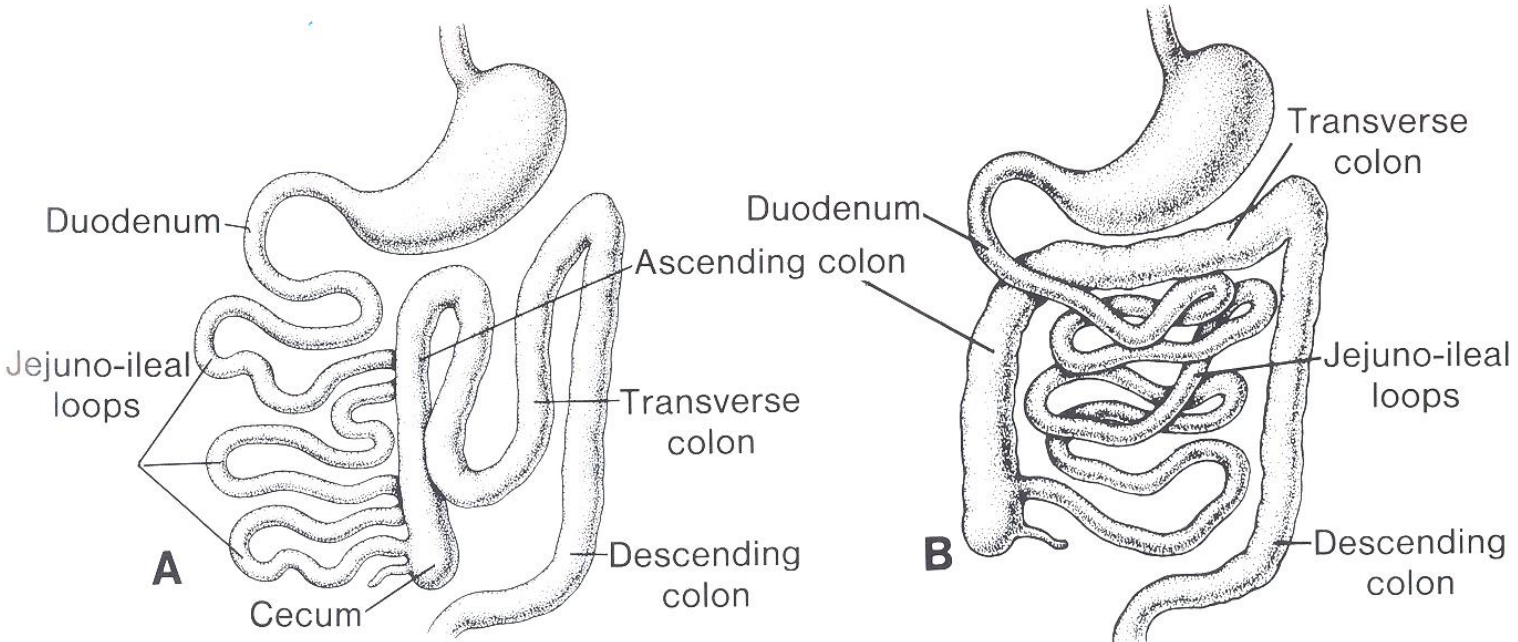
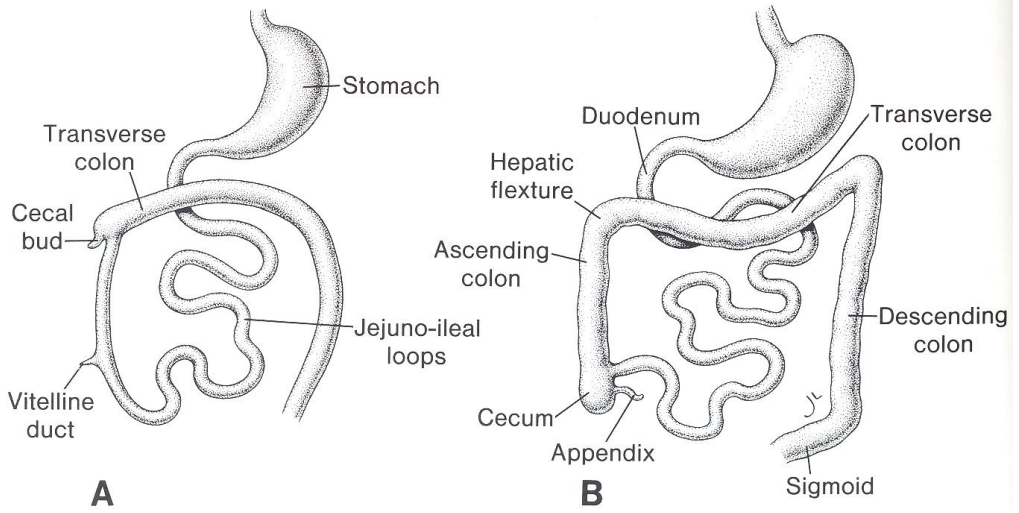
- 8th week
- Normal reposition in 10th week

Abnormalities:

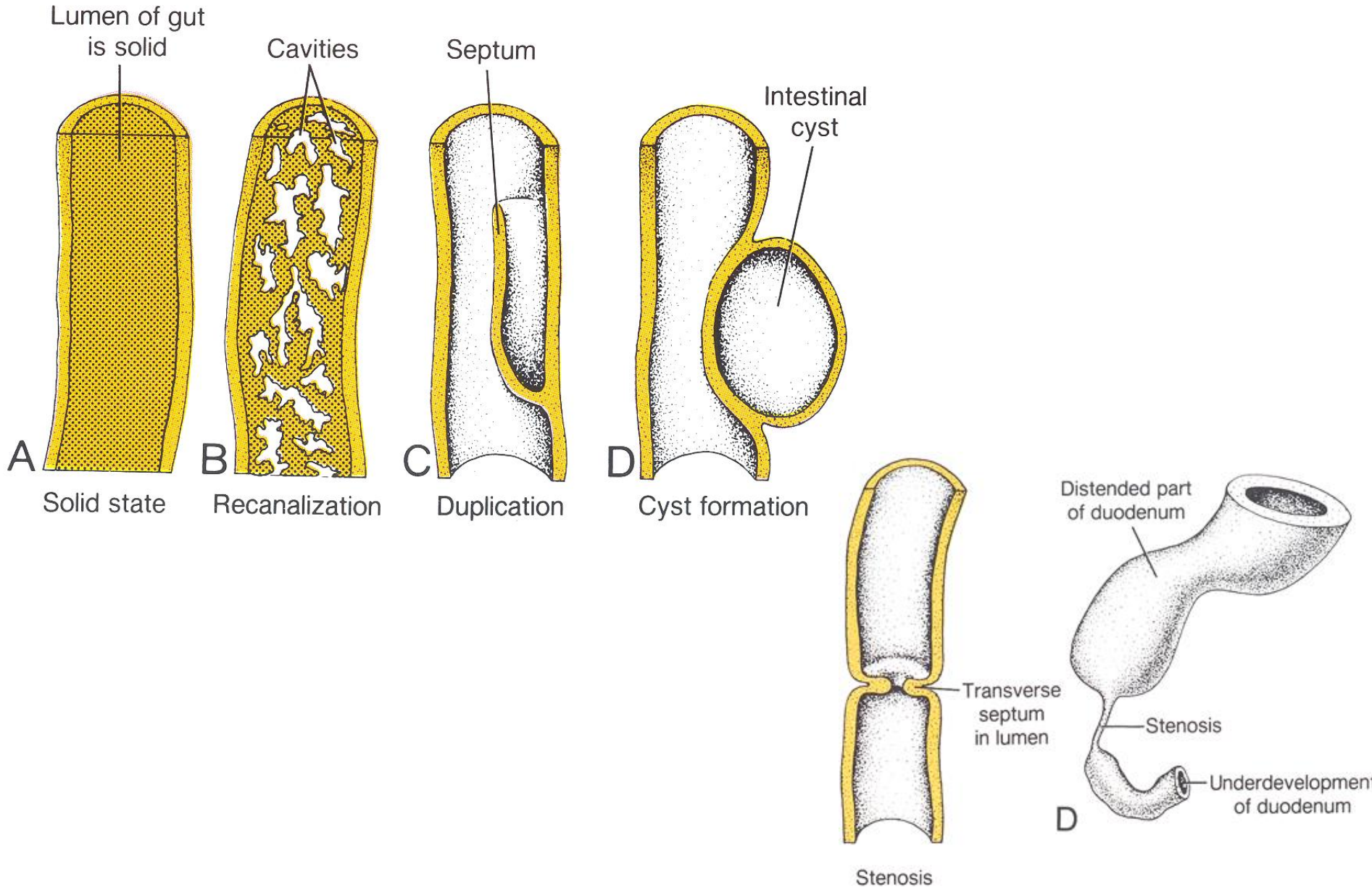
- Incomplete closure of umbilicus
- Including omentum majus and small intestine, skin and connective tissue
- Develops after birth, spontaneous reposition possible (X gastroschisis)



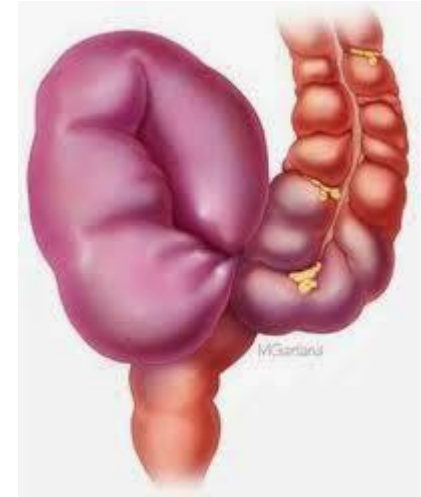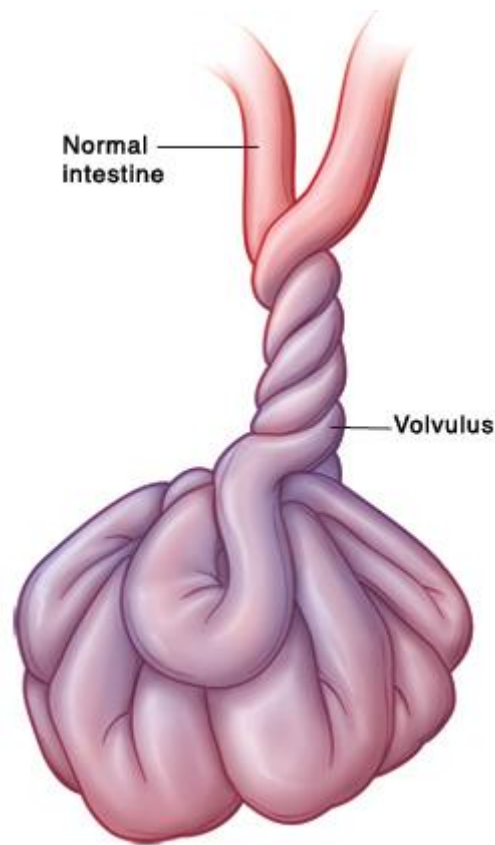
ABNORMAL INTESITINAL ROTATION



ILEUM DEVELOPMENT AND ABNORMALITIES

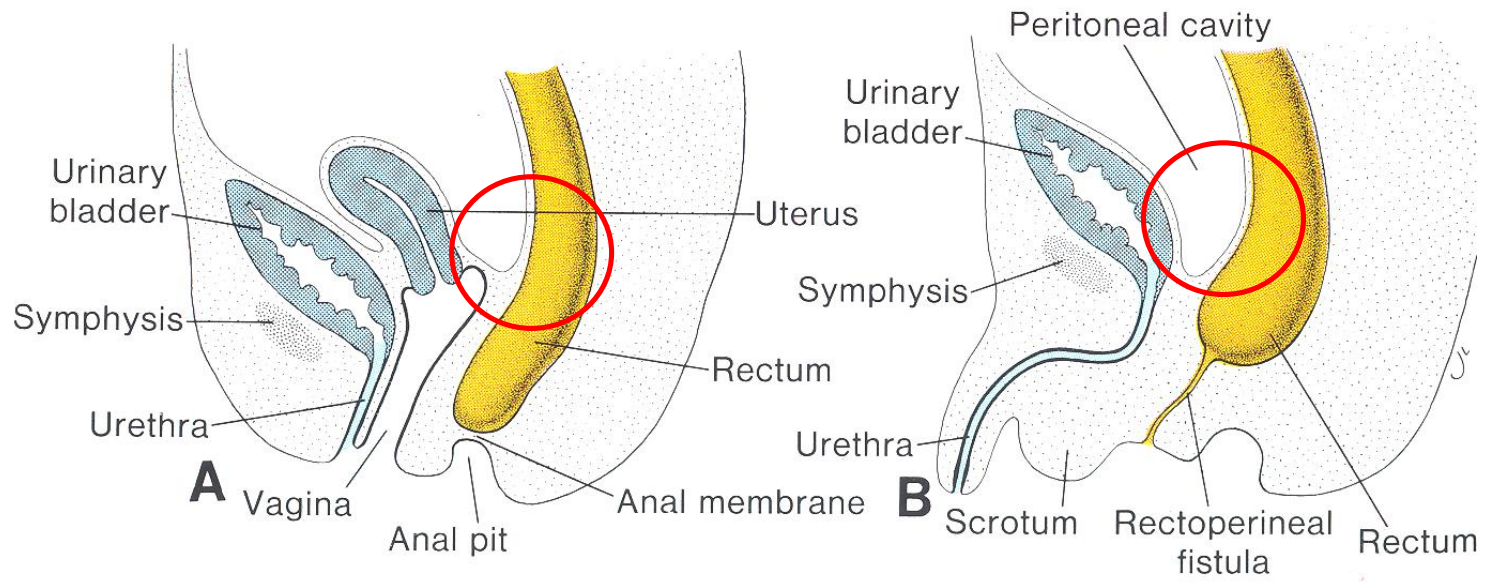
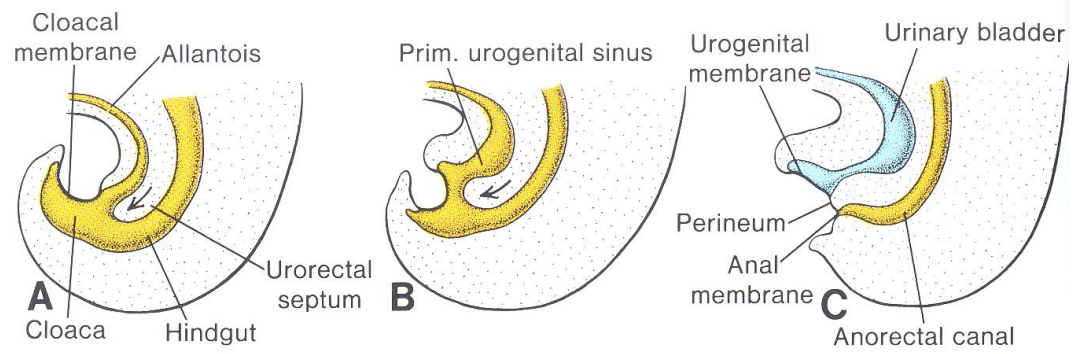


VOLVULUS

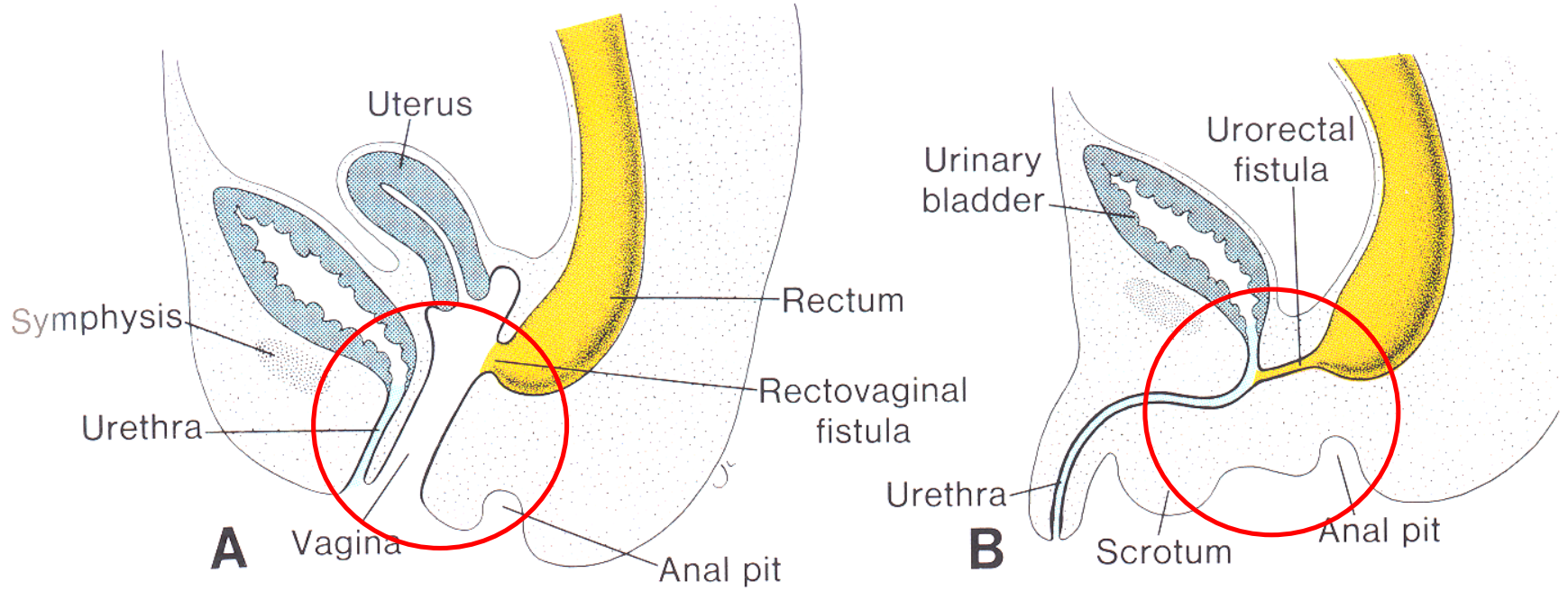


- malrotation of midgut and left colon (obstruction of a. mesenterica sup. and duodenum)
- reversed rotation (obstruction of colon)
- abnormal adhesion of caecum to liver (subhepatic caecu) - abnormal position of appendix
- caecum mobile

ANUS DEVELOPMENT AND ITS ABNORMALITIES

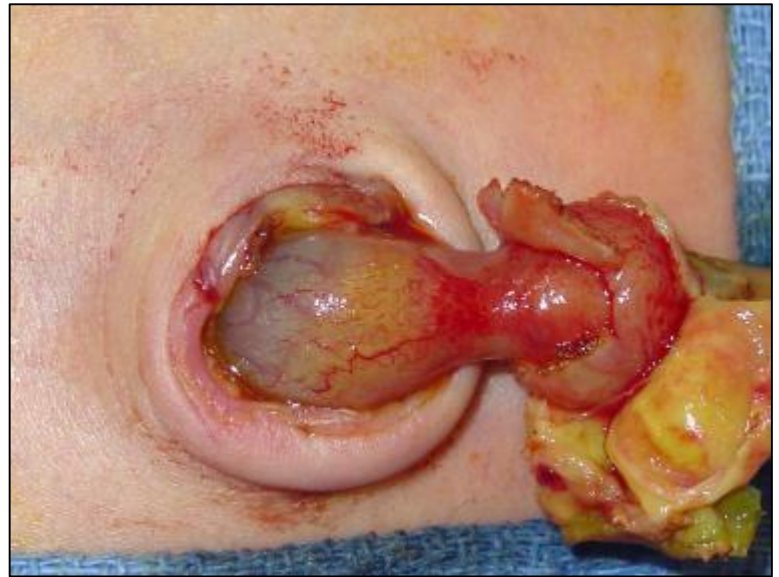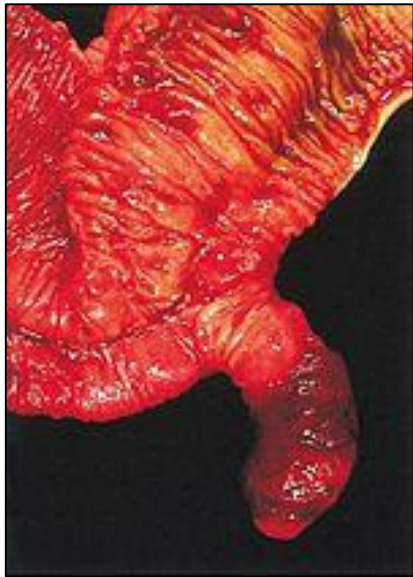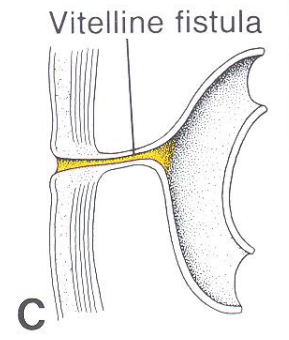
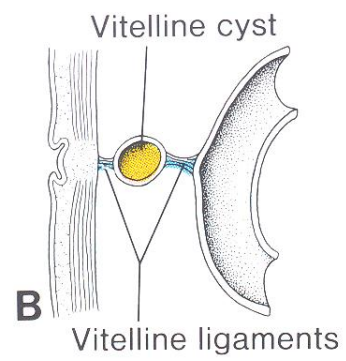
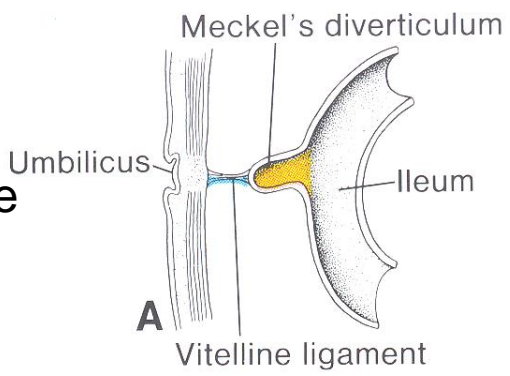


ANUS DEVELOPMENT AND ITS ABNORMALITIES



DIVERTICULUM MECKELI

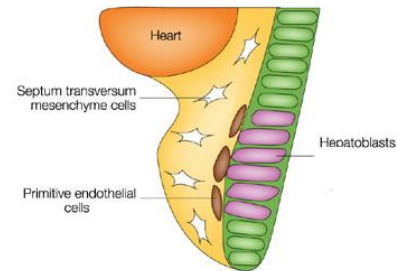
- often phenomenon (2-4%)
- clinically relevant
- vitelline cysts
- volvulus of diverticle



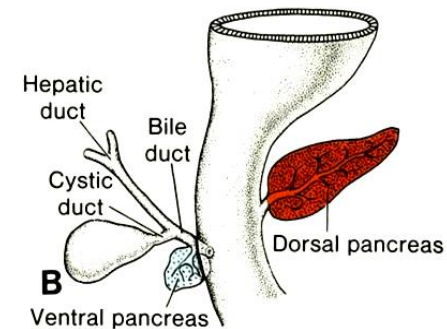
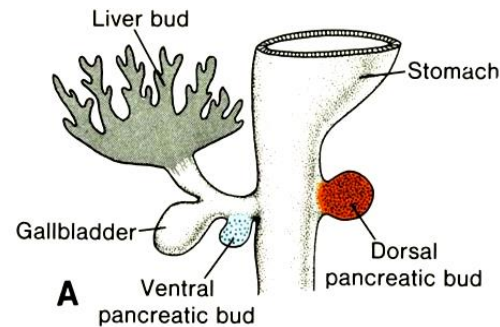
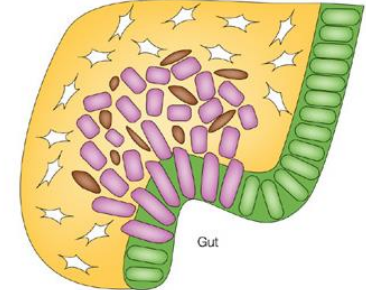
EMBRYONIC DEVELOPMENT OF LIVER

- Diverticulum of embryonic duodenum - **liver diverticulum**
- **Pars hepatica** (parenchyma + ductus hepaticus) and **pars cystica** (ductus cysticus + gall bladder) form d. choledochus
- Rapidly proliferating cells penetrate septum transversum (mesodermal plate between pericardial cavity and yolk sac) and growth into ventral mesentery
- liver cords – parenchyma
- Interactions between cells of liver cords and vv. omphalomesentericae induce development **liver sinusoids**
- C.t. , Kupffer and hematopoietic cells – from mesoderm of septum transversum
- Surface mesoderm differentiate into visceral peritoneum

a Post-specification
11-13-somite stage

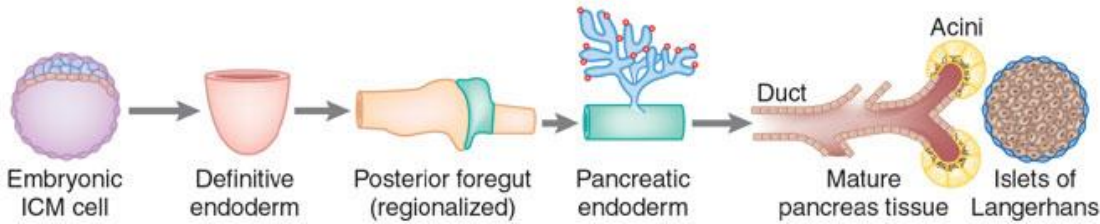


b Liver-bud stage
18-25-somite stage

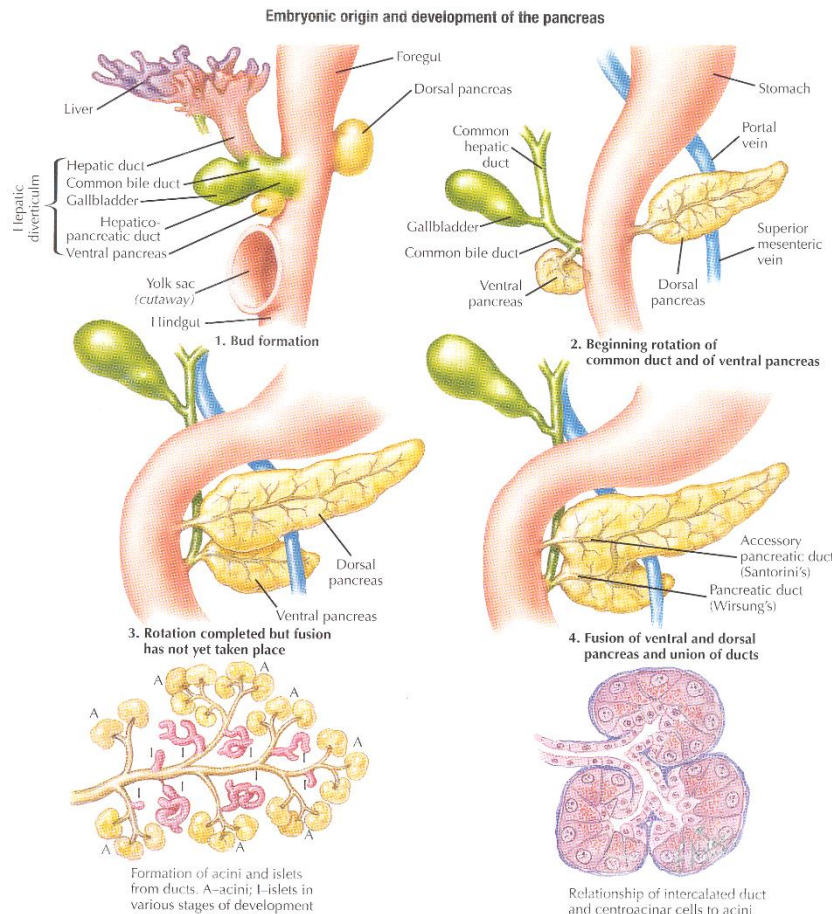


- 10th week
 - 10% of body volume
 - hematopoiesis
- 12th week
 - bile production

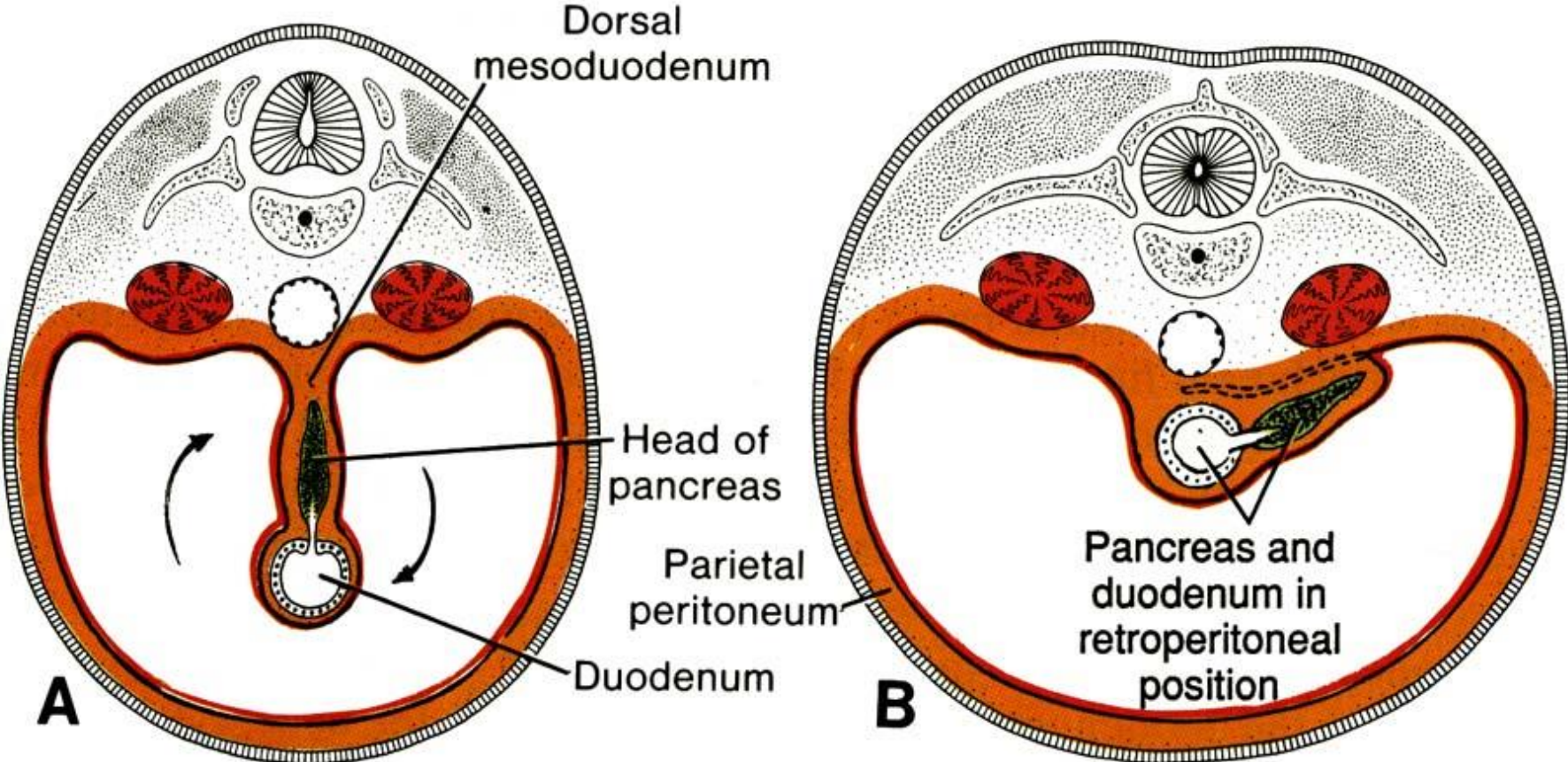
EMBRYONIC DEVELOPMENT OF PANCREAS



- 6th week of development
- two endodermal diverticles
- dorsal and ventral duodenal diverticle (= pancreas dorsale et ventrale)
- after rotation of duodenal loop both diverticula fuse
- ducts persist (ventral - major and dorsal - accessorius)
- ductal system develops first, secretory acini follow
- cells that are not part of ductal structures differentiate into Islets of Langerhans
- since 4th month in utero - secretory activity



EMBRYONIC DEVELOPMENT OF PANCREAS



Summary of GIT II

- Microscopic anatomy of liver: endocrine and exocrine function of liver, vascularization, liver lobulus and its definition, liver cells, ultrastructure and function of hepatocytes, organization of intra- and extra-hepatic passages
- Microscopic anatomy of pancreas: endocrine and exocrine function, pancreatic acinus and its ducts, ultrastructure and function of acinar cells, Islets of Langerhans and their structure, cell types of Islet of Langerhans and their function
- Embryonic development and morphogenesis of digestive tube, liver and pancreas, primitive gut and its derivatives, esophagus, stomach, intestine. Flexion of embryo and rotation, liver and pancreatic diverticulum, differentiation of individual cell types.

Thank you for attention

Petr Vaňhara, PhD
Ústav histologie a embryologie LF MU

pvanhara@med.muni.cz
<http://www.med.muni.cz/histology>