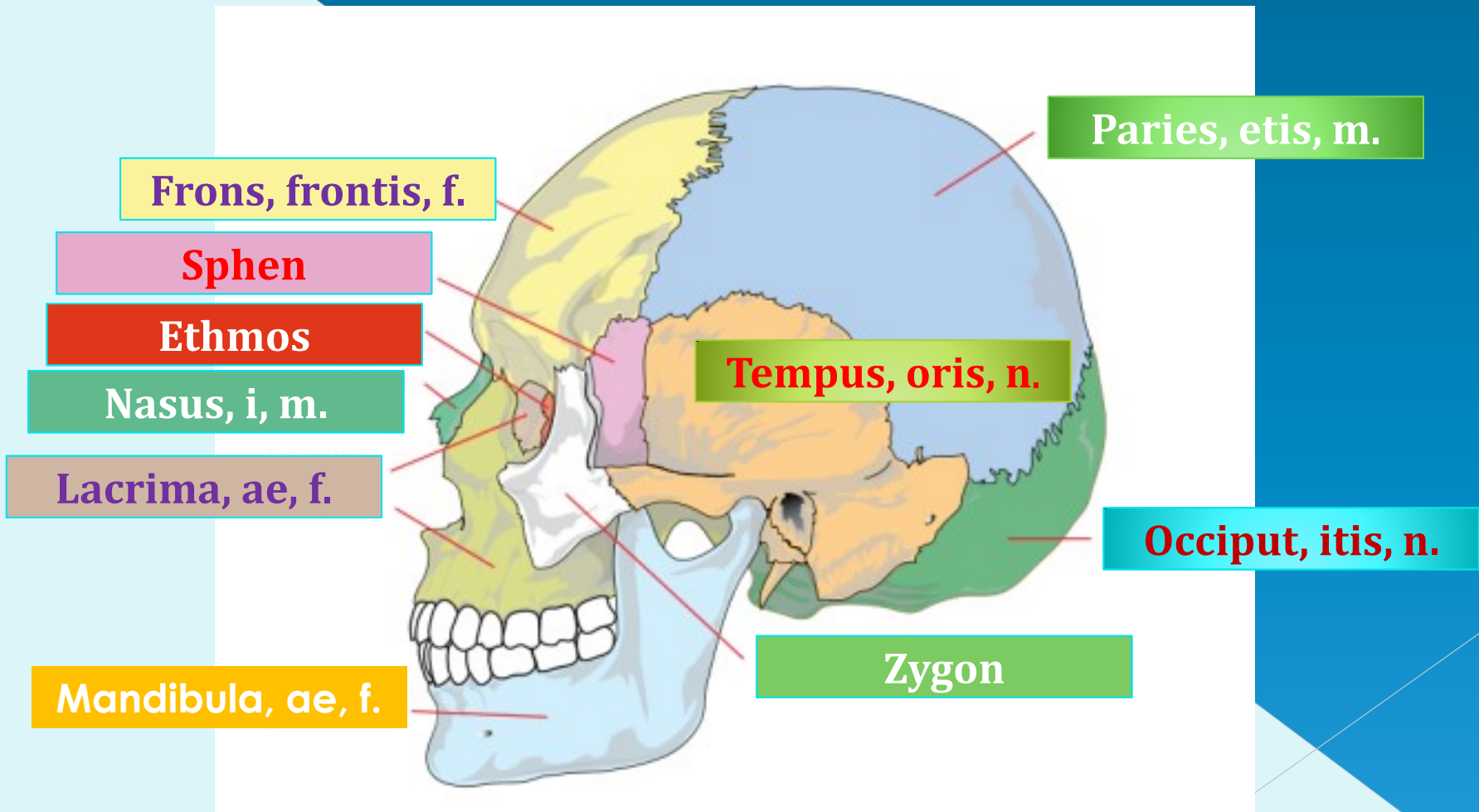


Name bones of skull, use nouns as hints



Name types of permanent teeth

4

3

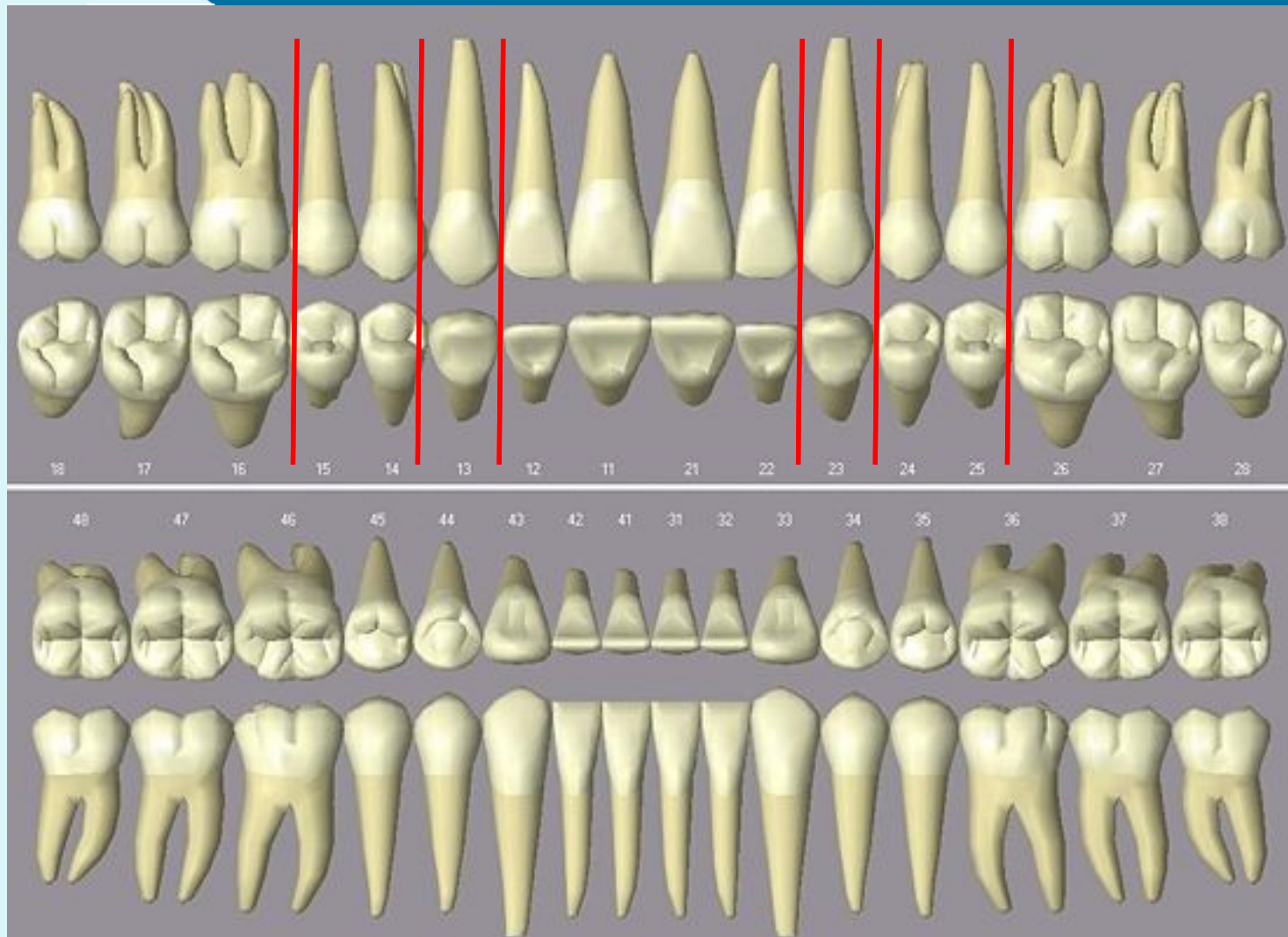
2

1

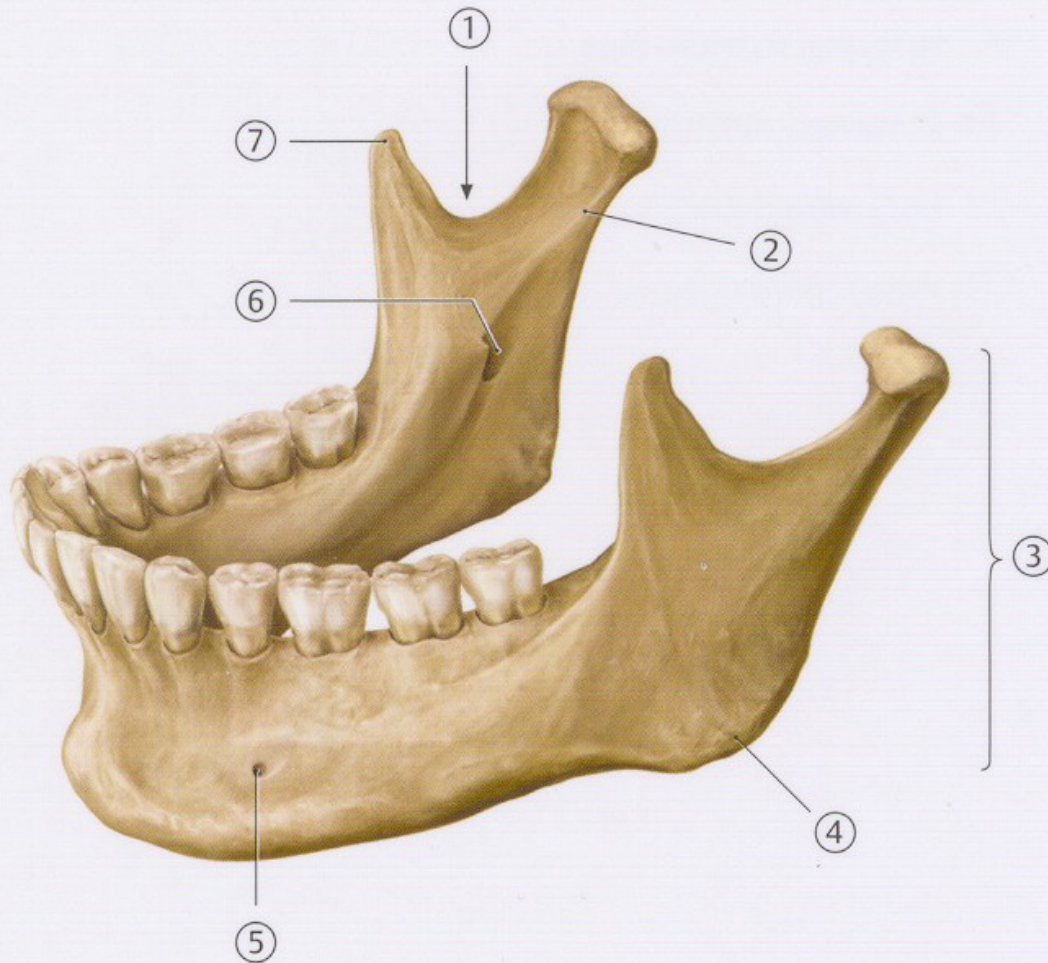
2

3

4

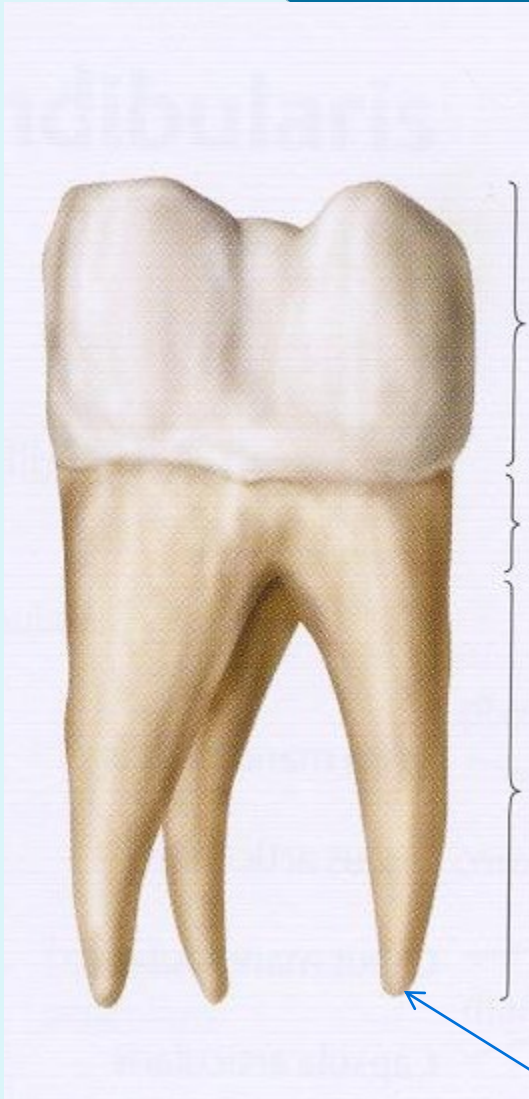


Name the main parts of the lower jaw



1. The notch of lower jaw
2. Processus condylaris
3. Process that projects superiorly to the upper jaw:
r _____ m _____
4. Angle between the body and the process of the upper jaw:
a _____ m _____
5. opening for the mental nerve:
f _____ mentale
6. Opening on the inner aspect of the process of lower jaw:
f _____ m _____
7. Coronoid process?

Name the main parts of the tooth



A C _ _ _ _ _ d _ _ _ _ _

B C _ _ _ _ _ d _ _ _ _ _ =
C _ _ _ _ _ d _ _ _ _ _

C R _ _ _ _ _ d _ _ _ _ _

D A _ _ _ _ _ r _ _ _ _ _ d _ _ _ _ _

Name the parts of tooth as seen in the longitudinal section

the extremely hard substance surrounding the crown of tooth?

D E _____ = s _____ a _____

predominant mass of tooth?

E D _____ = s _____ e _____

pulp cavity of tooth?

F C _____ d _____

gingival margin?

G M _____ gingivalis

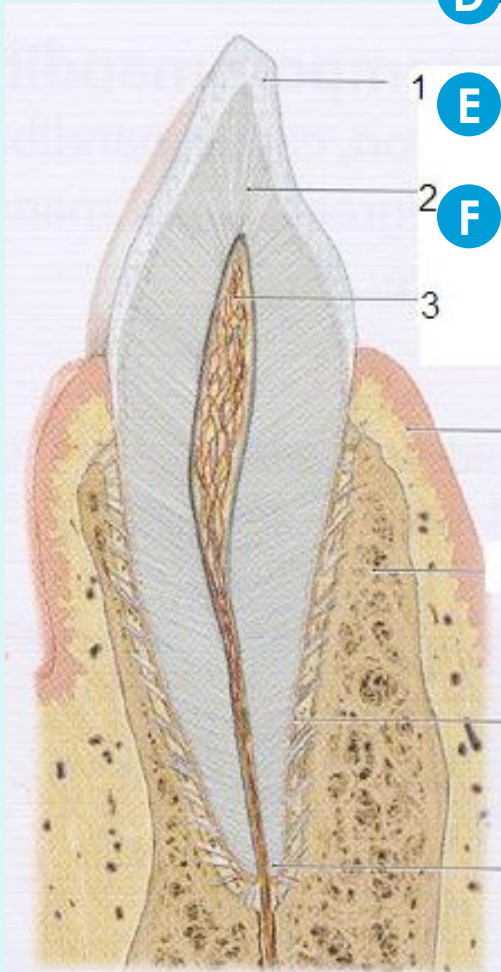
H Alveolus dentalis

substance similar to bone surrounding the tooth?

I C _____ = s _____ o _____

canal between the pulp cavity and the apical foramen?

J C _____ r _____ d _____



Create stomatosurgical diagnoses

Fractura
Laceratio
Luxatio
Vulnus

alveolus
caput mandibulae
gingiva
enamelum
radix
corona
corpus mandibulae
labium

contusolacer, a, um
complicatus, a, um
traumaticus, a, um

Translate types of tooth fractures : ICD S 02.50-54

Fracture of
tooth
enamel

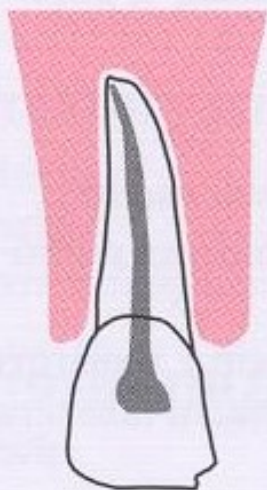
Simple
fracture of
the tooth
crown not
penetrating
to the
dental pulp

Complicated
fracture of
the tooth
crown
penetrating
to the dental
pulp

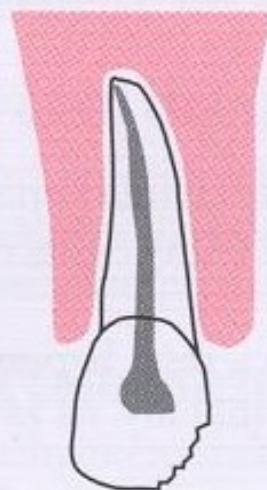
Fracture of
the tooth
root

Fracture of
the tooth
crown and
tooth root

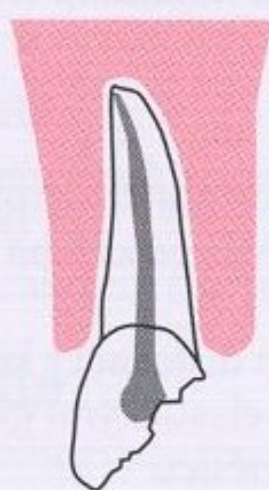
S02.50



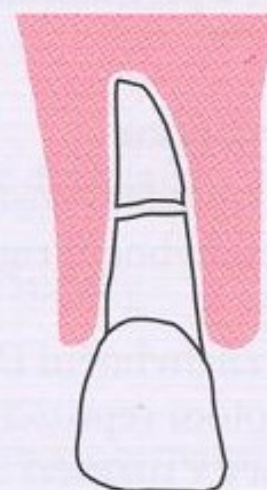
S02.51



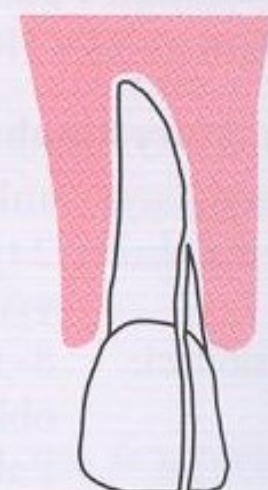
S02.52



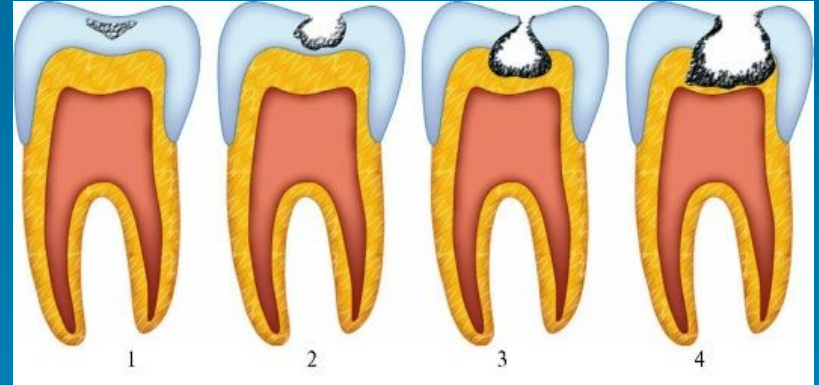
S02.53



S02.54

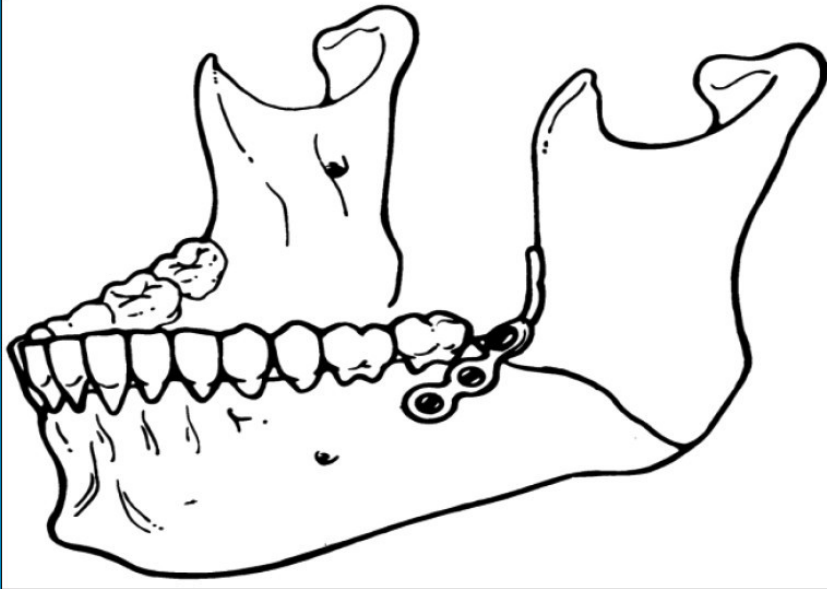


- 1) Number types of tooth decay based on its severity, start from the simplest
- 2) Identify all adjectives, which declension are they?



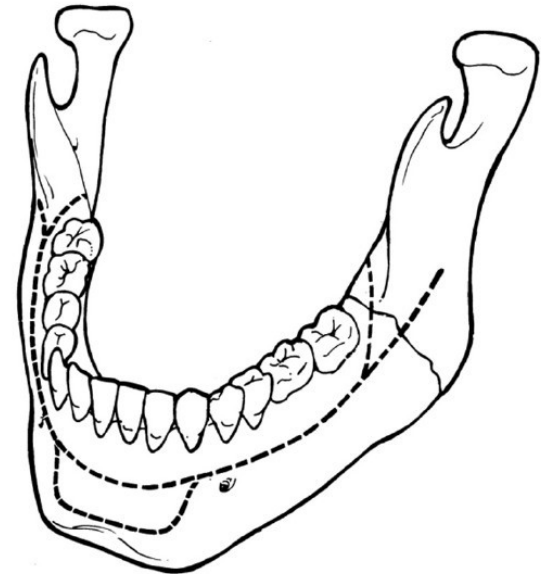
- 4 A. *caries profunda simplex*
- 3 B. *caries media*
- 6 C. *caries ad pulpam penetrans*
- 2 D. *caries superficialis*
- 5 E. *caries profunda pulpae proxima*
- 1 F. *caries incipiens*

Fixation via the miniplate according to Champy

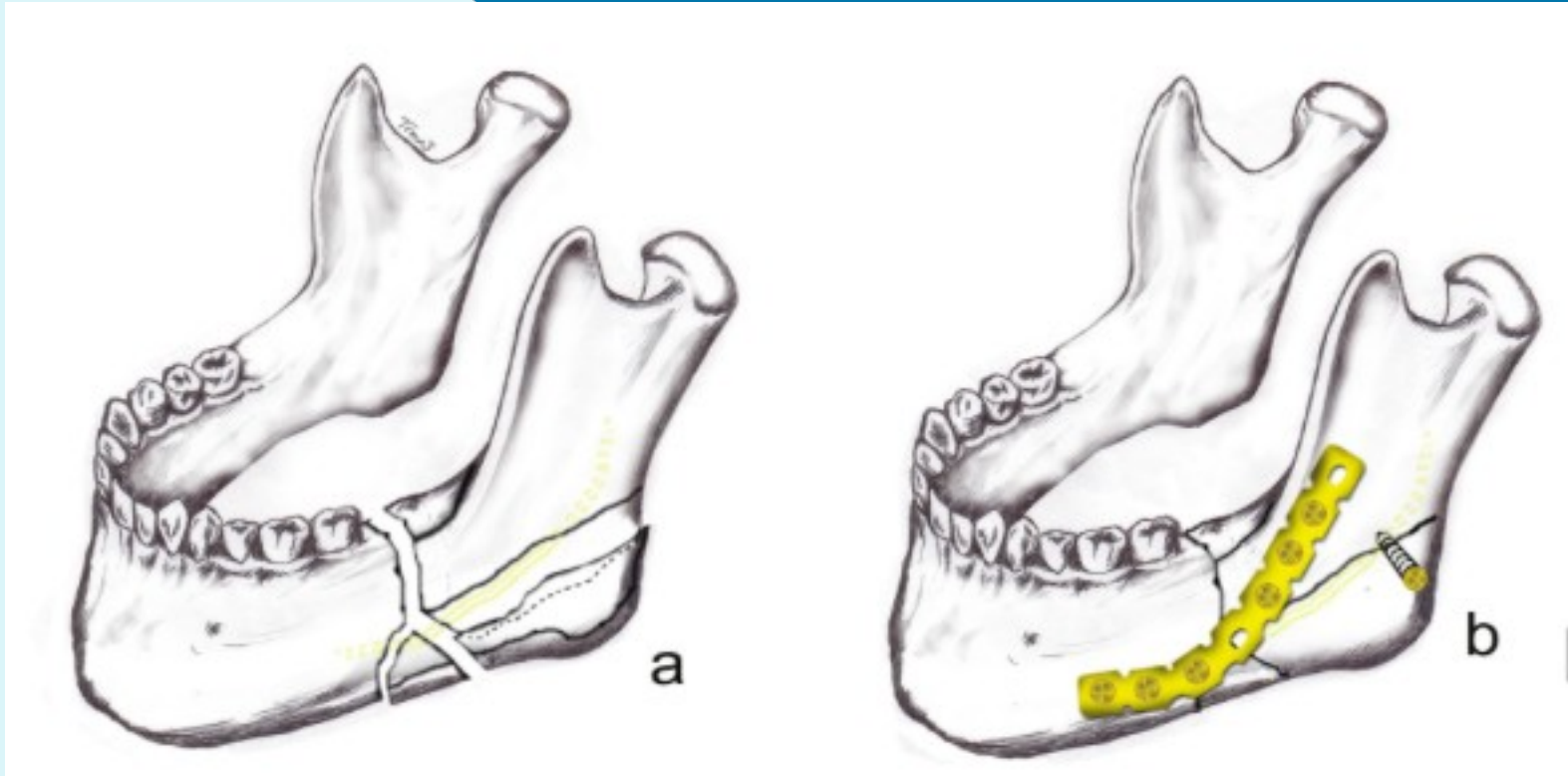


miniplate load-sharing semi-rigid fixation technique popularized by French doctor M. Champy

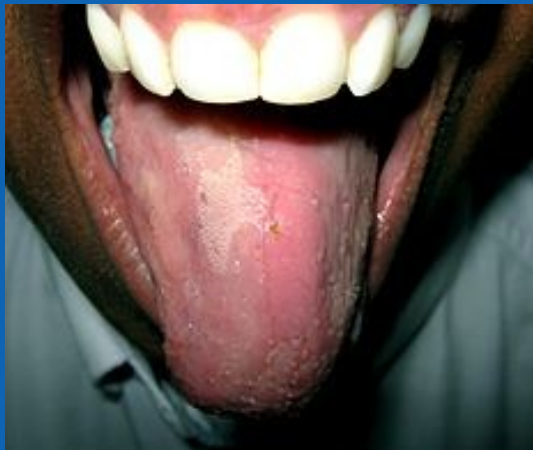Champy's line of the osteosynthesis of lower jaw



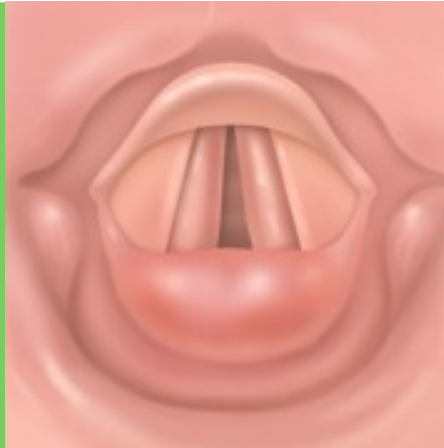
osteosynthesis according to Champy due to fracture of the process of lower jaw on the left side?



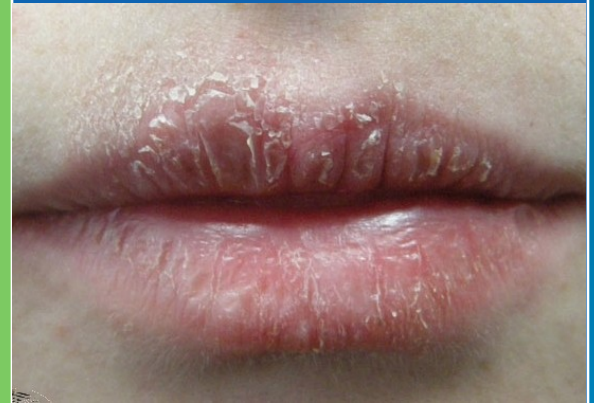Inflammationes



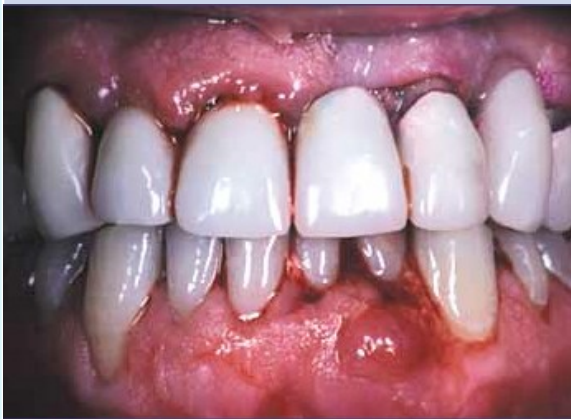MKN K 14.0



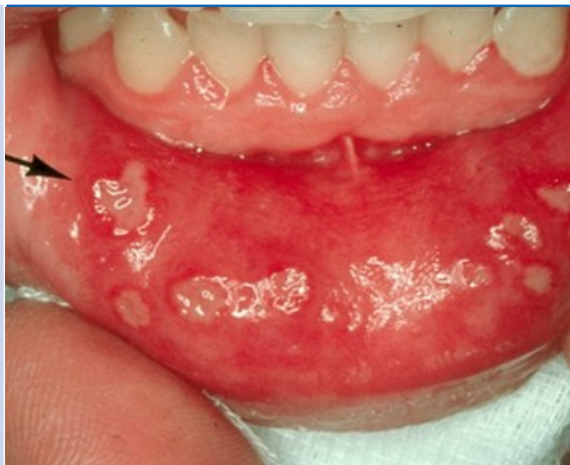MKN J 37.0



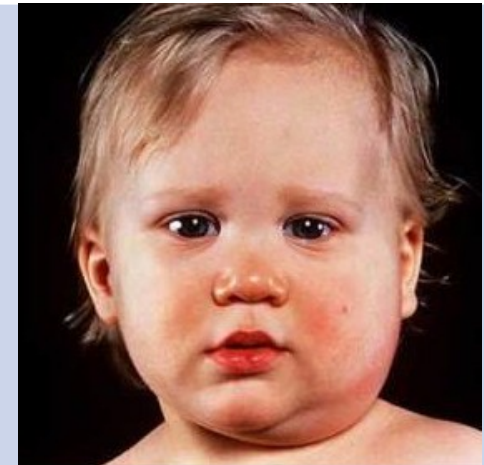MKN K 13.0



MKN K 05.3



MKN K 12.0



MKN B 26.0

Translate the underlined phrases, guess the meaning of the abbreviations

hospitalizován od: 26.10.2010 do: 28.10.2010

DG: C023 Carcinoma linguae et baseos oris

Stp. chir. intervenci

Stp. CHT a RT

PEG

I10 Morbus hypertonicus

Stp. transpl.ledviny

DM II na inzulinu

Hydrokéla testis l.sin., po transplantaci

Chron. bronchitis, t.č. v klidu

NO: pac. s verifikovaným spino Ca linguae et baseos oris l. dx, pac.

3.cyklu CHT.Zmenšení Tu asi o 20%, LU submandibulárně hmatné.

Stp. radikální resekci a radikálnímu krčnímu bloku vpravo.

Nyní přijat s krvávením z nádoru k observaci a i.v. terapii.