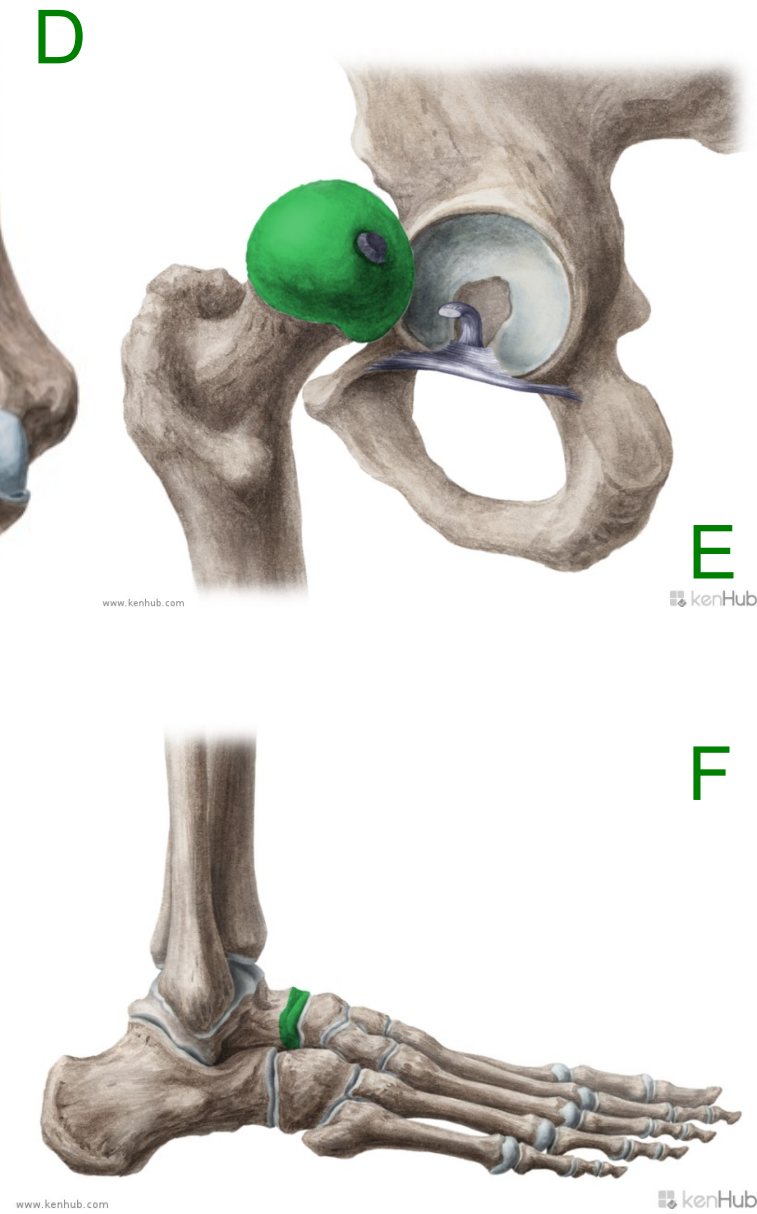
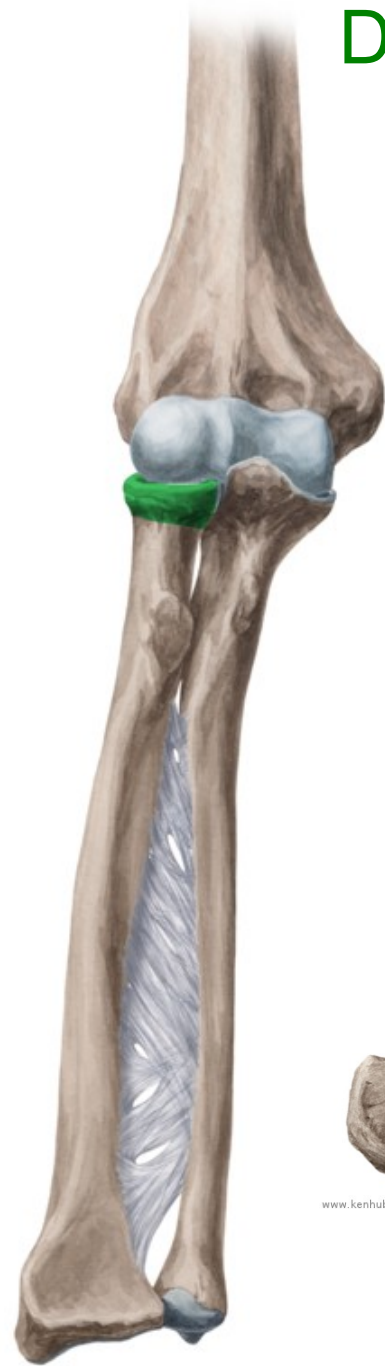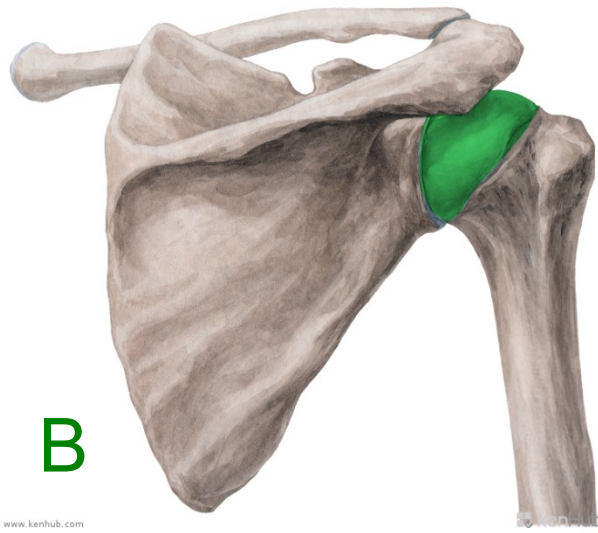
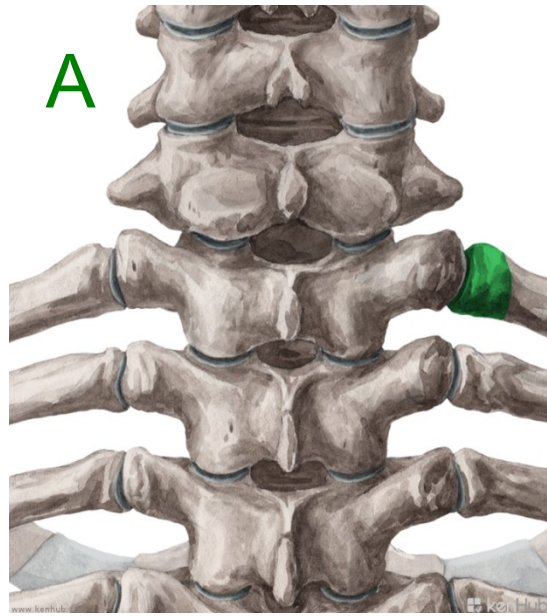


REVISION

- **What means do we use to define an anatomical term?**
- **What cases are used with prepositions in medical terminology?**
- **Are there any prepositions connected with two cases?**
- **Which prepositions are connected with the ablative case?**



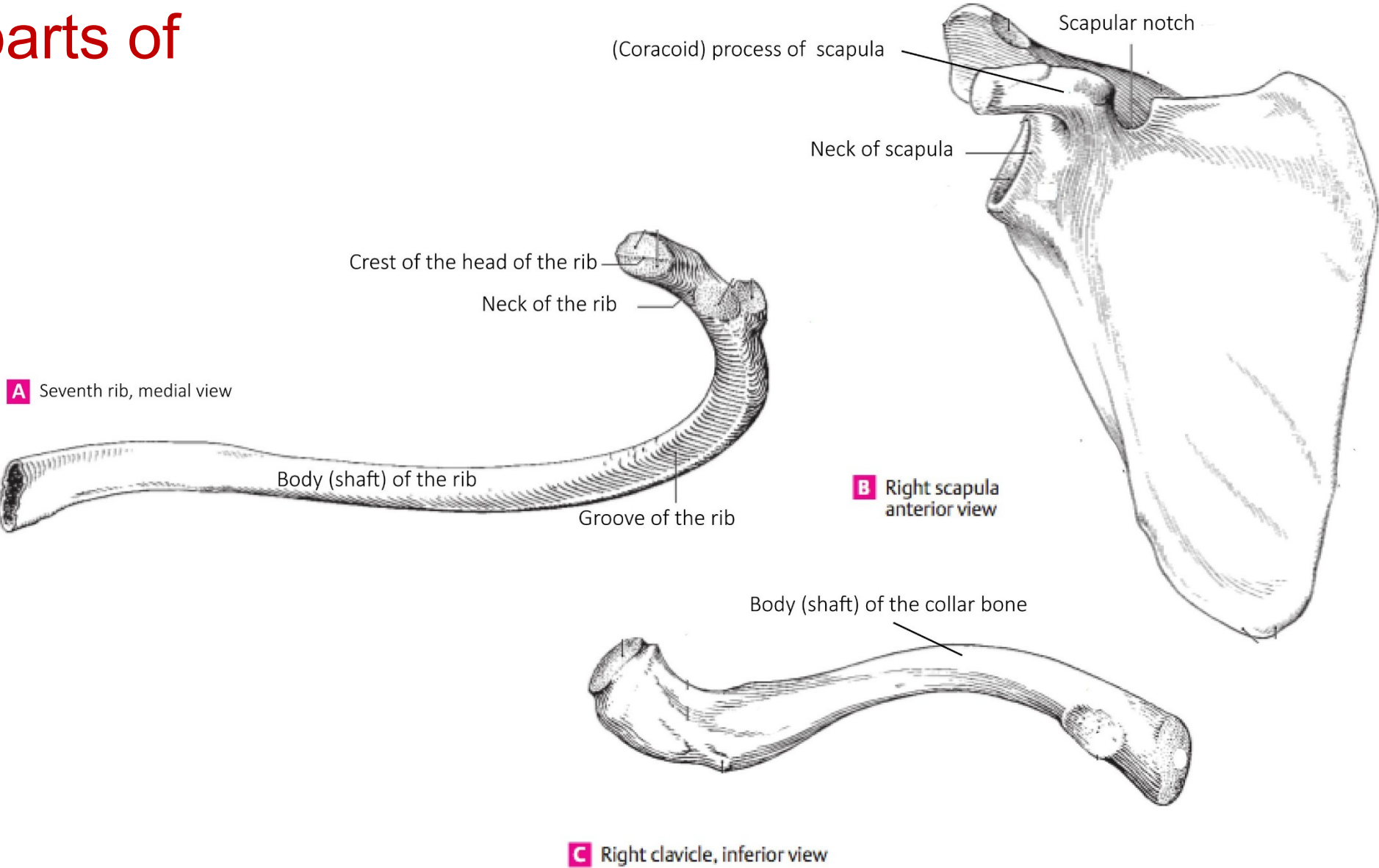
Connect the following nouns with RUPTURA or FRACTURA to create meaningful short diagnoses!

aorta ~ sclera ~ ulna ~ digitus ~ maxilla ~ ligamentum ~ trachea ~ tibia

RUPTURA

FRACTURA

Name parts of bones



Adjectives of
the 1st and 2nd
declension,
dictionary entry

Magnus, a, um

Magnus magna magnum

m.

f.

n.

Dexter, a, um

Dexter dextra dextrum

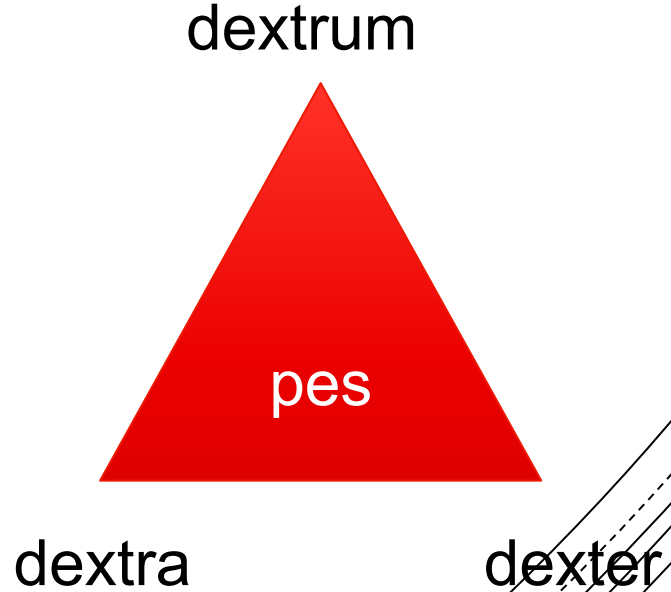
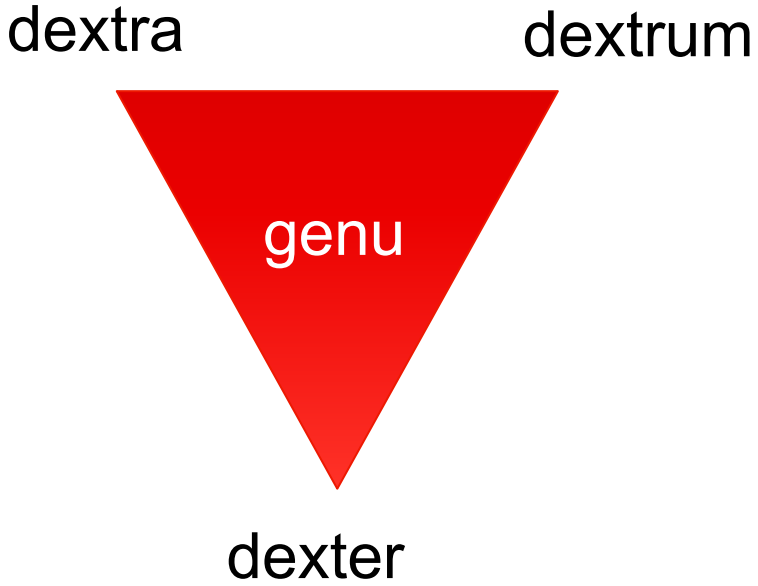
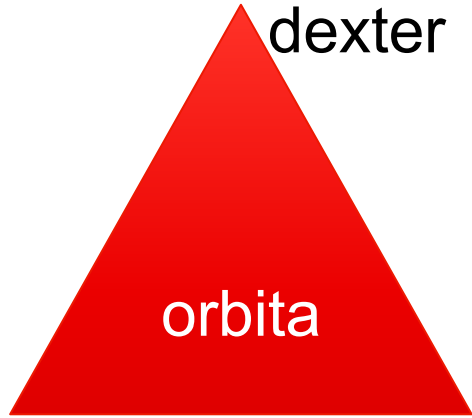
m.

f.

n.

(* liber, libera, liberum)

**Agreed
attribute**



Za správnosť

Lekárska správa - nález

Označenie zdrav. zariadenia, odd., pracovisko

pre

Priezvisko a meno

rok nar.

č. prot.

Klin. dg.

vykonané vyšetrenie

dňa

Dnes asi o 19.30 pri služobnom zároku úraz v obl. jarmovej kosti vpravo, na okolnosti sponína, v bezvedomí, nebol, nezvracal. I.č. v ÚVTOS.

Vyš: RFG / OPG, PND, Clementschitch - bez traumatických zmien skeletu. e.o. hematóm v obl. jarmovej kosti vpravo, pre výraznejší bolestivý opuch v obl. jarmovej kosti vpravo táto nepalpateľná, dolný okraj orbí bilat. bez scjodíka, vizus orient. v norme, senzít. inerv. tváre zachovalá

i.o. otváranie úst bez obmedz., sliz. EPN, skelet pevný, záryz v norm

Dg: Contusio faciei l.dx. reg. ossis zygomat.
Haematoma faciei l.dx. reg. ossis et arc. zygo at.
Ih: in. len vyšetrenie.

Udp: Chladiť, analgetiká p.p. Vhodné v ÚVTOS predpísať Augmentin 625mg p.o. 4-8 hod.

KO: V prípade ťažkostí ihneď

Contusio faciei l.dx. reg. ossis zygomat.

Contusio faciei lateris dextri regionis ossis zygomatici

Haematoma faciei l. dx. reg. ossis et arc. zygomat.

Haematoma faciei lateris dextri regionis ossis et arcus

zygomatici

Read and guess
the
meaning:

Dg.:
*Corpus alienum trac. GI
l.sin. sine compl, sine
inflam.*

**Corpus alienum tractus
gastrointestinalis lateris
sinistri sine
complicationibus, sine
inflammatione**

