

KOSTRA DOLNÍ KONČETINY ***(ossa membri inferioris)***

KOSTRA DOLNÍ KONČETINY ***(ossa membri inferioris)***

- orgán opory a lokomoce
- ve srovnání s horní končetinou – robustnější kosti
- značně omezená pohyblivost (klouby a svaly)

Skelet pánevního pletence

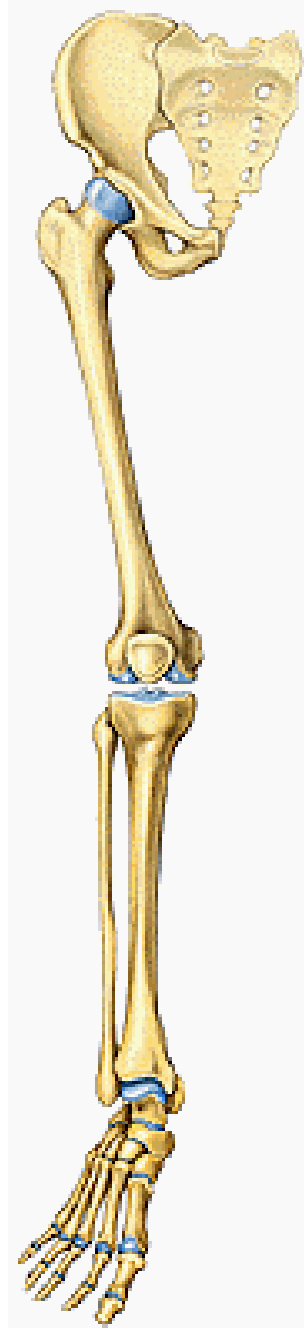
kost pánevní – **os coxae**
(**os ilium, os ischii, os pubis**)

Skelet volné dolní končetiny

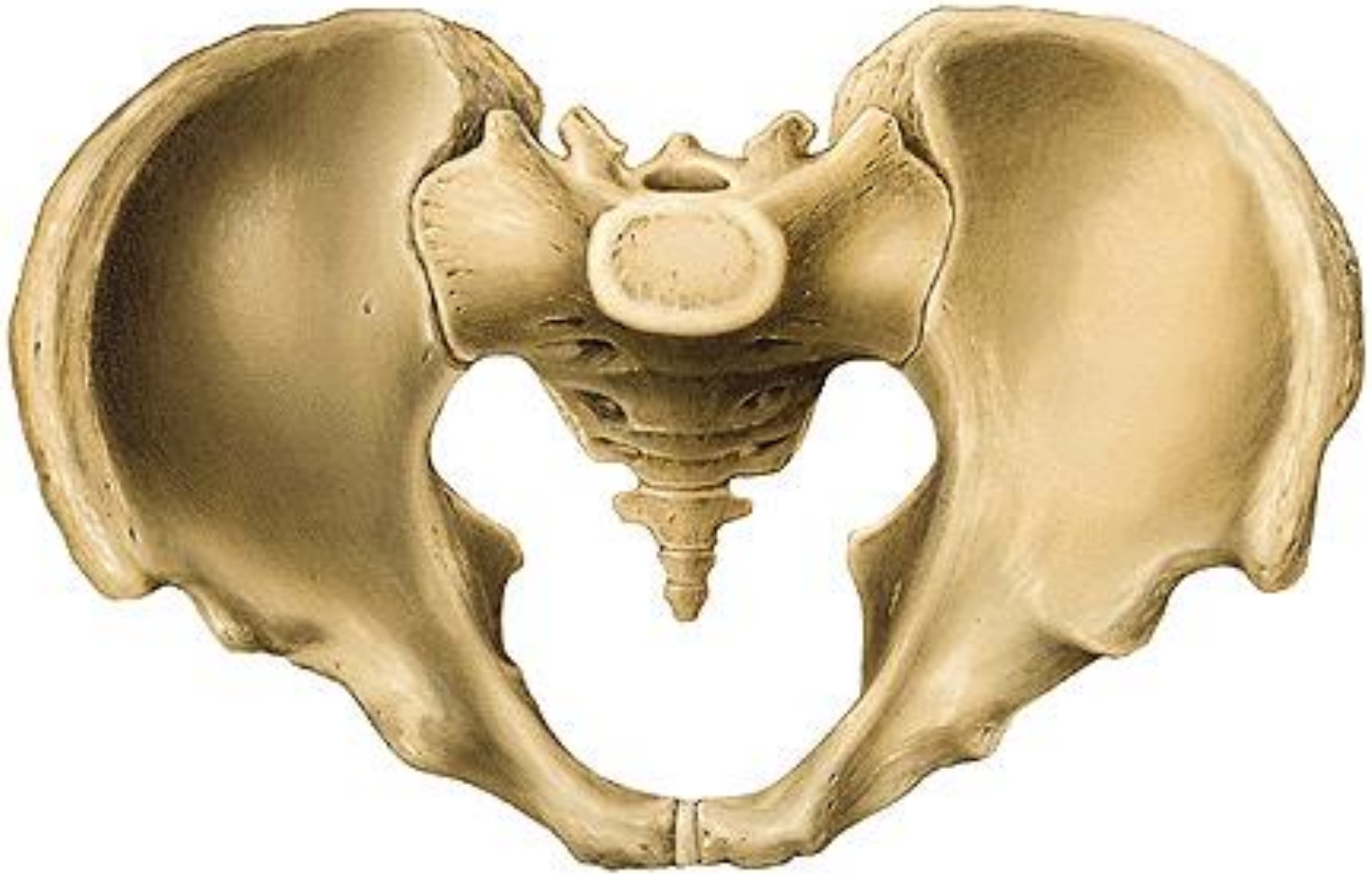stehenní kost – **femur**
čéška – **patella**

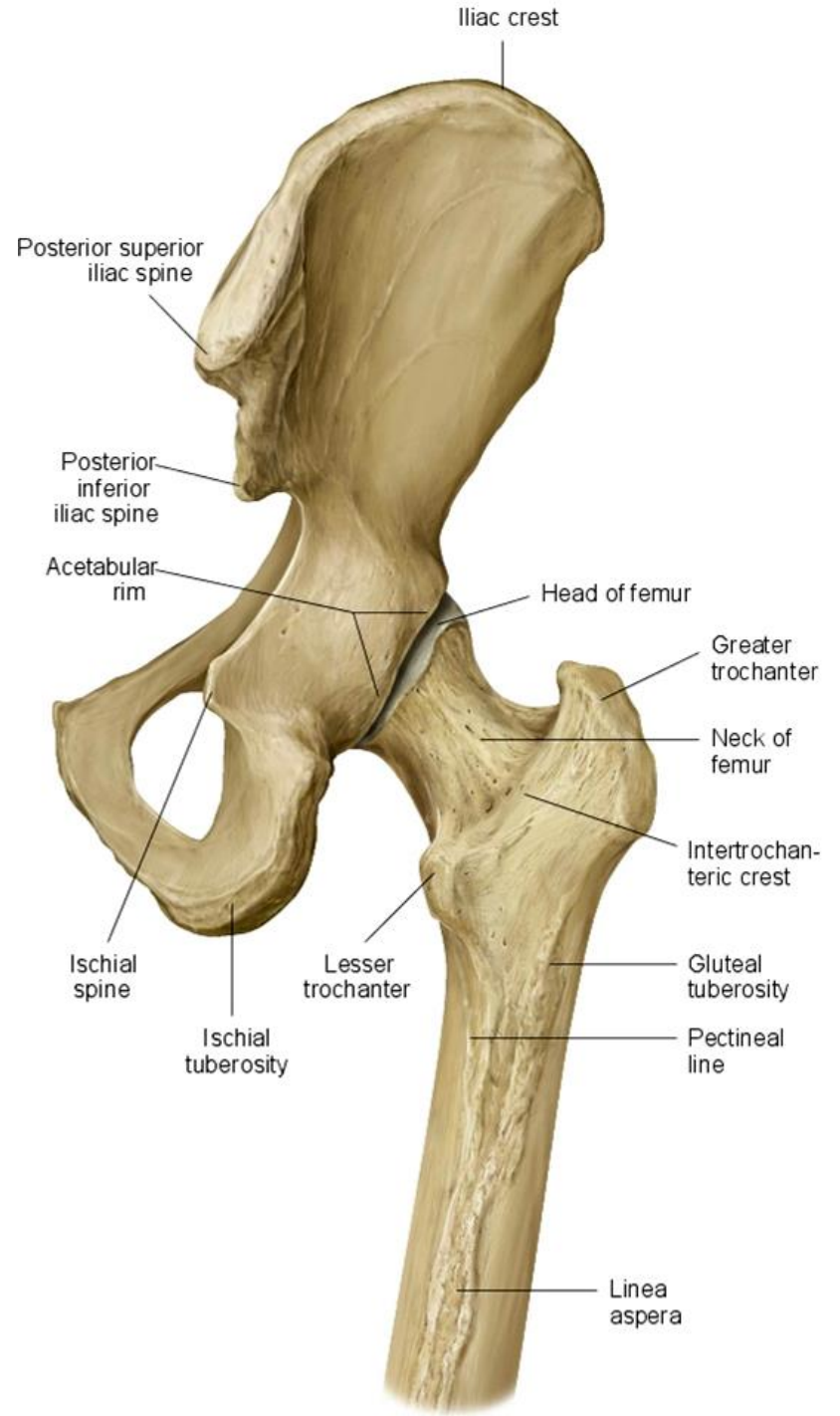
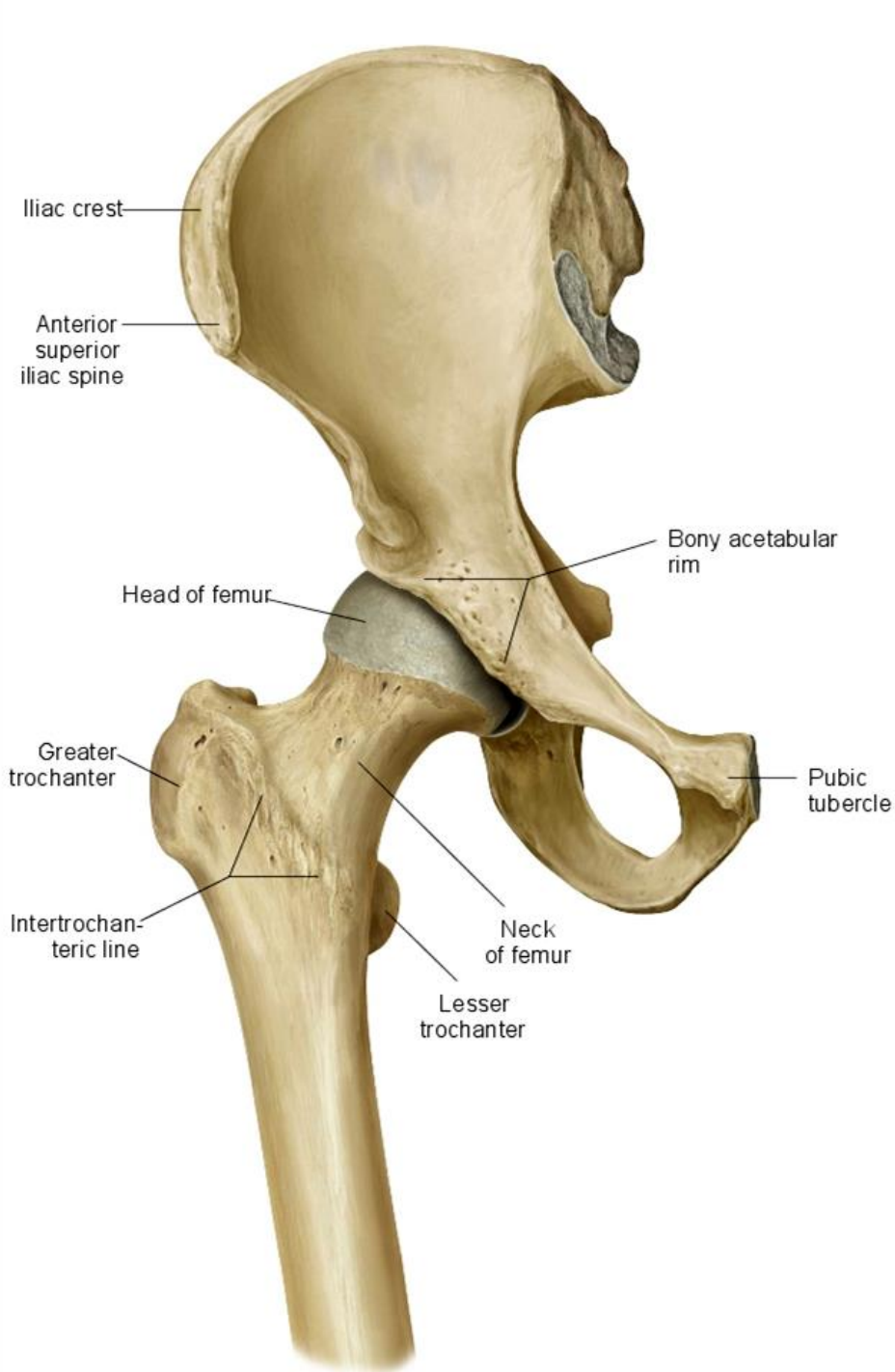
holenní kost – **tibia**
lýtková kost – **fibula**

zánártní kosti – **ossa tarsi**
nártní kosti – **ossa metatarsi**
kosti prstů nohy (**ossa digitorum pedis – phalanges**)



Cingulum membri inferioris

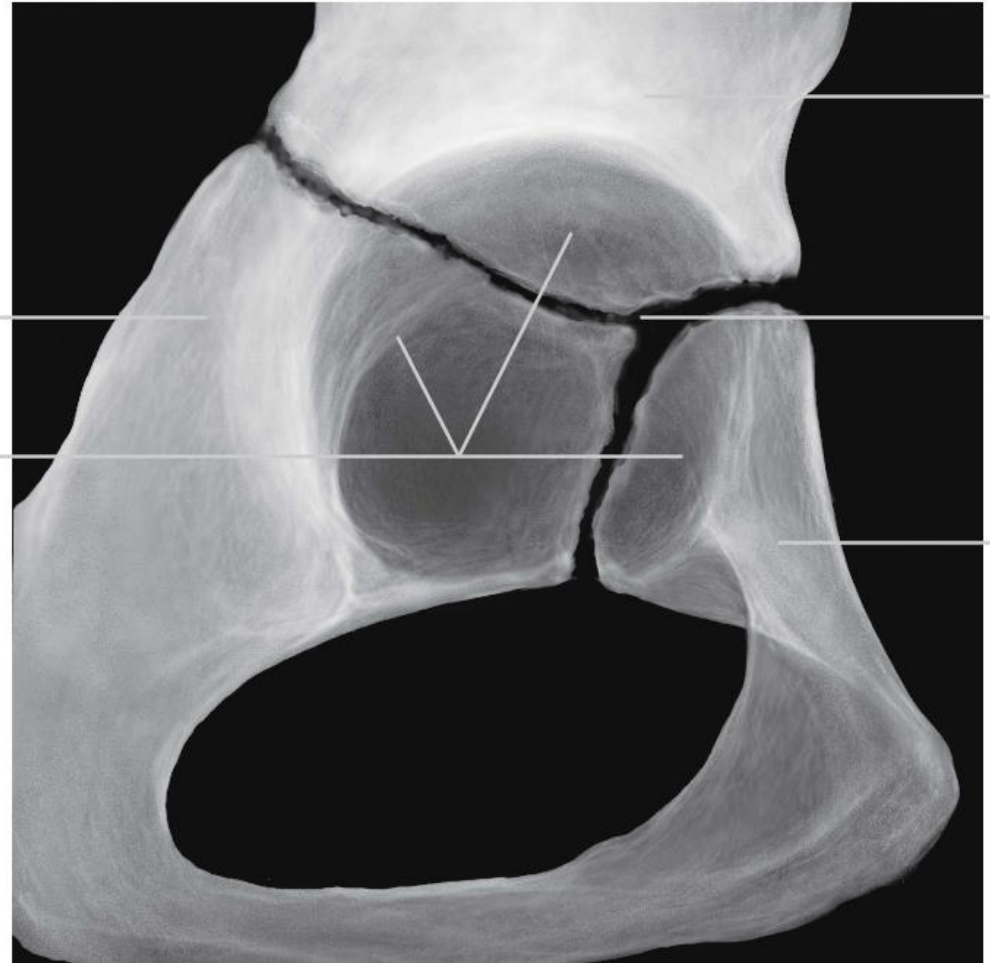
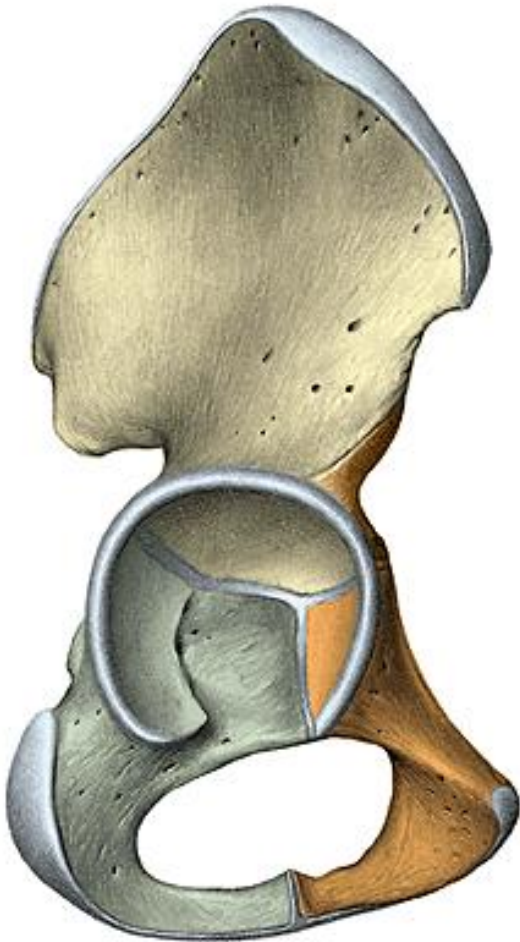




Os coxae

os ilium, os pubis, os ischii

- plochá kost - vývojově srůstá ze 3 kostí v kloubní jamce mezi 16.-20. rokem



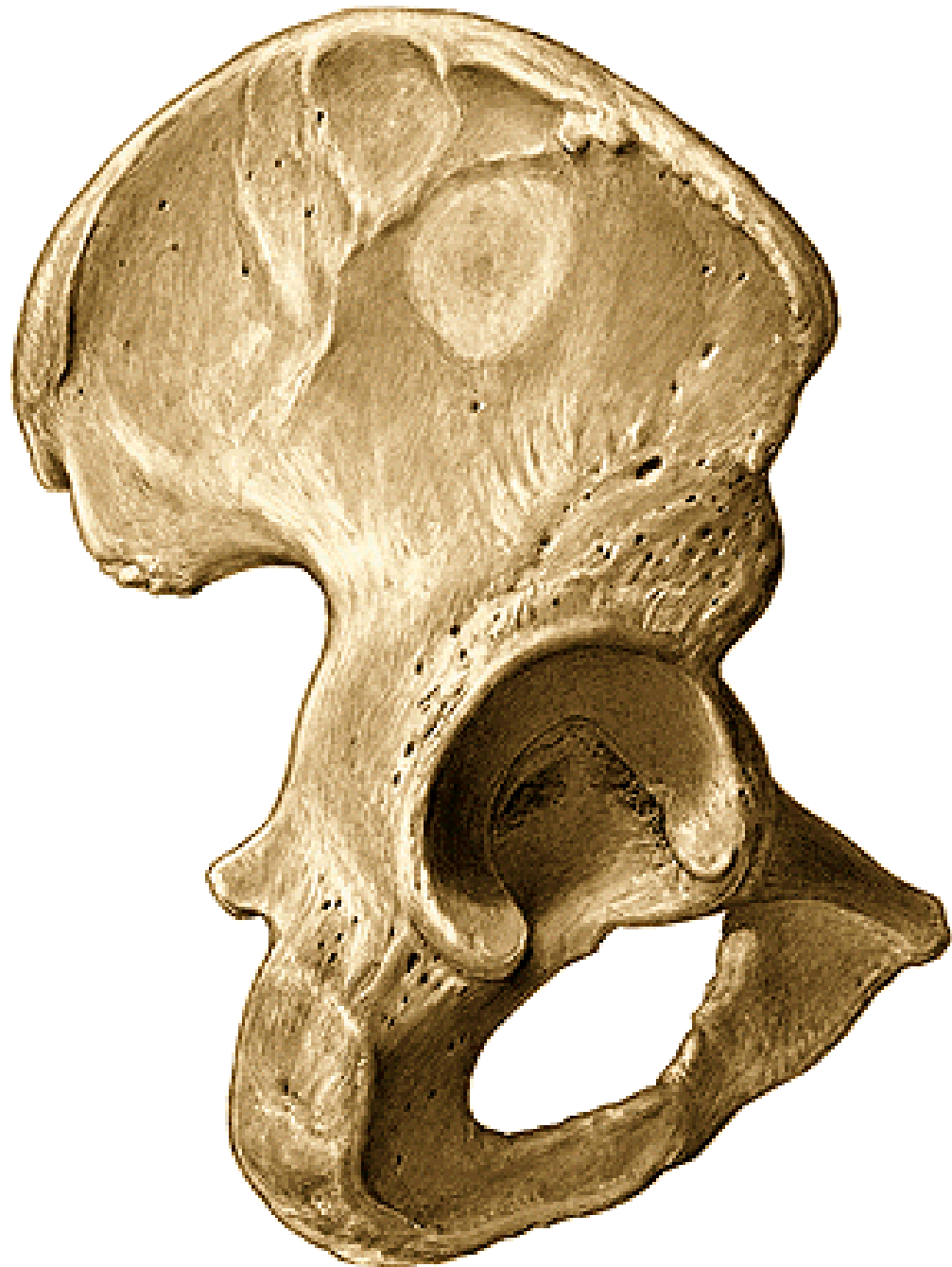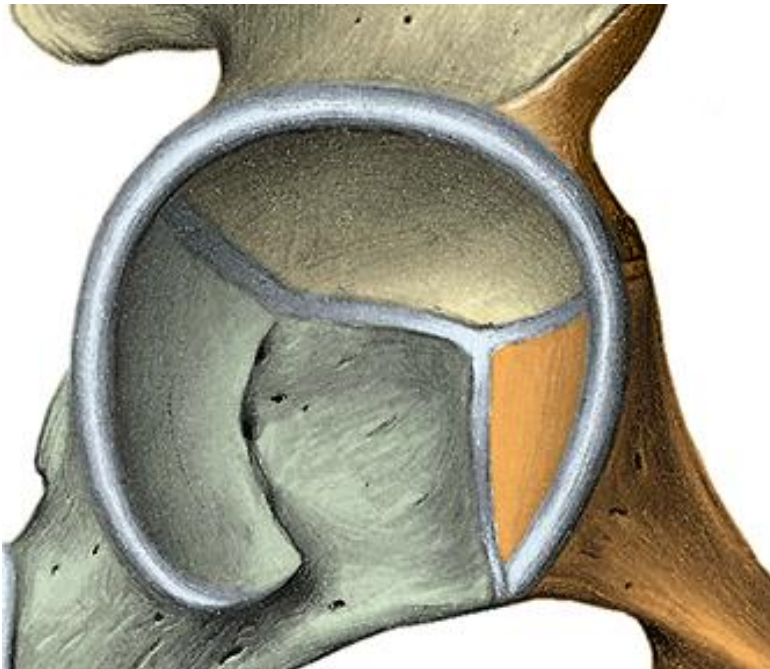
acetabulum

facies lunata

fossa acetabuli

incisura acetabuli

foramen obturatum

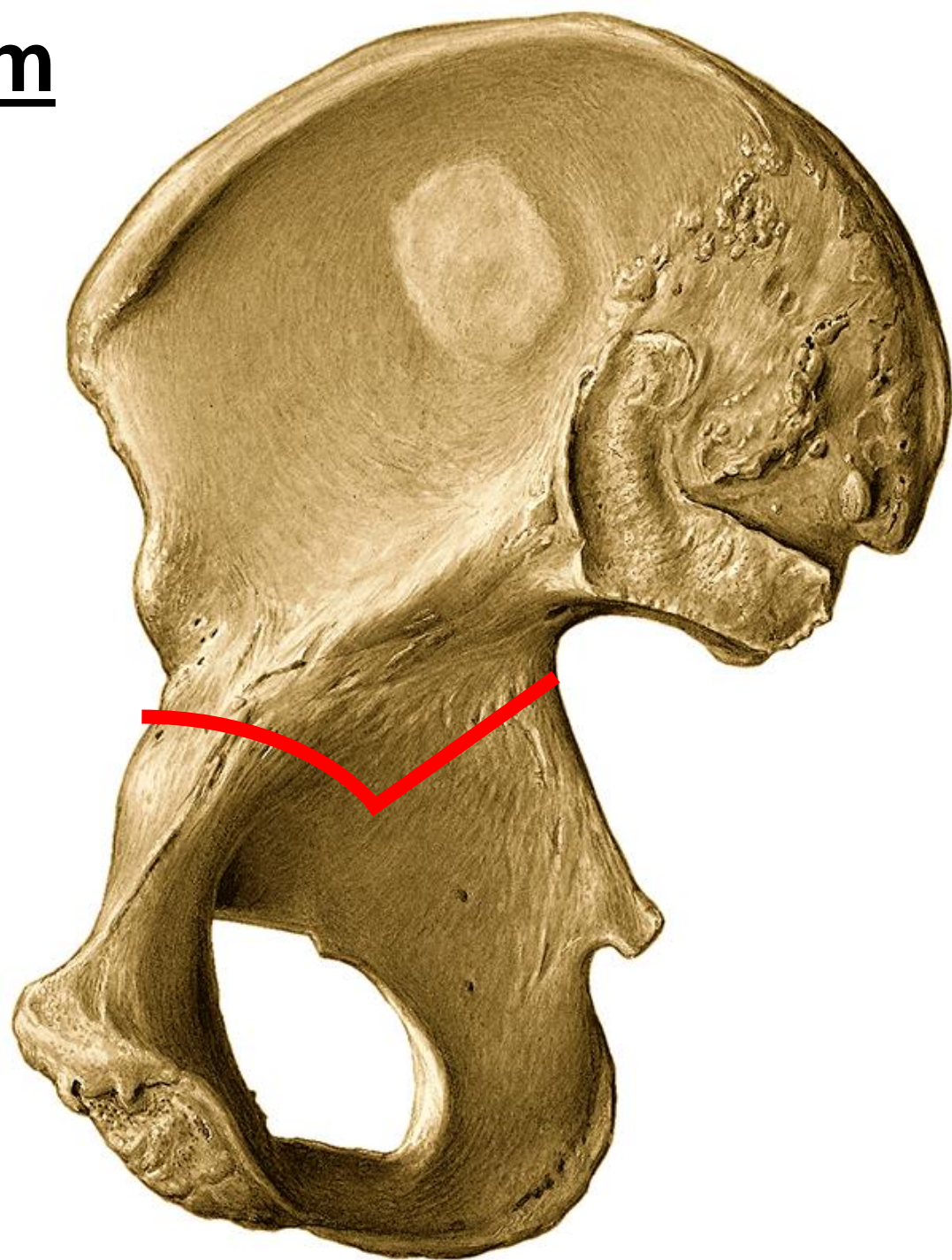


kyčelní kost – os ilium

corpus

ala

- mediální plocha
- fossa iliaca
- facies auricularis
- tuberositas iliaca
- linea arcuata



crista iliaca

labium externum

linea intermedia

labium internum

tuberculum iliacum

spina iliaca anterior superior

spina iliaca anterior inferior

spina iliaca posterior superior

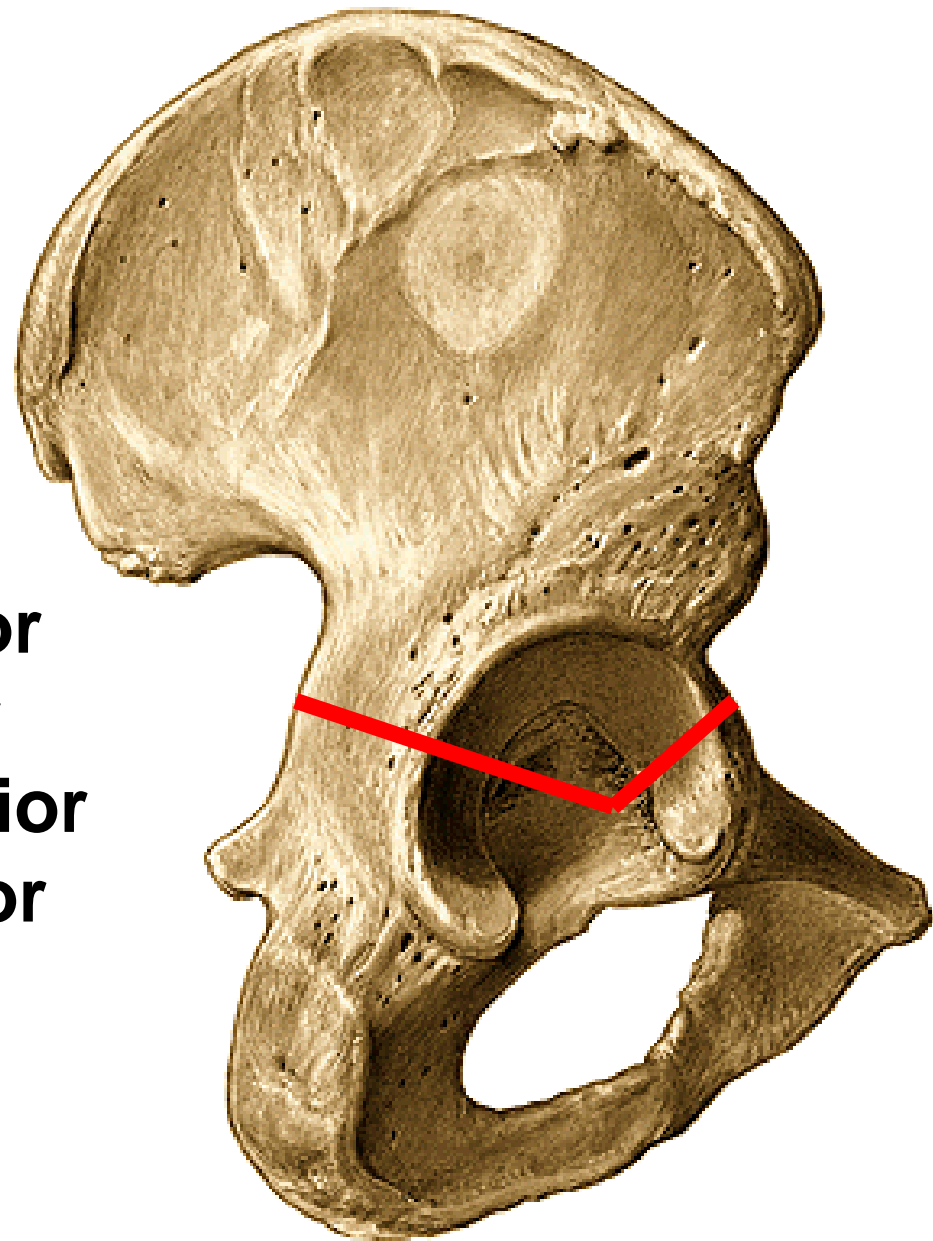
spina iliaca posterior inferior

• laterální plocha

linea glutea posterior

linea glutea anterior

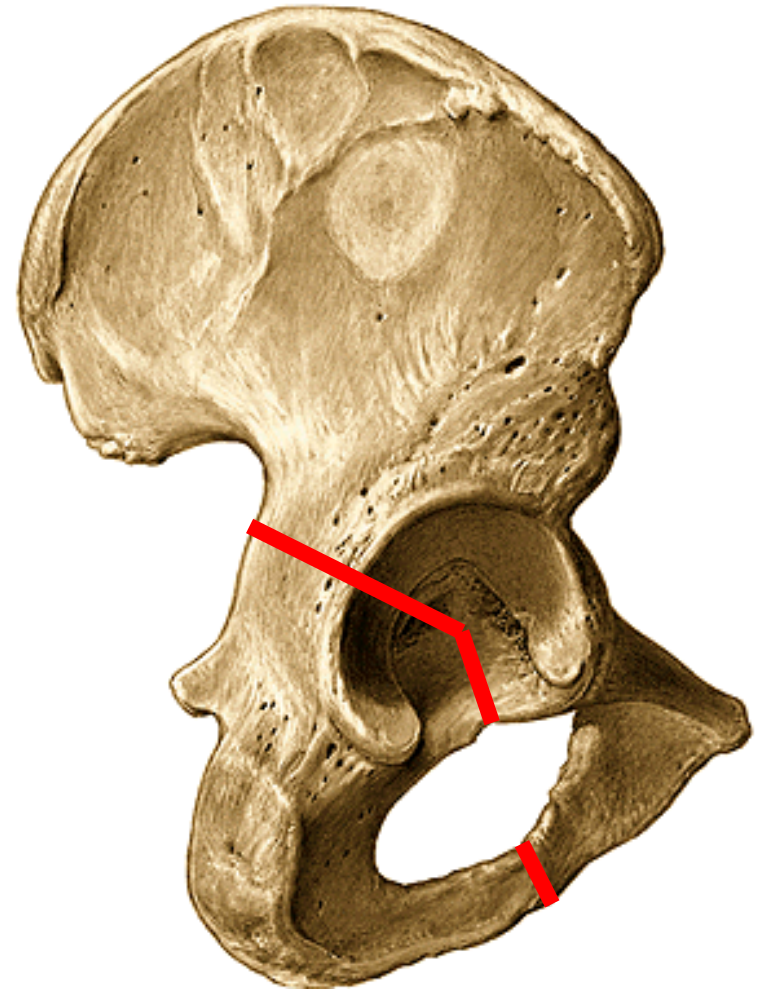
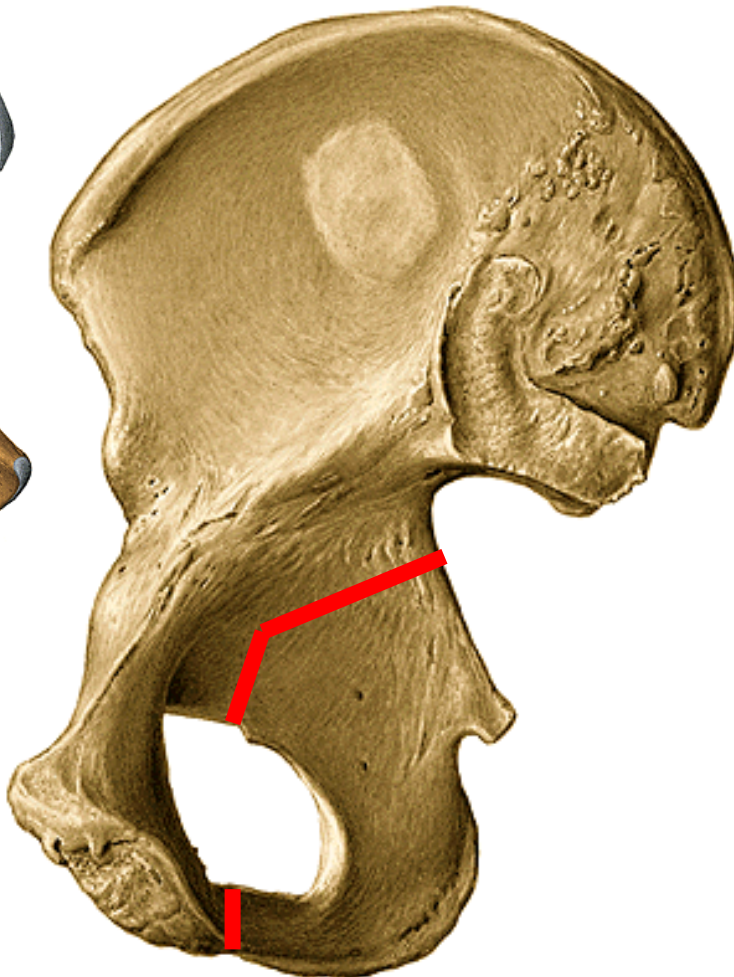
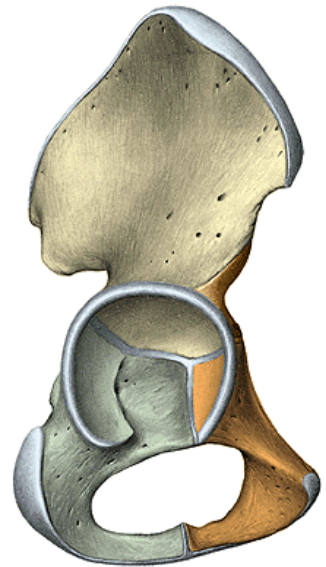
linea glutea inferior



sedací kost – OS ischii

corpus
ramus

tuber ischiadicum
spina ischiadica
incisura ischiadica major
incisura ischiadica minor

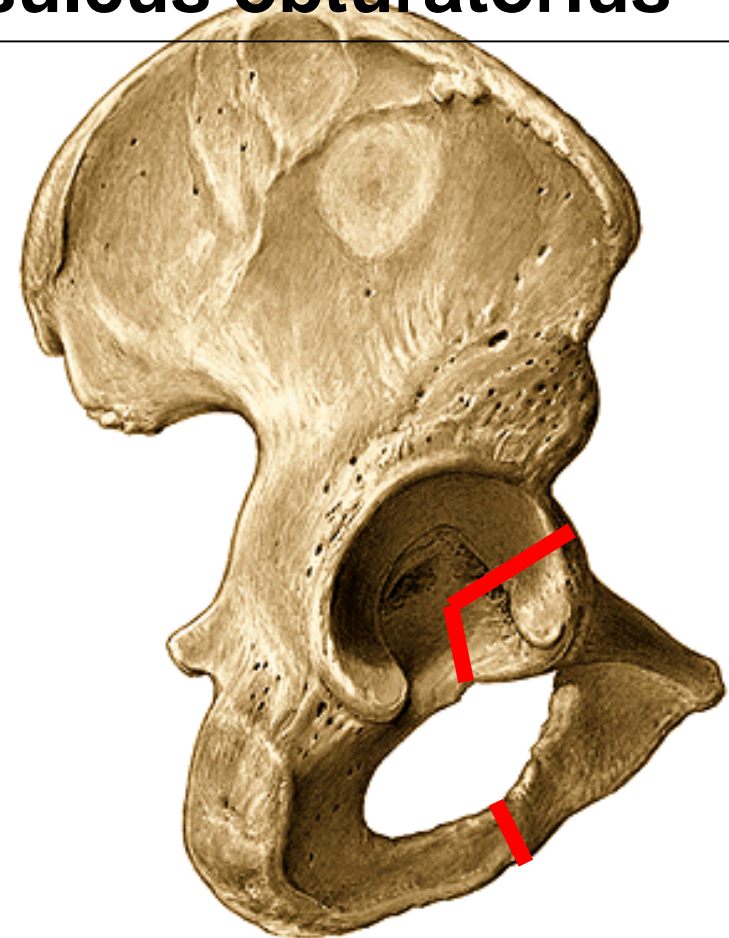
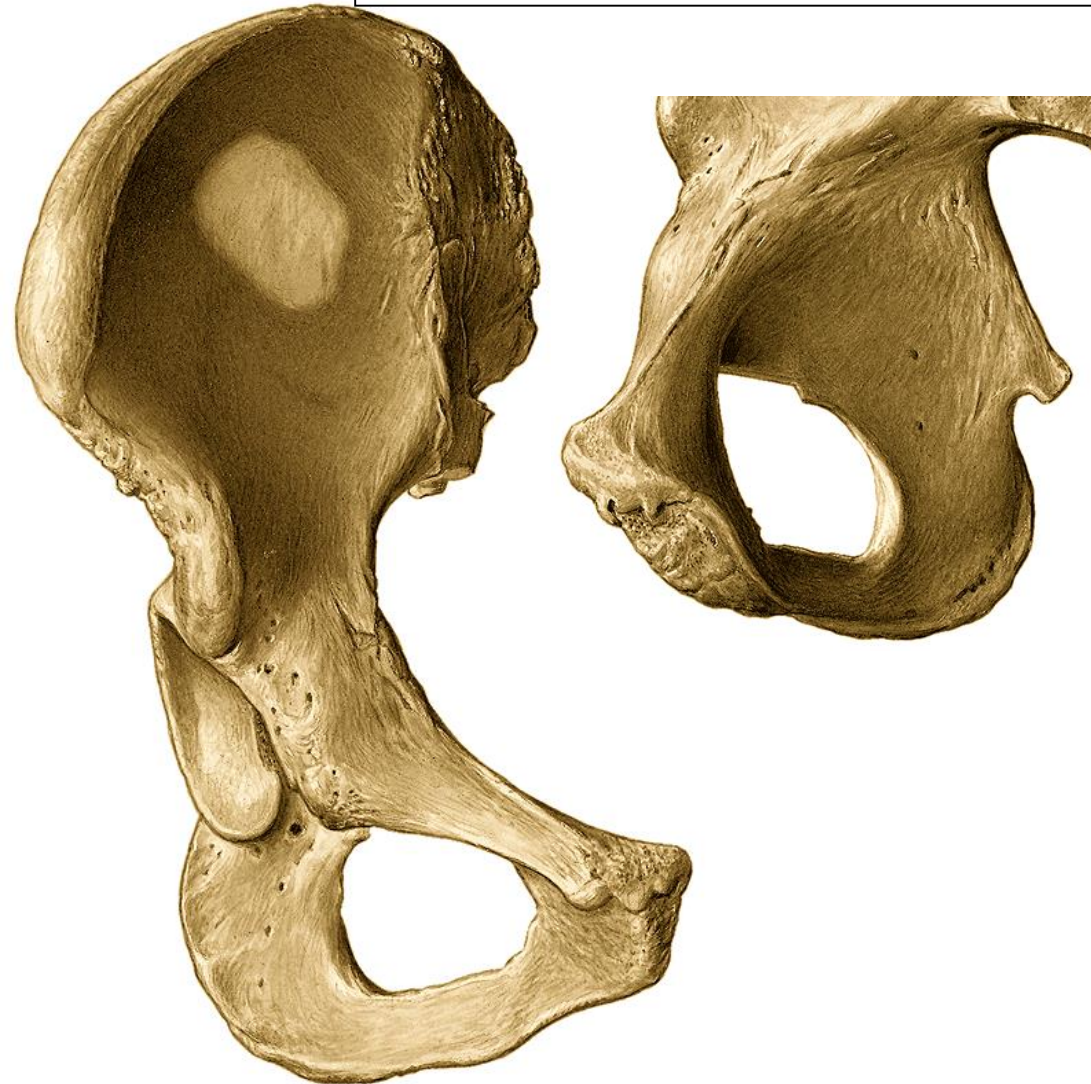

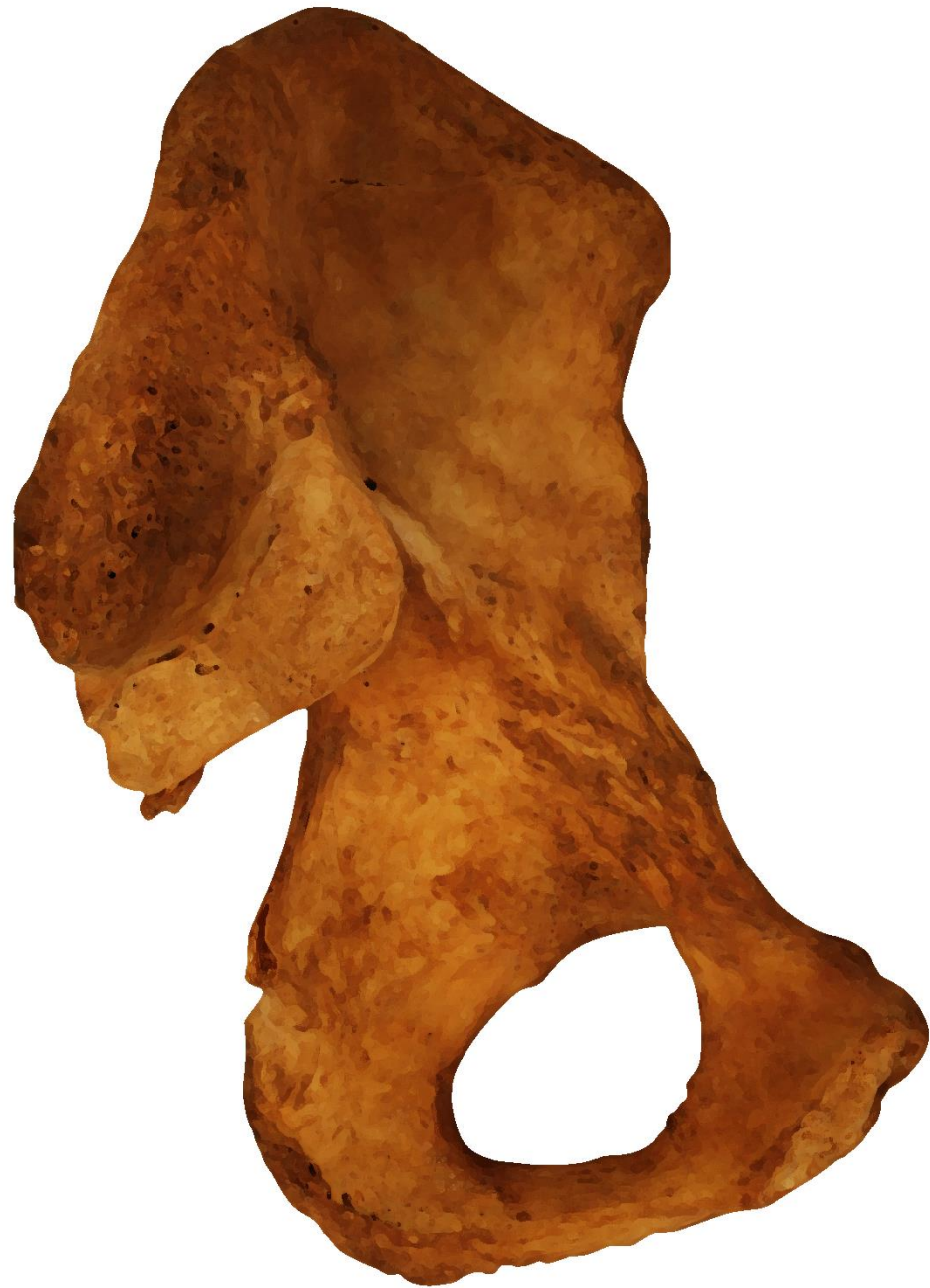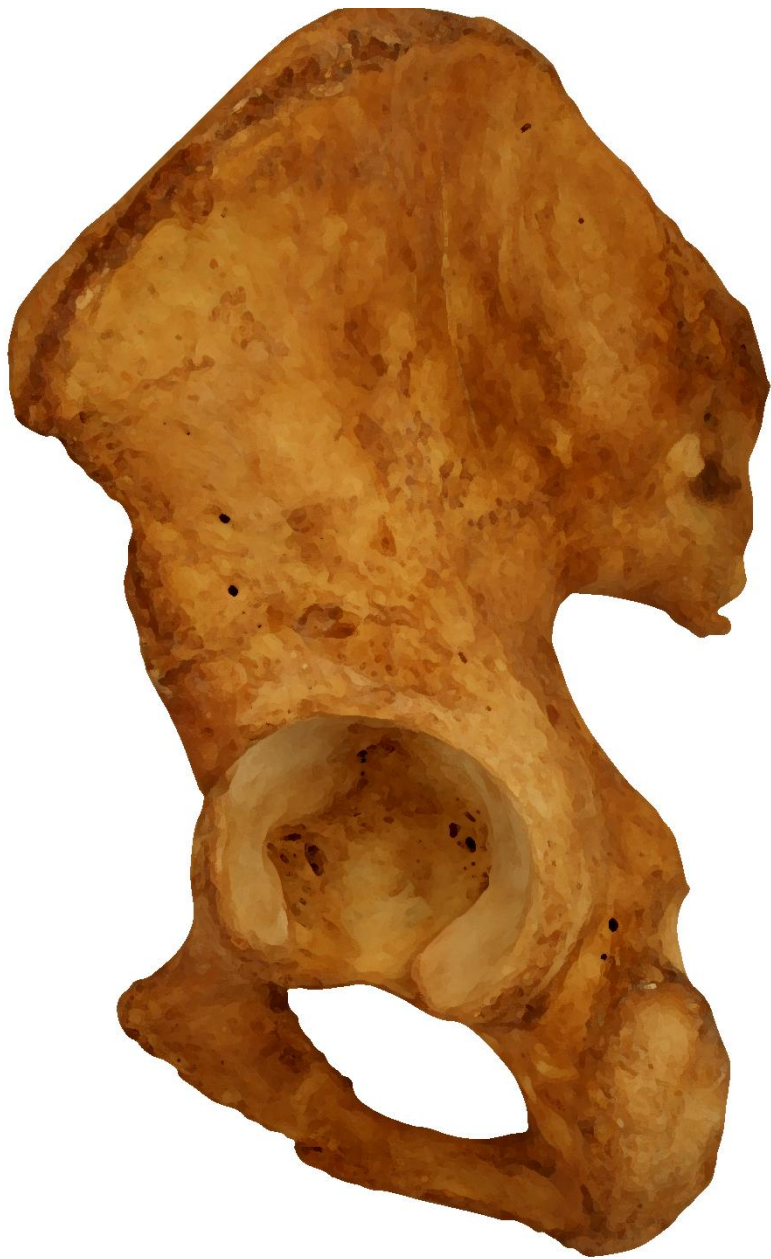stydká kost – os pubis

corpus

ramus inferior
facies symphysealis
crista phallica

ramus superior
eminentia iliopubica
pecten ossis pubis
tuberculum pubicum
sulcus obturatorius





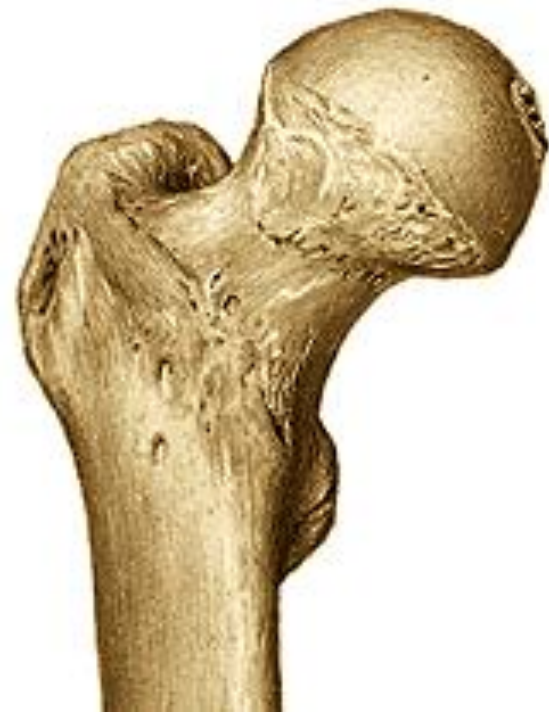Femur – stehenní kost

proximální konec:

caput femoris

fovea capitis femoris

collum femoris



mezi proximálním koncem a tělem:

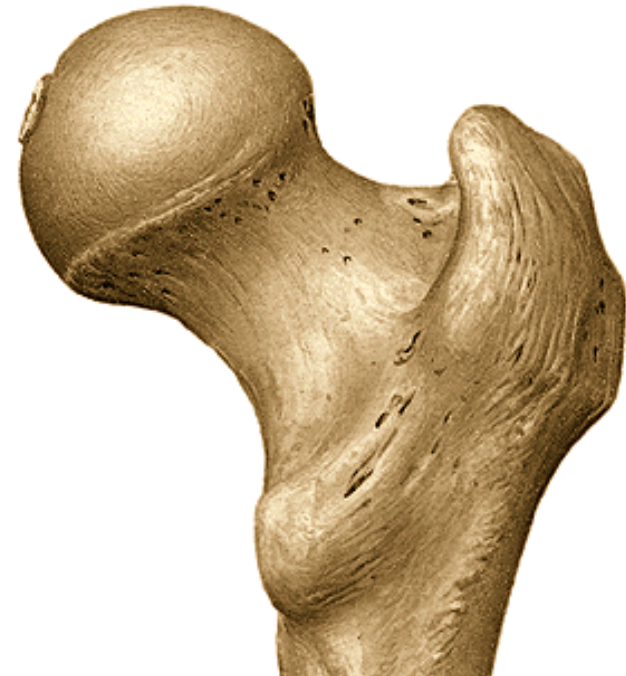trochanter major

trochanter minor

linea intertrochanterica

crista intertrochanterica

fossa trochanterica

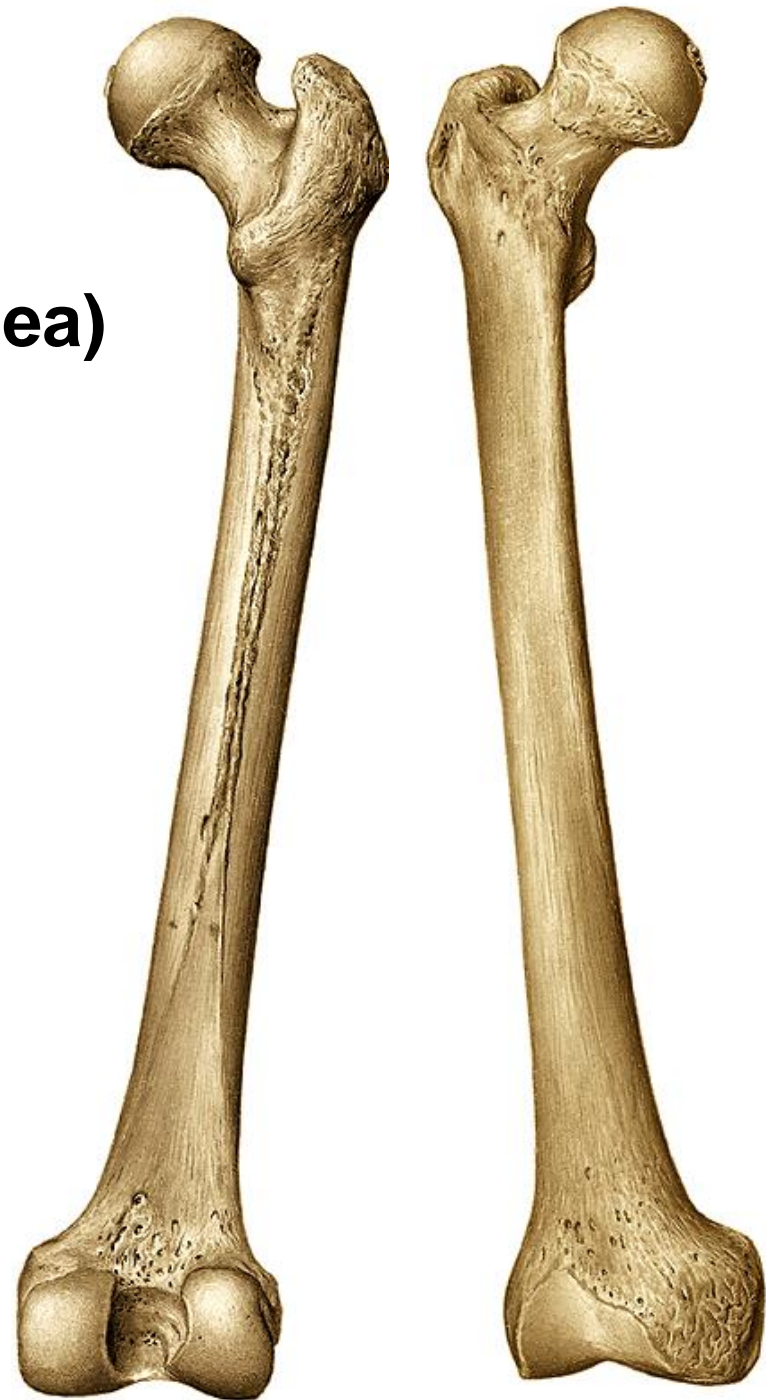
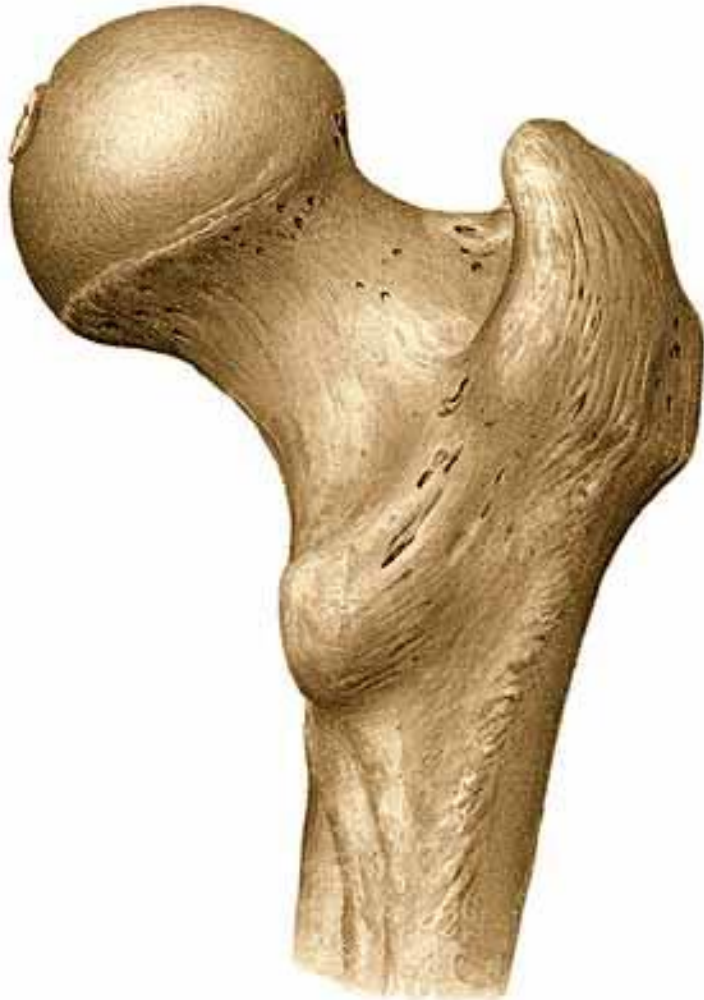
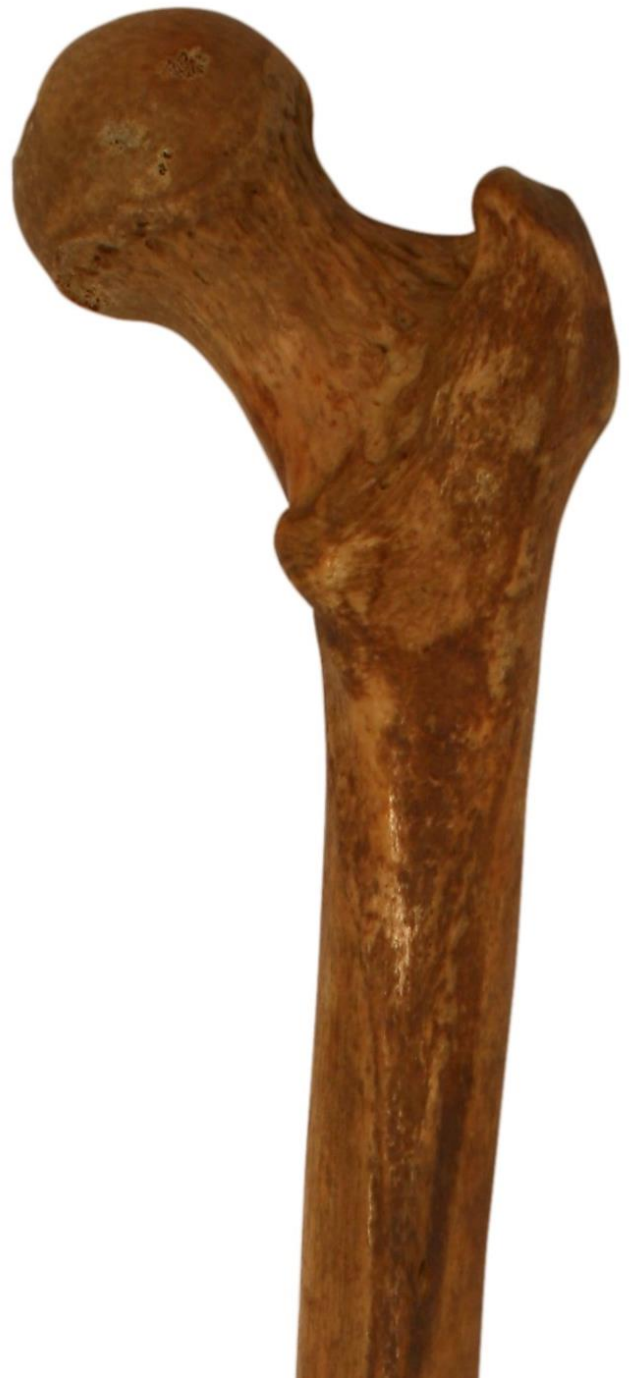corpus femoris

linea aspera

labium mediale (linea pectinea)

labium laterale (tuberositas glutea)





distální konec:

condylus medialis

condylus lateralis

epicondylus medialis

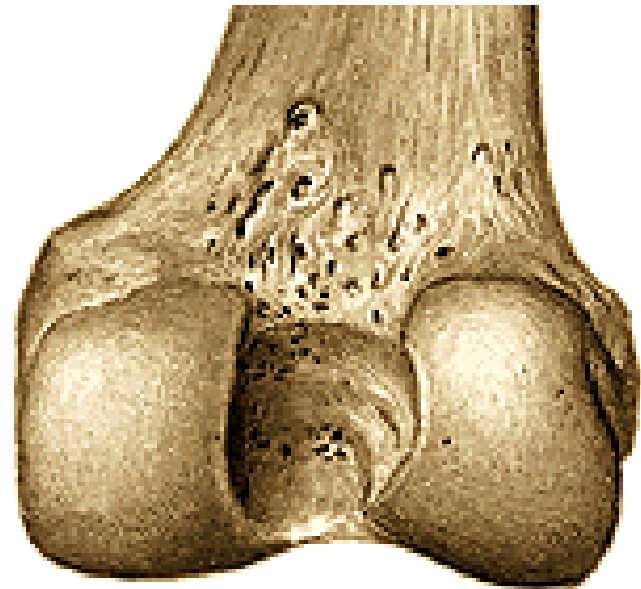
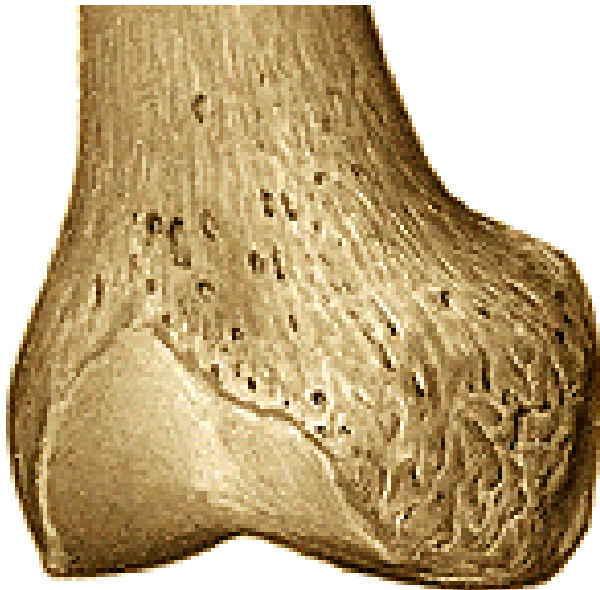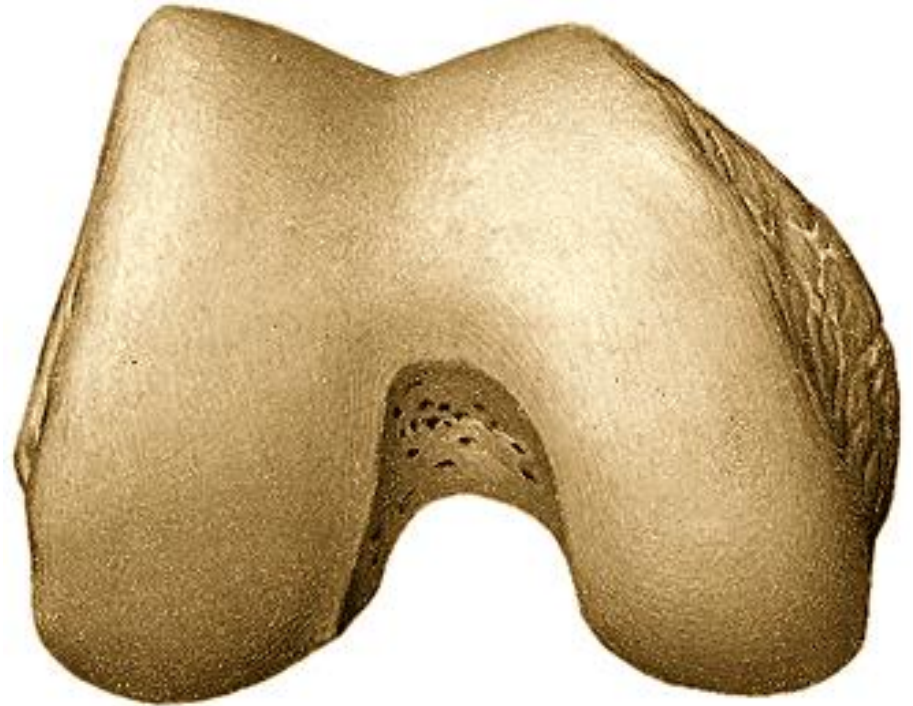epicondylus lateralis

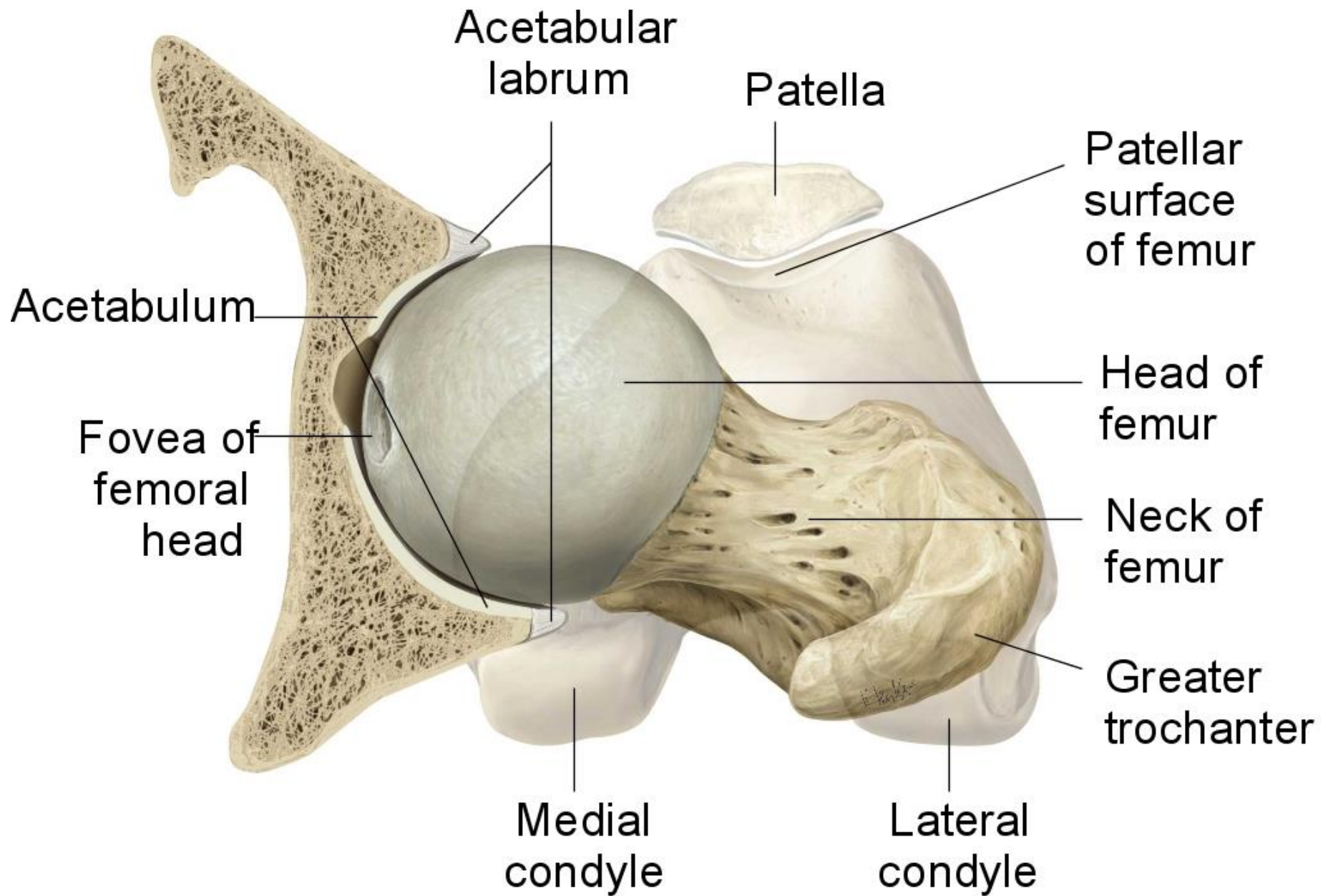
facies patellaris

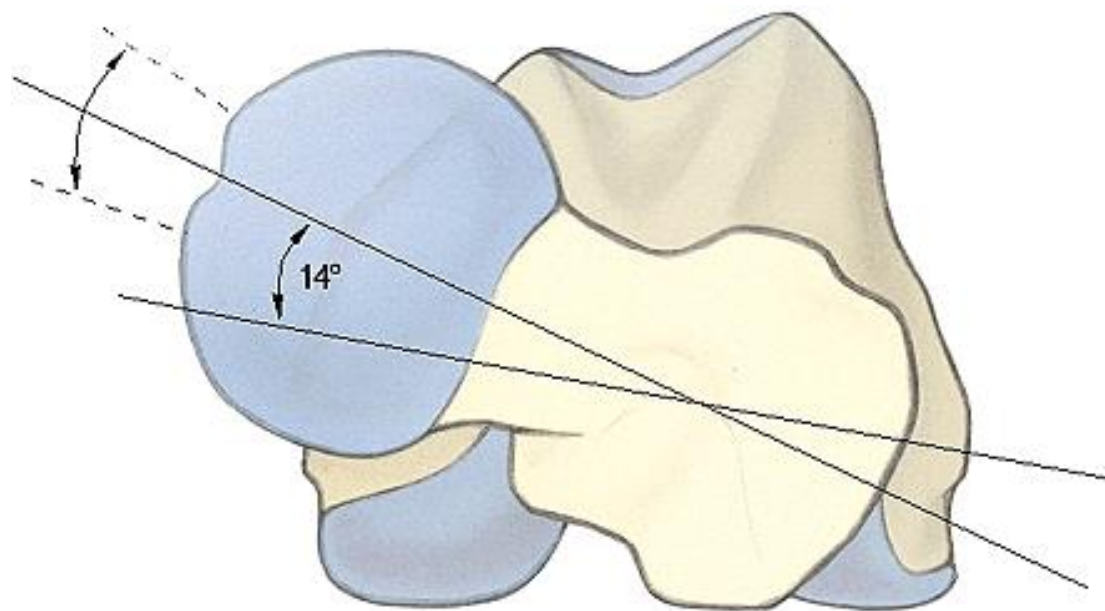
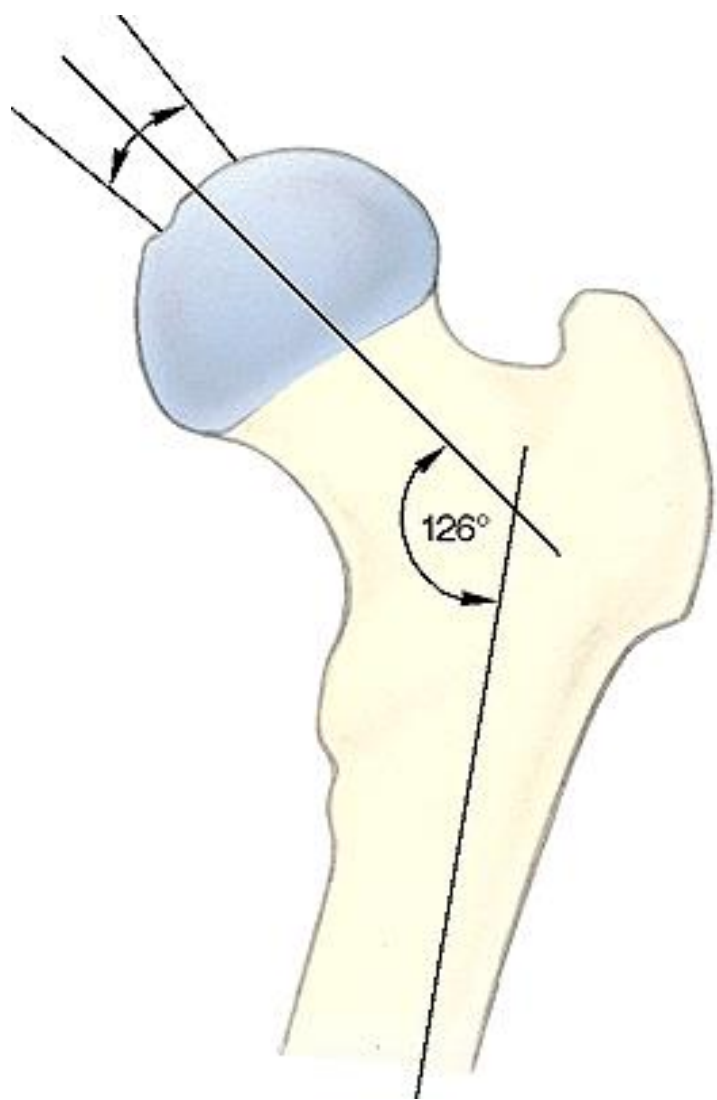
facies poplitea

fossa intercondylaris

linea intercondylaris







Patella – čéška

basis patellae

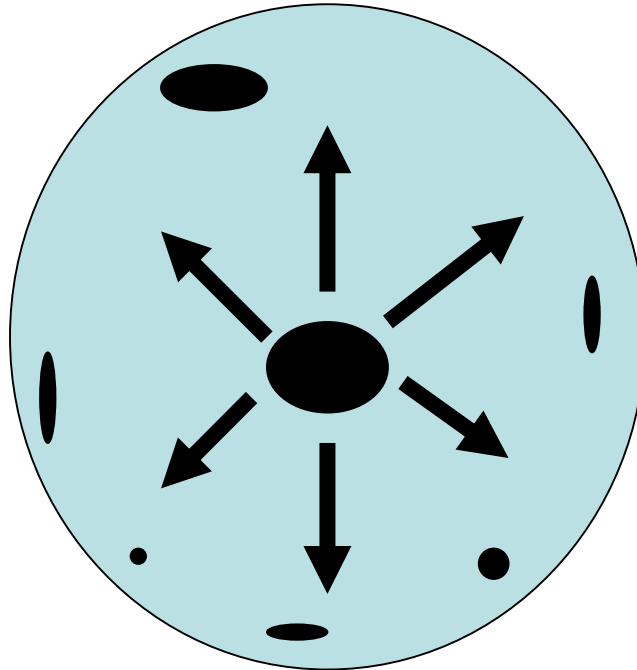
apex patellae

facies articularis patellae- laterální a mediální faseta

facies anterior



OSIFIKACE PATELLY

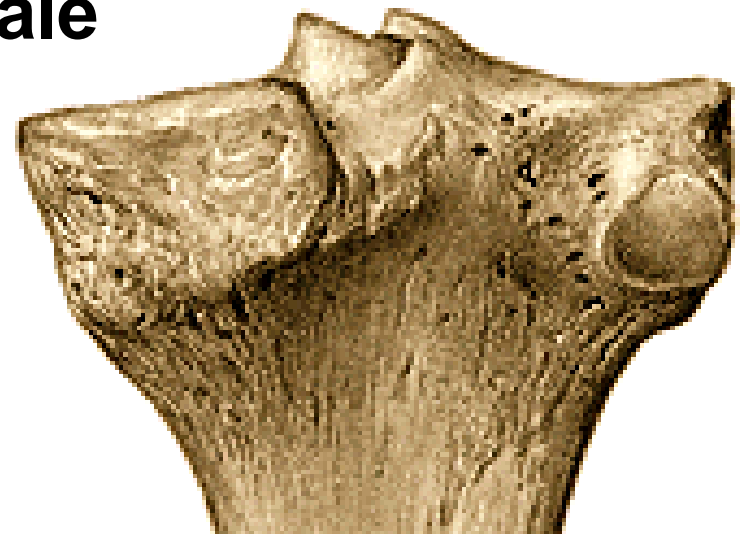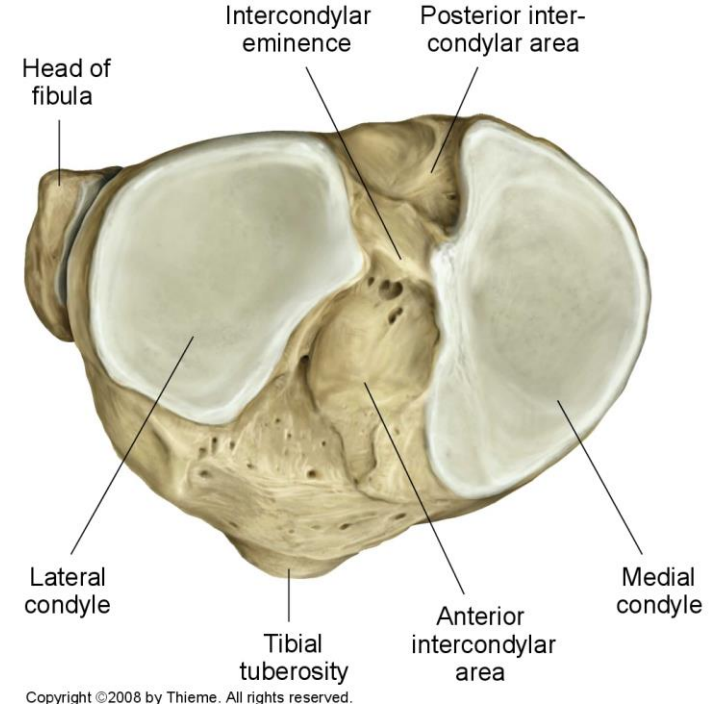


Tibia – holenní kost

proximální konec:
condylus medialis
condylus lateralis

facies articularis superior
eminentia intercondylaris
tuberculum intercondylare mediale
tuberculum intercondylare laterale
area intercondylaris anterior
area intercondylaris posterior

facies articularis fibularis



corpus

tuberositas tibiae

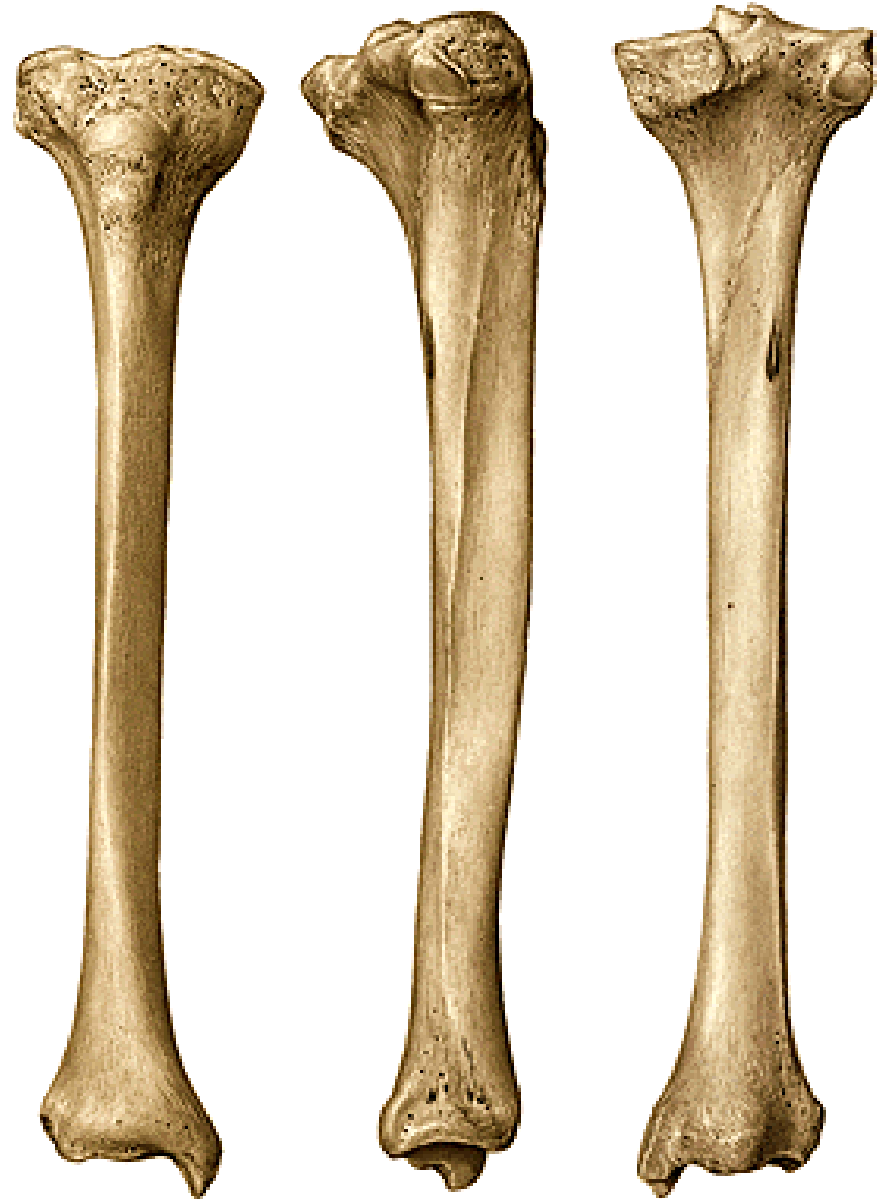linea musculi solei

margo medialis

margo anterior

margo interosseus

tuberositas tractus iliotibialis



distální konec:

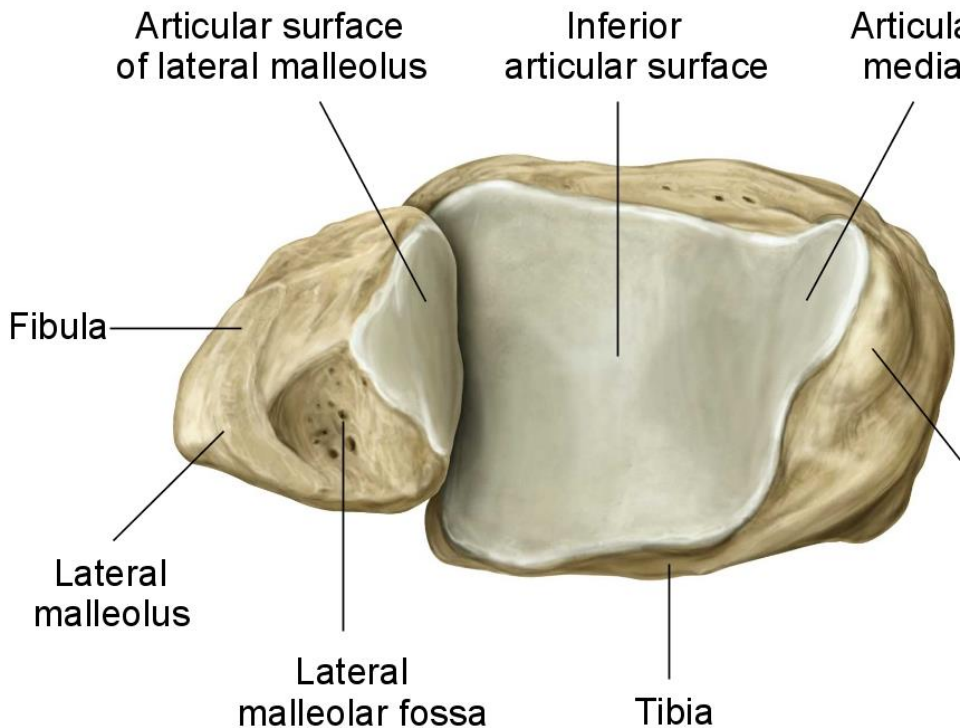
malleolus medialis

sulcus malleoli medialis

facies articularis malleoli medialis

incisura fibularis

facies articularis inferior (distalis)





Fibula – lýtková kost

proximální konec:

**caput fibulae (facies articularis capitis fibulae)
apex capitis fibulae**

corpus:

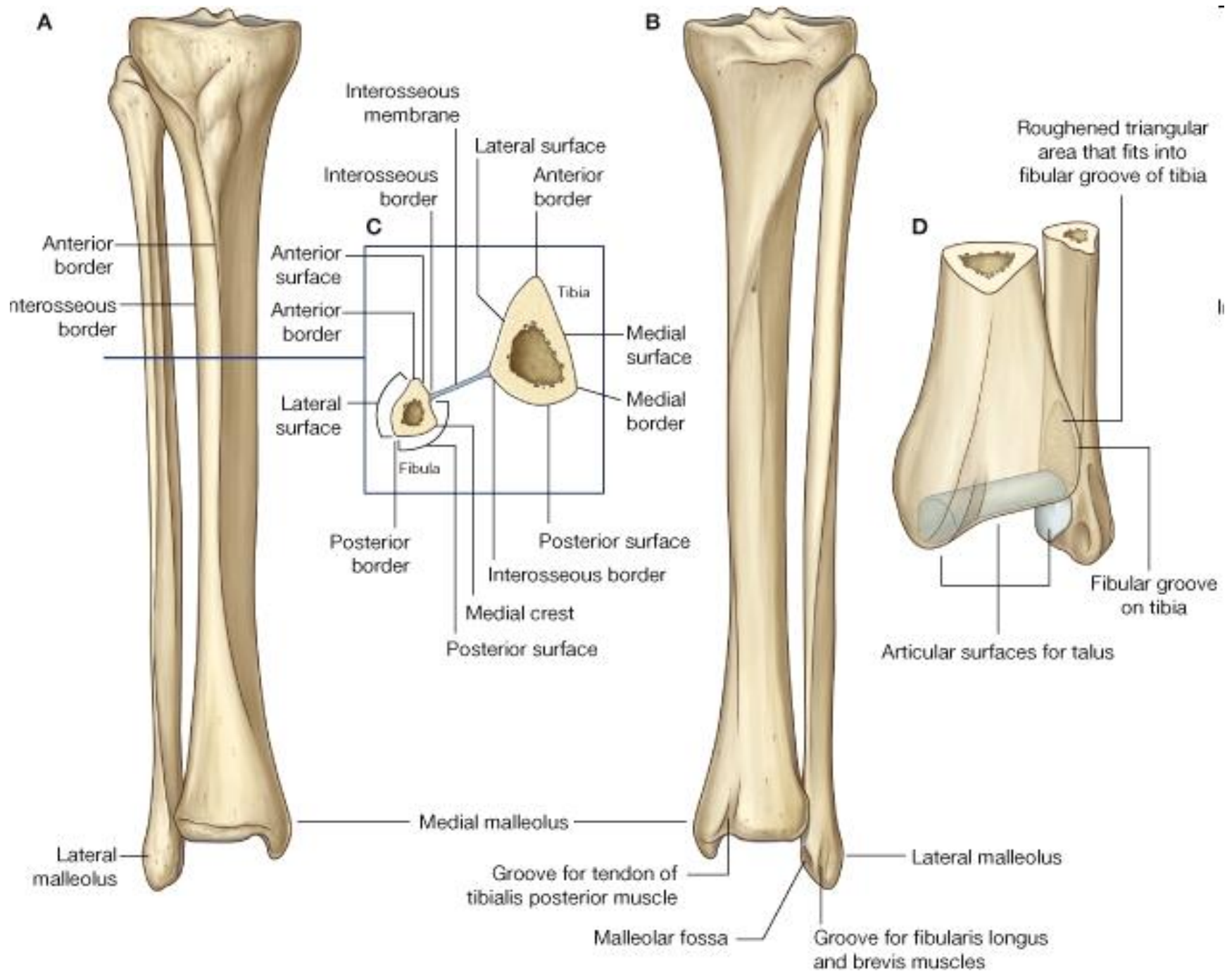
**margo anterior
margo medialis
margo posterior
margo interosseus**

distální konec:

**malleolus lateralis
facies articularis malleoli lateralis
sulcus malleoli lateralis
fossa malleoli lateralis**





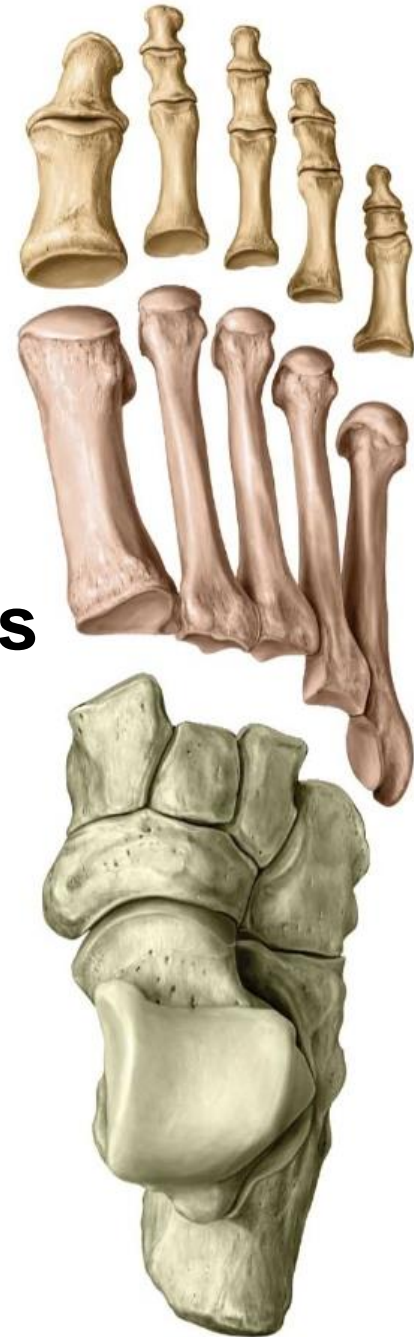

ossa pedis– kosti nohy

I. kosti zánártní– ossa tarsi

II. kosti nártní – ossa metatarsi

III. kosti prstů nohy – ossa digitorum pedis



kosti zánártní – ossa tarsi (7)

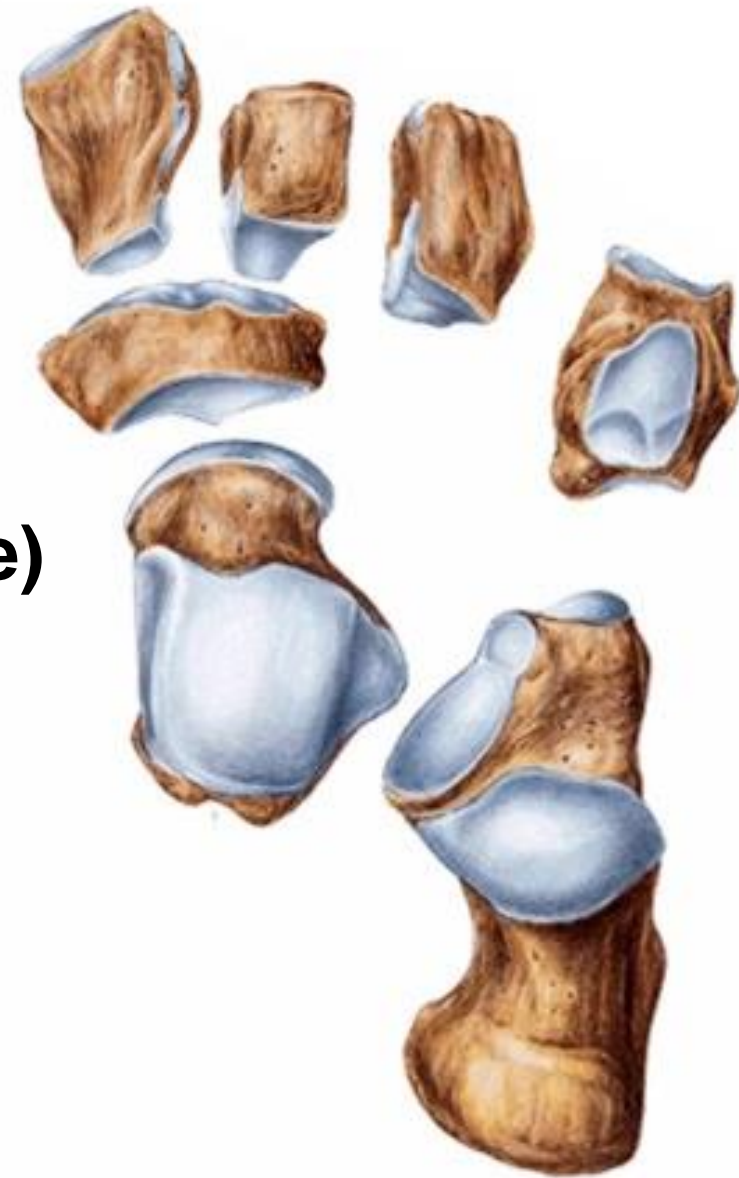Kost hlezenní – **talus**

Kost patní – **calcaneus**

Kost lod'kovitá – **os naviculare**

Kost krychlová – **os cuboideum**

Kosti klínové – **ossa cuneiformia**
(**mediale, intermedium et laterale**)



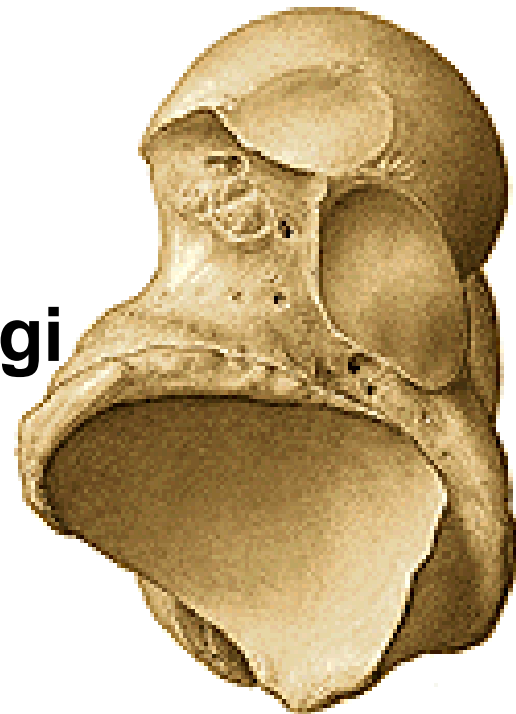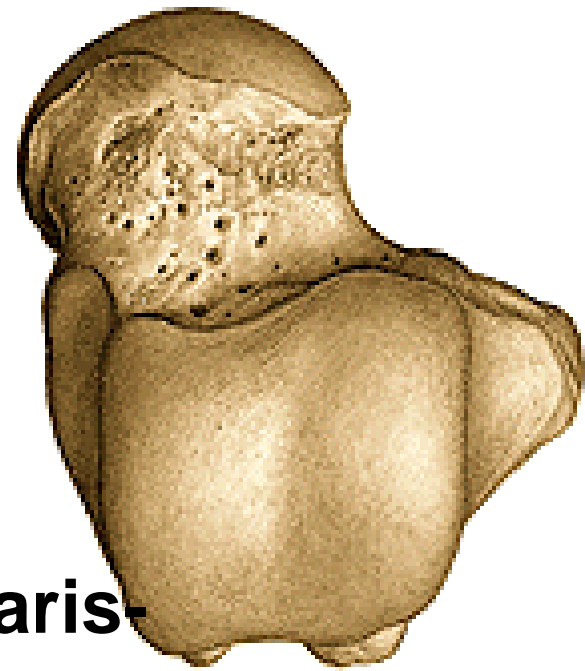
Talus – kost hlezenní

Proximální část:

corpus tali

- **dorsálně:** trochlea tali-
facies superior et maleolaris
(lateralis, medialis)
- **plantárně:** facies articularis calcanearis-
posterior, media, anterior
sulcus tali- sinus tarsi
- **processus posterior tali-**
tuberculum mediale et laterale-
sulcus tendinis m. flexoris hallucis longi
- **processus lateralis tali**

collum tali



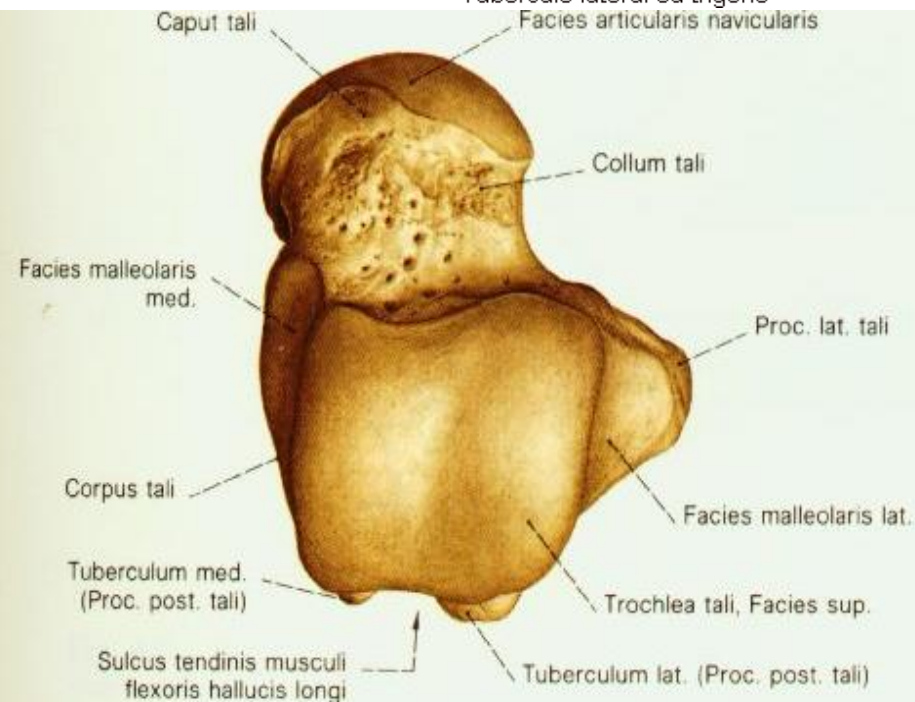
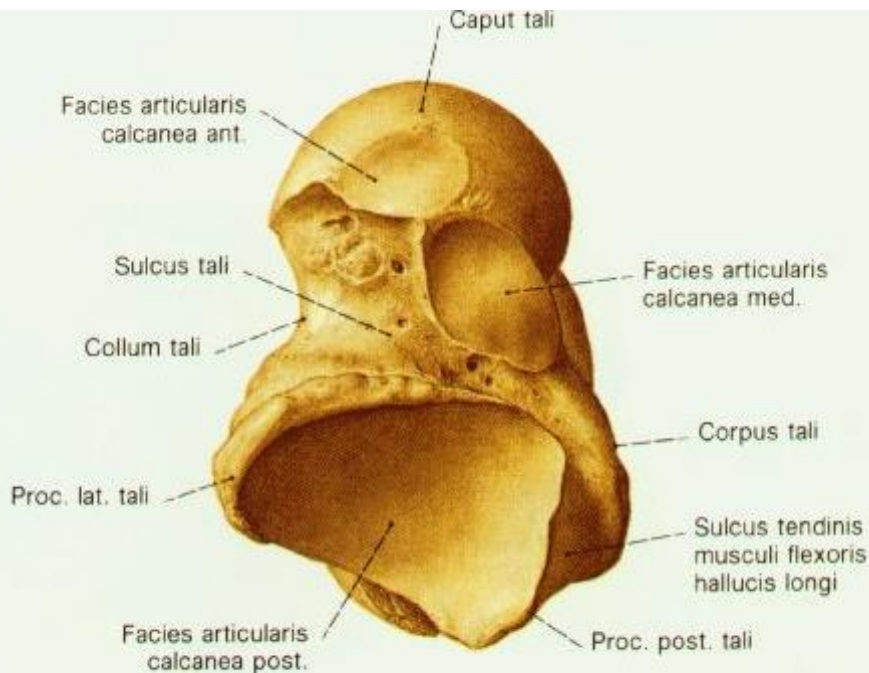
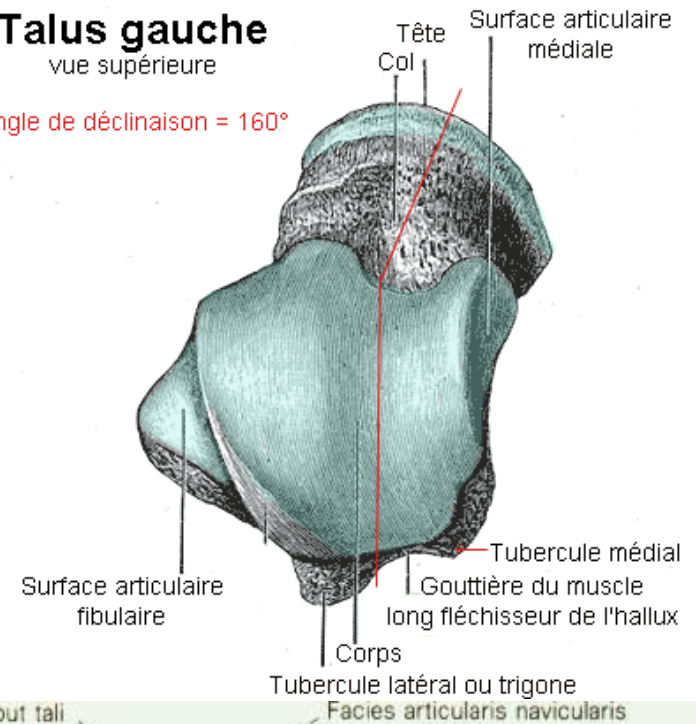
Distální část

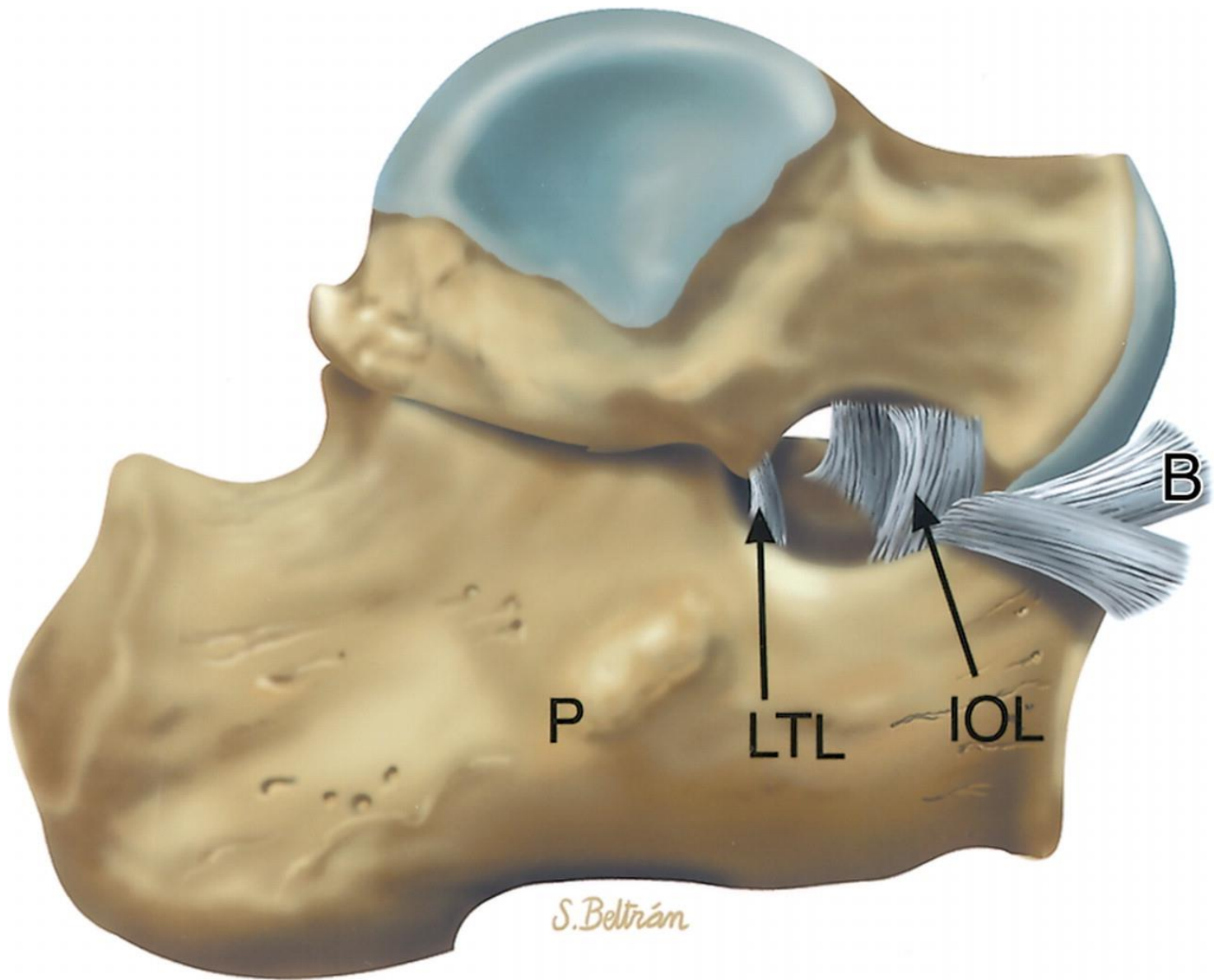
- caput tali- facies articularis navicularis

Talus gauche

vue supérieure

Angle de déclinaison = 160°

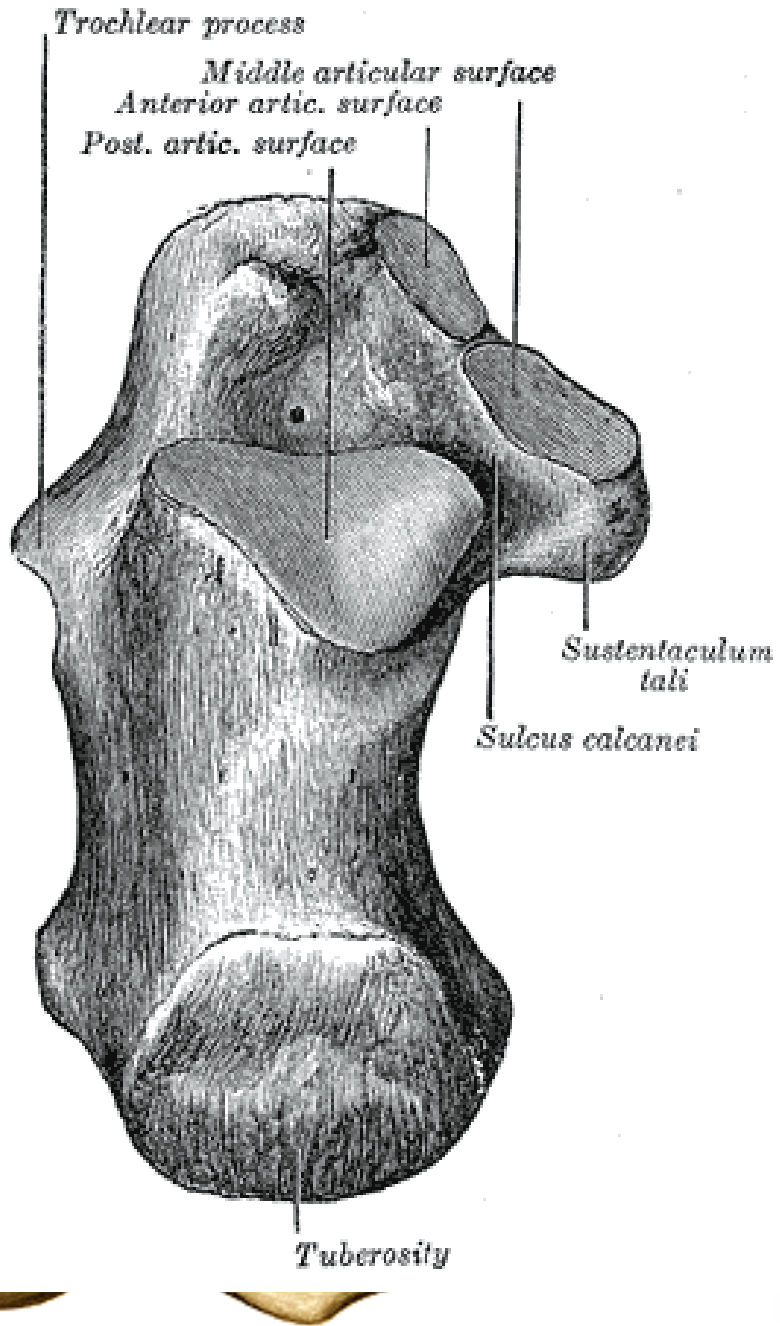




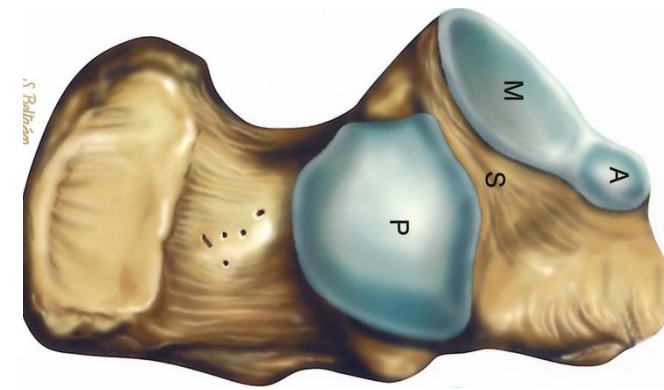
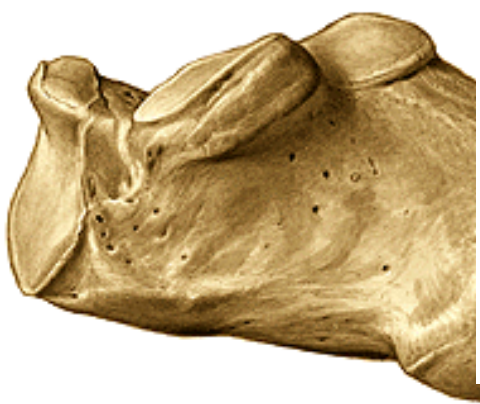

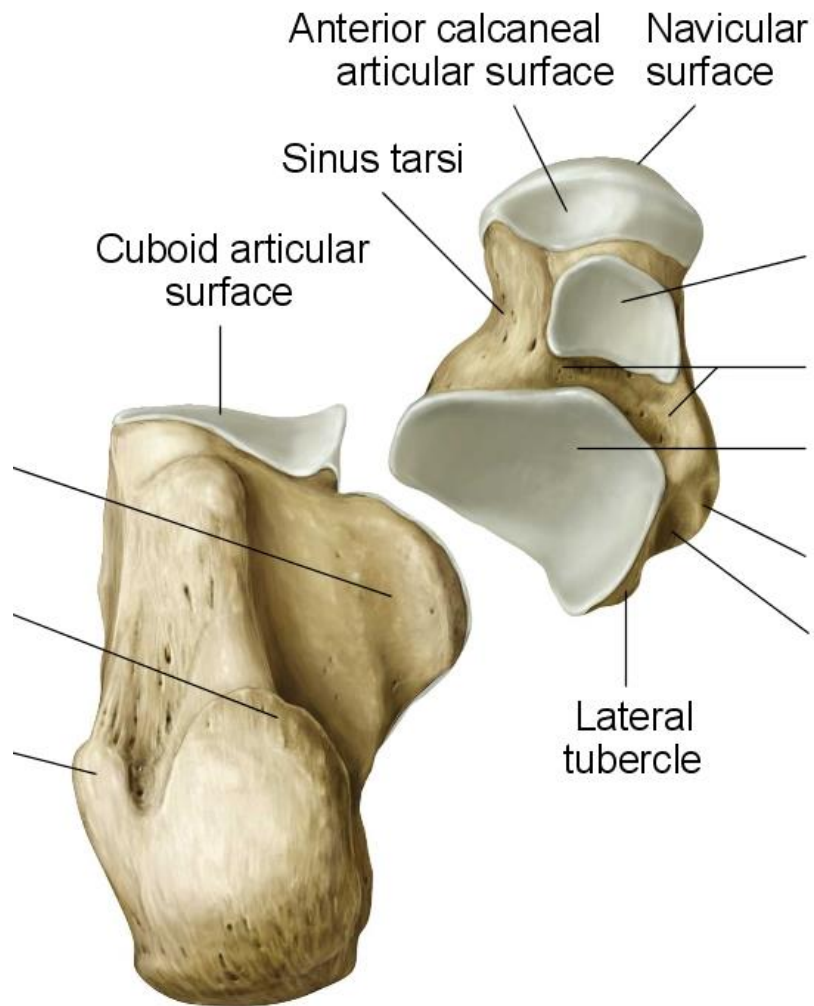
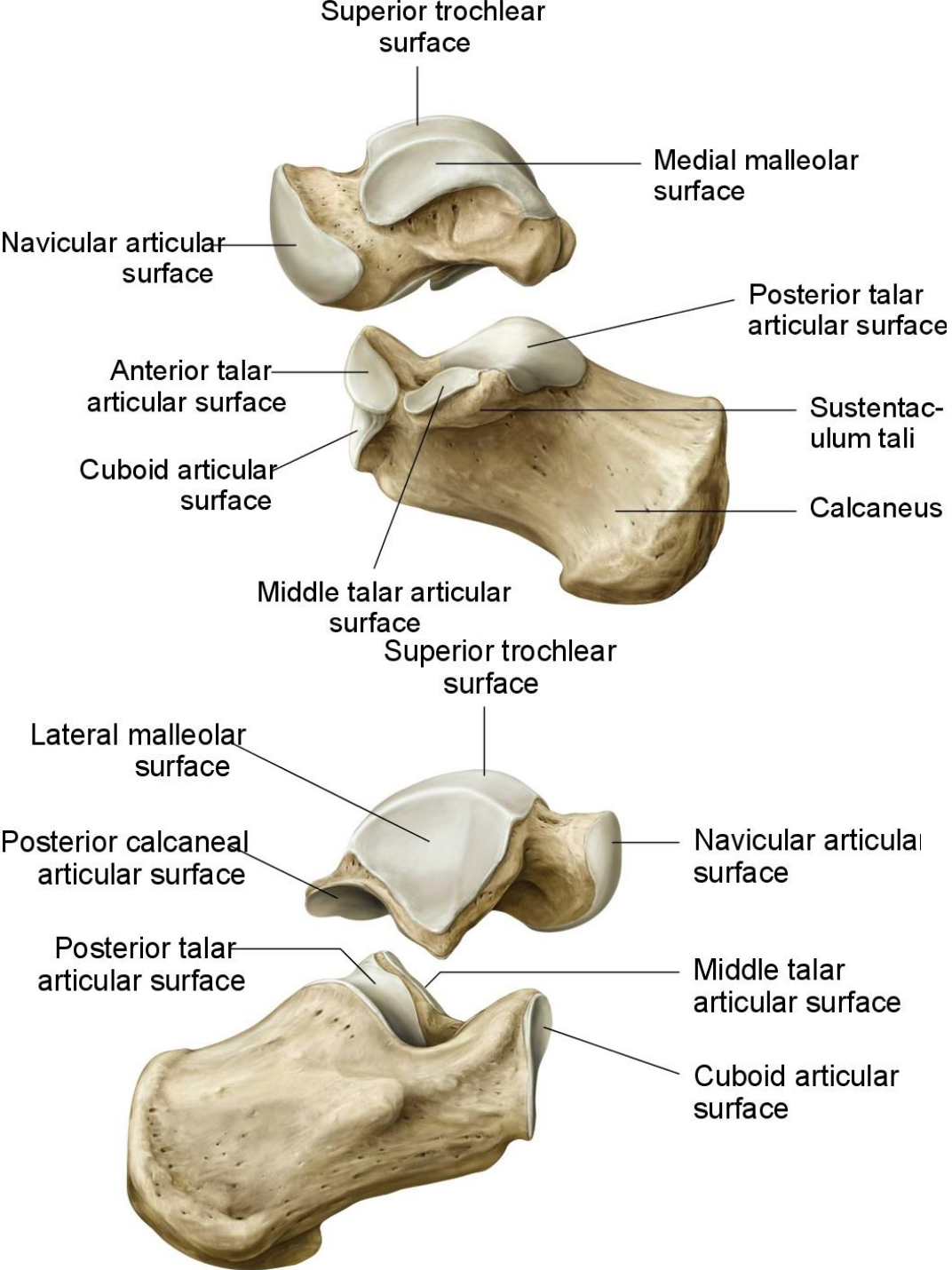
Calcaneus – potní kost

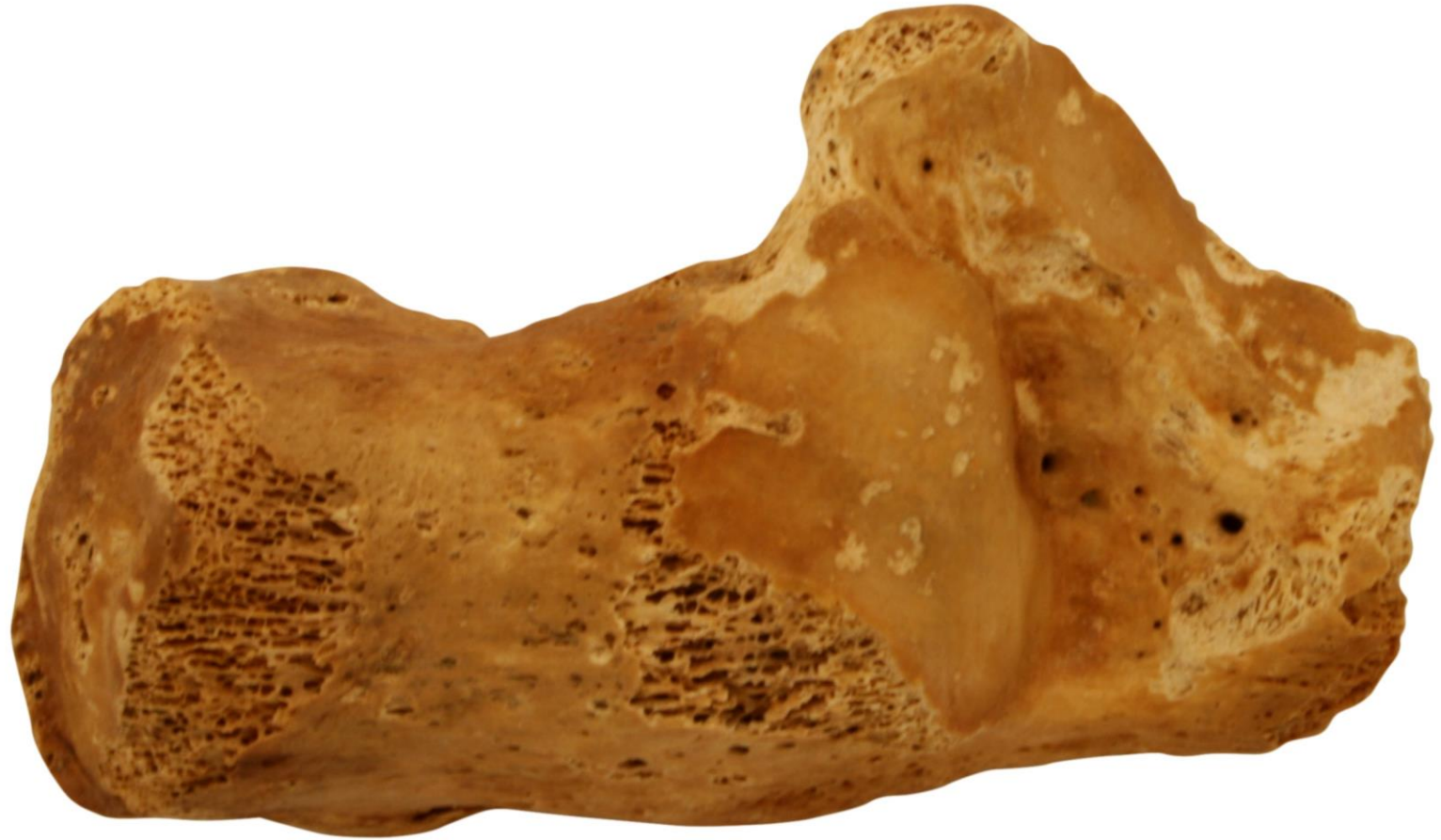- tuber calcanei
- sustentaculum tali
- hallucis longi
- trochlea peronei longi
- facies articularis superior
- facies articularis inferior
- sulcus calcanei
- sulcus



s et lateralis)
 s musculi flexoris
 is musculi
 media et anterior
 = sinus tarsi

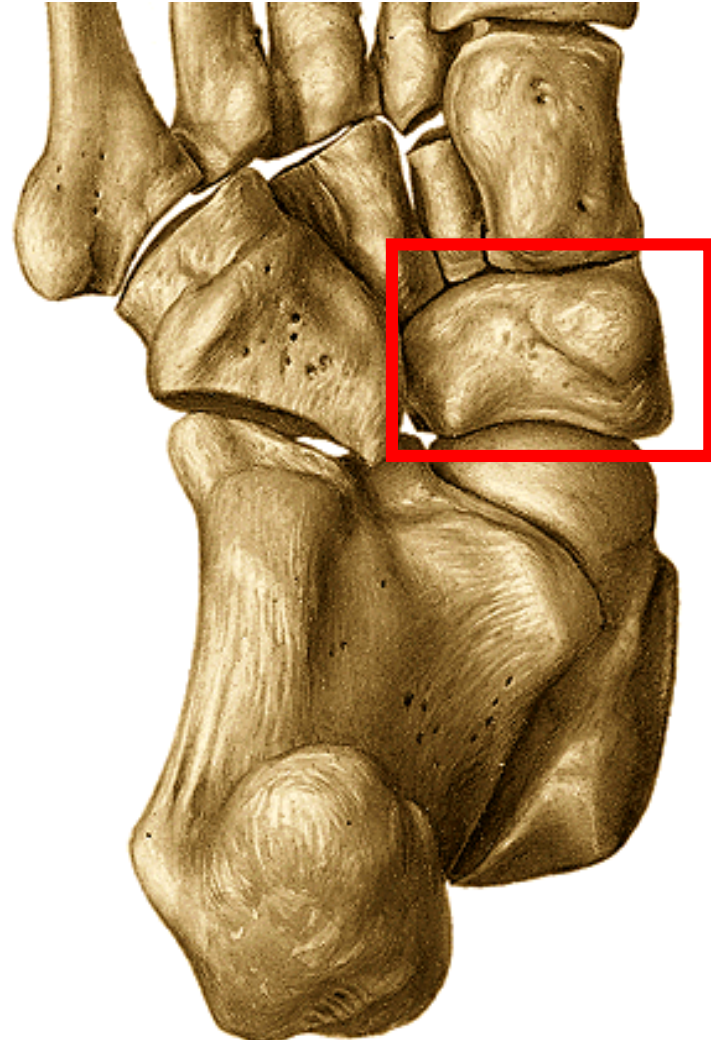
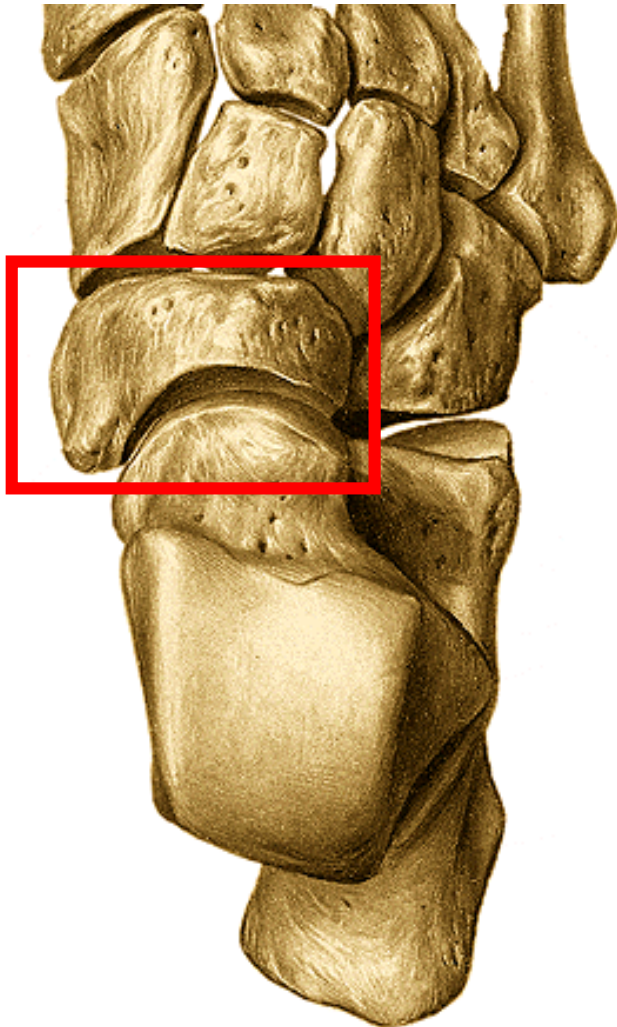






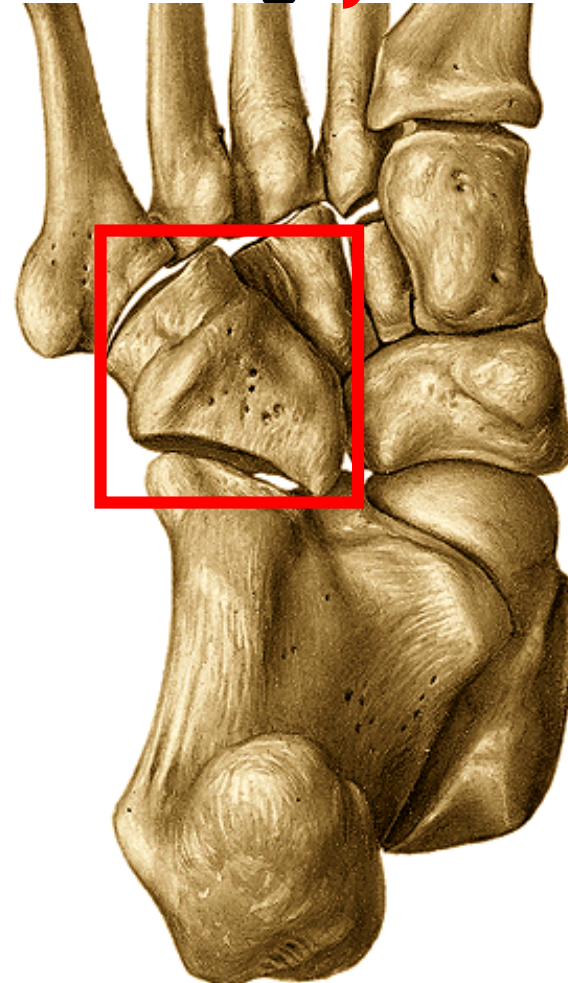
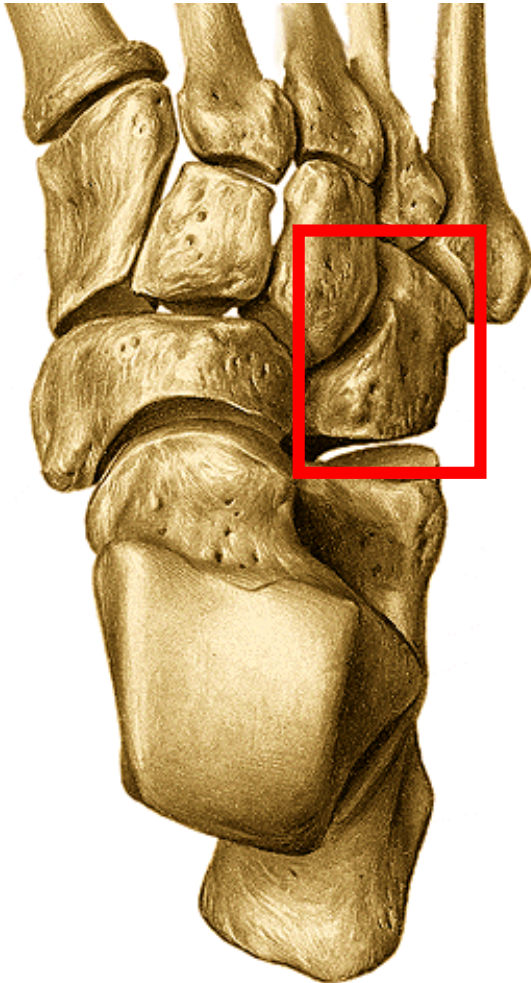
Iod'kovitá kost - os naviculare

- **facies articularis talaris**- konkávní
- **facies articularis cuneiformis**- konvexní- 3 fasety
- **tuberositas ossis navicularis**- plantárně



krychlová kost – os cuboideum

- **f. articularis calcanearis**, 2 fasety pro IV. a V. metatarsus
- plocha pro skloubení s os cuneiforme laterale
- **tuberositas ossis cuboidei**
- **sulcus tendinis musculi peronei longi** } plantárně



kosti klínové – ossa cuneiformia:

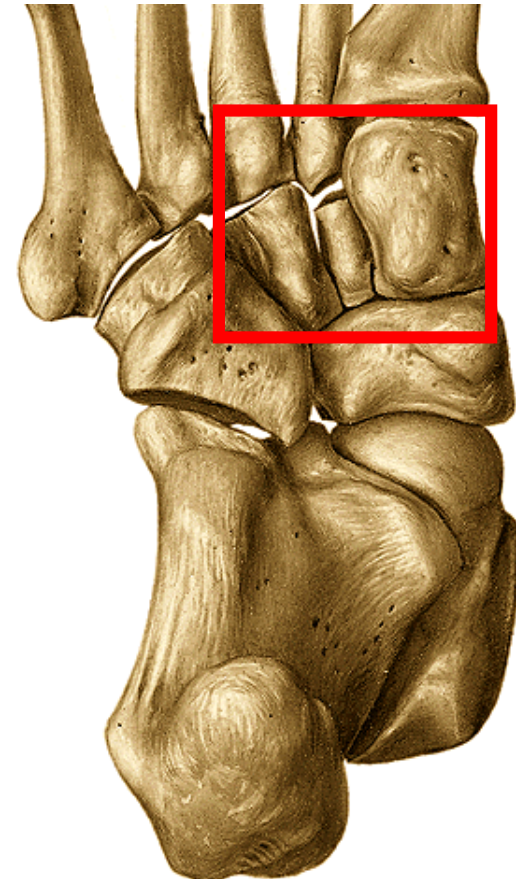
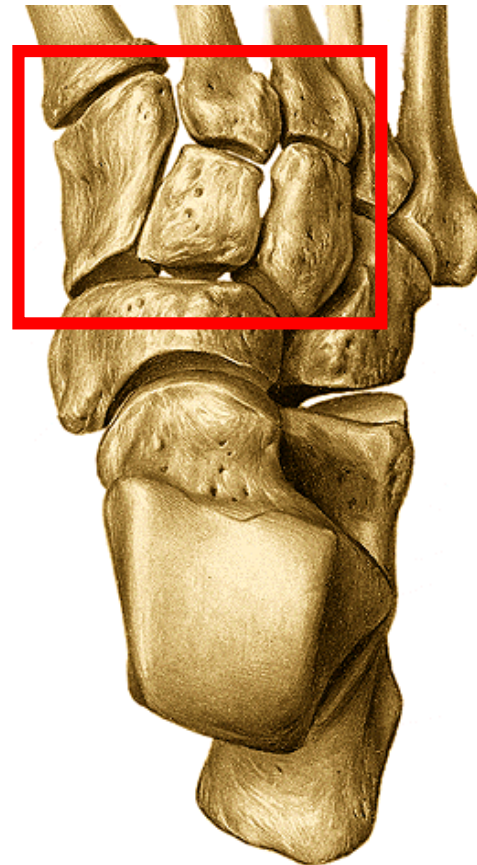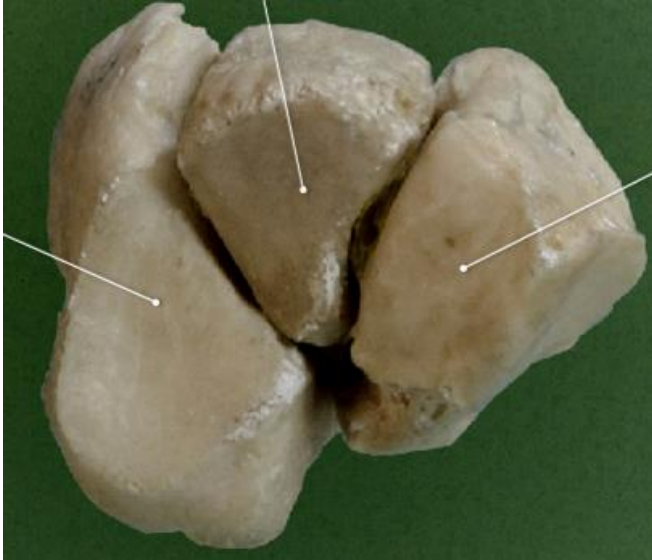
mediale, intermedium et laterale

mediale: největší- u palce- ostří klínu dorsálně

intermedium: ostří klínu plantárně

laterale: ostří klínu plantárně

podílí se na nožní klenbě

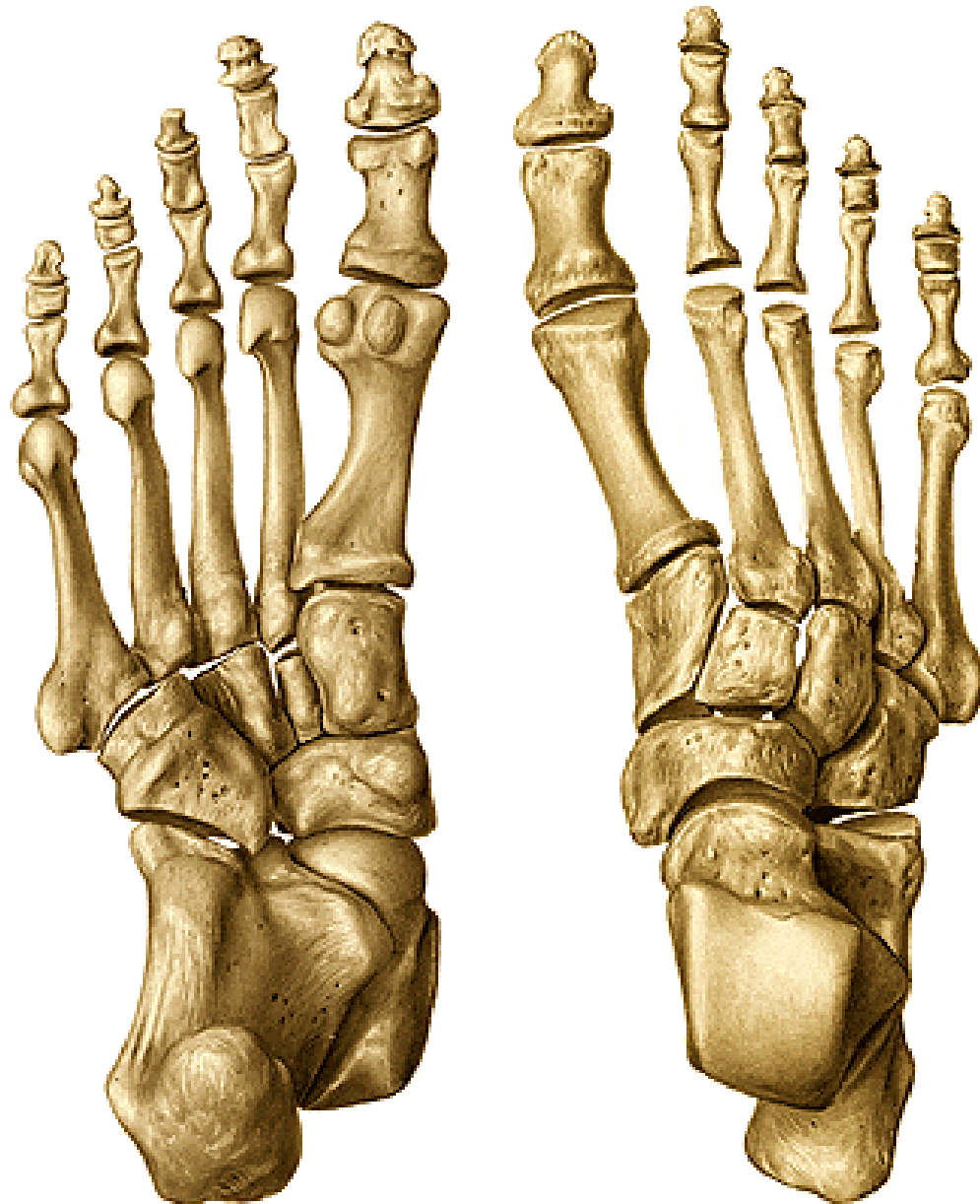

nártní kosti – ossa metatarsi (I. – V.)

basis (tuberositas ossis metatarsi I. et V.)

corpus

caput



kosti prstů nohy – ossa digitorum pedis (phalanges)

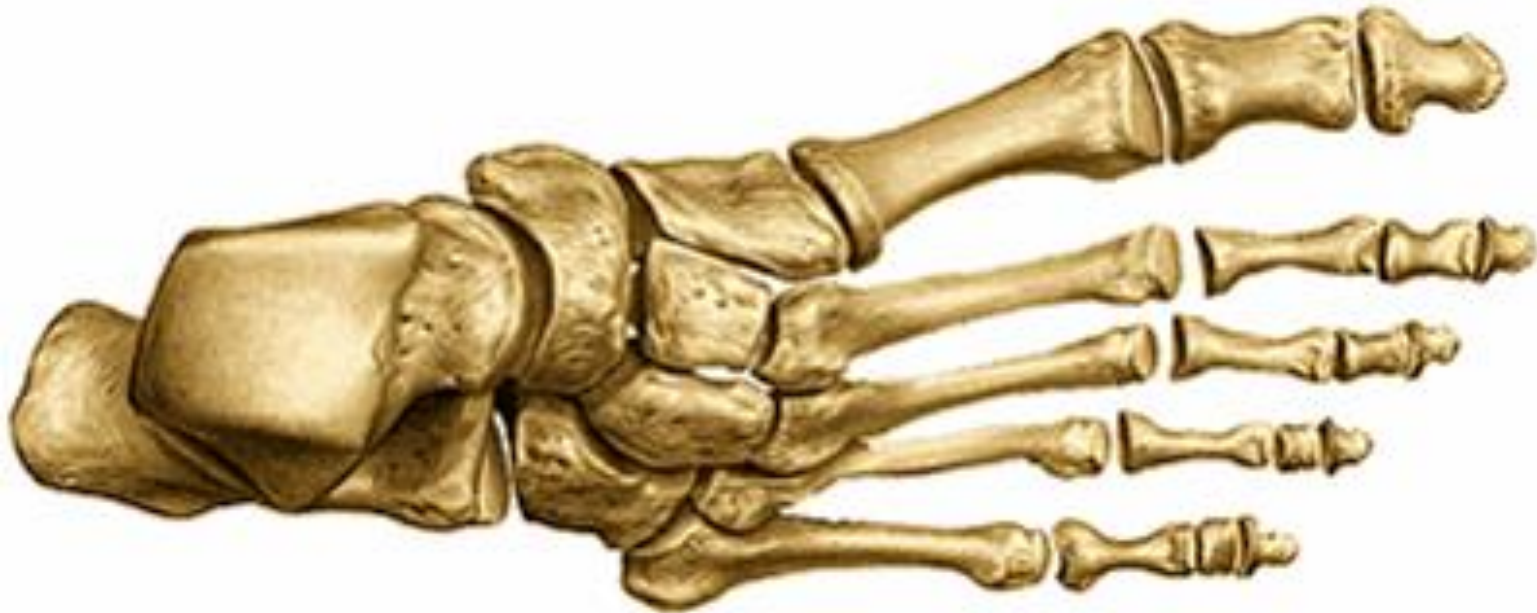palec – phalanx proximalis et distalis

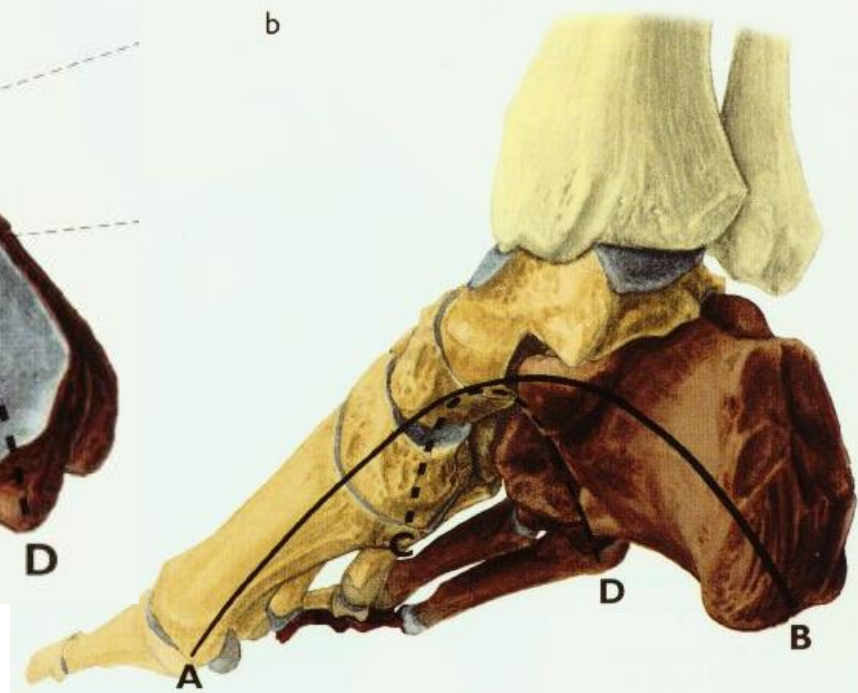
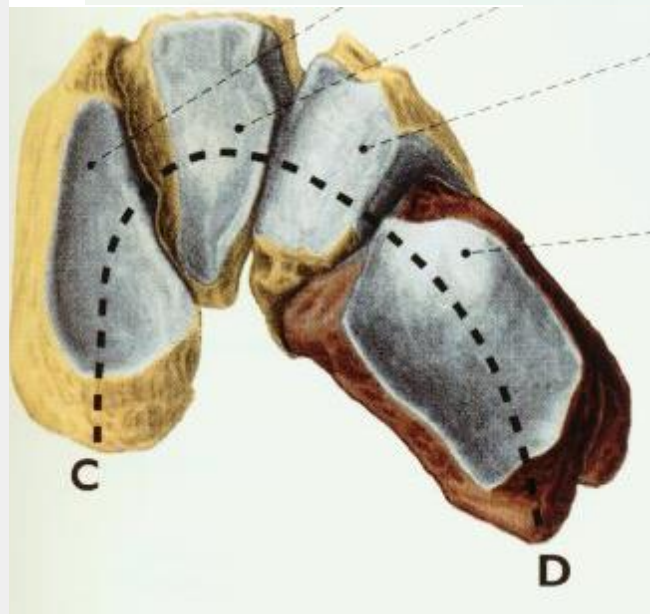
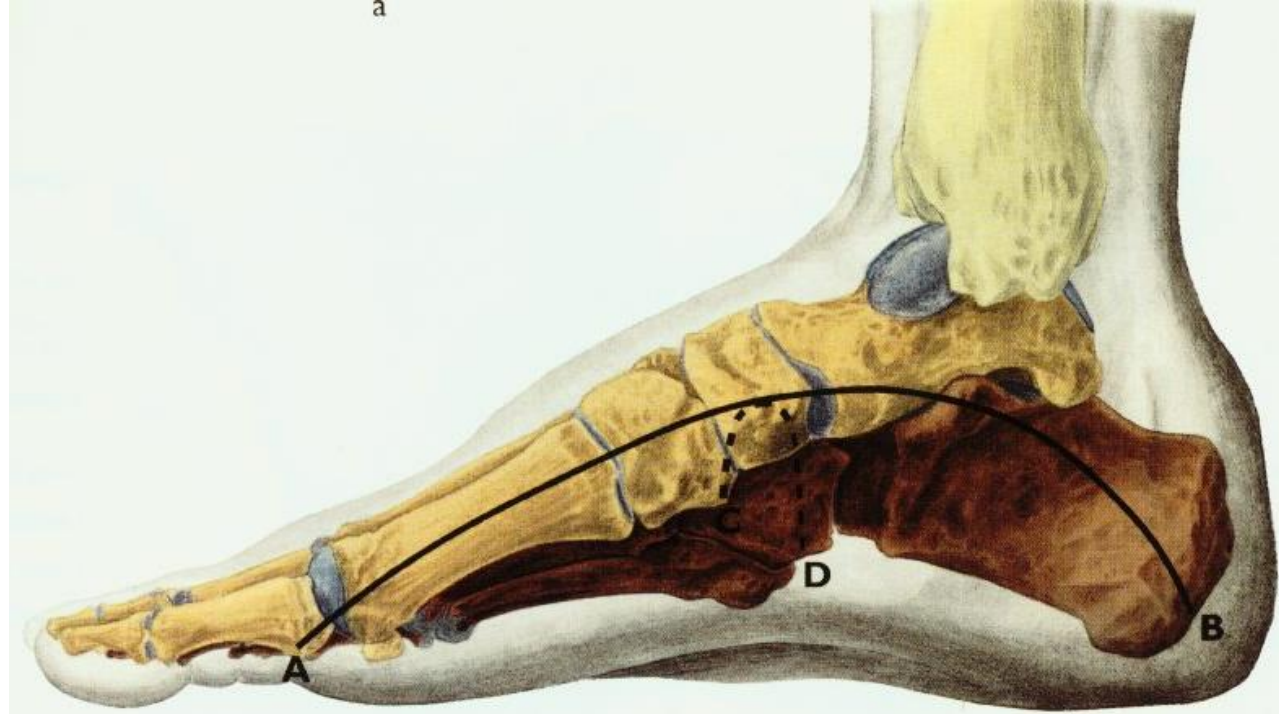
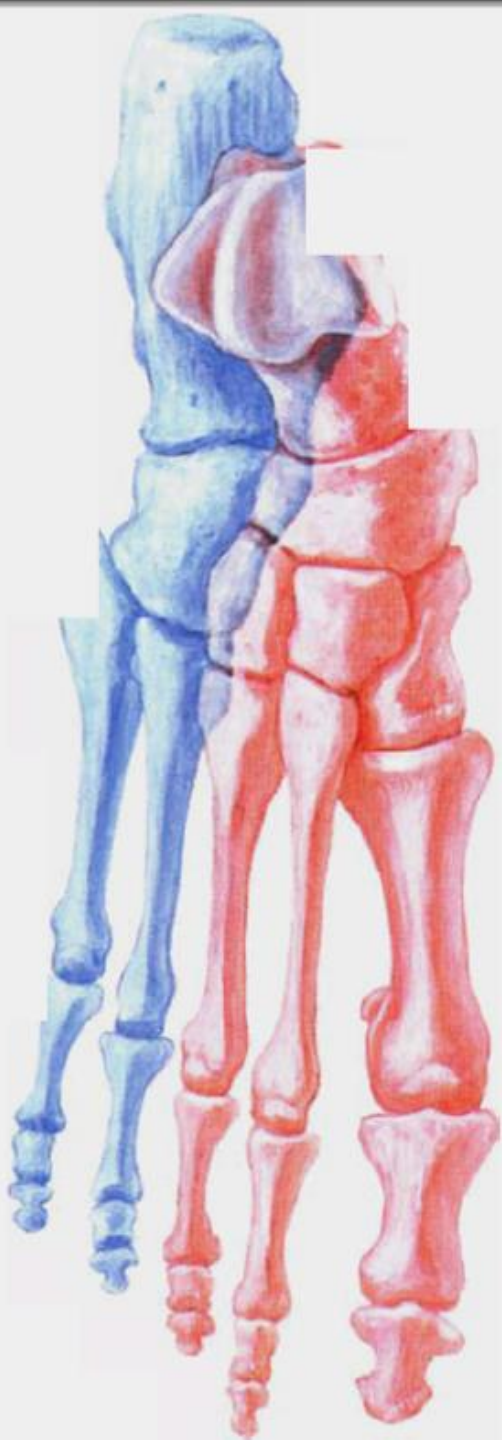
II. – V. prst – phalanx proximalis, media et distalis

basis phalangis

corpus phalangis

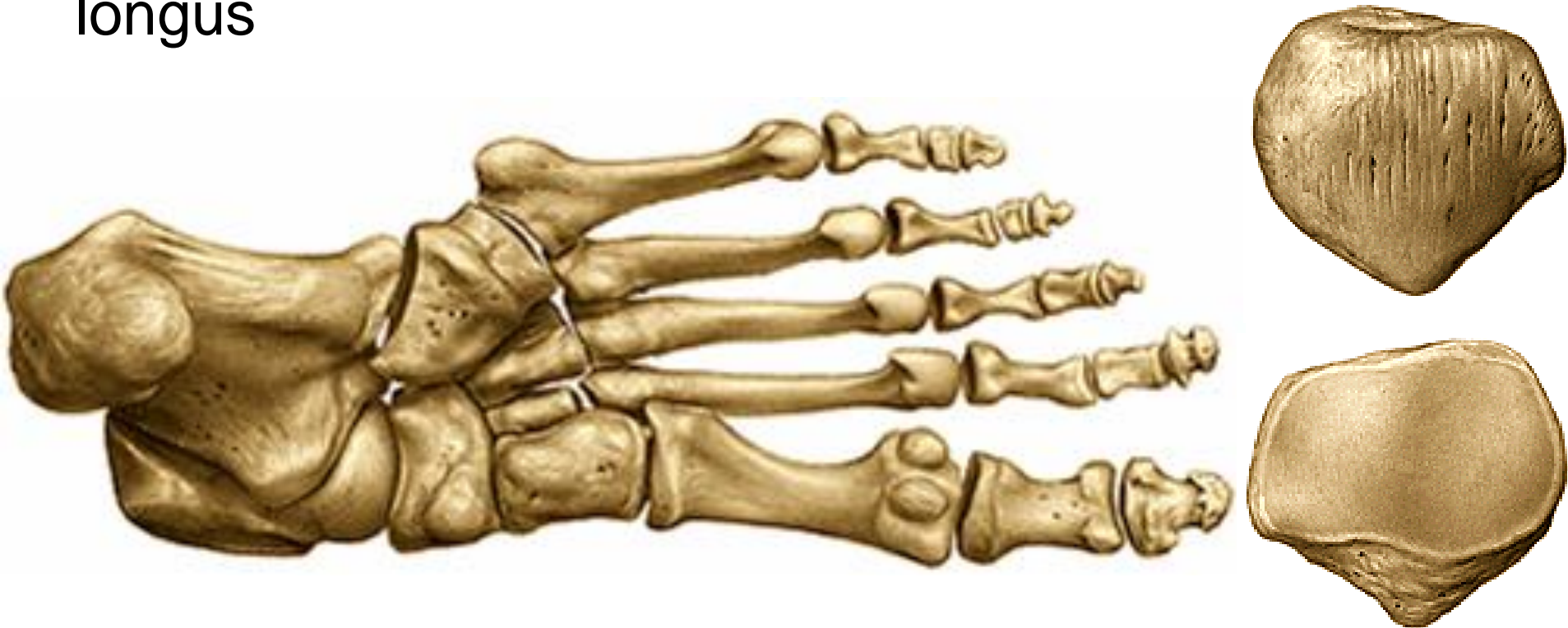trochlea (u distálního článku – tuberositas phalangis distalis)





Ossa sesamoidea

- **patella**
- pod hlavicí palcového metatarsu: 2 kůstky (laterální a mediální) **u metatarsophalangového kloubu**
- občas i pod hlavicí V. a II.metatarsu nebo na plantární ploše os cuboideum ve šlaše m.peroneus longus



Os intermetatarsale

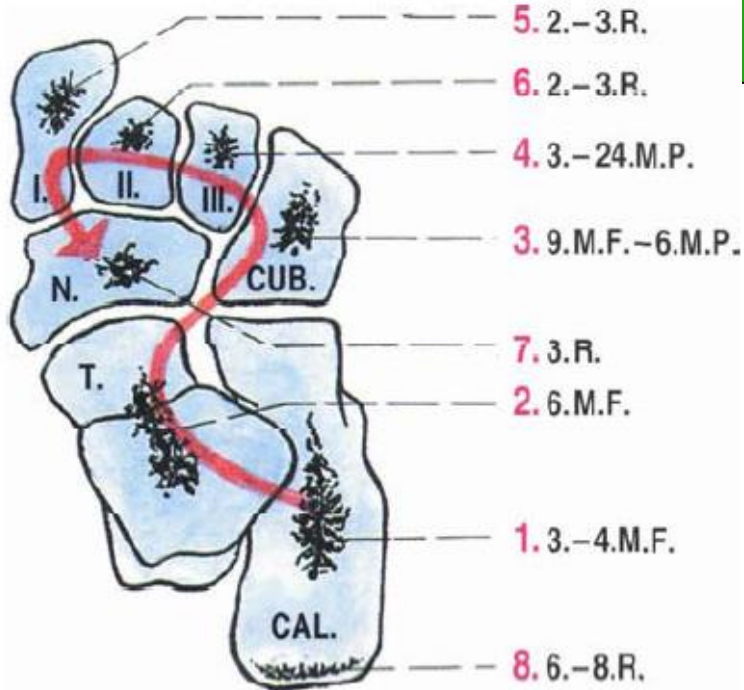
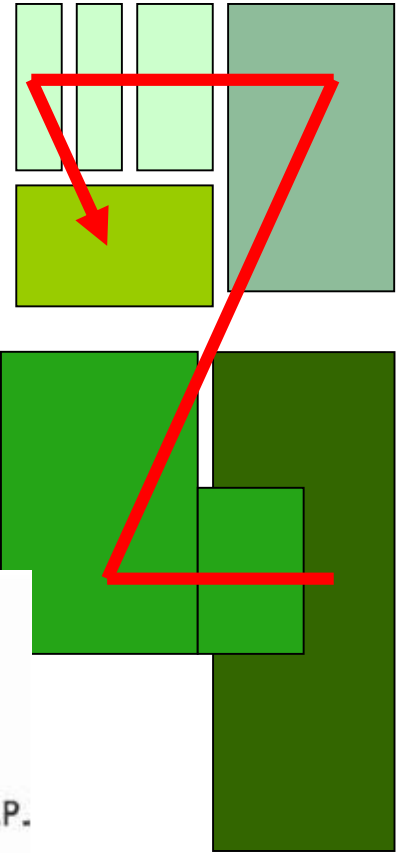
Os Vesali

osifikace

Os tibiale
exter.

Calcaneus accesorius

Os trigonum



Děkuji za pozornost

Obrázky:

Atlas der Anatomie des Menschen/Sobotta. Putz,R., und Pabst,R. 20. Auflage.

München:Urban & Schwarzenberg, 1993

Netter: Interactive Atlas of Human Anatomy.

Naňka, Elišková: Přehled anatomie. Galén, Praha 2009.

Čihák: Anatomie I, II, III.

Drake et al: Gray's Anatomy for Students. 2010