



Chest trauma



Petráš M.,.

Klinika úrazové chirurgie LF MU a TC FN Brno

Introduction

- **vital structures** – chest trauma is often sudden and dramatic
 - heart, great vessels, tracheobronchial tree and lungs
- abdominal injuries are common with chest trauma
- the most common type of injuries is blunt
- serious pathological consequences – hypoxia, hypovolaemia, myocardial failure

Physiology

- ventilation

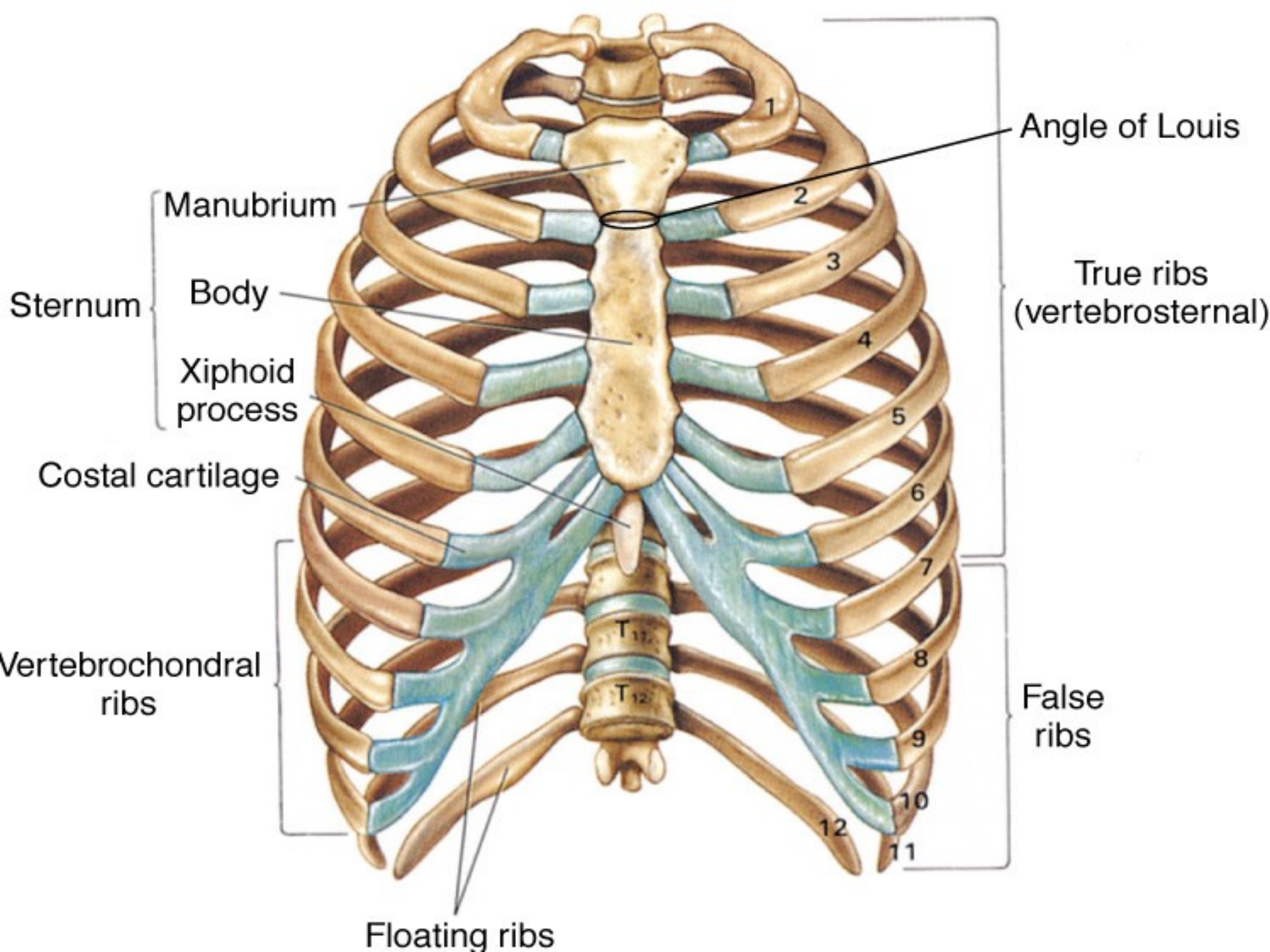
the mechanical process of moving air into and out of the lungs

- respiration

the exchange of oxygen and carbon dioxide between the outside atmosphere and the cell of the body

Anatomy

- skin
- bones
 - 12 pair of ribs
 - ribs 1-7: join at sternum with cartilage end-points
 - ribs 8-10: join at sternum with combined cartilage at 7th rib
 - ribs 11-12: no anterior attachment
 - sternum
 - thoracic spine



Angle of Louis

True ribs
(vertebrosternal)

False ribs

Manubrium

Body

Xiphoid
process

Costal cartilage

Vertebrochondral
ribs

Floating ribs

Sternum

1

2

3

4

5

6

7

8

9

10

11

12

T₁₁

T₁₂

Anatomy

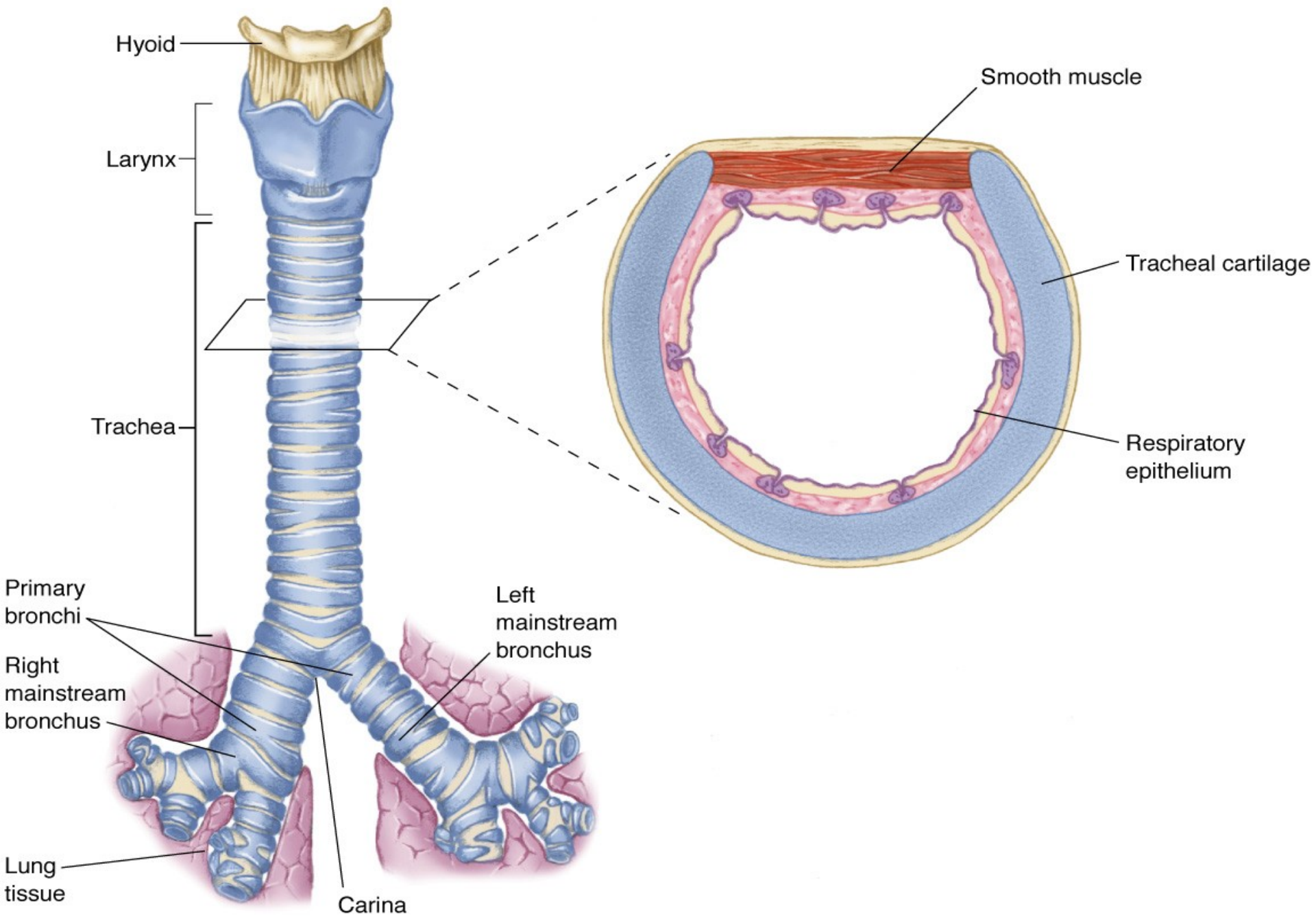
- topographical thoracic reference lines
 - midclavicular line
 - anterior axillary line
 - mid-axillary line
 - posterior axillary line
- intercostal space
 - artery, vein and nerve on inferior margin of each rib

Anatomy

- muscles of respiration
 - diaphragm
 - intercostal muscles
 - contract to elevate the ribs and increase thoracic diameter
 - increase depth of respiration
 - sternocleidomastoid
 - raise upper rib and sternum

Anatomy

- trachea
 - hollow & cartilage supported structure
- bronchi
 - right & left extend for 3 centimeters
 - enters lungs at pulmonary hilum
 - also where pulmonary arteries & veins enter
 - further subdivide and terminate as alveoli
 - basic unit of structure & function in the lungs
 - single cell membrane
- lungs
 - right = 3 lobes
 - left = 2 lobes

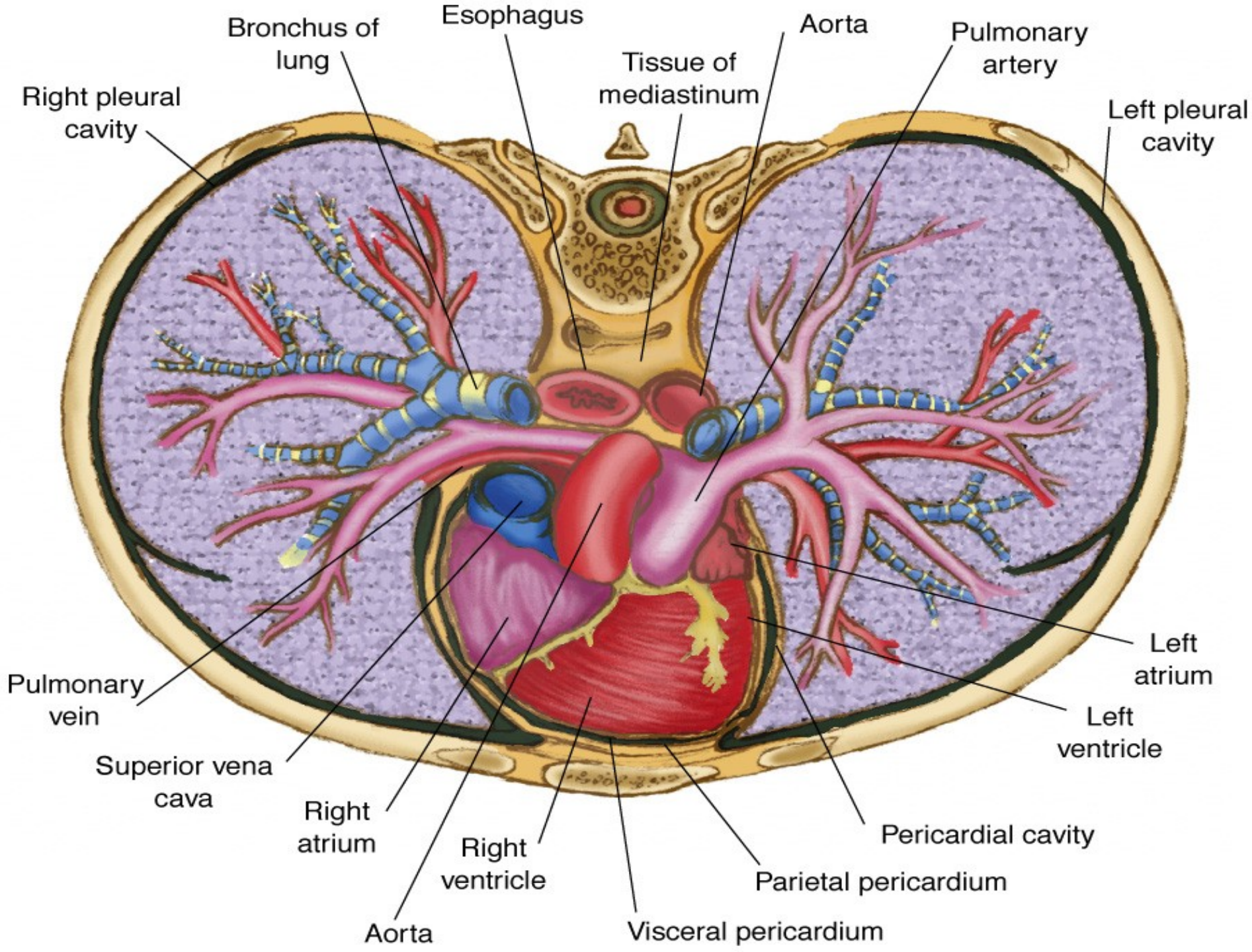


Anatomy

- pleura
 - visceral pleura
 - cover lungs
 - parietal pleura
 - lines inside of thoracic cavity
 - pleural space
 - POTENTIAL SPACE
 - Air in Space = PNEUMOTHORAX
 - Blood in Space = HEMOTHORAX
 - serous (pleural) fluid within

Anatomy

- mediastinum
 - central space within thoracic cavity
 - boundaries
 - lateral: lungs
 - inferior: diaphragm
 - superior: thoracic outlet
 - structures
 - heart
 - great vessels
 - esophagus
 - trachea
 - nerves
 - vagus
 - phrenic
 - thoracic duct



Classifications

- skeletal injury
- pulmonary injury
- heart and great vessel injury
- diaphragmatic injury

Classification mechanism of injury

- blunt thoracic injuries - most common
- forces distributed over a large area

deceleration

compression

age factors

- pediatric thorax: more cartilage = absorbs forces
- geriatric thorax: calcification & osteoporosis = more fractures

- penetrating thoracic injuries

Pathophysiology

- impairments in cardiac output
 - blood loss
 - increased intrapleural pressures
 - blood in the pericardial sac
 - vascular disruption
- impairments in gas exchange
 - atelectasis
 - contused lung tissue
 - disruption of the respiratory tract

Assessment findings

- pulse
 - deficit
 - tachycardia
 - bradycardia
- blood pressure
 - narrowed pulse pressure
 - hypertension
 - hypotension

Assessment findings

- respiratory rate and effort
 - tachypnea
 - bradypnea
 - laboured
 - other evidence of respiratory distress

Assessment findings

- Skin

- diaphoresis

- pallor

- cyanosis

- open wounds

- other evidence of trauma

Assessment - neck

- position of trachea
- subcutaneous emphysema
- jugular venous distention
- penetrating wounds

Assessment - chest

- contusions
- tenderness
- asymmetry
- lung sounds
 - absent or decreased
 - unilateral
 - bilateral
 - location
 - bowel sounds in hemothorax

Rib fractures

- incidence

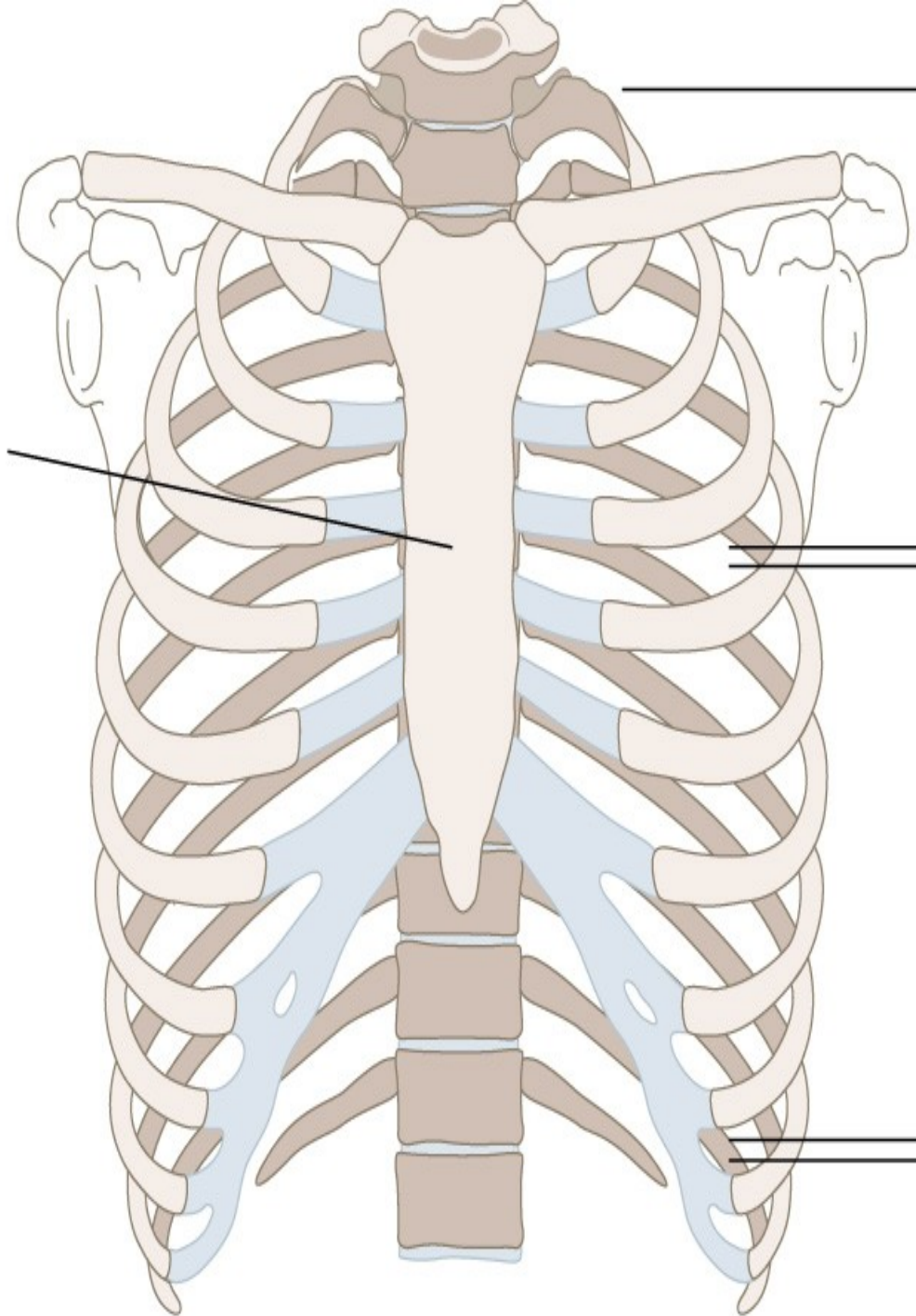
- is the most common thoracic injury
- most often elderly patients

older ribs are more brittle and rigid

- ribs 3 to 8 are fractured most often
- they are thin and poorly protected

- lower ribs fracture are associated with spleen and liver injury

Great force is required for sternal fractures.



Ribs 1–3 are well protected by shoulder bones and muscles.

Ribs 4–9 are most frequently fractured.

Ribs 10–12 are relatively mobile and fracture less frequently.

Rib fractures

- signs and symptoms
 - localized pain
 - crepitus

Rib fractures

- management
 - analgesics – for pain and improve chest excursion
 - oxygen
 - encourage coughing and deep breathing
 - position of comfort

Flail chest

- 3 or more ribs broken in 2 or more places
- segment of the chest that becomes free to move with the pressure changes of respiration

Flail chest

- signs and symptoms
 - chest pain
 - crepitus
 - respiratory distress
 - tachypnea
 - paradoxical chest wall movement

Flail chest

- management

- analgesics

- oxygen

position of comfort

stabilize the flail segments

endotracheal intubation, positive pressure

ventilation

Sternal fracture

- high association with myocardial or lung injury

myocardial contusion

myocardial rupture

cardiac tamponade

pumonary contusion

association with thoracic vertebrae fractures

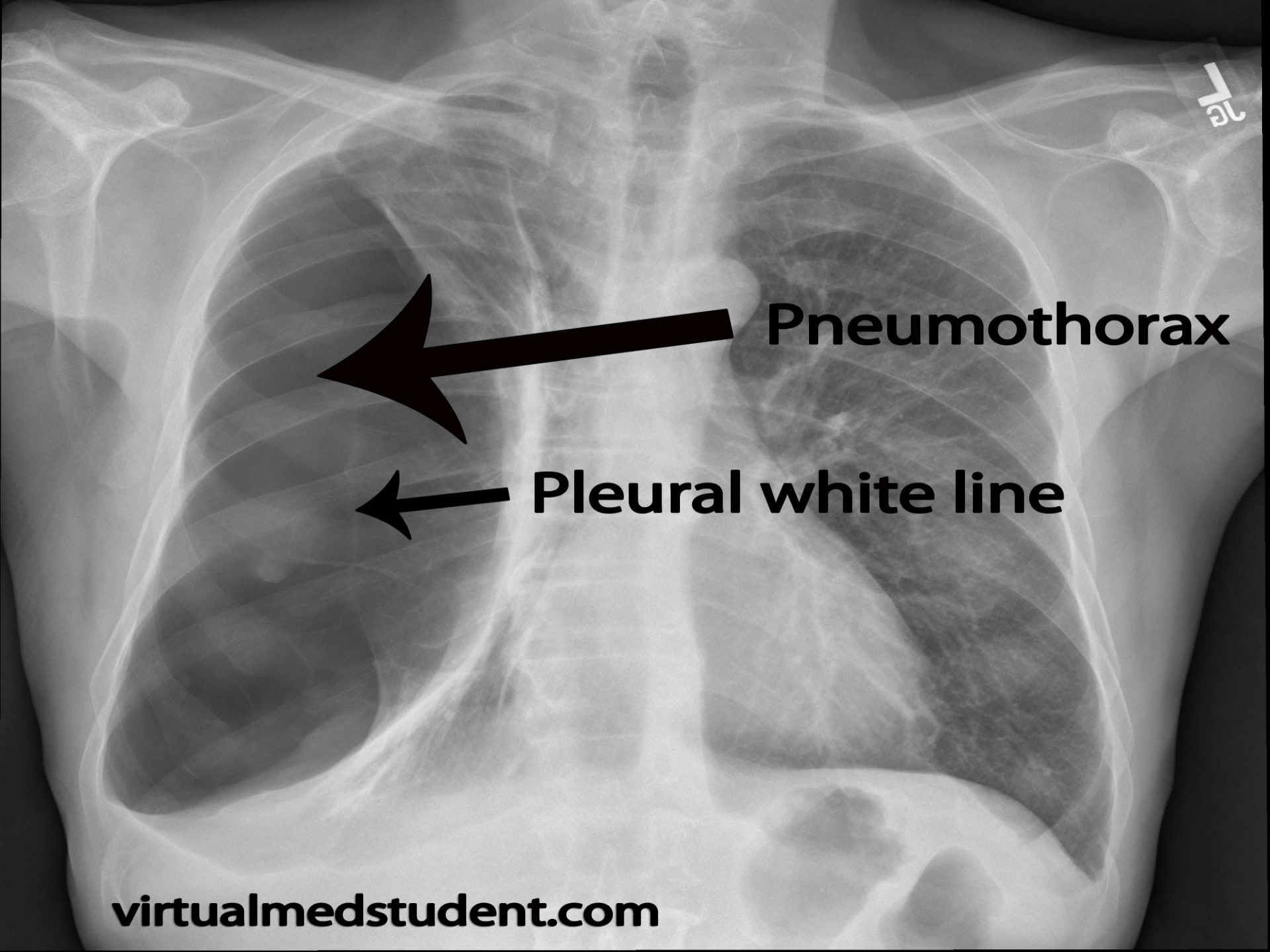
Sternal fracture

- management
 - analgesics
 - high –concentration oxygen
 - restrict fluids if pulmonary contusion suspected
 - transport to cardiology if myocardial injury suspected

Pulmonary injury

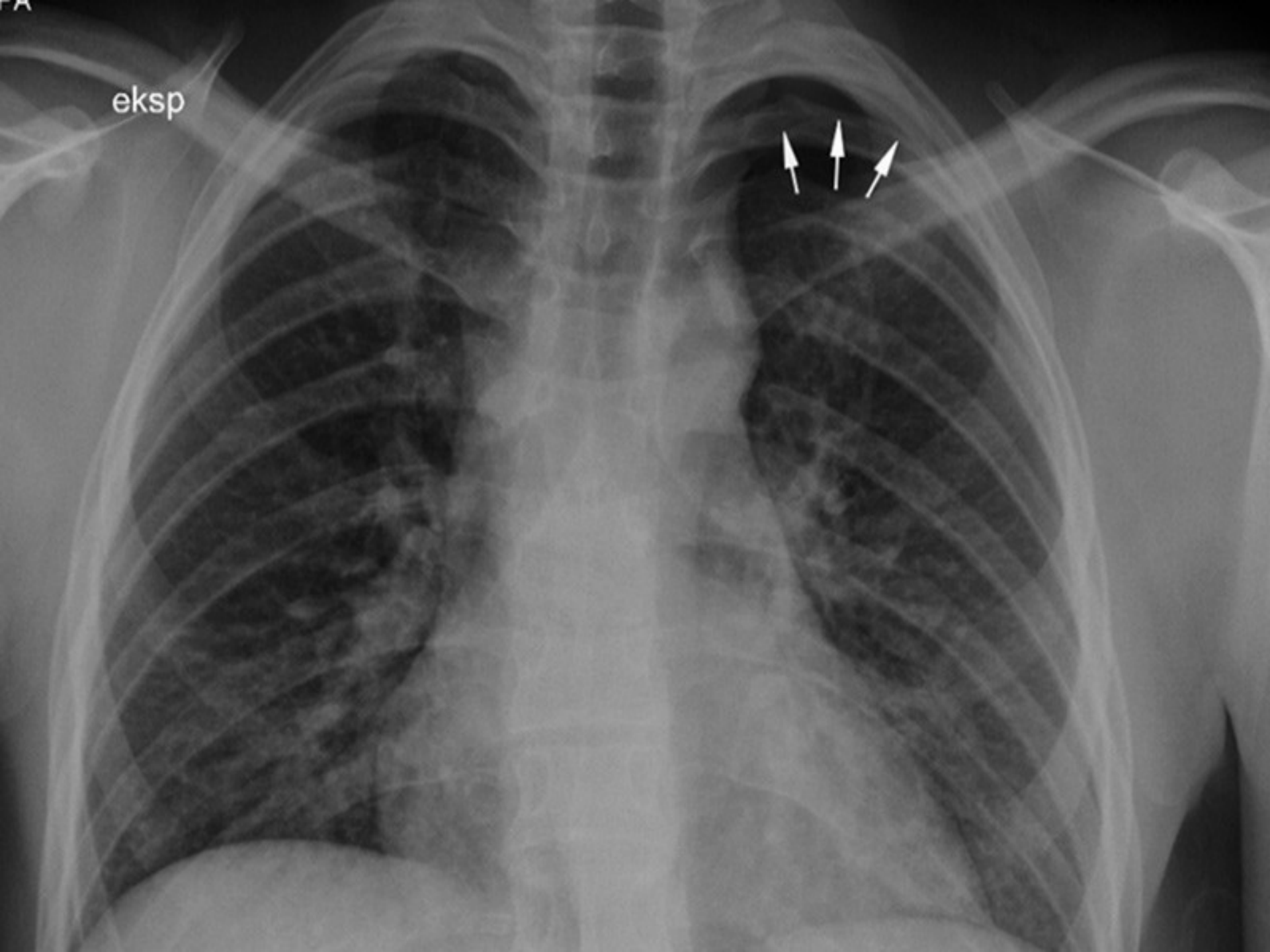
Closed pneumothorax

- occurs when lung tissue is disrupted and air leaks into the pleural space
- incidence
 - 10% to 30% in blunt chest trauma
- morbidity/ mortality
 - extent of atelectasis
 - associated injuries



Pneumothorax

Pleural white line



eksp



Pulmonary injury

Closed pneumothorax

- signs and symptoms
 - absent or decreased breath sounds on the injured side
 - hyperresonant percussion
 - tachypnea
 - dyspnea
 - chest pain referred to the shoulder or arm on the injured side
 - respiratory distress

Pulmonary injury

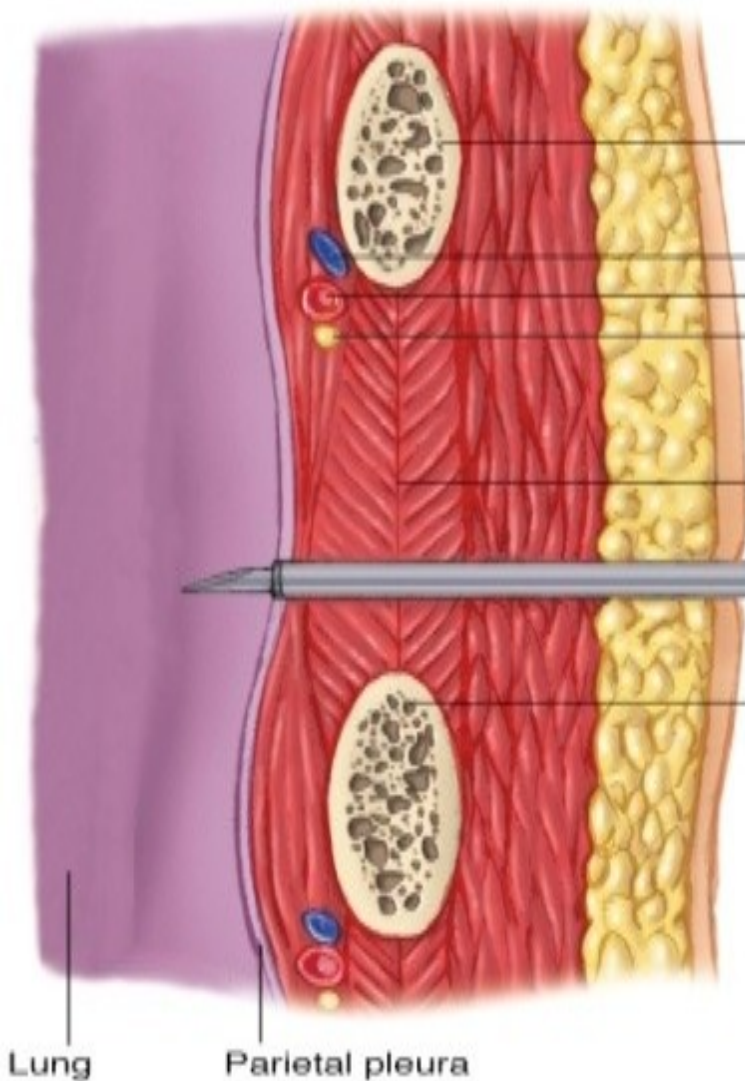
Closed pneumothorax

- Management
 - analgesics
 - position of comfort
 - high –concentration oxygen
 - positive-pressure ventilation if necessary
 - if respiration is rate <12 or >28 per minute, ventilatory assistance with a bag-valve mask may be indicated

Pulmonary injury

Closed pneumothorax

- management
 - tube thoracostomy – pleural decompression
 - 4nd intercostal space in mid-axillary line
 - TOP OF RIB



2nd rib

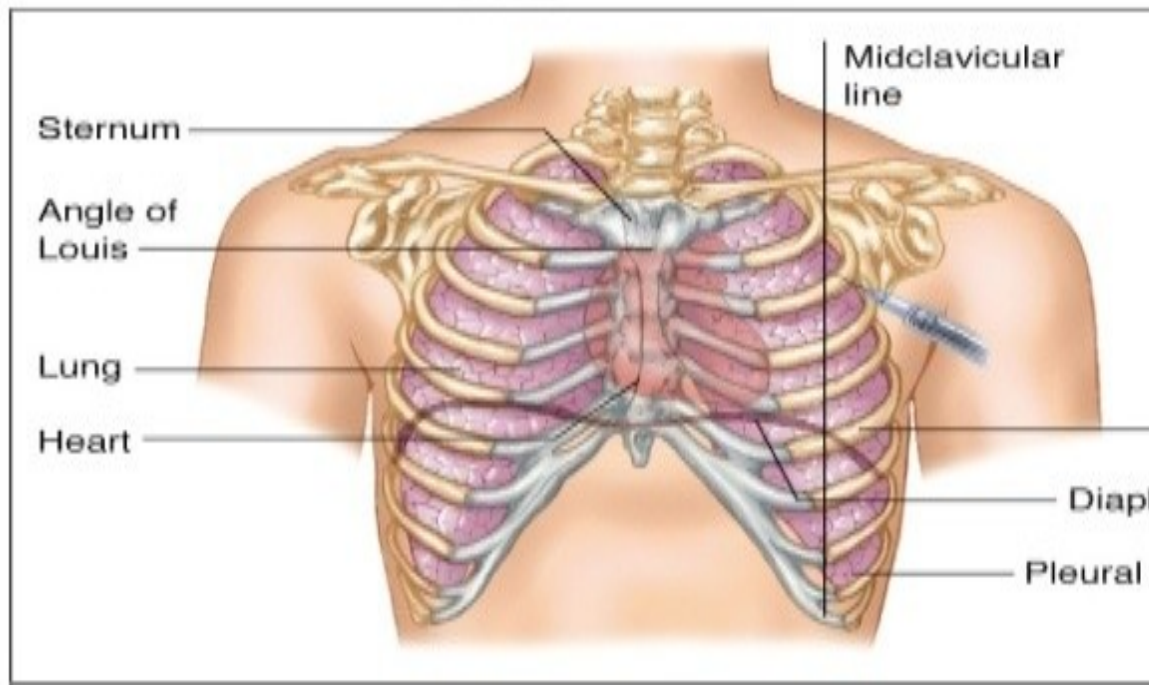
The intercostal vessels and nerves are located at the inferior borders of the ribs.

To avoid damaging the intercostal neurovascular bundle with needle or catheter, follow the upper border of the 3rd rib in entering the pleural space.

3rd rib

Lung

Parietal pleura



Sternum

Angle of Louis

Lung

Heart

Midclavicular line

Diap

Pleural

Pulmonary injury

Open pneumothorax

- incidence

 - gunshot wounds

 - knife wounds

 - falls

 - motor vehicle collisions

- If the chest wound opening is greater than two-thirds the diameter of the trachea, air follows the path of least resistance through the chest wall with each inspiration

Pulmonary injury

Open pneumothorax

- signs and symptoms
 - decreased breath sounds on the injured side
 - a defect in the chest wall
 - a sucking sound on inhalation
 - subcutaneous emphysema
 - tachypnea
 - tachykardia
 - respiratory distress

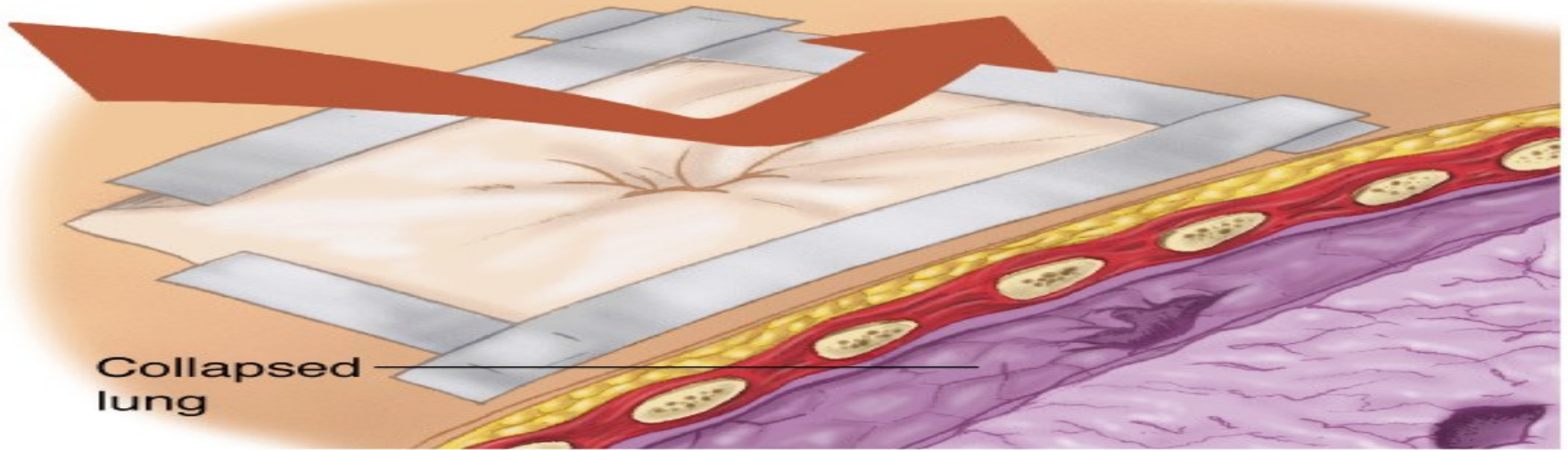
Pulmonary injury

Open pneumothorax

● management

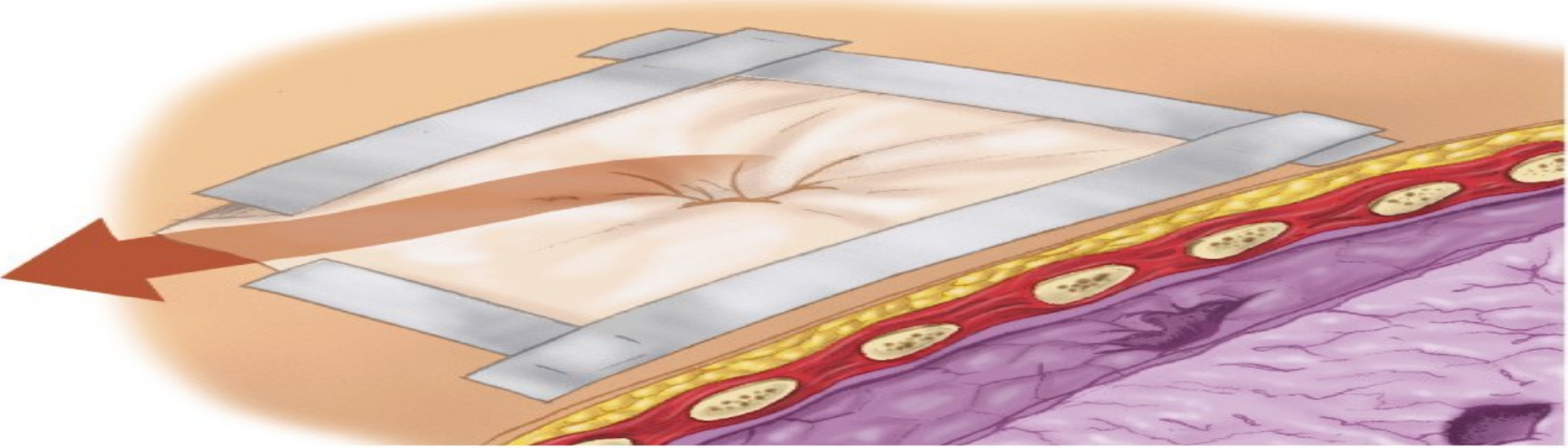
- analgesics
- high – flow oxygen
- positive-pressure ventilation if necessary
- ventilatory assistance with a bag-valve mask
- circulation – treat for shock with crystalloid infusion
- cover site with sterile occlusive dressing taped on three sides
- tube thoracostomy, videothoracoscopy, thoracotomy – in- hospital management

On inspiration, dressing seals wound, preventing air entry



Collapsed lung

Expiration allows trapped air to escape through untaped section of dressing



Pulmonary injury

Tension pneumothorax

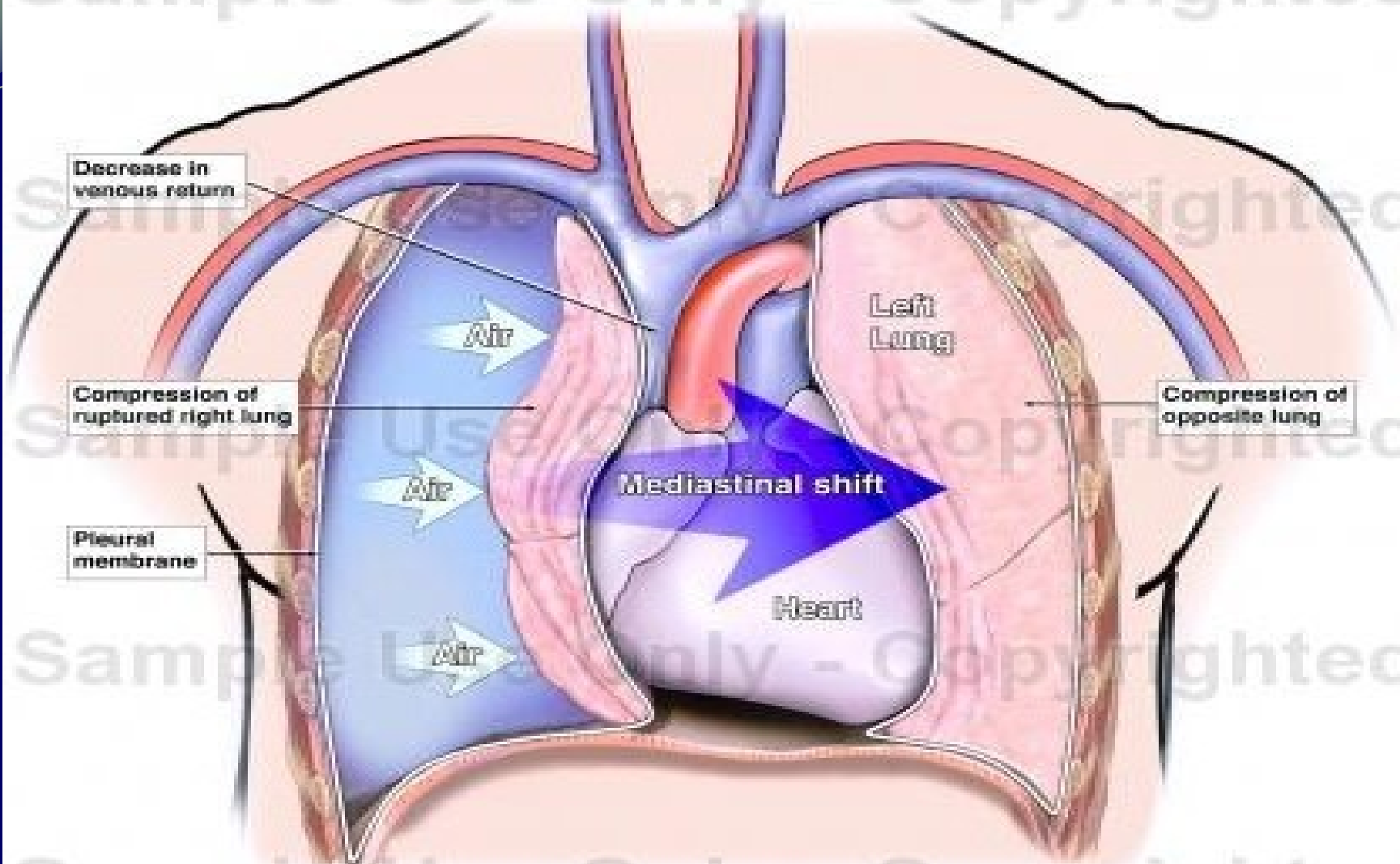
- occurs when air enters the pleural space from a lung injury or through the chest wall without a means of exit
- results in death if it is not immediately recognized and treated
- when air is allowed to leak into the pleural space during inspiration and becomes trapped during exhalation, an increase in the pleural pressure results

Pulmonary injury

Tension pneumothorax

- increased pleural pressure produces mediastinal shift
- mediastinal shift results in:
 - compression of the uninjured lung
 - compression of the superior and inferior vena cava, decreasing venous return to the heart
- progression of simple or open pneumothorax

Tension Pneumothorax



In a tension pneumothorax, air from a ruptured lung enters the pleural cavity without a means of escape. As air pressure builds up, the affected lung is compressed and all of the mediastinal tissues are displaced to the opposite side of the chest.

Pulmonary injury

Tension pneumothorax

- signs and symptoms
 - absent breath sounds on the injured side
 - hyperresonance to percussion
 - subcutaneous emphysema
 - tachypnea and increasing dyspnea
 - tachykardia
 - cyanosis
 - hypotension
 - jugular venous distention
 - extreme anxiety
 - respiratory distress

Pulmonary injury

Tension pneumothorax

- management
- emergency care is directed at reducing the pressure in the pleural space
- occlude open wound
- needle thoracostomy
- tube thoracostomy – in-hospital management
 - 4nd intercostal space in mid-axillary line
 - TOP OF RIB

Pulmonary injury

Tension pneumothorax

- management

pleural decompression should only be employed if the patient demonstrates significant dyspnea and distinct signs and symptoms of tension pneumothorax

Pulmonary injury

Hemothorax

- accumulation of blood in the pleural space caused by bleeding from
 - penetrating or blunt lung injury
 - chest wall vessels
 - intercostal vessels
 - myocardium

Pulmonary injury

Hemothorax

- incidence
 - associated with pneumothorax – it is called a hemopneumothorax
 - blunt or penetrating trauma
 - rib fractures are frequent cause
- hypovolemia results as blood accumulates in the pleural space

Pulmonary injury

Hemothorax

- signs and symptoms

- diminished or decreased breath sounds on the injured side
- hypotension
- tachypnea
- dyspnea
- narrowed pulse pressure
- pale, cool, moist skin
- respiratory distress

Pulmonary injury

Hemothorax

- management

- analgesics
- high – flow oxygen
- positive-pressure ventilation if necessary
- ventilatory assistance with a bag-valve mask
- circulation – volume-expanding fluids to correct hypovolemia
- tube thoracostomy
- videothoracoscopy or thoracotomy - if it is blood loss by tube thoracostomy more than 2000ml or next 3 hours is blood loss more than 500ml/hours

Pulmonary injury Contusion

- 30-75% of patients with significant blunt chest trauma
- frequently associated with rib fracture
- younger patients – also without rib fracture
- signs and symptoms
 - cough
 - tachypnea
 - tachycardia
 - dyspnea
 - cyanosis
 - respiratory distress

Pulmonary injury Contusion

- management

- analgesics
- high – flow oxygen
- positive-pressure ventilation if necessary
- ventilatory assistance with a bag-valve mask
- respiratory rehabilitation
- antibiotics
- bronchoscopy

Cardiovascular injuries

Myocardial contusion

- injury may reduce strength of cardiac contractions
 - reduced cardiac output
- progressive problems
 - myocardial necrosis
 - dysrhythmias
 - cardiogenic shock

S/S

- tachycardia and/or irregular rhythm
- retrosternal pain
- associated injuries
 - rib/sternal fractures

Cardiovascular injuries

Myocardial contusion

- management
 - monitor ECG
 - Alert for dysrhythmias

Cardiovascular injuries

Pericardial tamponade

- restriction to cardiac filling caused by blood or other fluid within the pericardium
- occurs in <2% of all serious chest trauma
 - however, very high mortality
- results from tear in the coronary artery or penetration of myocardium
 - blood seeps into pericardium and is unable to escape
 - 200-300 ml of blood can restrict effectiveness of cardiac contractions

Cardiovascular injuries

Pericardial tamponade

- increased intrapericardial pressure
 - does not allow the heart to expand and refill with blood
 - results in a decrease in stroke volume and cardiac output
- myocardial perfusion decreases due to pressure effects on the walls of the heart and decreased diastolic pressures
- ischemic dysfunction may result in infarction
- removal of as little as 20ml of blood may drastically improve cardiac output

Cardiovascular injuries

Pericardial tamponade

- signs and symptoms
 - tachycardia
 - respiratory distress
 - Becks triad - narrowing pulse pressure
 - neck vein distention
 - muffled heart sounds
 - ECG changes

Cardiovascular injuries

Pericardial tamponade

- management
 - high flow O₂
 - IV therapy
 - pericardiocentesis — needle insertion through the skin incision directed toward the left shoulder at a 45 degree angle to the abdominal wall.

Cardiovascular injuries

Aortic rupture

occurs almost exclusively with extreme blunt thoracic trauma - rapid deceleration in high-speed motor vehicle crashes

- falls from great heights

- 85-95% of these patients die at the scene as result of massive hemorrhage

signs & symptoms

- rapid and deterioration of vitals
- retrosternal pain

Cardiovascular injuries

Aortic rupture

- IV therapy
 - mild hypotension may be protective
- keep patient calm
- endovascular repair
- operative repair – is associated with high mortality