

Myelodysplastický syndrom

L. Bourková, OKH FN Brno

Laboratorní nálezy

- morfologické hodnocení:
 - leukocytů, erytrocytů, trombocytů
 - stanovení prstenčitých sideroblastů
 - počet blastů v PK a KD
- charakteristika dysplazie pro rozlišení typů MDS
(pozor na správné barvení preparátů – artefakty)
- cytopenie v krevním obraze
(bez dysplastický změn by neměla mít návaznost na MDS)

Laboratorní nálezy - PK

■ erytrocyty:

anémie, anizocytóza, poikilocytóza, polychromázie, bazofilní tečkování, H.-J. tělíka, Papenheimerova tělíka, Cabottovy prstence, dysplastické rysy NRBC, ↓ RETIC

■ leukocyty:

obvykle ↓NE, hypo/hyper(>5segmentů) - segmentace NE, pseudo-Pelgerova-Huětova anomálie, hypo/hyper/nerovnoměrná-granulace NE, vakuolizace NE, evt. přetrvávající bazofilie cytoplazmy NE, abnormální mono/promonocyty

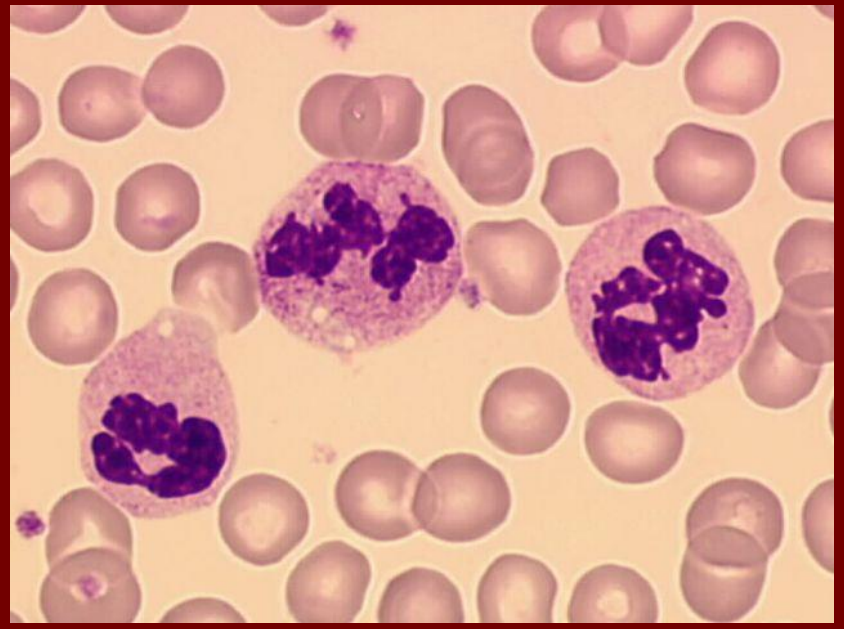
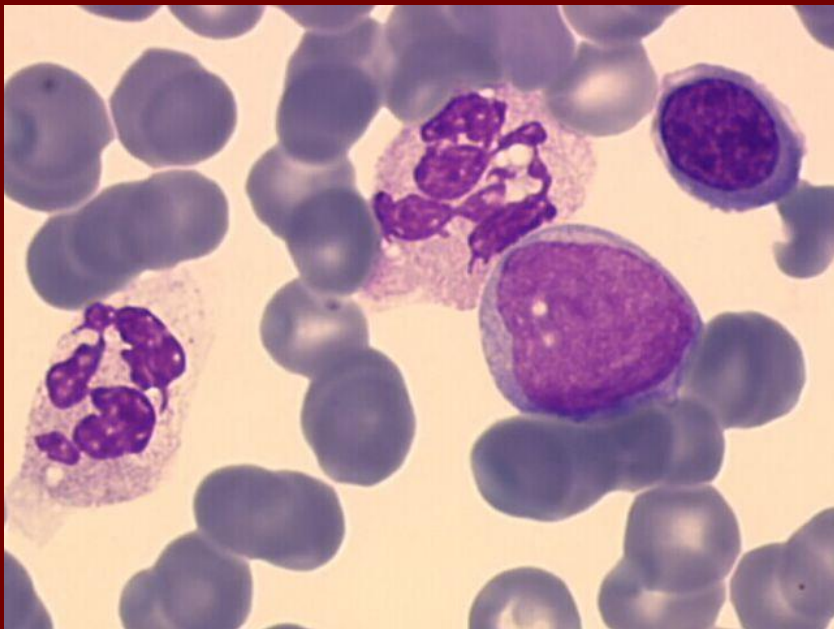
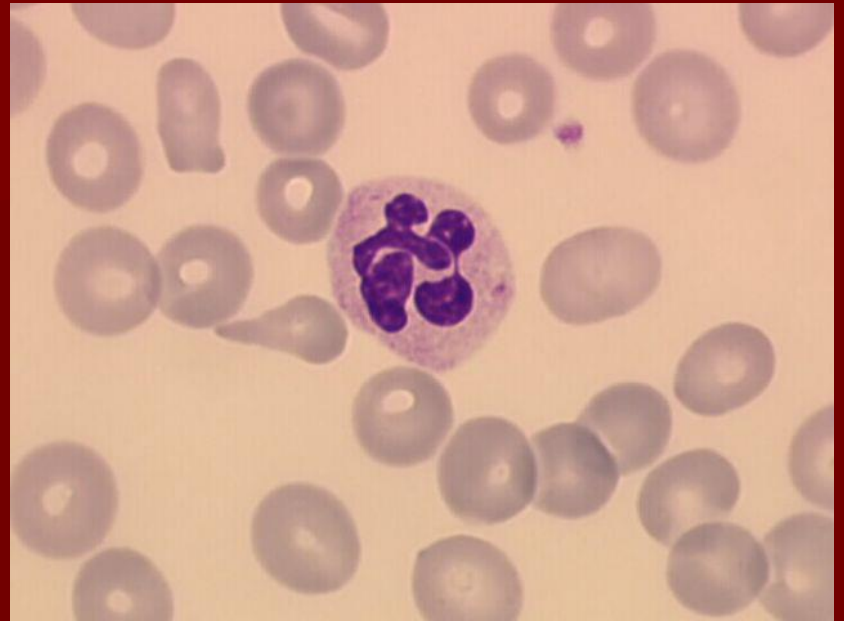
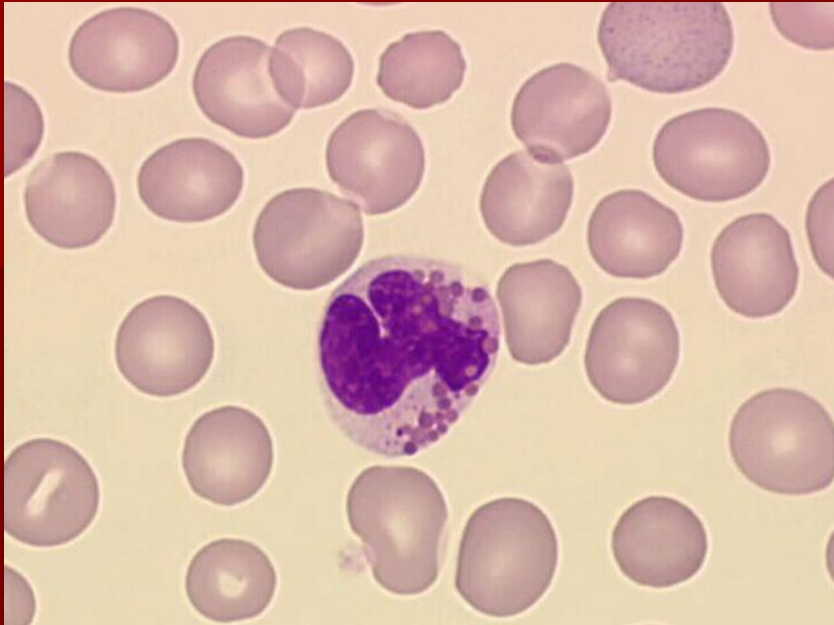
■ trombocyty:

většinou ↓PLT, anizocytóza, makrotrombocyty, hypogranulární PLT, fragmenty cytoplazmy MGK, mikro MGK, holá jádra MGK

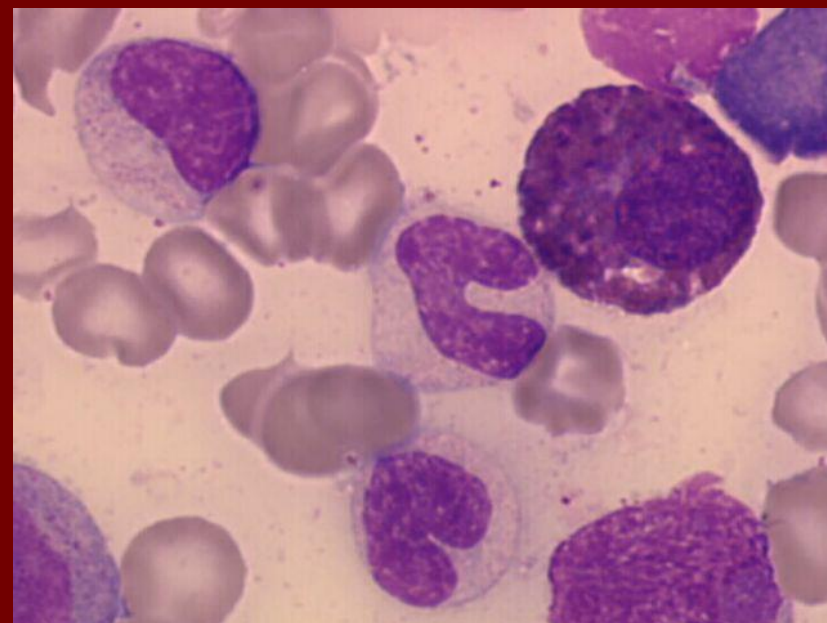
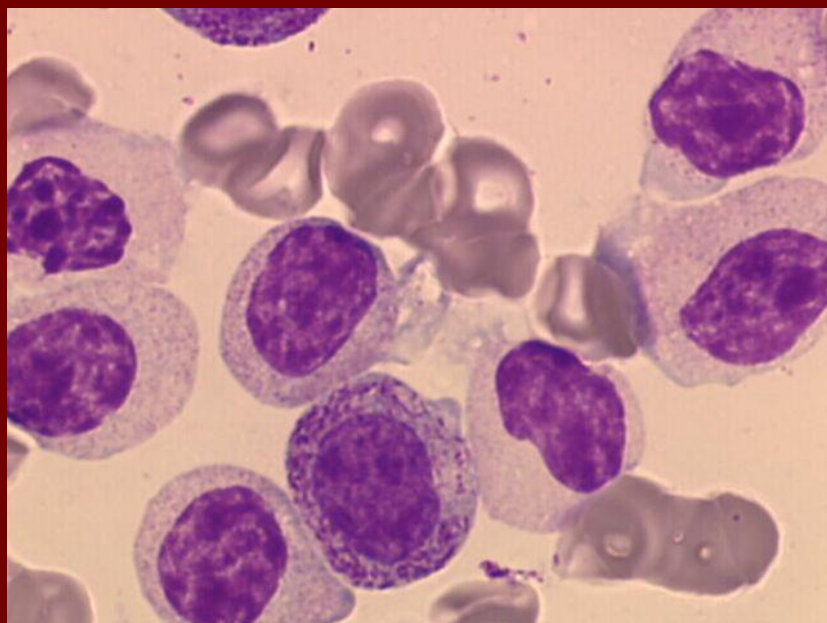
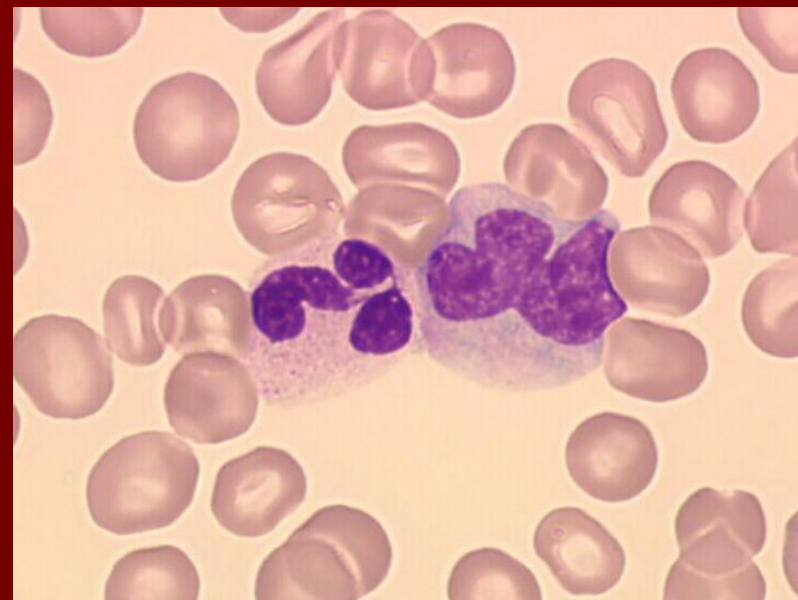
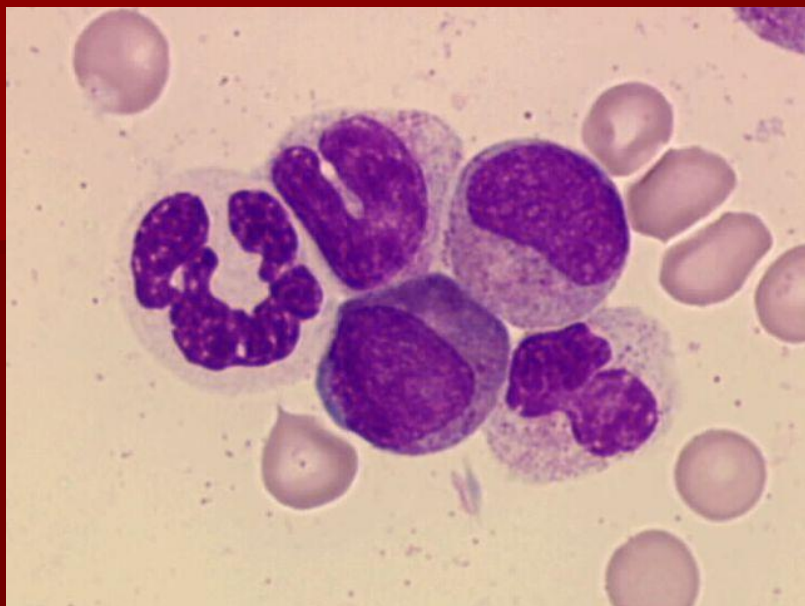
Laboratorní nálezy - KD

- dyserythropoéza:
podobné dysplatické změny jako v PK, dále
 - jádro: mezijaderné můstky, karyorexe, vícejadernost, megaloidní rysy, zneokrouhlení jádra
 - cytoplazma: vakuolizace, nerovnoměrná barvitelnost
 - PAS pozitivita
- dysgranulopoéza:
podobné dysplatické změny jako v PK, dále
 - asynchronie vyžívání jádra a cytoplazmy, Auerovy tyče, pseudo-Chédiakova-Higashiho granula
 - deficit myeloperoxidázy v neutrofilech
- dysmegakaryopoéza:
mikro/obrovské MGK, hypolobularizace MGK, mnohojadernost MGK, vakuolizace, hypogranulace MGK

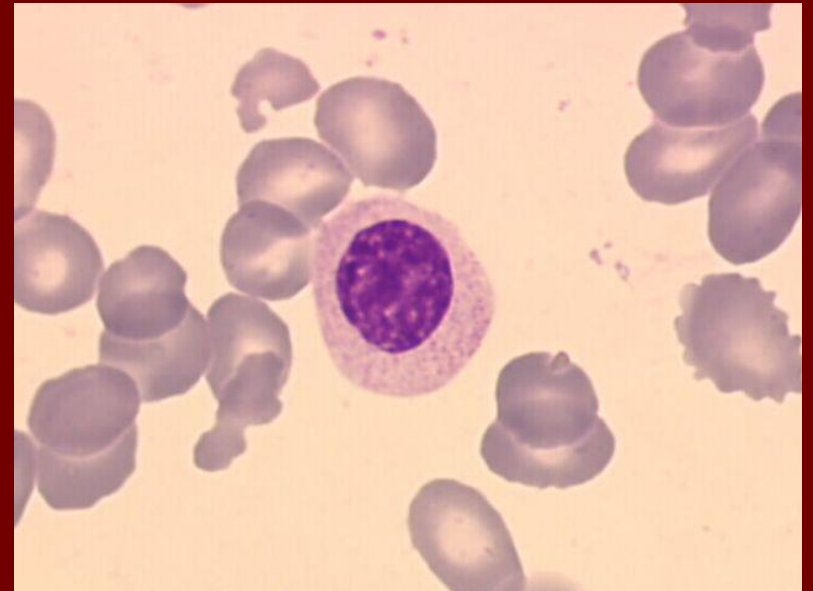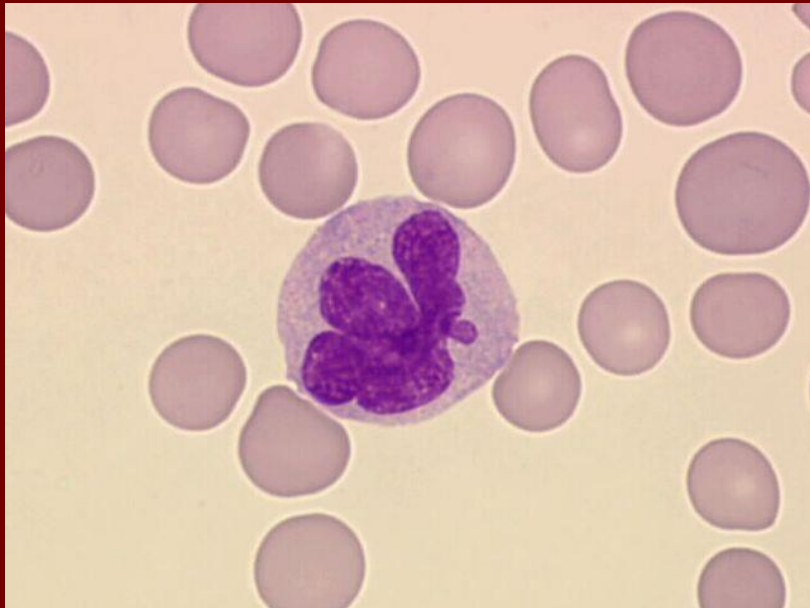
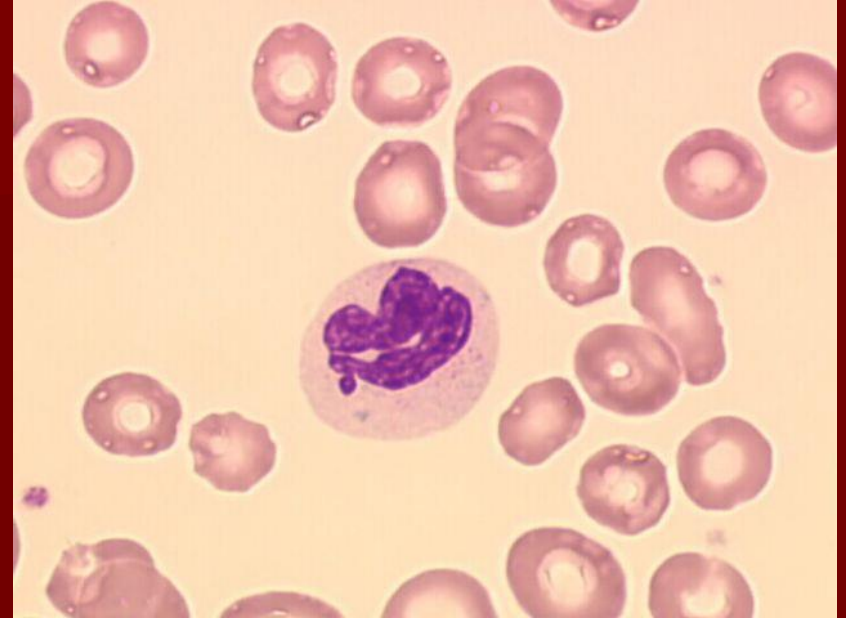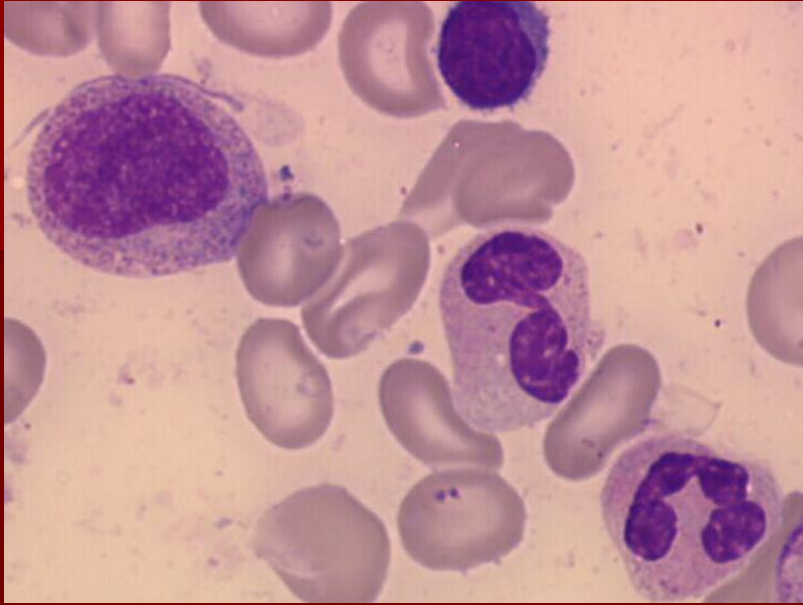
MDS – hypersegmentace, hypogranulace



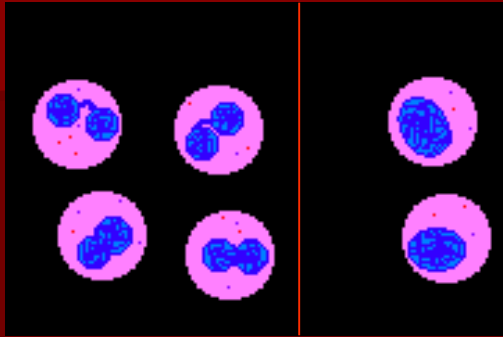
MDS - hypogranulace



MDS – hypogranulace, hyposegmentace

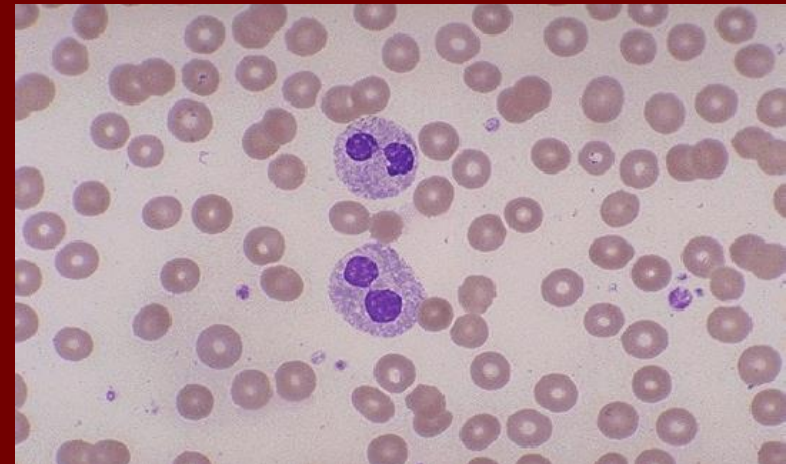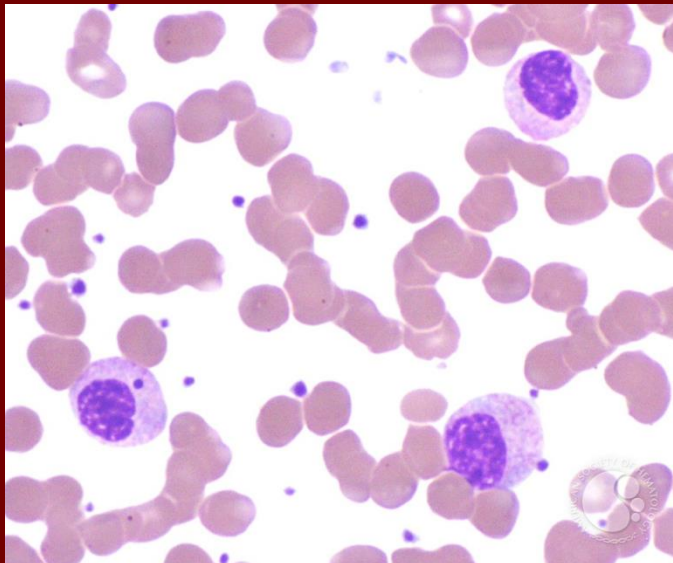
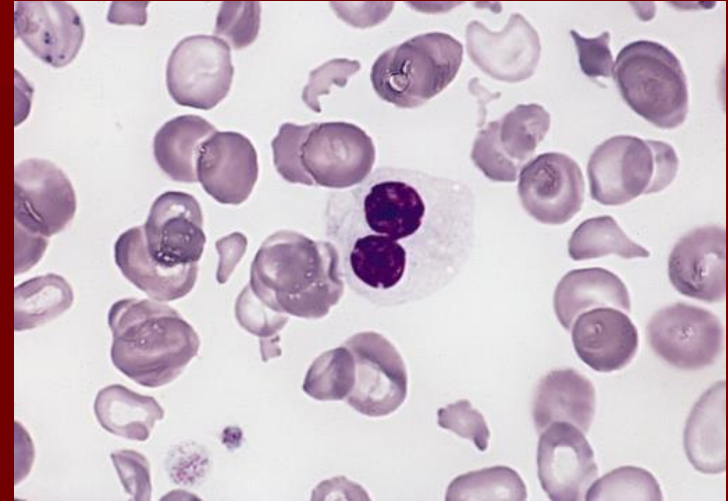


Pelgerova-Huětova anomálie

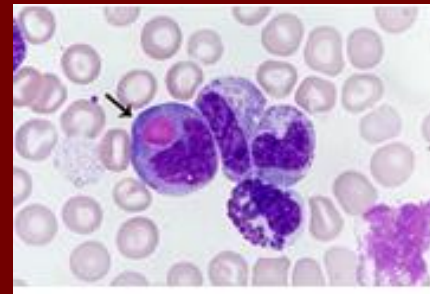
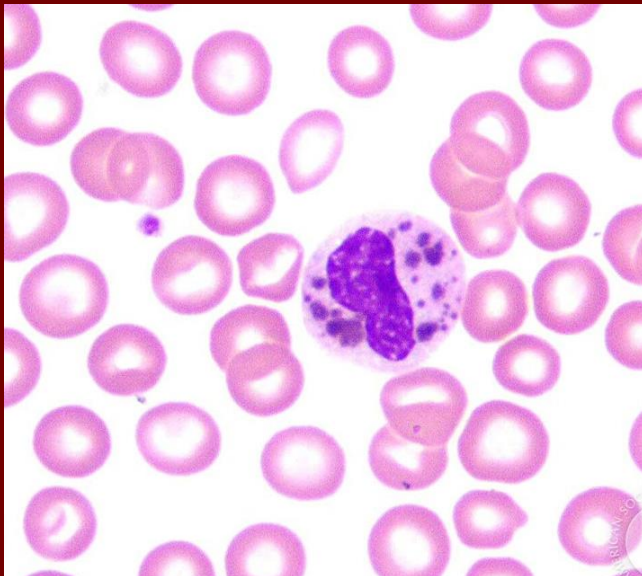
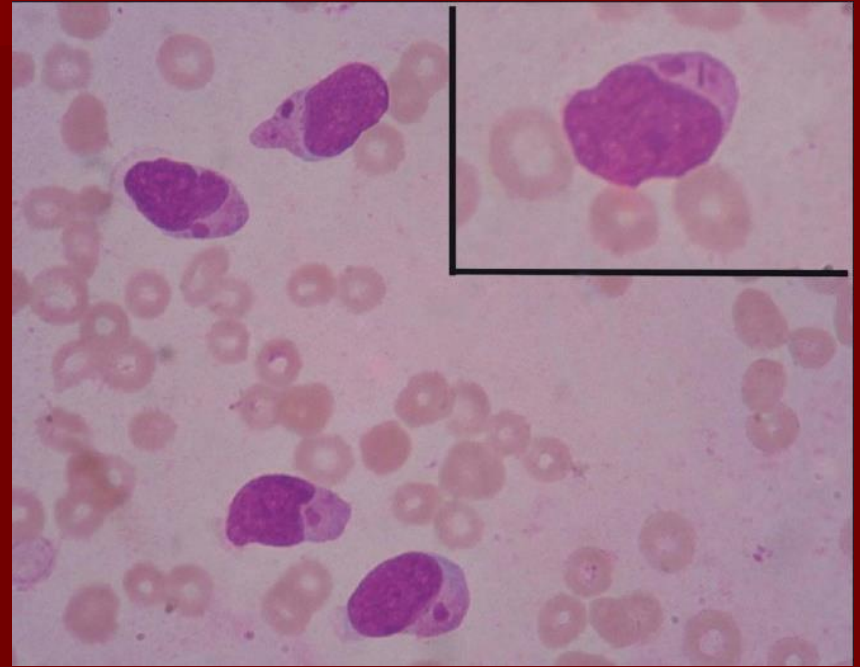
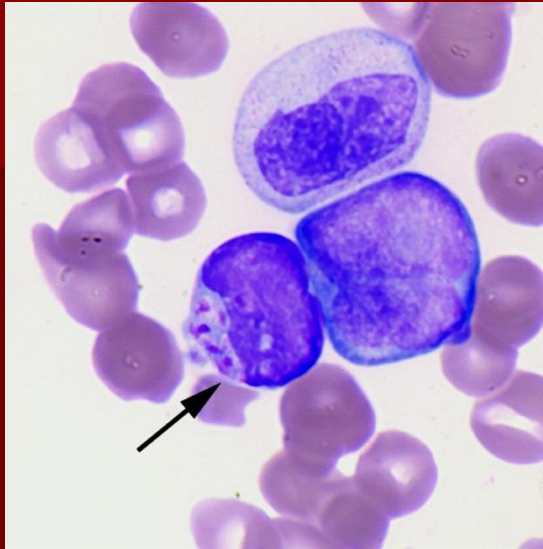


heterozygot

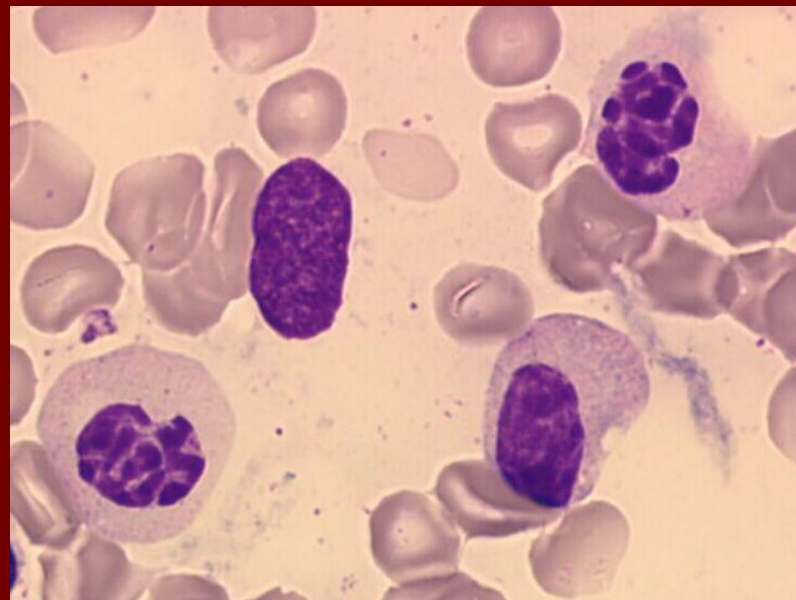
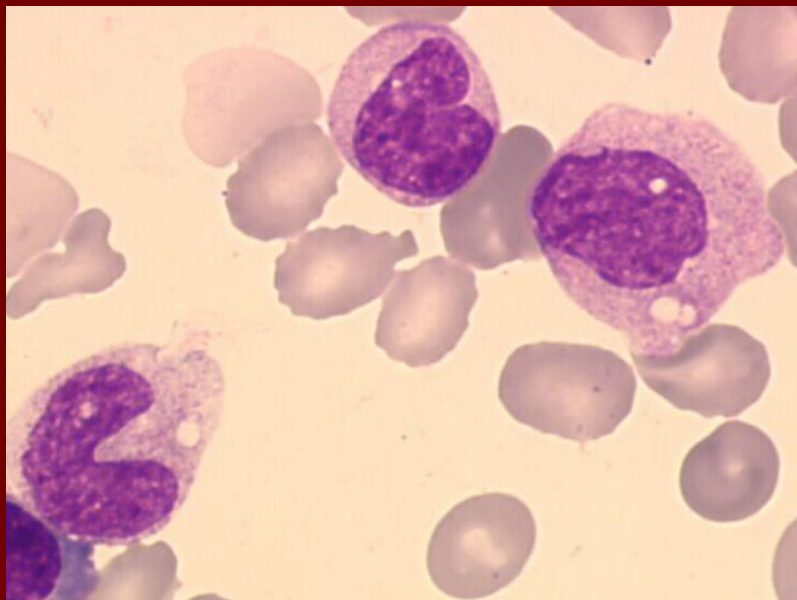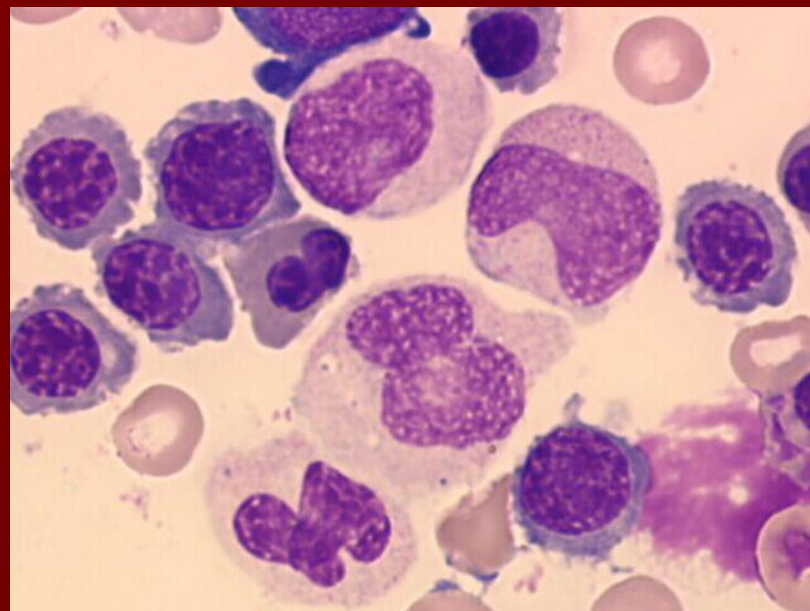
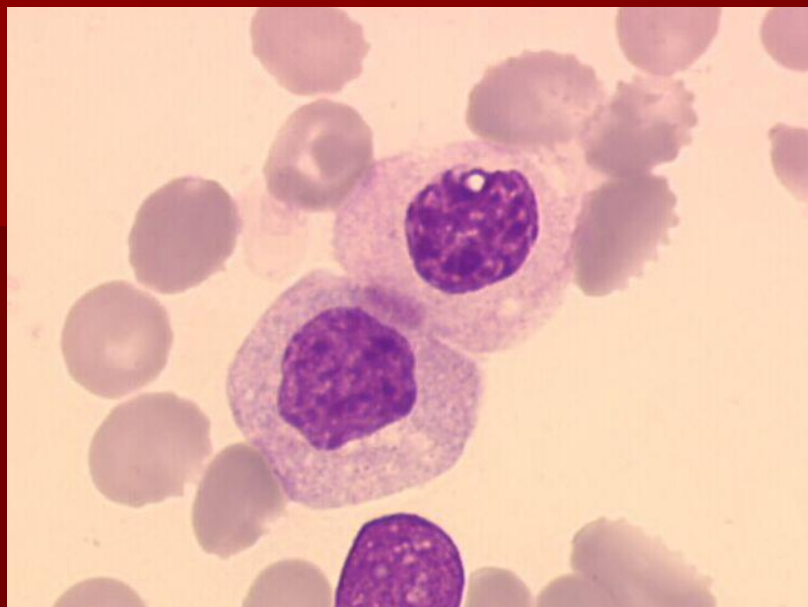
homozygot



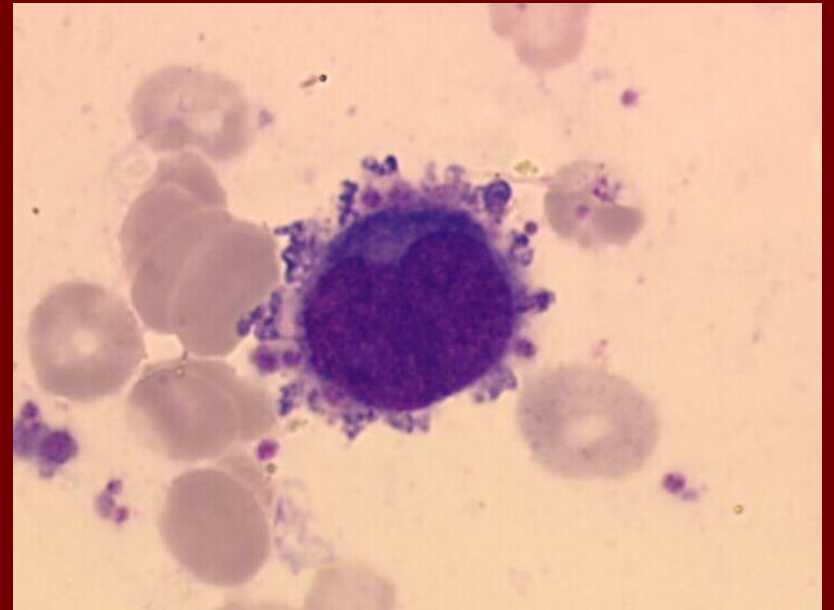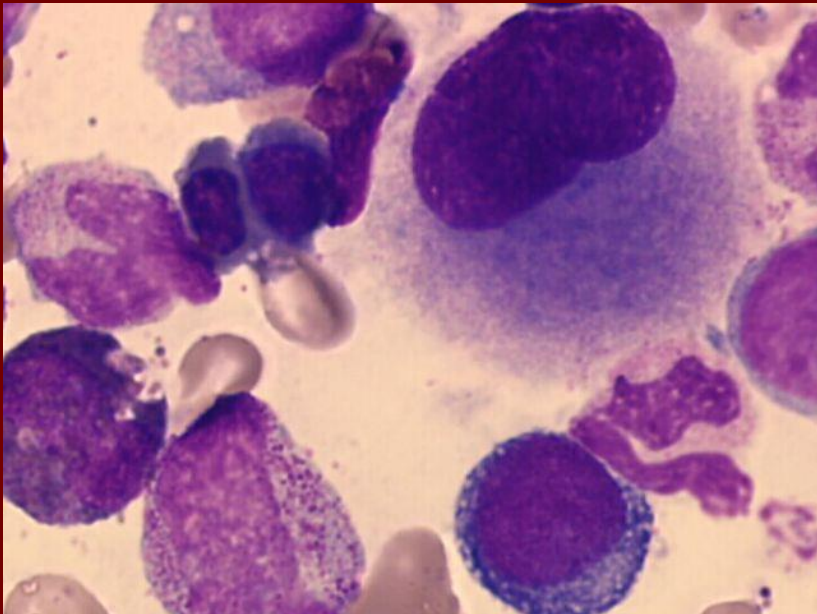
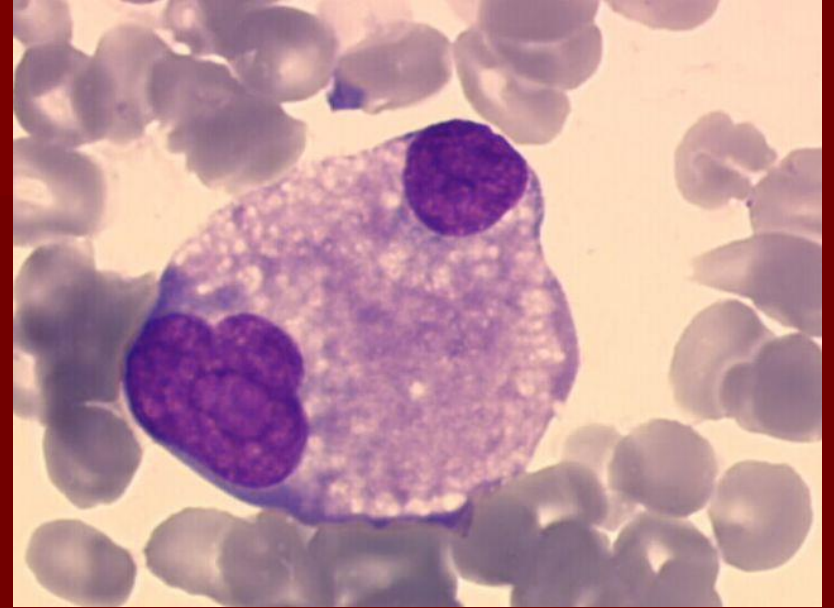
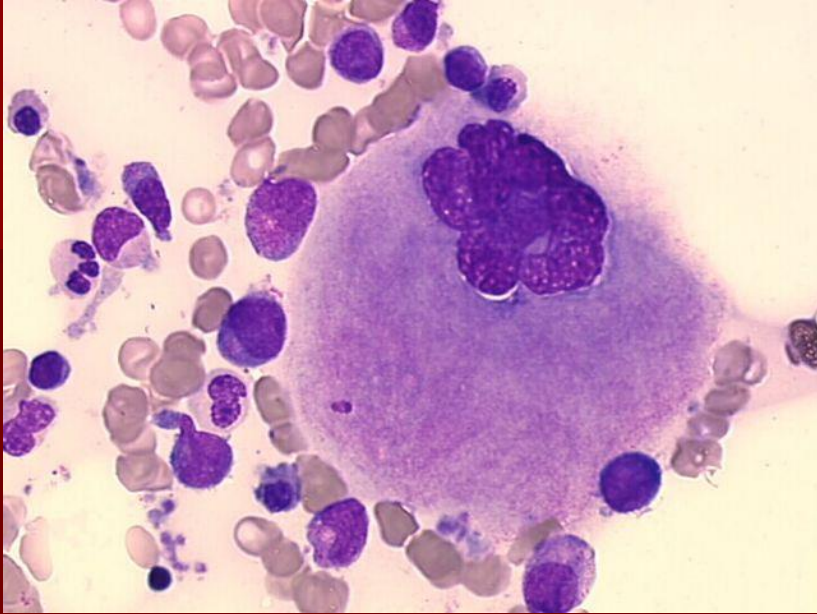
pseudo-Chédiakova-Higashiho granula



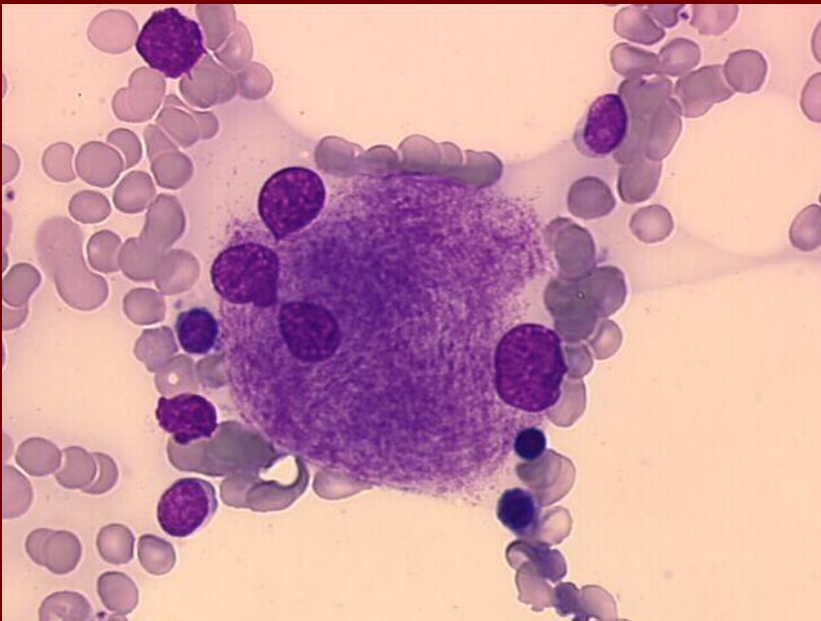
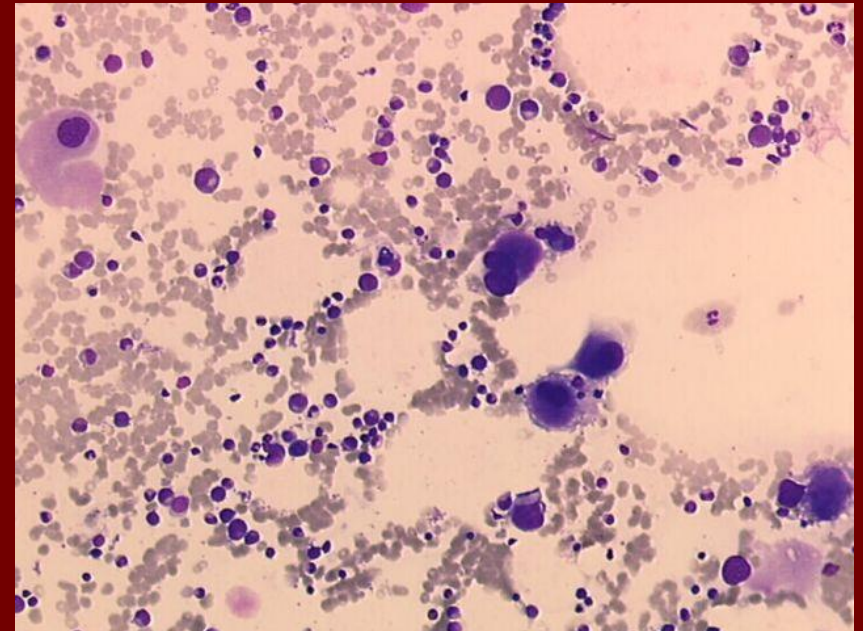
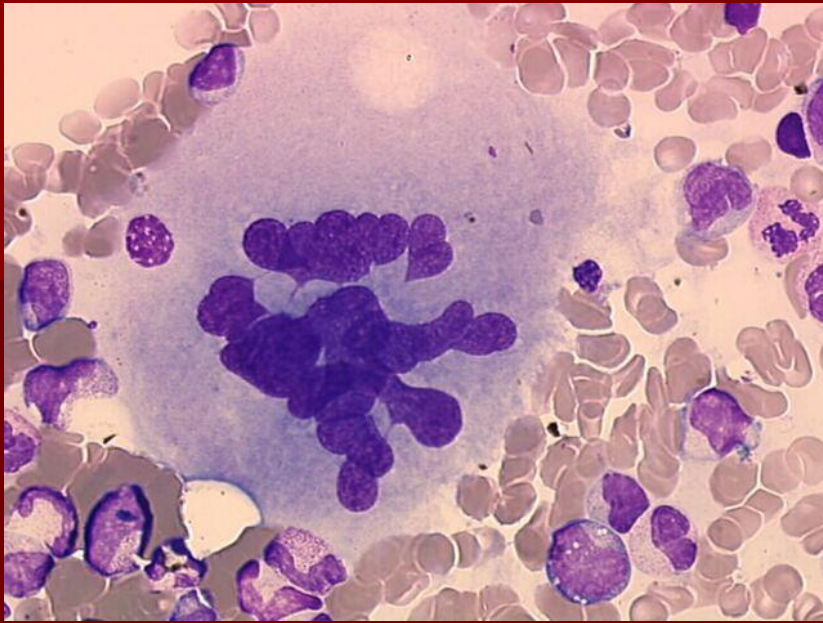
MDS – hypogranulace, hyposegmentace



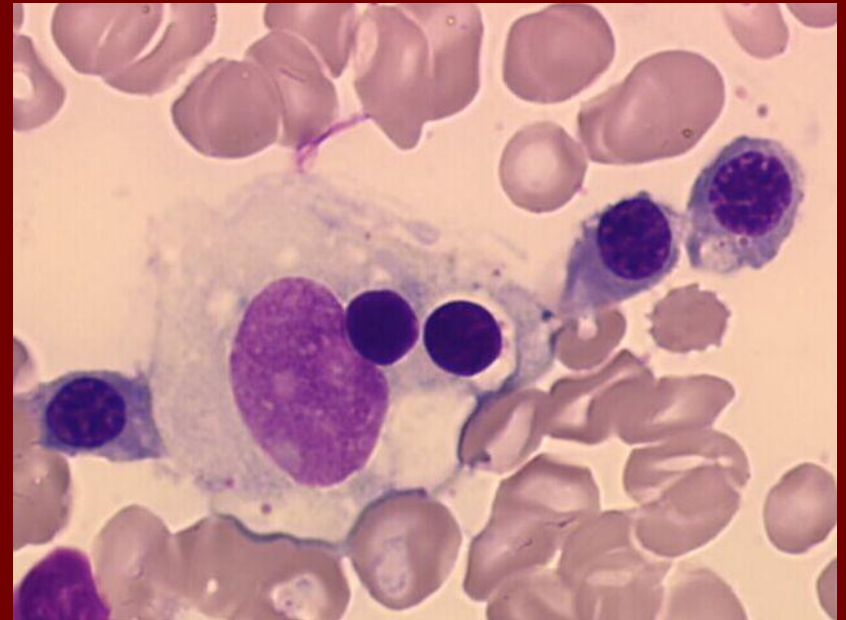
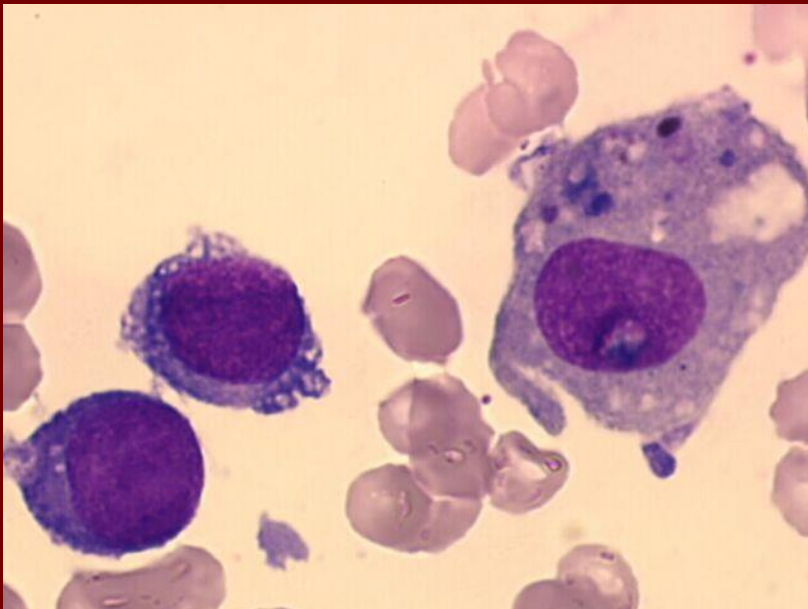
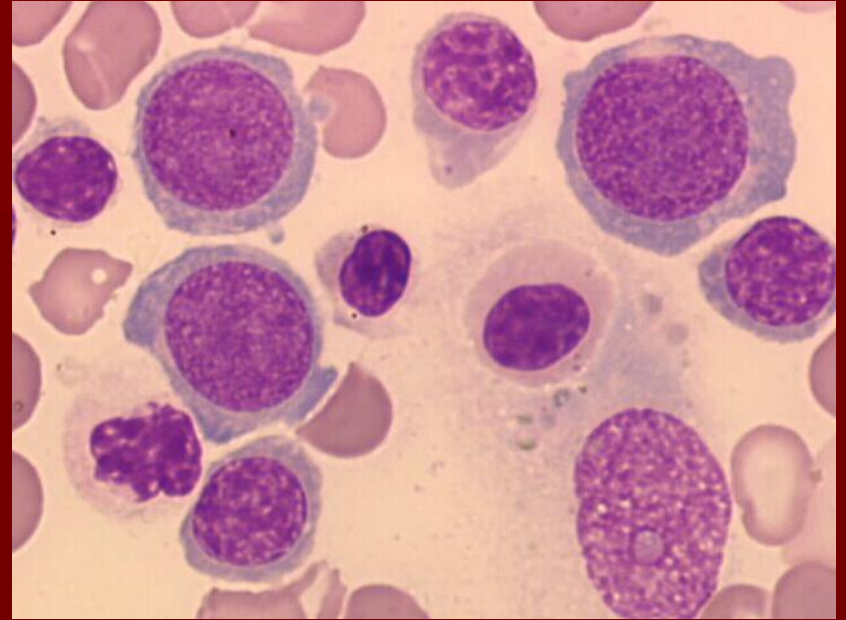
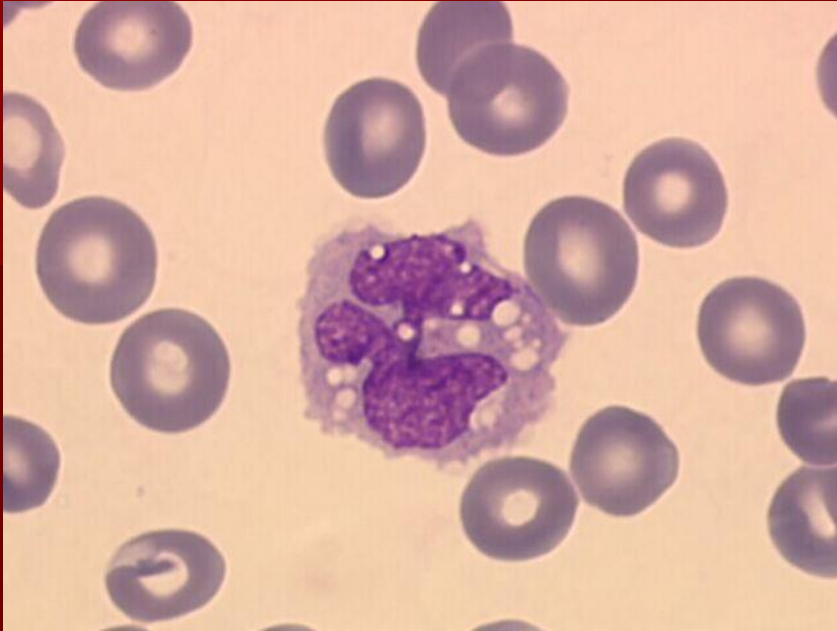
MDS - megakaryocyty



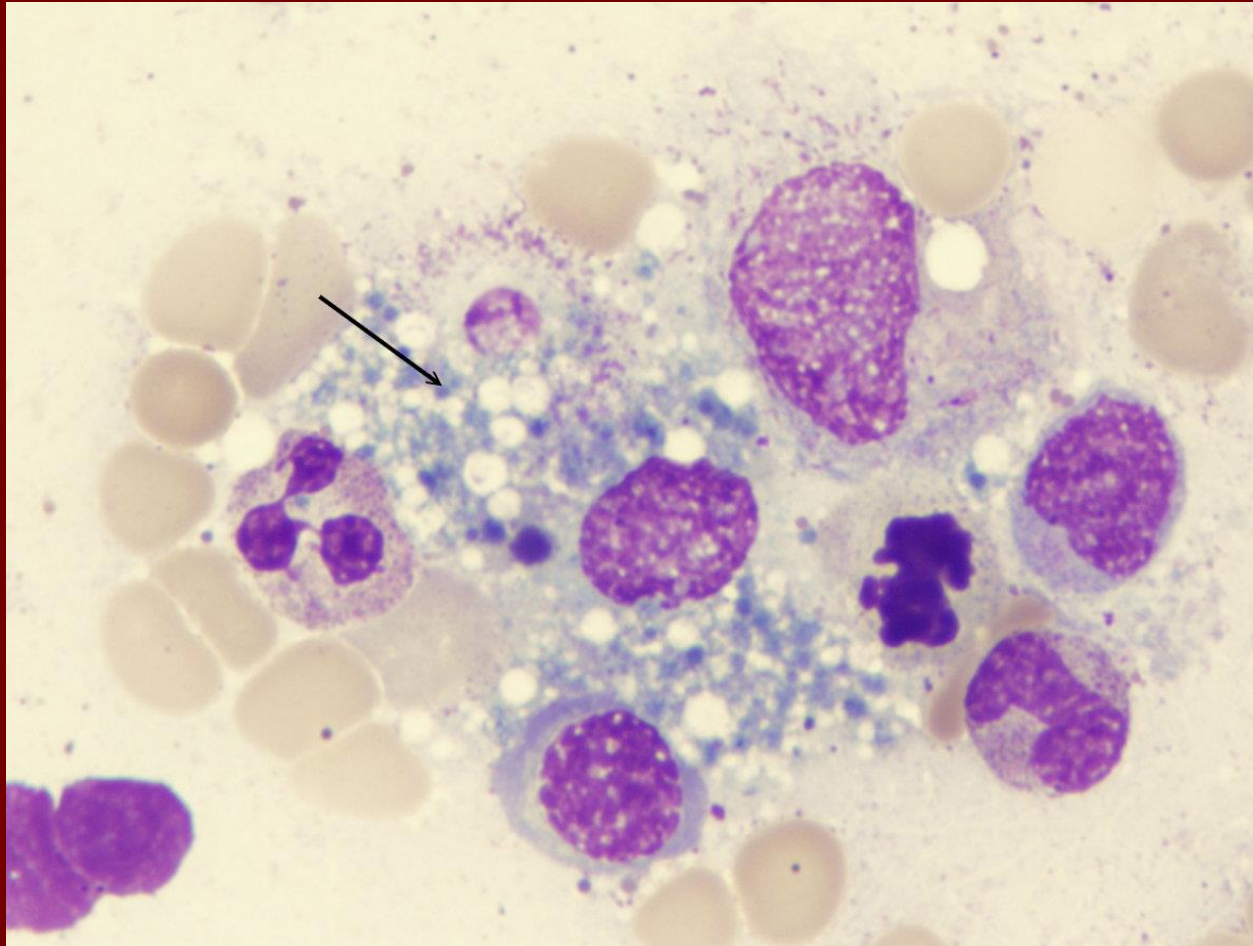
MDS - megakaryocyty



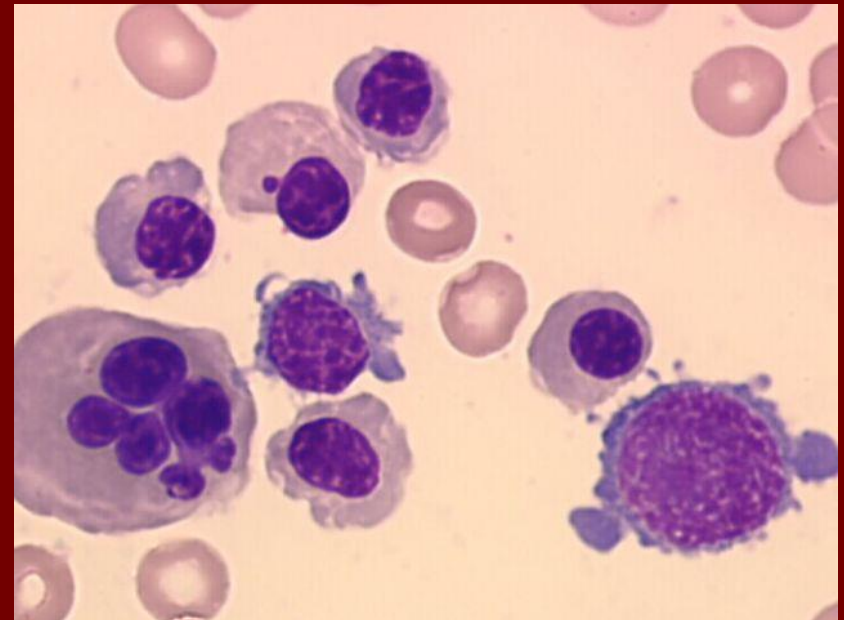
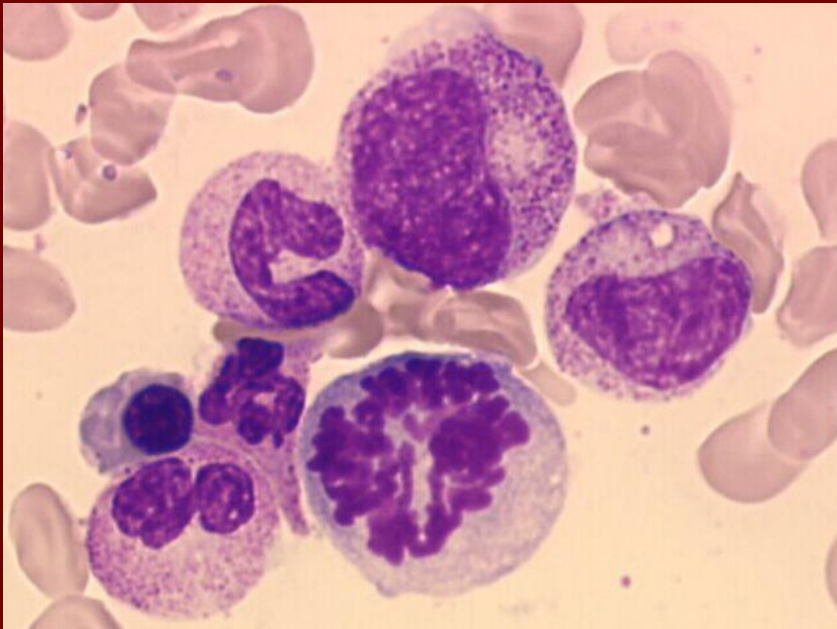
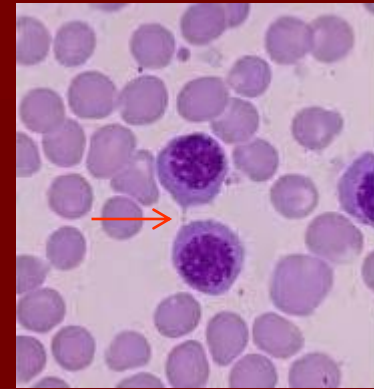
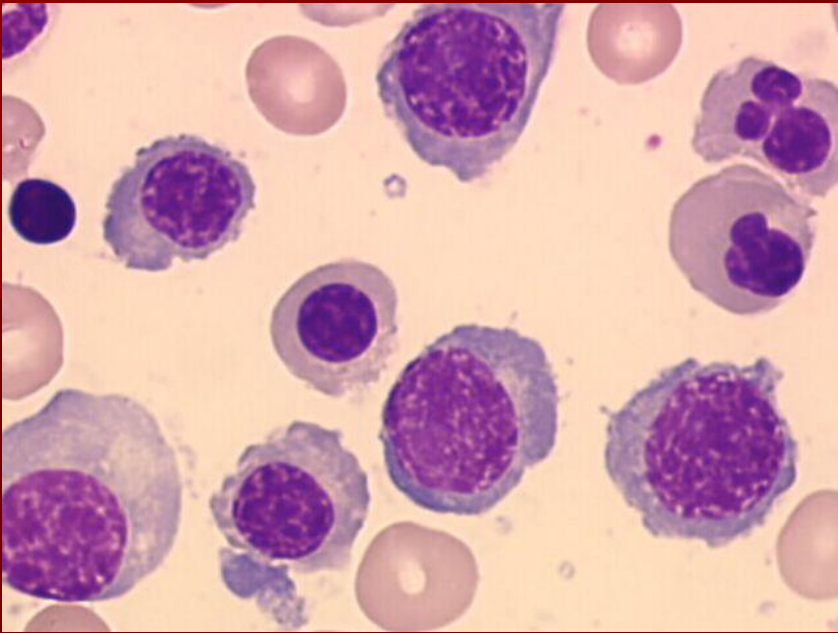
MDS - makrofág



Kostní dřeň – fagocytující makrofág



MDS – jaderné erythrocyty



Dyserythropoéza

