

Acute peripheral arterial occlusion

Tomáš Novotný

II. chirurgická klinika LF MU a FN u sv. Anny



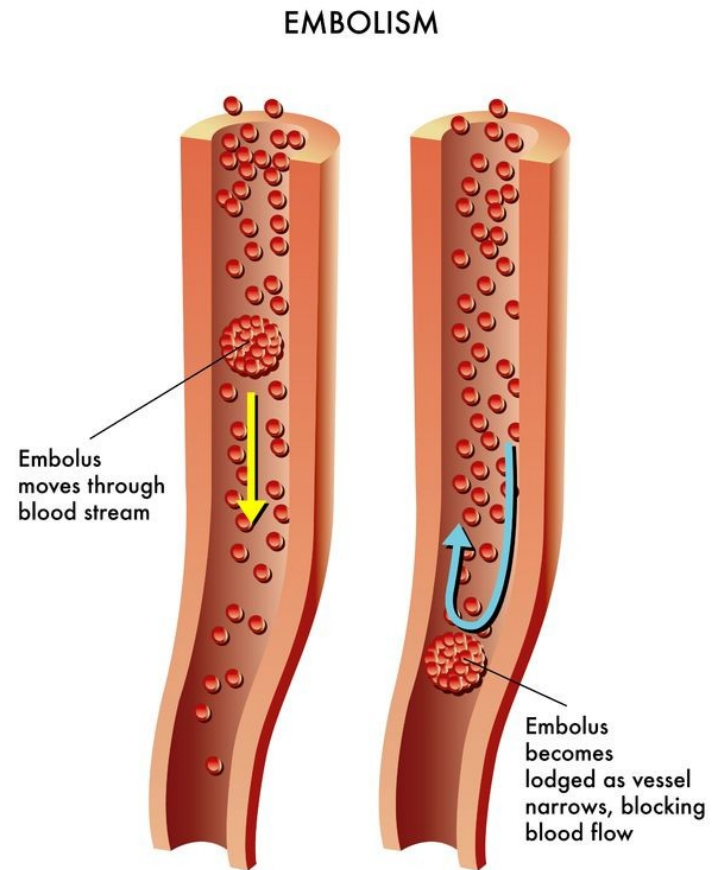
Acute ischemia

- result of a **sudden deterioration in the arterial blood supply**
- Causes
 - **arterial embolism**
 - **arterial thrombosis**
 - other causes
 - trauma
 - iatrogenic causes
 - occlusion of a vascular reconstruction



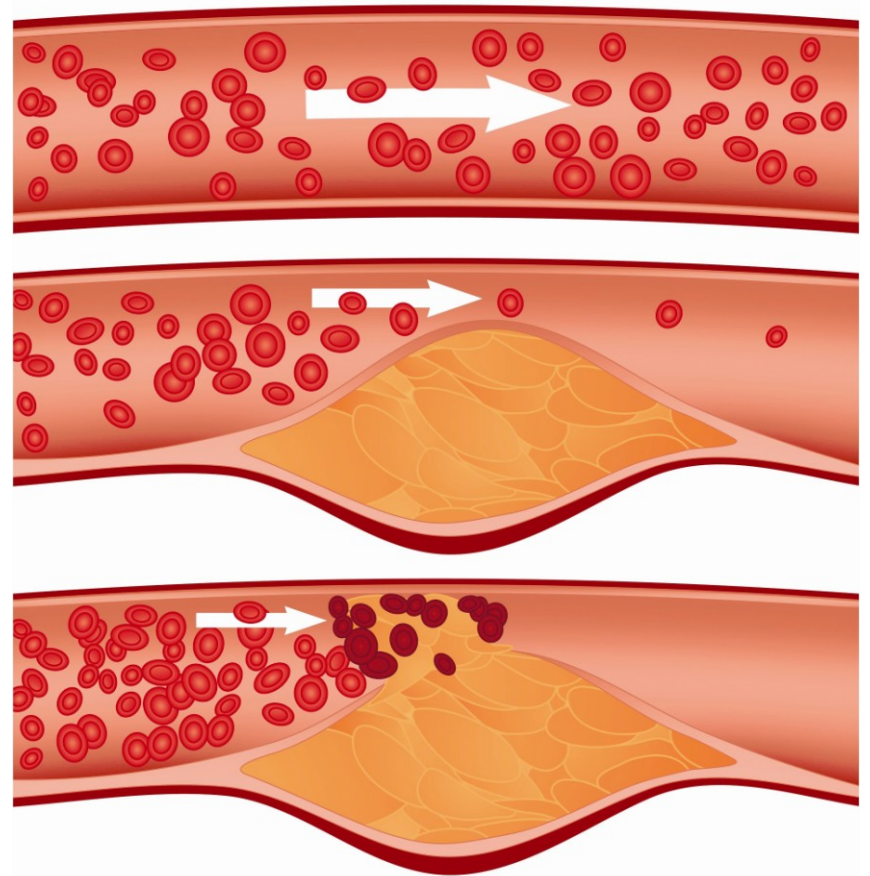
Arterial embolism

- result of a **material** (embolus) passing through the arterial tree and **obstructing a peripheral artery**
- Source
 - **the heart**
 - atherosclerotic debris
 - tumors
 - foreign bodies
 - ...



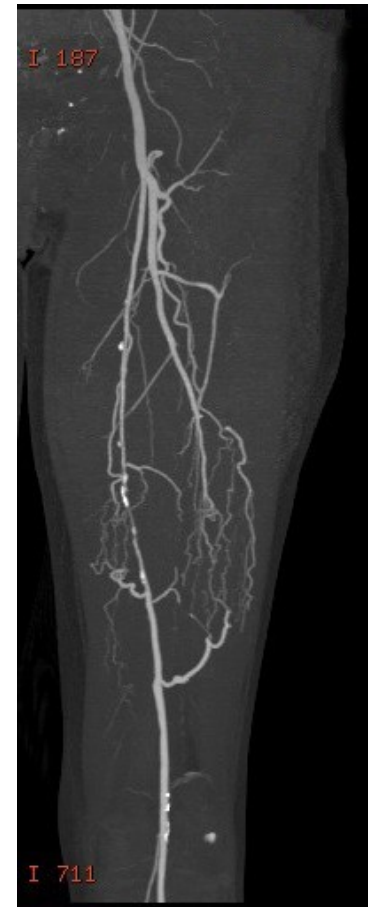
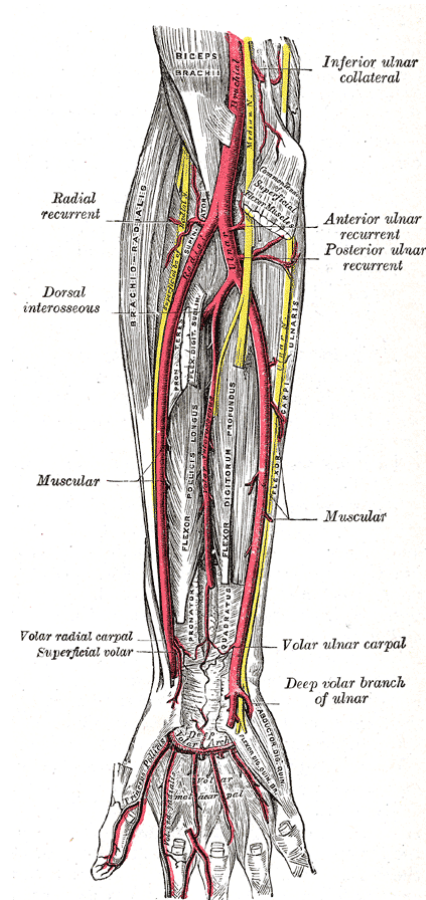
Arterial thrombosis

- **most commonly** the result of **progressive atherosclerotic narrowing** in peripheral arteries
- hypercoagulable states
- shock
- arterial dissection



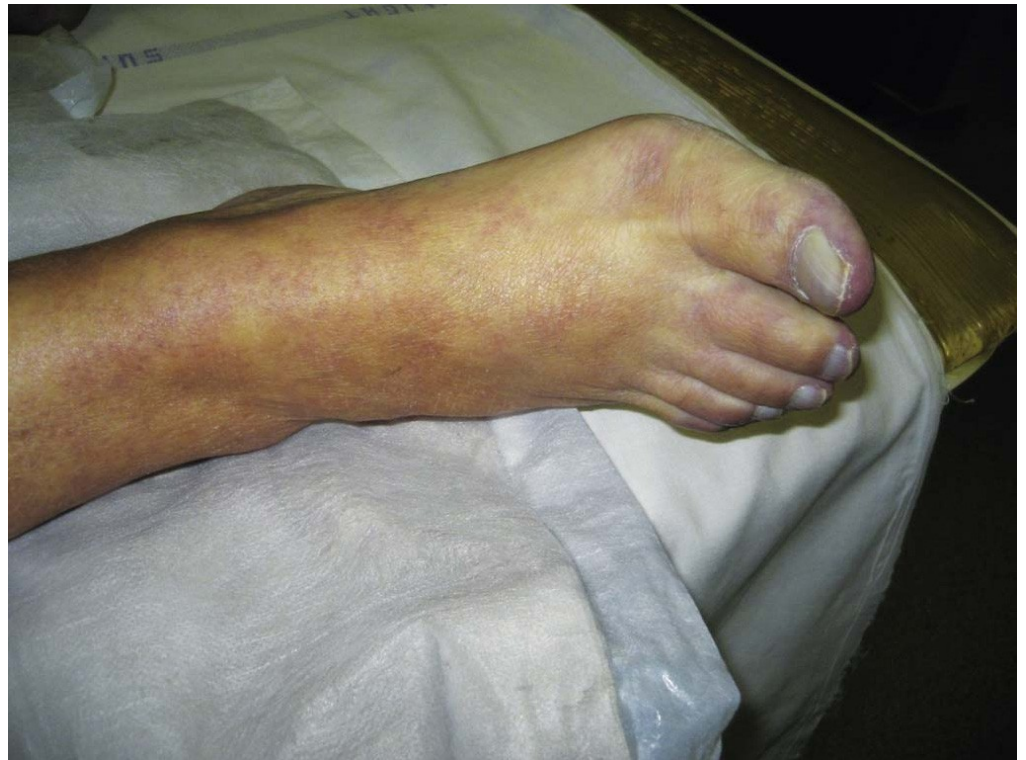Clinical presentation

- **depends on**
 - **size of occluded artery**
 - **available collaterals**
(physiological or developed)
- e.g. superficial femoral artery occlusion in the presence of well-established collaterals may be entirely asymptomatic



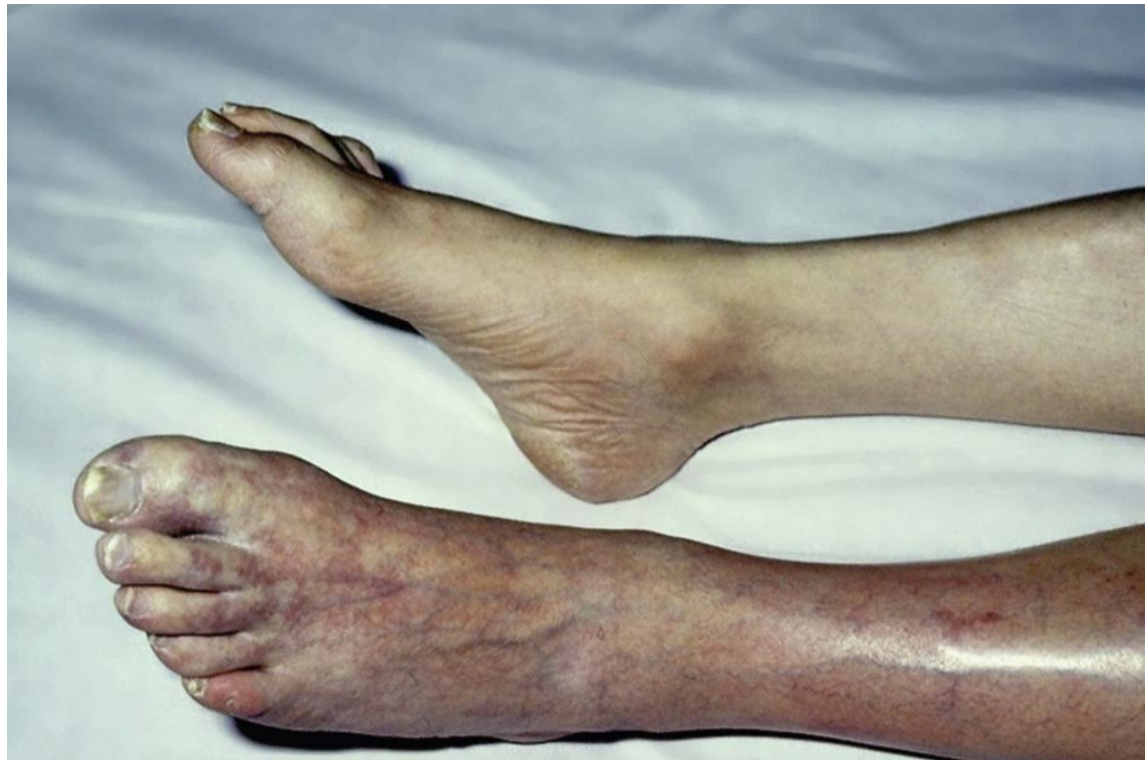Clinical presentation

- **sensory loss**
- **motor loss**
- sudden pain
- cold leg
- white leg
- absent peripheral pulses



Clinical presentation

- **sensory loss**
- **motor loss**
- sudden pain
- cold leg
- white leg
- absent peripheral pulses



Clinical assessment

- **History**
- clinical presentation assessment, duration
- source of embolism
 - atrial fibrillation, previous myocardial infarctions, valvular heart disease, ...
- peripheral arterial disease
 - intermittent claudication
- atherosclerosis risk factors
- **Physical findings**
- rule of Ps
 - pain
 - pallor
 - paresis
 - pulse deficit
 - paresthesia
 - poikilothermia
- aneurysms
- irregular pulse
- contralateral extremity



Embolism vs. thrombosis

- **Embolism**
- History
 - **source of embolism**
 - no claudication
- Physical findings
 - **irregular pulse, ...**
 - normal peripheral pulses in contralateral extremity
- **Thrombosis**
- History
 - no source of embolism
 - **claudication**
- Physical findings
 - regular pulse, ...
 - **no peripheral pulses in contralateral extremity**

! Embolism might occur in a patient with claudication/peripheral arterial disease and without known sources of embolism in history and vice versa!



Classification of Acute Limb Ischemia

Category / class	Description / Prognosis	FINDINGS		DOPPLER SIGNALS	
		Sensory Loss	Muscle Weakness	Arterial	Venous
I. Viable	Not immediately threatened	None	None	Audible	Audible
II. Threatened					
a. Marginally	Salvageable if promptly treated	Minimal (toes) or none	None	Inaudible	Audible
b. Immediately	Salvageable with immediate revascularization	More than toes, associated with rest pain	Mild, moderate	Inaudible	Audible
III. Irreversible	Major tissue loss or permanent nerve damage inevitable	Profound, anesthetic	Profound, paralysis (rigor)	Inaudible	Inaudible

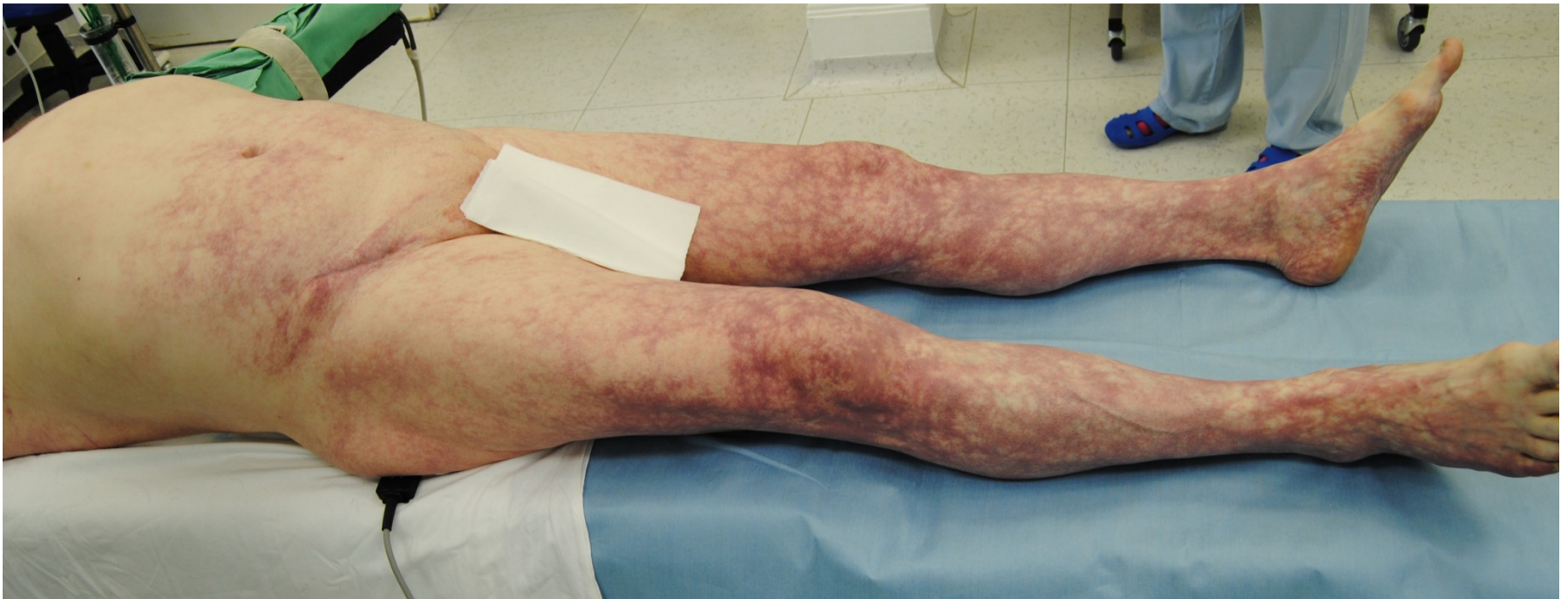

Diagnosis

- the **anatomical location of arterial occlusion**
 - aortic occlusion
 - iliac occlusion
 - femoropopliteal occlusion
 - popliteal and infrapopliteal occlusion
- **Imaging may be valuable**
- **However, there may be no time!**

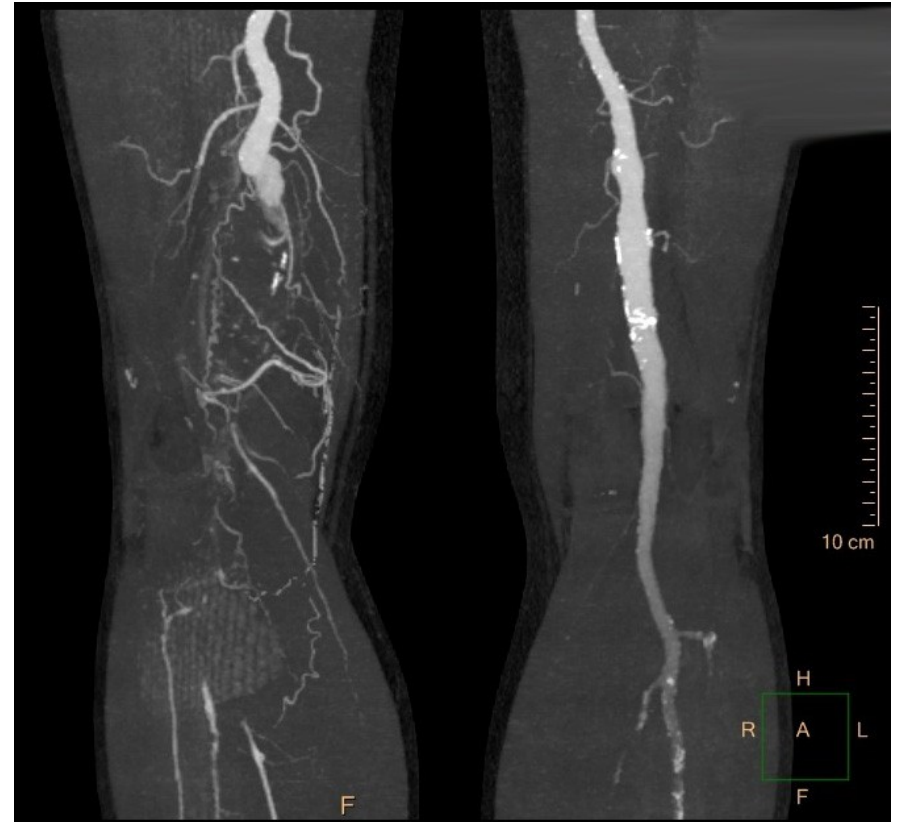


Aortic occlusion



Diagnosis - imaging

- Computed Tomographic (CT) **Angiography**
- usually available 24/7
- **the investigation of choice** for acute arterial ischemia



Diagnosis - imaging

- Duplex ultrasonography
 - availability?
- Digital subtraction angiography
 - less accessible than CT angiography
 - best choice when an endovascular solution to the arterial occlusion is likely
- Magnetic resonance angiography (MRA)
 - not suitable
 - usually not available at off hours



Initial management

- **Anticoagulation**

- **immediate anticoagulation** with intravenous calcium heparin **can stabilize the condition of the leg**
- the potential for immediate reversal with protamine makes **calcium heparin the drug of choice**

- **Ancillary supportive measures**

- oxygen delivered by facemask
- intravenous fluid administration
- analgesia



Treatment

- **Anticoagulation**
- **Operative intervention**
 - embolectomy or thrombectomy using Fogarty catheters
 - vascular reconstruction (bypass, endarterectomy, patch angioplasty)
- **Endovascular intervention**
 - percutaneous intra-arterial thrombolysis
 - mechanical thrombectomy / aspiration embolectomy



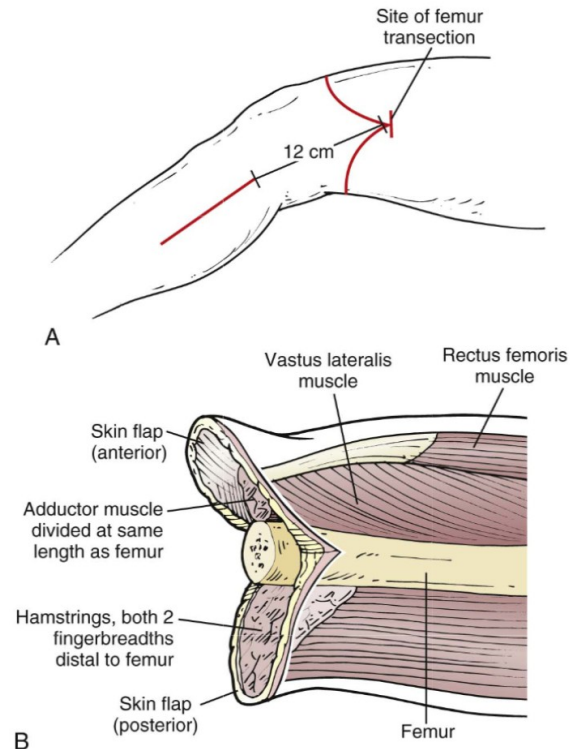
Treatment selection

- Category I
 - **medical therapy**
 - elective revascularization (optional)
- Category IIa
 - **immediate revascularization not necessary**
 - **endovascular or surgical options may be considered**
- Category IIb (sensory and motor deficit)
 - **immediate revascularization is necessary**
 - **surgical revascularization is generally preferred**
 - endovascular options may be considered



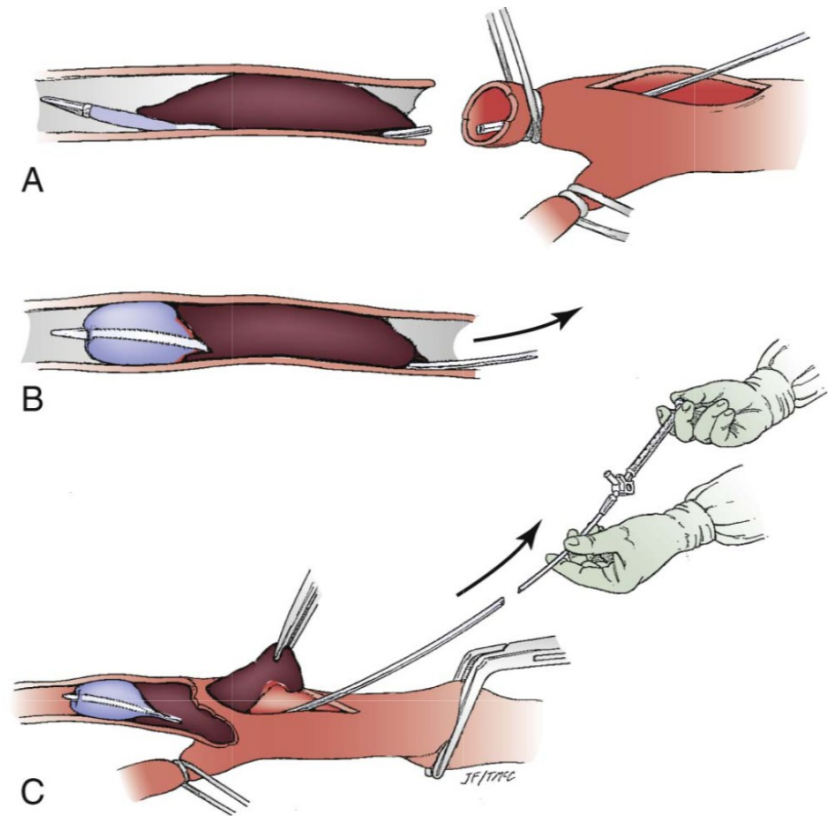
Treatment selection

- Category III
 - primary amputation should be considered



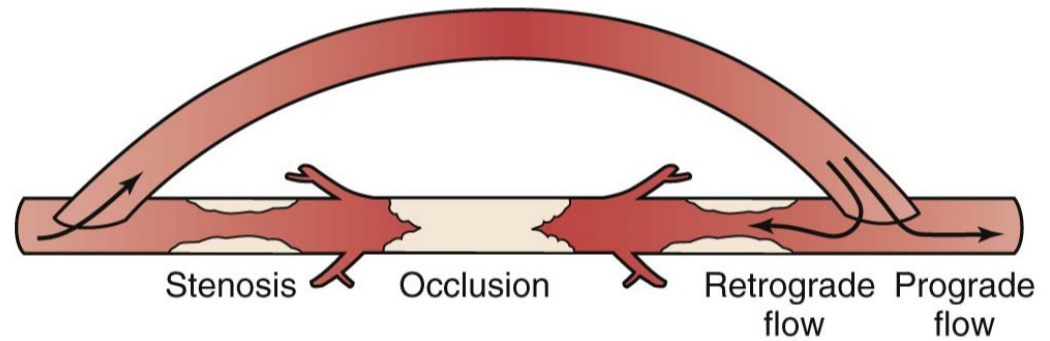
Operative intervention

- Embolectomy or thrombectomy
 - balloon catheters are passed proximally and distally until no visible thrombus is removed and a pulse or backflow is established
 - completion angiography is important to evaluate the effectiveness of thrombus removal

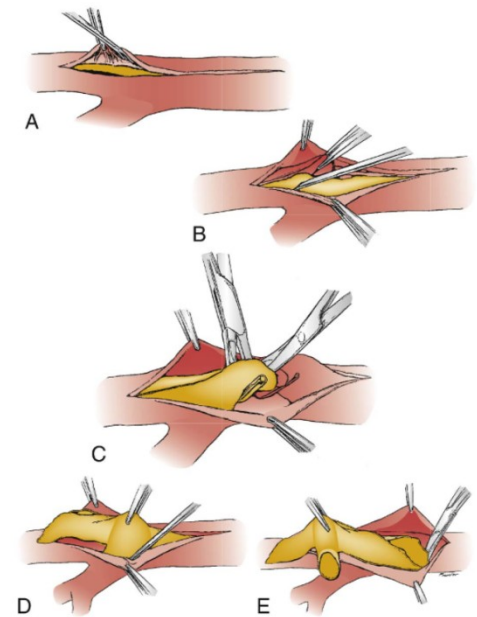


Operative intervention

- Bypass

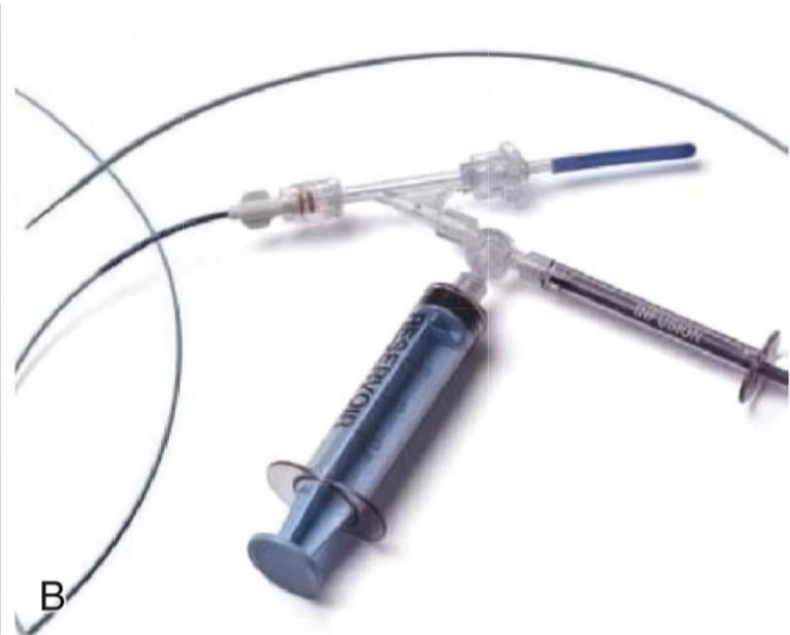


- Endarterectomy and patch plasty



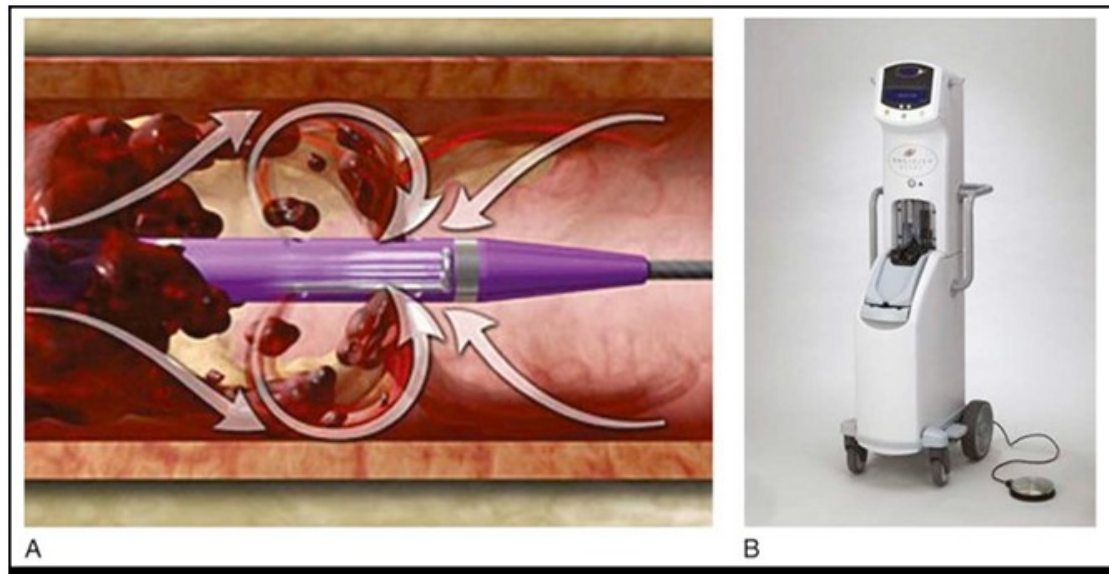
Endovascular treatment

- Catheter-directed thrombolysis
 - **tissue plasminogen activators** are used (e.g. Actilyse)



Endovascular treatment

- Percutaneous mechanical thrombectomy
 - devices
 - hydrodynamic
 - rotational
 - aspiration thrombectomy catheters



Prognosis

- The **medical state of a patient** who presents with acute leg ischemia **is a good prognostic index** of survival.
- **The outcome after** treatment for **acute limb ischemia is often poor.**



Upper limb ischemia

- **Patients are** on average about 4 years **older.**
- **seldom threatens the limb**
- **treatment is to prevent late complications**
 - activity-induced arm fatigue and pain (up to 50% patients have late symptoms if untreated)
- **cardiac embolism** is the main cause
- **atherosclerosis is rare**



Upper limb ischemia

- **often cold feeling and numbness** rather than pain in the arm
- **diagnosis is clinical**
 - (can be confirmed by duplex imaging)
- **up to 20% of patients** with acute arm ischemia **do not survive the acute event!**



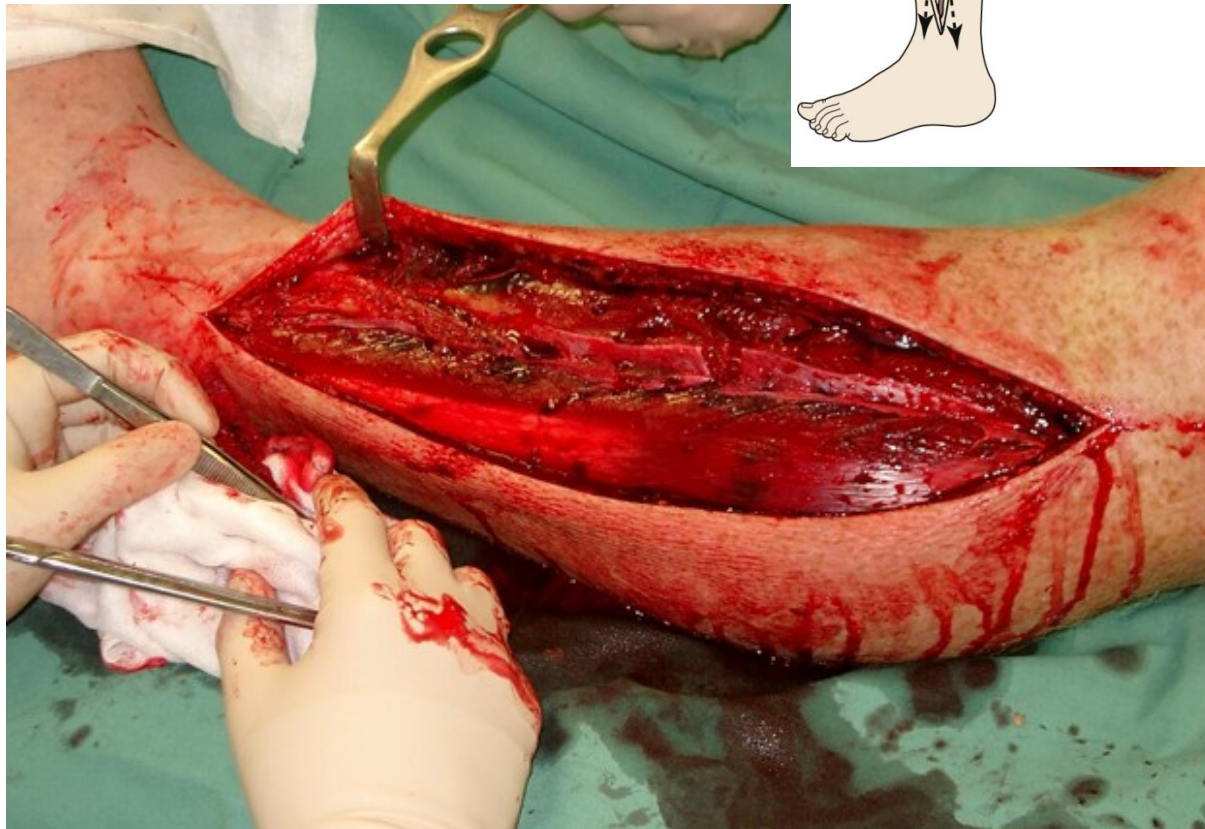
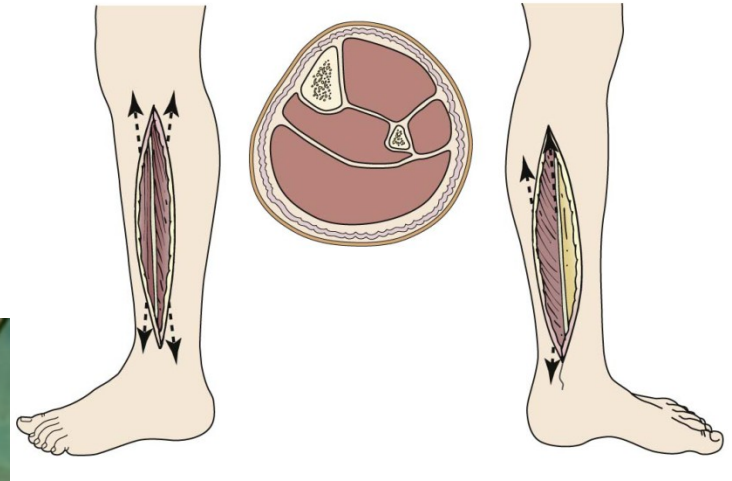
Compartment syndrome

- is an **increase in intracompartmental pressure**
- **up to 20% of patients after revascularization**
- mechanism is **ischemia-reperfusion**
- **risk factors**
 - **prolonged ischemia time (>6 hours); young age; insufficient arterial collaterals;** acute time course for arterial occlusion; hypotension; poor back-bleeding from the distal arterial tree at embolectomy



Compartment syndrome

- Fasciotomy



Fasciotomy - indications

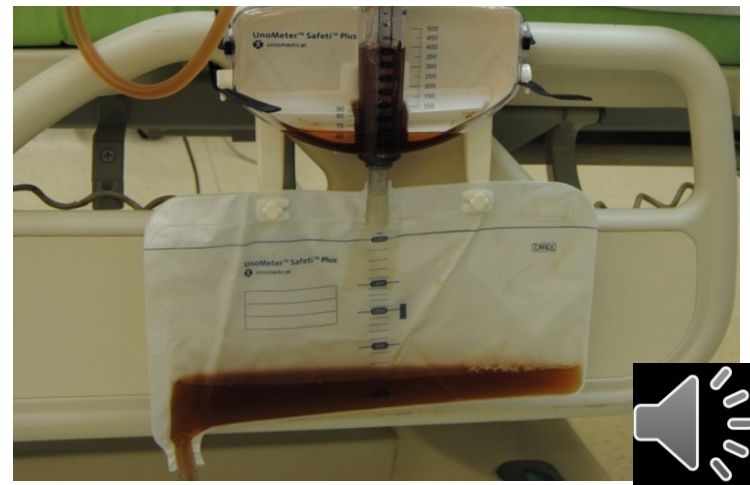Absolute Indications	Potential Indications
<ul style="list-style-type: none">• Tense compartment <i>plus either</i>:<ul style="list-style-type: none">• Pain with passive motion of muscles traversing the same compartment or• Paresis or paresthesias referable to the same compartment• Tense compartment in a patient who cannot be examined serially due to obtundation or need for other operations.• ICP minus mean blood pressure $<40 \text{ mm Hg}$• ICP minus diastolic blood pressure $<10 \text{ mm Hg}$	<ul style="list-style-type: none">• Acute ischemia $>6 \text{ hr}$ with few collaterals• Combined arterial and venous traumatic injuries• Phlegmasia cerulea dolens• Tense compartment after crush injury• Tense compartment after fracture

ICP, Intracompartmental pressures.



Systemic sequelae of myonecrosis

- large quantities of intracellular potassium, phosphate, myoglobin, and creatine phosphokinase are liberated
- **Hyperkalemia**
 - dialysis or continuous veno-venous hemofiltration might be needed
- **Myoglobinuria**
 - tea-colored urine



Systemic sequelae of myonecrosis

- **Myoglobinuria** induces
 - renal vasoconstriction
 - tubular cast formation
 - direct heme protein-induced cytotoxicity
- **Management** of myoglobinuria
 - aggressive crystalloid infusion
 - forced diuresis
 - alkalinization of the urine with bicarbonate (optional)
 - hemodialysis is not a useful



Thank you for your attention!

