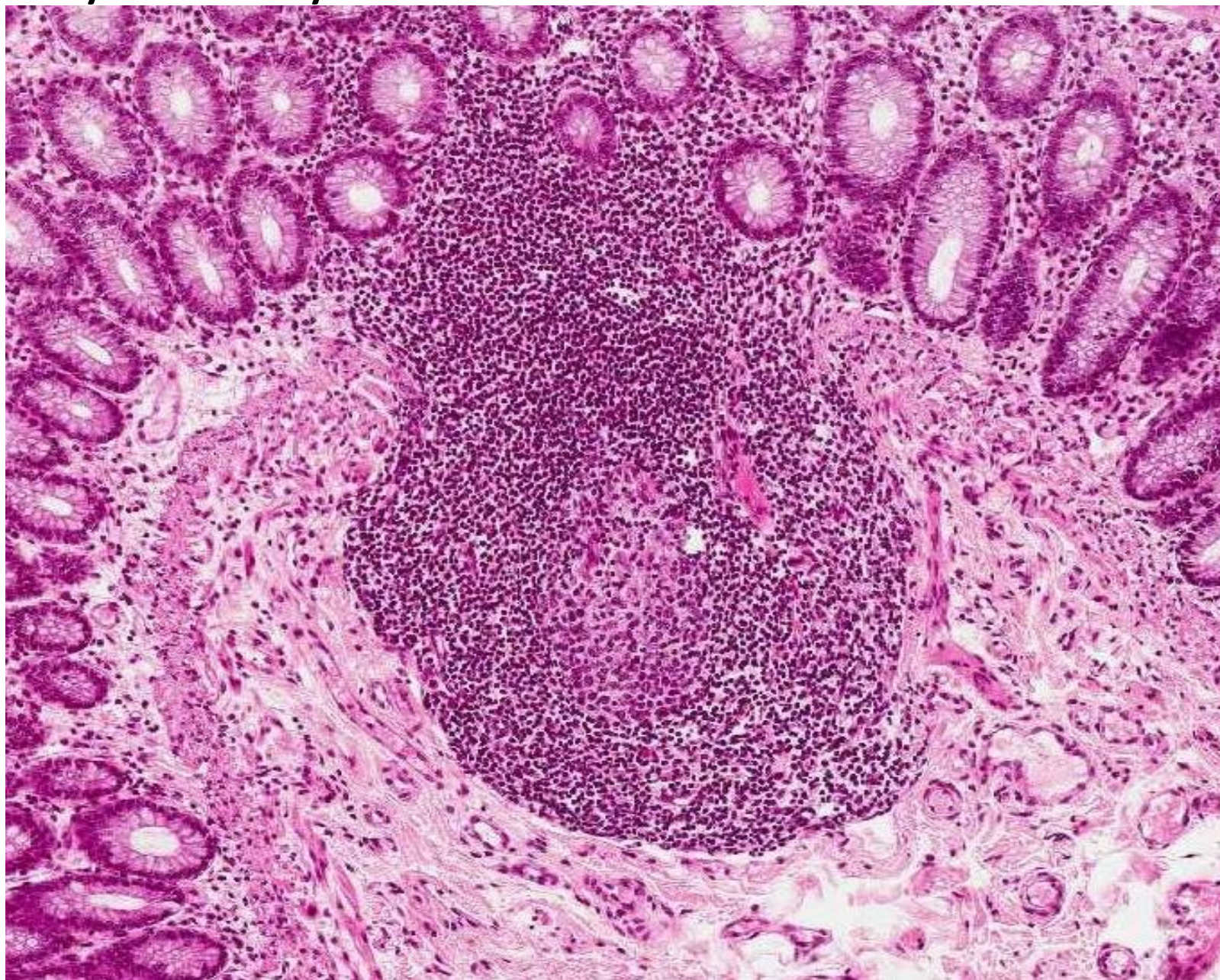




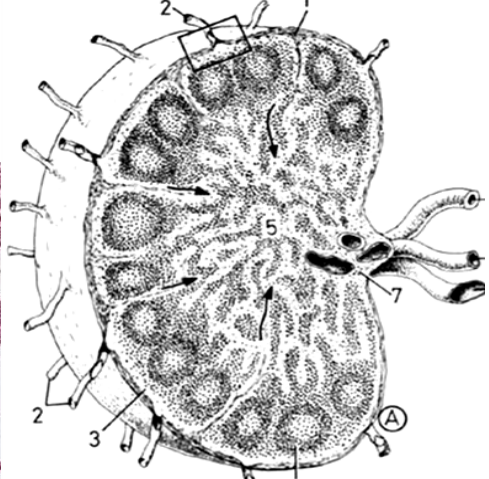
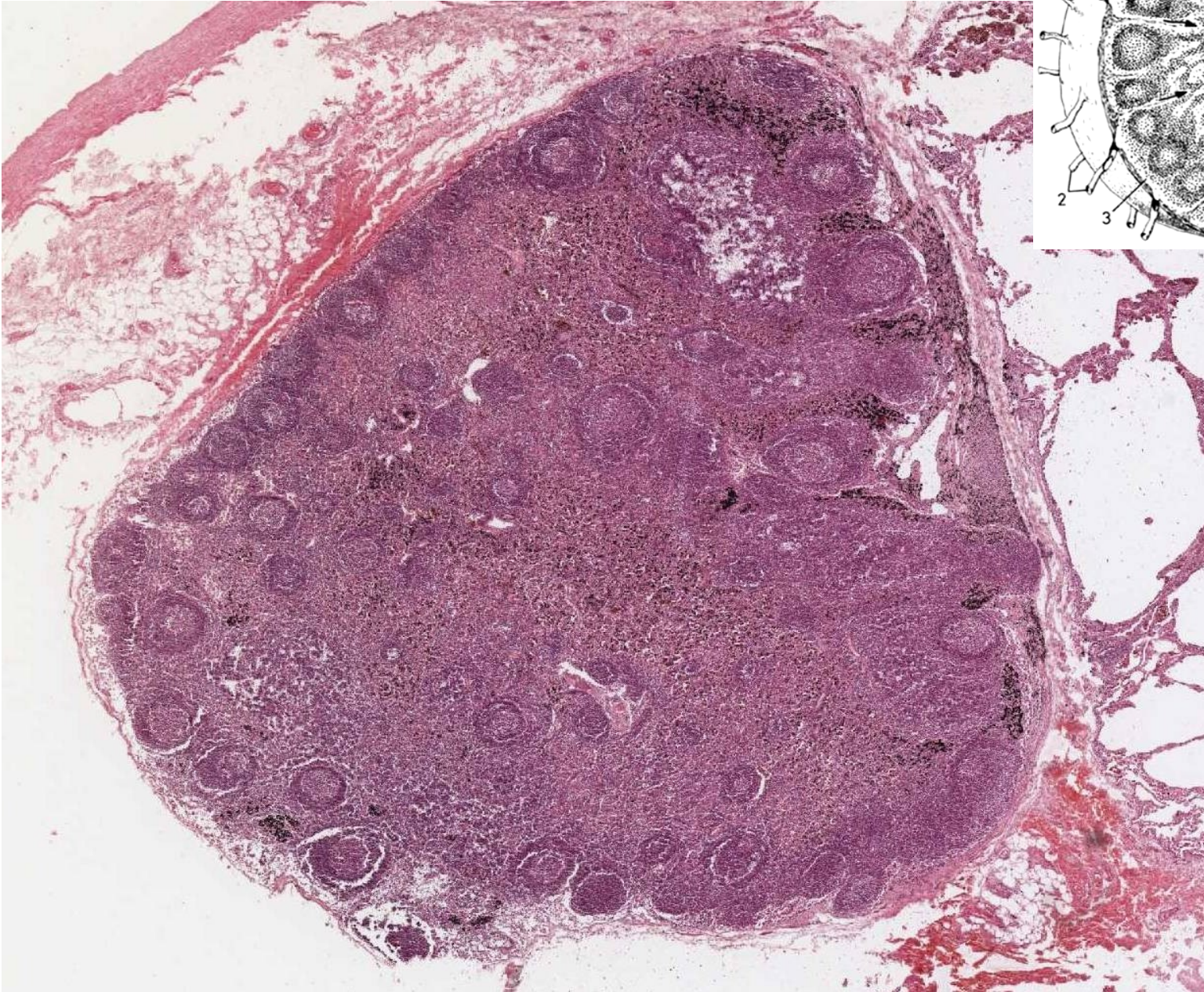
LYMFATICKÝ SYSTÉM

- Lymfatická tkáň, lymfatický uzlík
- Lymfatické orgány:
 - Centrální → thymus, (kostní dřeň)
 - Periferní
 - lymfatická uzlina
 - slezina
 - tonsily
 - lymfatická tkáň ve sliznicích
- Lymfatické cévy

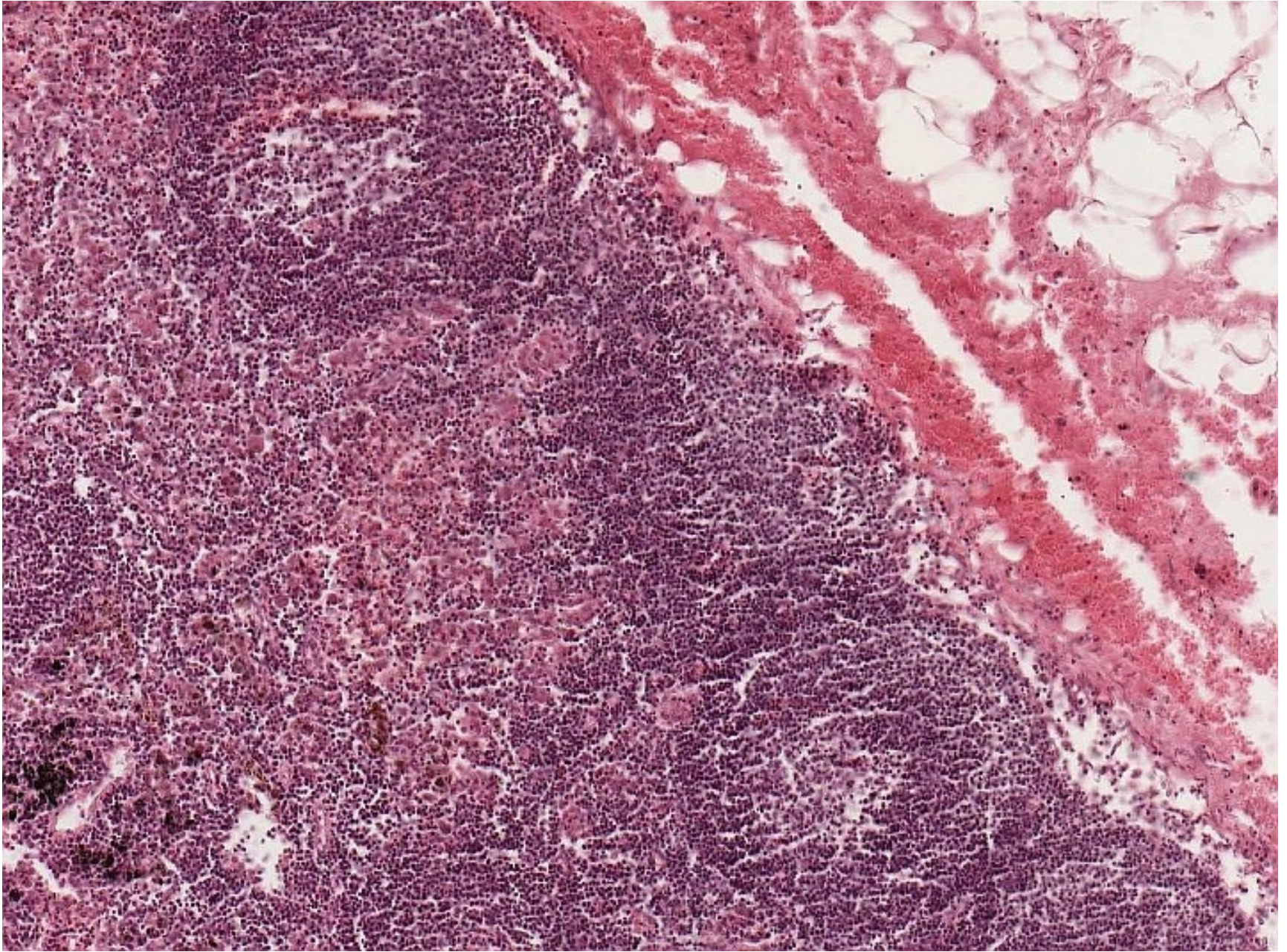
Lymfatický uzlík ve stěně střeva



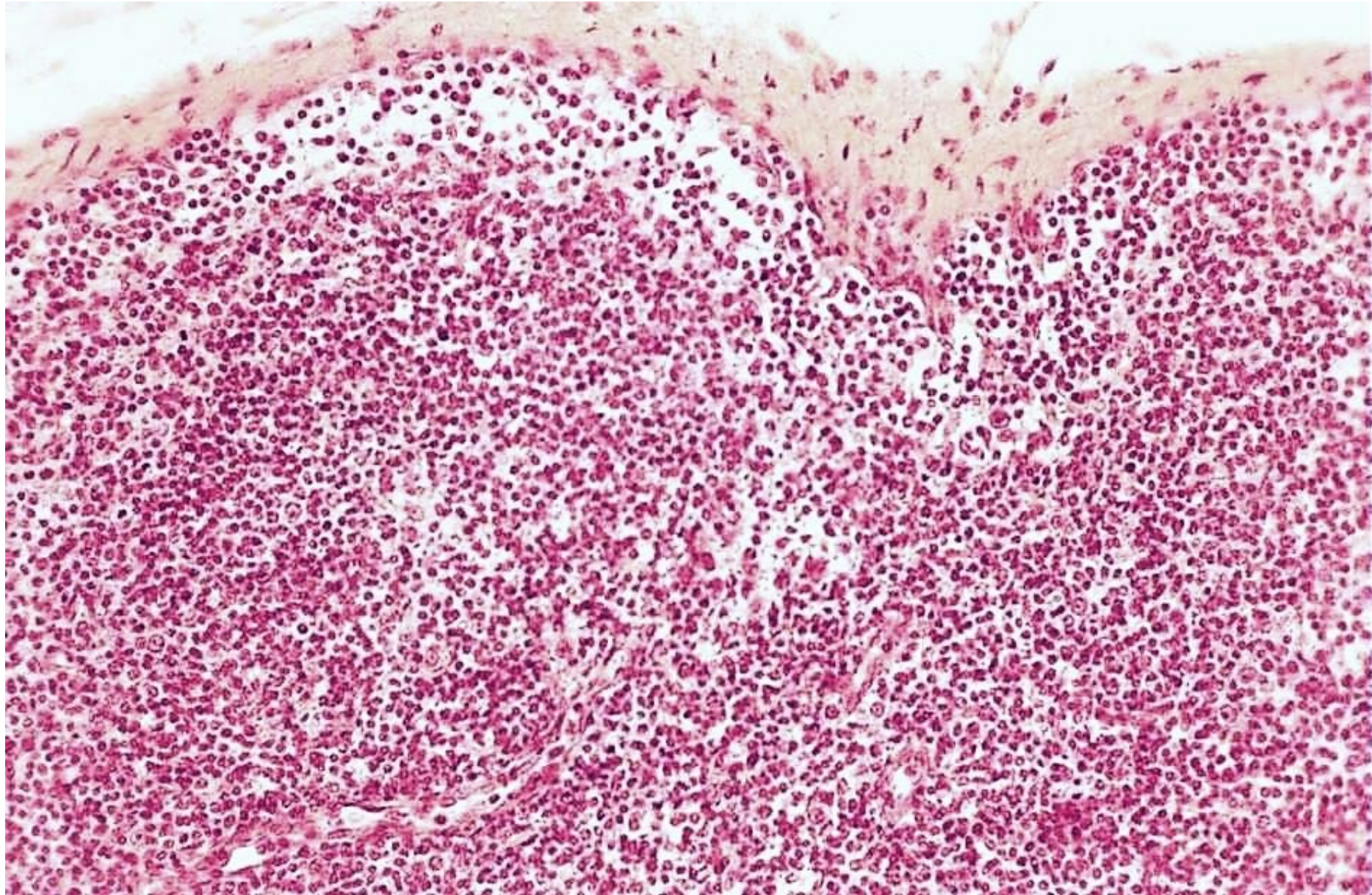
Lymphonodus



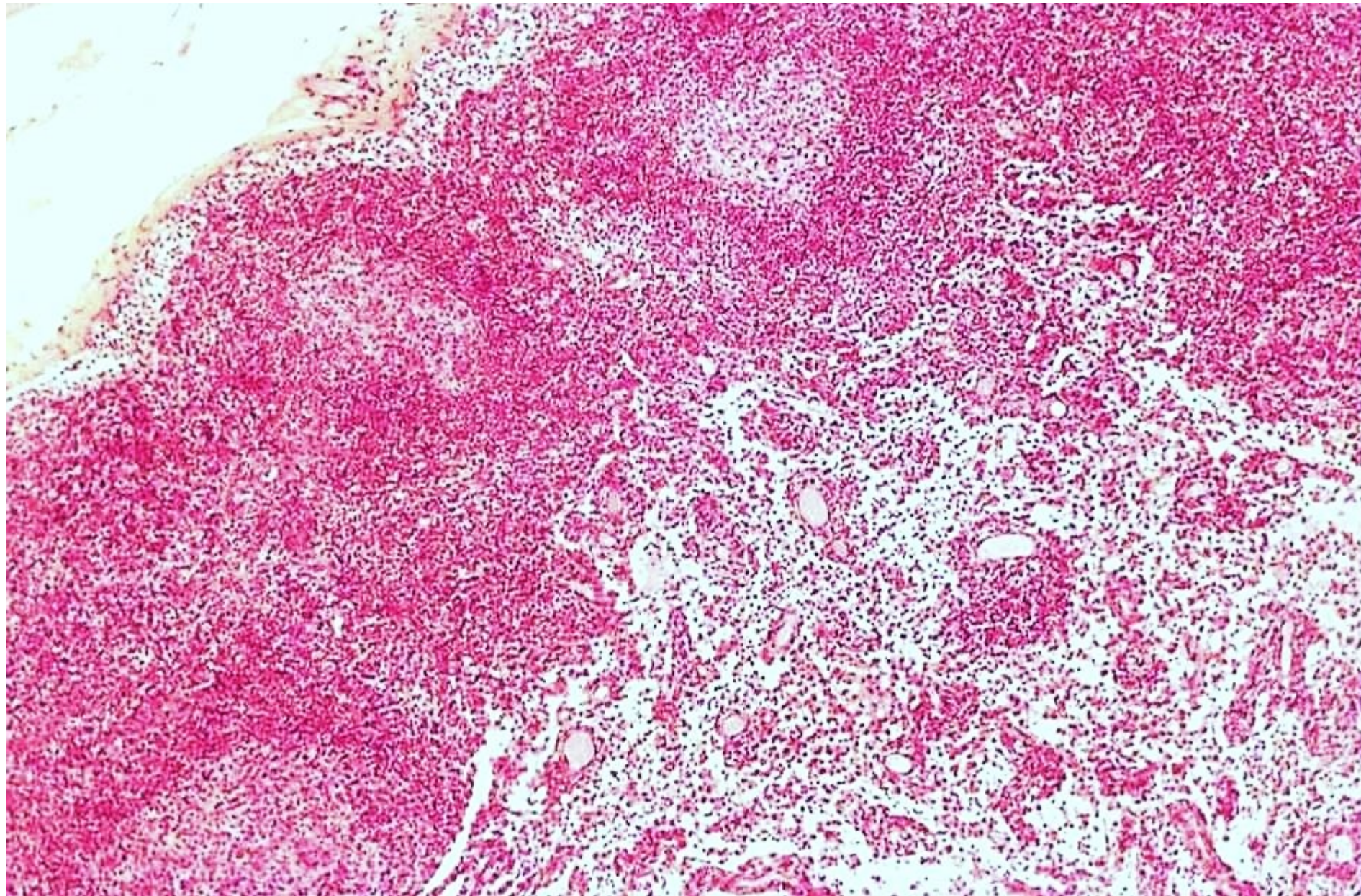
Lymphonodus – pouzdro, subkapsulární sinus, kůra



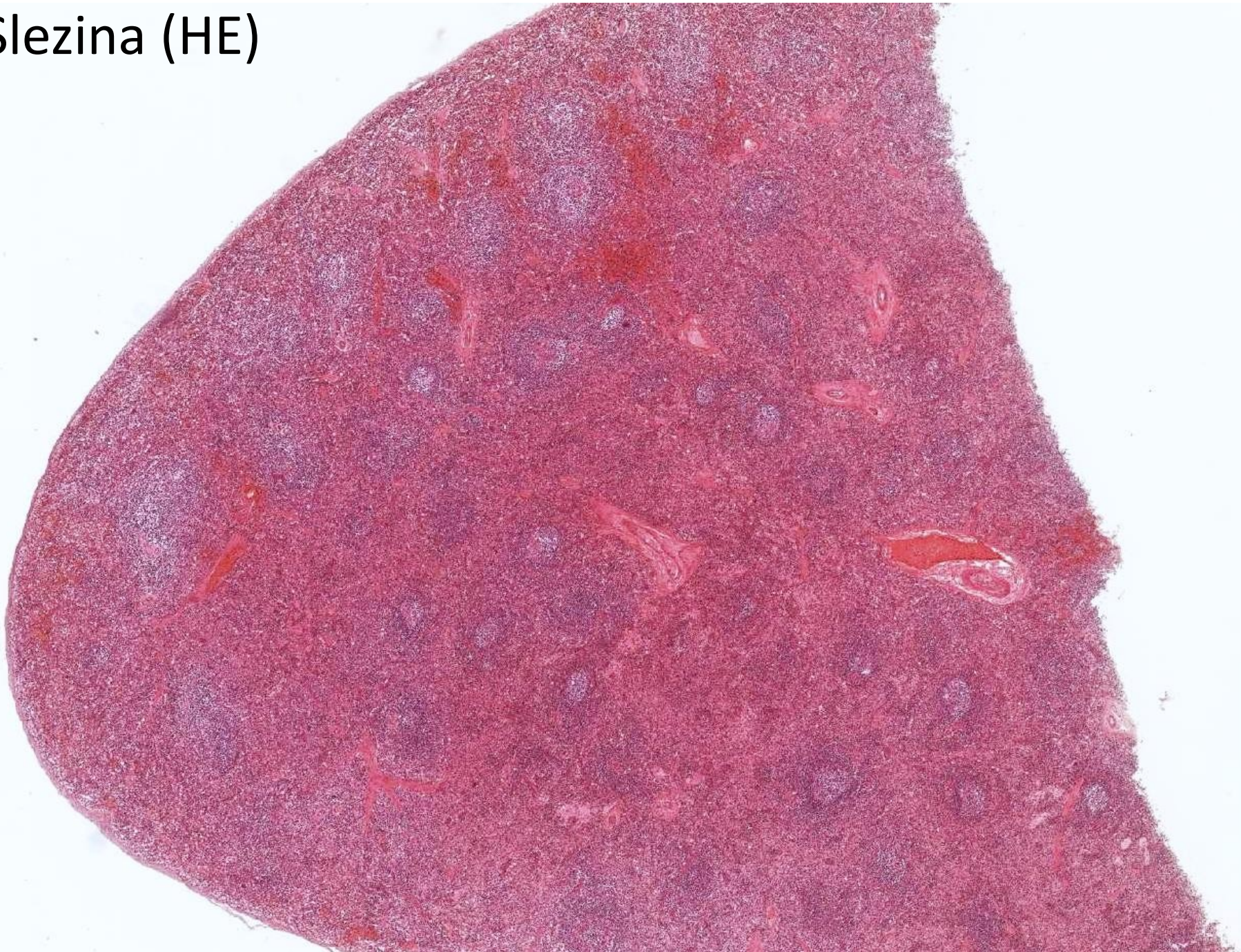
Lymphonodus – pouzdro, subkapsulární sinus, kůra



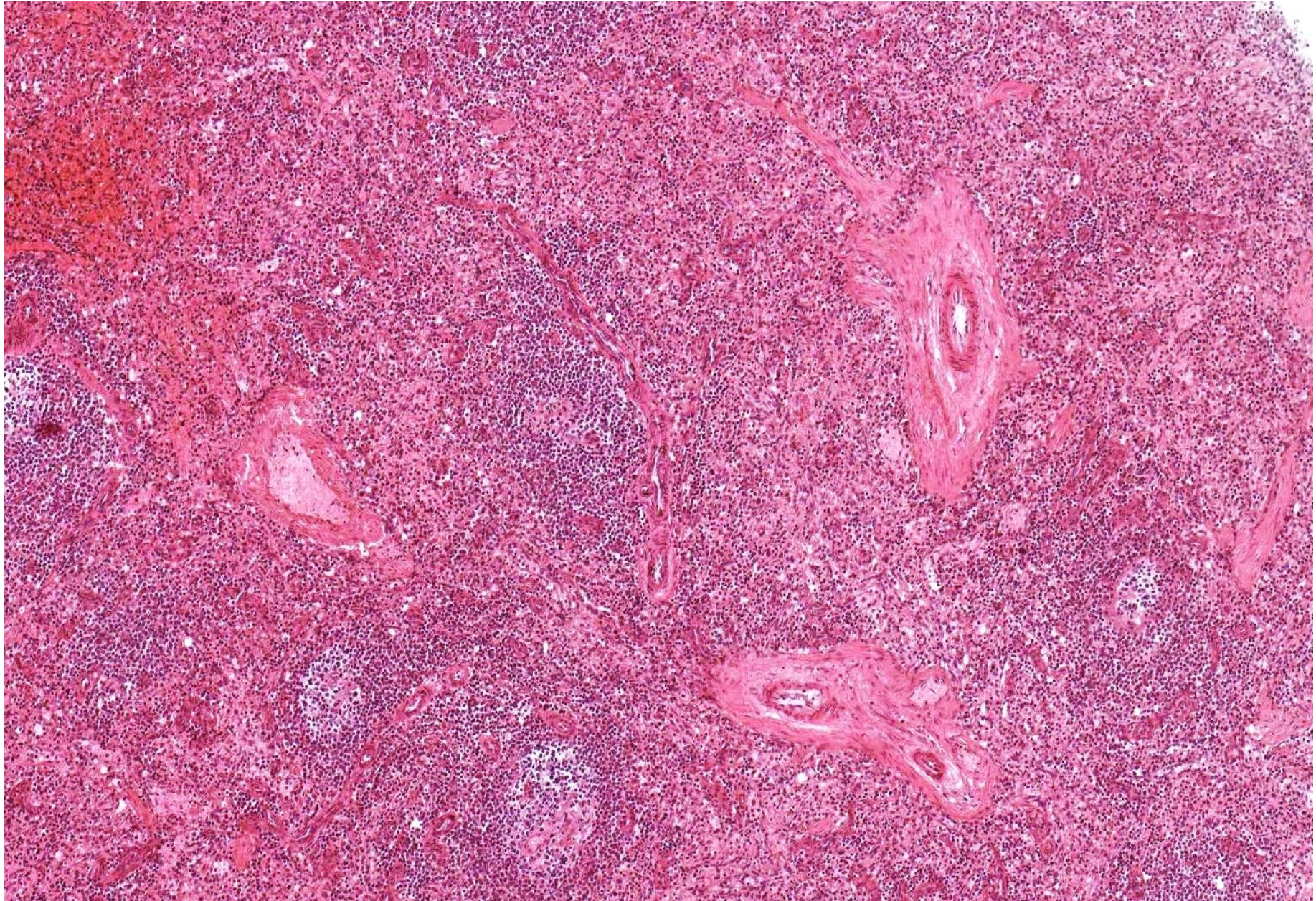
Lymphonodus – kůra, dřeň



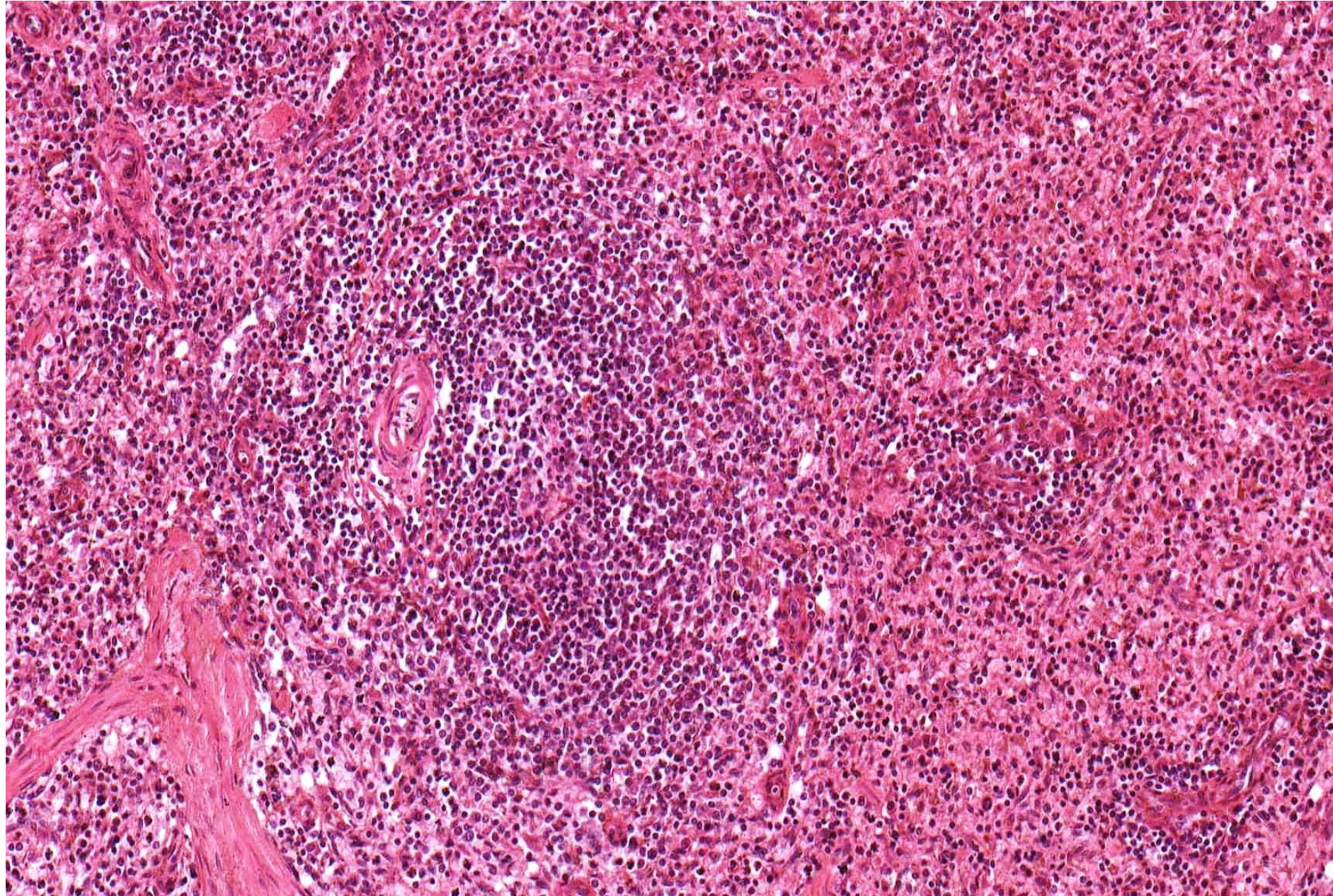
Slezina (HE)



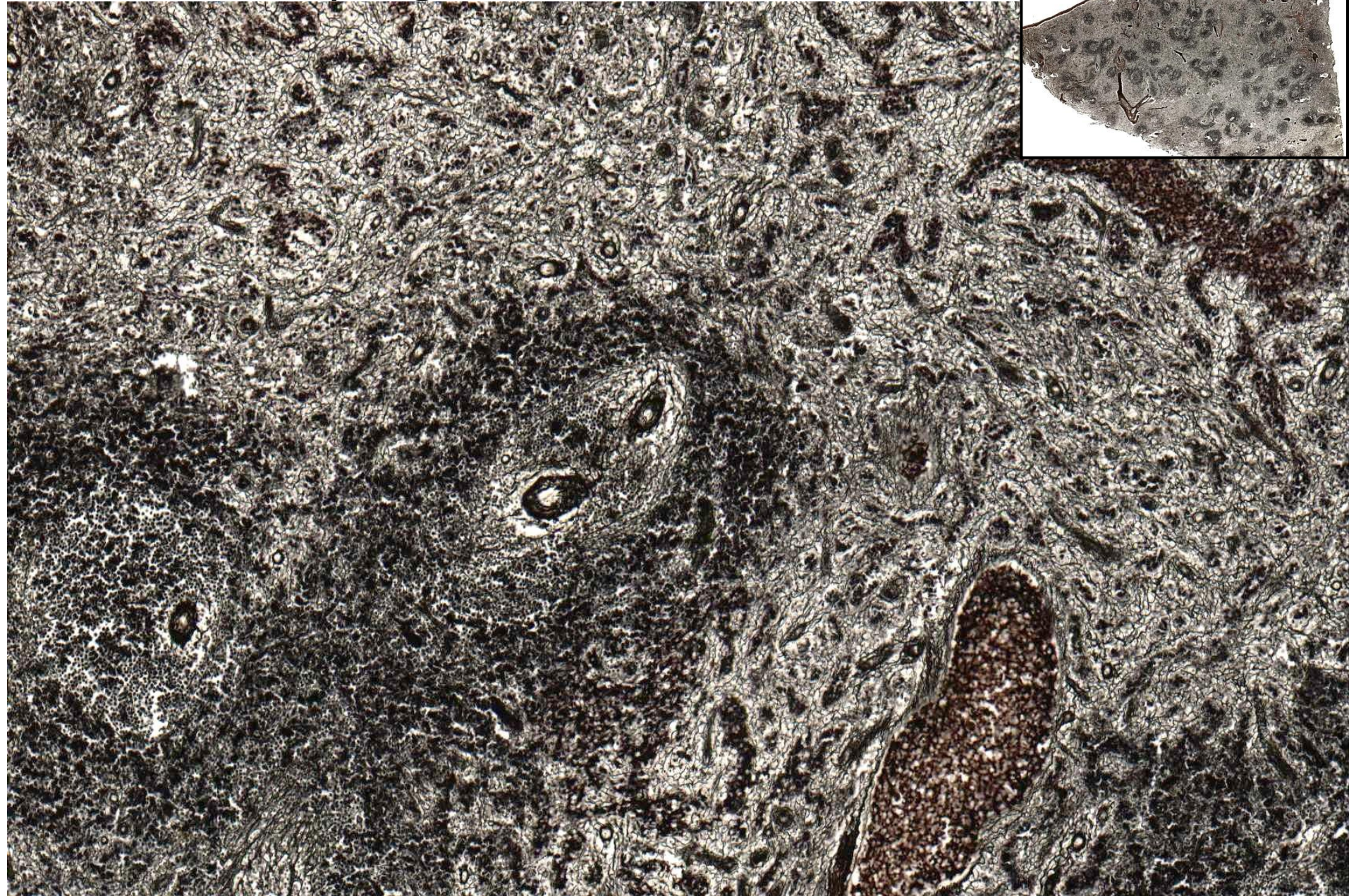
Slezina (HE) – bílá a červená pulpa, trabekuly



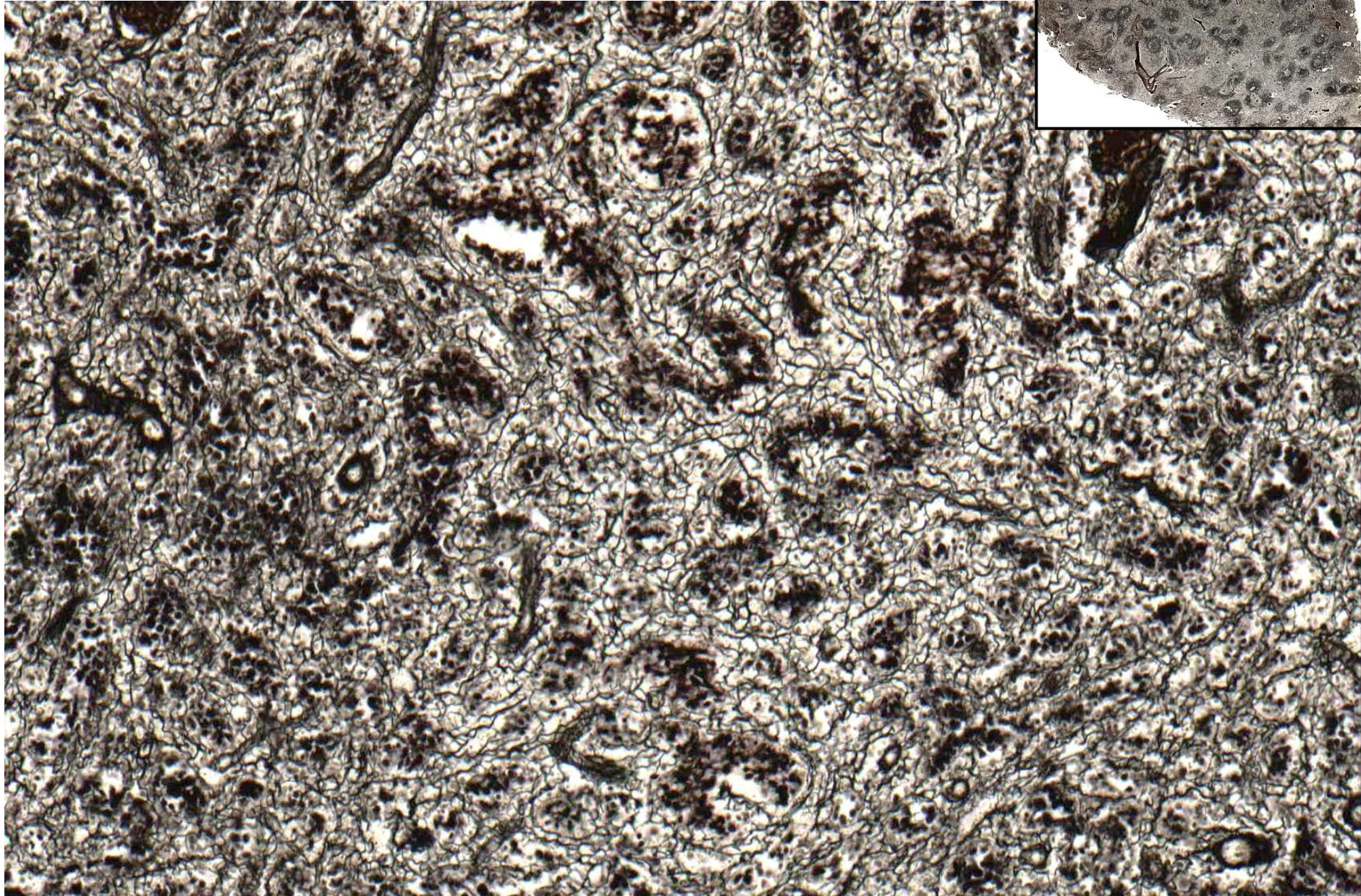
Slezina (HE) – bílá a červená pulpa, a. centralis



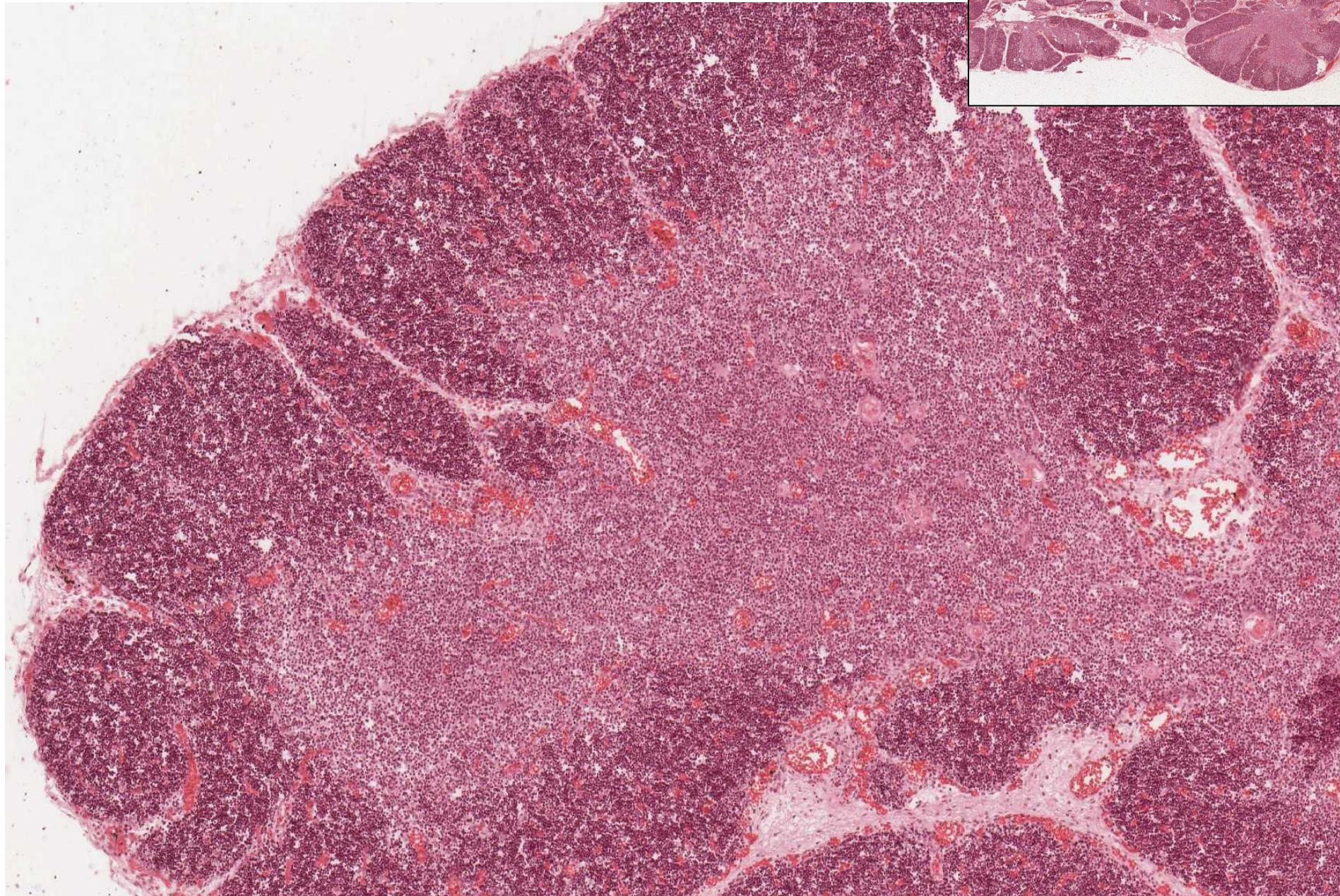
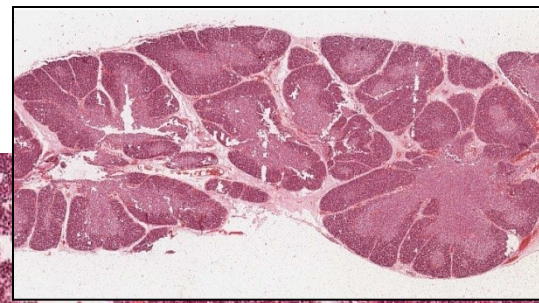
Slezina - impregnace

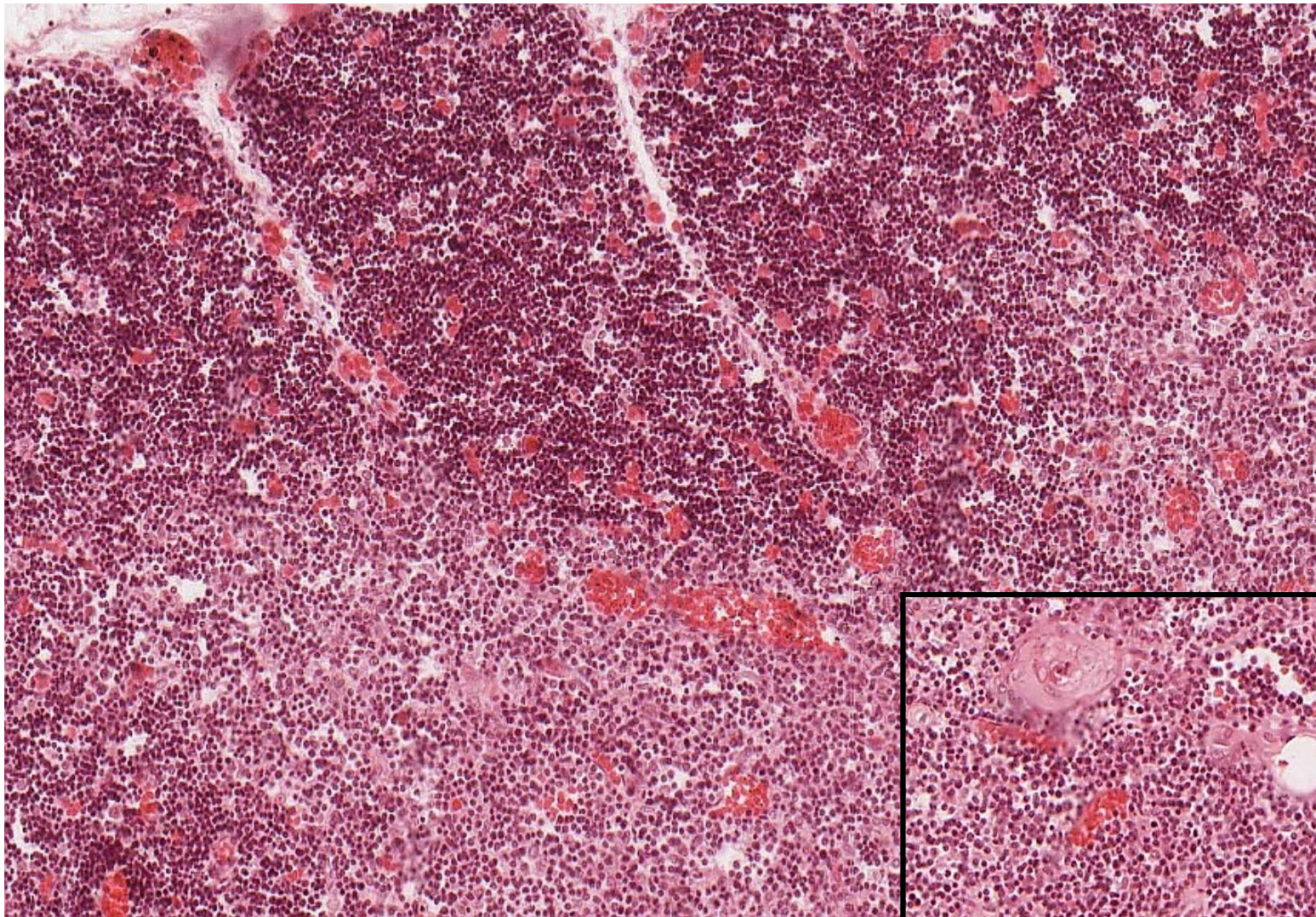


Slezina, červená pulpa - impregnace

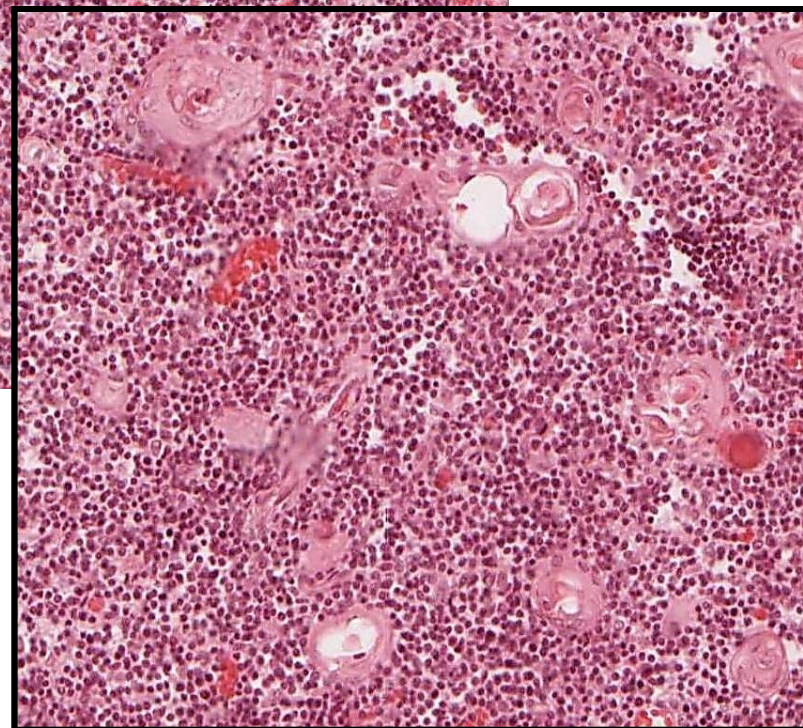


Thymus mladý (HE)

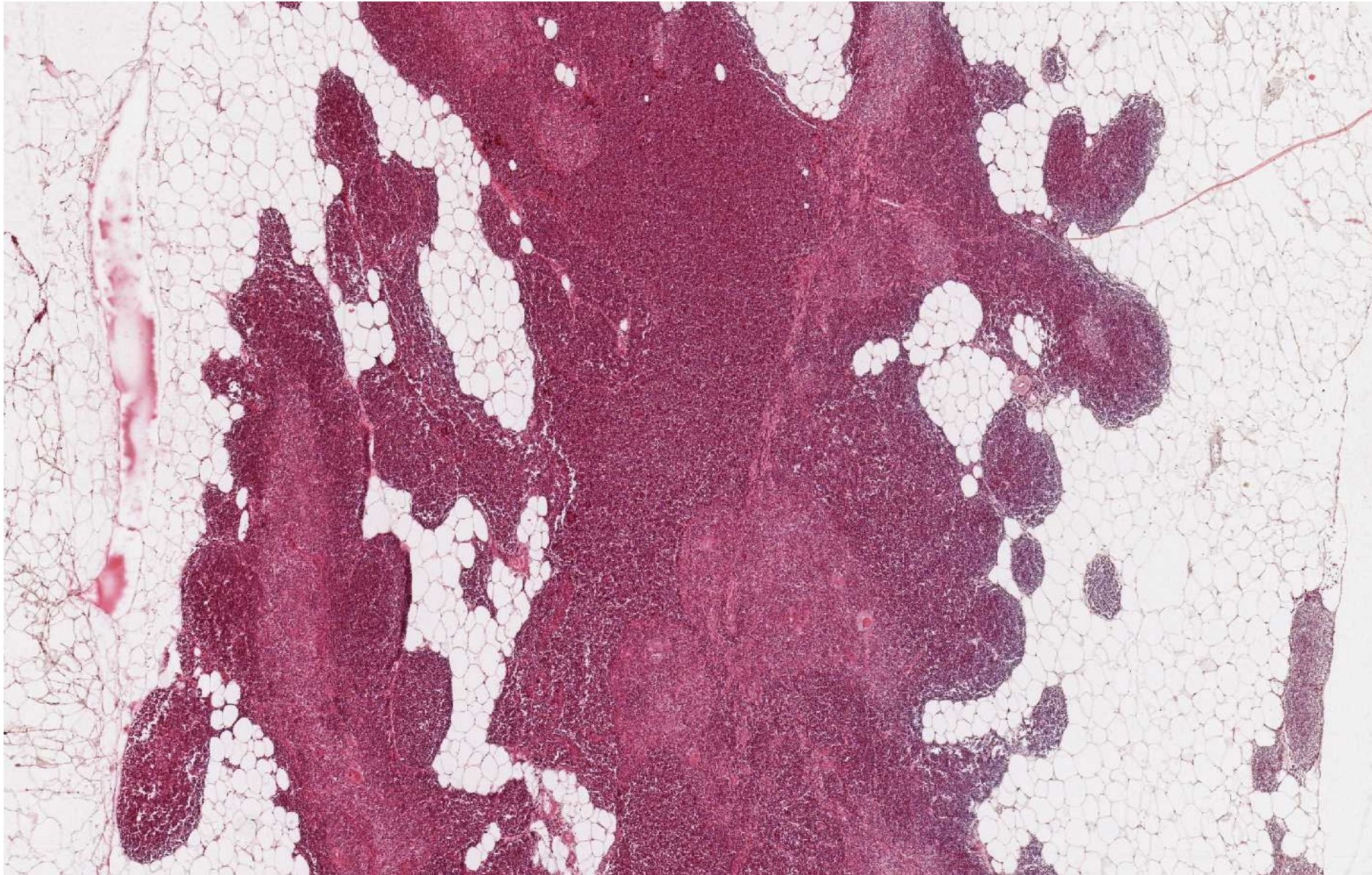




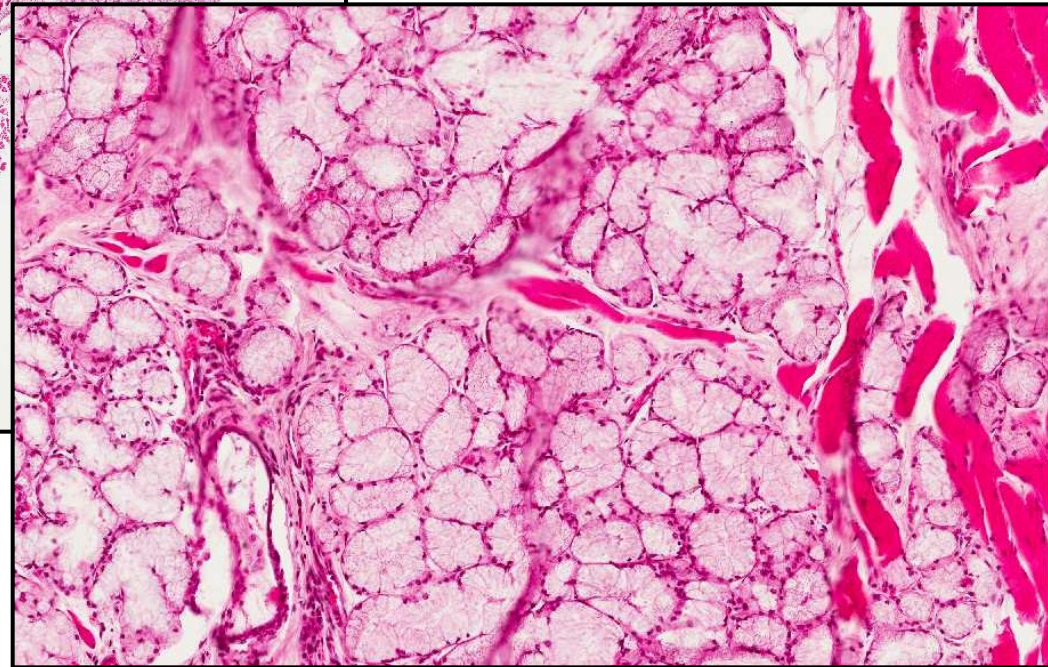
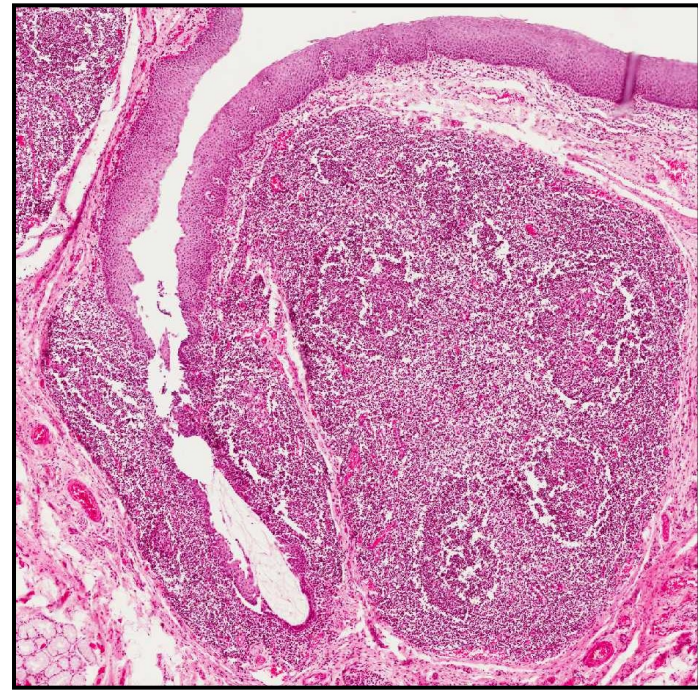
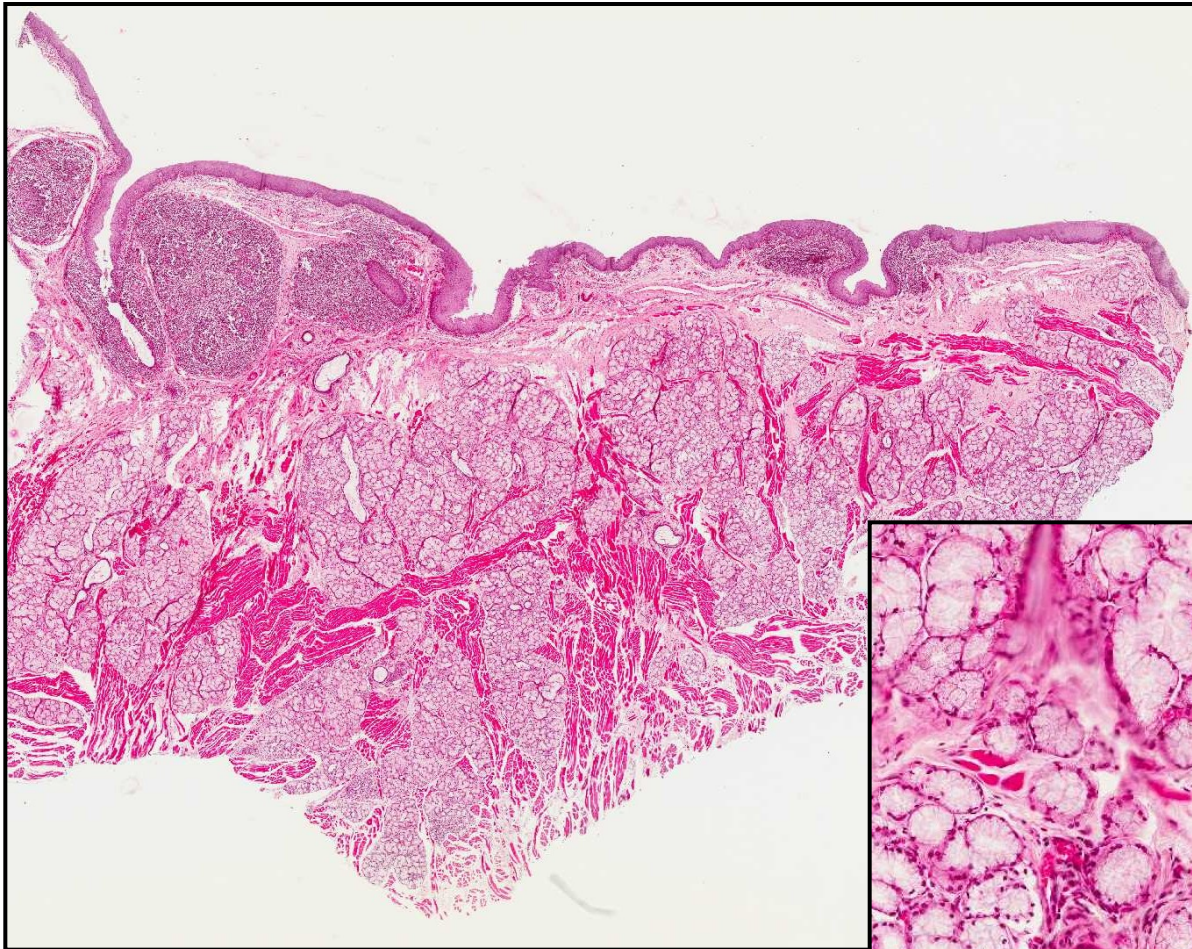
Thymus mladý – kůra a dřeň
Hassalova tělíška



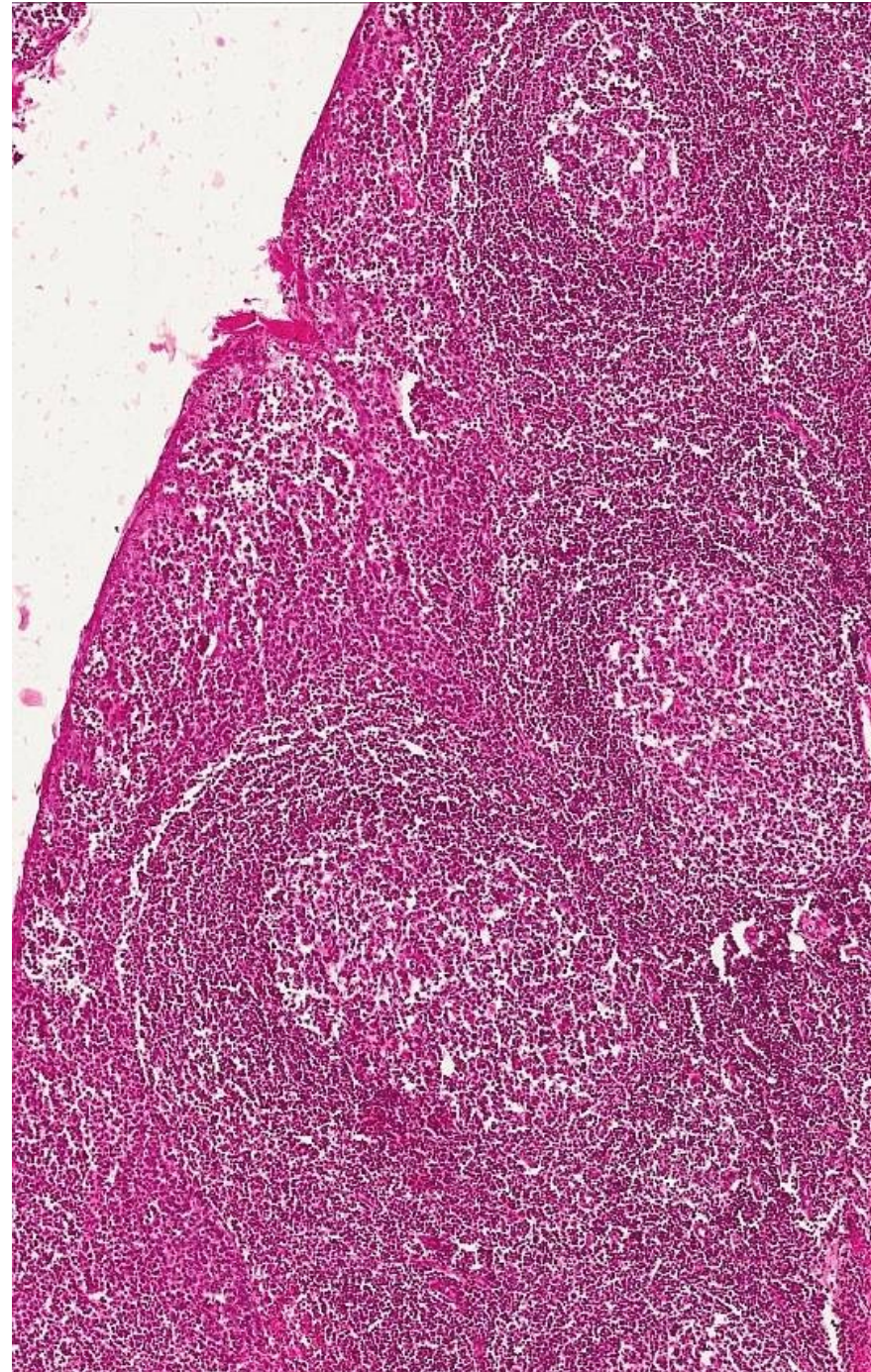
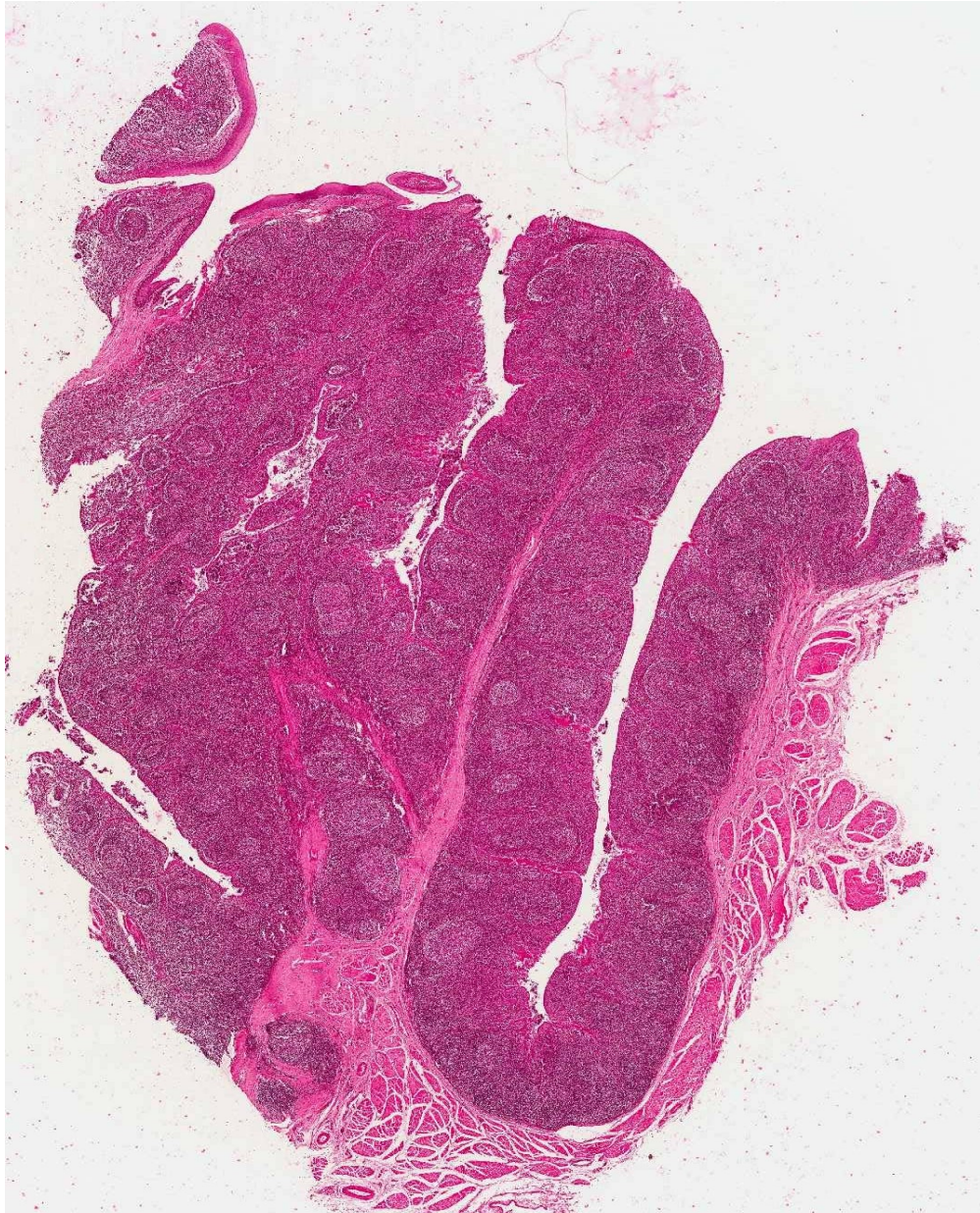Thymus v involuci (HE)



Tonsilla lingualis (HE)



Tonsilla palatina (HE)





LYMFATICKÝ SYSTÉM

Preparáty

66. Lymphonodus (HE)

67. Lien (HE)

68. Lien (impregnace)

57. Thymus mladý (HE)

58. Thymus v involuci (HE)

4. Tonsilla lingualis (HE)

6. Tonsilla palatina (HE)