



# Mužský pohlavní systém

gonády – testes

vývodní cesty

- epididymis
- ductus deferens
- ductus ejaculatorius
- mužská urethra

akcesorní žlázy

- prostata
- vesiculae seminales (gll. vesiculosae)
- gll. bulbourethrales

zevní pohl. orgány

- penis

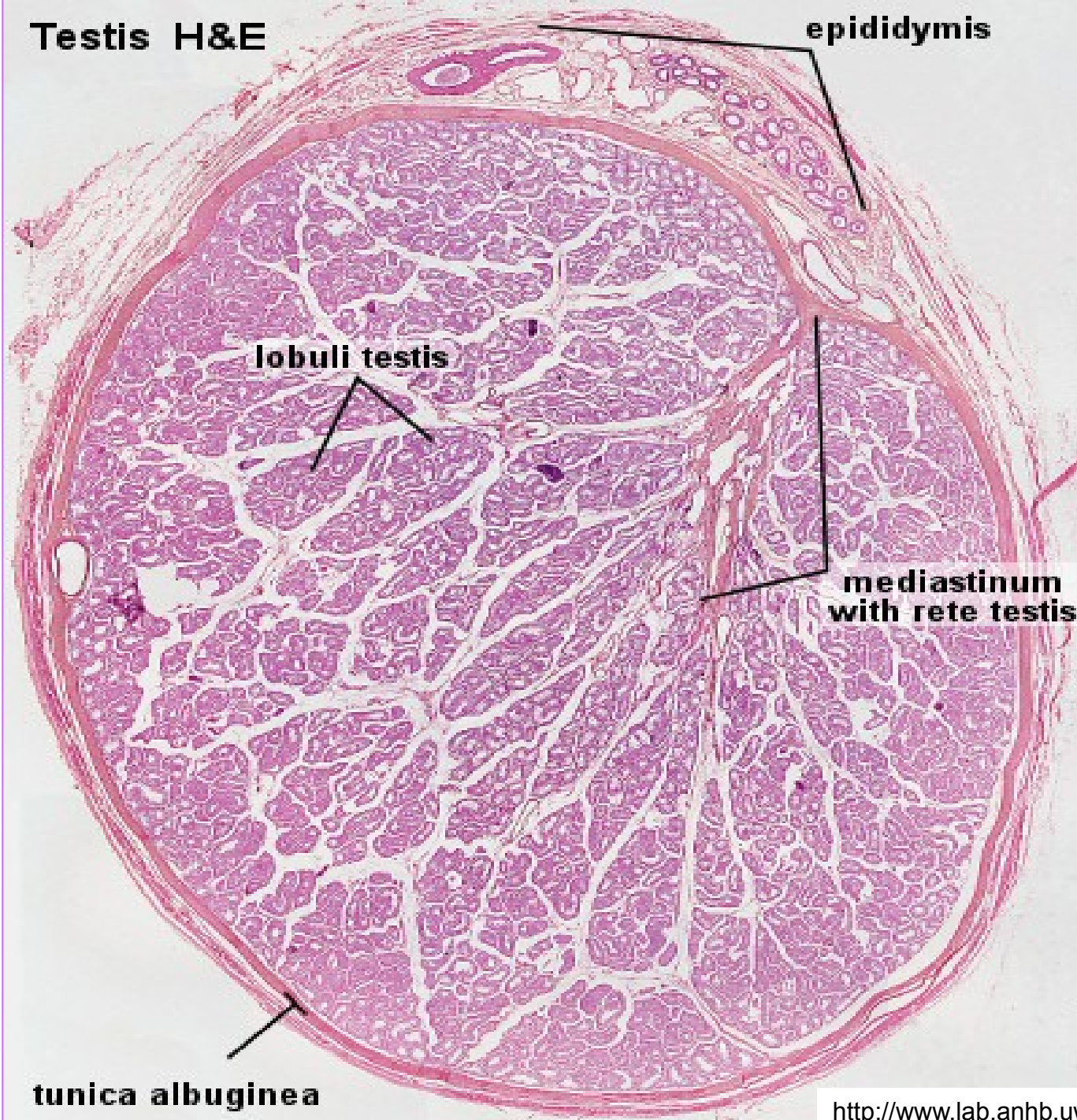
**Testis H&E**

**epididymis**

**lobuli testis**

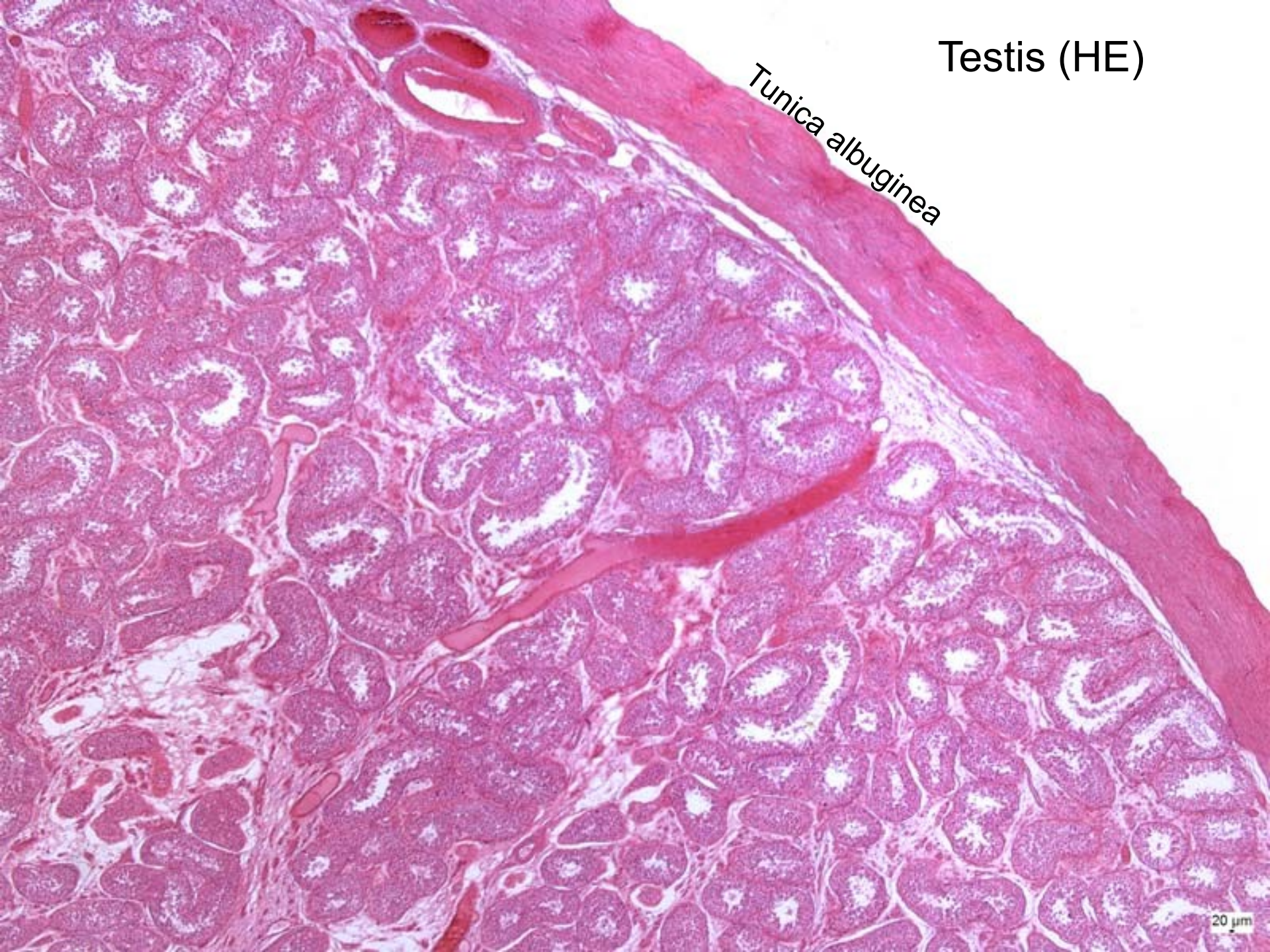**mediastinum  
with rete testis**

**tunica albuginea**

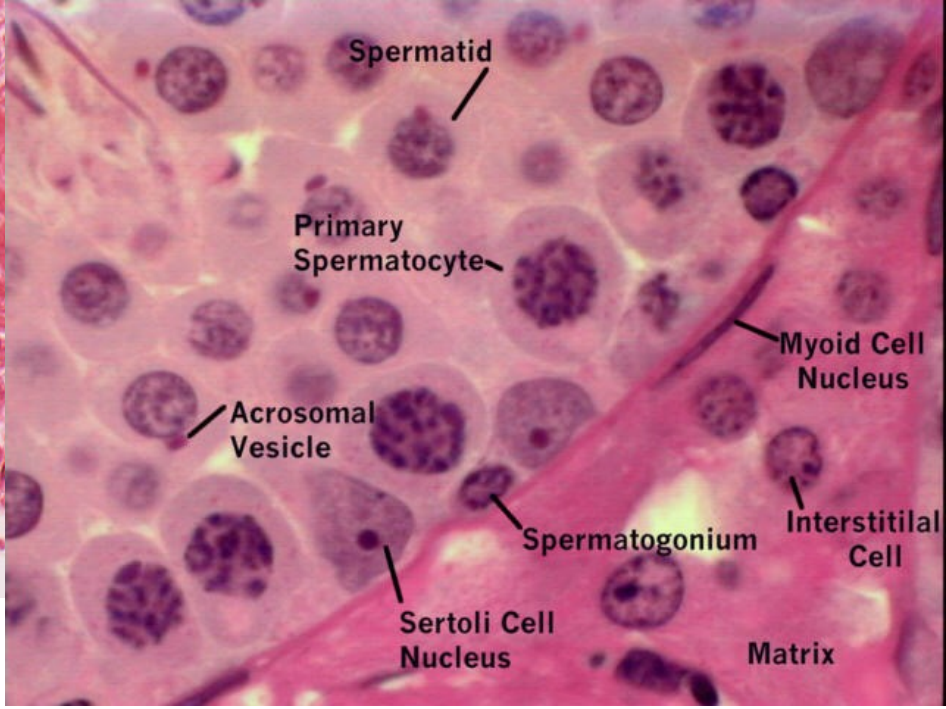
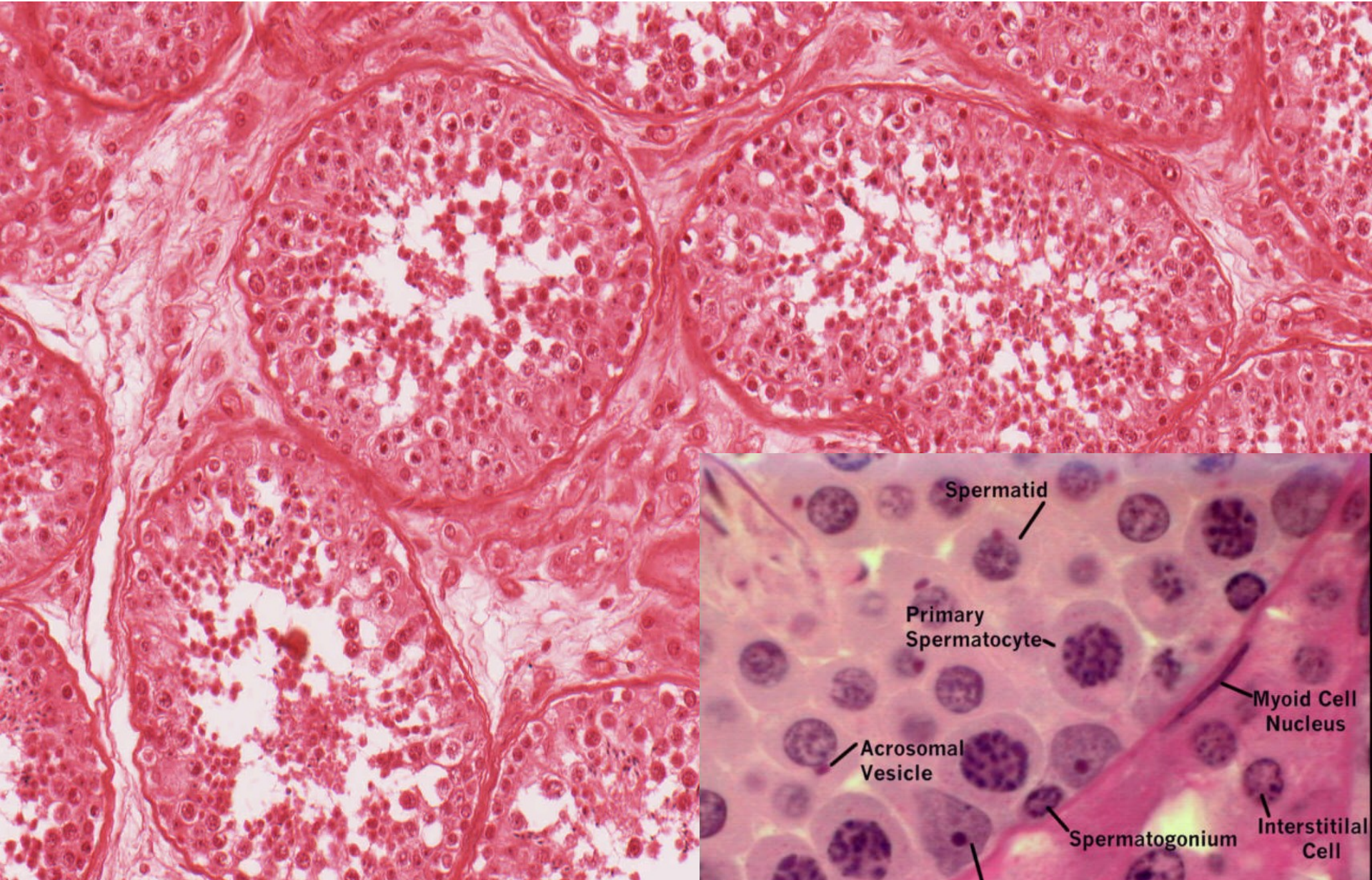


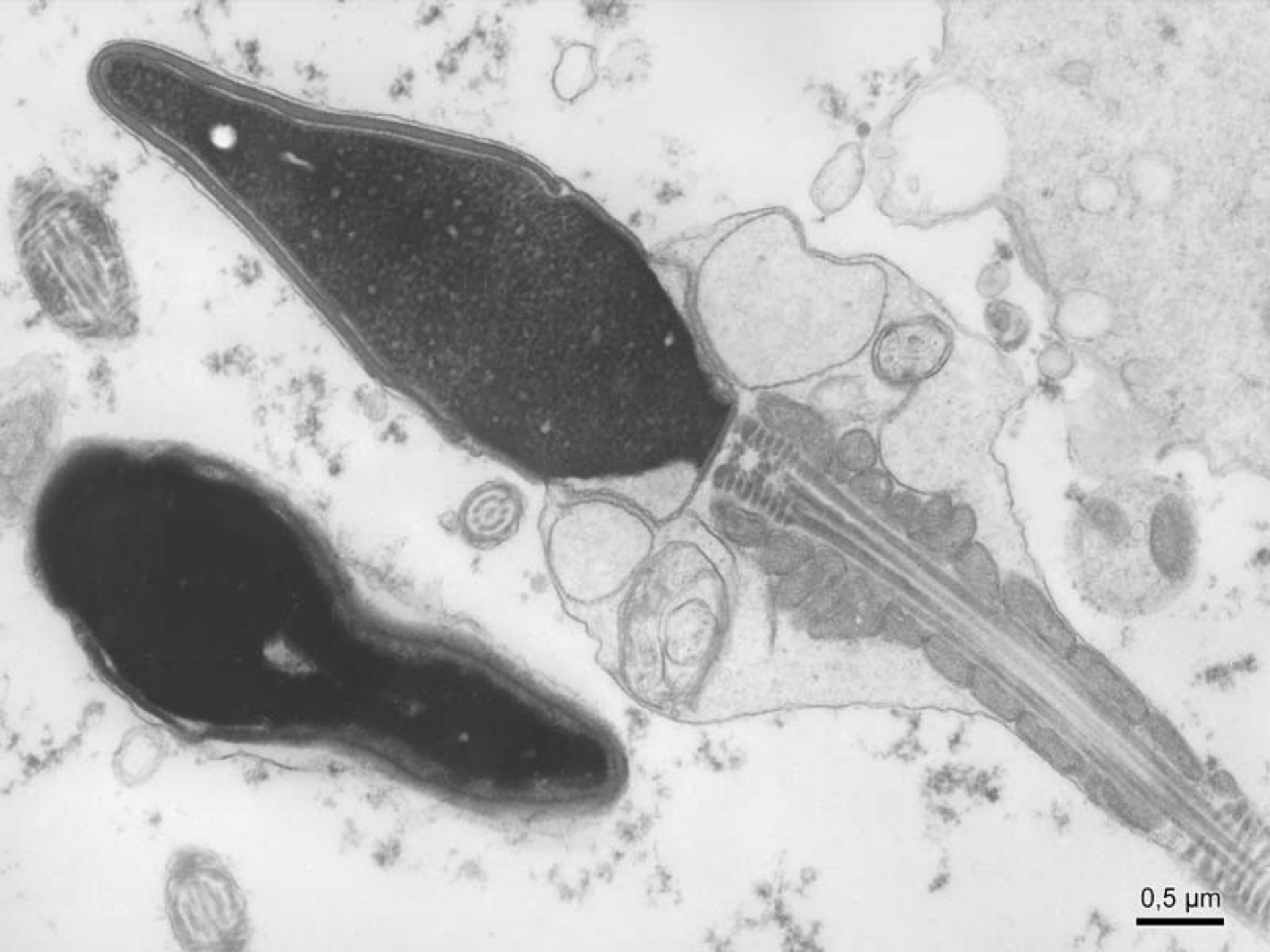# Testis (HE)

*Tunica albuginea*



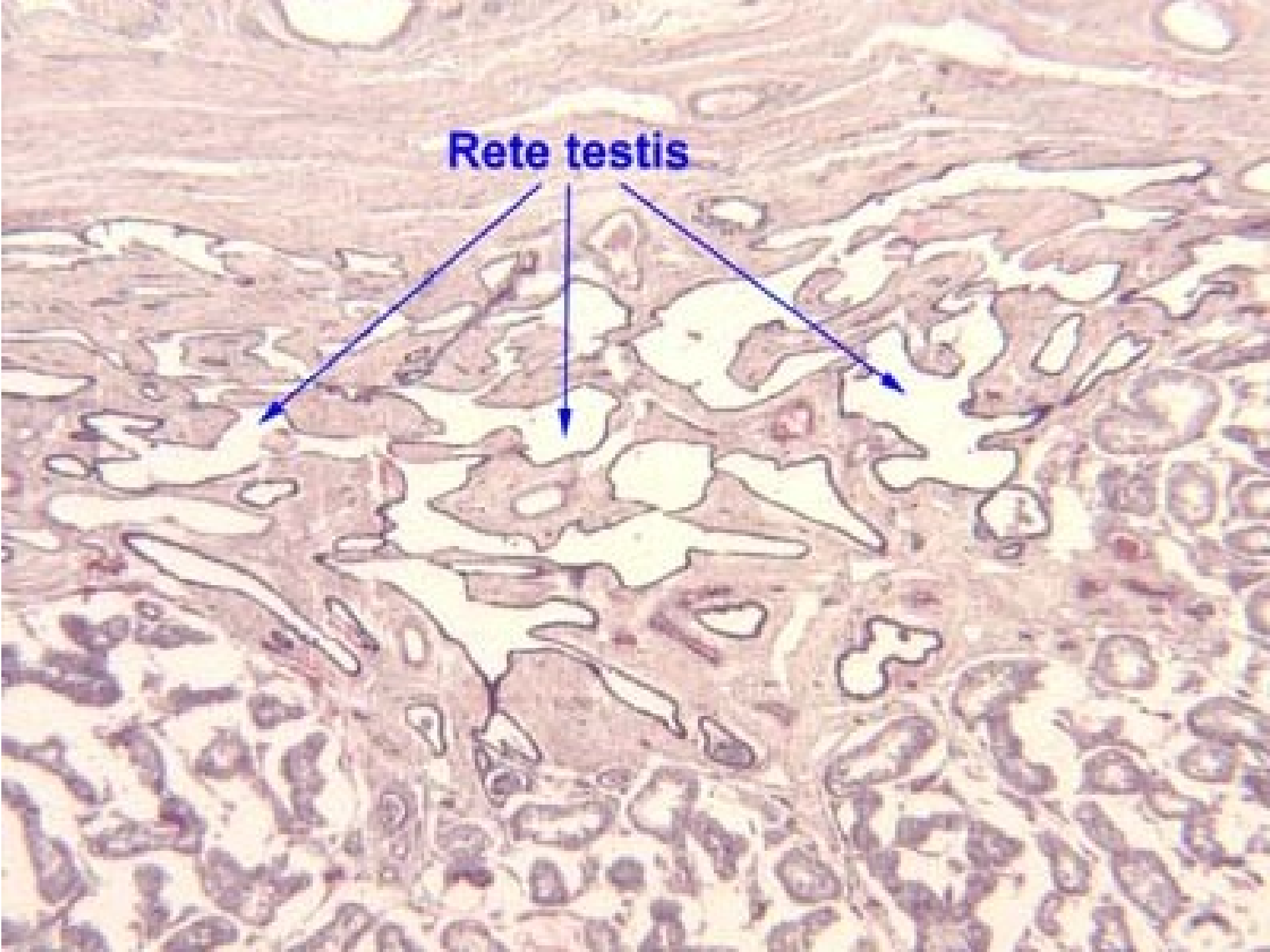# Tubuli seminiferi contorti - spermatogeneze



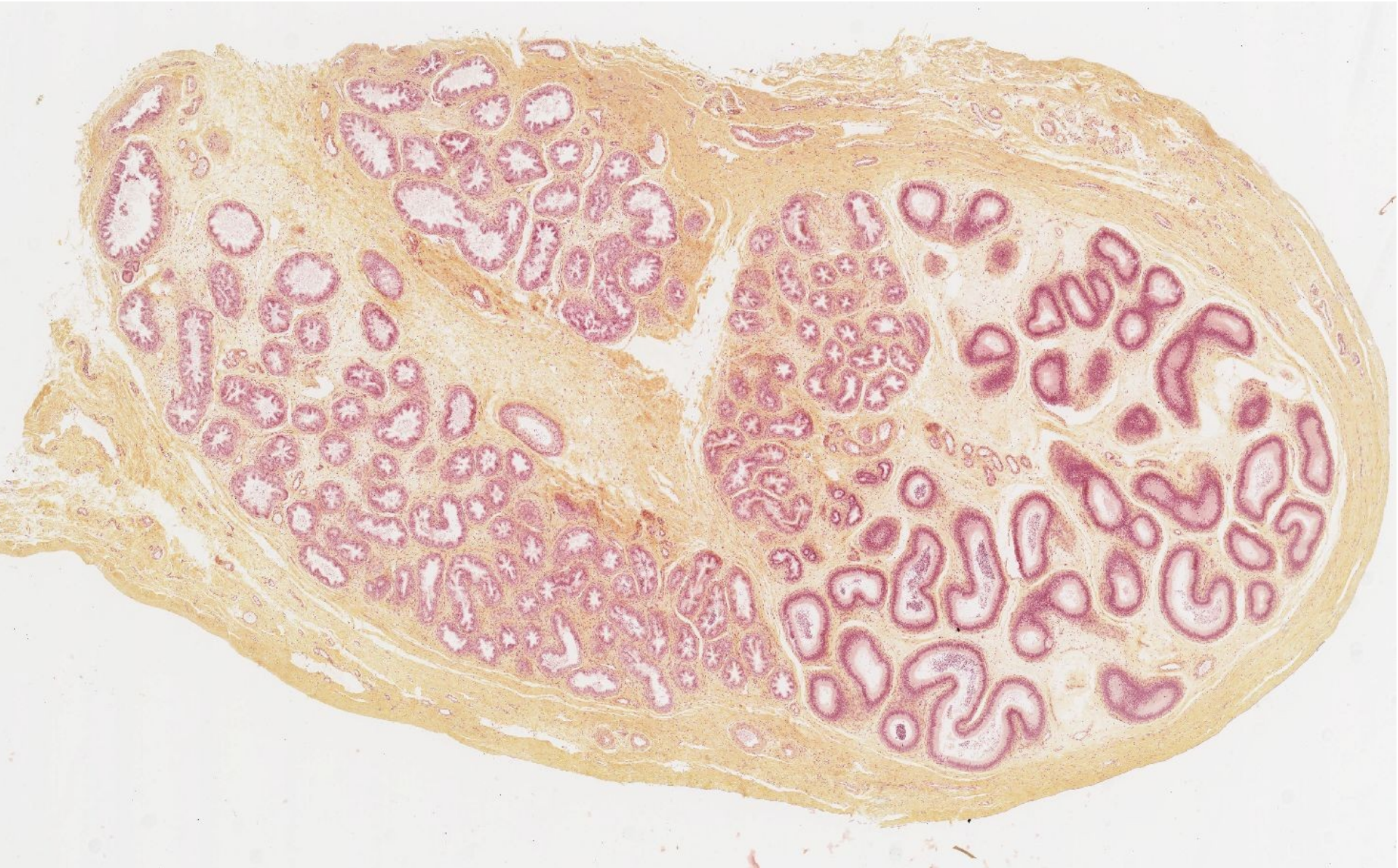

0,5 μm

**Rete testis**

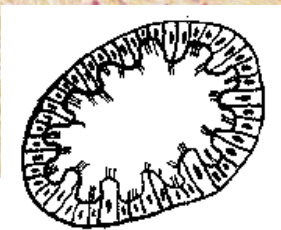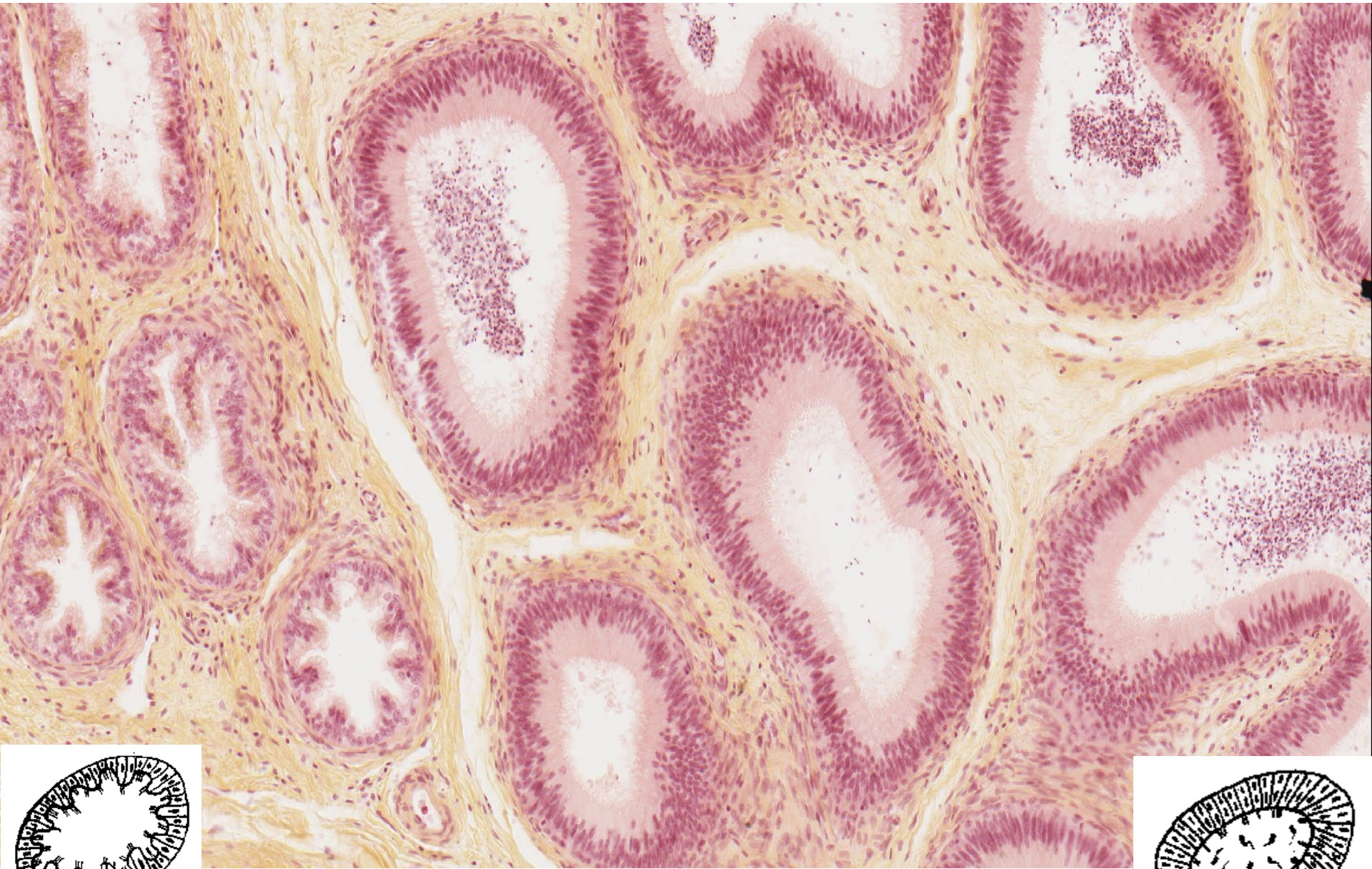


Epididymis (HEŠ)



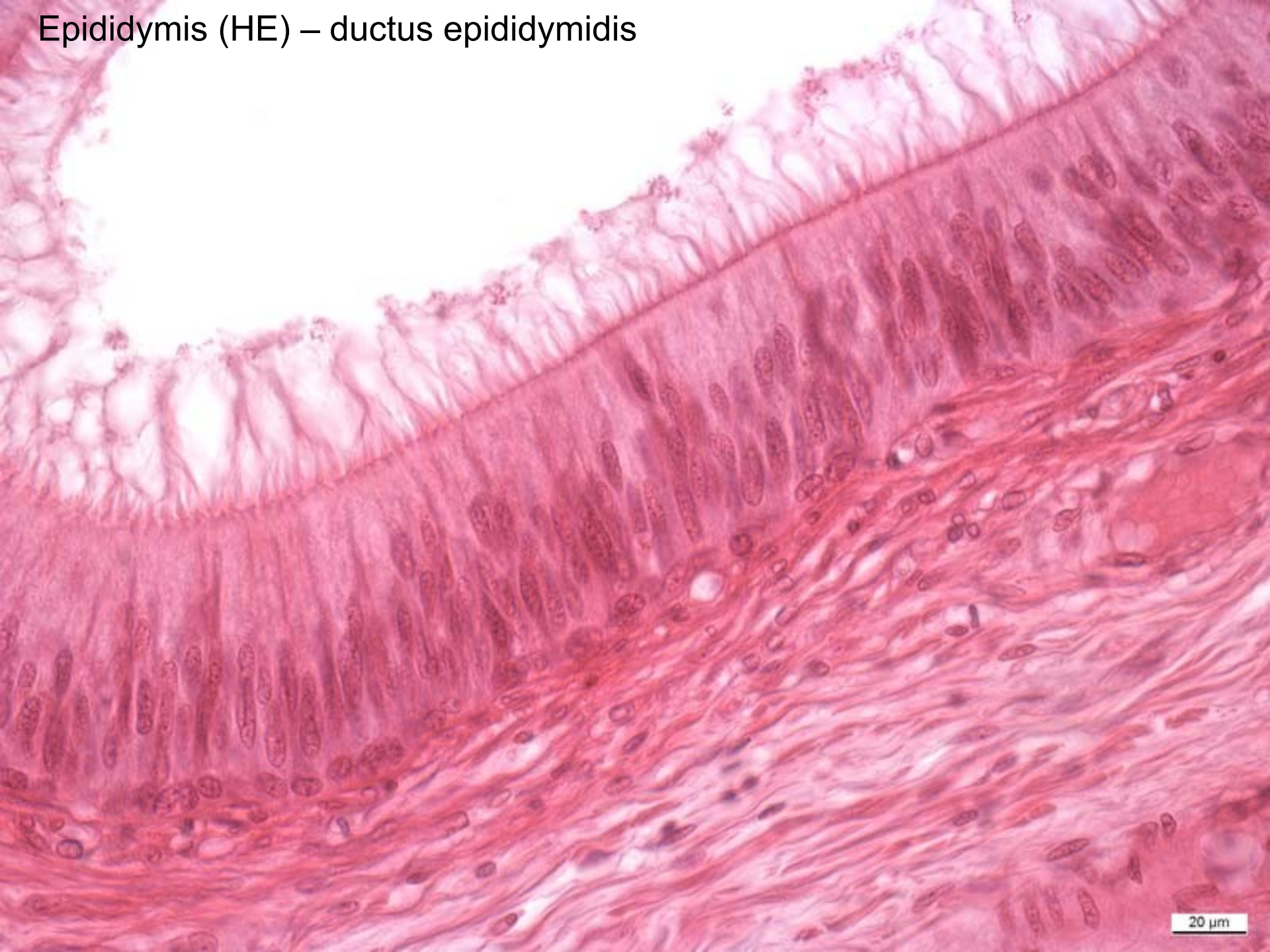Ductuli efferentes

Ductus epididymidis



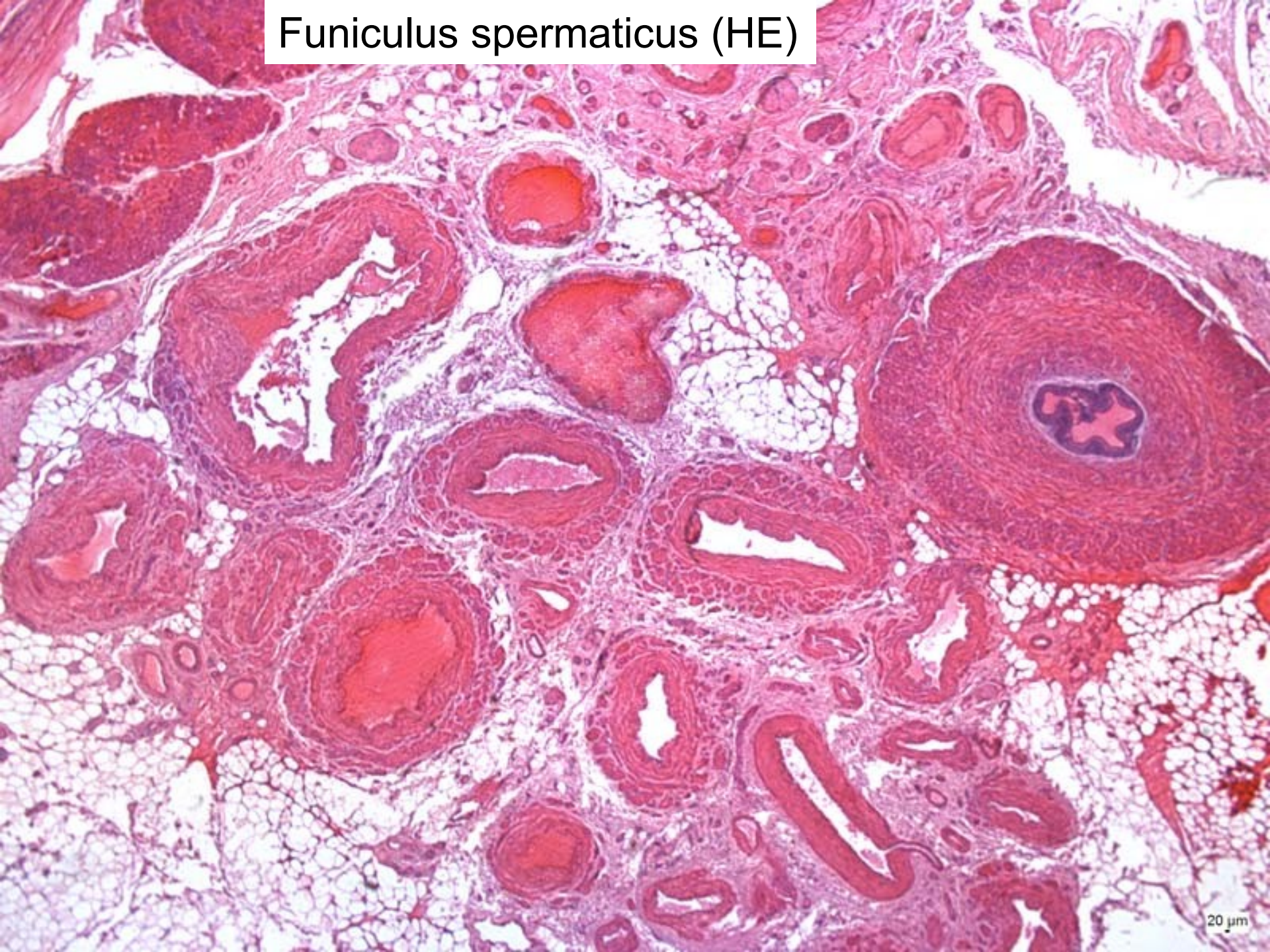


Epididymis (HE) – ductus epididymidis

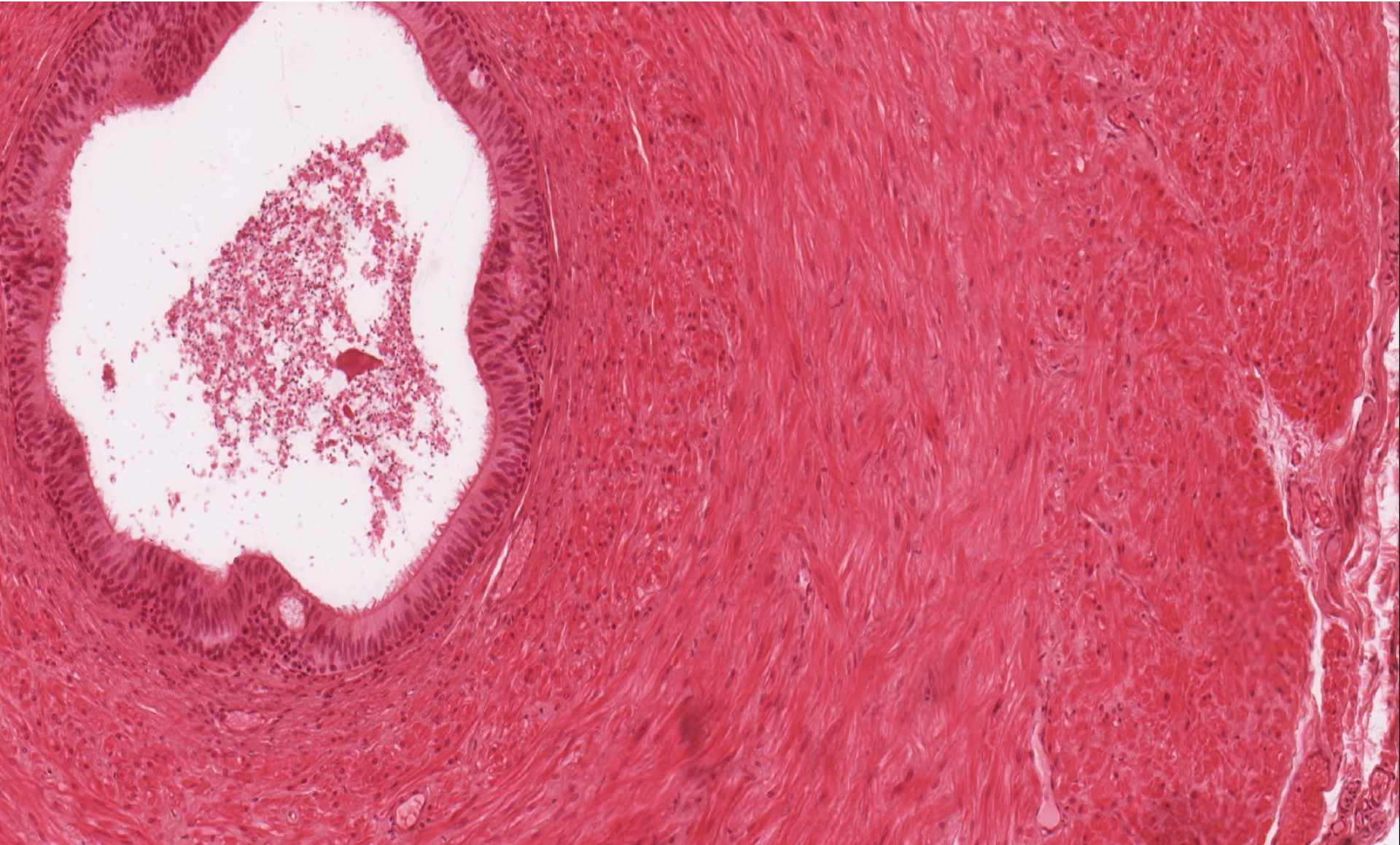


20  $\mu$ m

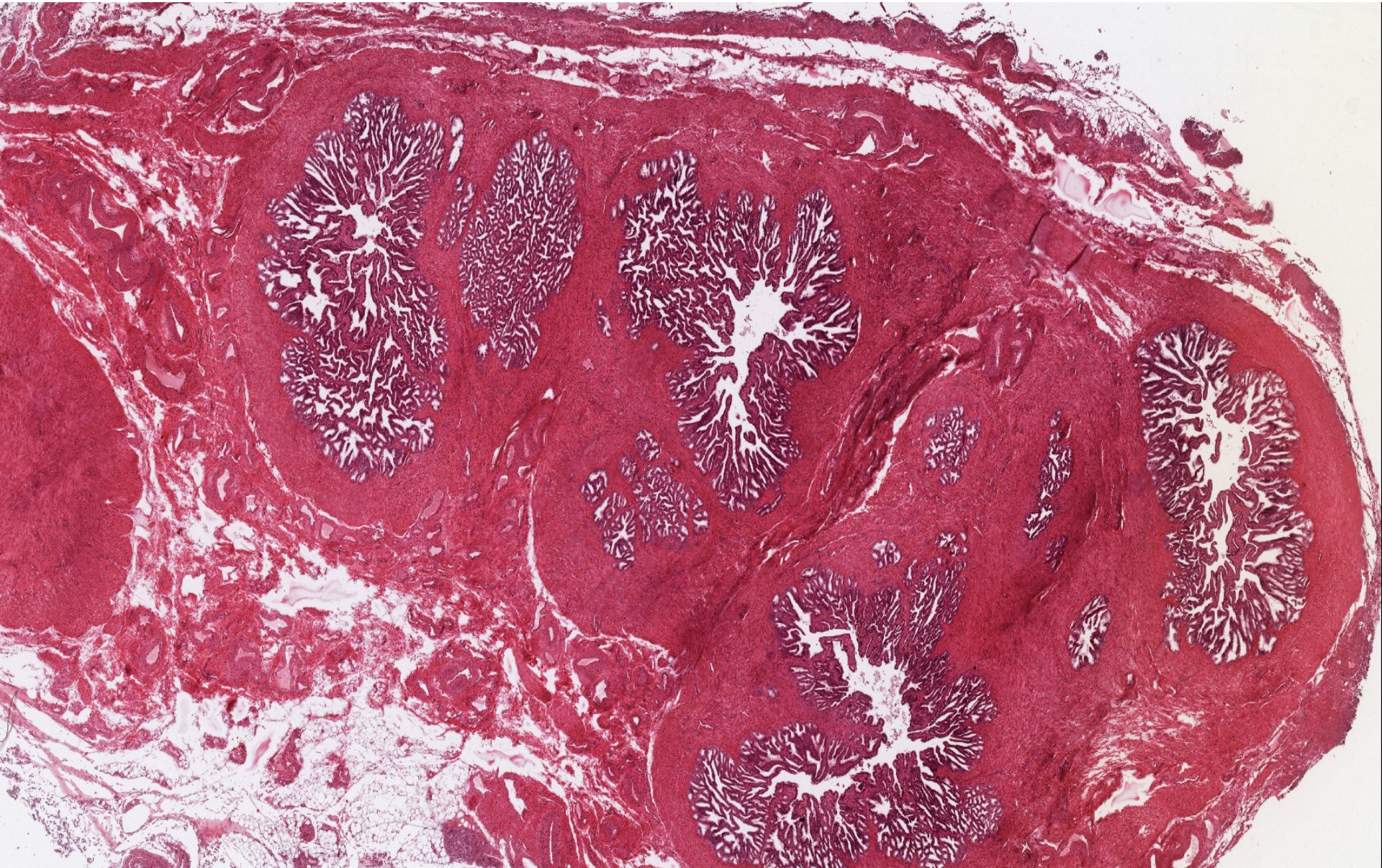
Funiculus spermaticus (HE)



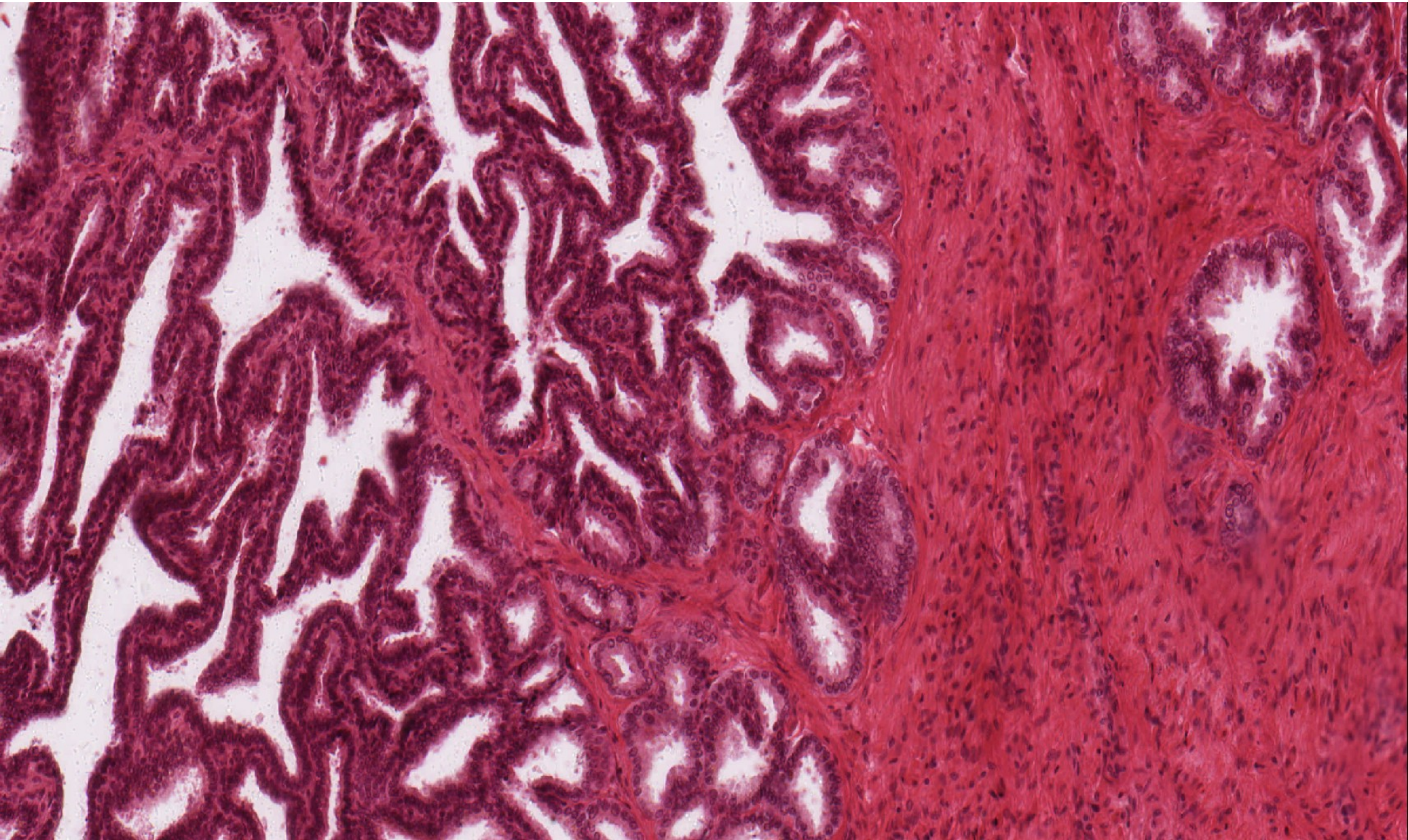
# Funiculus spermaticus (HE) – ductus deferens



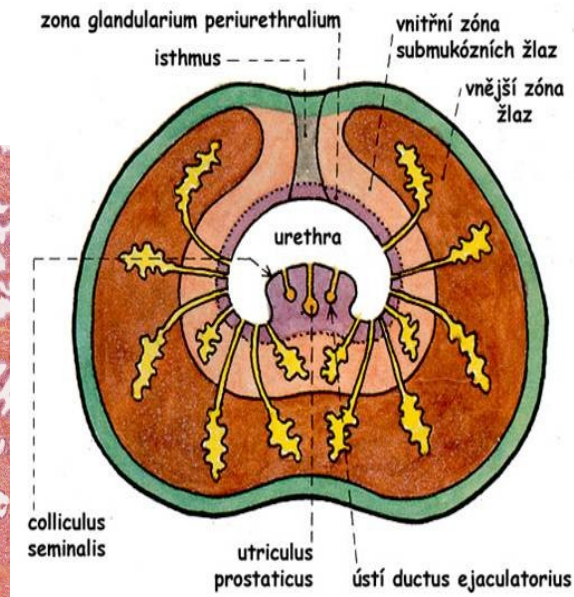
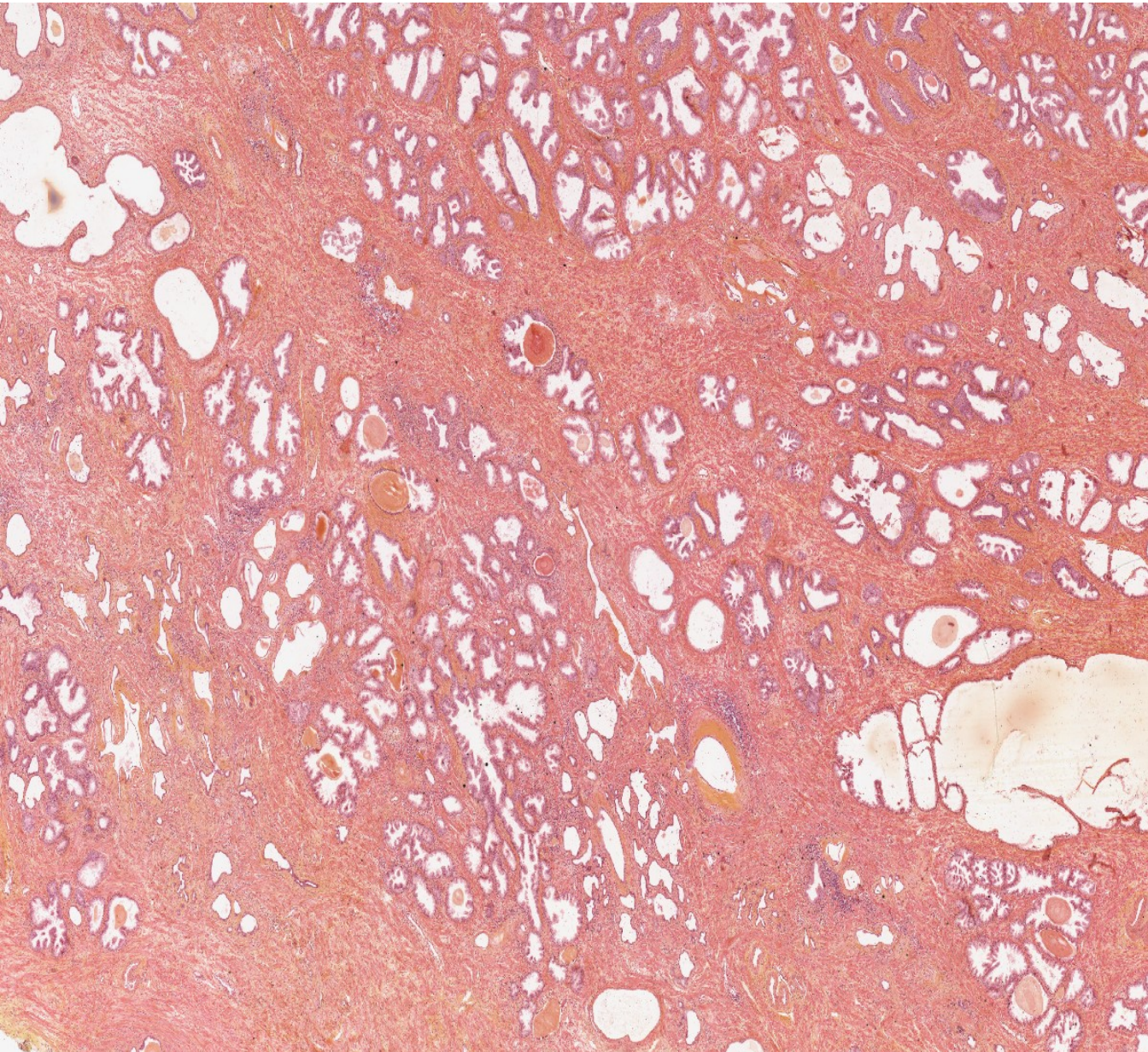
# Glandula vesiculosa (HE)



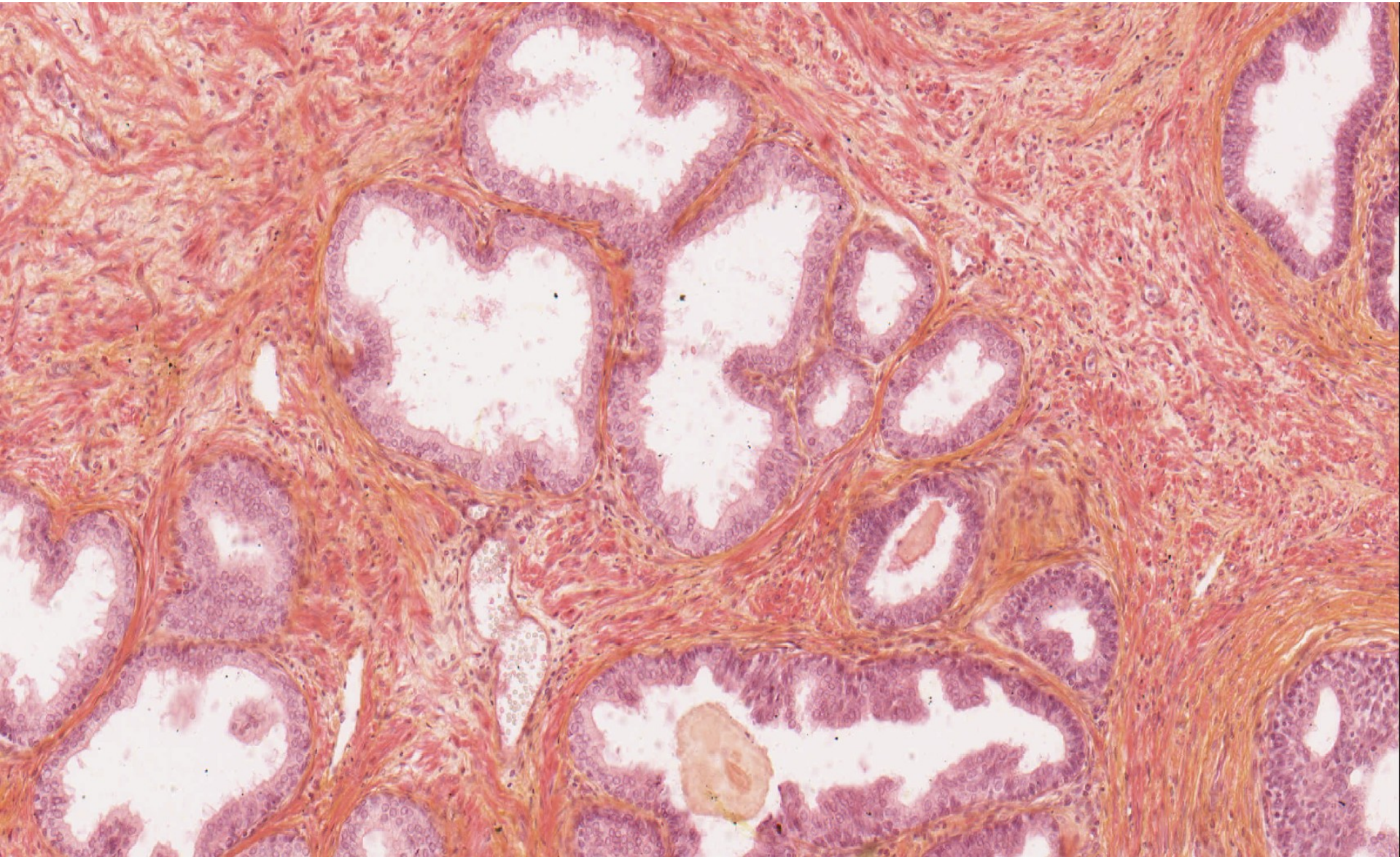
# Glandula vesiculosa (HE)

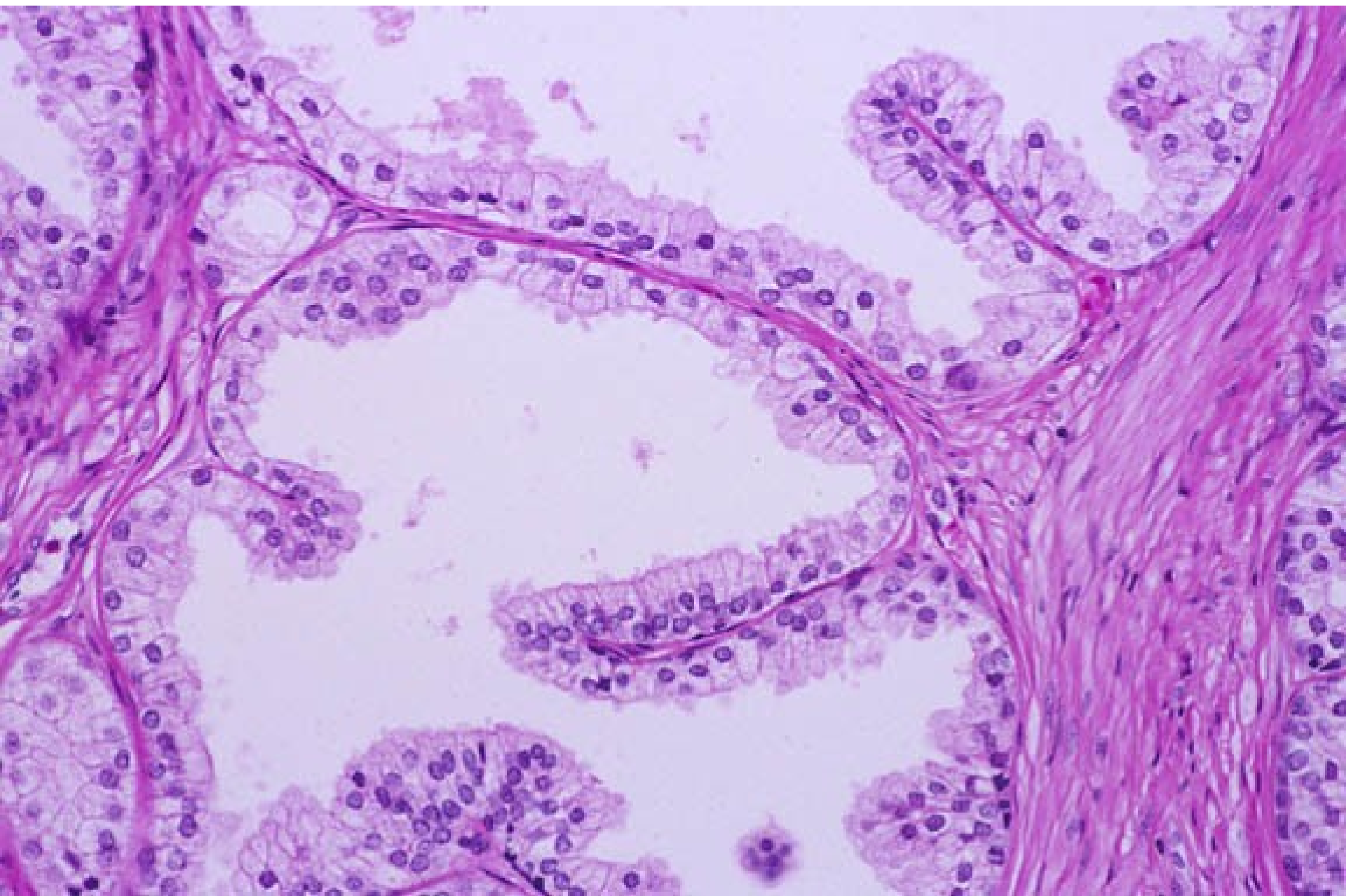


# Prostata (HEŠ)



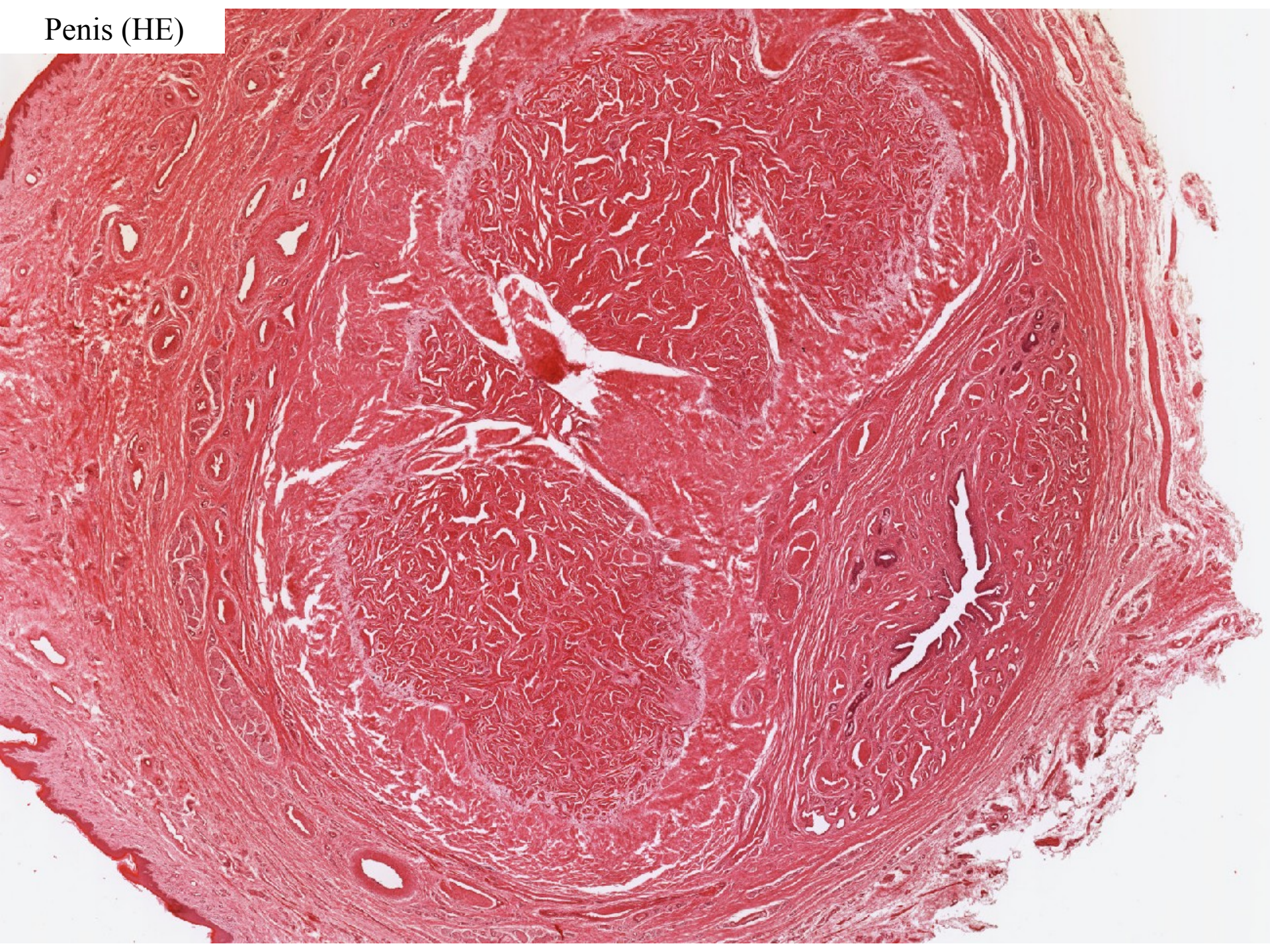
# Prostata (HEŠ)



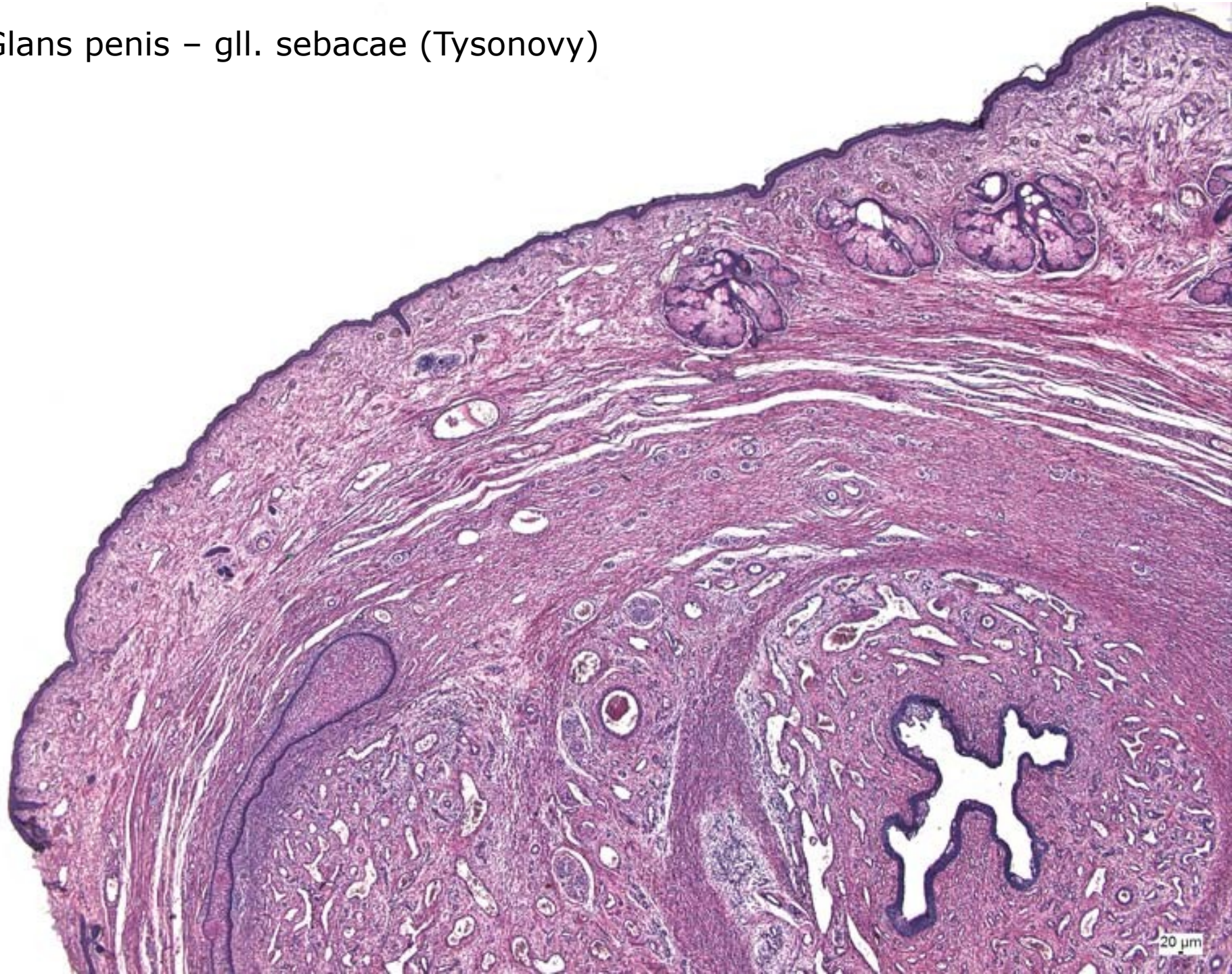



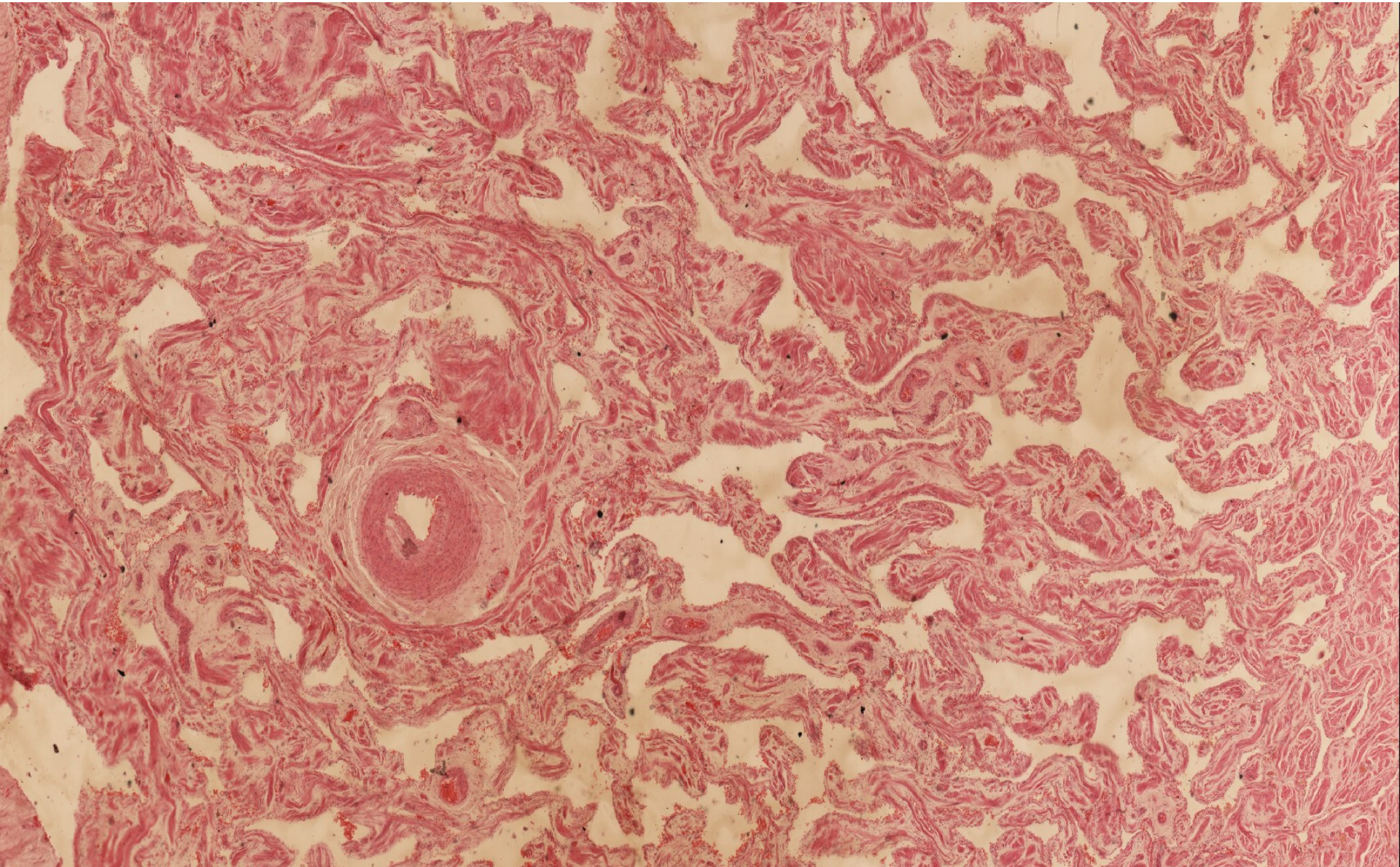
Penis (HE)



Glans penis – gll. sebaciae (Tysonovy)



## Penis – corpus cavernosum



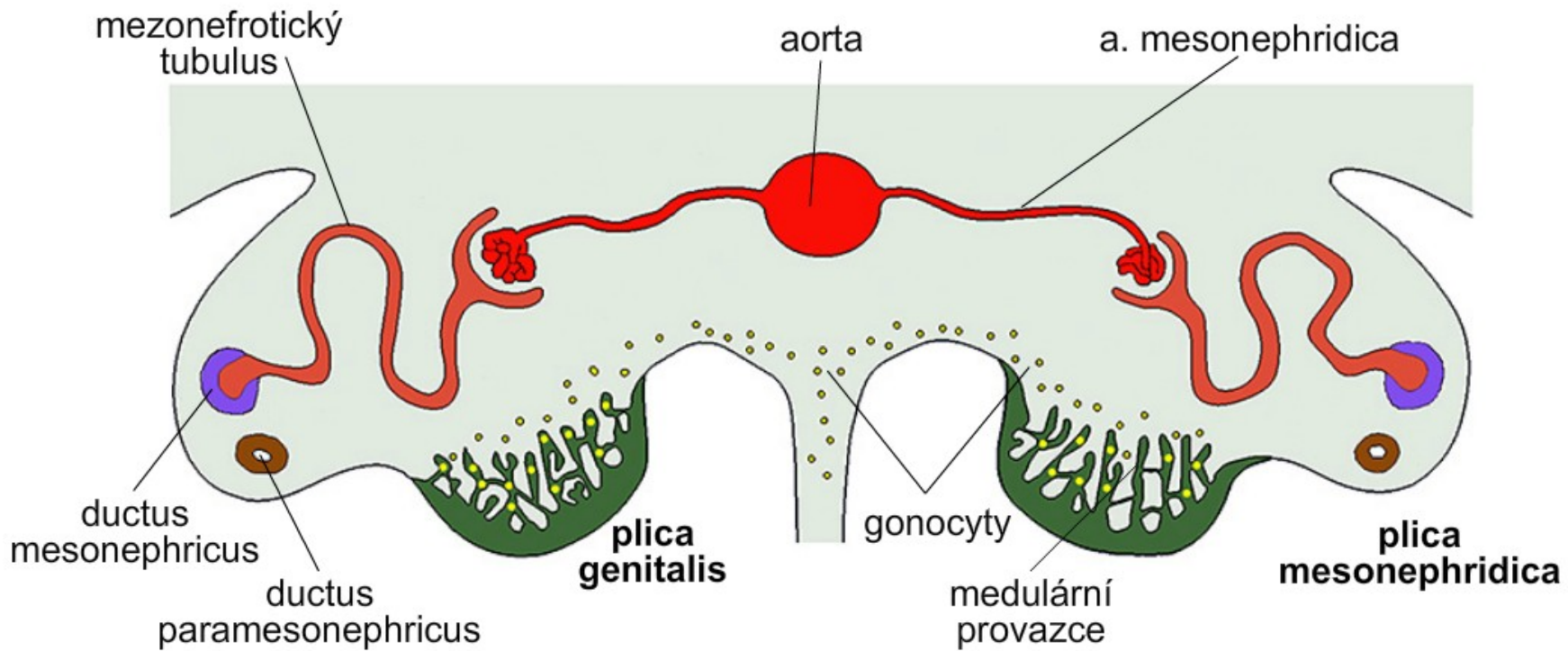
# Mužský pohlavní systém

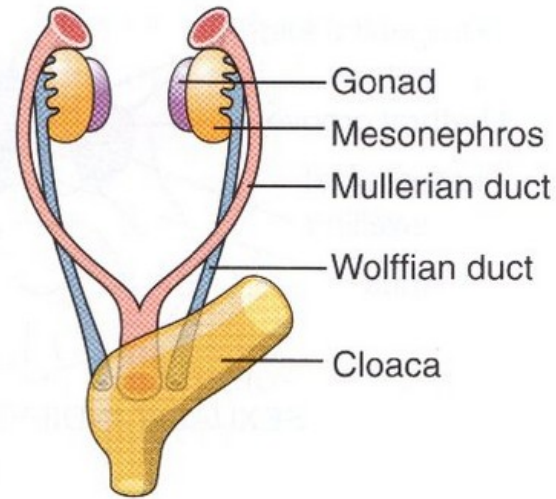
## Preparáty:

- 36. Testis (HE)
- 37. Epididymis (HE, HEŠ)
- 38. Funiculus spermaticus (HE)
- 39. Glandula vesiculosa (HE)
- 40. Prostata (HE)
- 41. Penis (HE)

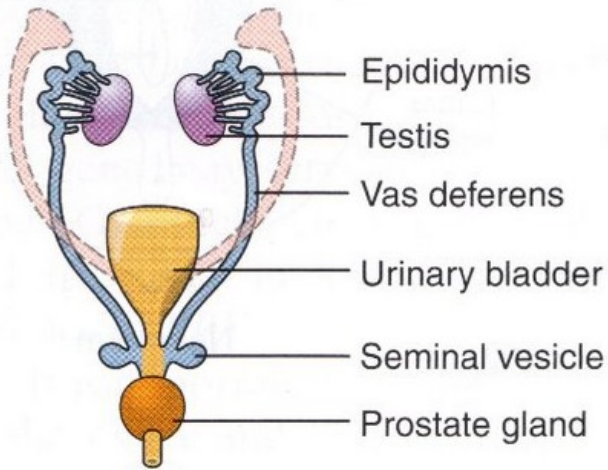
## Atlas EM:

- Lidská spermie (71)
- Vývoj gonád (95)
- Vývoj vývodních pohlavních cest a zevních genitálií (96)

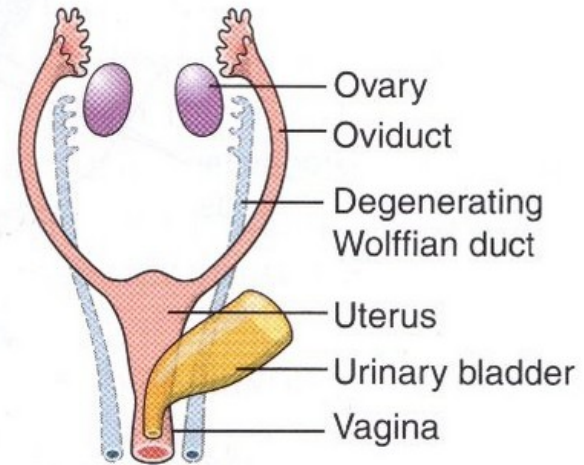




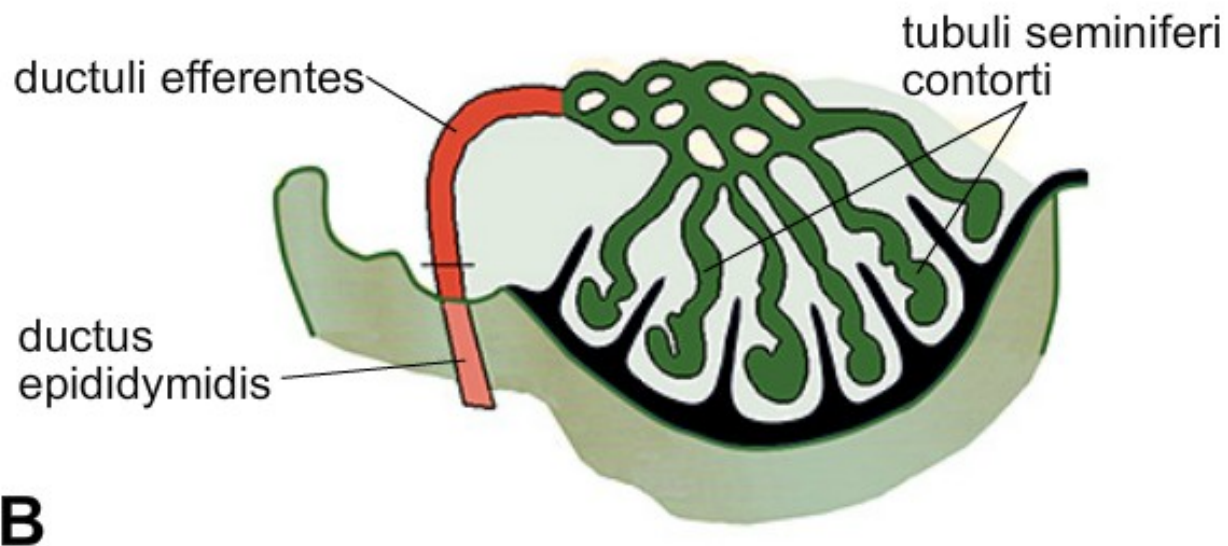
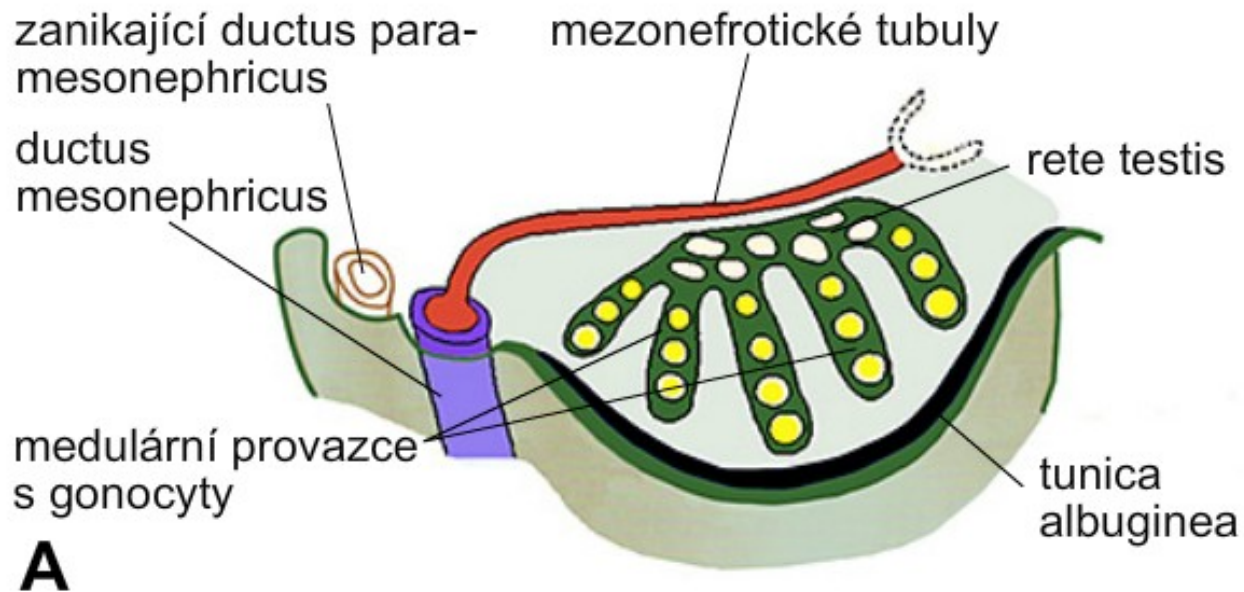
INDIFFERENT STAGE

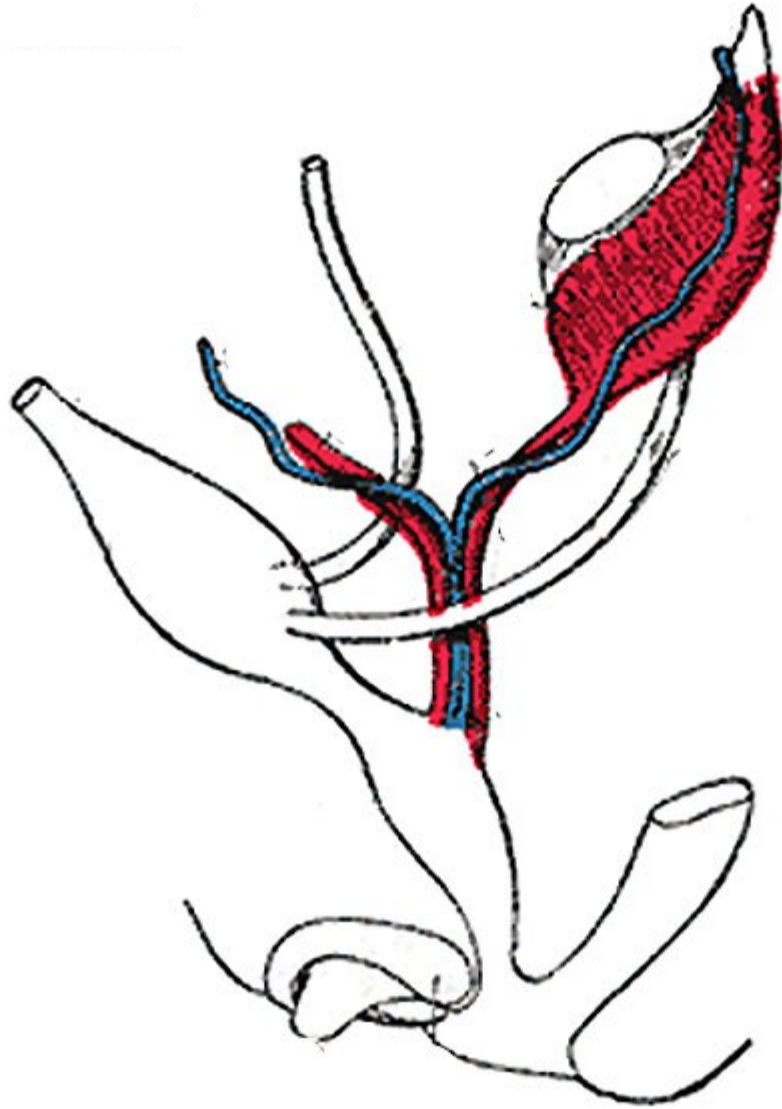


MALE



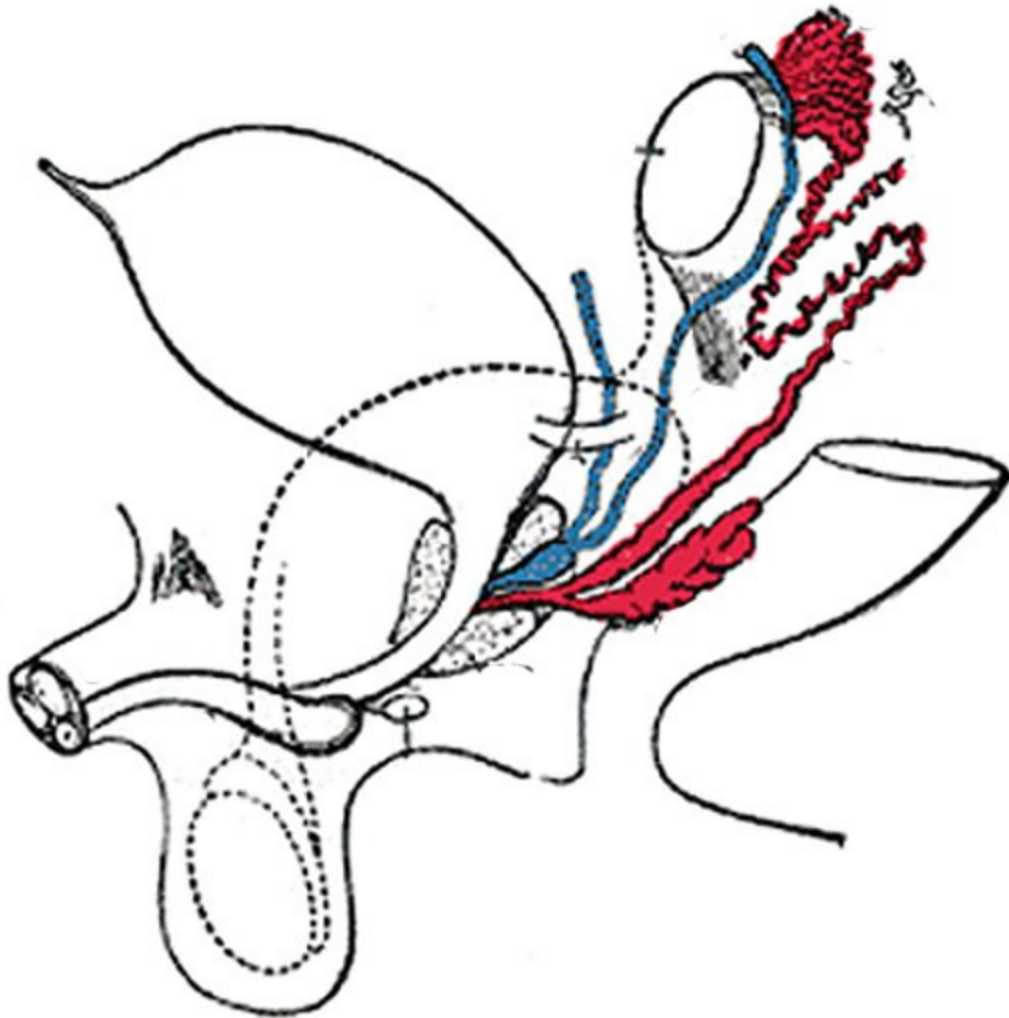
FEMALE





Gray, Henry. Anatomy of the Human Body. Philadelphia: Lea & Febiger, 1918.





Gray, Henry. Anatomy of the Human Body. Philadelphia: Lea & Febiger, 1918.