

Nervový systém

Cortex cerebri

Cerebellum (impregnace)

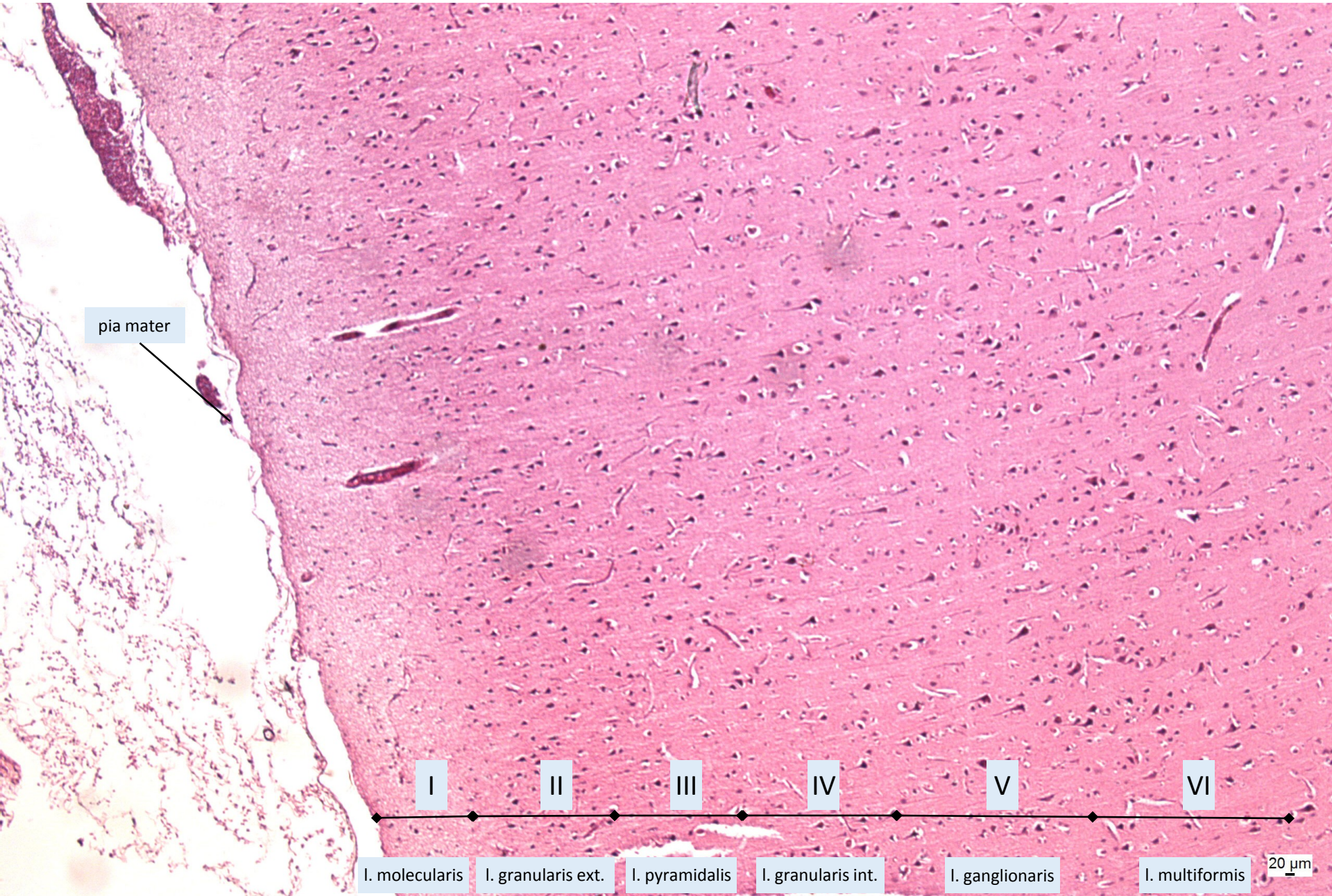
Medula spinalis

Plexus choroideus

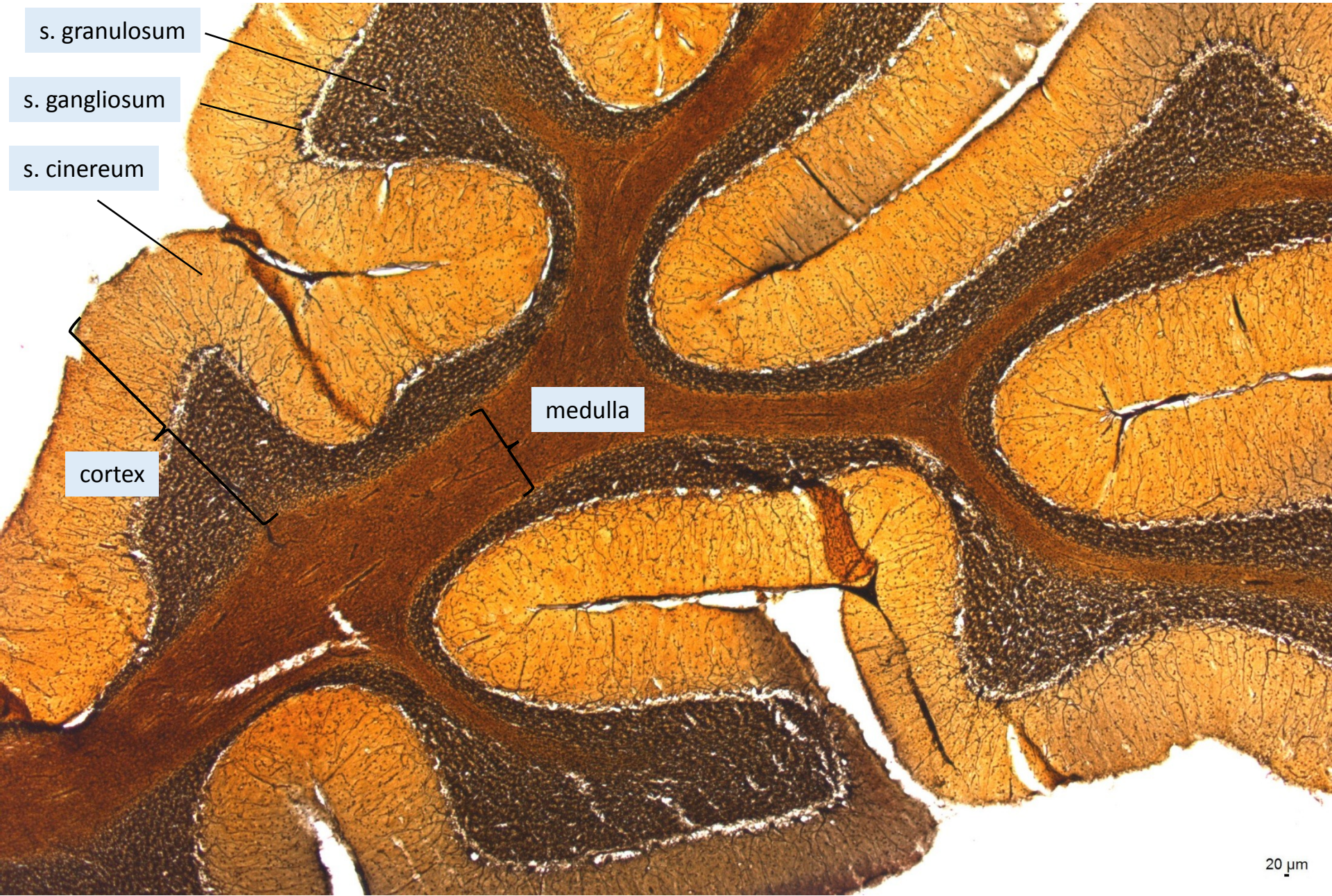
Autonomní ganglion

Periferní nerv

Cortex cerebri



Cerebellum



s. granulosum

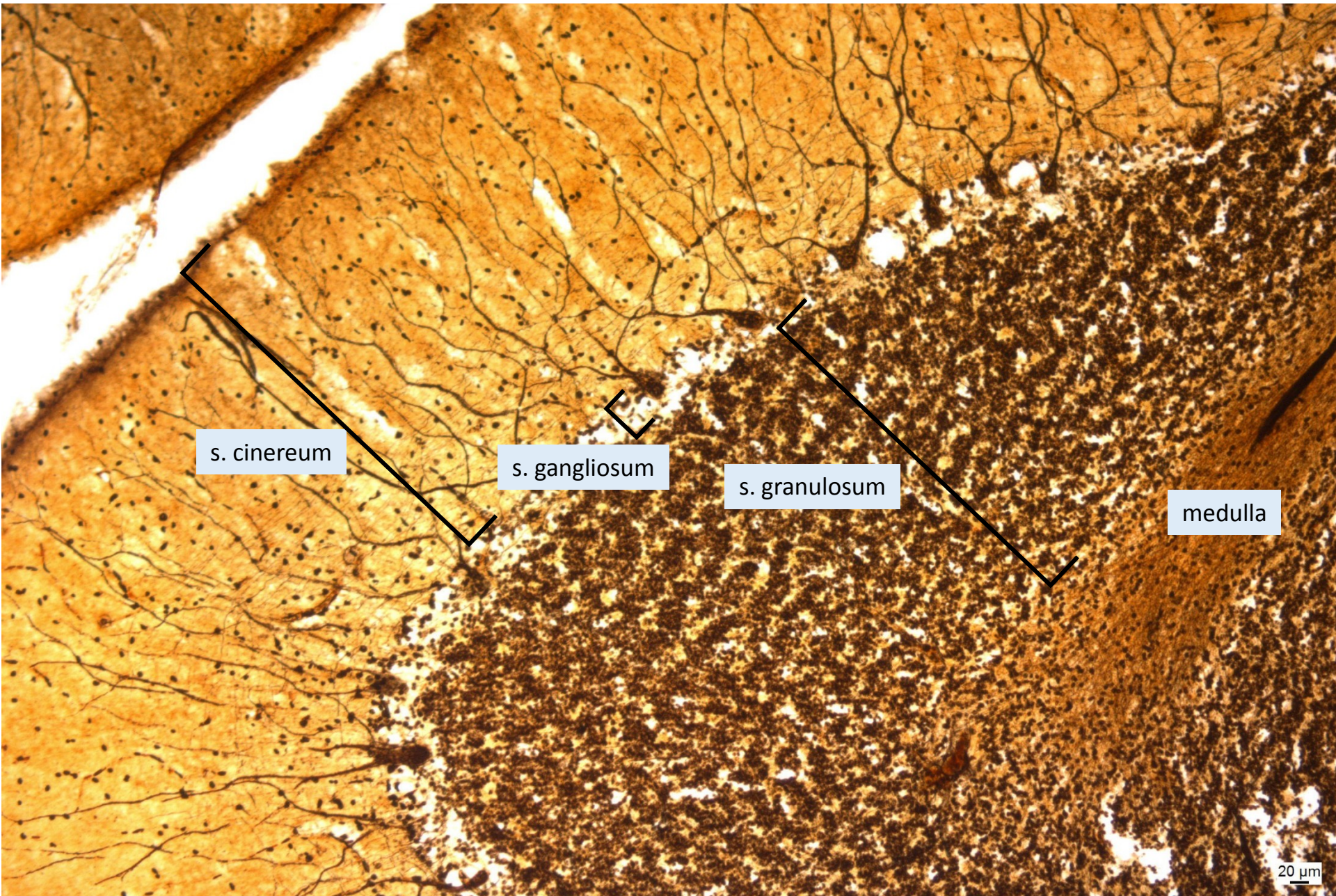
s. gangliosum

s. cinereum

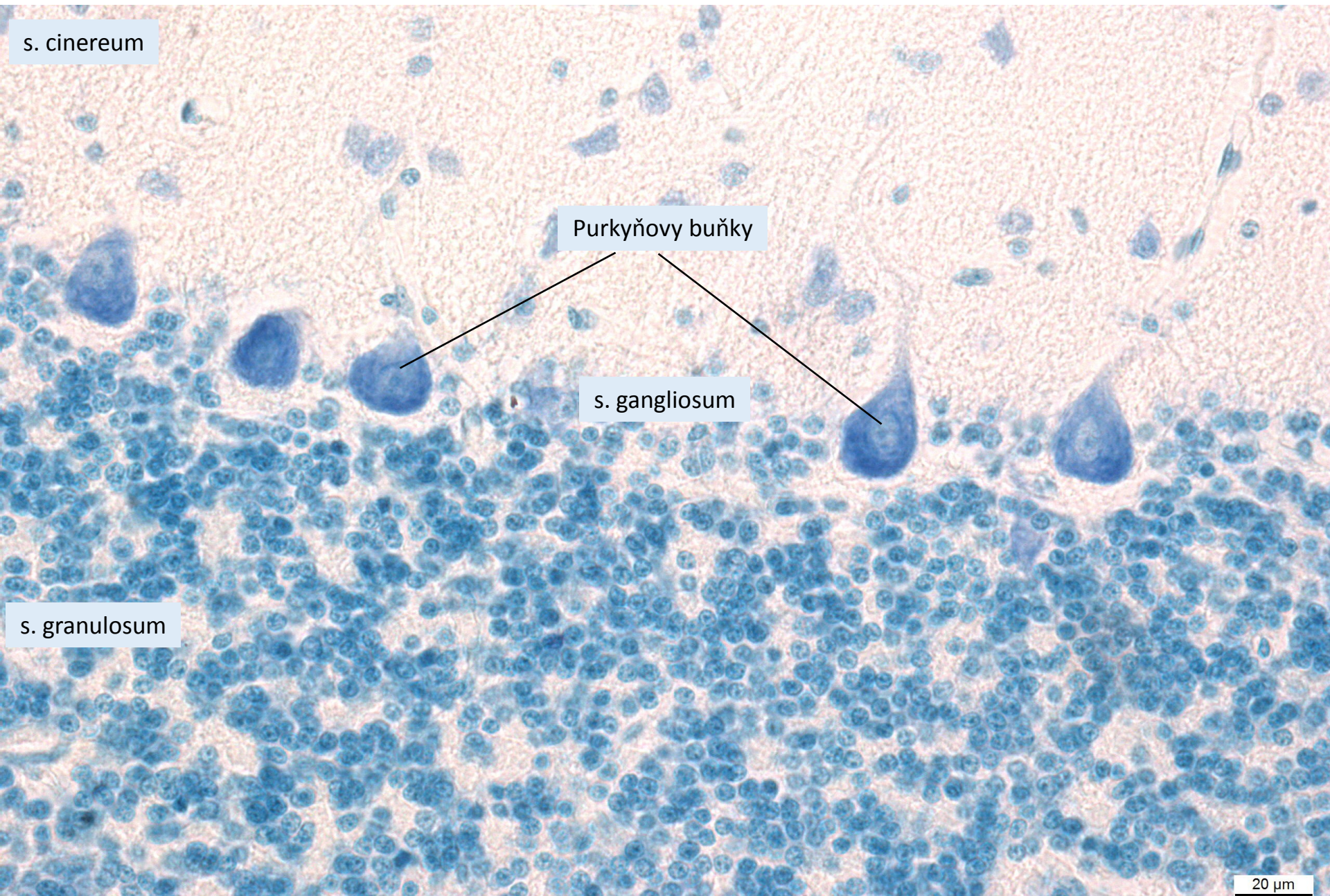
cortex

medulla

Cortex cerebelli



Cortex cerebelli – Purkyňovy buňky



s. cinereum

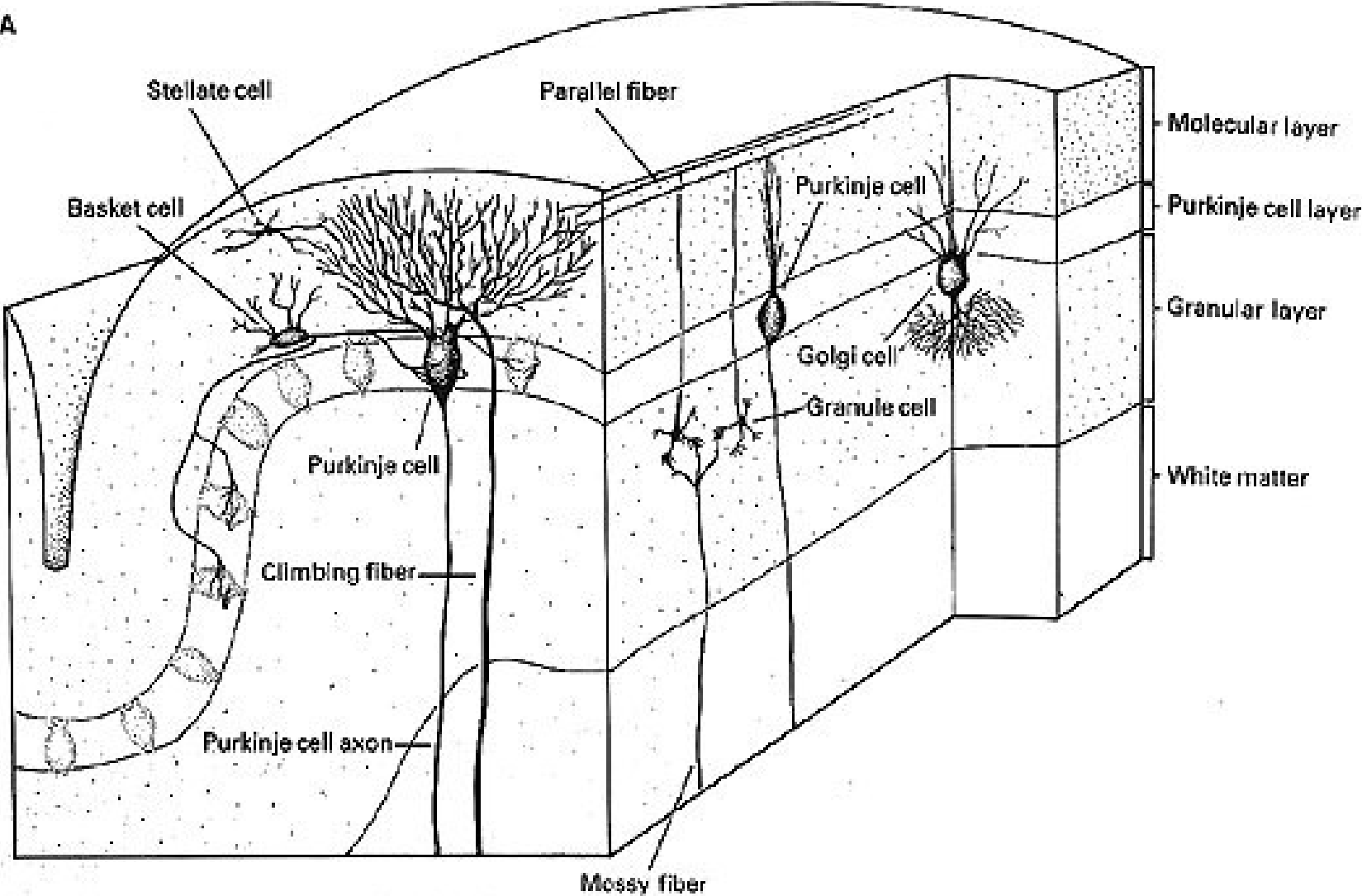
Purkyňovy buňky

s. gangliosum

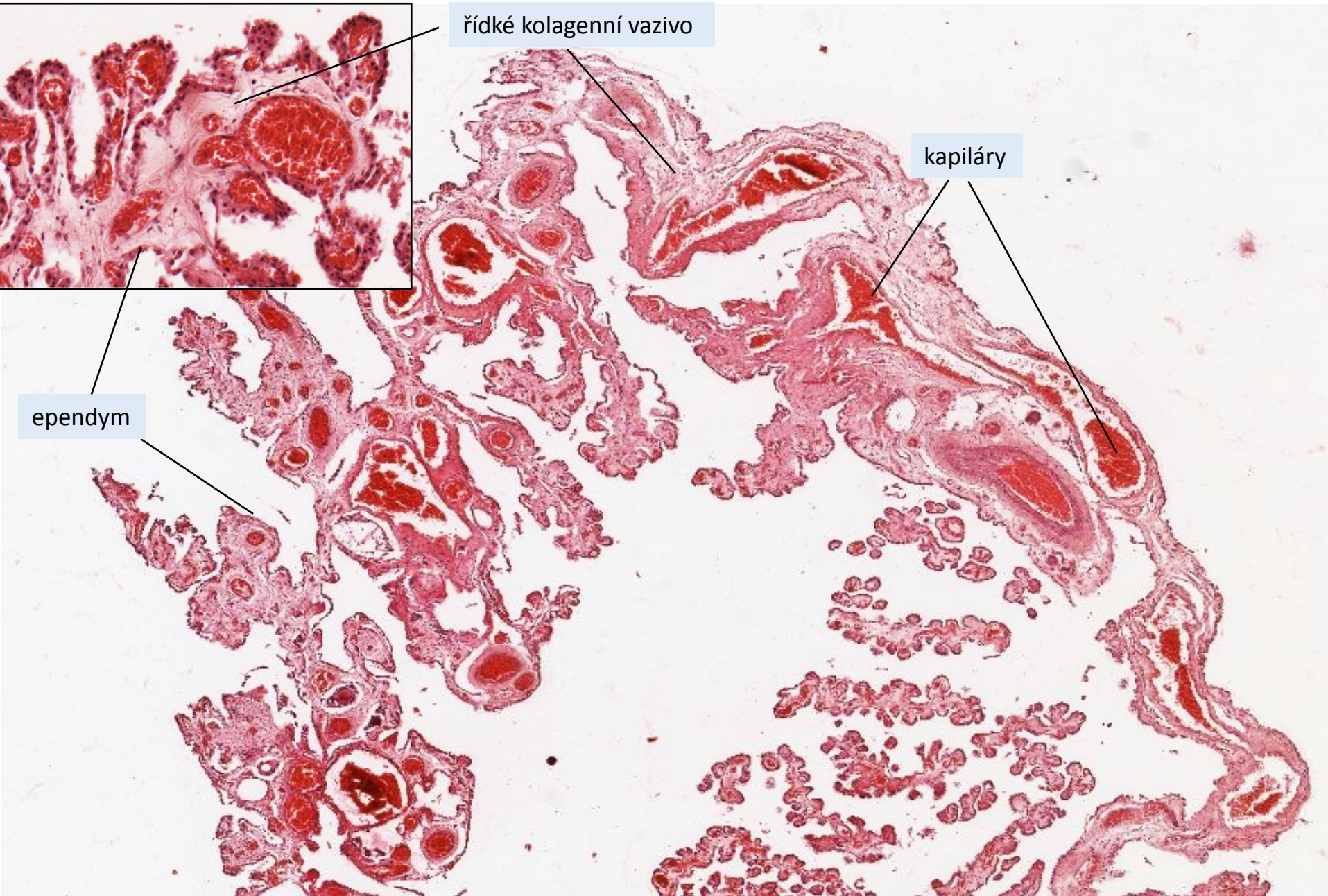
s. granulosum

Cerebellum – neuron synapses

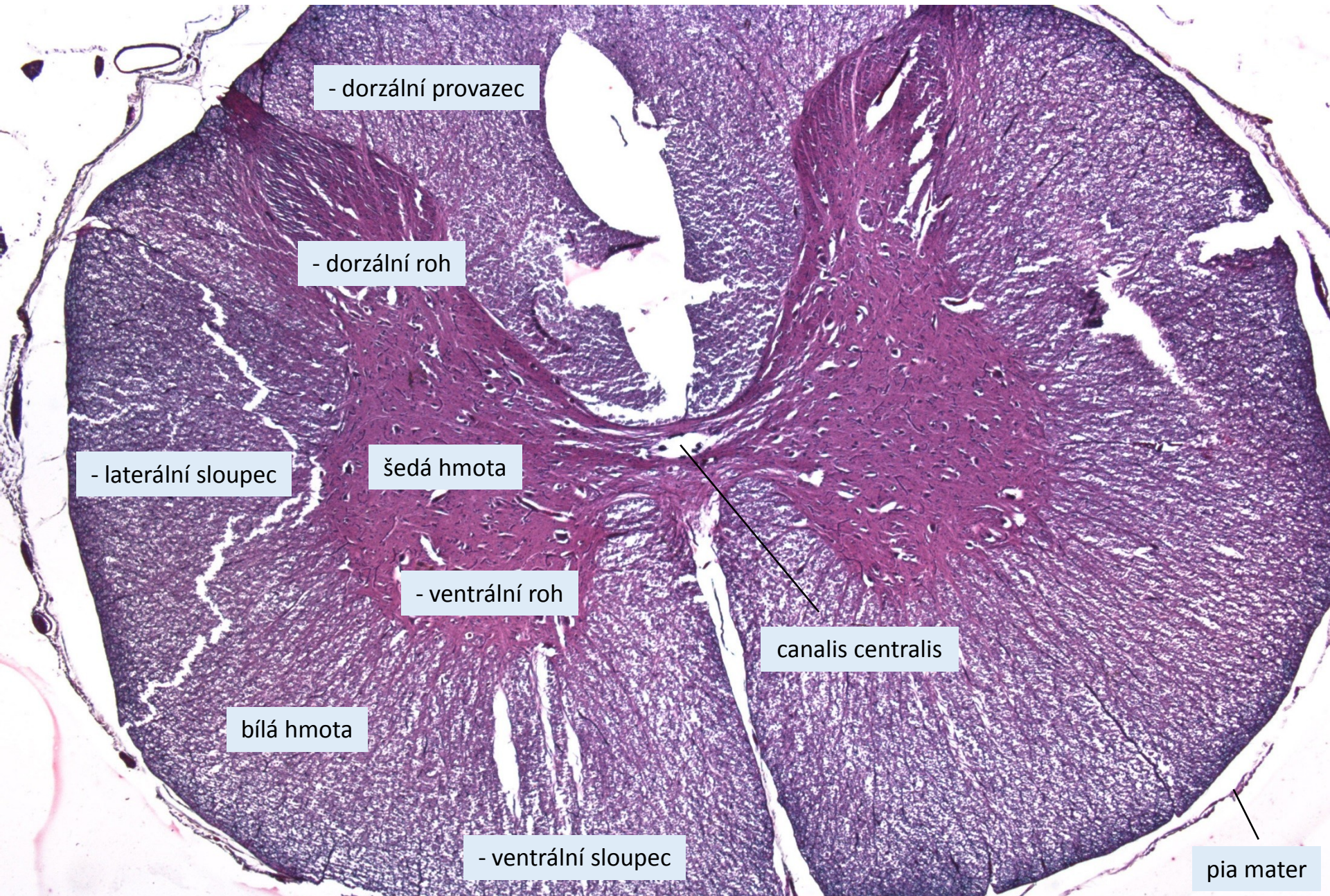
A



Choroidní plexus



Mícha



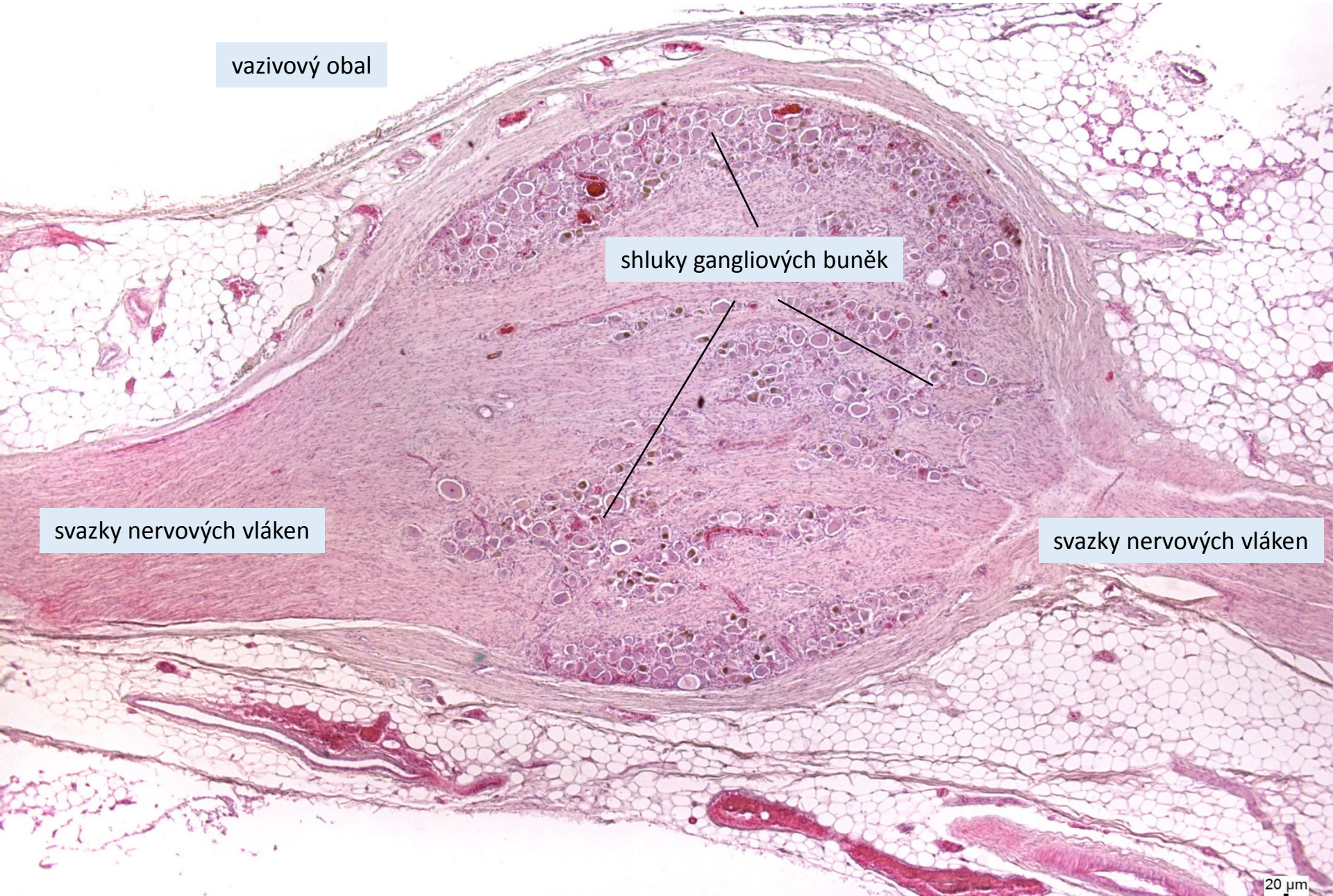
Spinální ganglion

vazivový obal

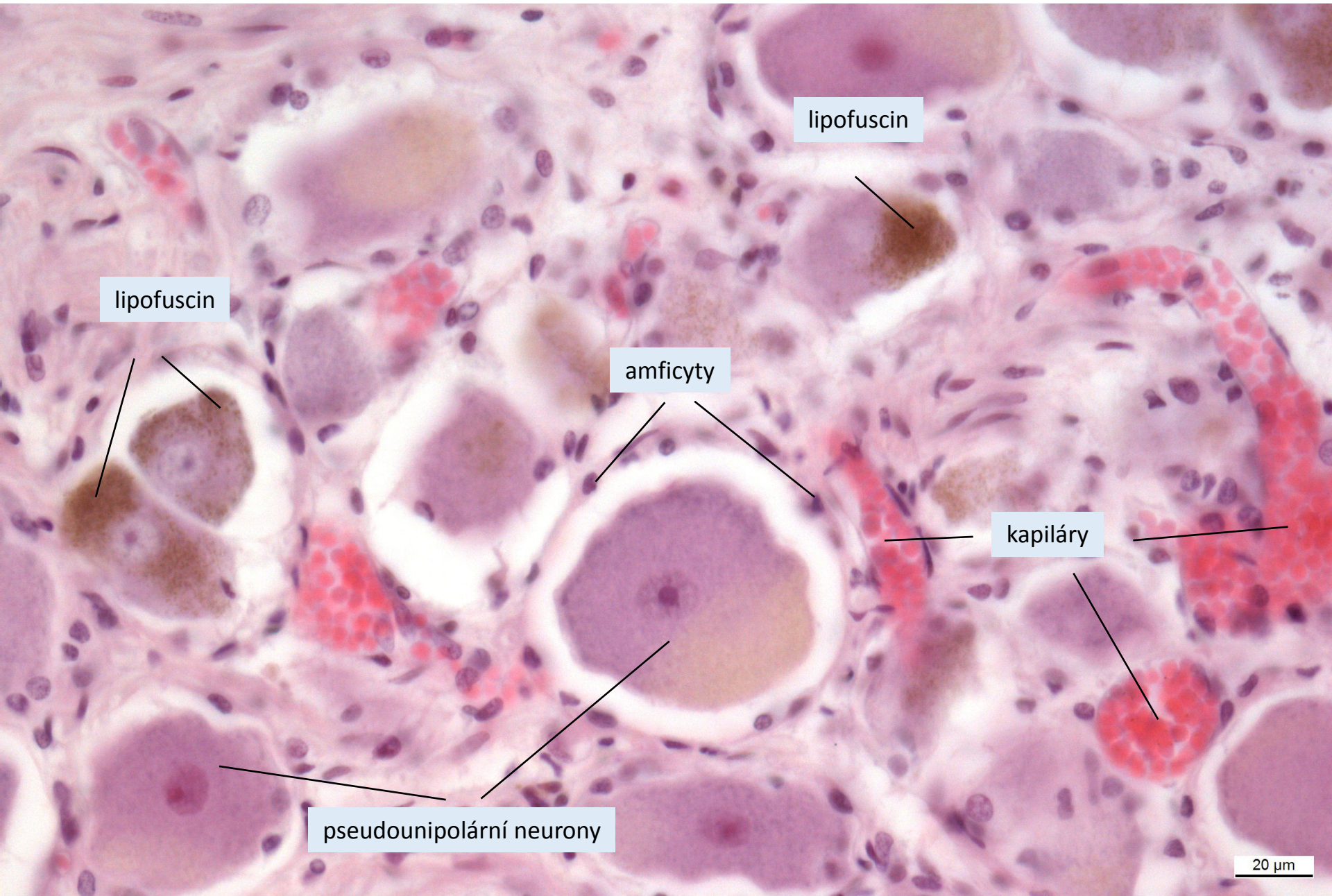
shluky gangliových buněk

svazky nervových vláken

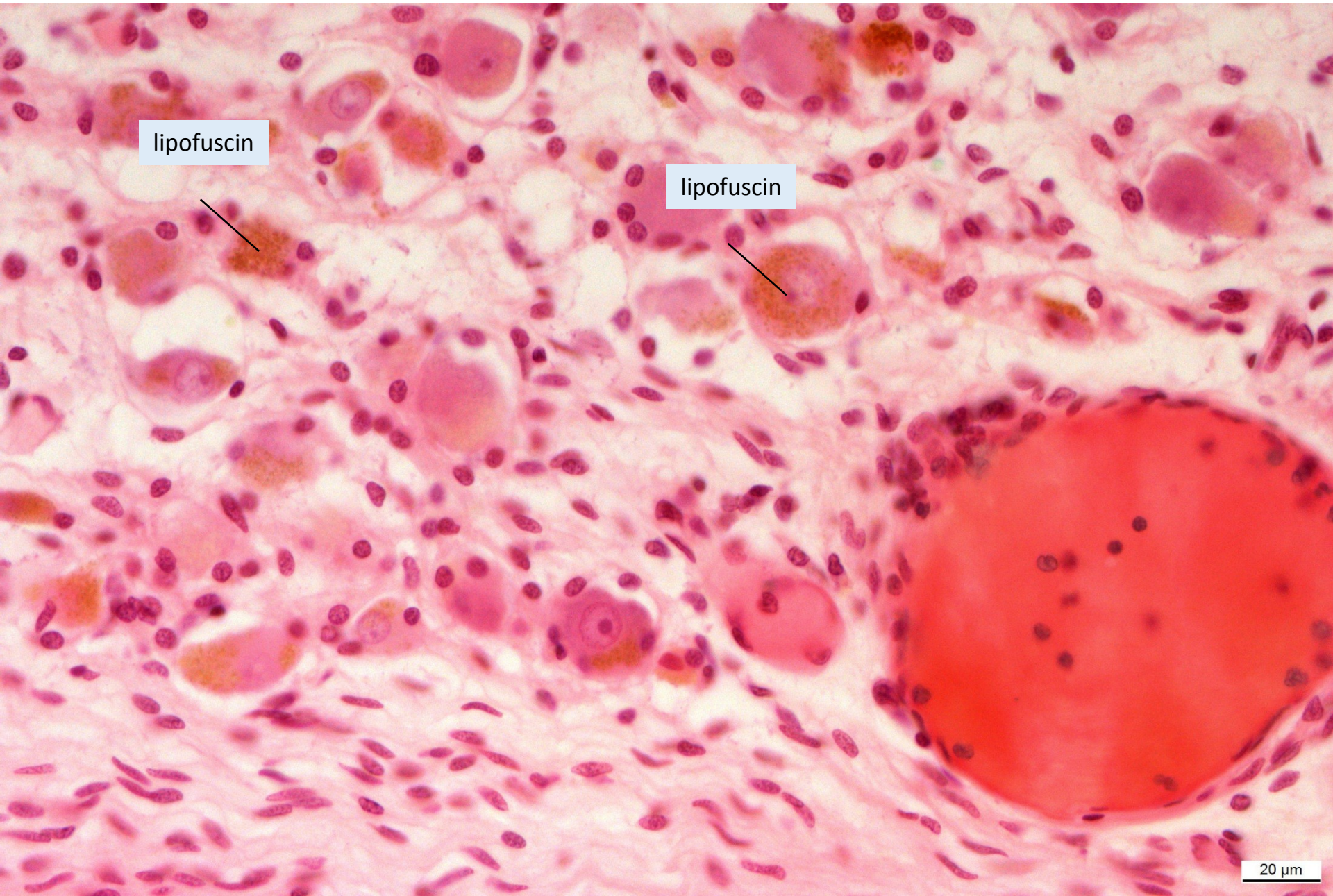
svazky nervových vláken



Spinální ganglion



Spinální ganglion - lipofuscin

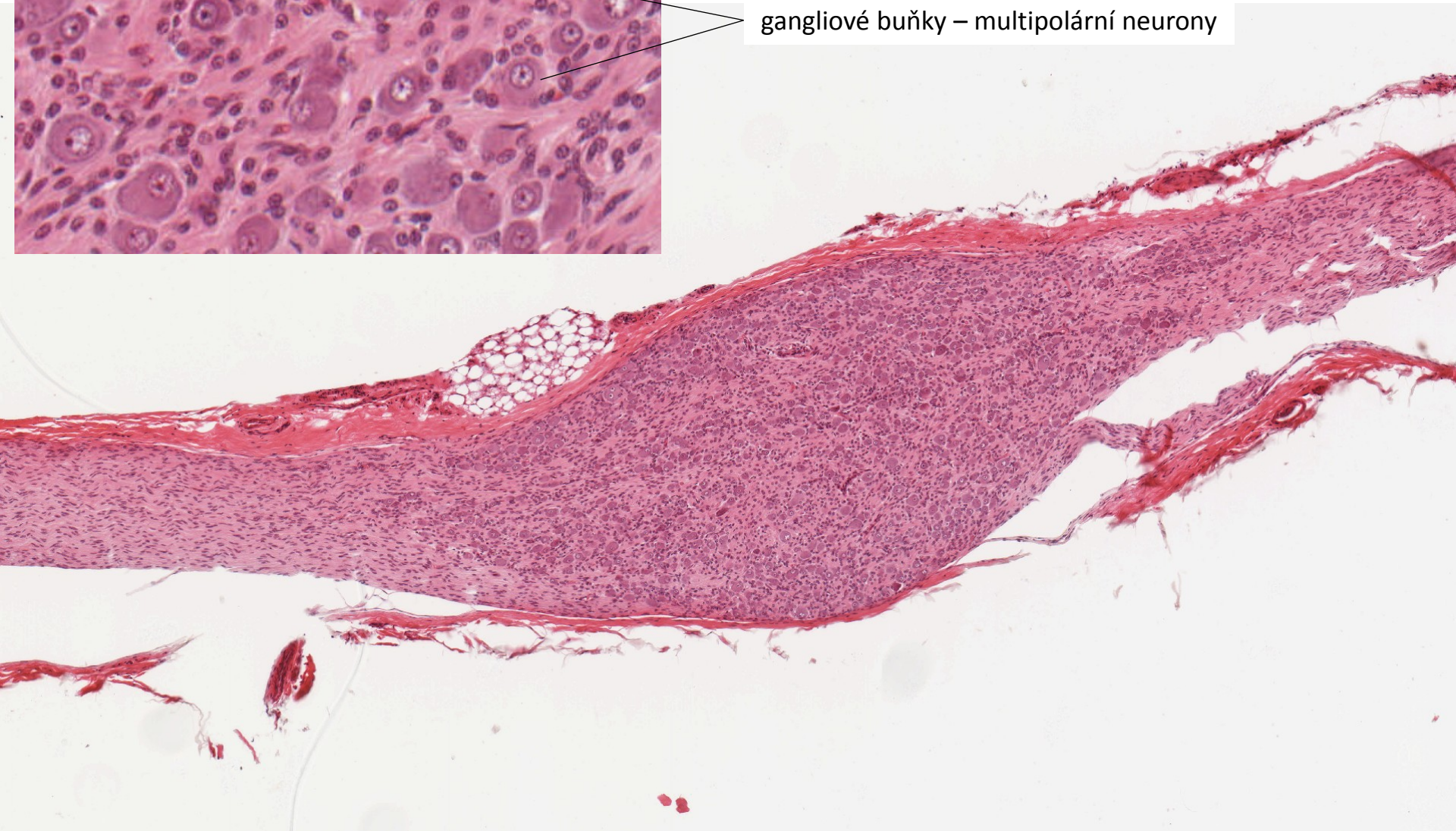
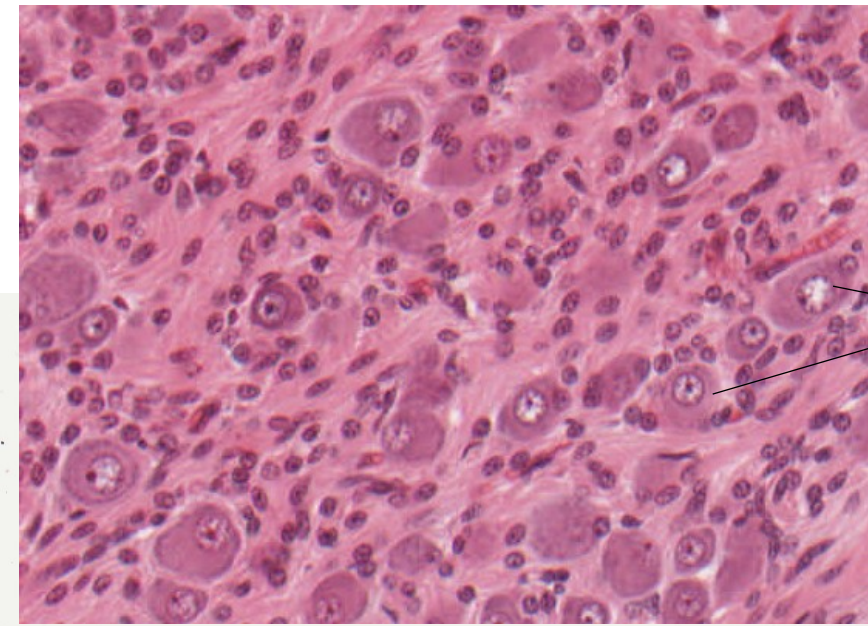


lipofuscin

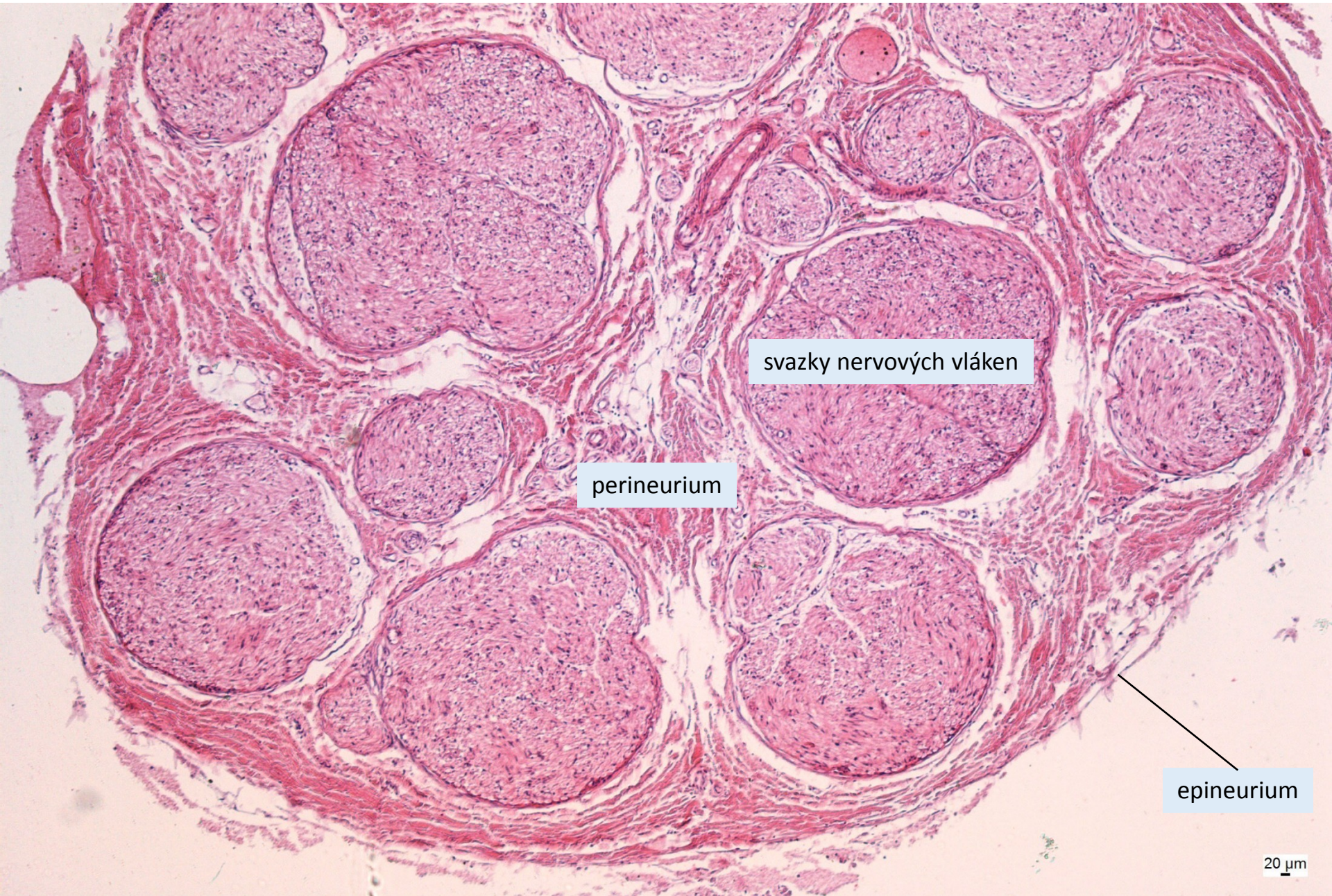
lipofuscin

Autonomní ganglion

gangliové buňky – multipolární neurony



Periferní nerv



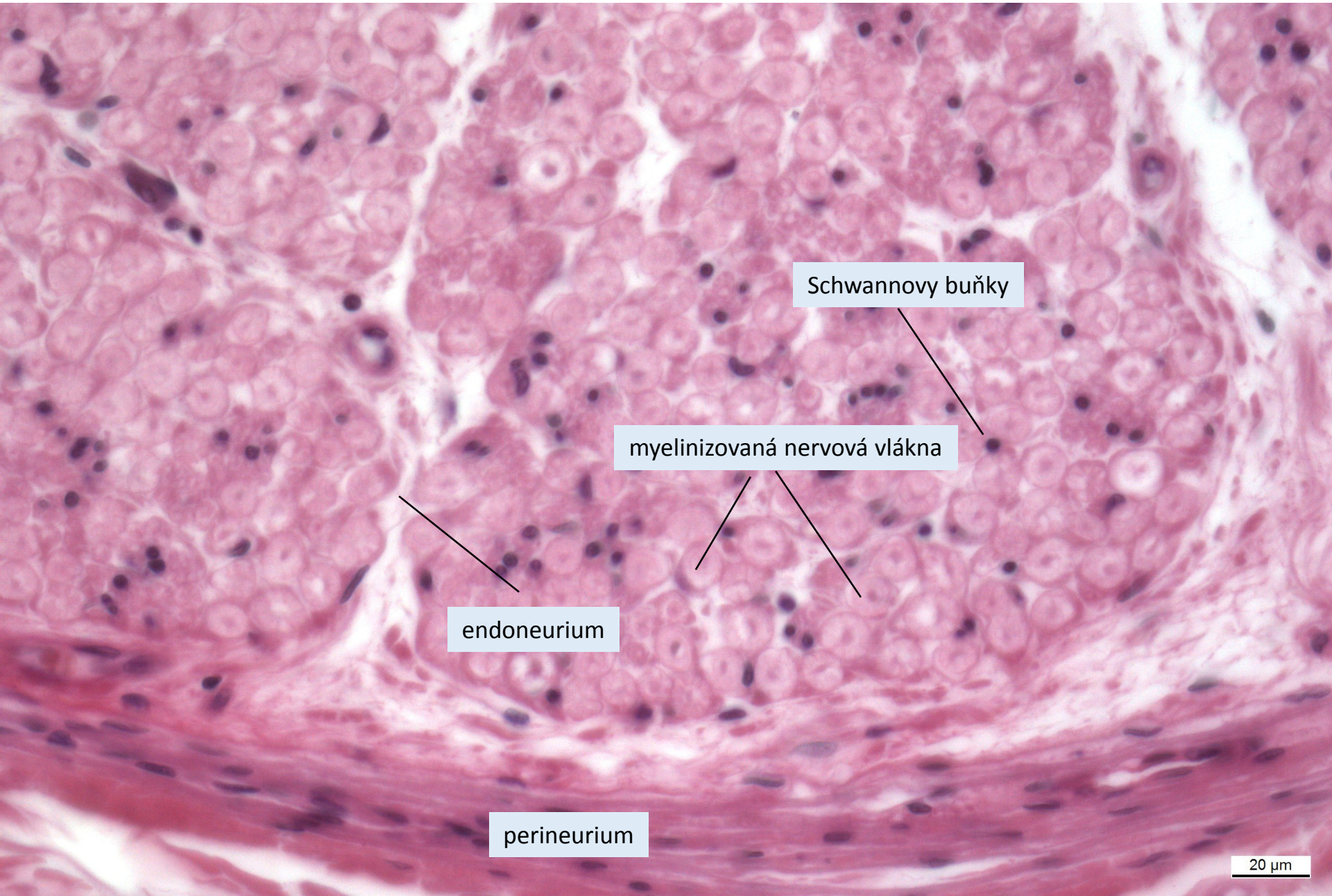
svazky nervových vláken

perineurium

epineurium

20 μ m

Periferní nerv



Schwannovy buňky

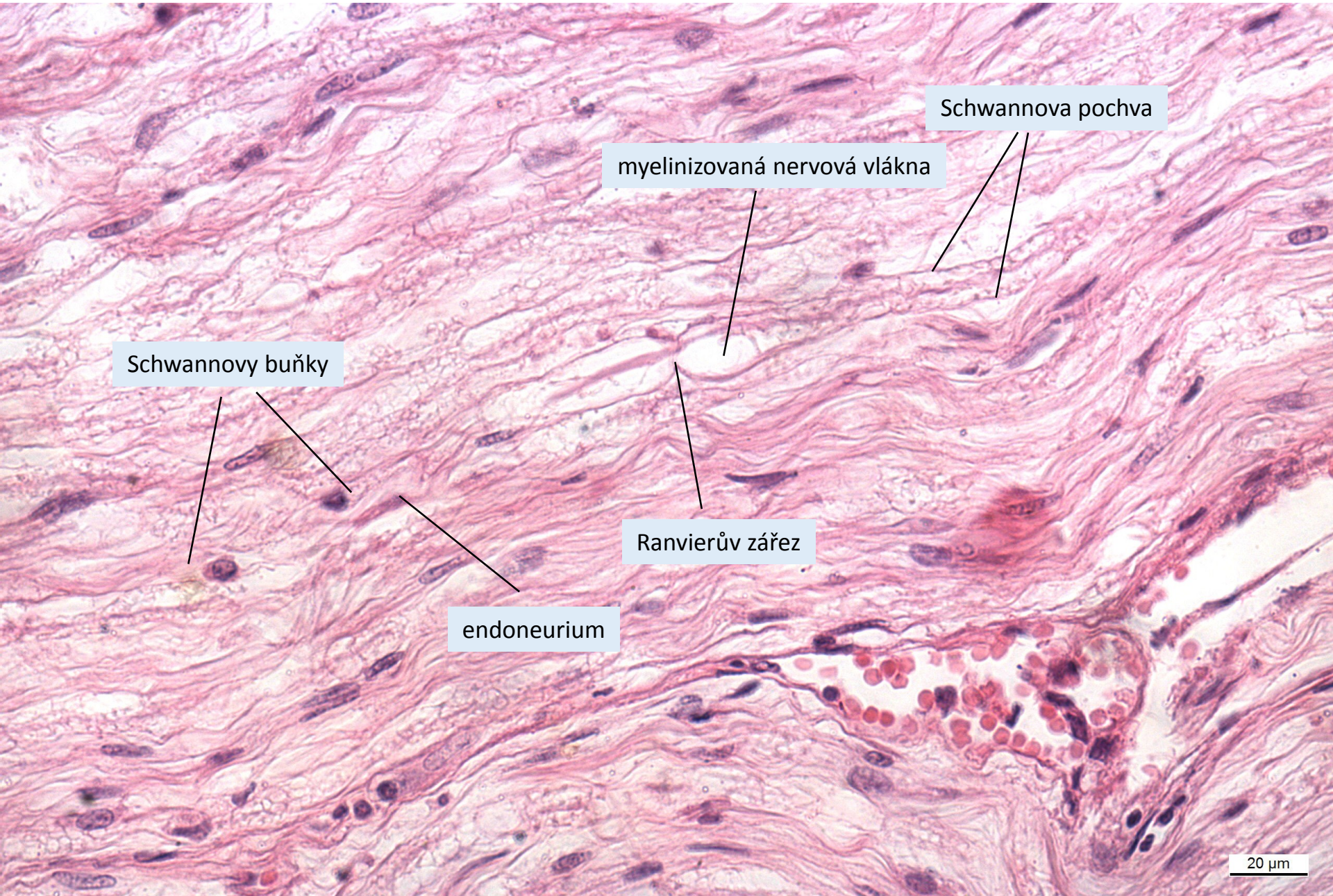
myelinizovaná nervová vlákna

endoneurium

perineurium

20 μ m

Periferní nerv



Schwannova pochva

myelinizovaná nervová vlákna

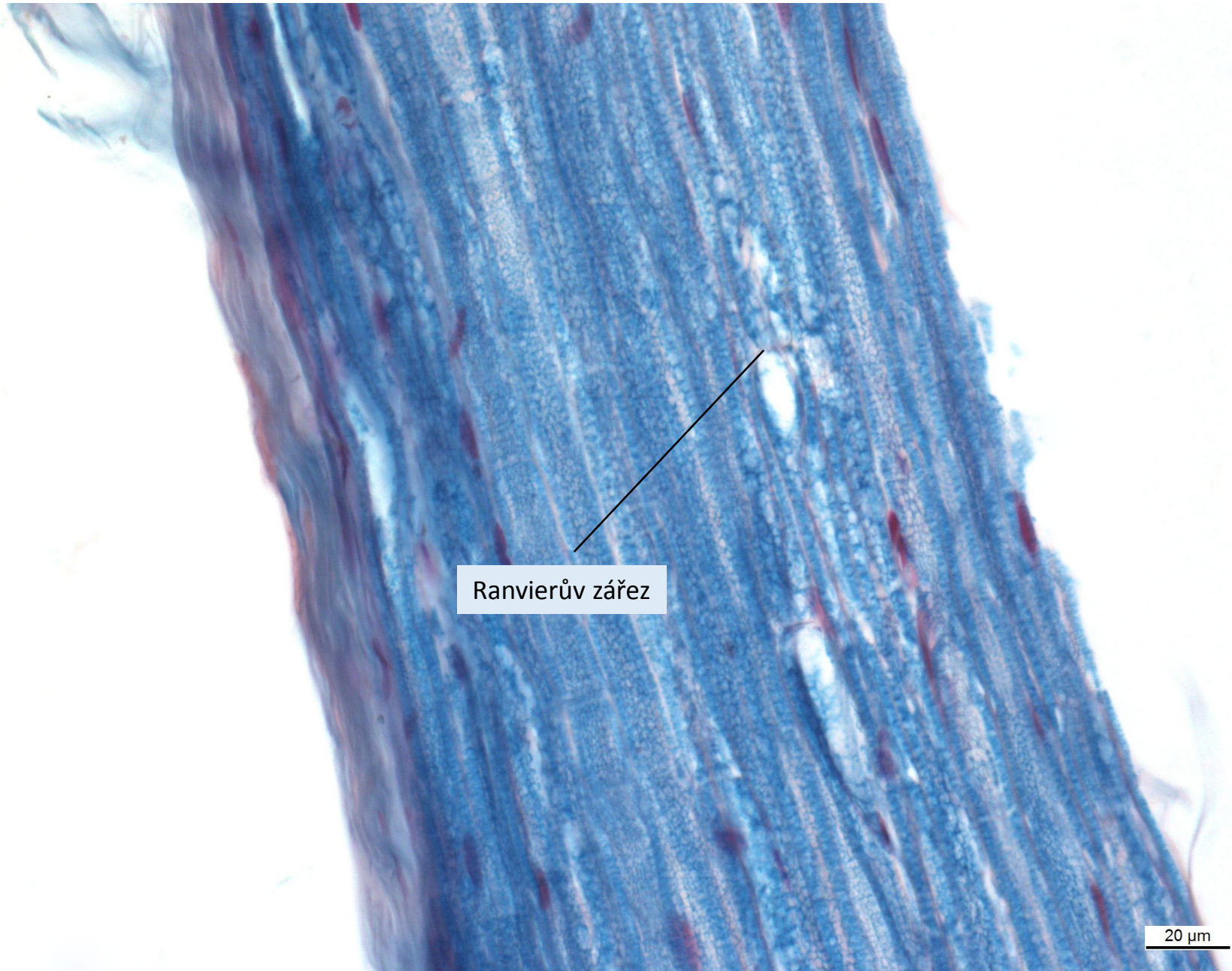
Schwannovy buňky

Ranvierův zářez

endoneurium

20 μ m

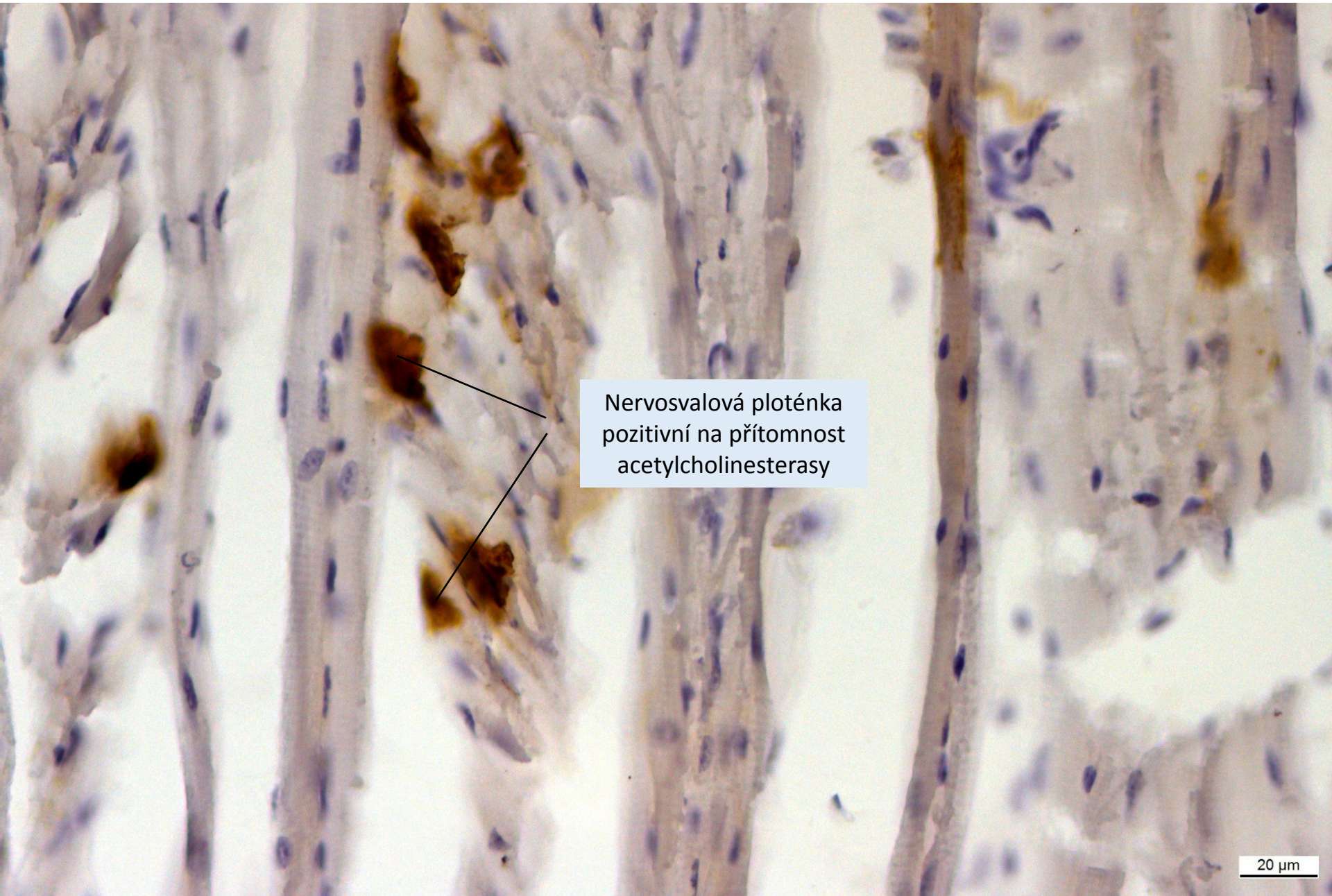
Periferní nerv



Ranvierův zářez

20 μm

Nervosvalová ploténka

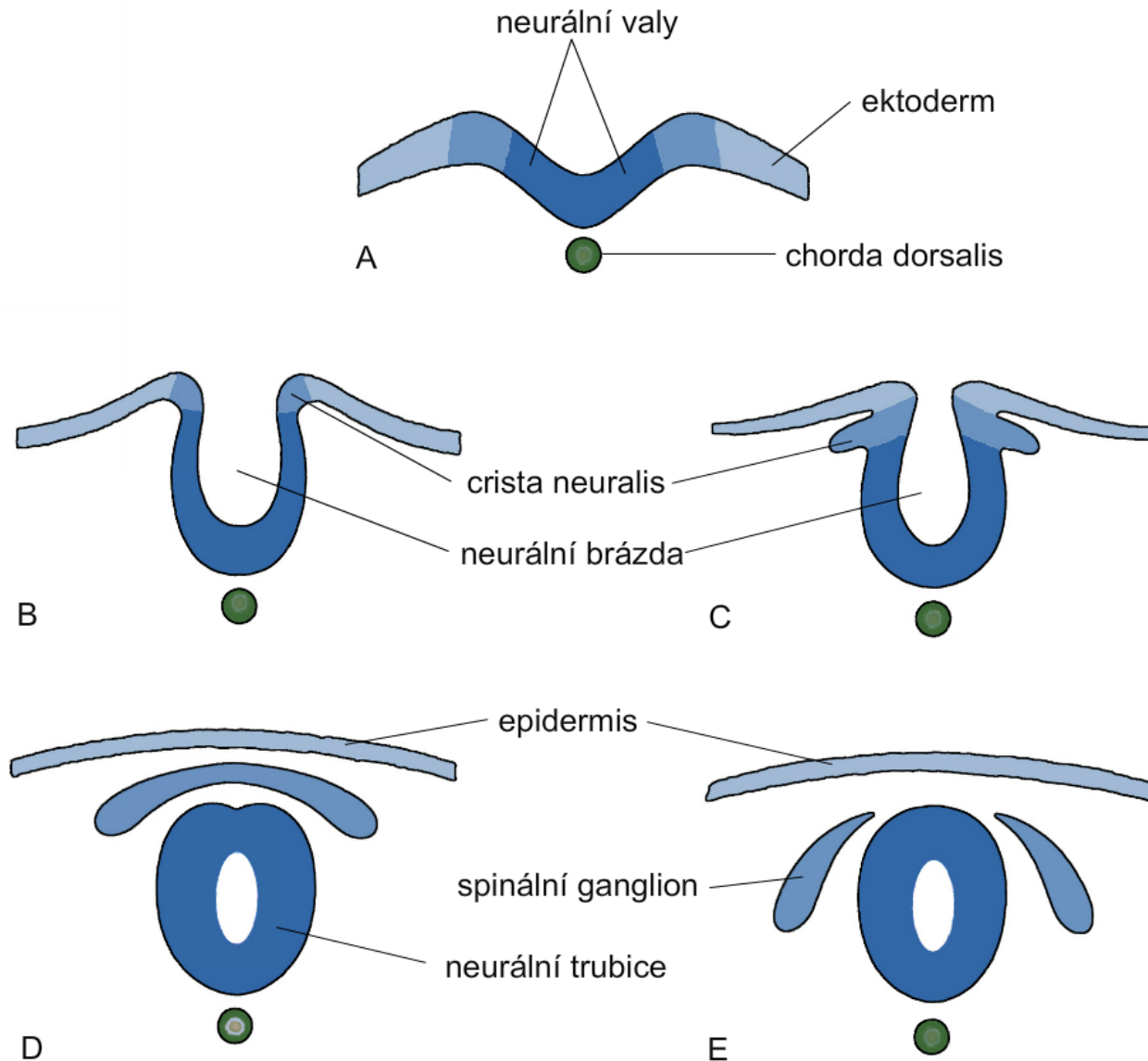


Nervosvalová ploténka
pozitivní na přítomnost
acetylcholinesterasy

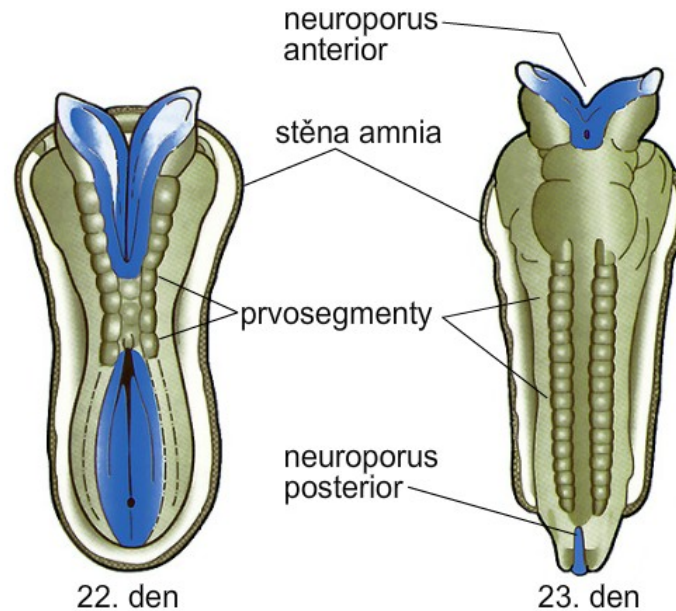
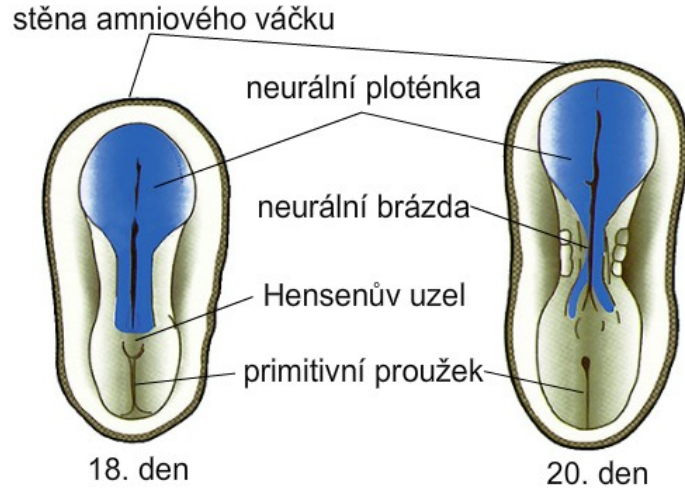
Seznam preparátů

- **75.** Cortex cerebri
- 76. Cortex cerebri (impregnace)
- **77.** Cerebellum (impregnace)
- 78. Cerebellum (Nisslova substance)
- **79.** Medulla spinalis
- 80. Plexus choroideus
- **81.** Ganglion spinale
- 82. Ganglion spinale (impregnace)
- **83.** Autonomní ganglion
- **84.** Periferní nerv – příčný řez
- 85. Periferní nerv – příčný řez (myelin)
- **86.** Periferní nerv – podélný řez
- 87. Periferní nerv – podélný řez (myelin)

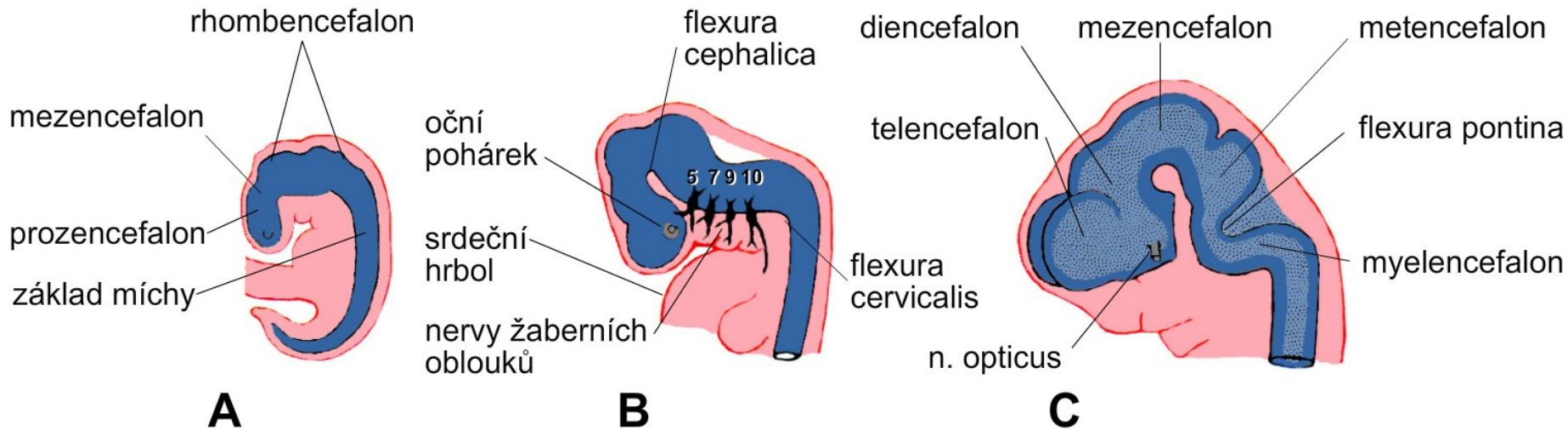
Vývoj nervové trubice



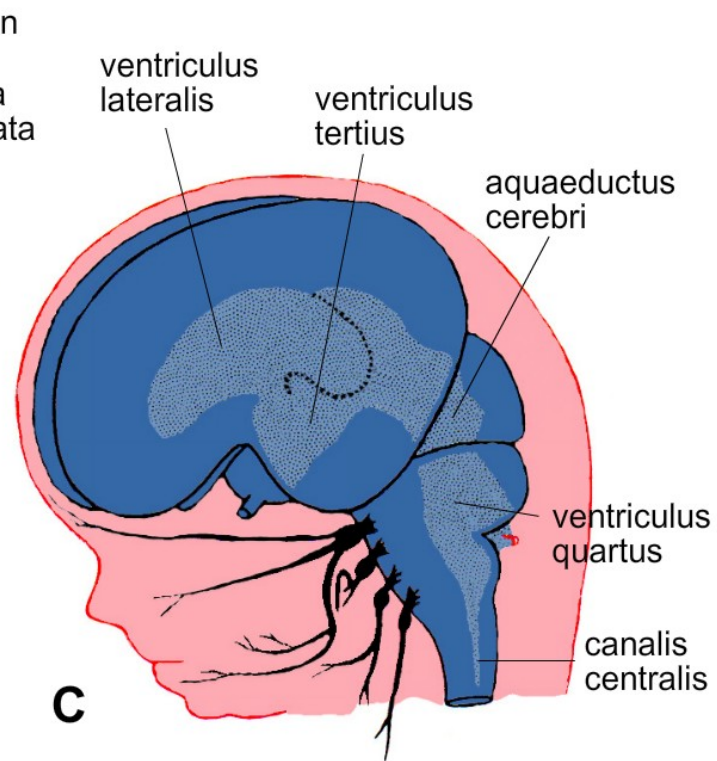
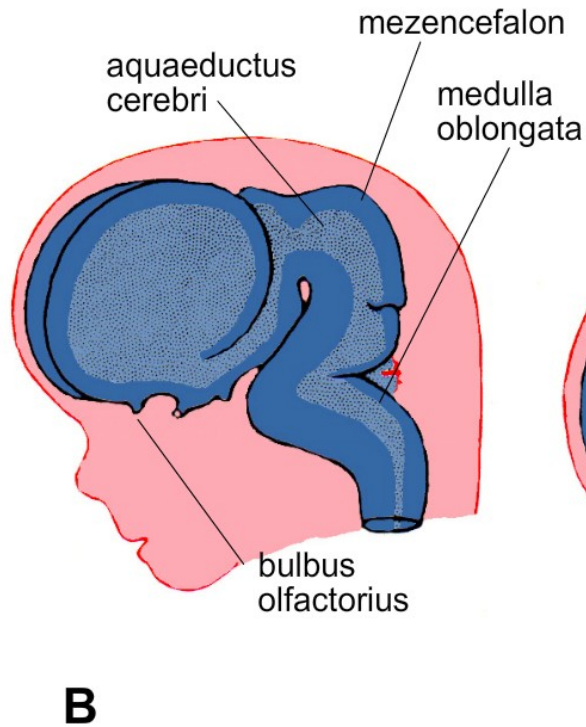
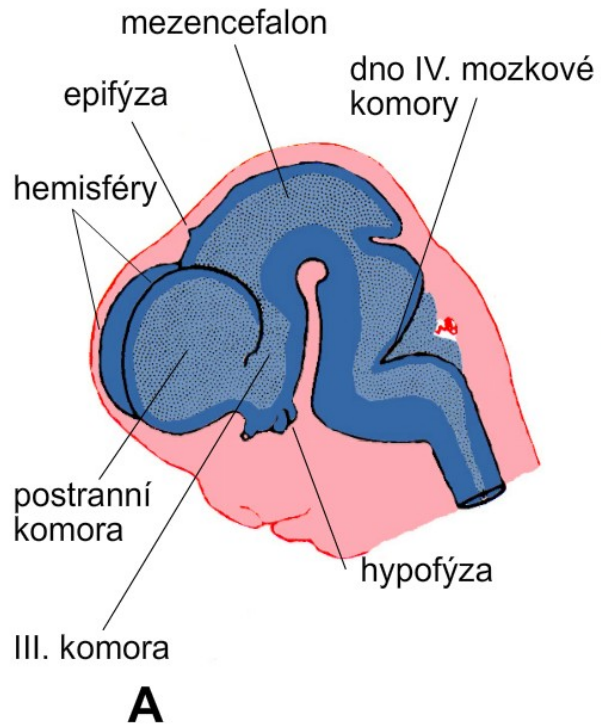
Uzavírání nervové trubice



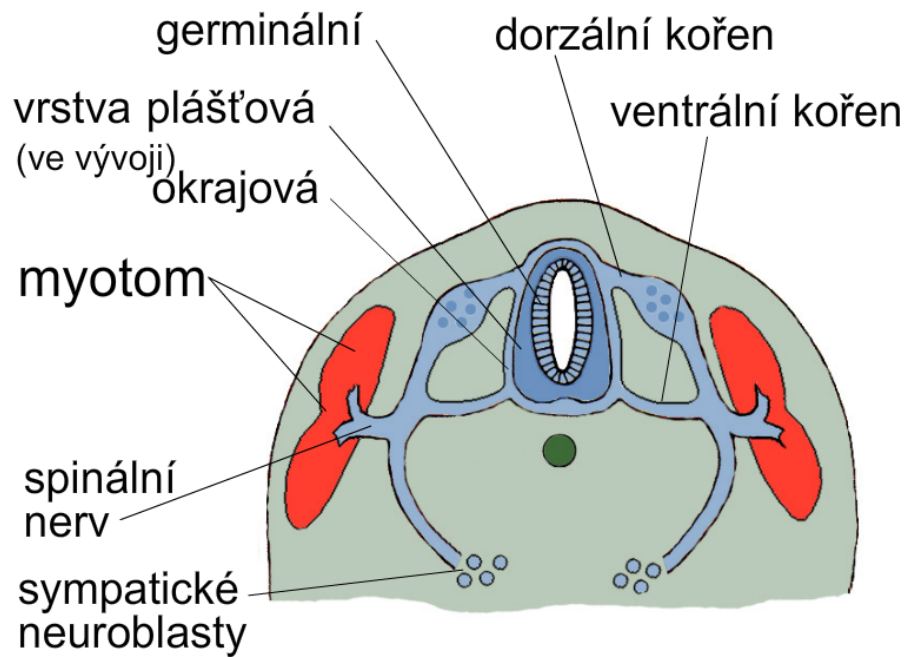
Vývoj mozku



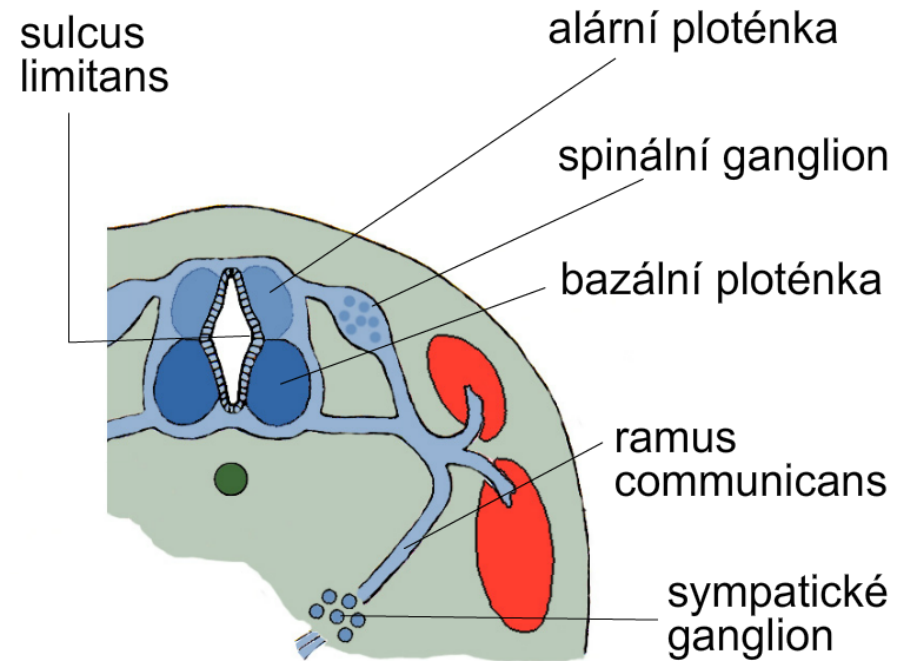
Vývoj mozku



Vývoj míchy



A



B