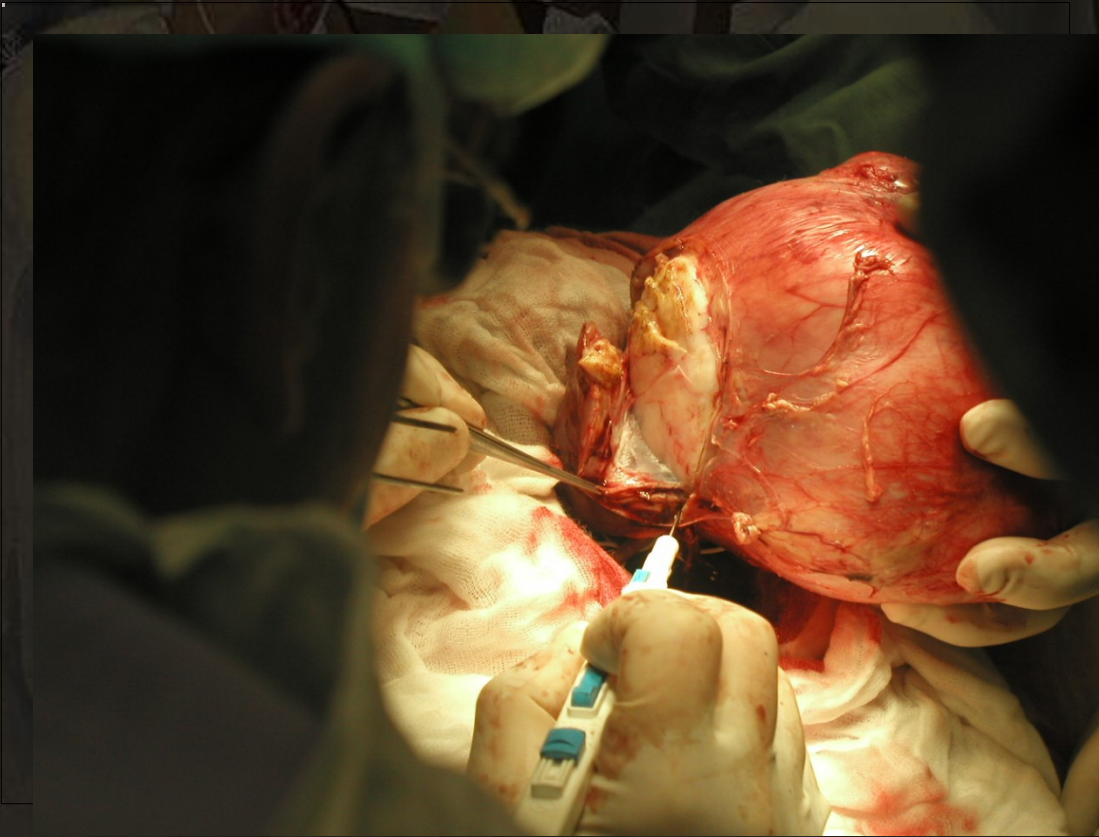




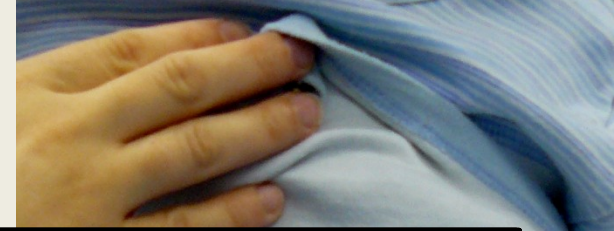PEDIATRIC ONCOSURGERY



PEDIATRIC ONCOSURGERY

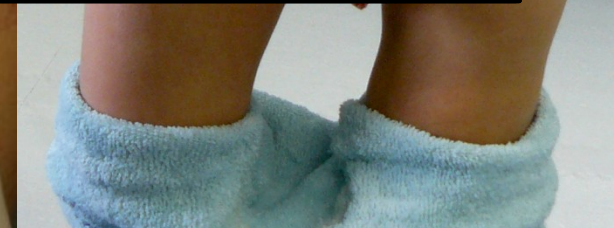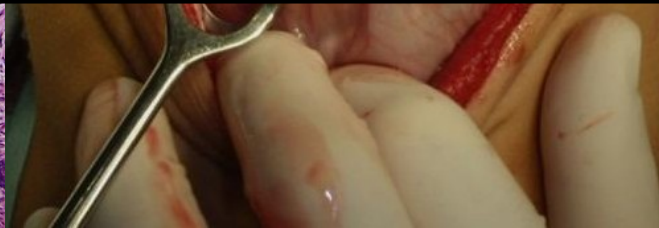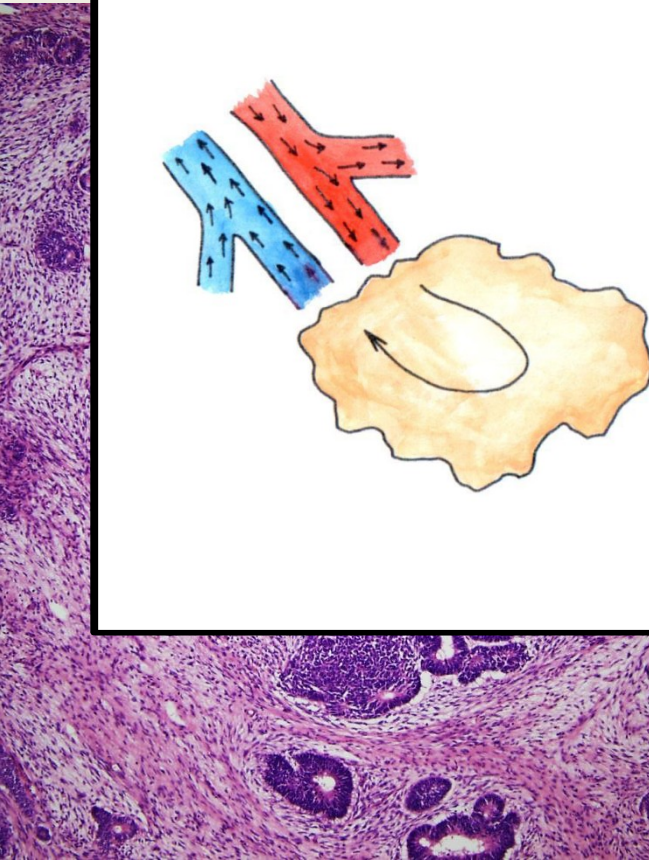
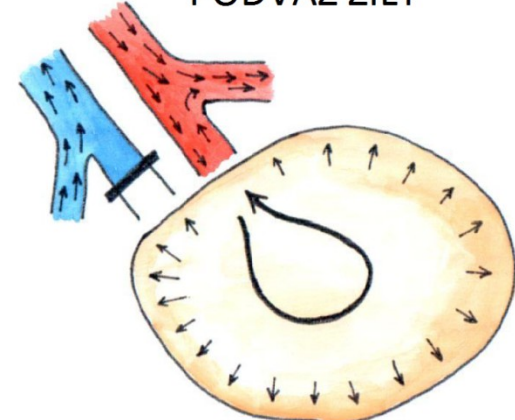
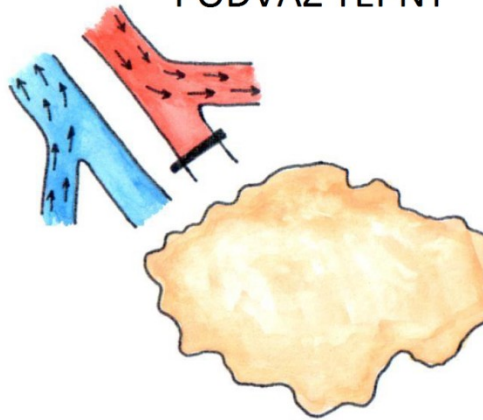
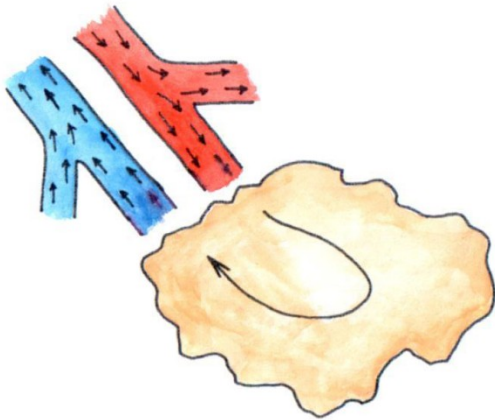
NEPHROBLASTOMA

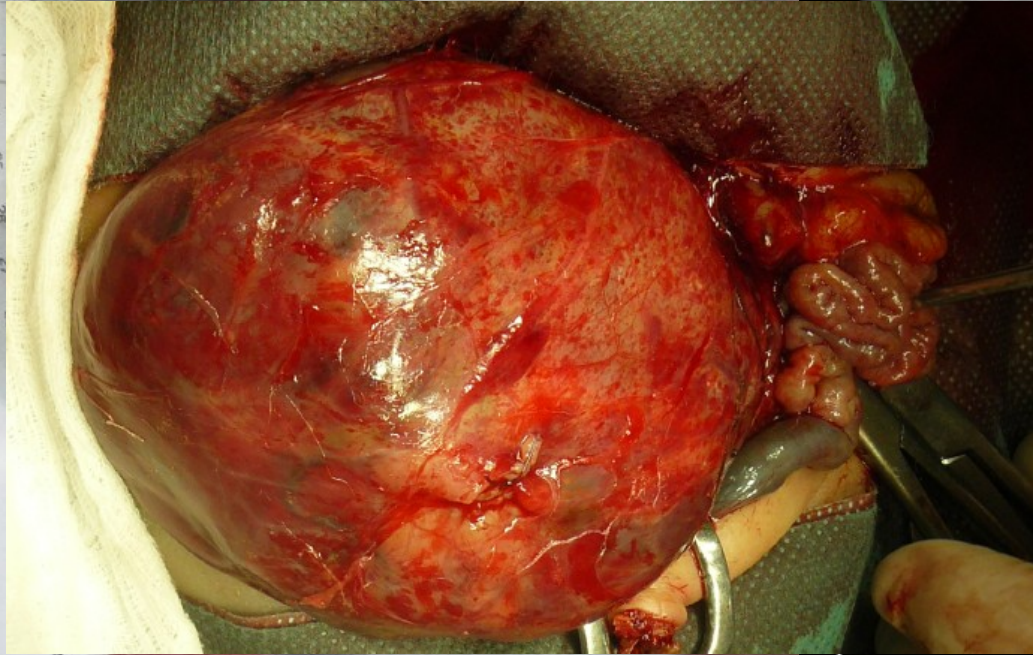
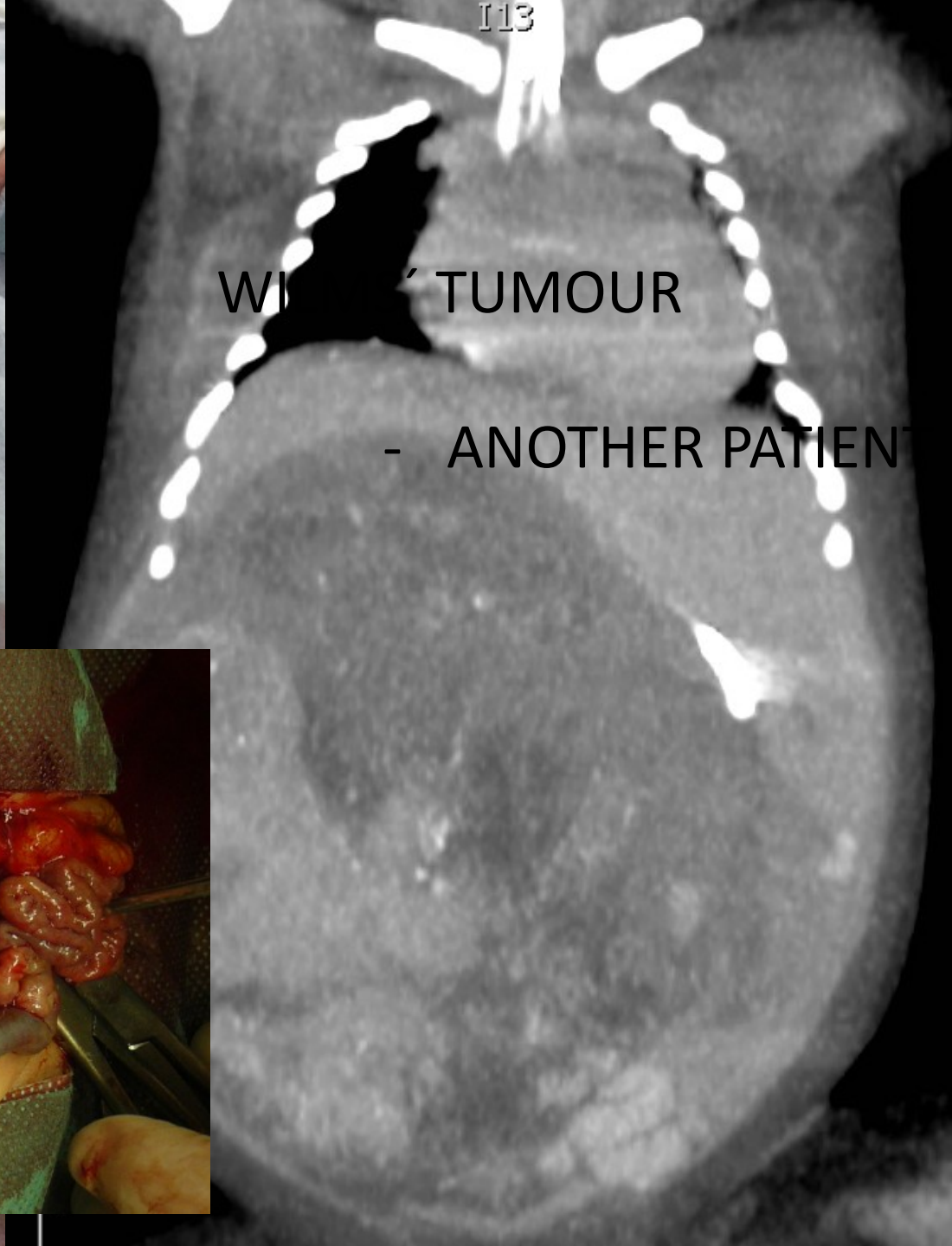
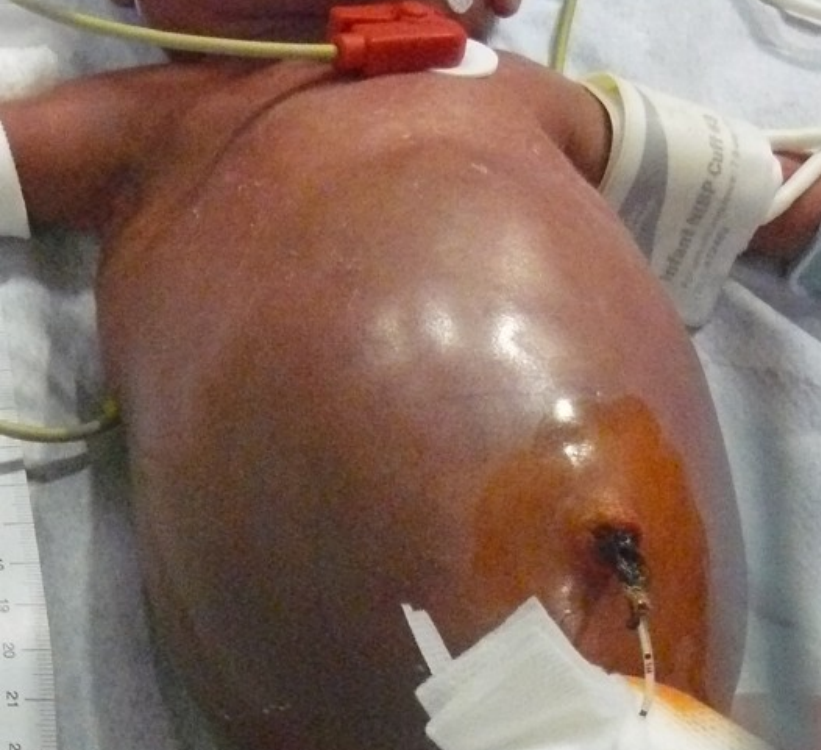a boy (3), parents found a „huge abdomen“ while bathing
large resistance of the right side of the abdomen



ARTERY LIGATION
PODVAZ TEPNY

VEIN LIGATION
PODVAZ ŽILY





PHEOCHROMOCYTOMA

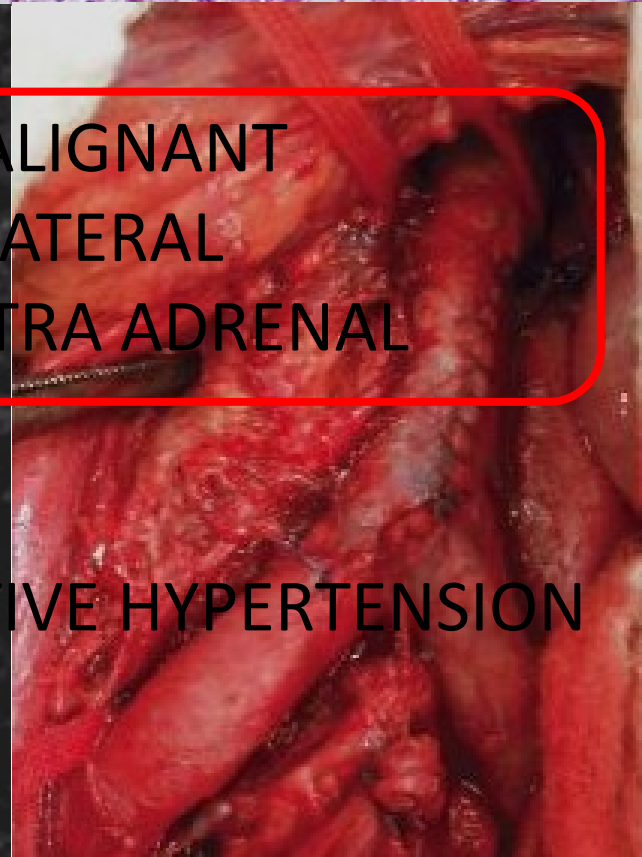
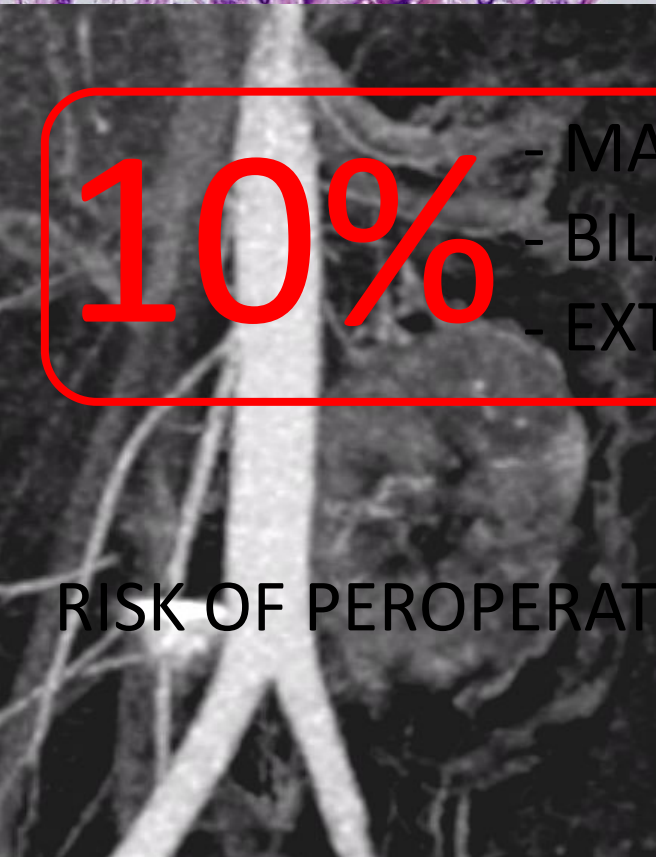a boy (16), seizures - headaches, palpitation, sweating, anxiety
hypertension, paleness, hyperglycemia, loss of weight
prove of metabolites of catecholamines




10%

- MALIGNANT
- BILATERAL
- EXTRA ADRENAL

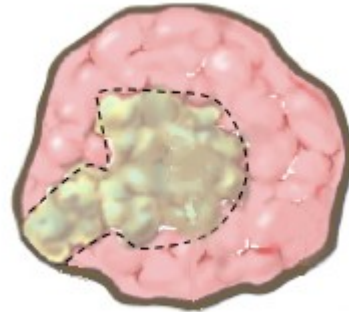
RISK OF PEROPERATIVE HYPERTENSION





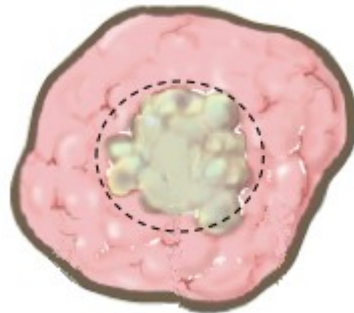
BIOF
RESECTION

R 2



R 1

RADICAL E



R 0

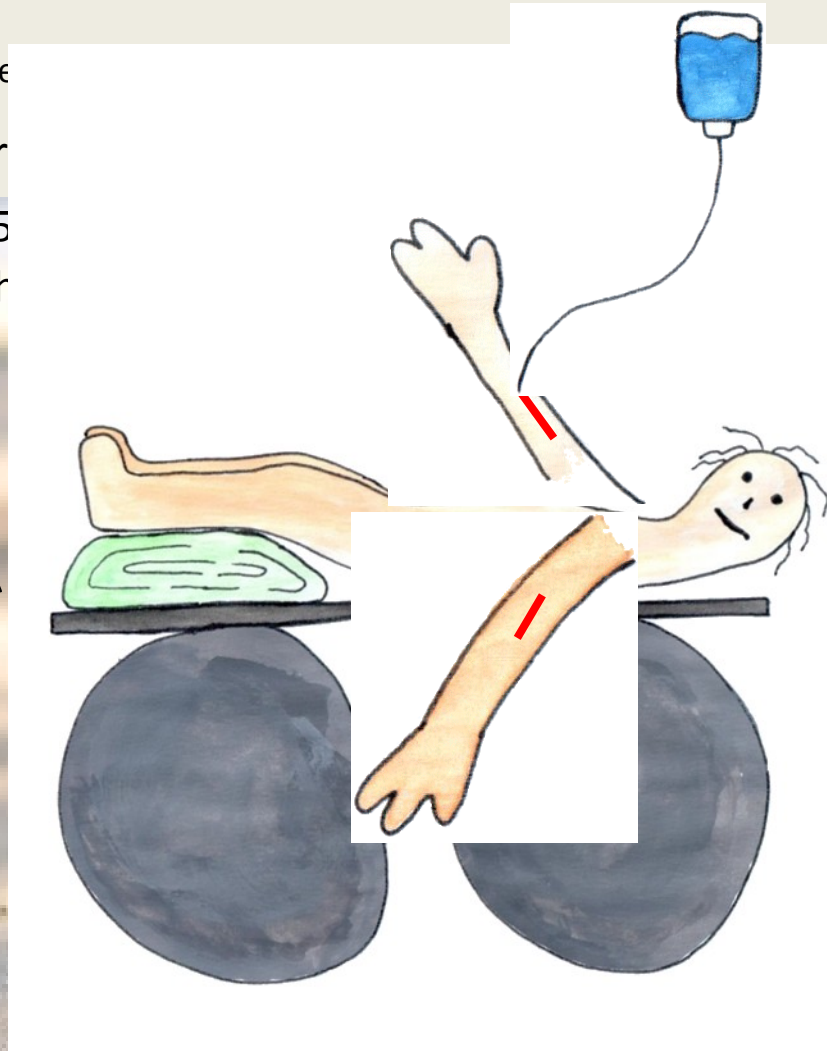
EXCISION IN PRACTICE -

ITIL

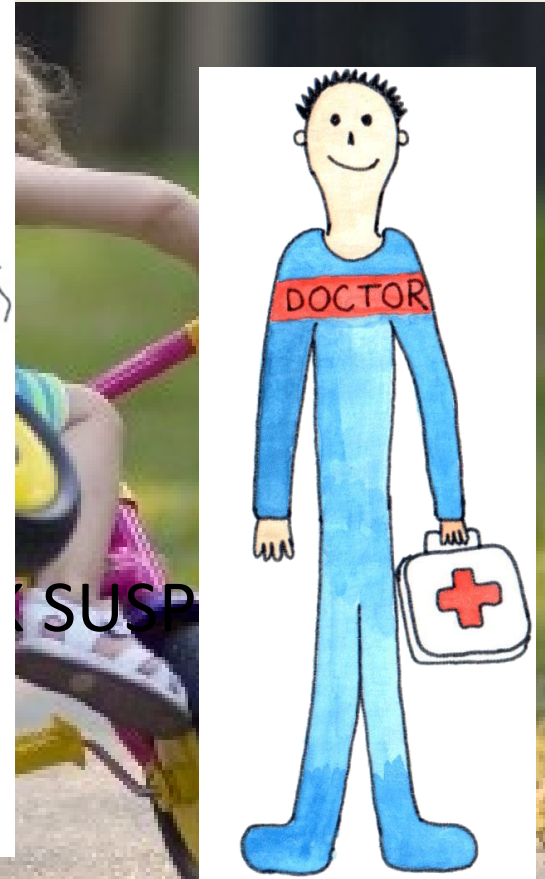
BASIC SANITATION

a girl (5) with stomach ache
fall on the side of ker
pale, sweaty, bp 90/5
sensitivity in PHK , ph

PREFER



ting room
omach ache



SUSP

AT HOSPITAL ADMISSION

pale, somnolent, non measurable bp, p 160

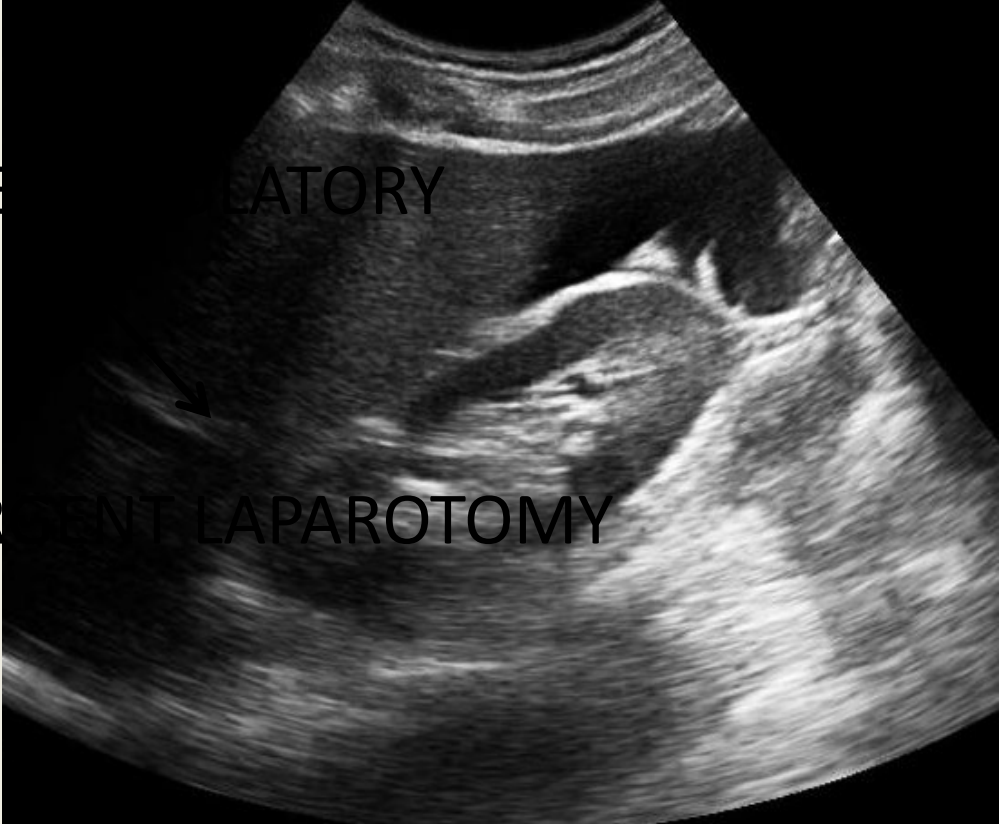

UNSTABLE
LABORATORY

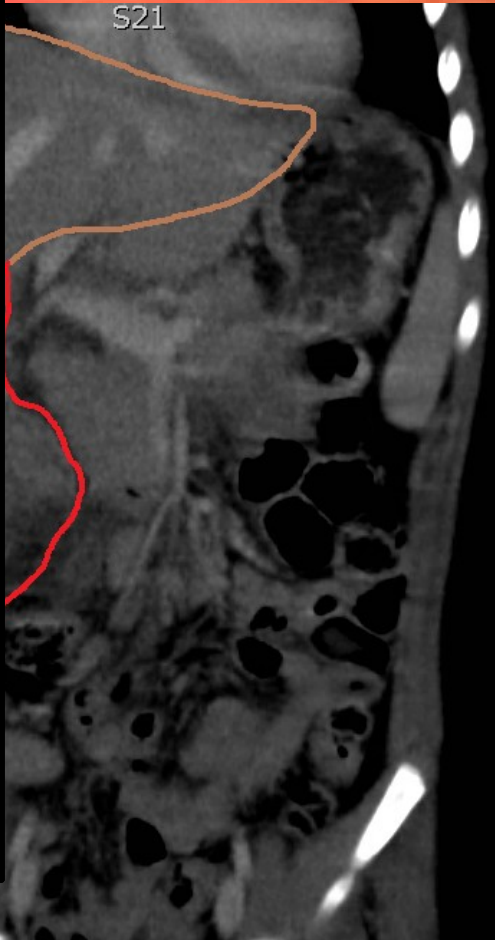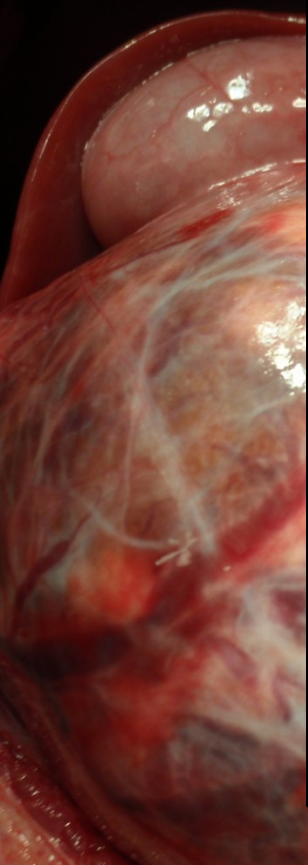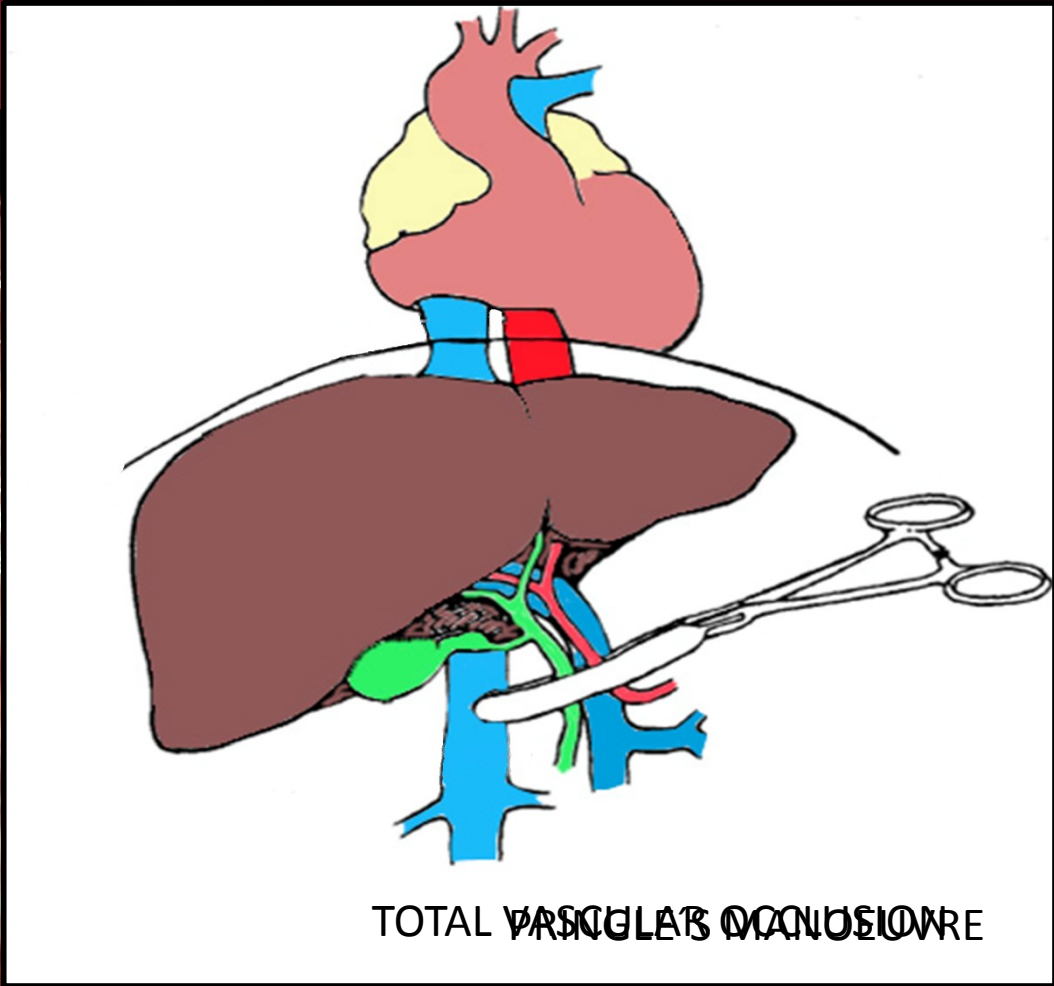


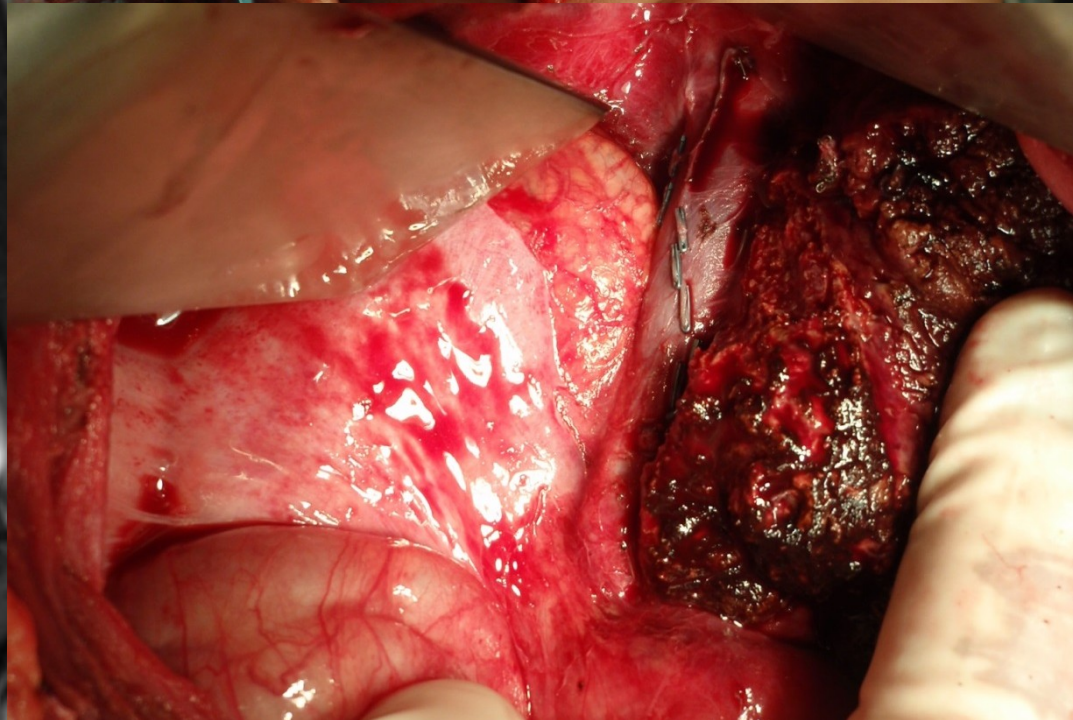
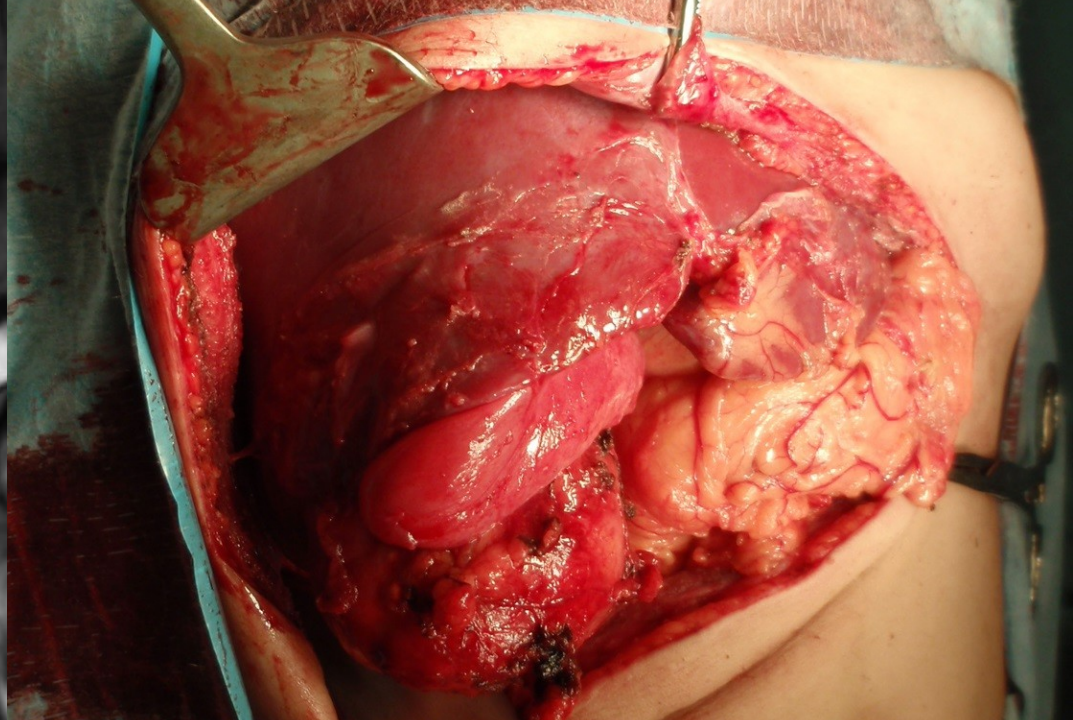
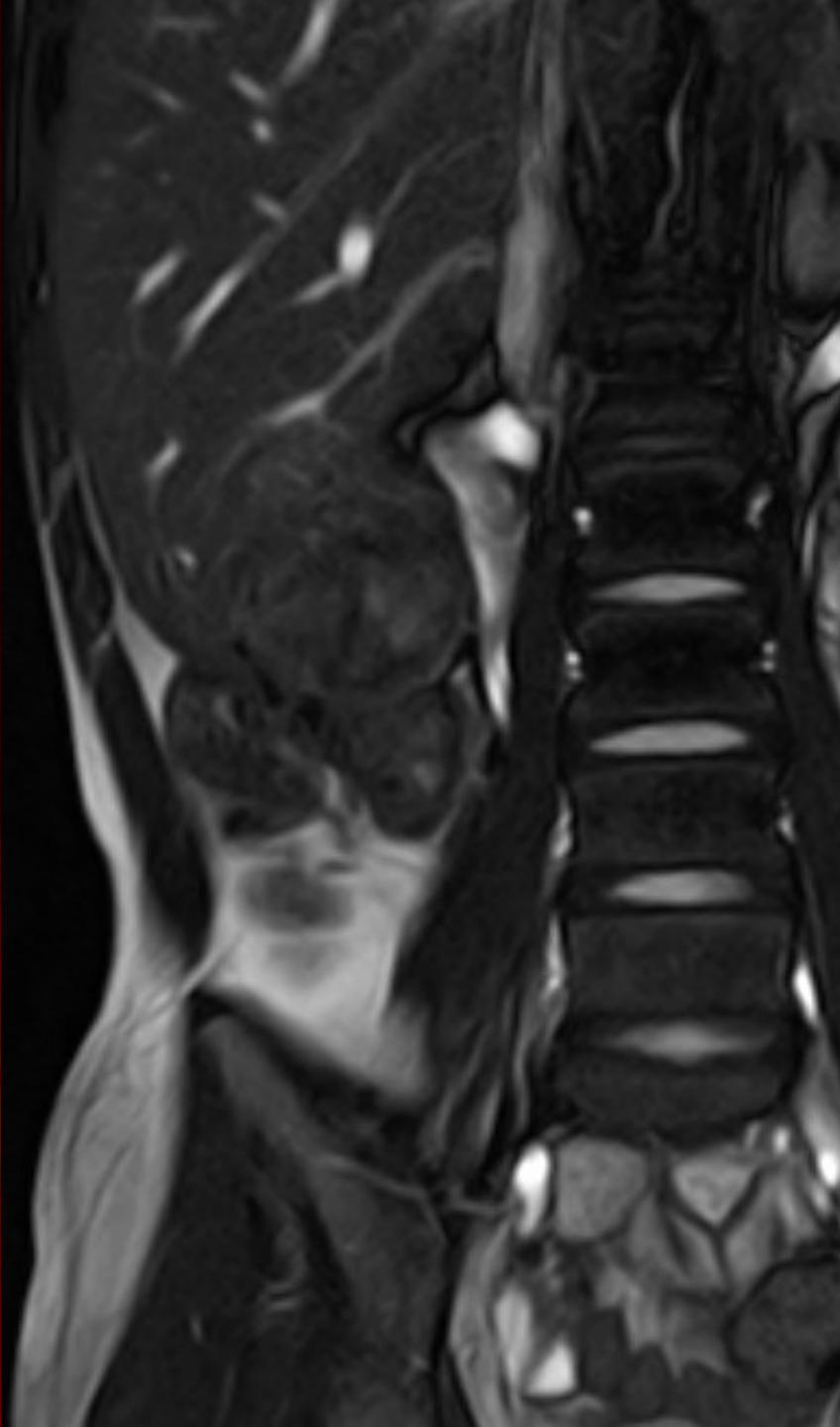
(WE DO NOT WAIT FOR THE RESULT)

URGENT LAPAROTOMY



HEPATOBLASTOMA





LIEDATODI LACTOMA

LULAR MA

INCIDENCE

AGE DISTRIBUTION

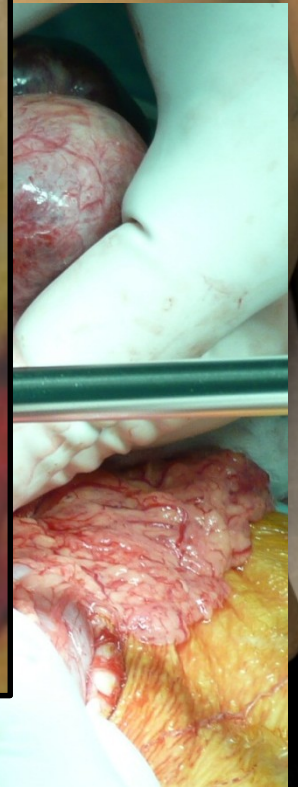
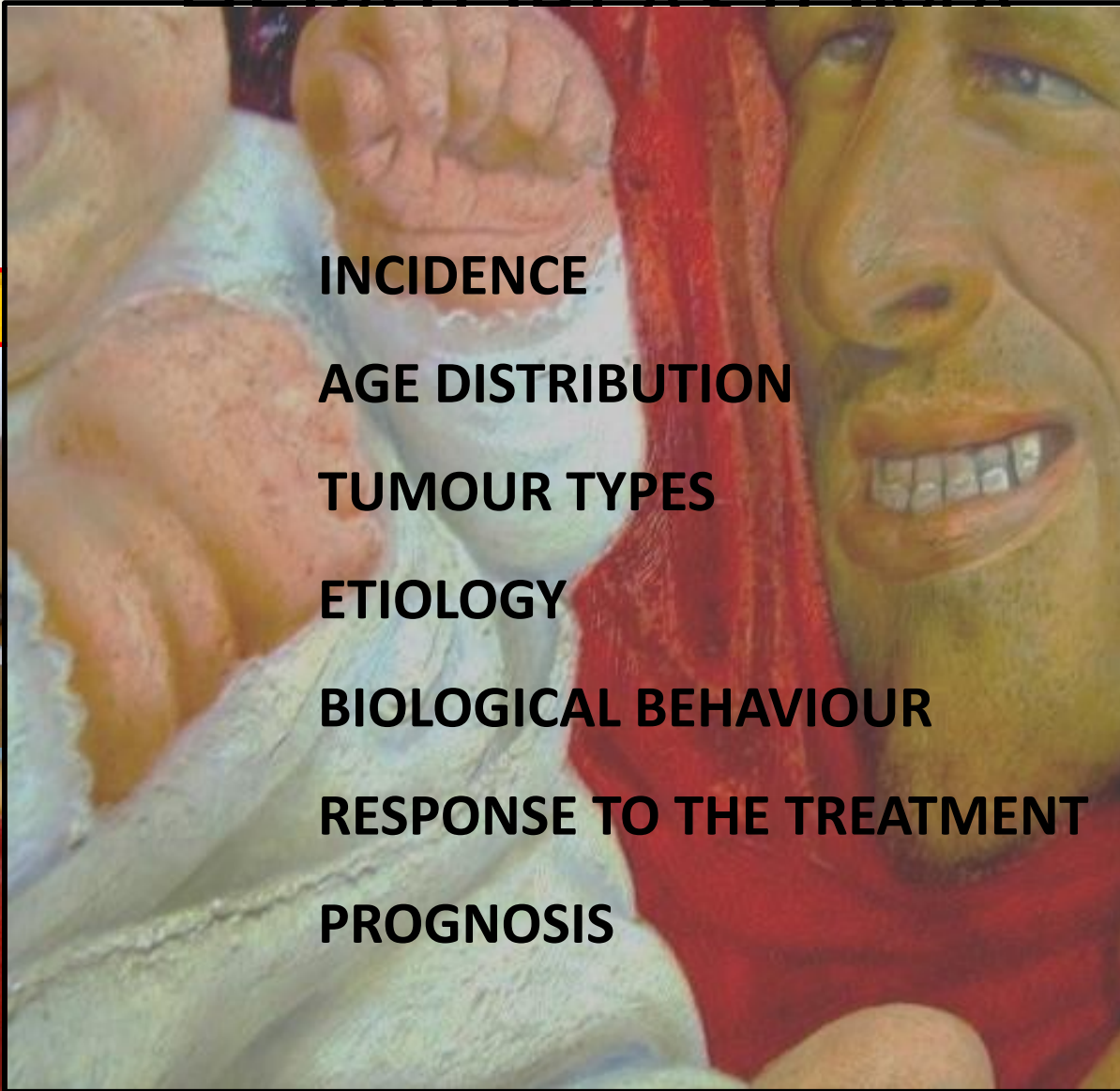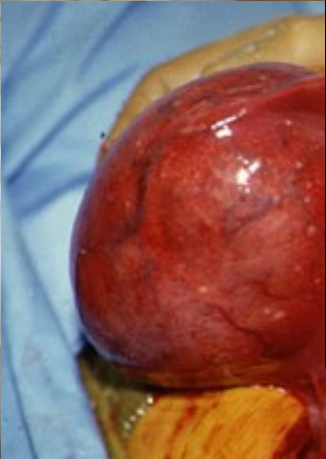
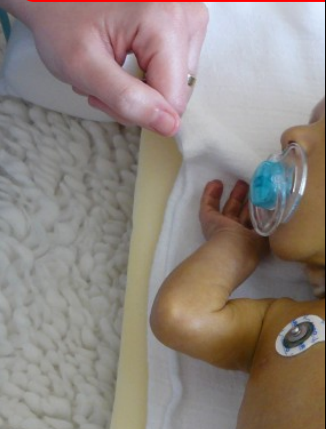TUMOUR TYPES

ETIOLOGY

BIOLOGICAL BEHAVIOUR

RESPONSE TO THE TREATMENT

PROGNOSIS



LYMPHOMA MEDIASTINUM

a girl (14) with progressive breathlessness, cough and head and neck swelling
head, neck and upper limbs swelling
dilatation of subcutaneous veins
conjunctiva congestion

UPPER BODY ELEVATION

OXYGEN THERAPY

CORTICOIDS

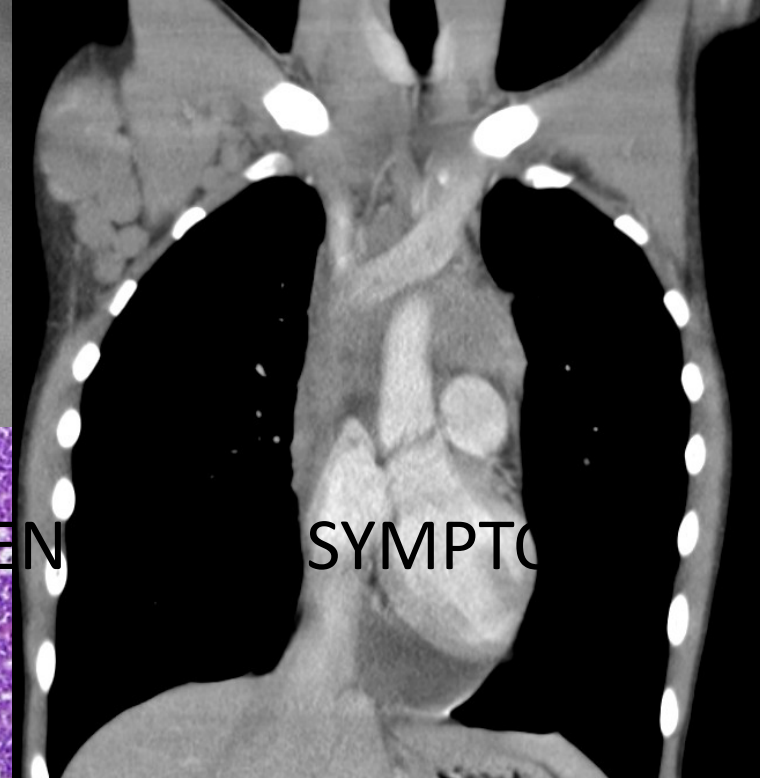
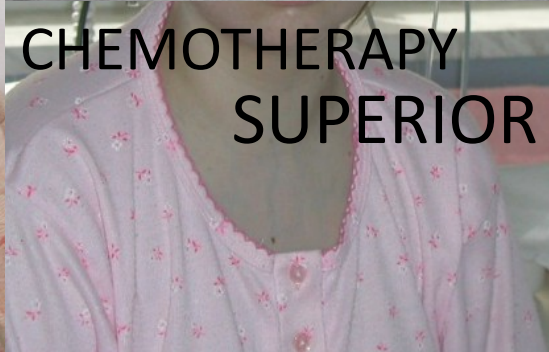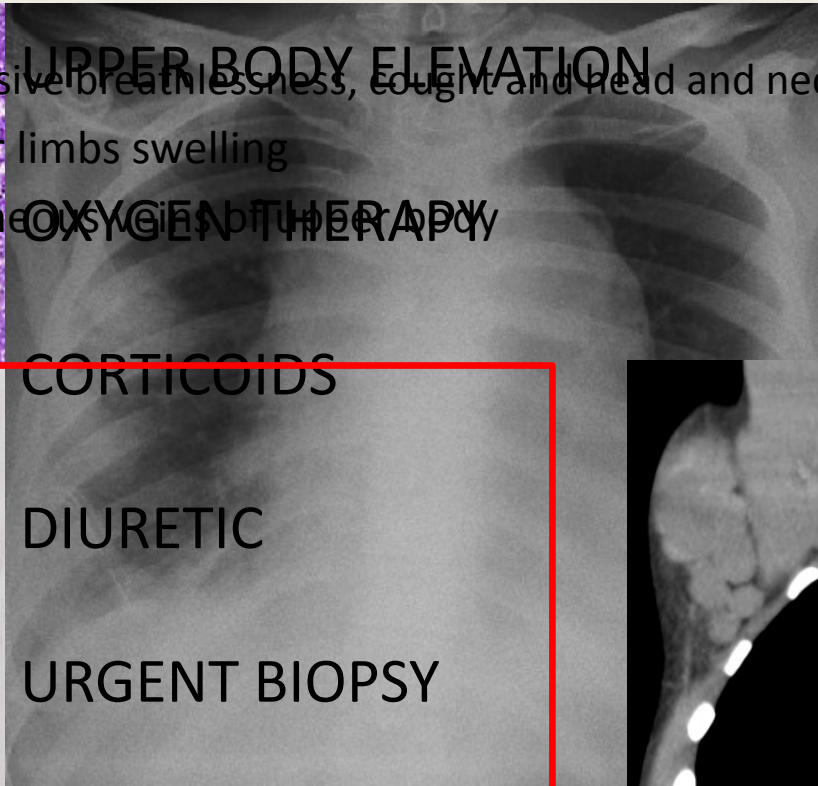
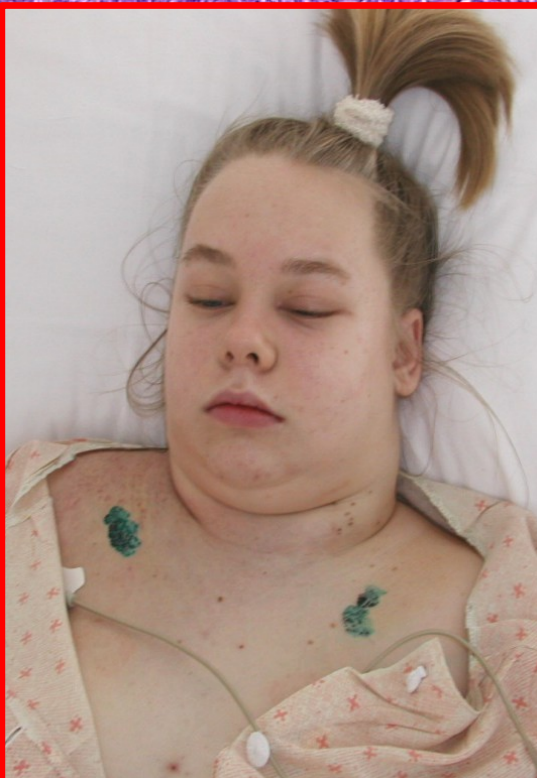DIURETIC

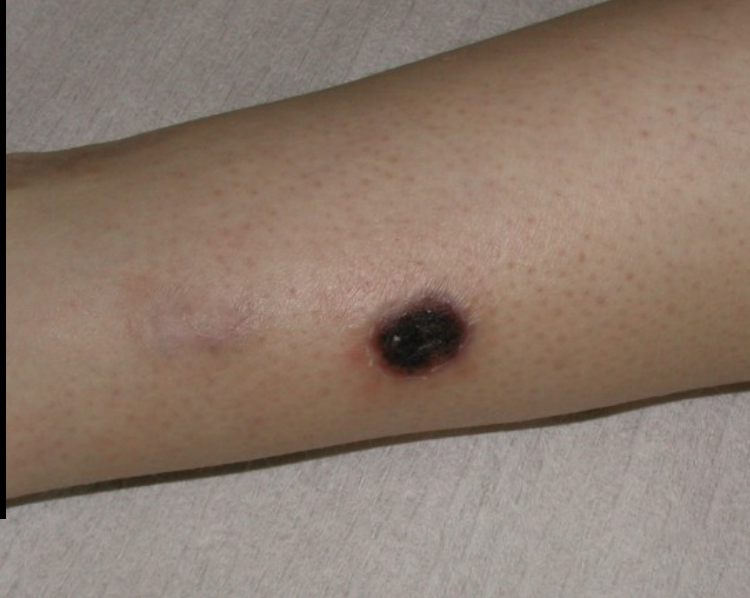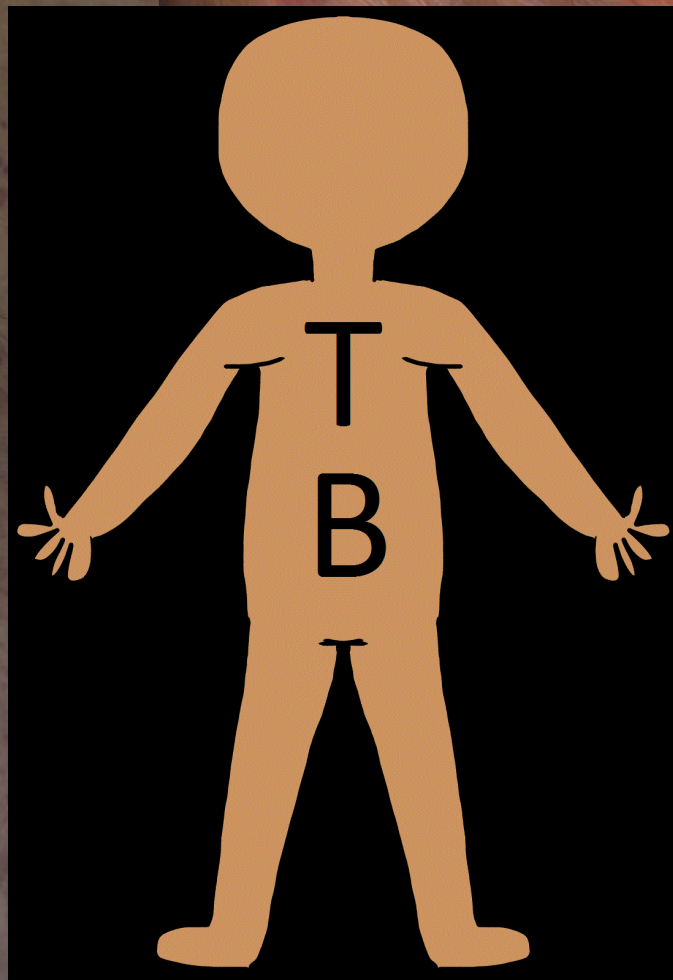
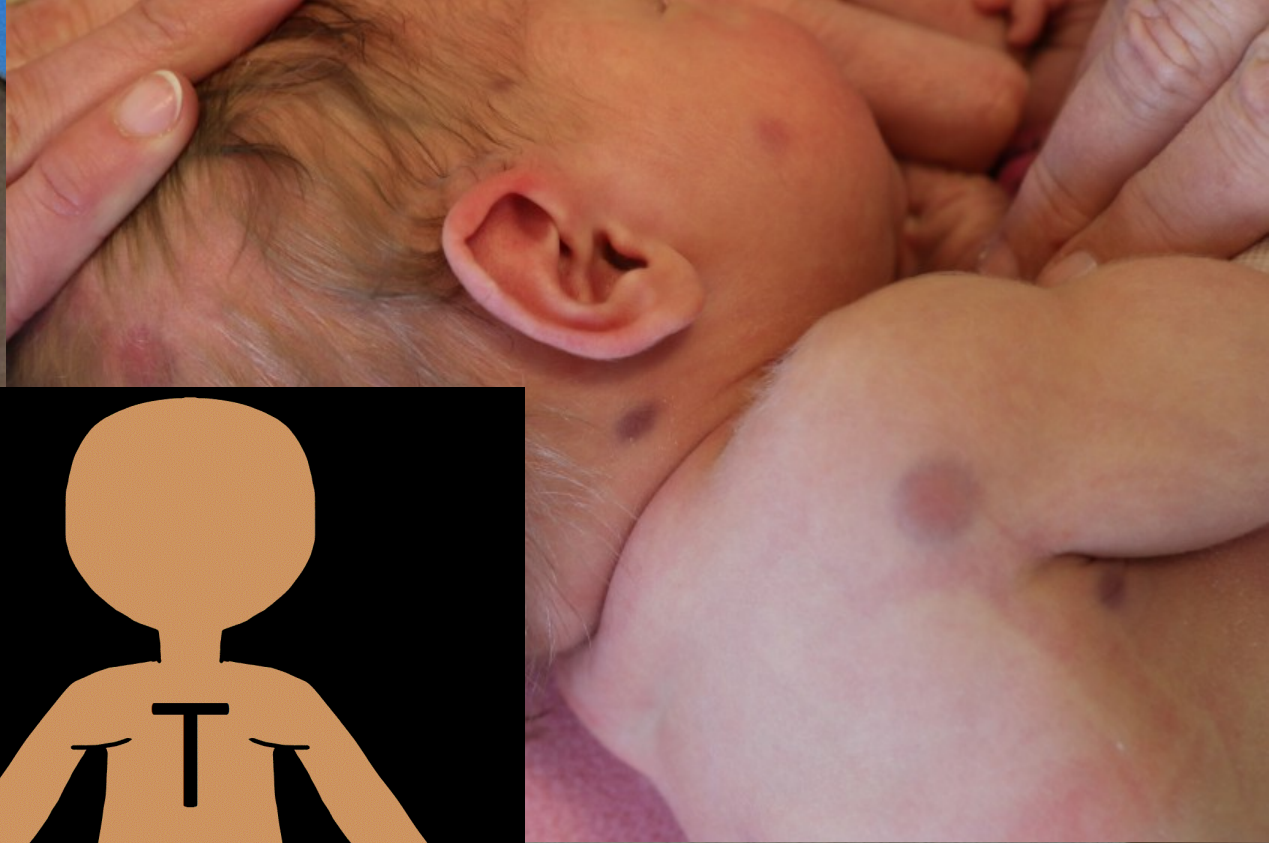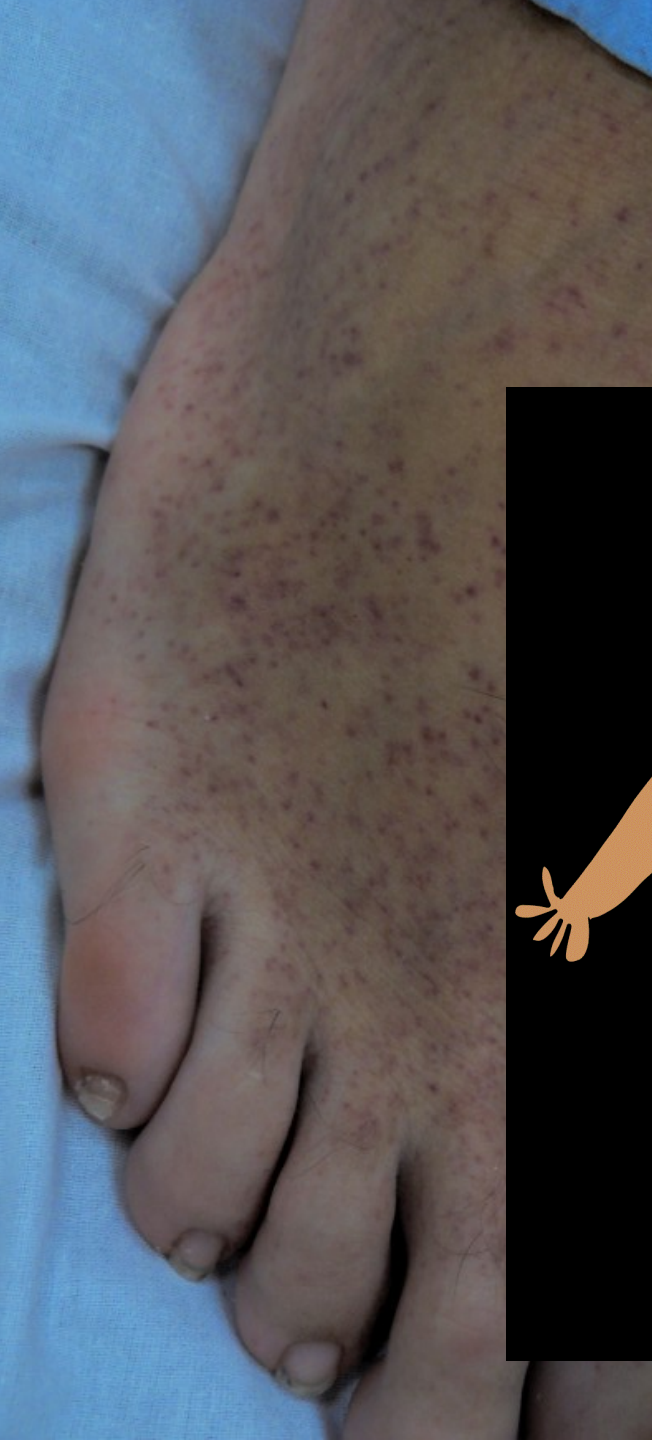URGENT BIOPSY

CHEMOTHERAPY

SUPERIOR VENA

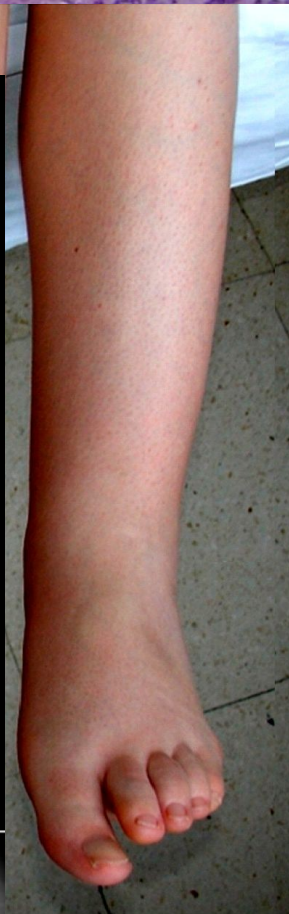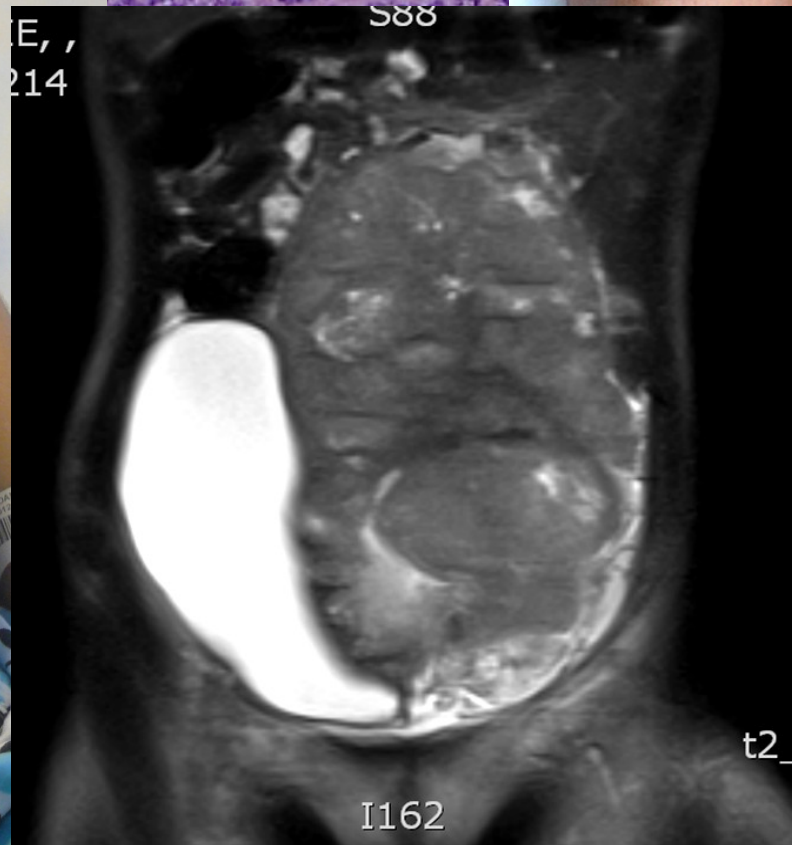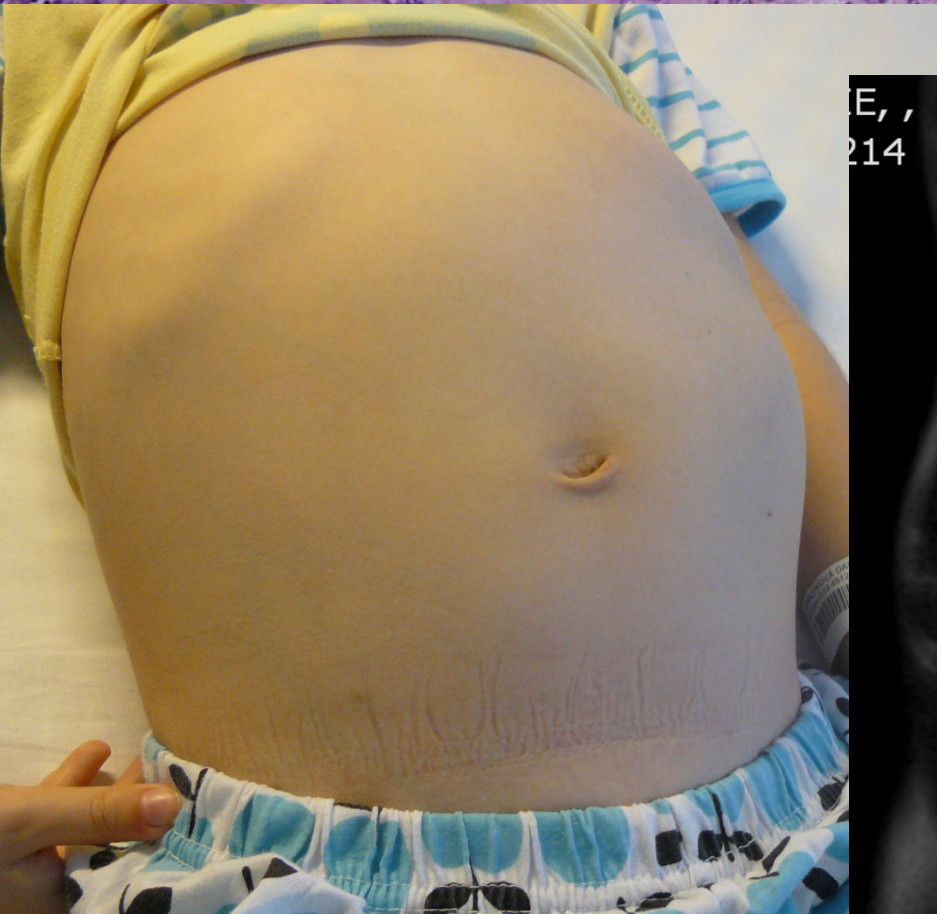
SYMPTOM



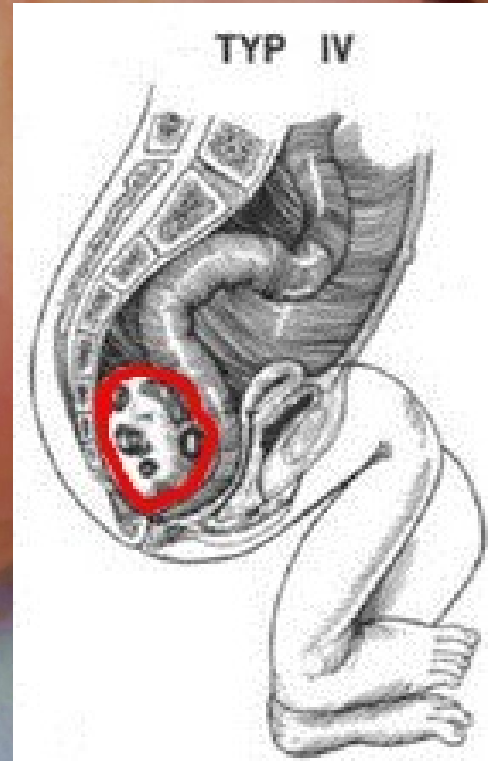
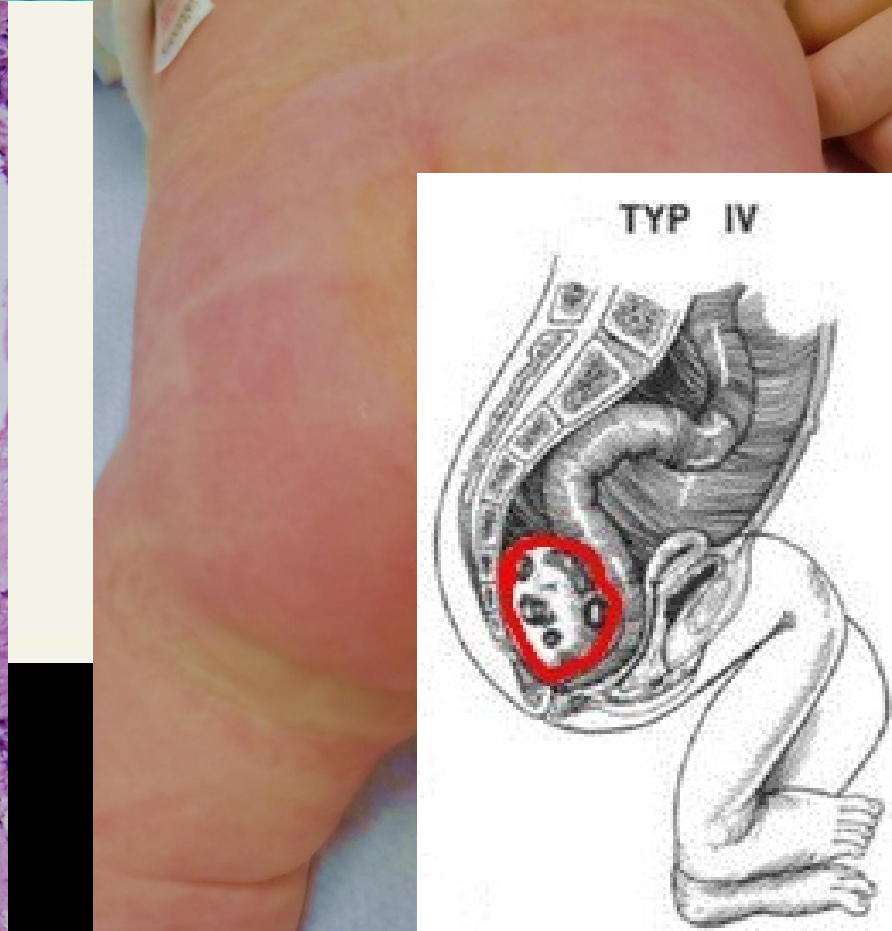
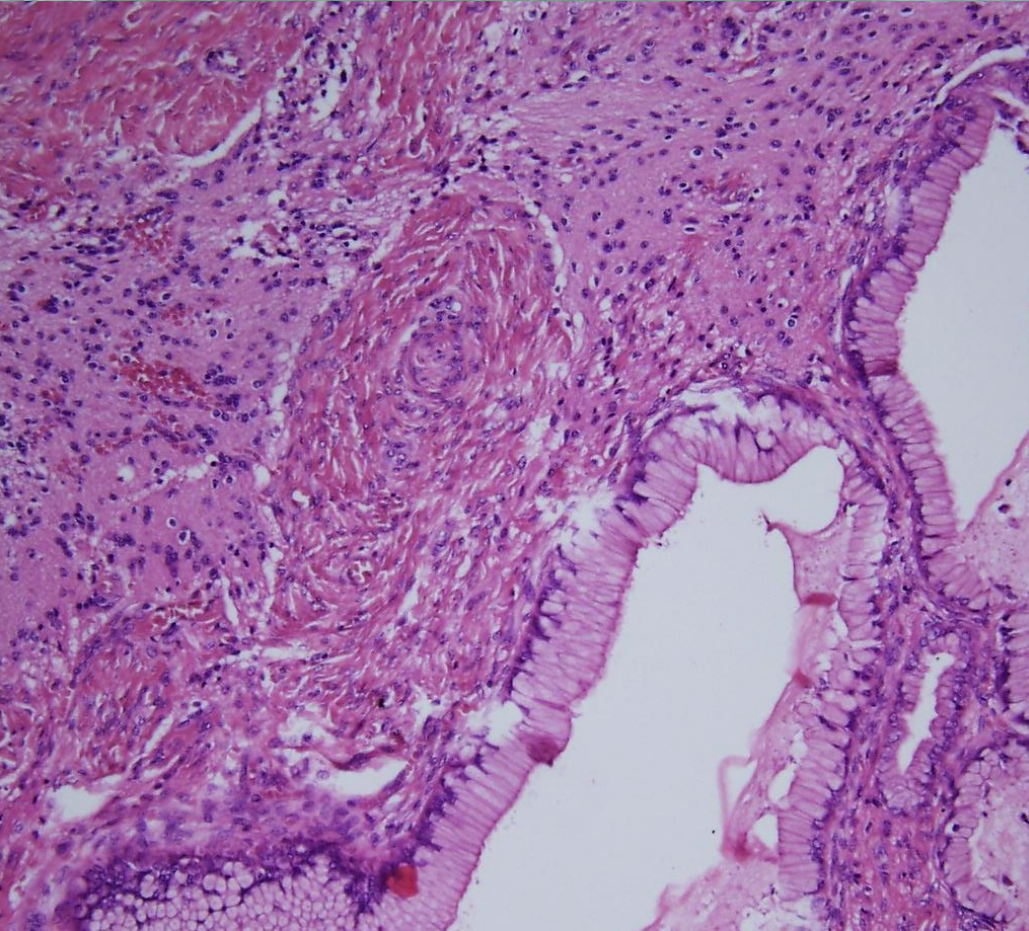


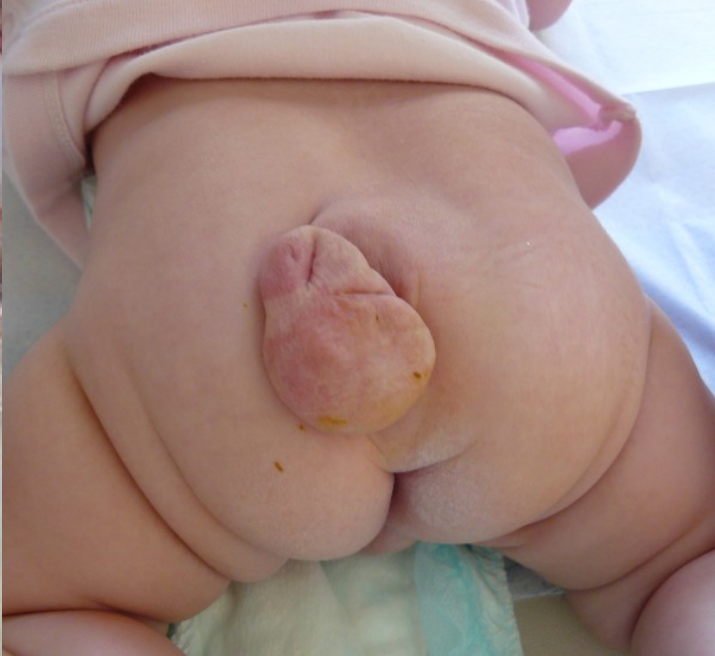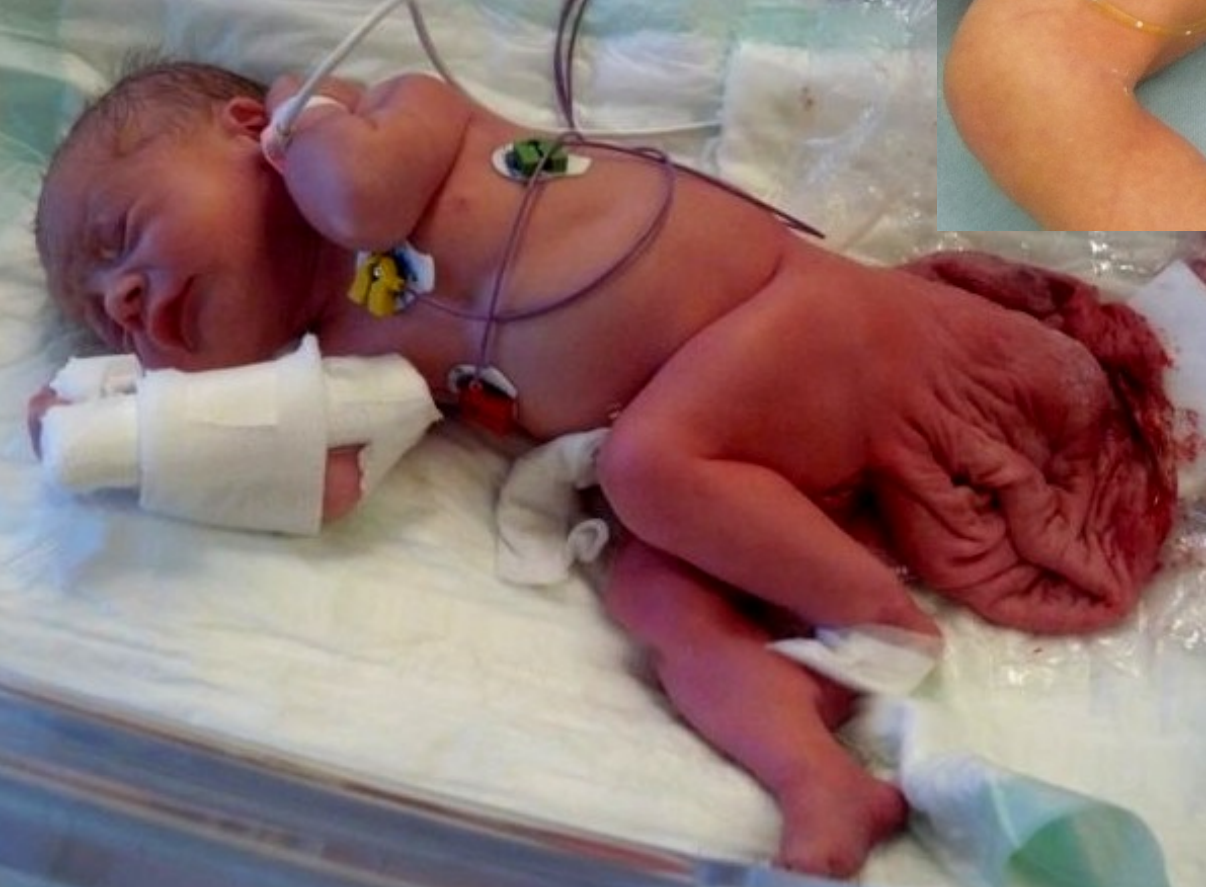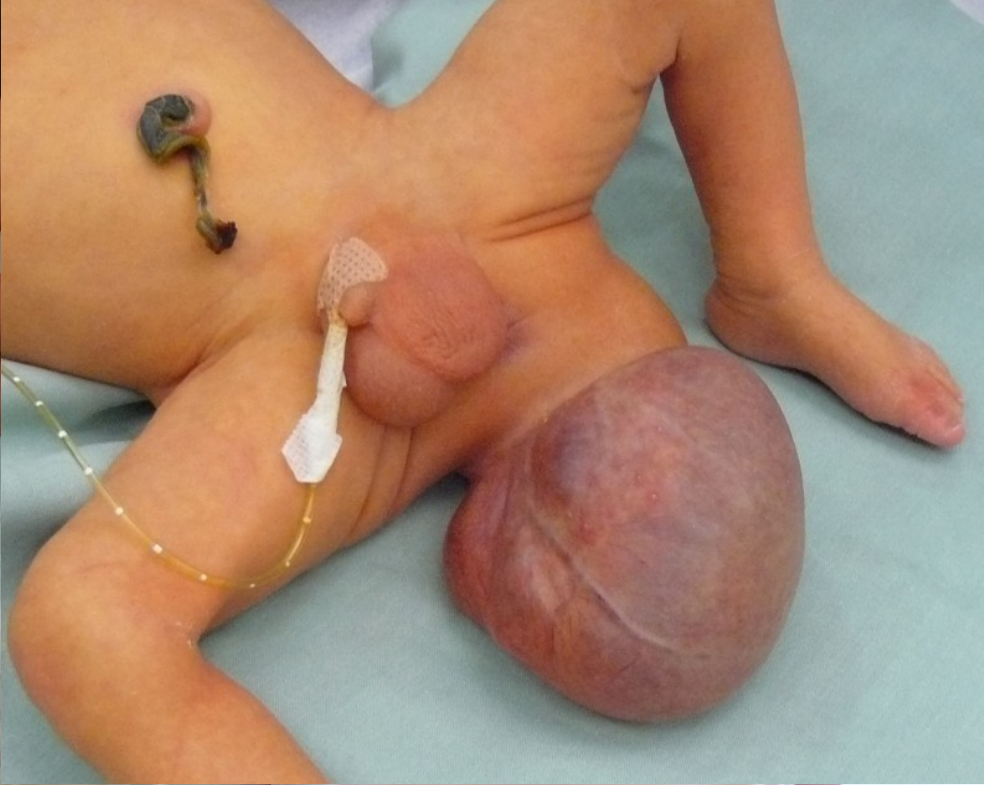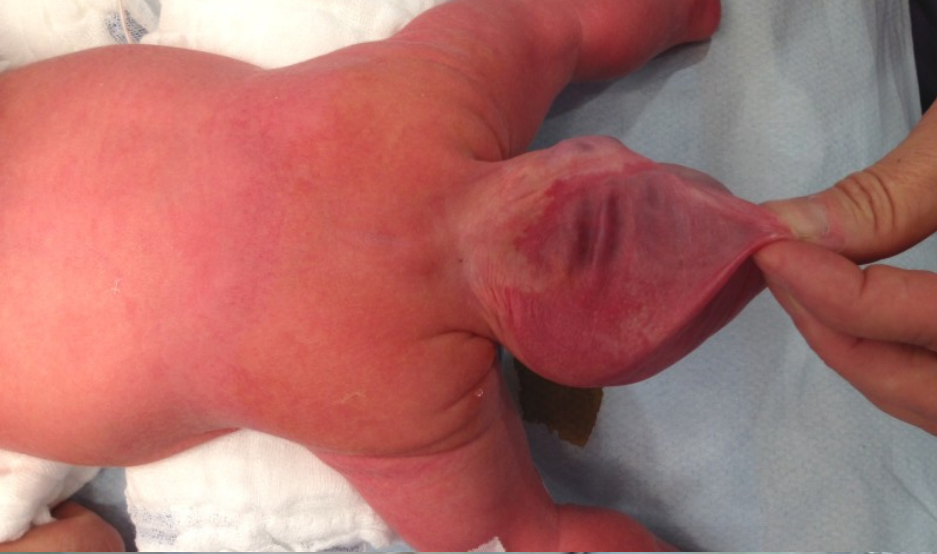RHABDOMYOSARCOMA OF PELVIS

a girl (10) with lower left limb swelling, no urinate for 20 hours
soft swelling of LLL, great abdomen resistance



SACROCOCCYGEAL TERATOMA

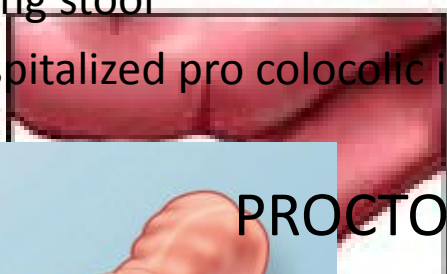




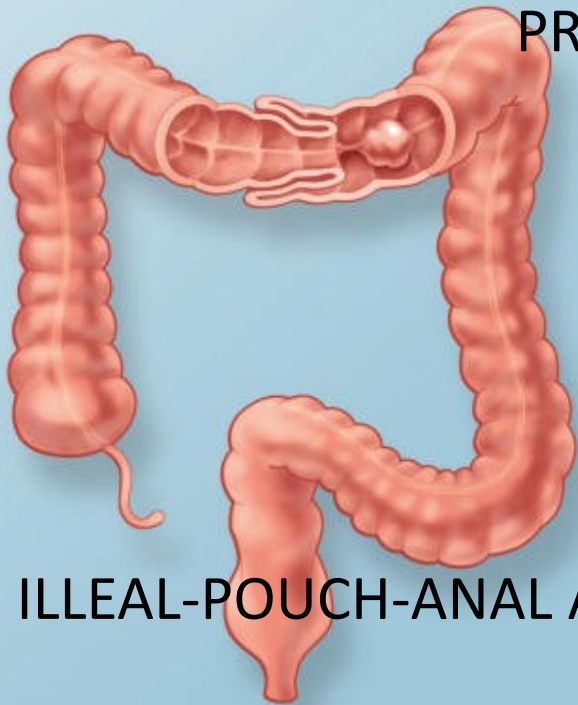
FAMILIAL COLON POLYPOSIS

RA: father and uncle died of CRC up to 30 years
a girl (15) with occasional stomach ache, mucus
and bleeding stool

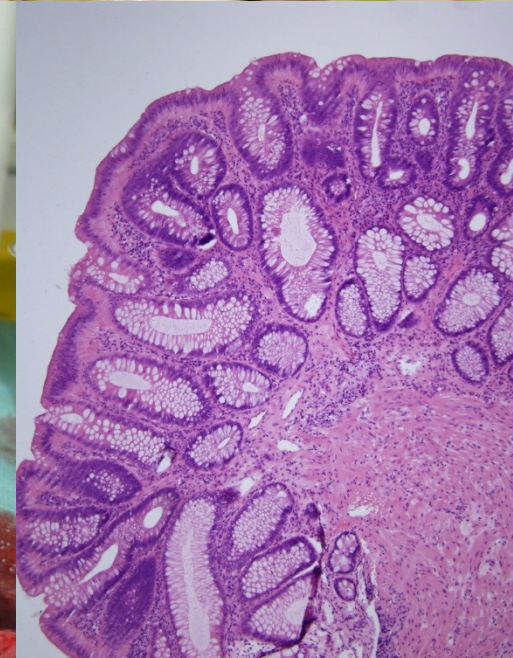
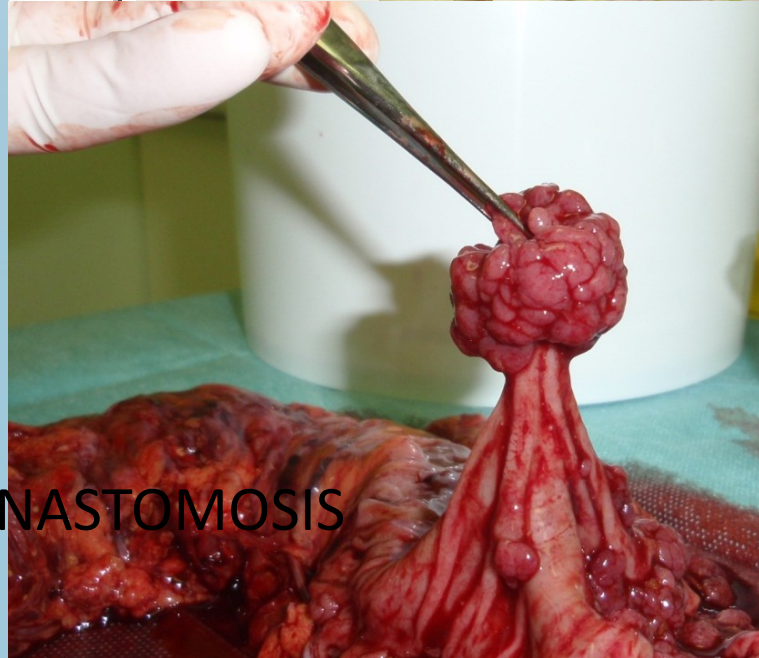OA: 2x hospitalized pro colocolic invagination



PROCTOCOLECTOMY – PREVENTIVE INTERVENTION



ILLEAL-POUCH-ANAL ANASTOMOSIS



A close-up photograph of a person's lips. The lips are closed, and there is prominent brown pigmentation (leukokeratosis) on the lower lip, particularly around the central sulcus and extending towards the corners. The pigmentation consists of irregular, dark brown spots and streaks. The surrounding skin also shows some minor pigmentation.

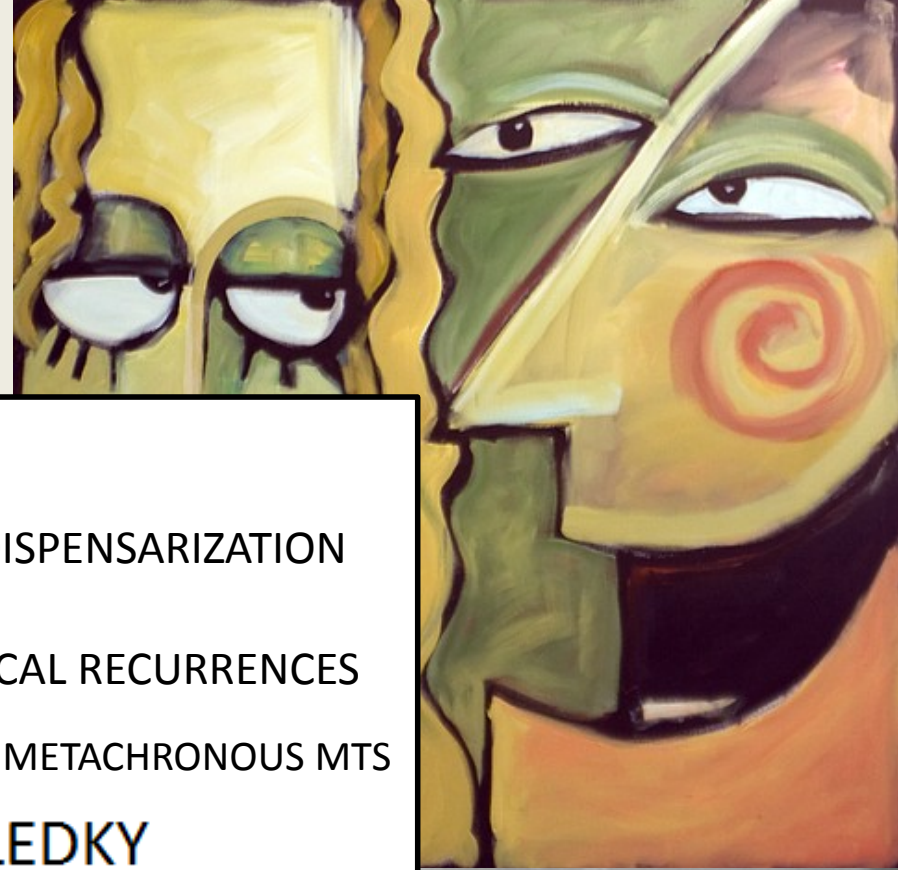LIP, ORAL CAVITY, FINGER PIGMENTATION

PEUTZ-JEGHERS SYNDROME (NOT FAP)

PULMONARY METASTASIS

subjectively without complication

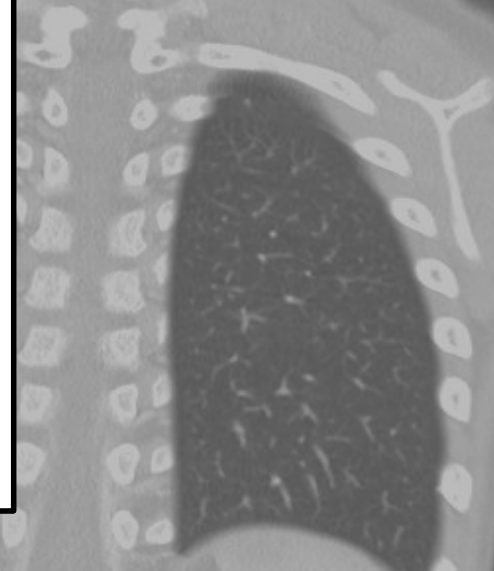
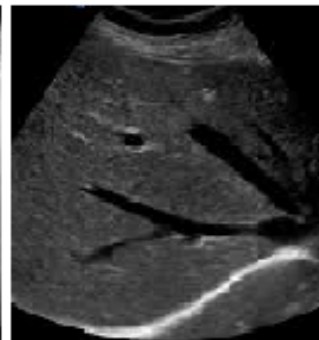
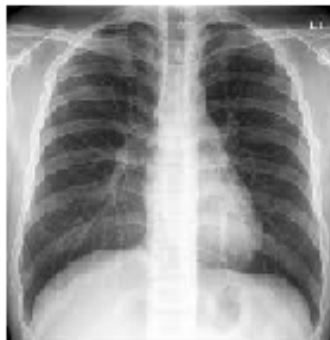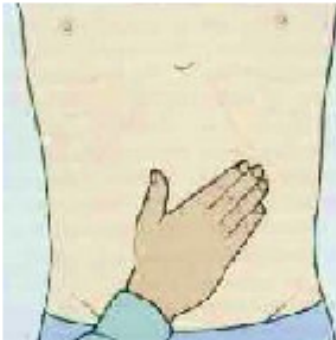objec
calm s
Ewing



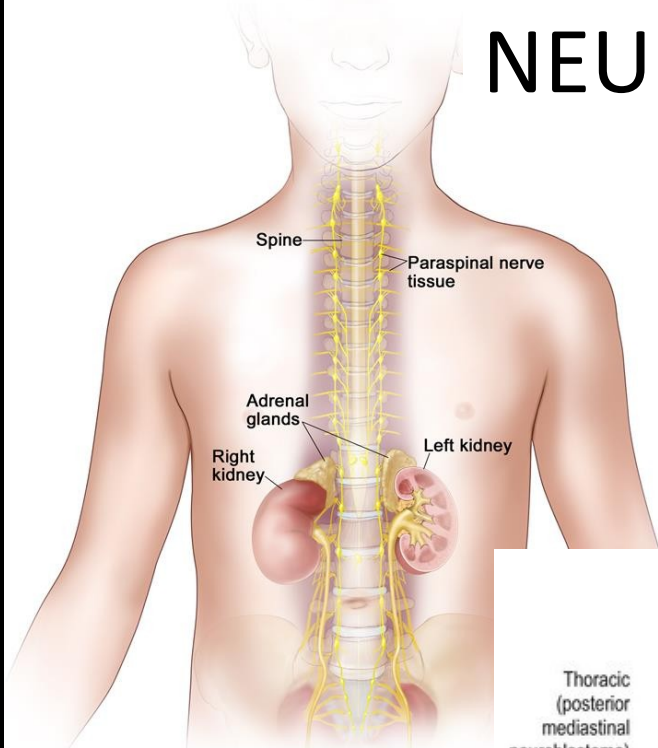
DISPENSARIZACE DISPENSARIZATION

- LOKÁLNÍ RECIDIVY LOCAL RECURRENCES
- METACHRONNÍ MTS METACHRONOUS MTS
- KOMPLIKACE A NÁSLEDKY

COMPLICATION AND CONSEQUENCES



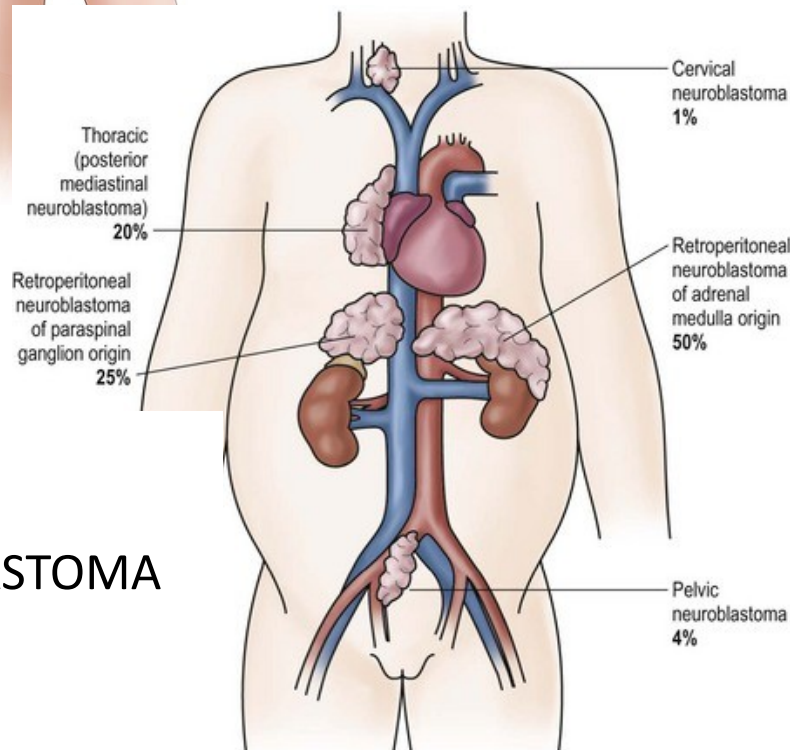
NEUROBLASTOMA



IDRF

INRGSS

nMYC

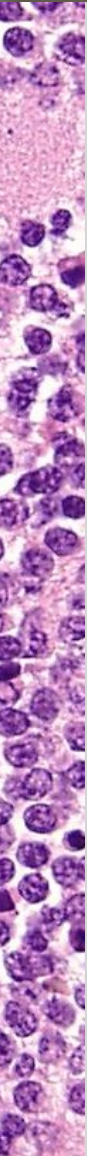

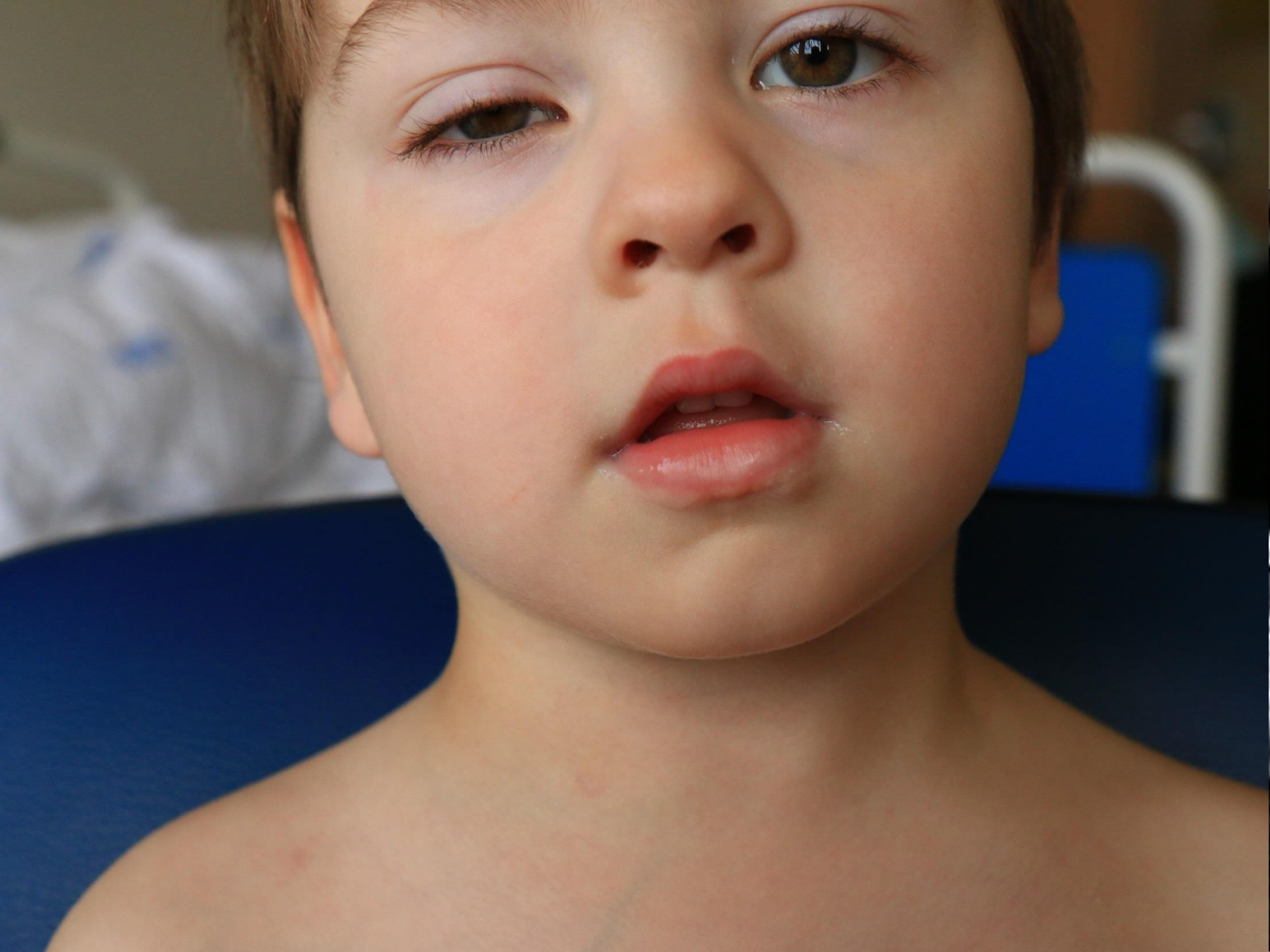NEUROBLASTOMA

GANGLIONEUROBLASTOMA

GANGLIONEUROMA

MIBG





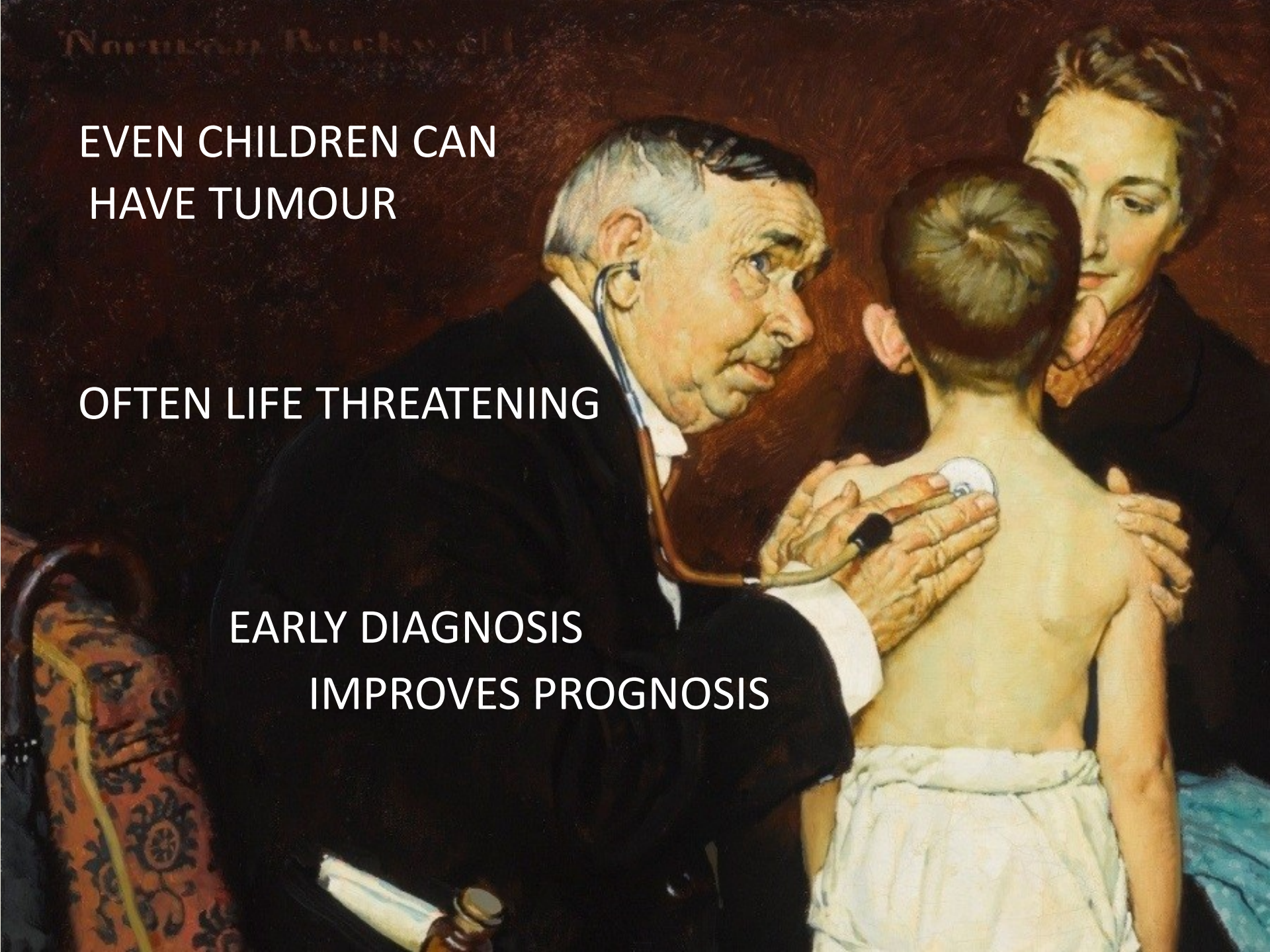Norman Rockwell

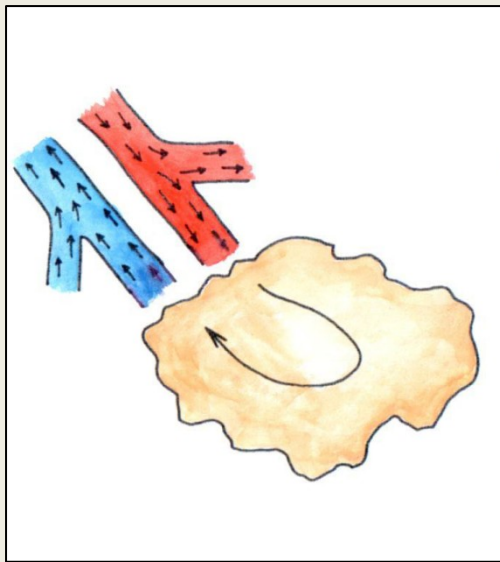
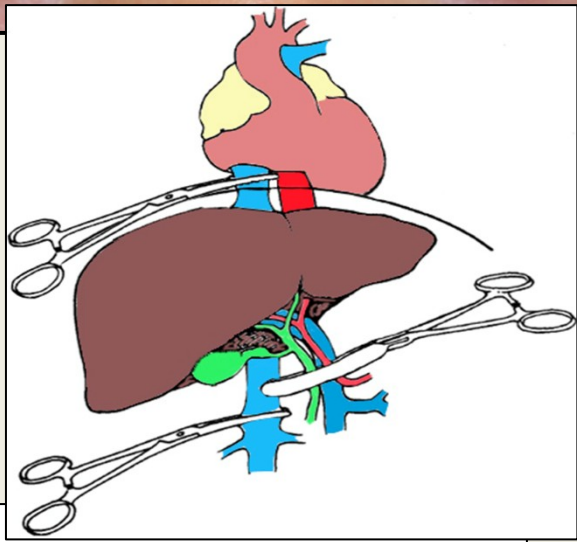
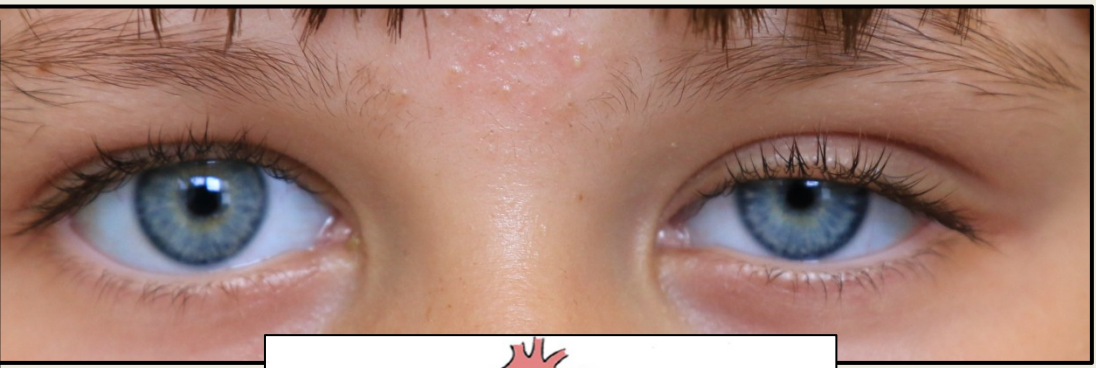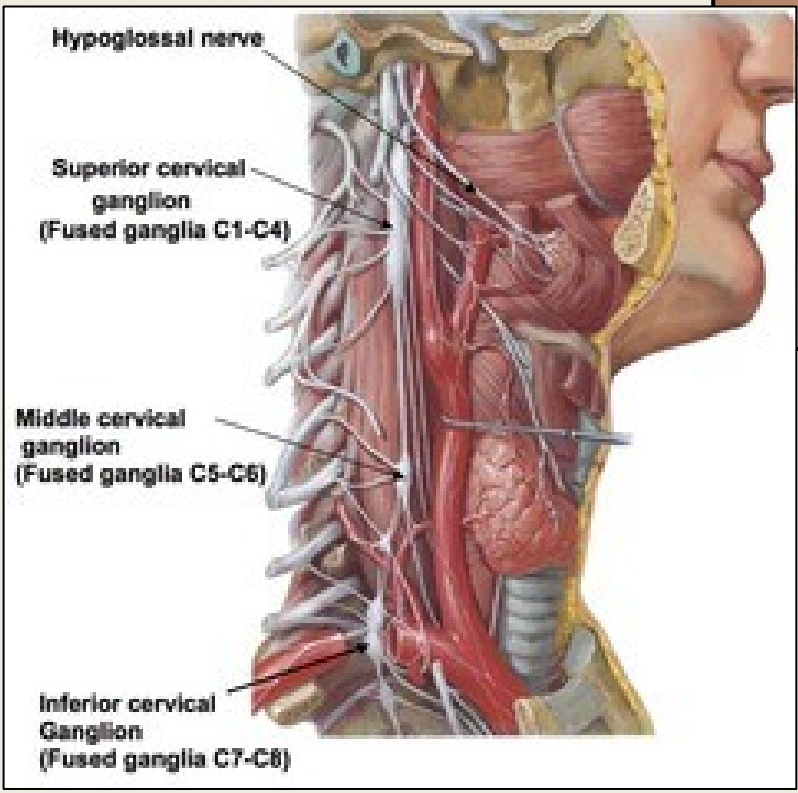
EVEN CHILDREN CAN
HAVE TUMOUR

OFTEN LIFE THREATENING

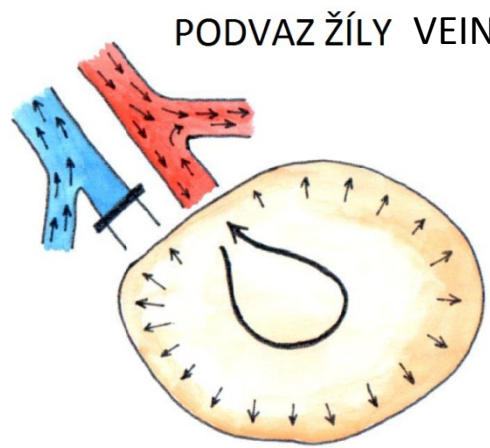
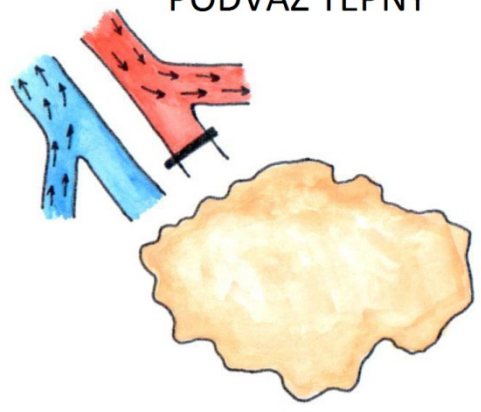
EARLY DIAGNOSIS

IMPROVES PROGNOSIS

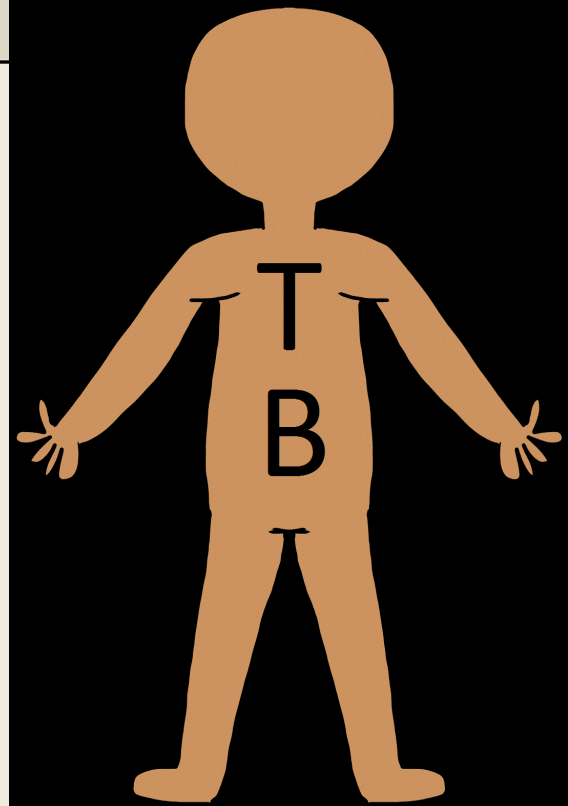
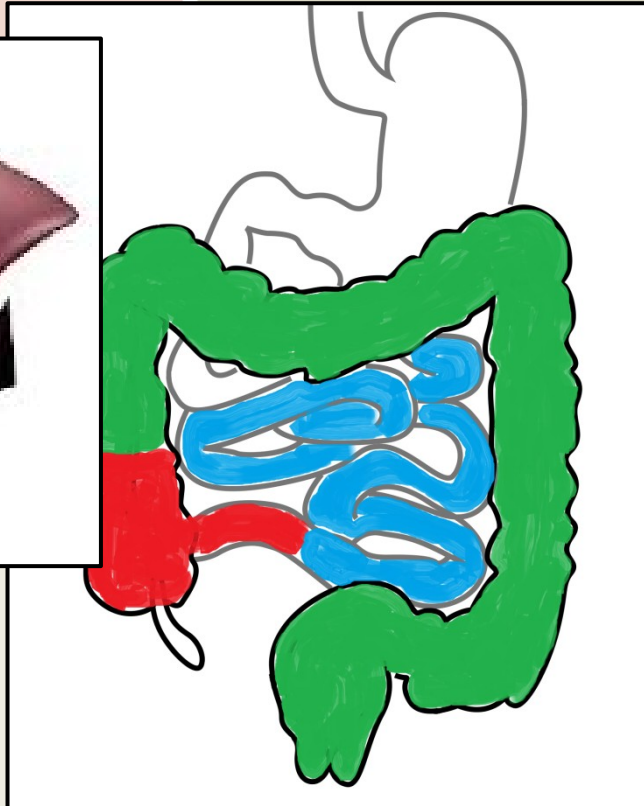
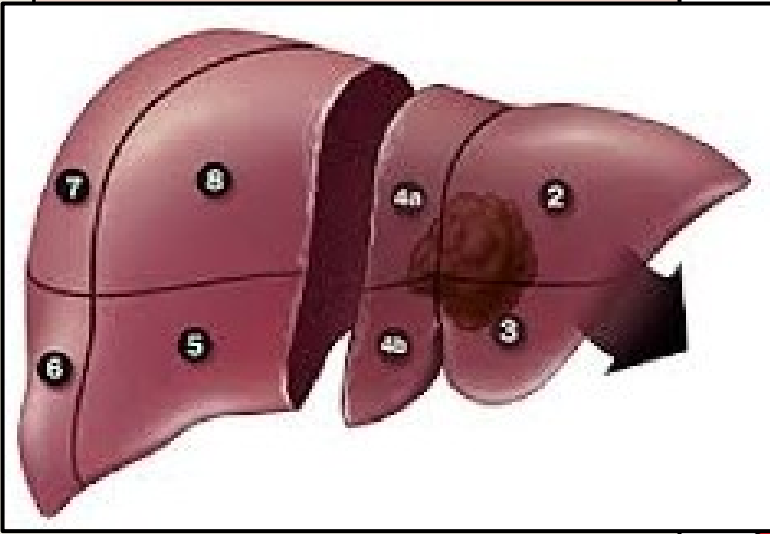
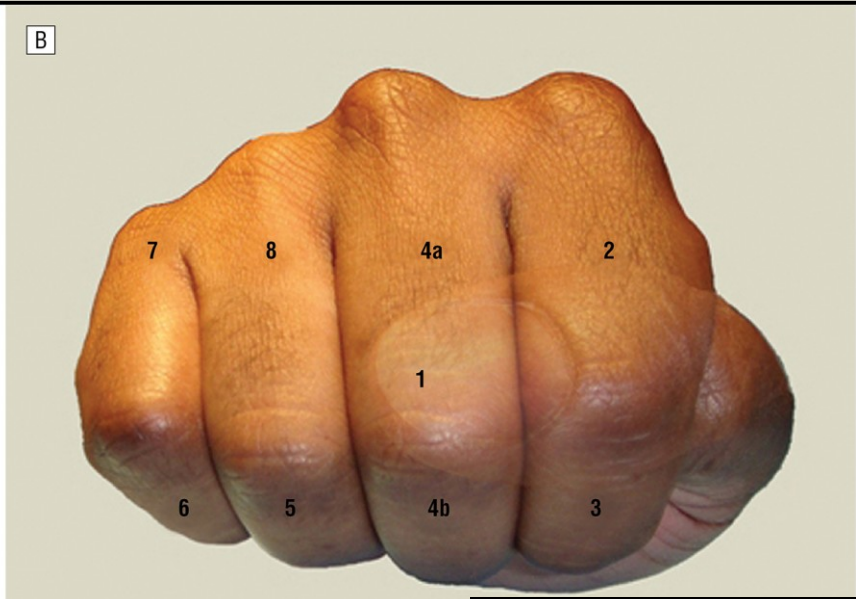
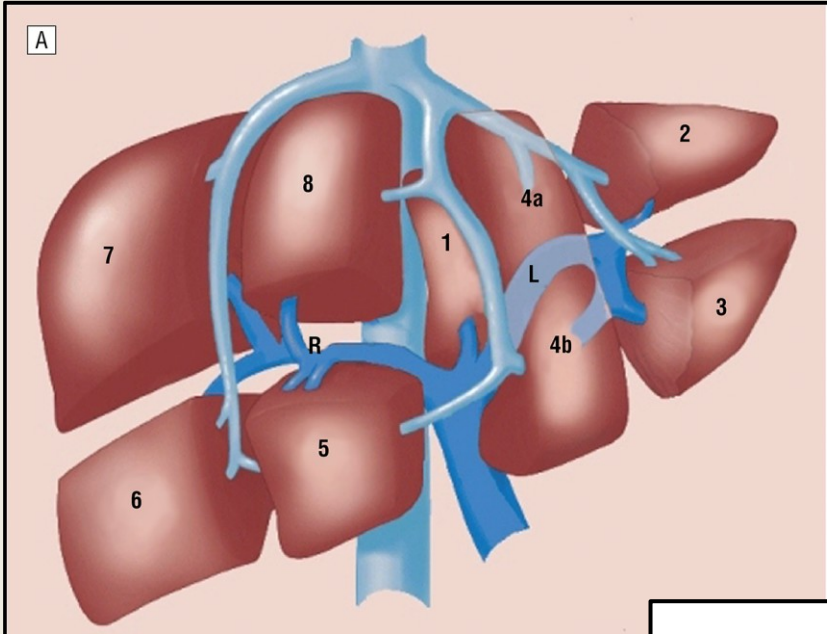




ARTERY LIGATION
PODVAZ TEPNY



PODVAZ ŽÍLY VEIN LIGATION



NEUROBLASTOMA OF ADRENAL GLAND

a boy (2), tire
great resistan

