



# Bacterial skin infections

## 1. **Suppurative** infections – pyoderma



a) affecting free skin

epidermal (impetigo, ecthyma)

dermal (erysipelas, cellulitis)

b) affecting skin appendages

folliculitis


furuncle, carbuncle



## 2) **Other bacterial** infections



# Predisposing factors

- Alteration of the normal skin flora
  - Skin trauma
  - Chronic dermatoses
  - Immunodeficiency
  - Corticosteroid therapy
  - Malnutrition
  - Peripheral vascular disease
  - Systemic disease ( diabetes)
- 



# Causative agents

## • Normal flora:

- St. Epidermidis
- St.saprophyticus
- Micrococcus
- Corynebacterium
- Propionibacterium acnes.

## Common pathogens:

St.aureus  
 $\beta$  hemol.streptoc.  
Escherichia coli  
Proteus mirabilis  
Pseudomonas aerug.

## Uncommon p.:

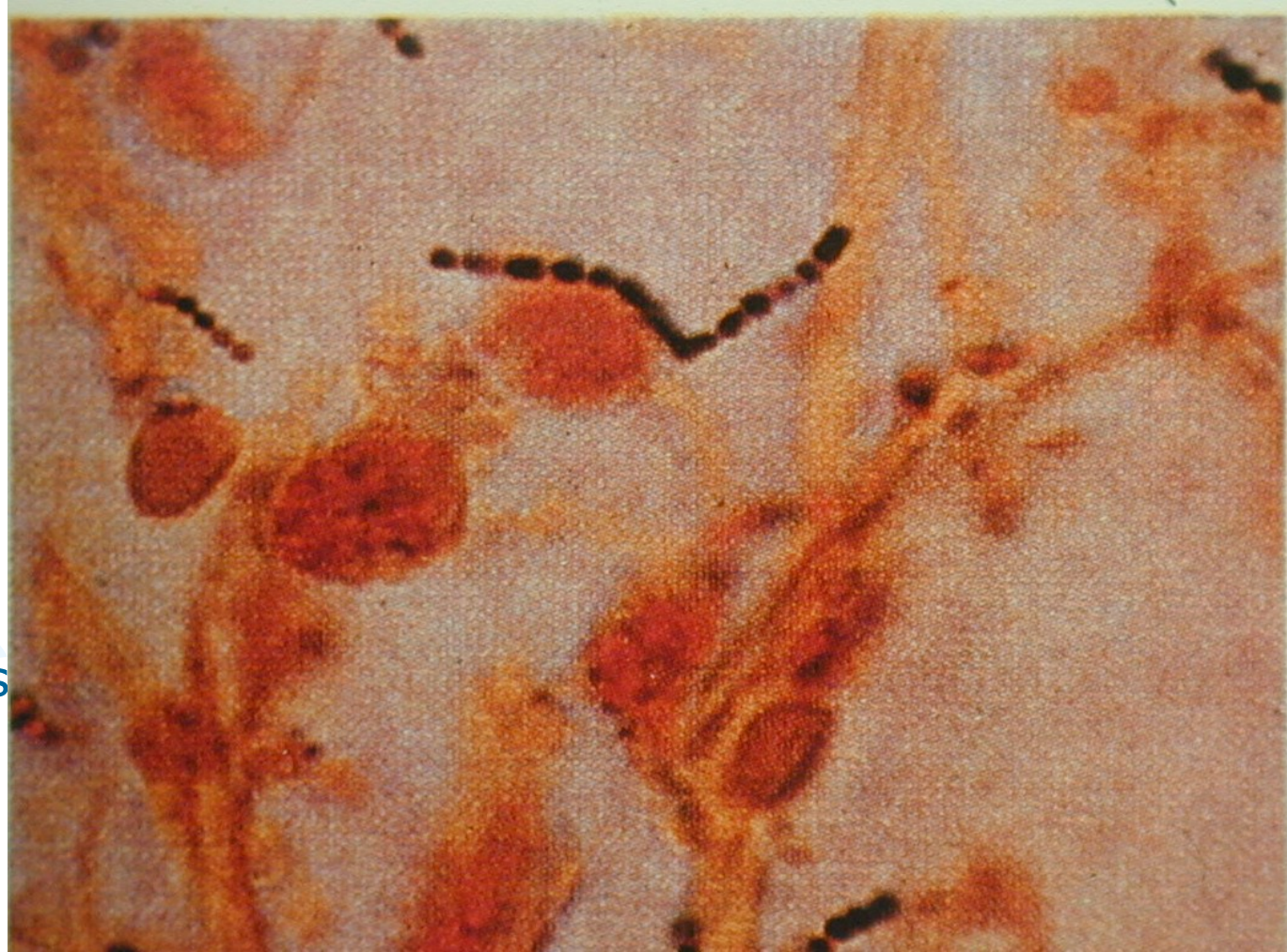
Enterobacter sp.  
Str.faecalis  
Providencia sp.  
Serratia sp.  
Bacteroides  
Clostridium

# Streptococcus pyogenes

- Group ( A-D,G) G+ cocci

- toxins
- DNase
- Strepto  
- kinase

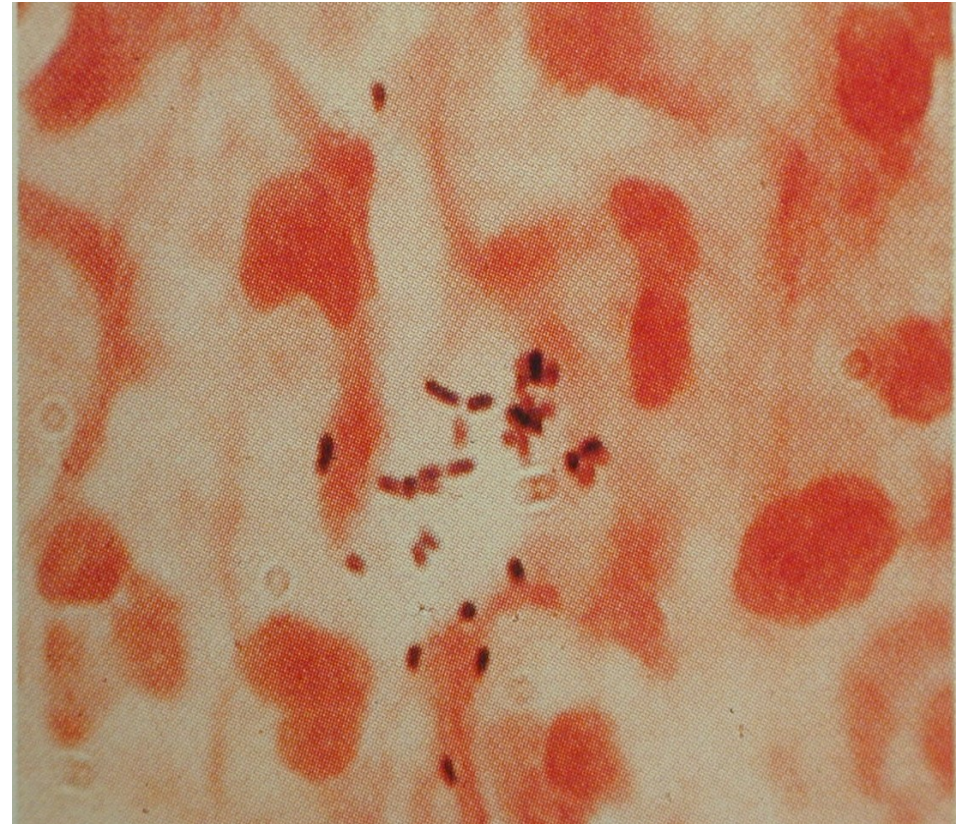
can trigger  
guttate psoriasis



# Staphylococcus aureus

- G+, spherical cocci
- destructive enzymes  
coagulase  
proteases ...
- toxins: TSS toxin  
enterotoxins –  
SEA,SEB

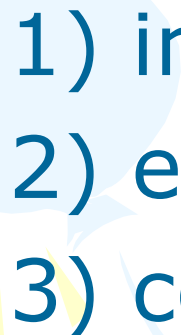
MRSA major problem in  
hospitals





# Pyoderma

A) affecting free skin

- 
- 
- 1) impetigo
  - 2) erysipelas
  - 3) cellulitis
  - 4) necrotising fasciitis
  - 5) chronic ulcerating pyoderma



# Pyoderma

B) affecting skin appendages



1) folliculitis

a) superficial folliculitis

b) folliculitis simplex

c) folliculitis barbae

(sycosis barbae)

d) G- folliculitis



e) non infectious folliculitis



# Pyoderma

2) furuncle/furunculosis

3) carbuncle

4) sweat gland infections

hidradenitis suppurativa

(5) nail fold infections paronychium

(6) eyelid infections – hordeolum

- blepharitis

- chalazion





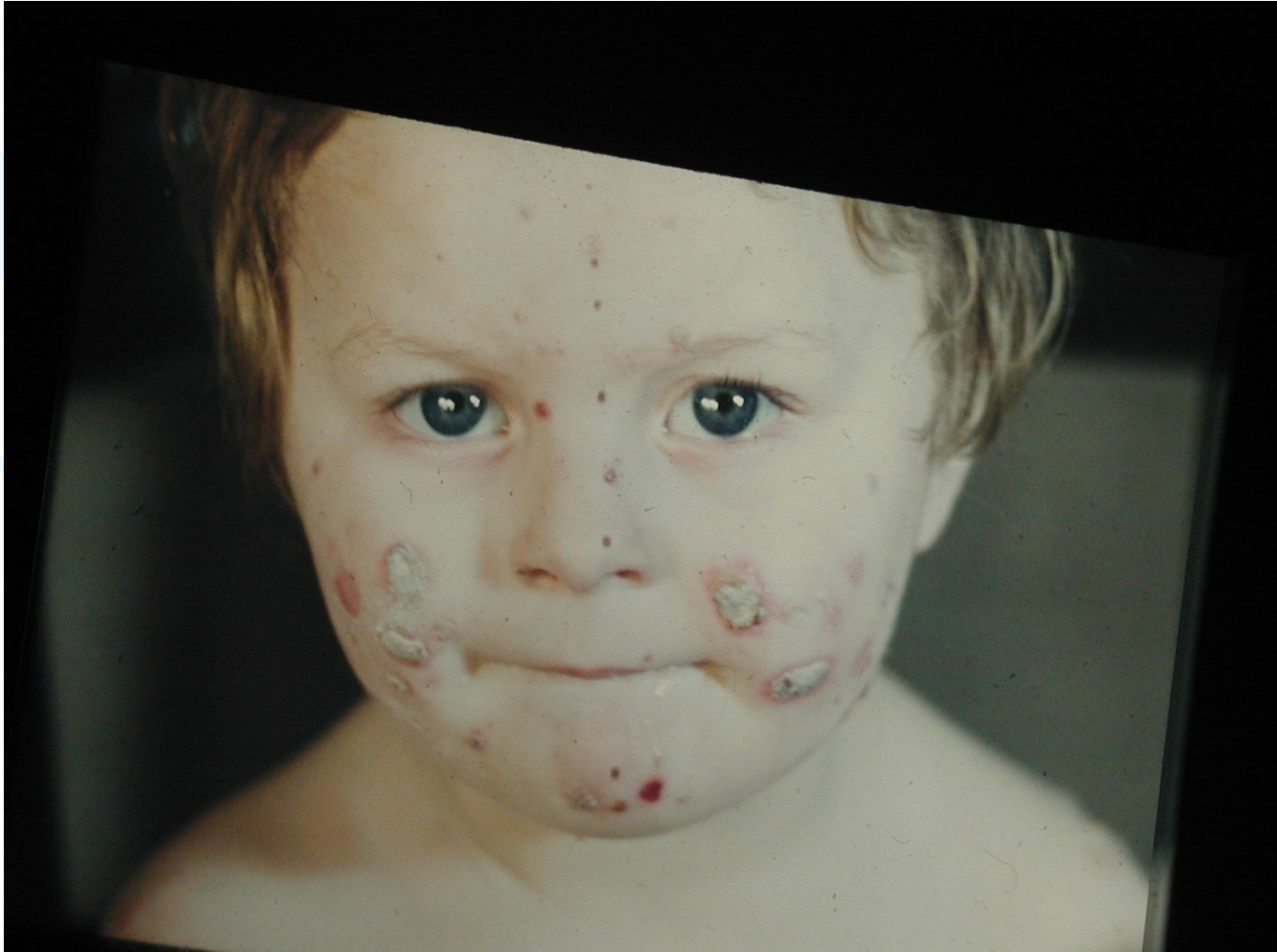# 1) impetigo

- Non bullous: caused by str. pyogenes
- Most common among children
- Transferred by direct contact or subjects
- Clinics: initially small vesicles, easily rupture, erosions covered with honey colored crusts
- Treatment: wet coating, topical ATB: mupirocin, fusidic acid, rapamulin
- Large areas, fever: systemic PNC, CFSP

# impetigo





# impetigo

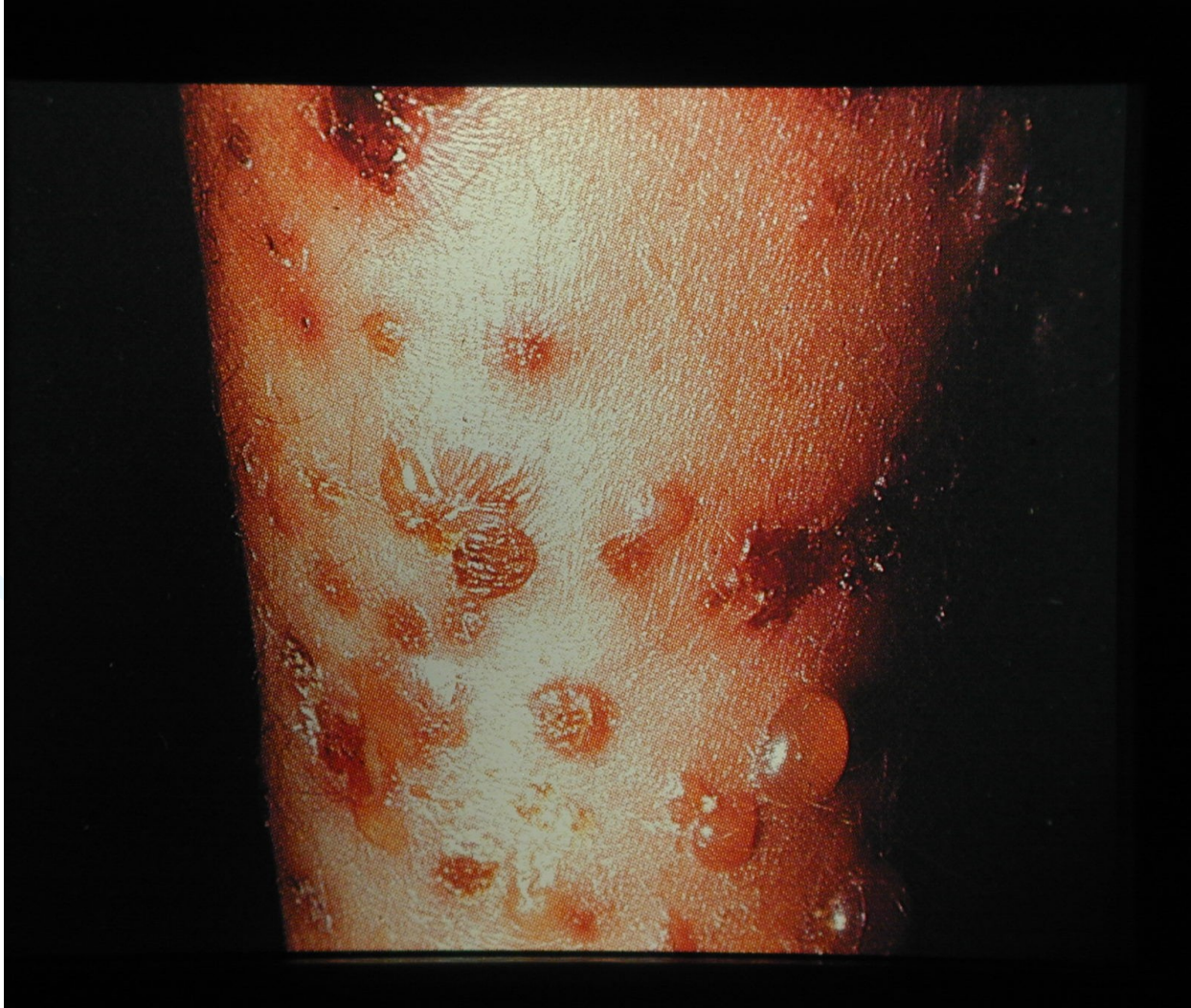



- Bullous impetigo:

- Caused by Staph. aureus producing exfoliatin A & B causing superficial separation in epidermis /str. granulosum/
  - Clinics: flaccid blisters containing pus  
face, groins, acral regions
  - Treatment: topical or systemic ATBs
- 
- 

# Bullous impetigo



# impetiginisation

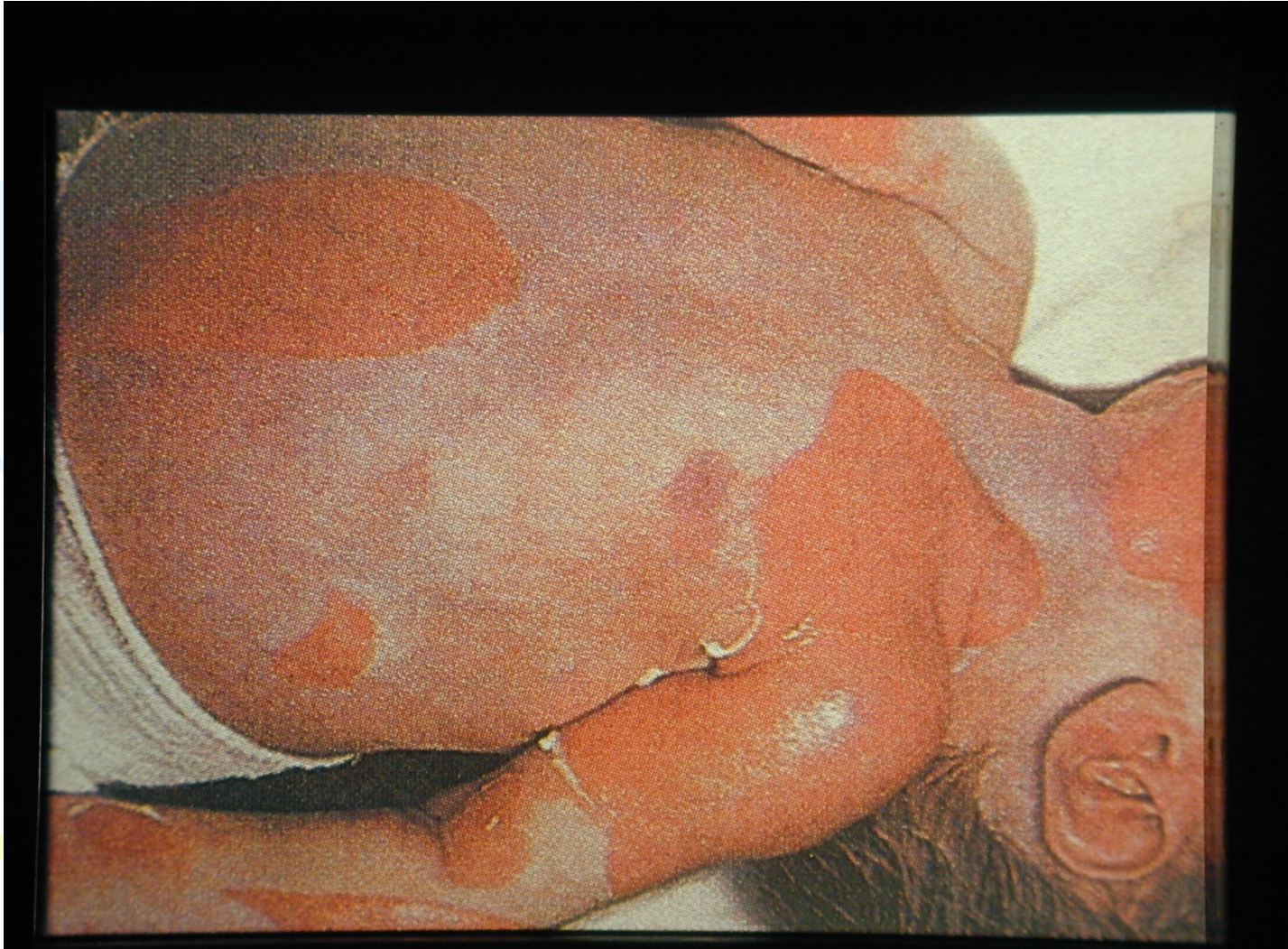




# Staphylococcal scalded skin syndrome (Ritter)

- widespread superficial skin loss caused by staphylococcal exfoliatin
- scarlatiniform rash around mouth, diaper area,
- fever
- flaccid blisters, easily rupture
- Th: ATB, repl. of fluids, temp. control

# Staphylococcal scalded skin syndrome





## 2) erysipelas

- Causative organism: Str. pyogenes ( $\beta$  hemolytic group A streptococci), less often other streptococci
- Entry: minor injury, interdig. fissure, leg ulcers ...
- Clinics: prodromes (fever, chills)

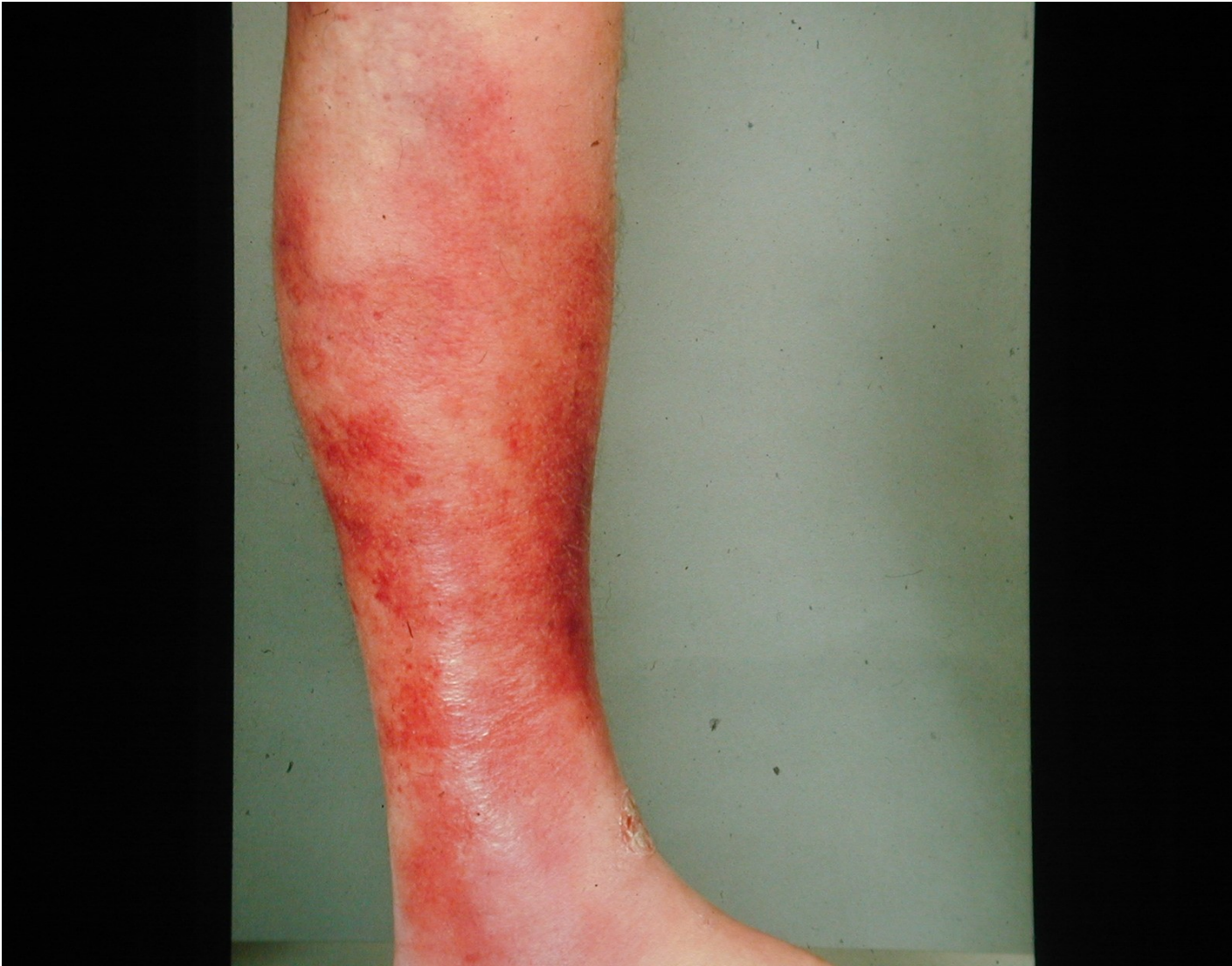warm painful red area with tongue like extensions mostly leg, less often face

Variants: blistering erysipelas, haemorrhagic e., abscessing e., necrotising e.

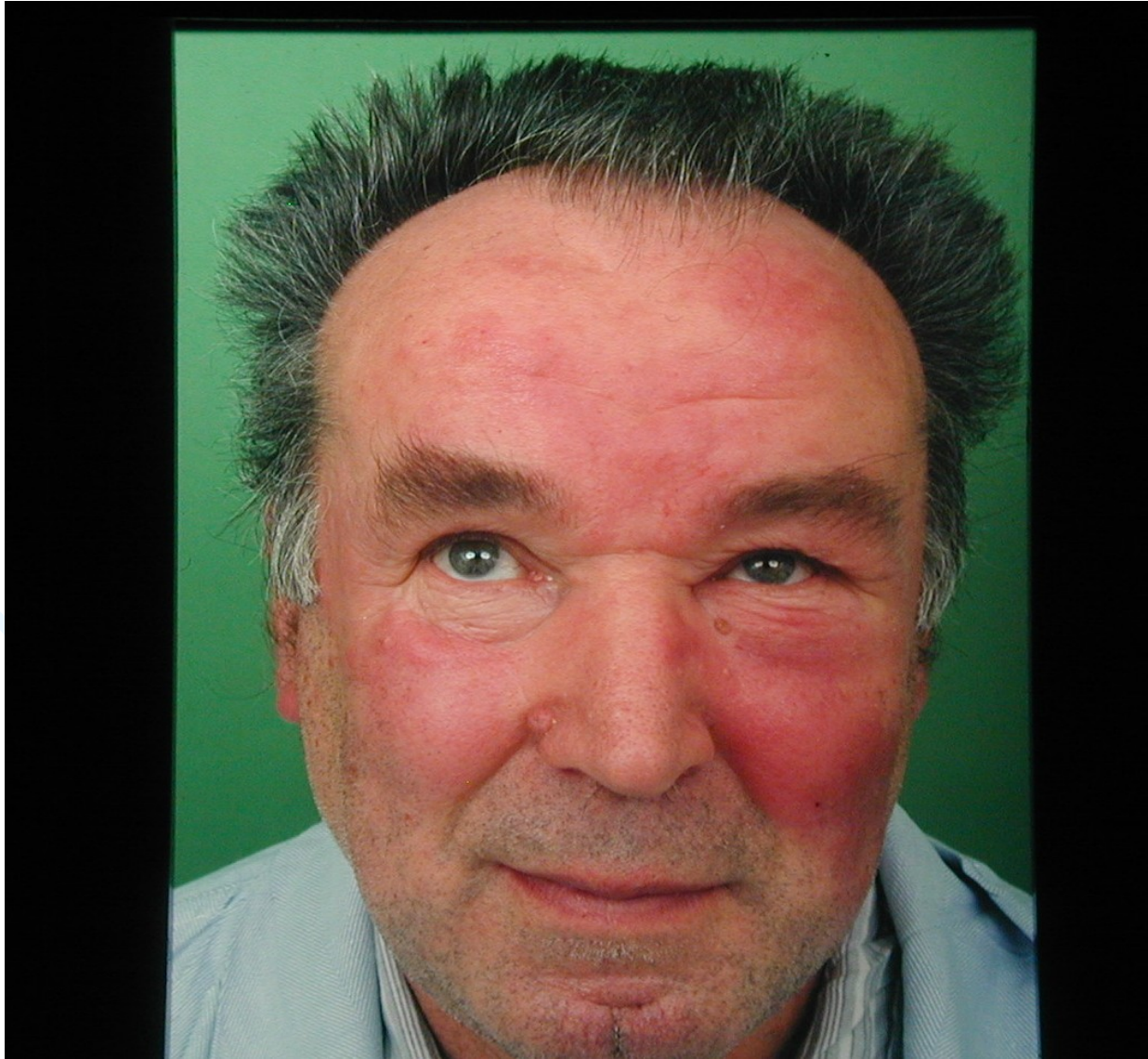Complications: endocarditis, glomerulonephritis

Treatment : procain G PNC i.m. 1,5 mil U 2 x d  
alternatives: cephalosporins, macrolides  
lincomycin

# erysipelas



# erysipelas





## 3) cellulitis

- Agents: Strept. pyogenes, St. aureus
- deeper infection than erysipelas
- After minor injury, surgical wound erythema, with spared regions swelling, pitting edema
- Regional lymphadenitis
- Fever
- Th: PNC, cephalosporins

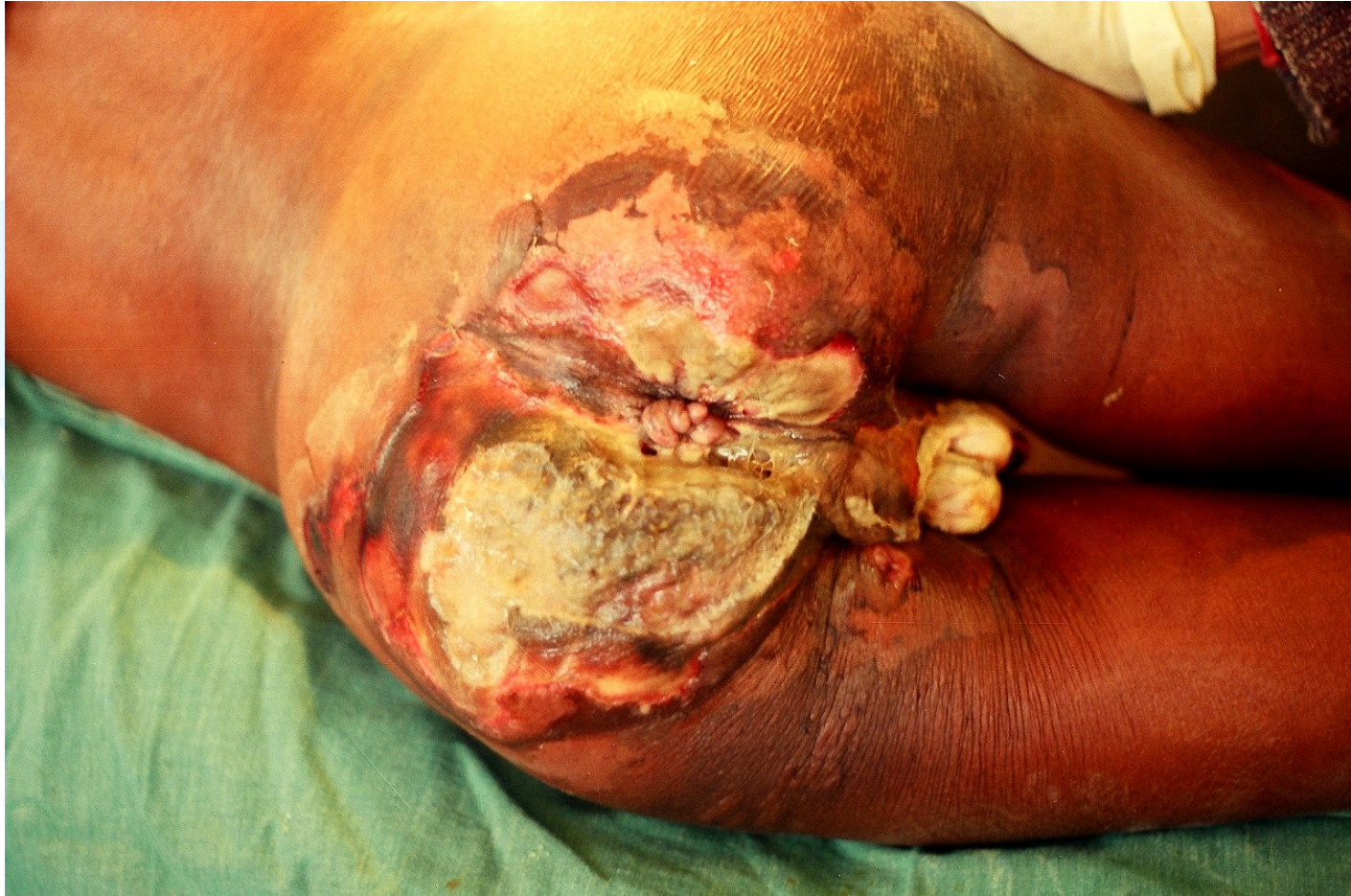# cellulitis



# 4) necrotising fasciitis

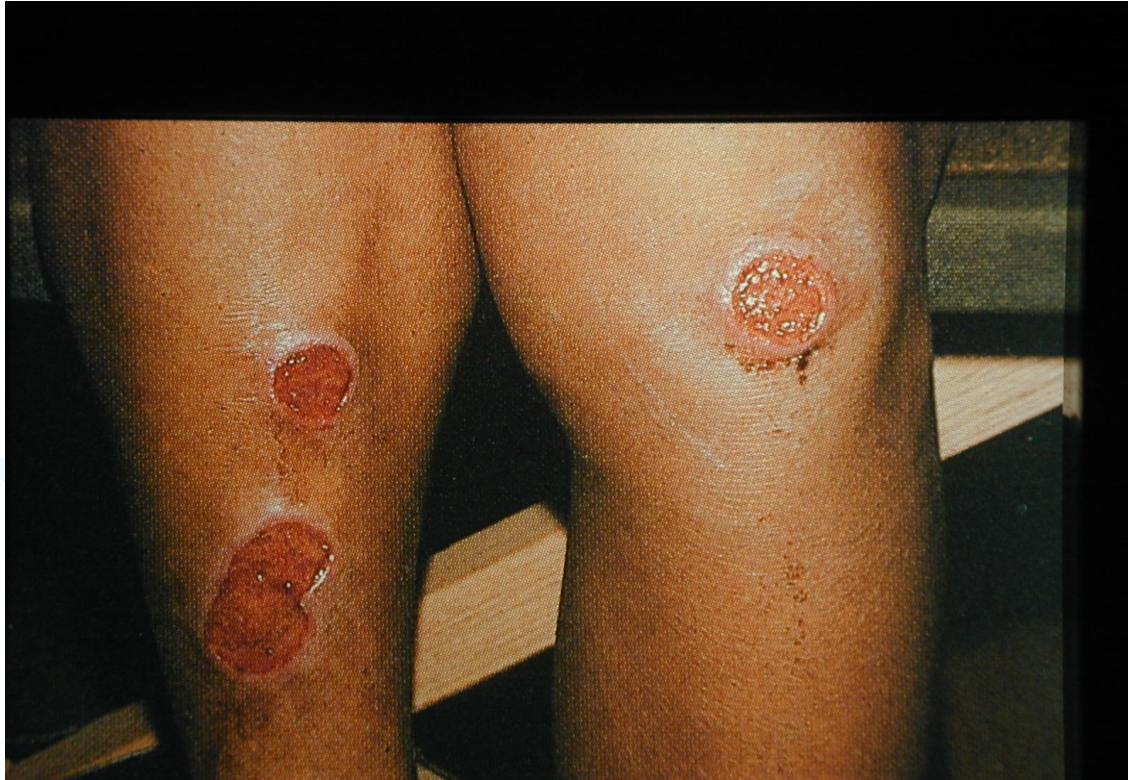- Agents: streptococcus pyogenes
- If more agents: Synergistic necrotising fasciitis/cellulitis
- Older, IS patients
- Erythema --> necrotic eschar
- crepitation
- Fever, extensive pain,
- Th: surgical debridement
- PNC+clindamycin or according to culture, iv Ig ! POOR PROGNOSIS !

# necrotising fasciitis



# 5) chronic ulcerating pyodermas

- Pyoderma ulcerosa, vegetans ...





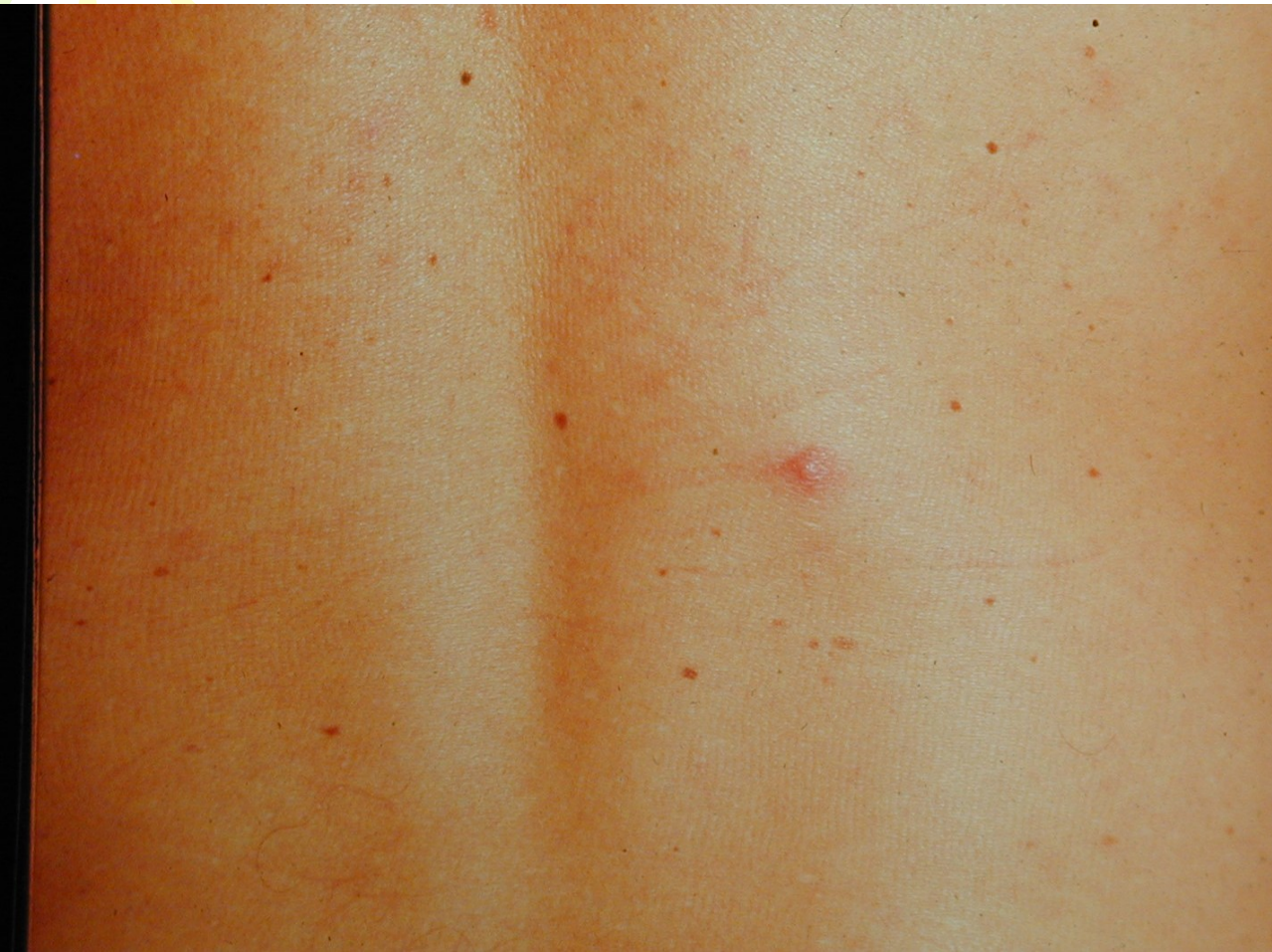# Pyoderma aff. skin appendages: a) superficial folliculitis (ostiofolliculitis)

Superficial  
inflammation  
of the  
hair follicle  
(opening of the  
hair follicle)

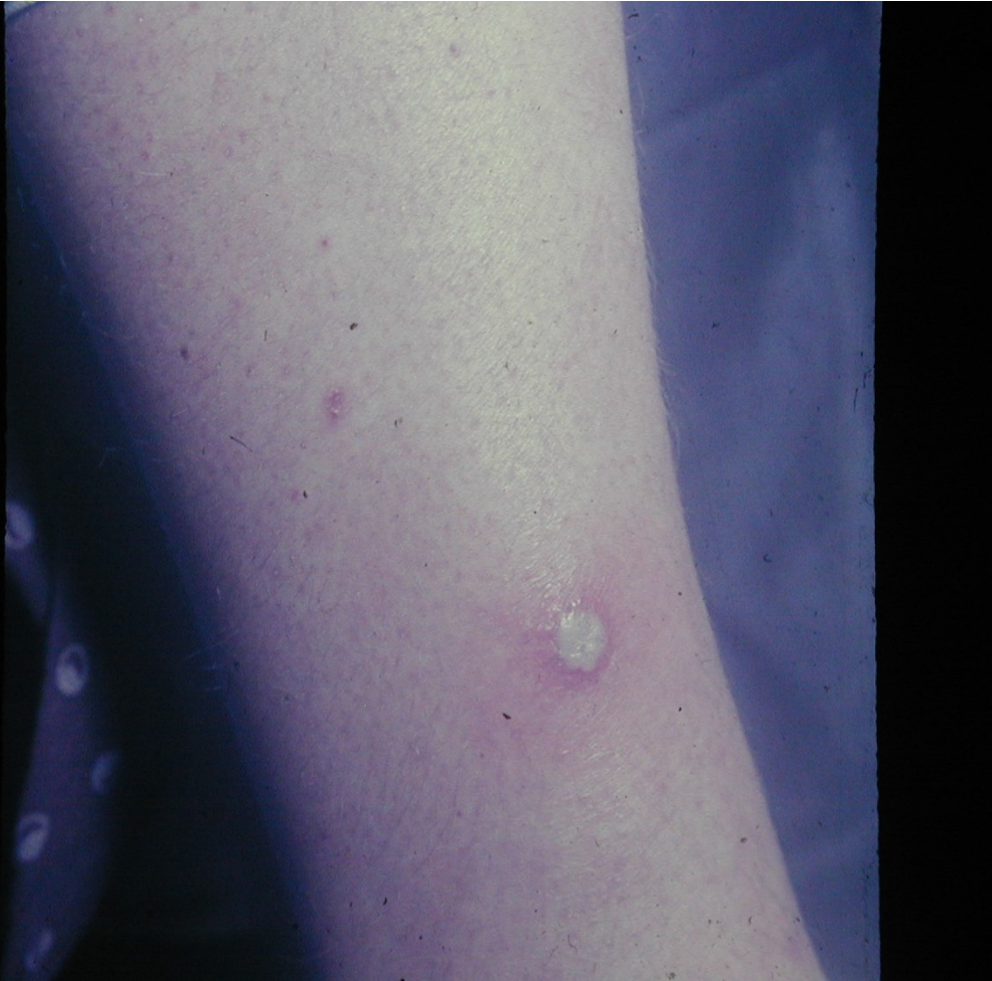Staph. aureus

Triggers: hot and  
humid weather  
sweating

Trt: disinfectant so  
topical ATB: Ery,  
clindamycin



## b) folliculitis simplex



inflammation  
of the whole  
hair follicle

Typical locations:

Back, buttocks

Scalp, axillae

Itching

Trt: disinfectant sol

topical ATB: Ery,

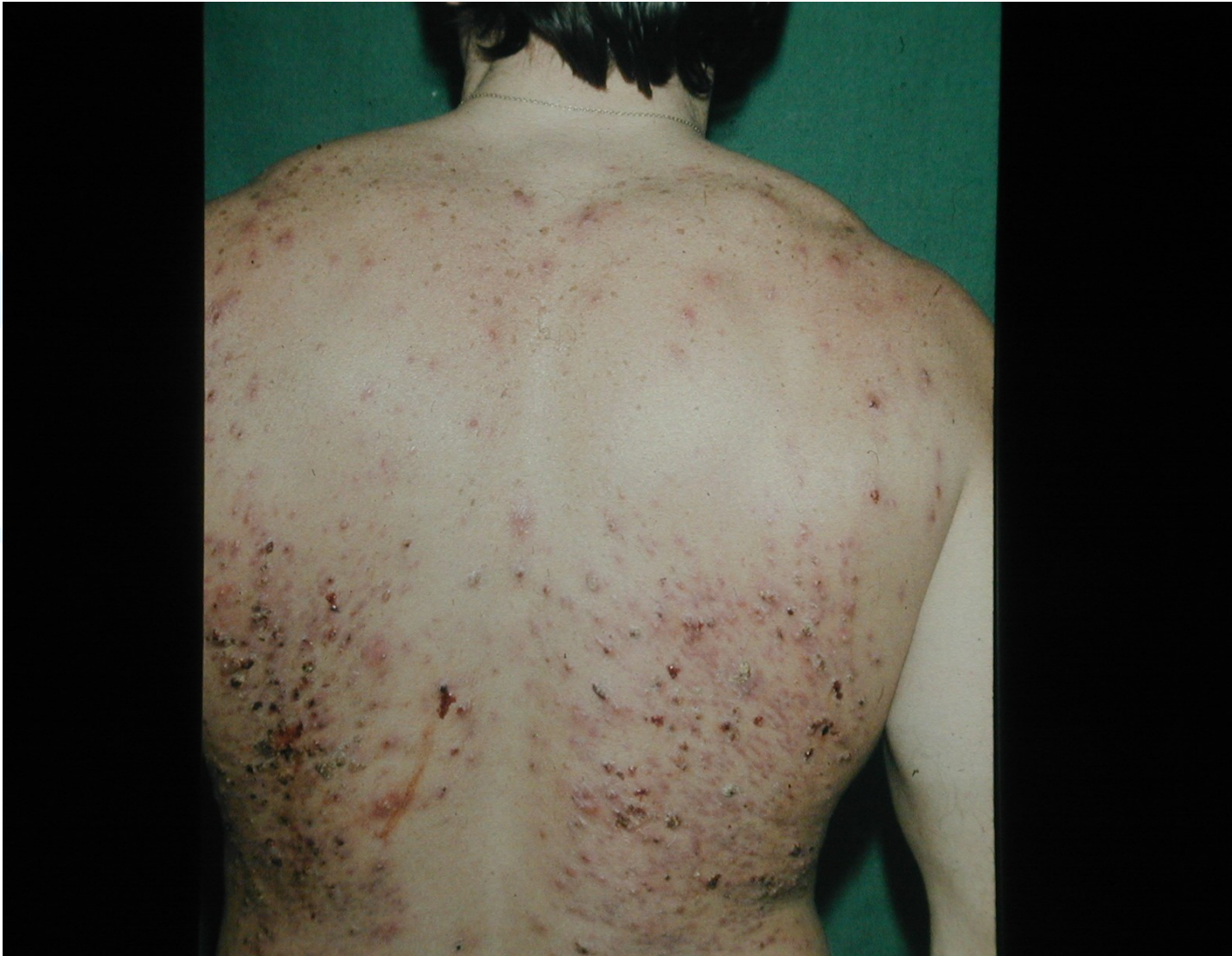Clindamycin

Large areas, fever:

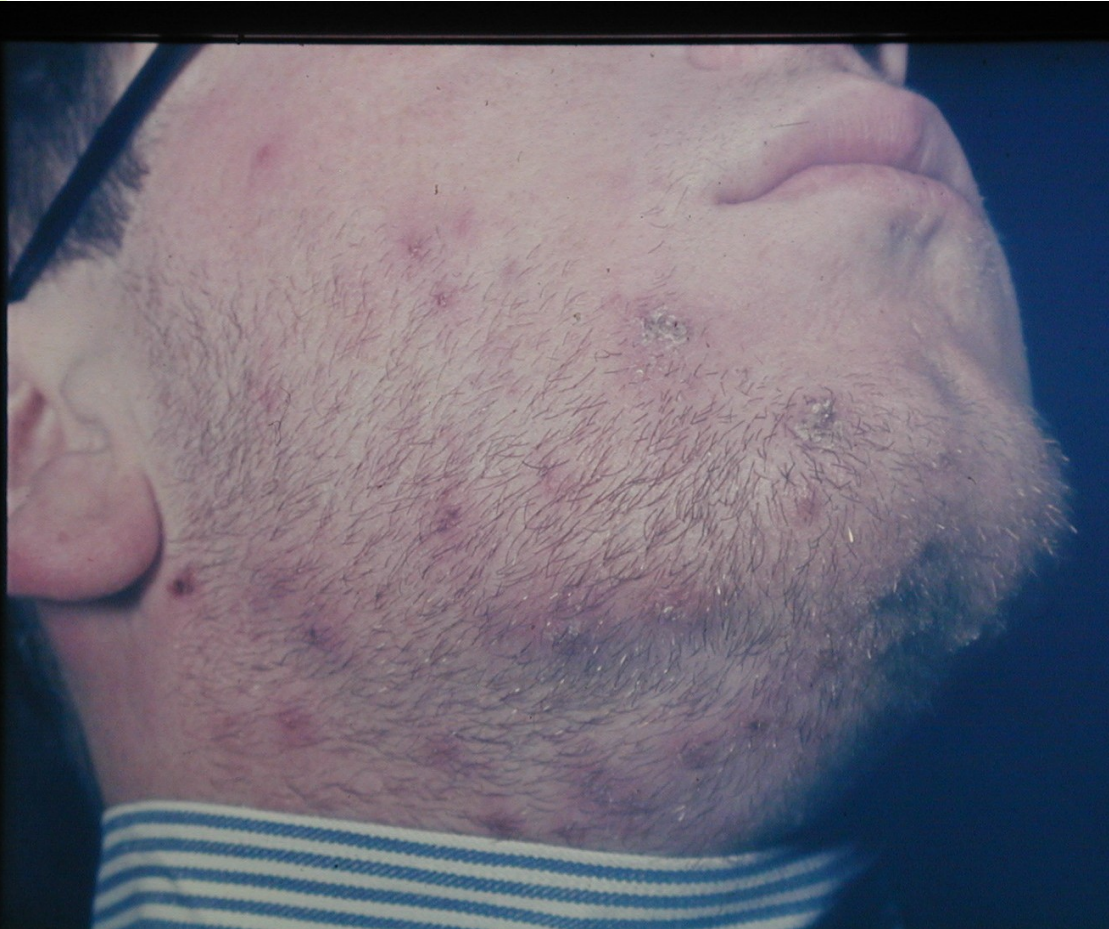Systemic ATB:

PNC, CFSP

# folliculitis simplex disseminata



## c) folliculitis barbae (sycosis barbae)



Most common variant  
of ordinary folliculitis  
Pustules  
Nodules, abscesses  
Involving beard region  
and sides of the neck  
Starts with minor trauma  
Spreads by shaving  
Trt: disinfectant sol  
topical ATB: Ery,  
Clindamycin  
Large areas, fever:  
Systemic ATB: PNC, CFSP

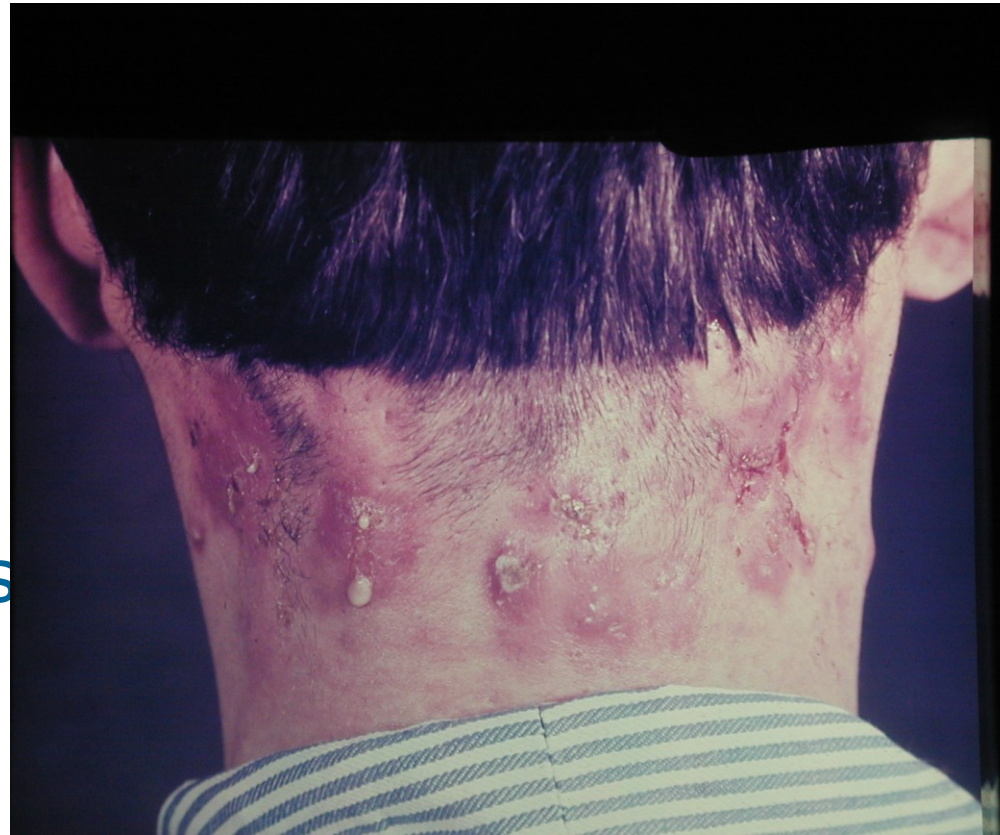

## d) G- folliculitis

- Chronic recurrent folliculitis of the mid-face region
- Caused by G-bacteria
- Enterobacter, E.coli, Klebsiella
- Complication of acne, rosacea
- Th: quinolones: ciprofloxacin  
+ isotretinoin

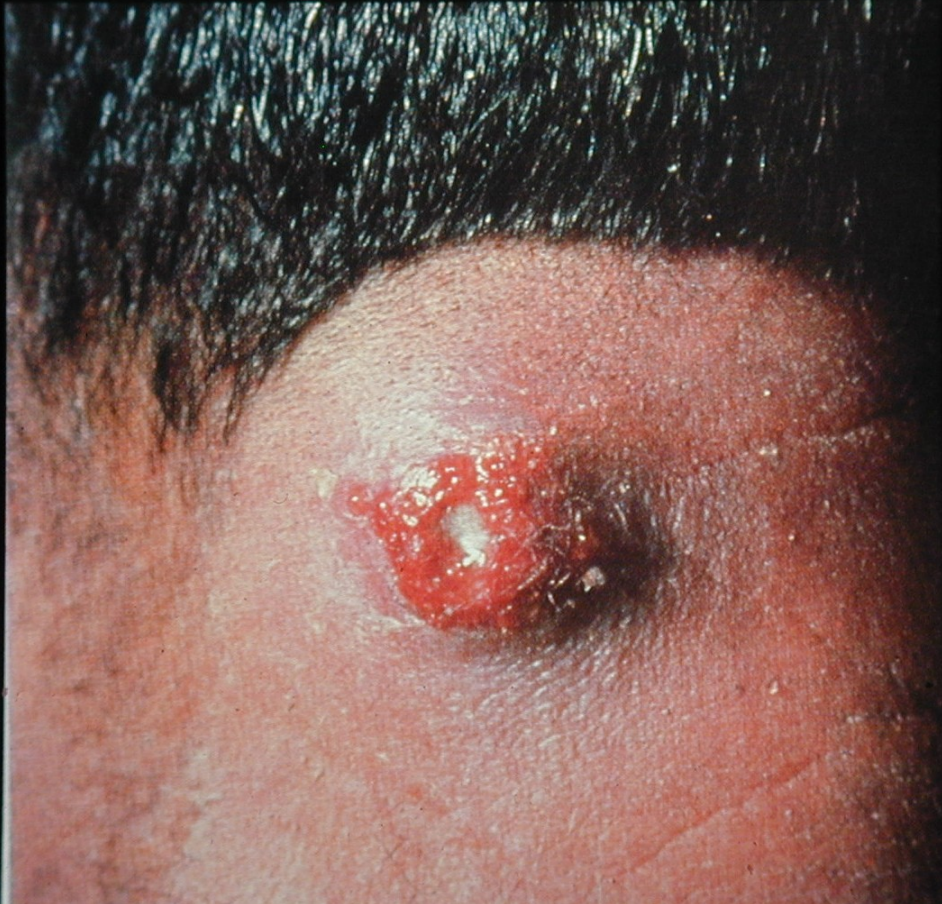## e) non infectious folliculitis

- Folliculitis decalvans
- Perifolliculitis capitis abscondens et suffodiens



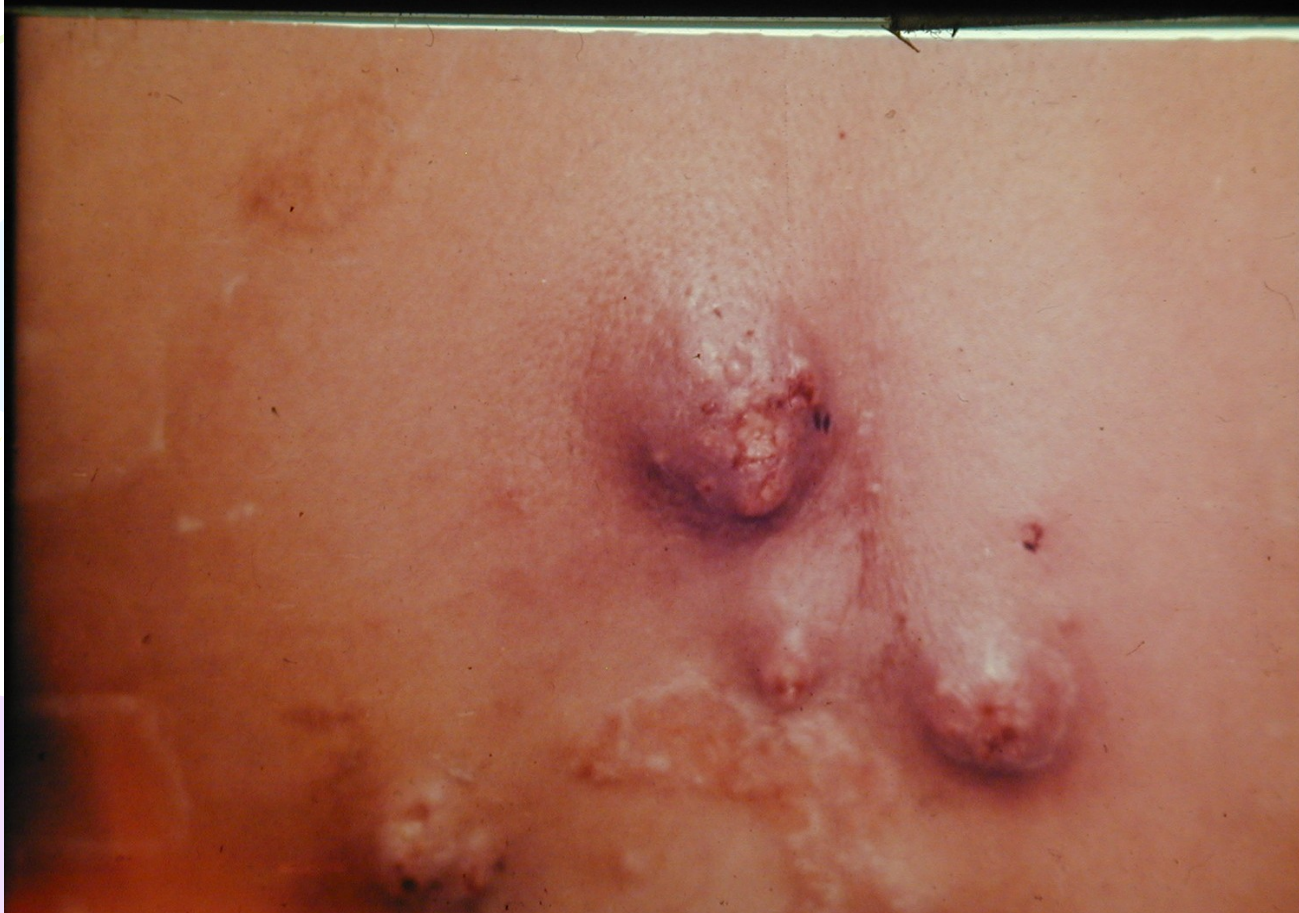

# Furuncle (boil)



Deep inflammatory nodule  
with central pus  
Develops from hair follicle  
infection  
Causative agent: St. Aureus  
Poor hygiene, diabetes,  
immunosuppression  
Areas of friction  
Clinics: pustule -->  
nodule, central plug  
--> discharge of pus  
Healing with scar  
Trt: top. drawing ointments  
(ichtamol – saloxyl ung.)  
topical ATB: mup., fusidic a.  
Systemic ATB: PNC, CFSP  
Surgery: incision

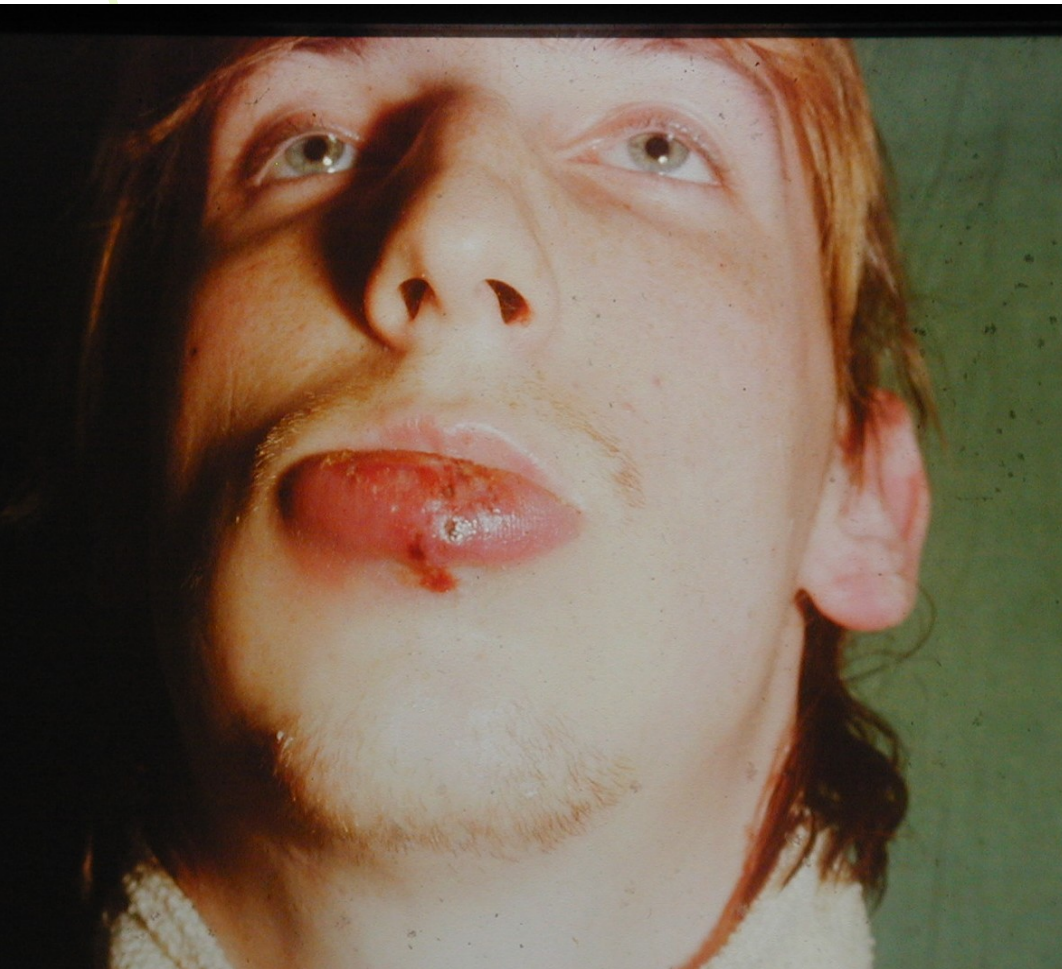# Furunculosis



Multiple recurrent boils  
Predisposing factors: DM  
poor hygiene, immunosuppression  
Atopic dermatitis  
nasal or perianal carriage of *St. aureus*

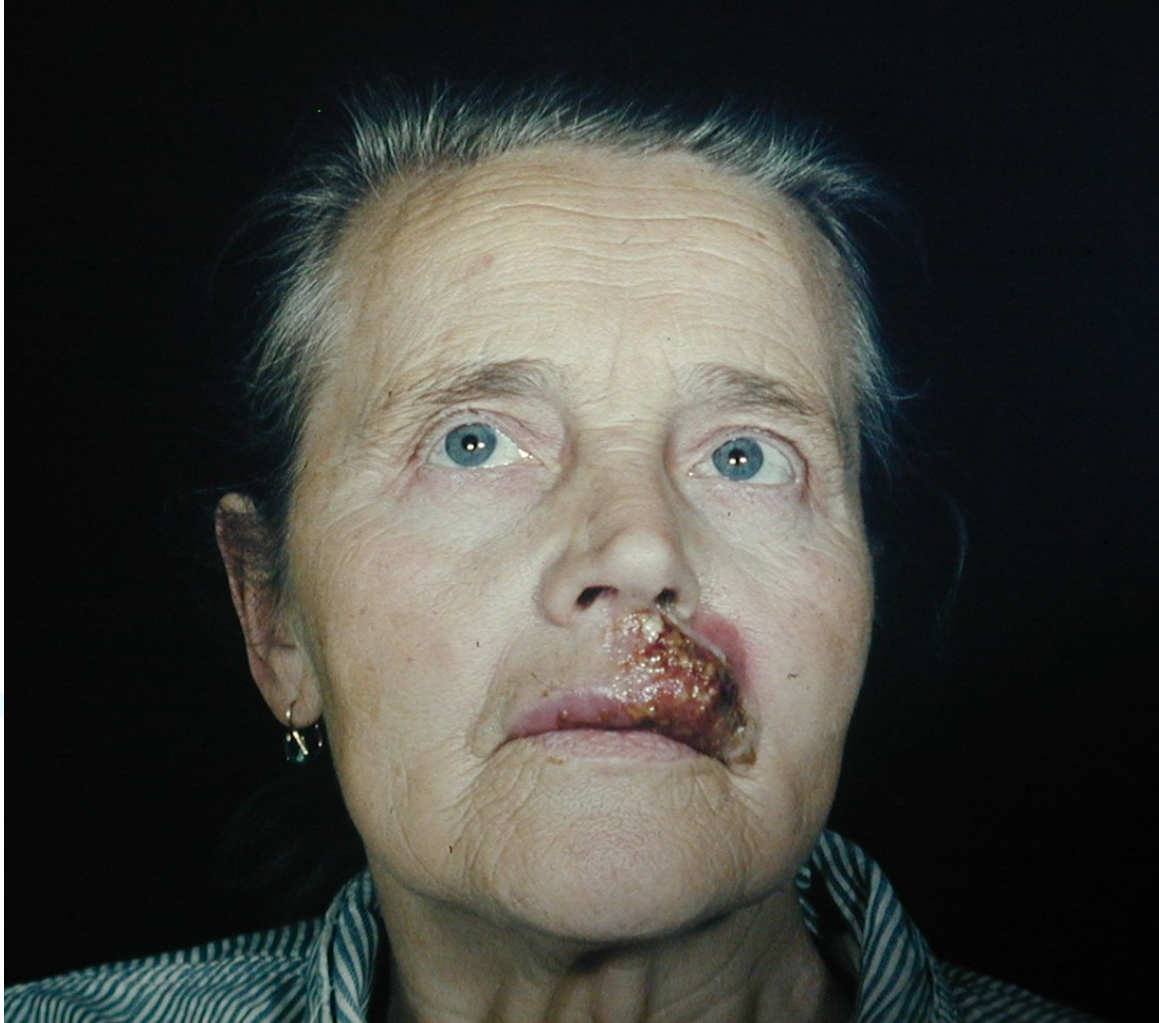

# Carbuncle



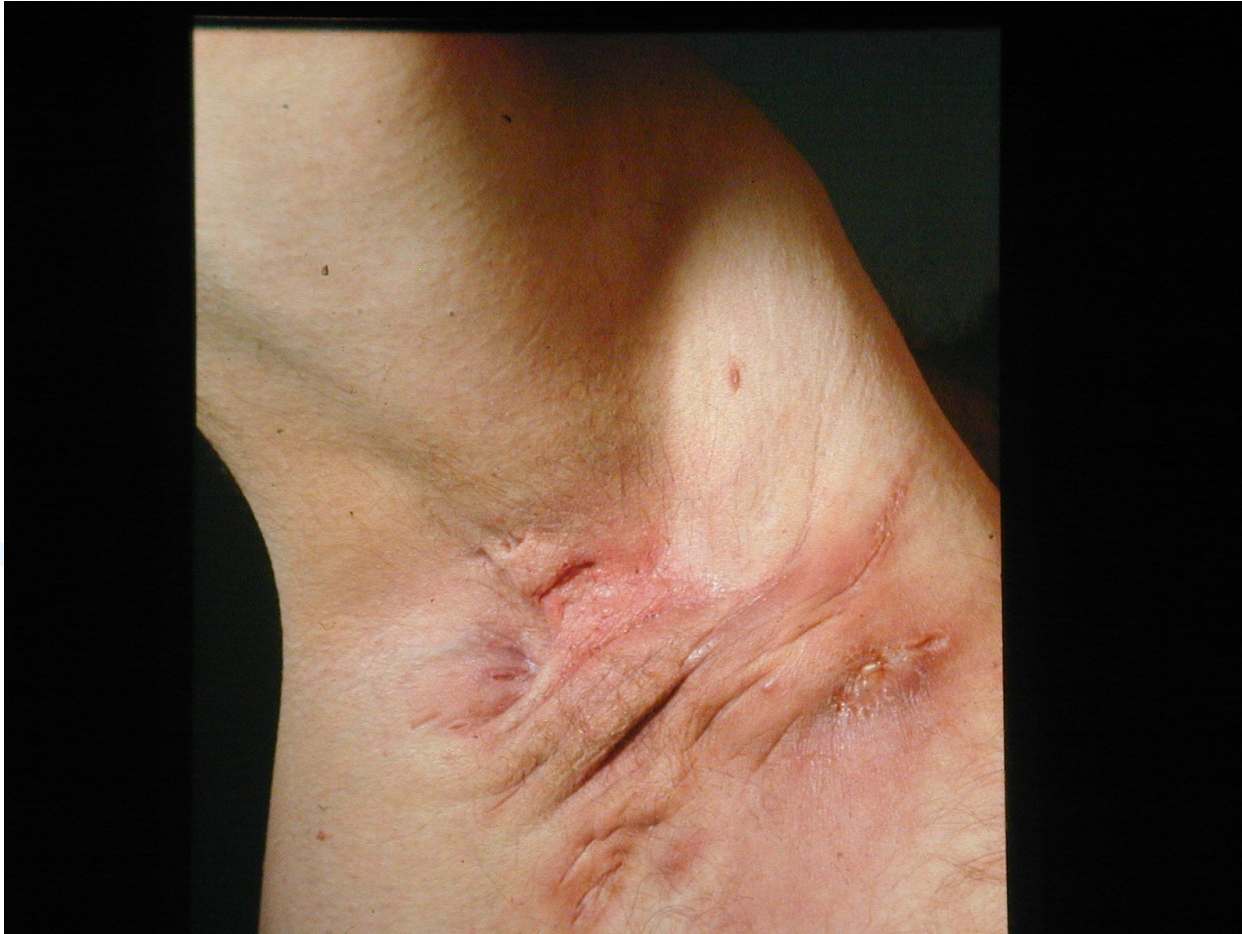Fusion of several boils  
Most common on the  
neck and trunk  
Inflamed swollen area  
Often with necrosis  
Treatment: systemic ATB  
surgery

# Carbuncle



# sweat gland infections

- hidradenitis suppurativa



# (5) nail fold infections - paronychia

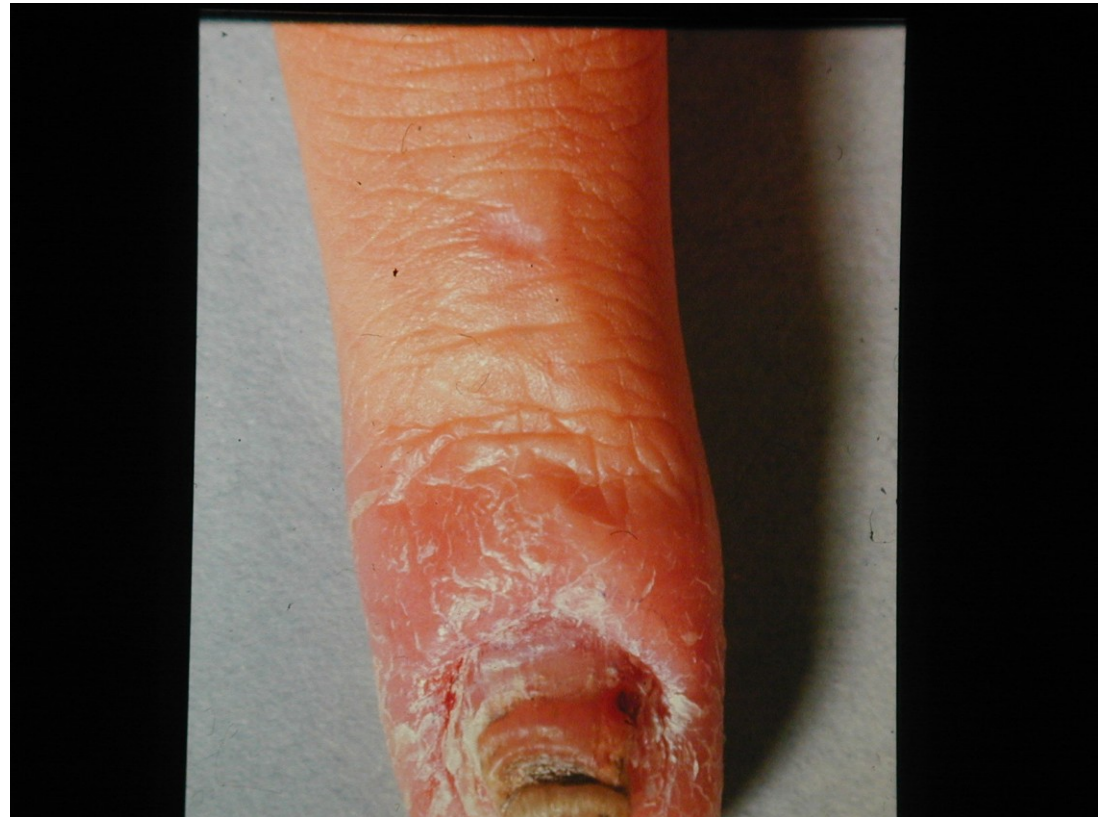Minor trauma of cuticle

St.aureus

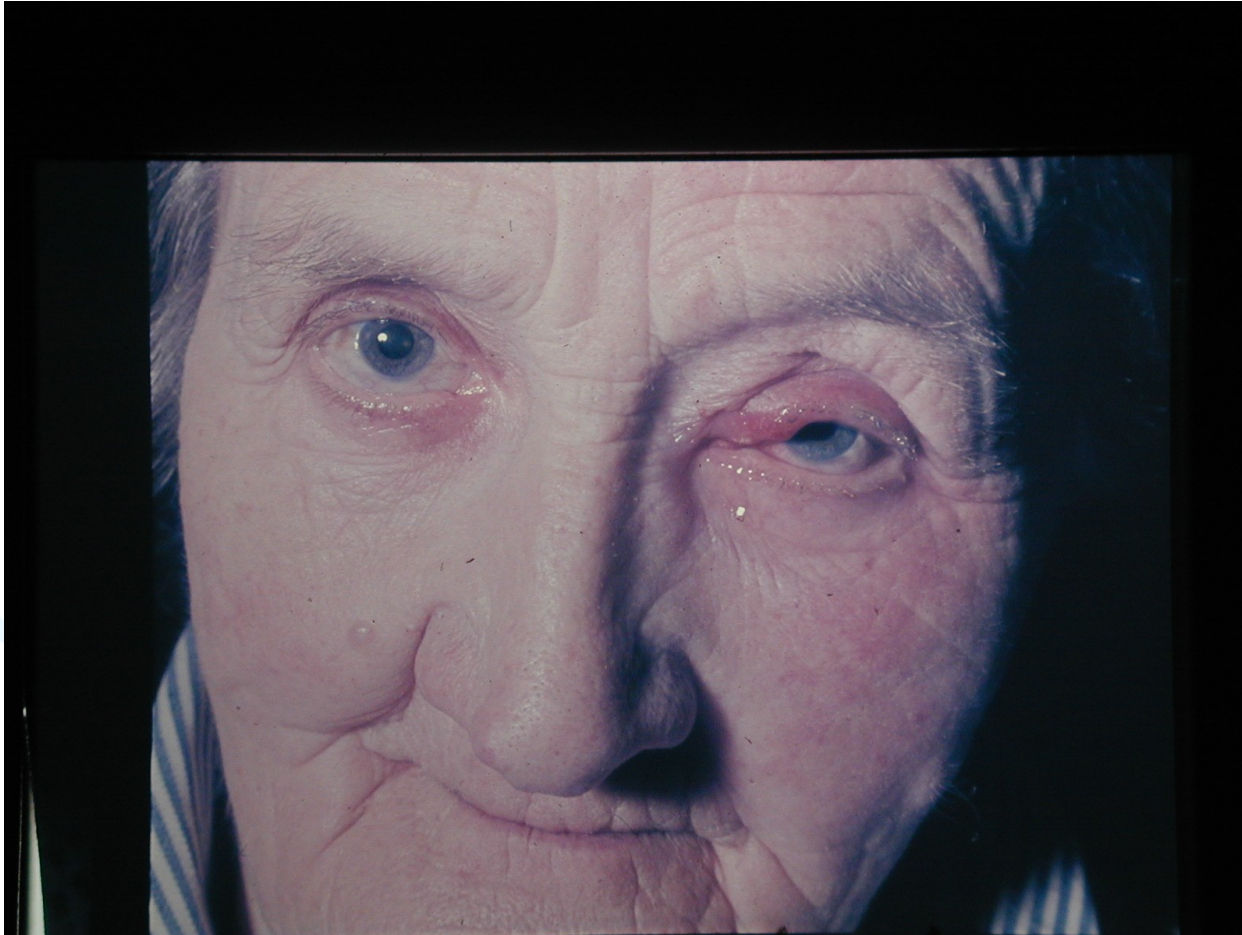Purulent secretion  
from the nail fold

Ddg: candidal paron.  
herpetic whitlow

Th: drainage  
topical ATB



## (6) eyelid infections –



## 2. Other bacterial infections

- Cutaneous diphtheria - *rare*
- Listeriosis - *rare*
- Actinomycosis
- Nocardiosis - *mostly in immunosuppressed pat.*
- Cat scratch disease (bartonella)
- Clostridial infections
- Zoonoses –  
erysipeloid, anthrax, tularemia

# Actinomycosis

Causative organism:

G+ anaerobic bacteria

*Actinomyces israelii*

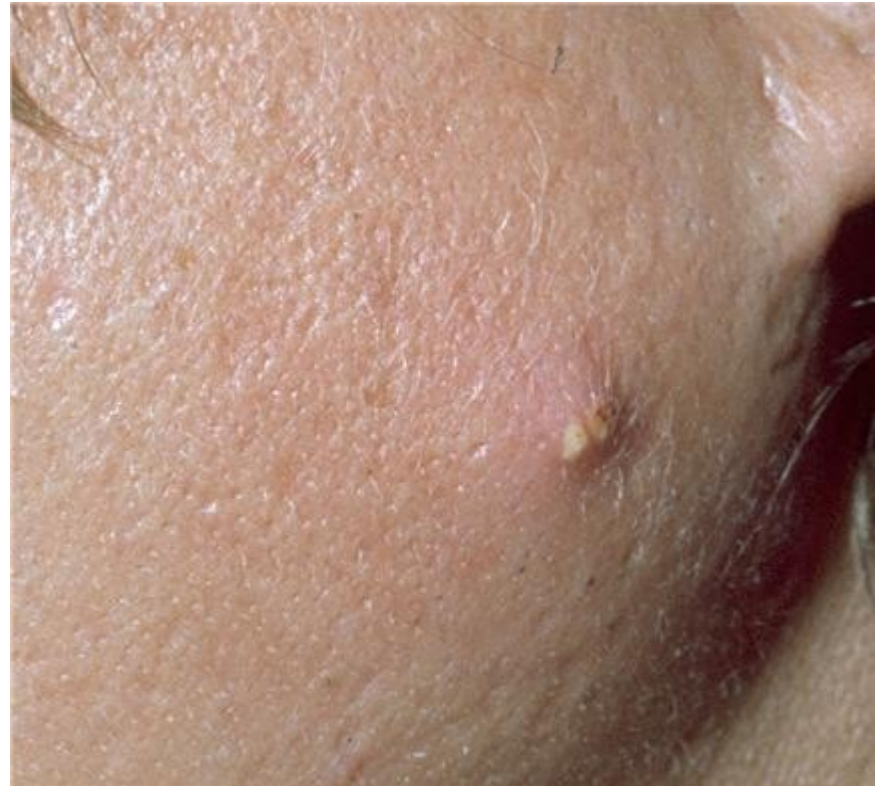Clinical types:

**CERVICOFACIAL ACTINOMYCOSIS**

the commonest form, initially a red indurated nodule on the cheek or submaxillary region.

Multiple sinuses, scarring and the formation of new nodules produce an uneven lumpy surface. Fistulas or even small ulcerations arise.

Characteristic sulphur granules may be found in the discharging pus.

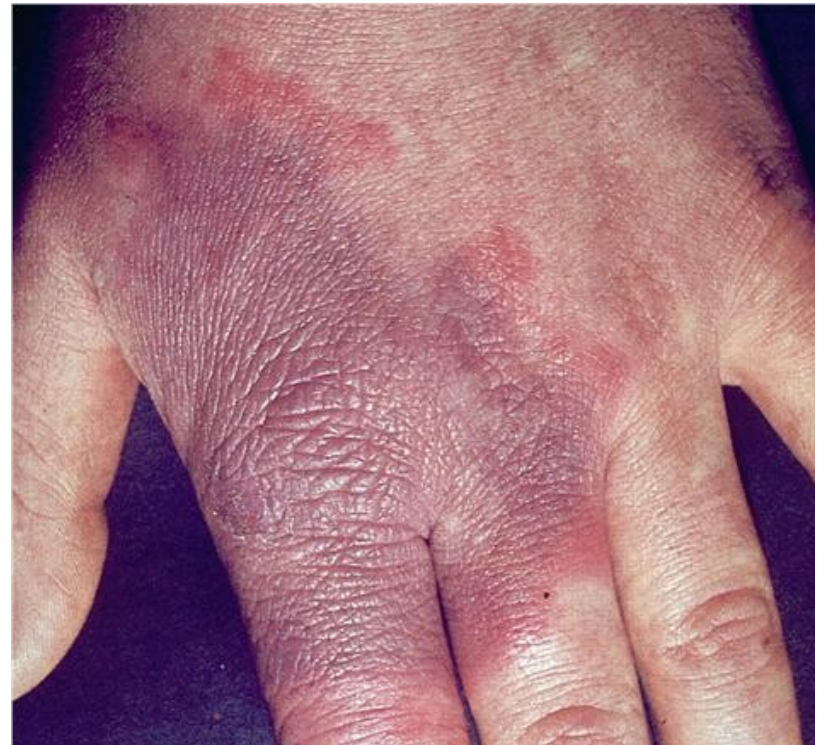

**THORACIC ACTINOMYCOSIS**

and **ABDOMINAL ACTINOMYCOSIS** cause general symptoms such as fever, chills, night sweats and weight loss TH: PNC, lincomycin

# Erysipeloid

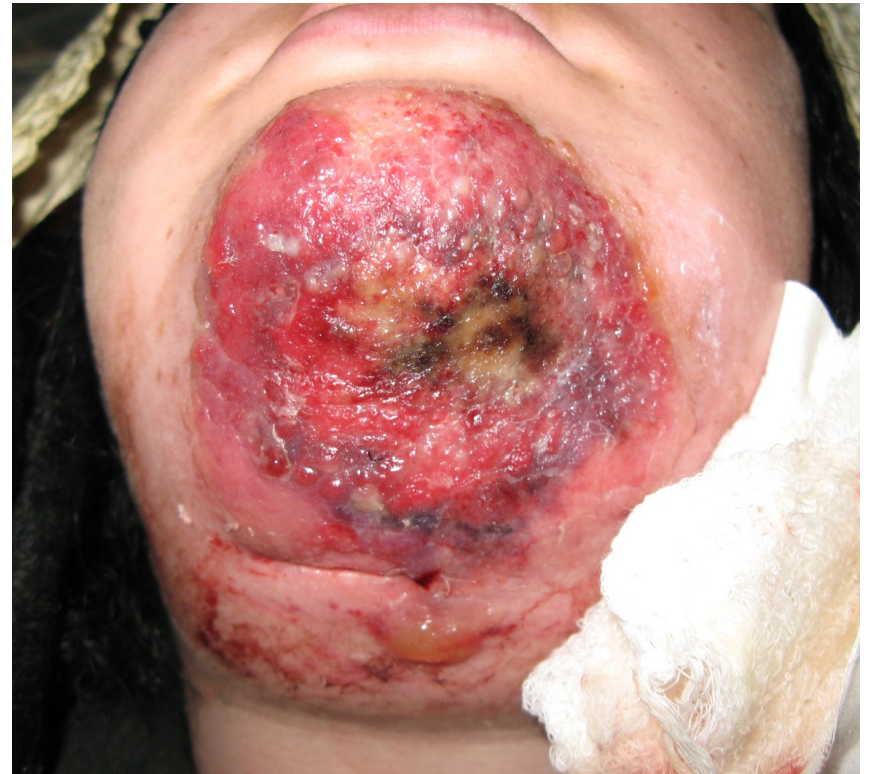- Causative agent: *Erysipelothrix rhusiopathiae*
- persons who in their occupation handle infected fish, shellfish, poultry, or meat.
- Three forms of this condition exist:
  - a mild localized form manifested by local swelling and redness of the skin;
  - a diffuse form that might present with fever;
  - and a rare systemic form associated with endocarditis
- Th: PNC





# Anthrax

- woolsorter's disease,
- gram positive *Bacillus Anthracis*
- exposure to infected animals or handling of hides or other animal products
- Th: PNC, TTC



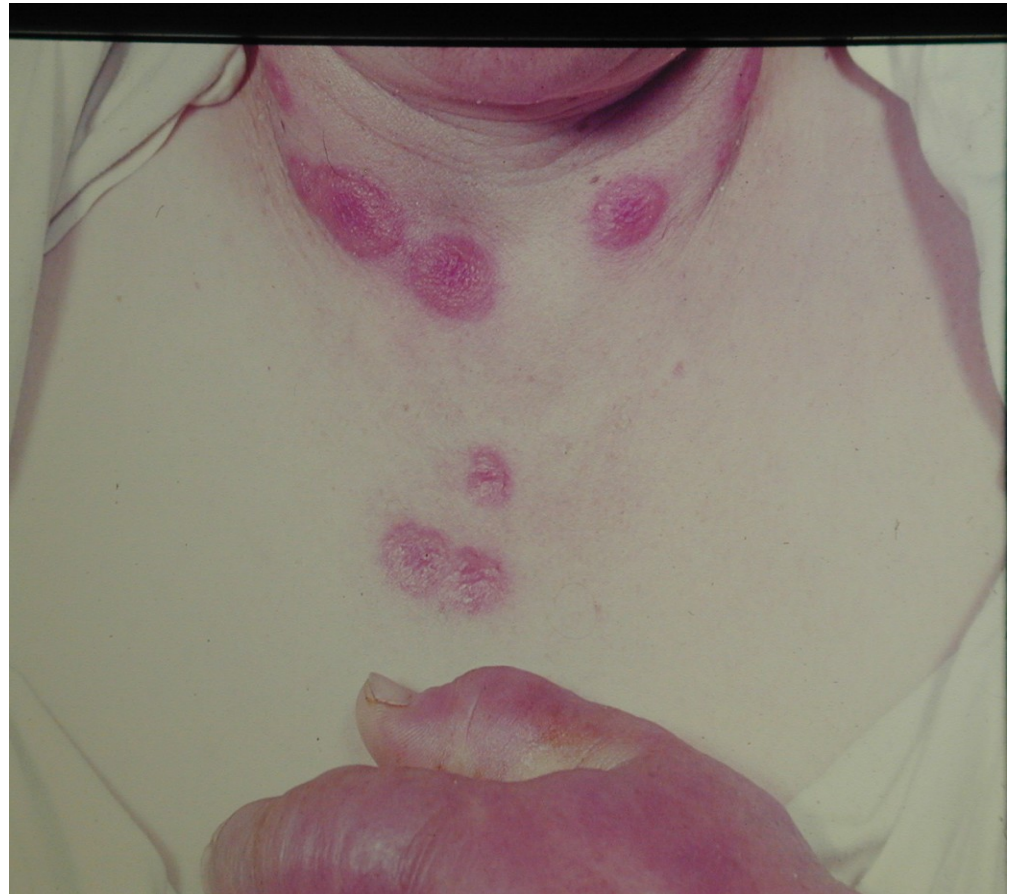# Tularemia

Rabbit fever (rabbits, hare, foxes..)

*Francisella tularensis*

Forms: ulceroglandular  
mucosal  
ocular  
typhoid

Th: macrolides





The left side of the page features three stylized balloons: a light green one at the top, a light blue one in the middle, and a light purple one at the bottom. Each balloon has a thin, curved line representing a string and several small, yellow, triangular shapes radiating from its base, suggesting light or movement.

**TEST**



# TEST

- What would you treat gonorrhoea with?
  - a/ penicilin
  - b/ tetracycline
  - c/ PUVA
  
- Mycosis fungoides originates from...
  - a/ T- lymphocytes
  - b/ B –lymphocytes
  - c/ NK cells

# TEST

- What causes pemphigus vulgaris?
  - a/ AB against desmosomes
  - b/ AB against hemidesmosomes
  - c/ AB against gluten
- Most biologicals used for the treatment of severe psoriasis are directed against...
  - a/ IL-12/23
  - b/ IFN  $\gamma$
  - c/ TNF  $\alpha$

# TEST

- The two main subtypes of atopic dermatitis are....
  - a/ young and adult
  - b/ cutaneous and systemic
  - c/ extrinsic and intrinsic
- The cause of erysipelas is...
  - a/ Hemophilus Ducreyi
  - b/  $\beta$  hemolytic Streptococcus
  - c/ Staphylococcus aureus