



Male reproductive system

gonads – testes

passages

- epididymis
- ductus deferens
- ductus ejaculatorius
- male urethra

accessory glands

- prostate
- vesiculae seminales (gll. vesiculosae)
- gll. bulbourethrales

external genitalia

- penis

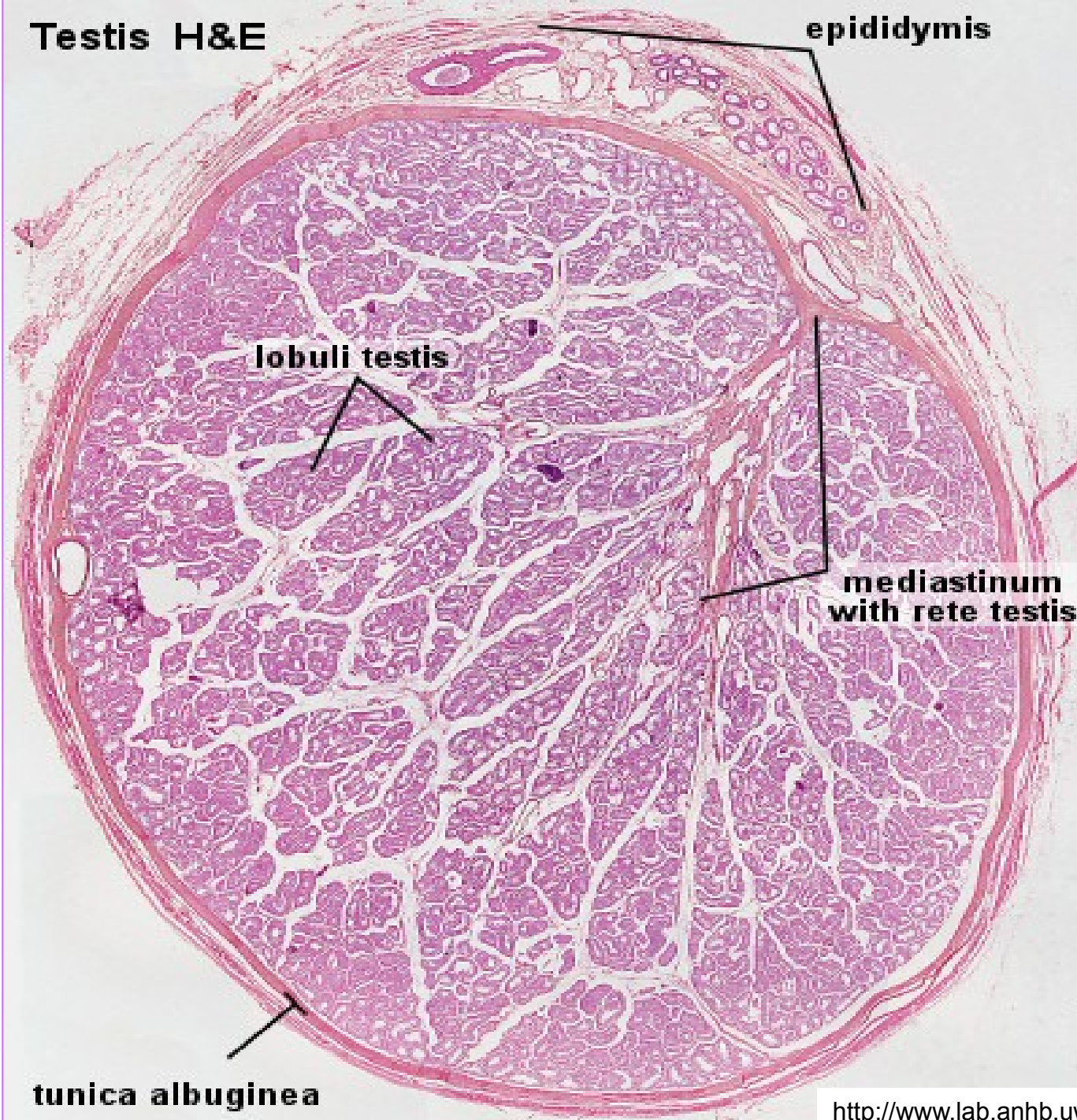
Testis H&E

epididymis

lobuli testis

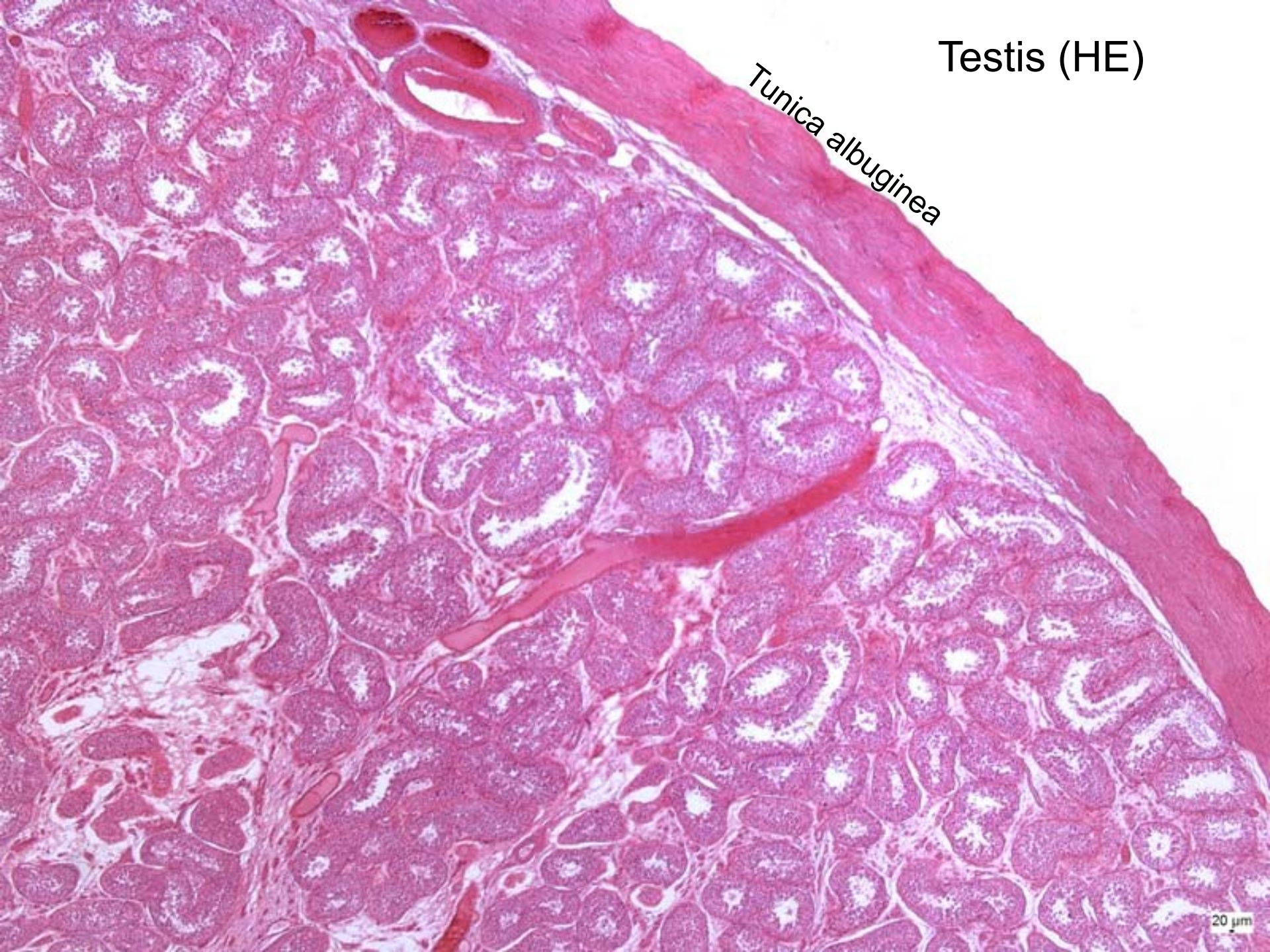**mediastinum
with rete testis**

tunica albuginea

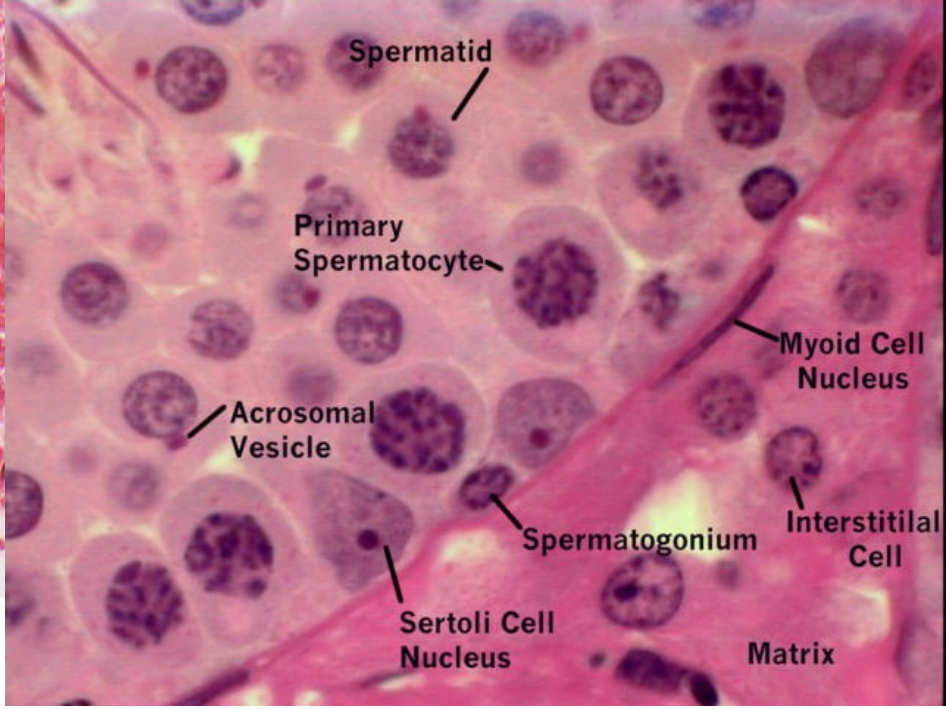
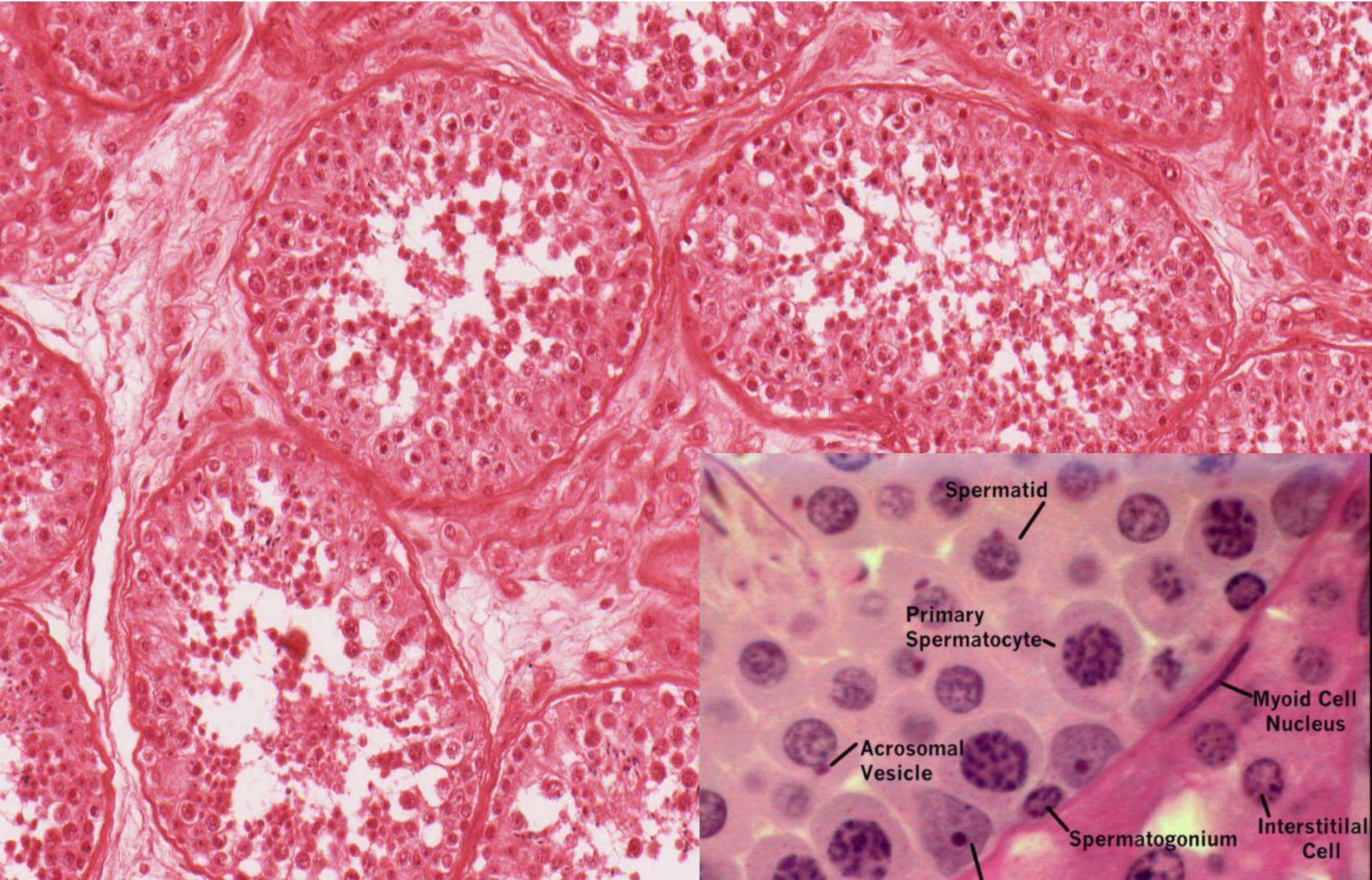


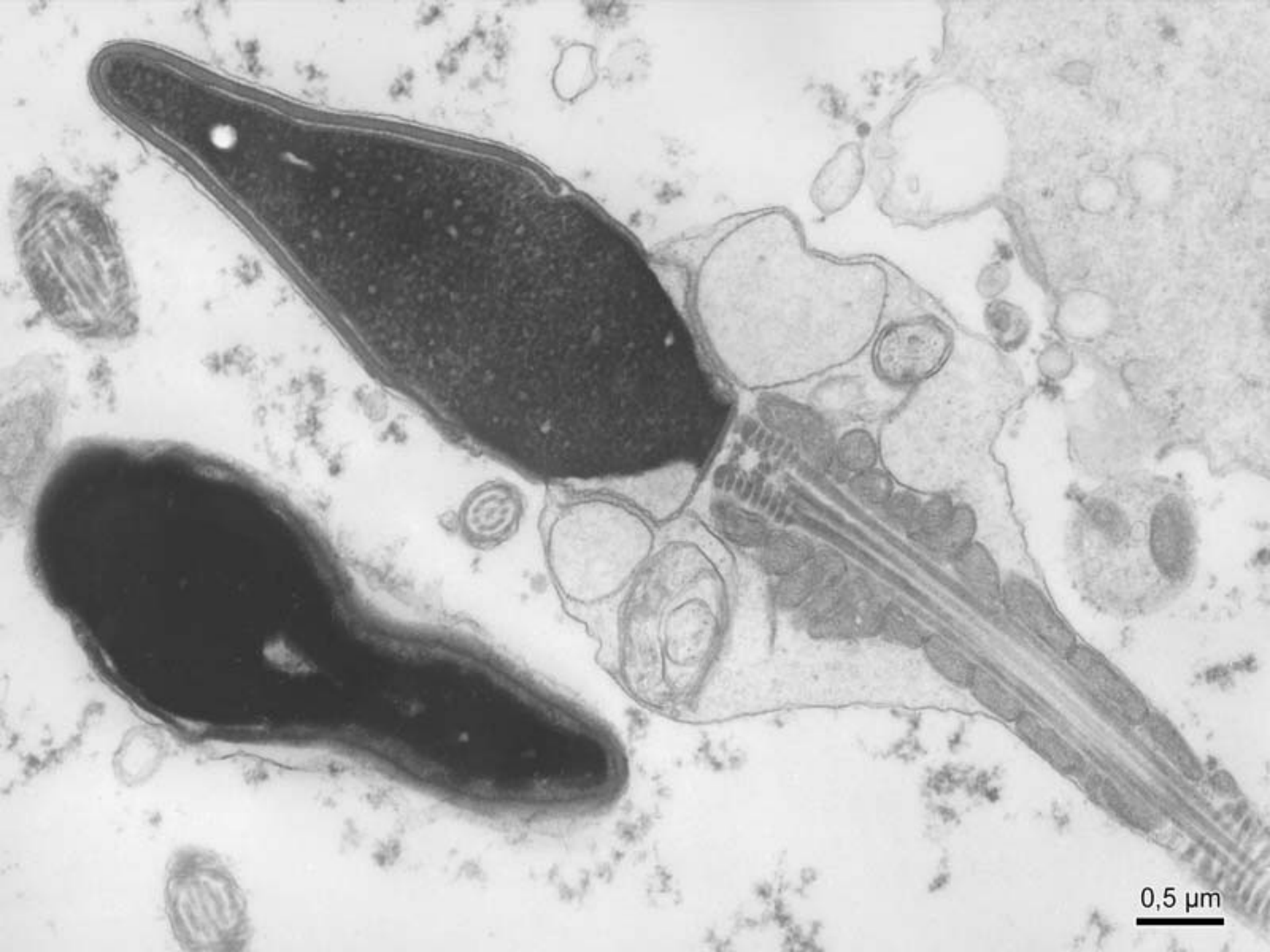
Testis (HE)

Tunica albuginea



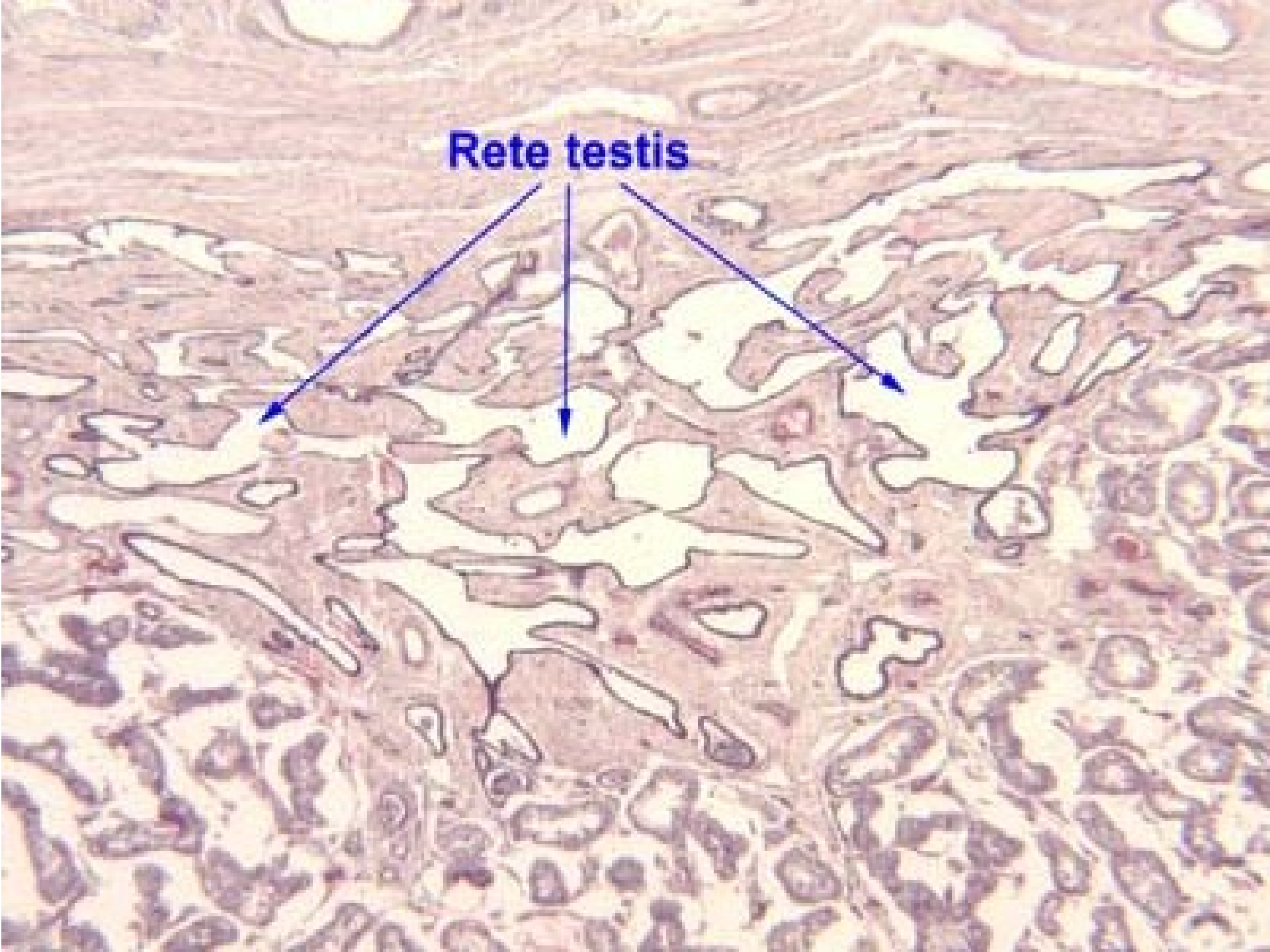
Tubuli seminiferi contorti - spermatogenesis



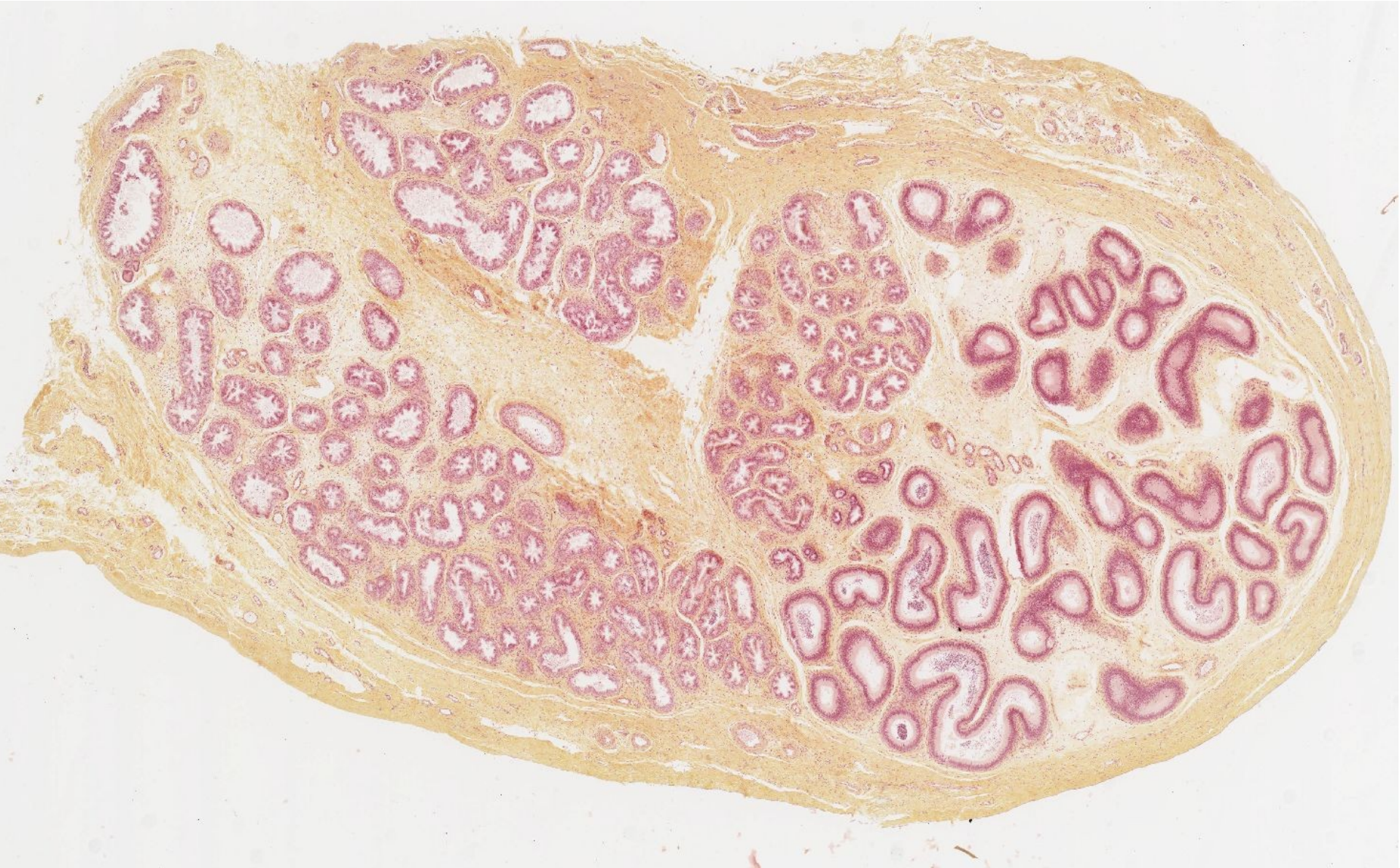


0,5 μm

Rete testis

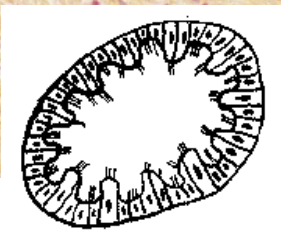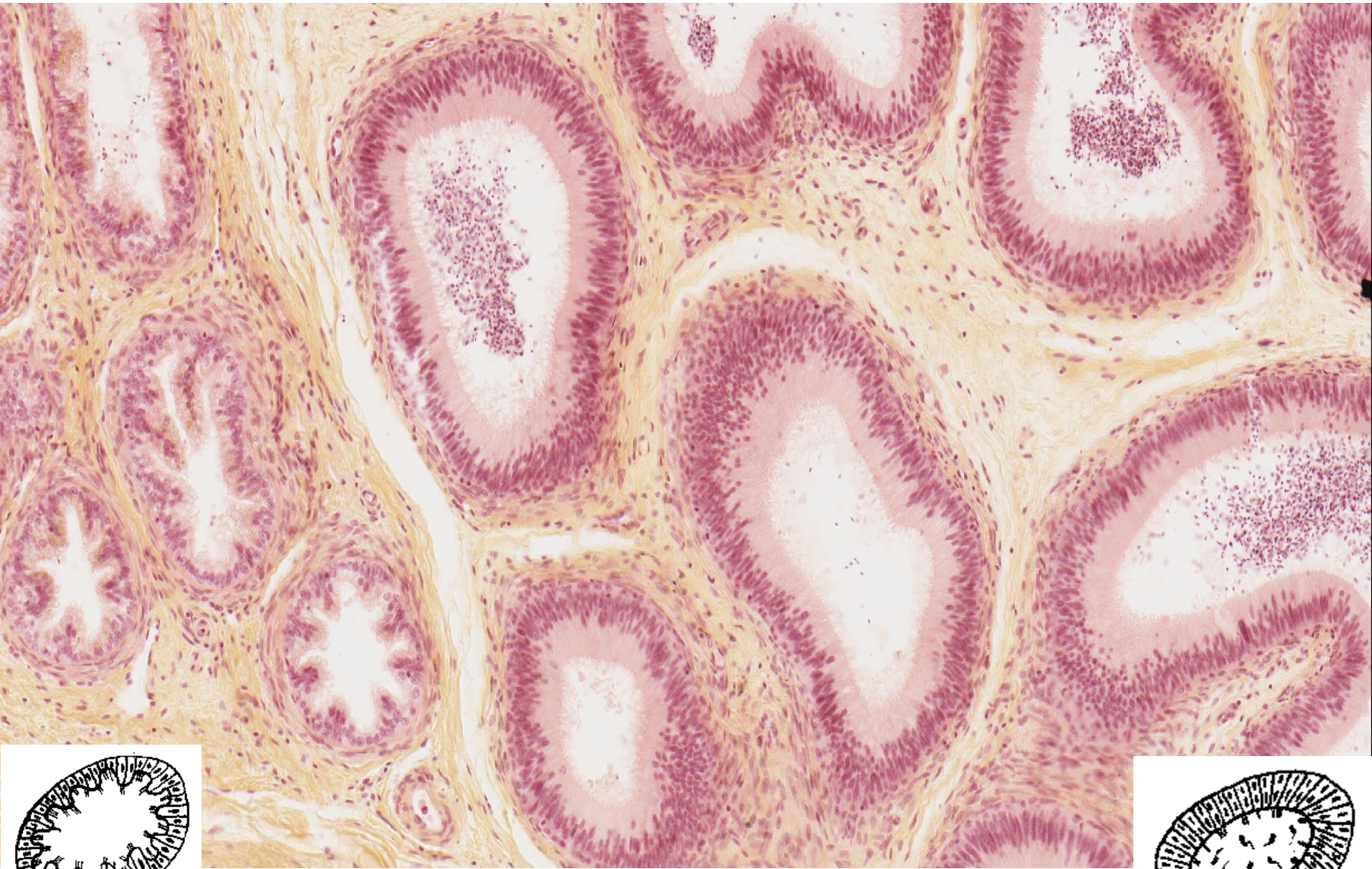


Epididymis (HEŠ)

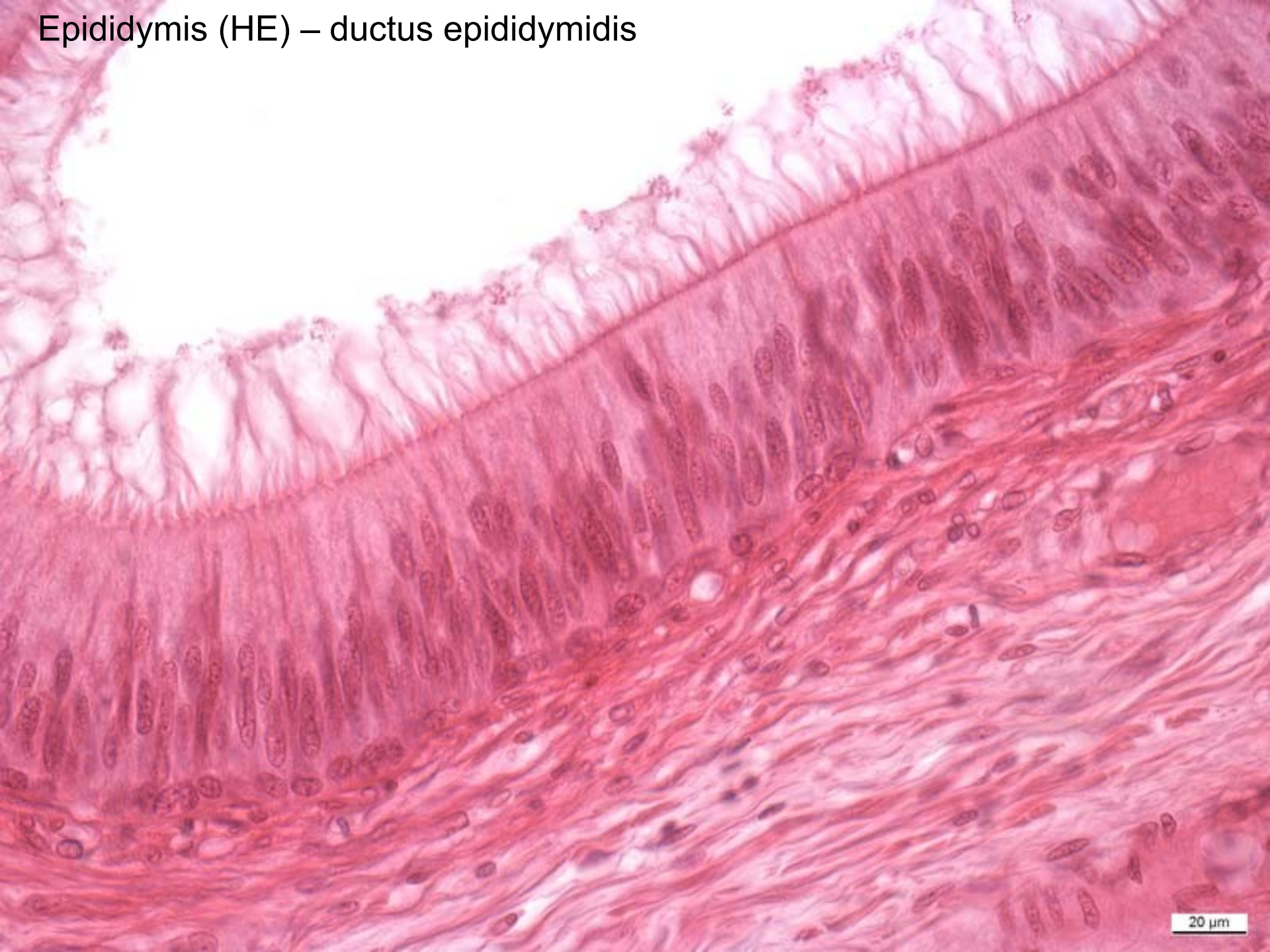

Ductuli efferentes

Ductus epididymidis

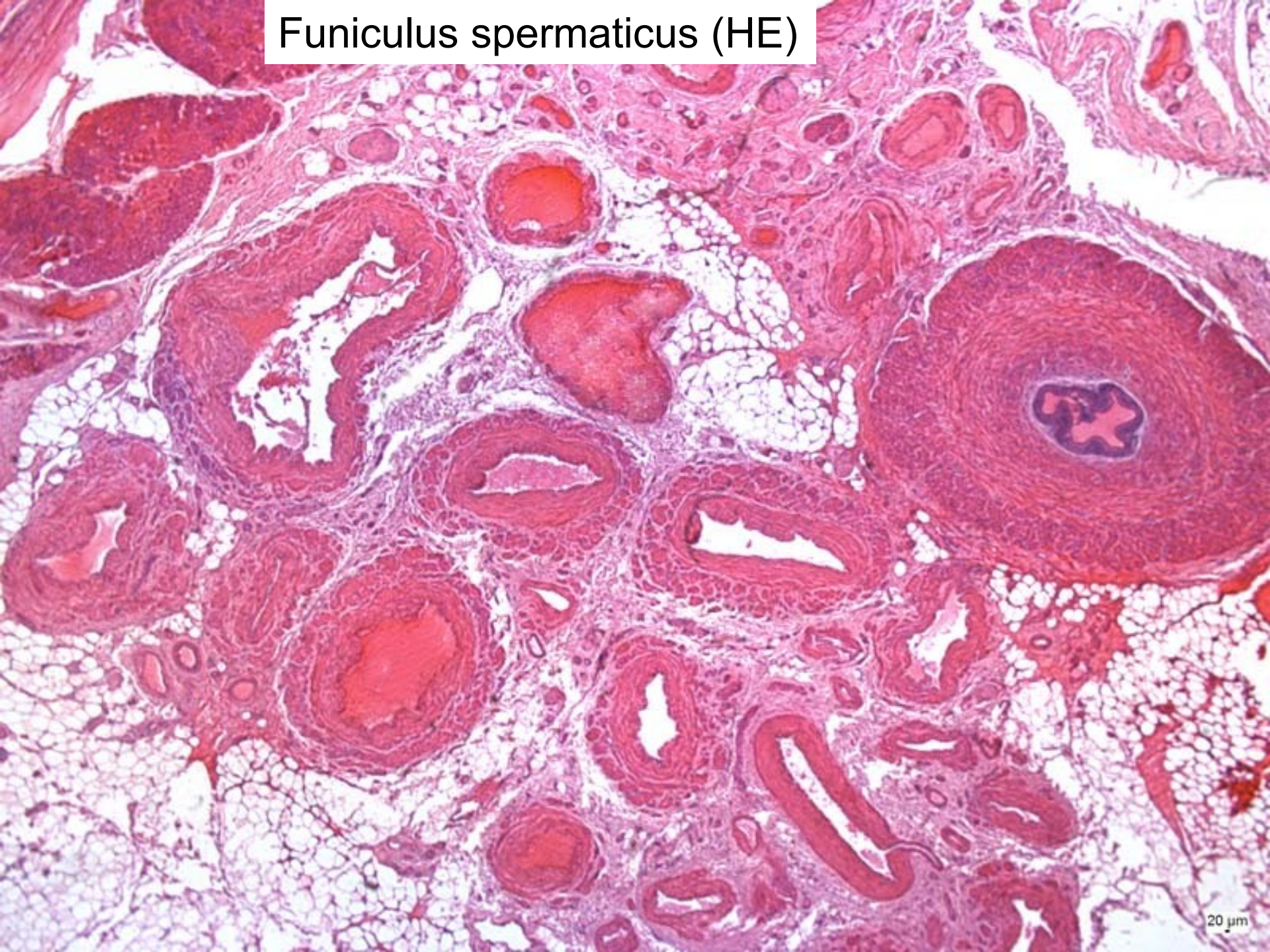


Epididymis (HE) – ductus epididymidis

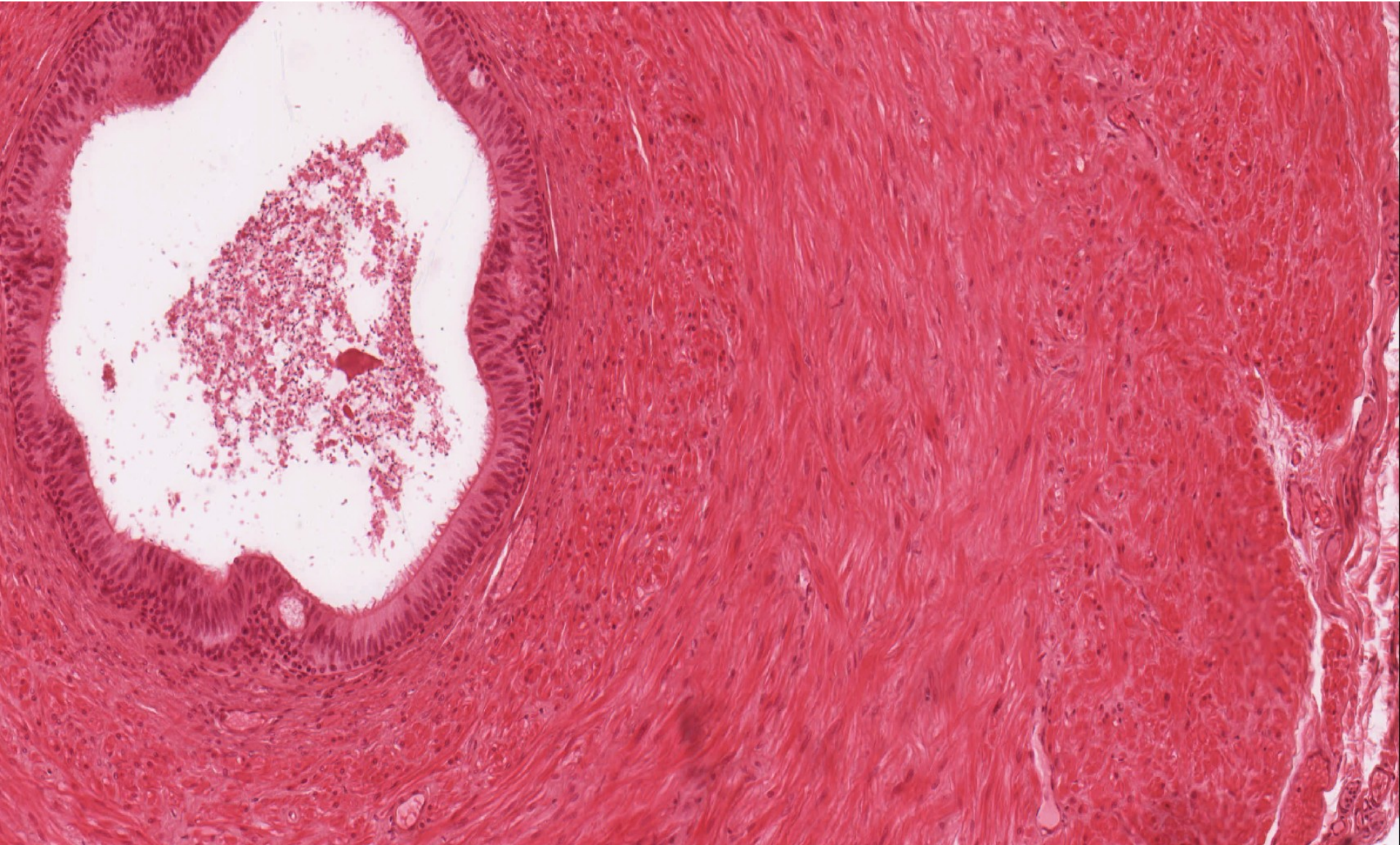


20 μ m

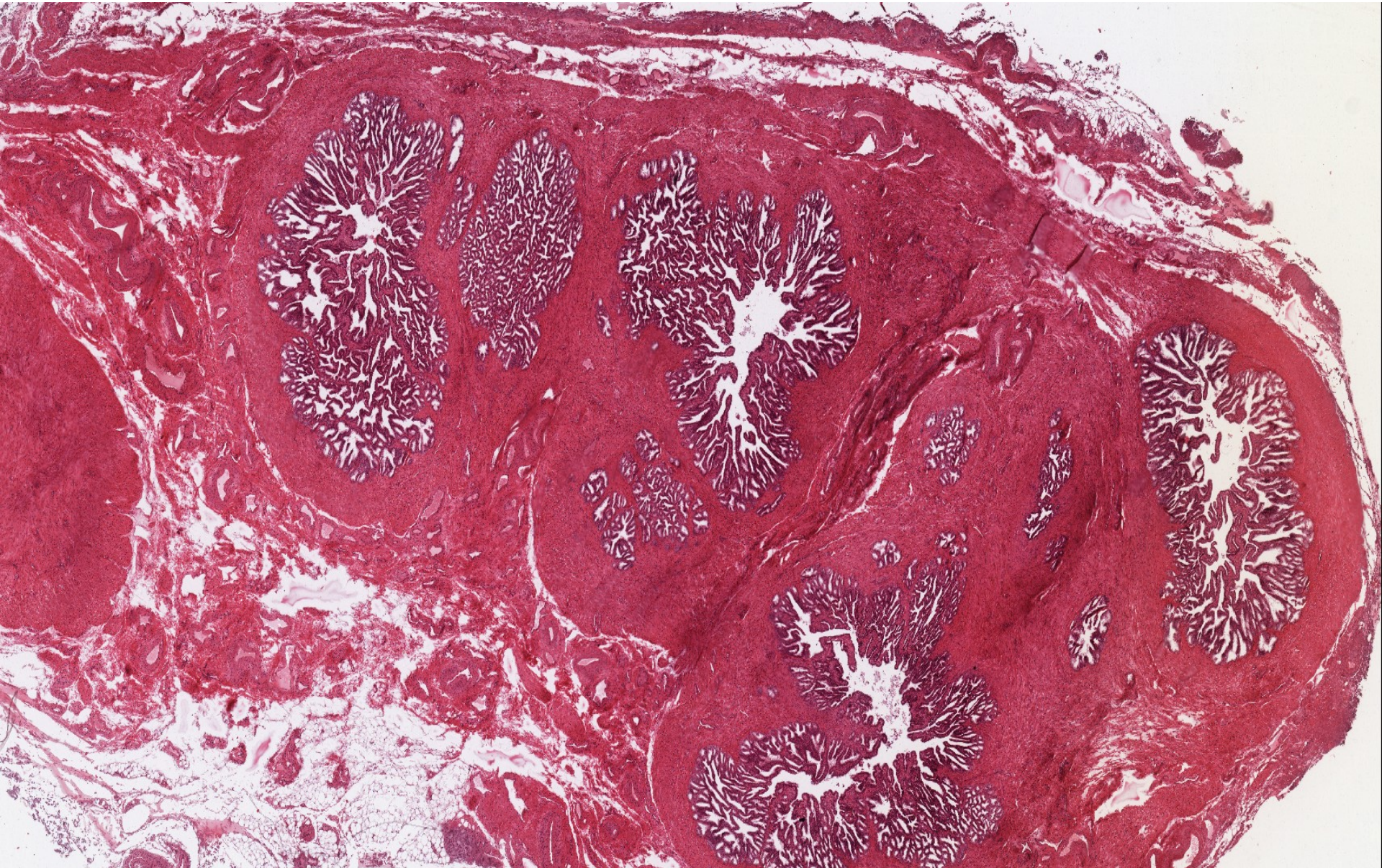
Funiculus spermaticus (HE)



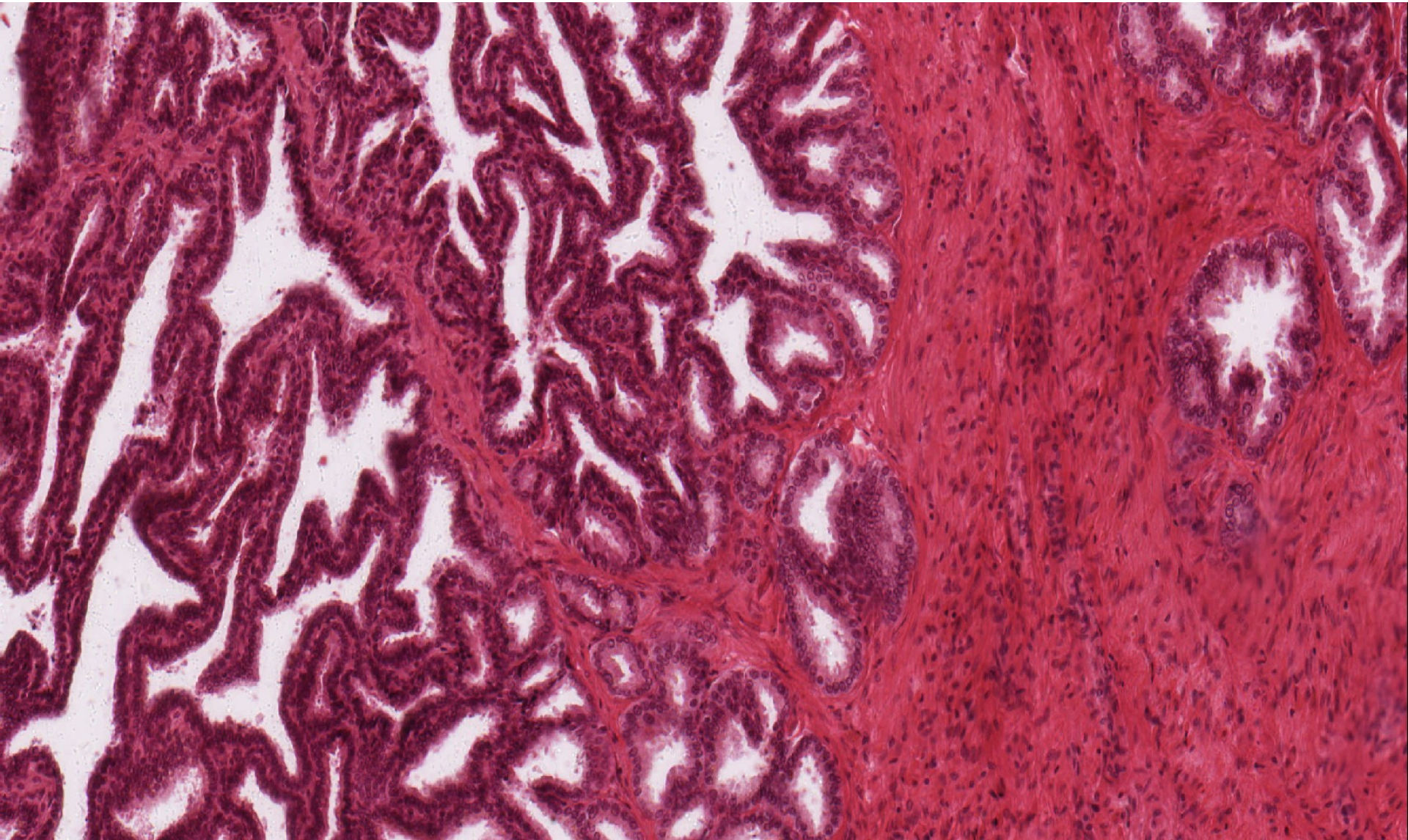
Funiculus spermaticus (HE) – ductus deferens



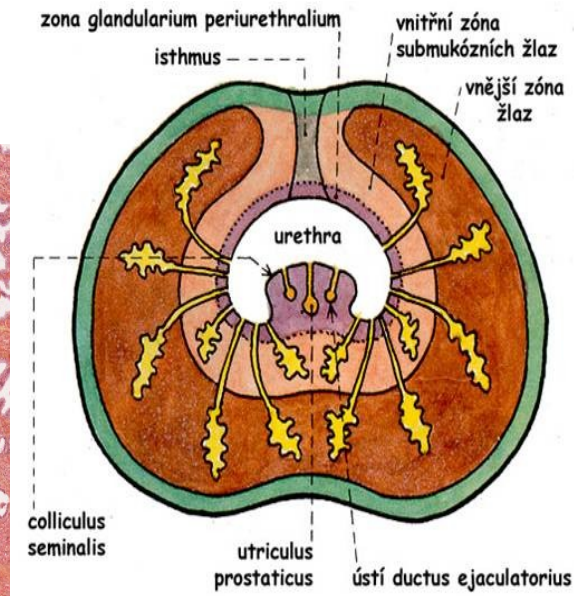
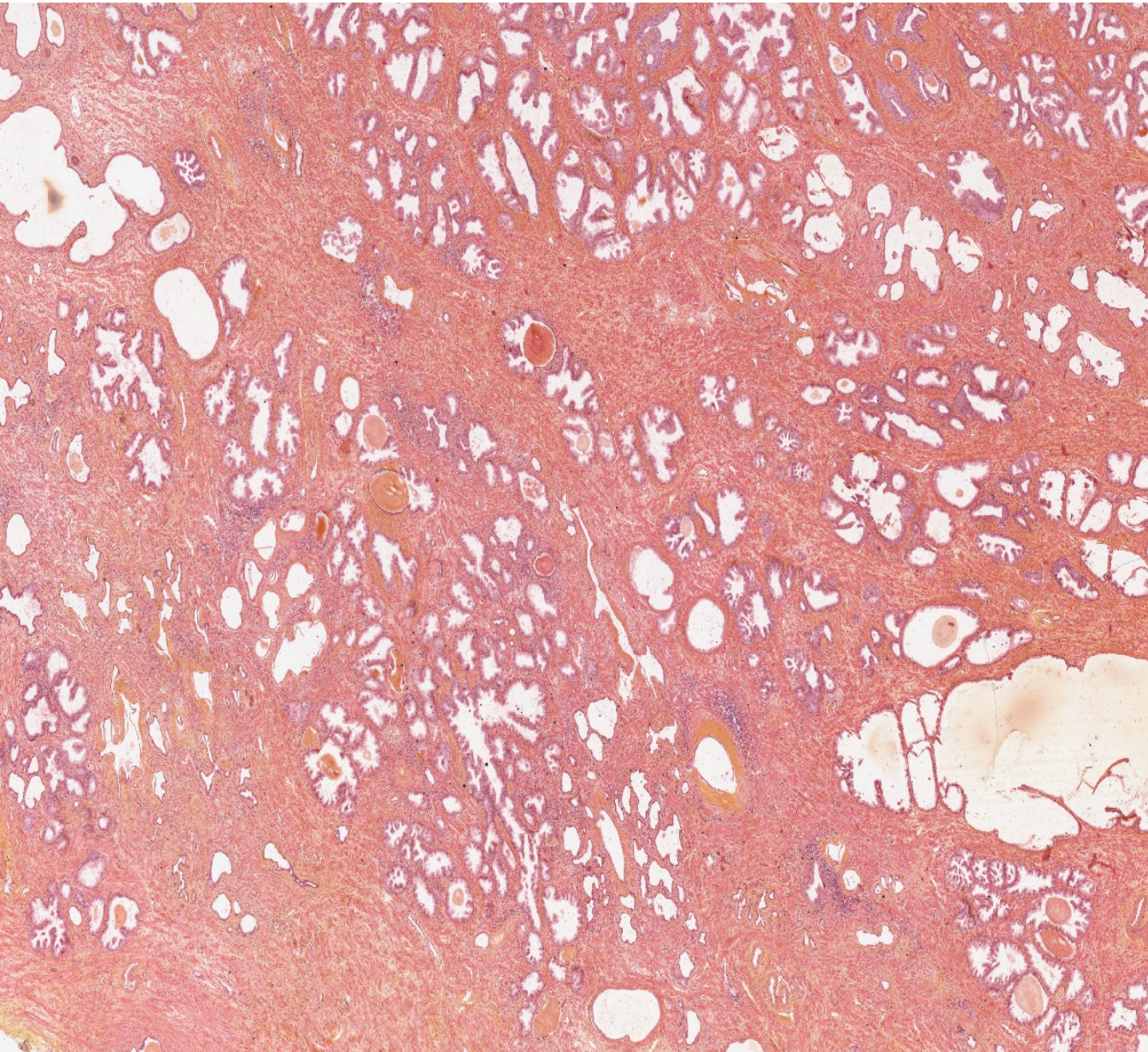
Glandula vesiculosa (HE)



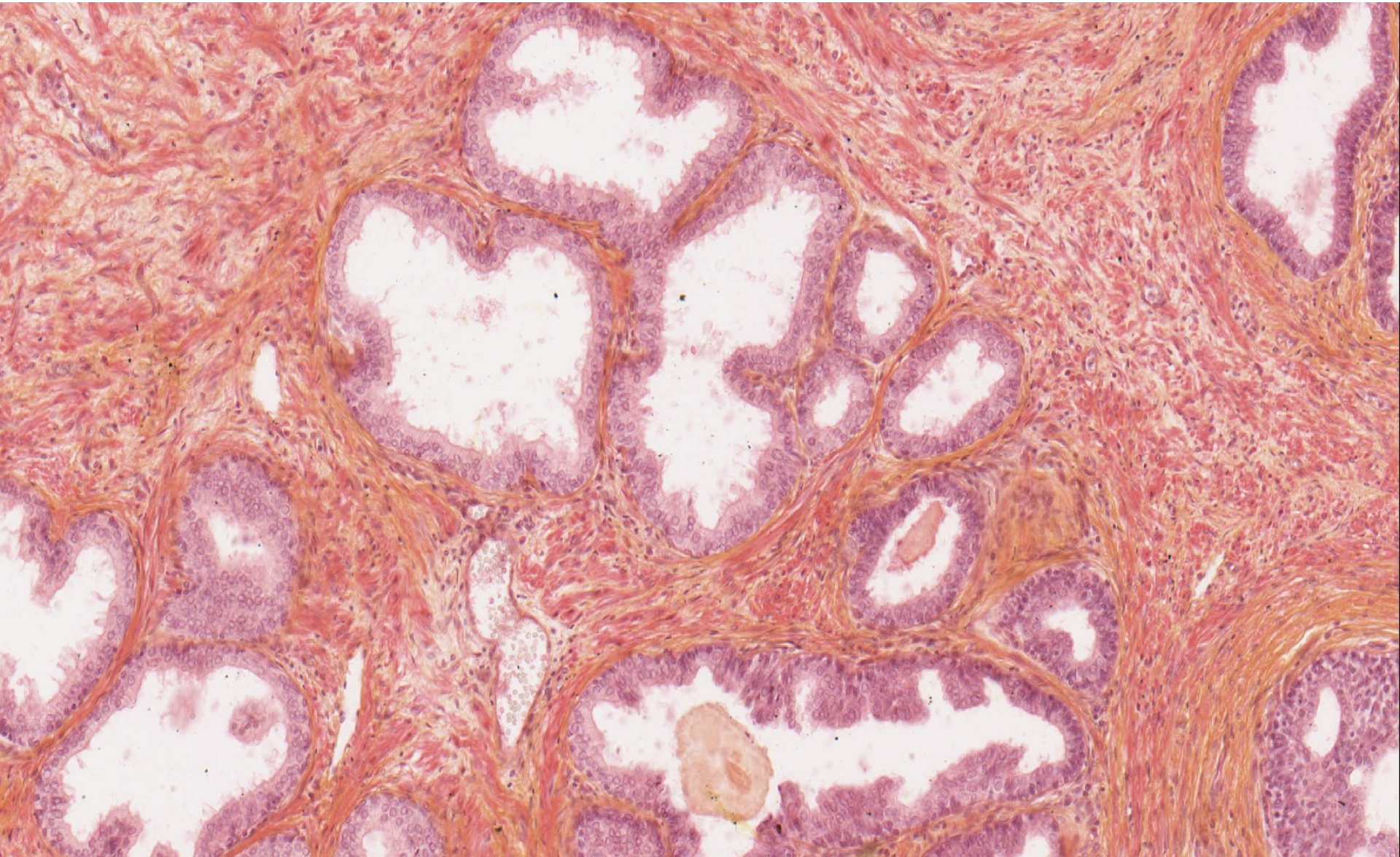
Glandula vesiculosa (HE)

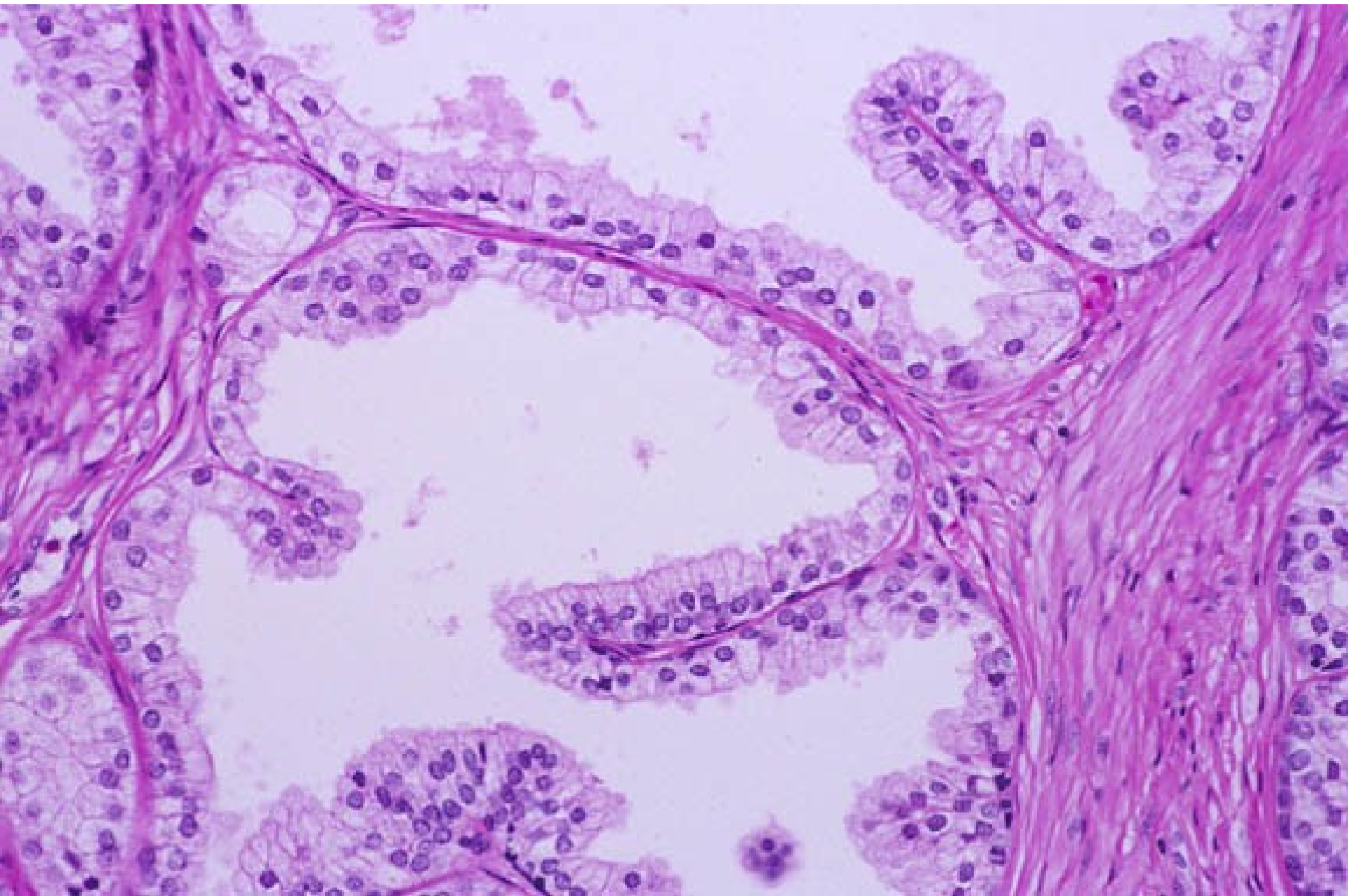


Prostate (HES)

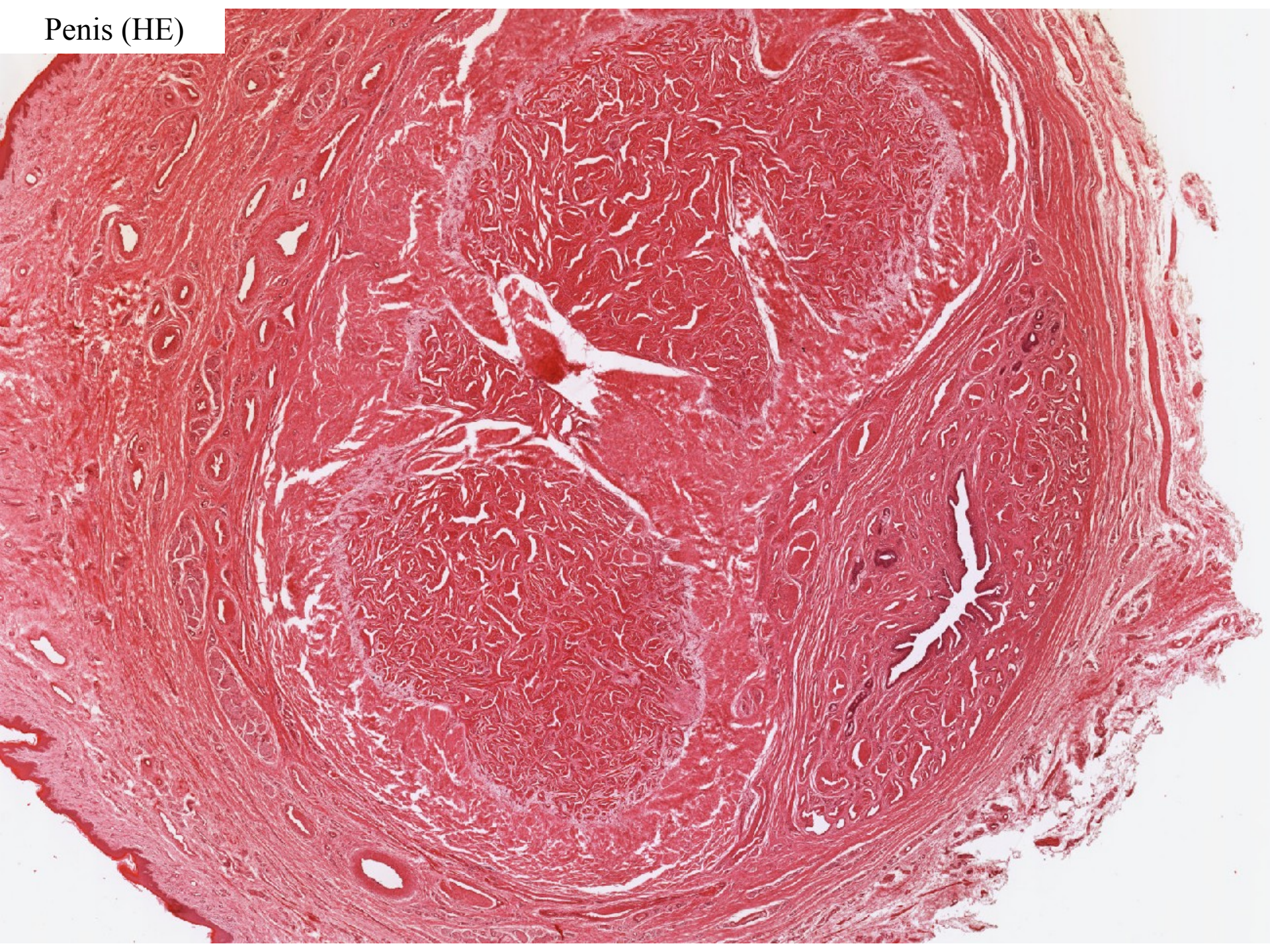


Prostate (HES)

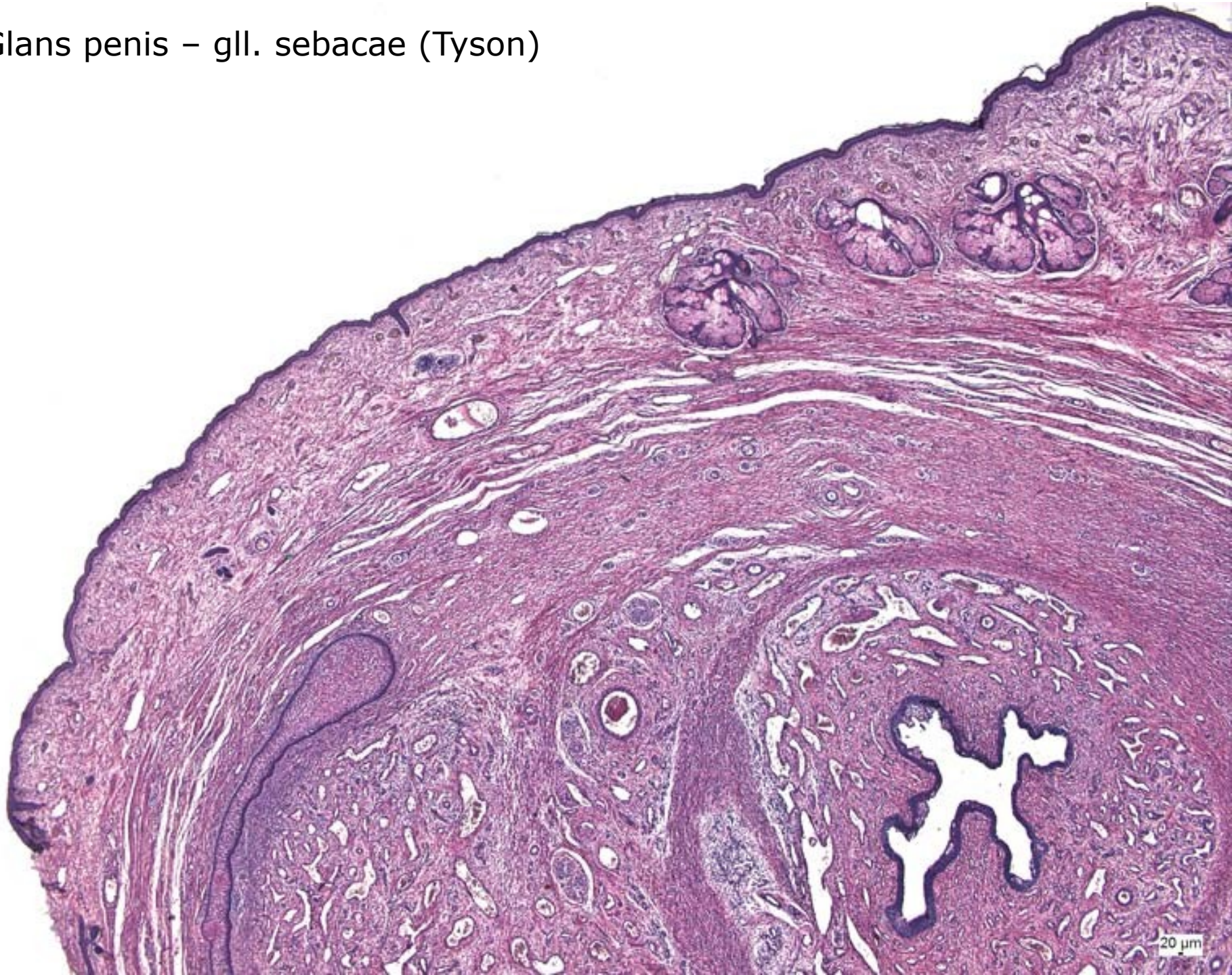



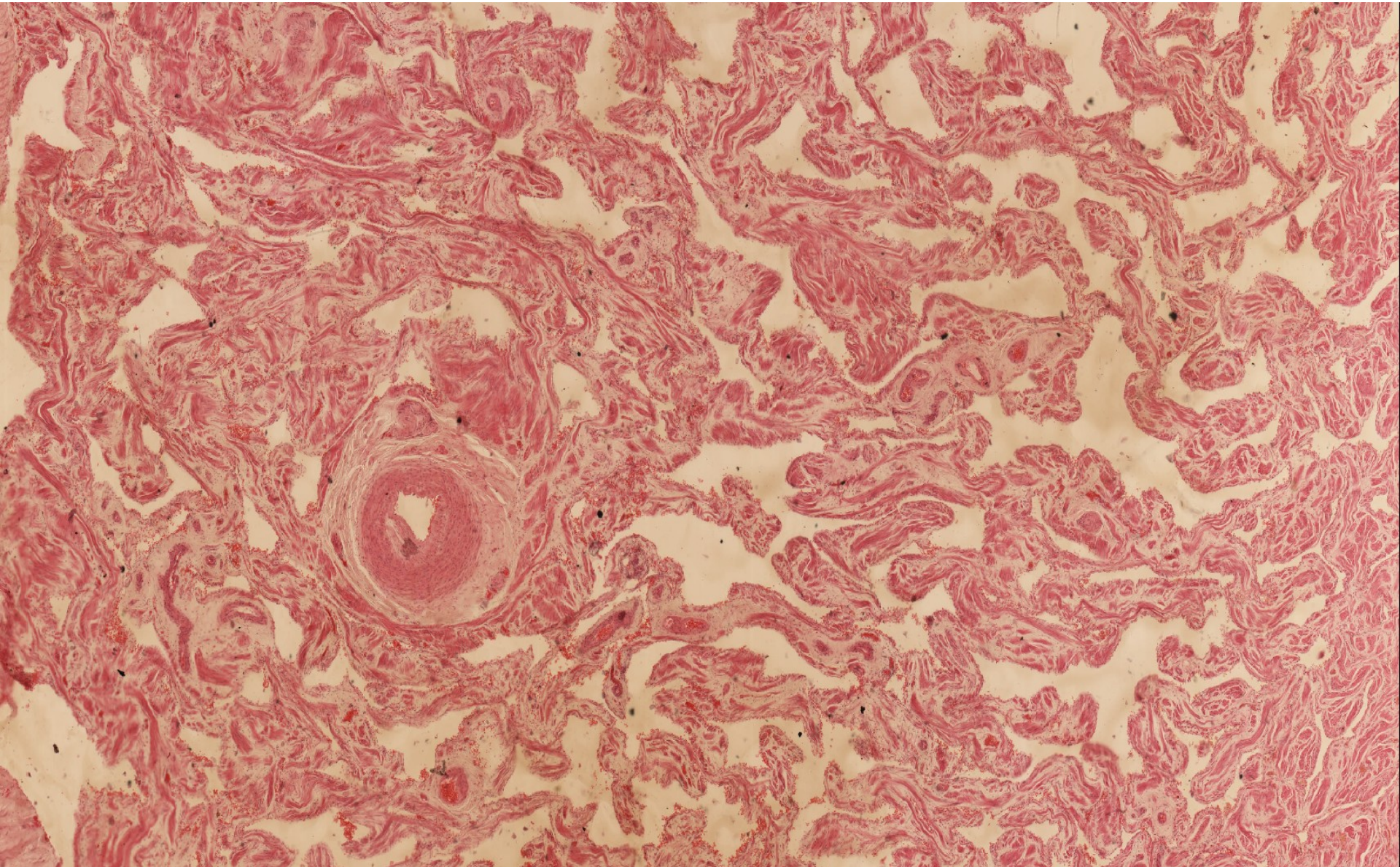
Penis (HE)



Glans penis – gll. sebaciae (Tyson)



Penis – corpus cavernosum



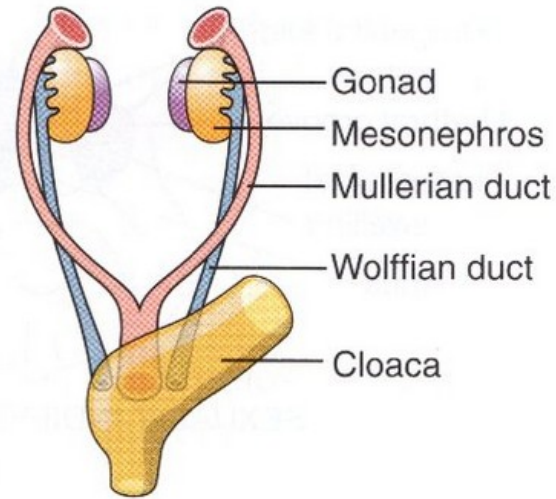
Male reproductive system

Slides:

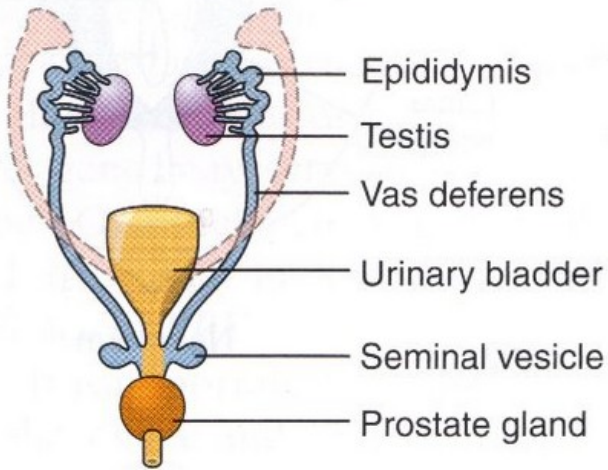
- 36. Testis (HE)
- 37. Epididymis (HE, HEŠ)
- 38. Funiculus spermaticus (HE)
- 39. Glandula vesiculosa (HE)
- 40. Prostate (HE)
- 41. Penis (HE)

Atlas EM:

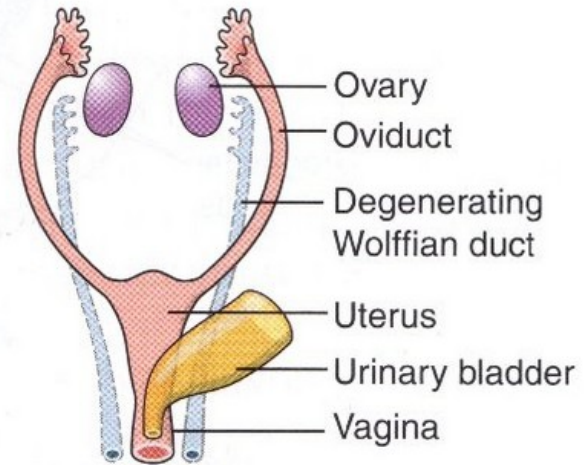
- Spermatozoon (71)
- Gonad development (95)
- Development of reproductive passages and external genitalia (96)



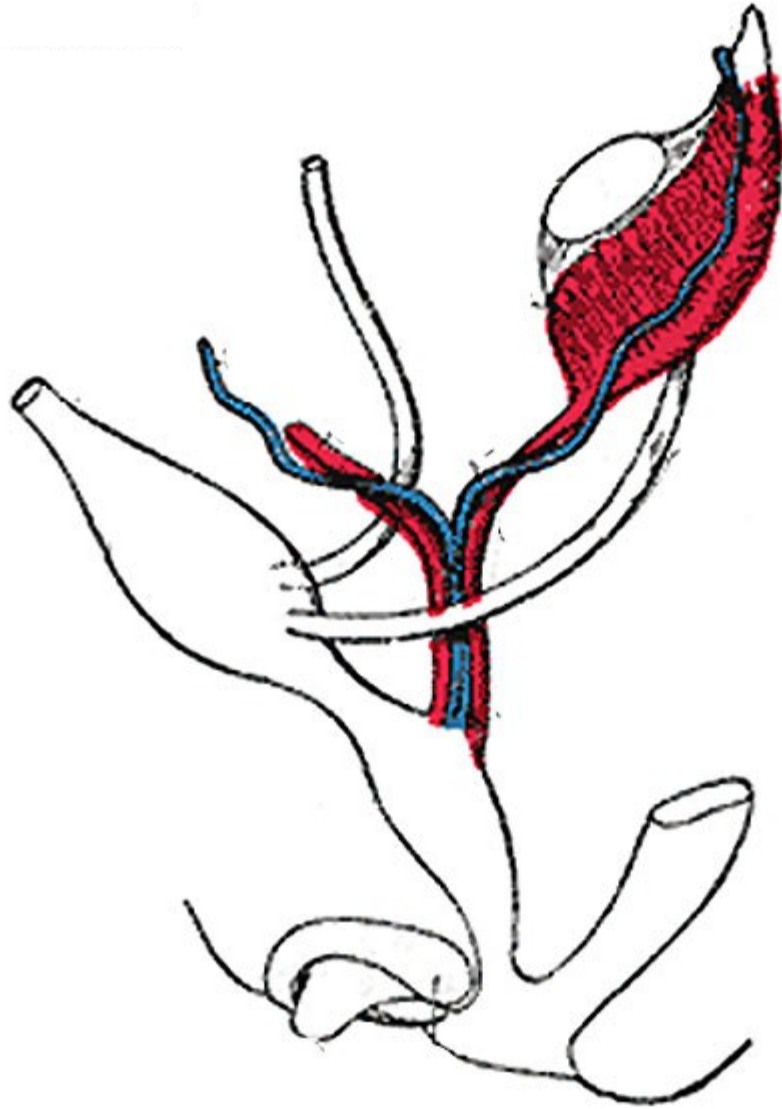
INDIFFERENT STAGE



MALE



FEMALE



Gray, Henry. Anatomy of the Human Body. Philadelphia: Lea & Febiger, 1918.

