

Nervous system

Cortex cerebri

Cerebellum (impregnation)

Spinal cord

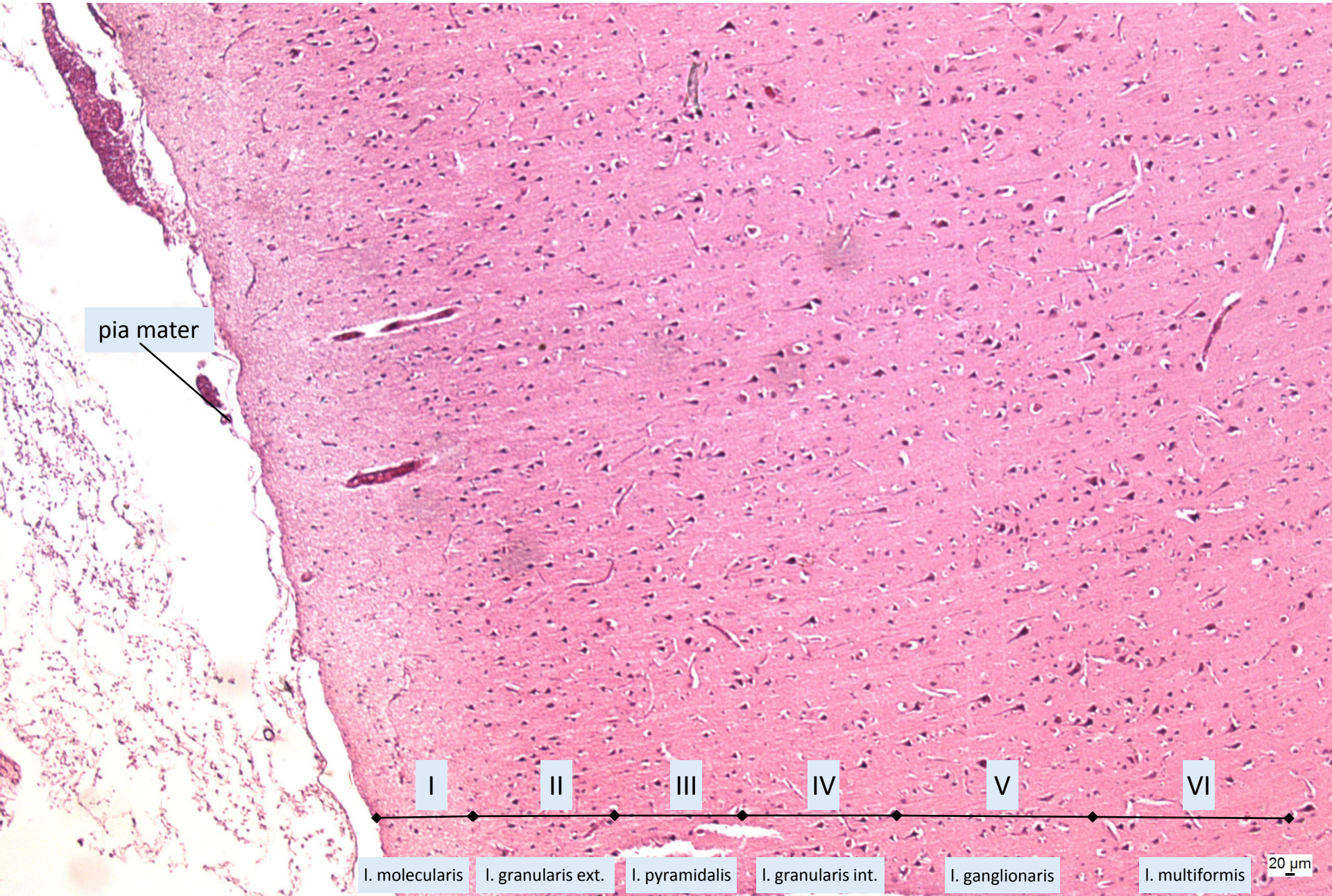
Plexus choroideus

Ganglion spinale

Autonomnic ganglion

Peripheral nerve

Cerebral cortex



pia mater

I

II

III

IV

V

VI

I. molecularis

I. granularis ext.

I. pyramidalis

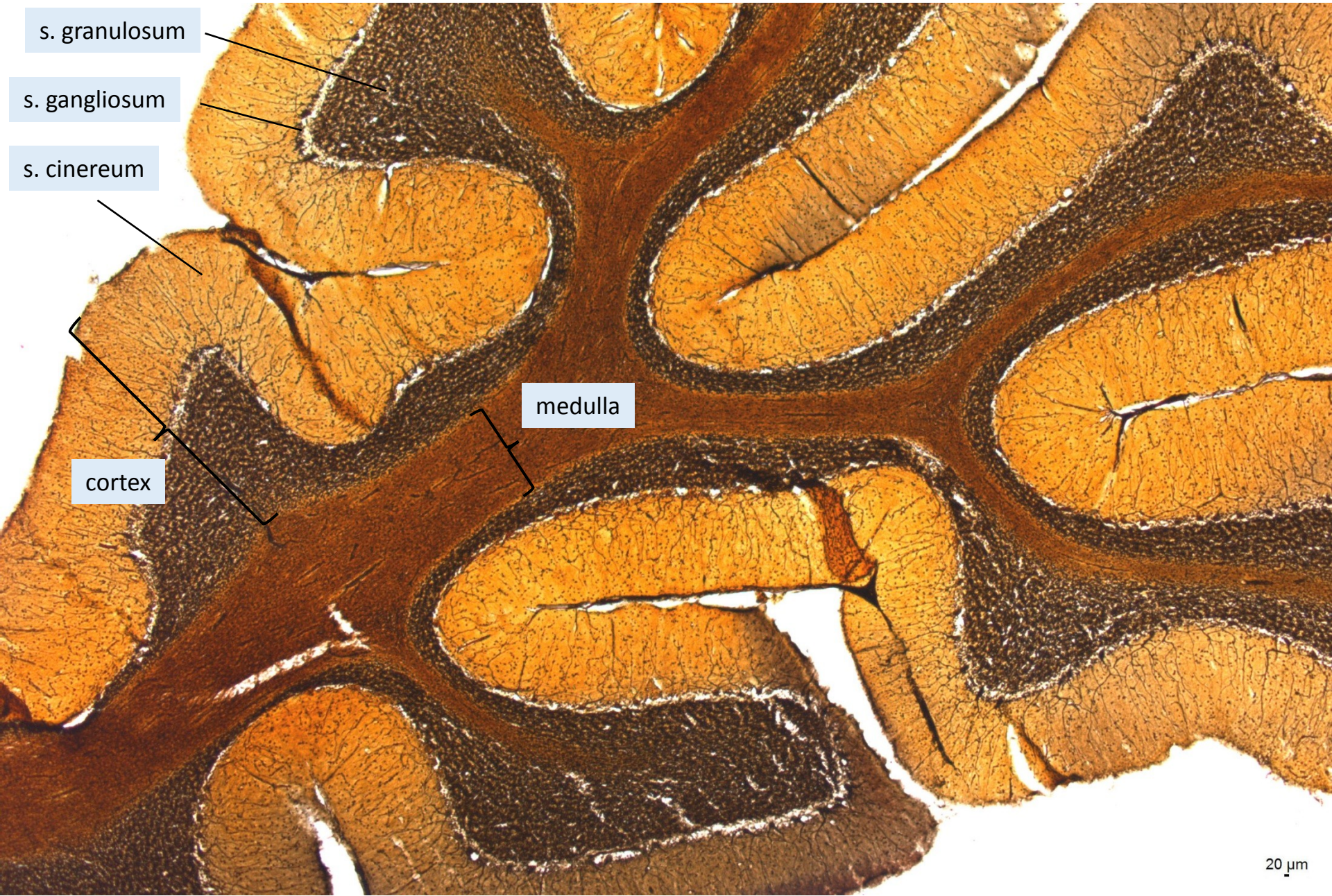
I. granularis int.

I. ganglionaris

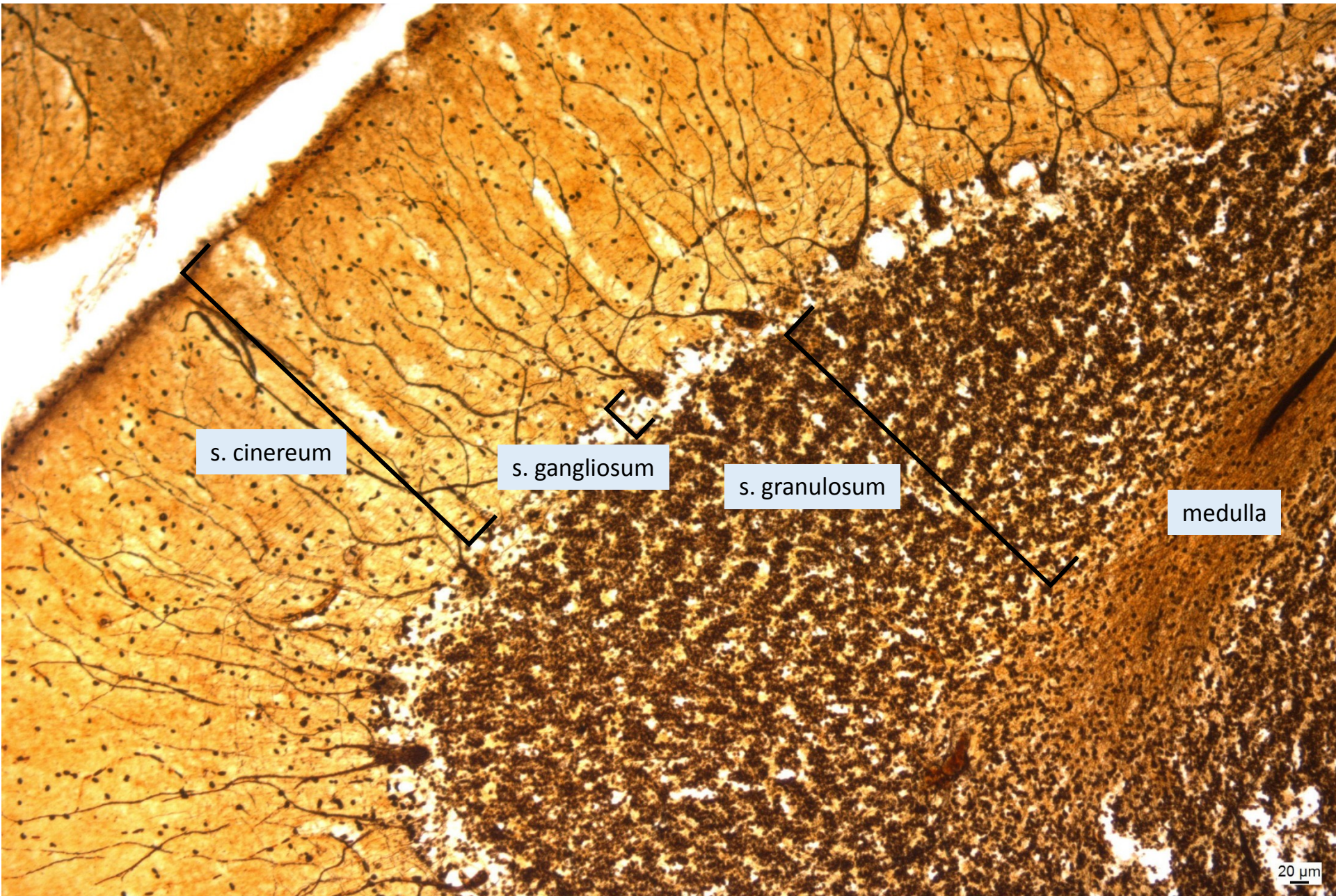
I. multiformis

20 μm

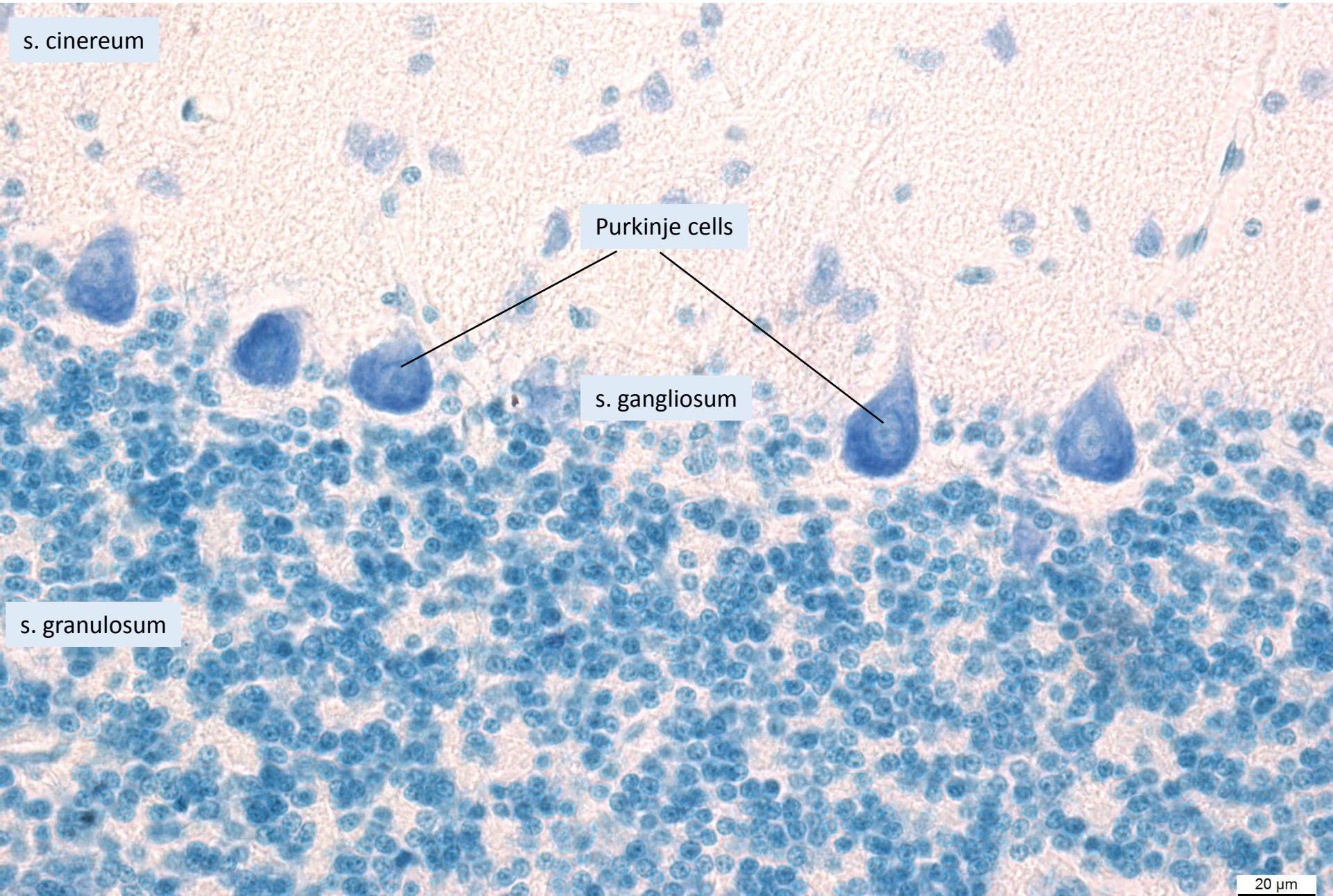
Cerebellum



Cerebellar cortex



Cerebellar cortex – Purkinje cells



s. cinereum

Purkinje cells

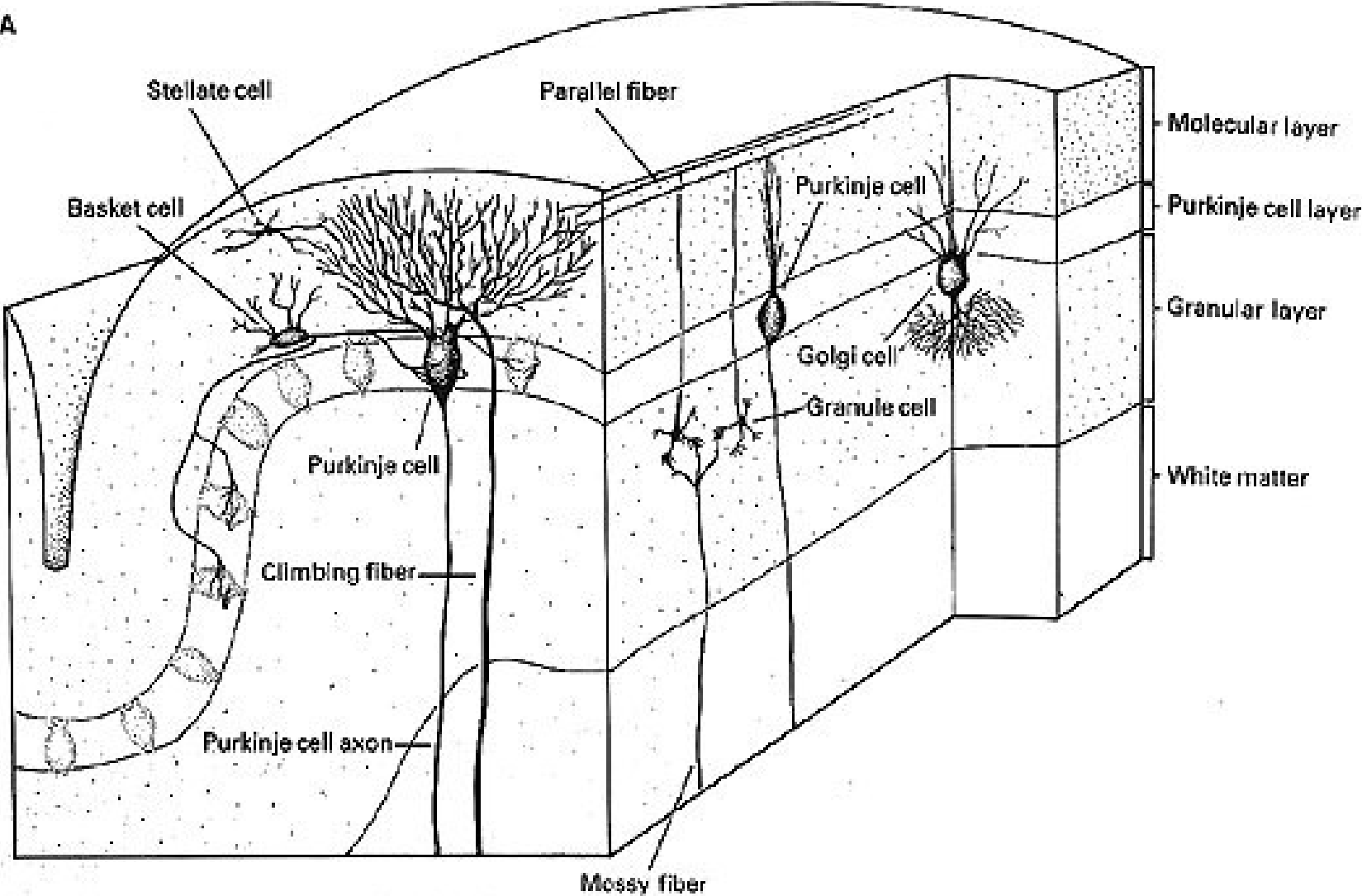
s. gangliosum

s. granulosum

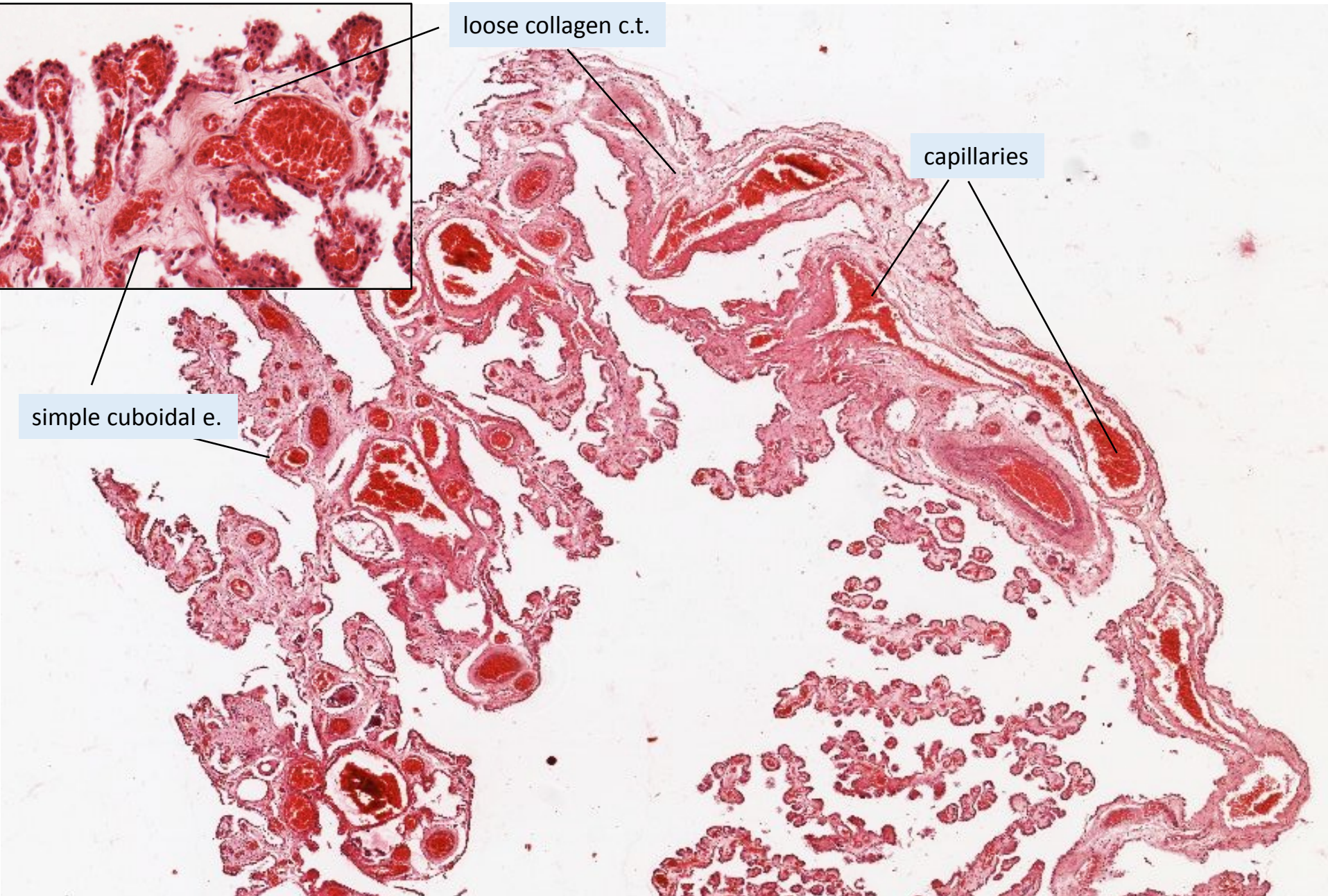
20 µm

Cerebellum – neuron synapses

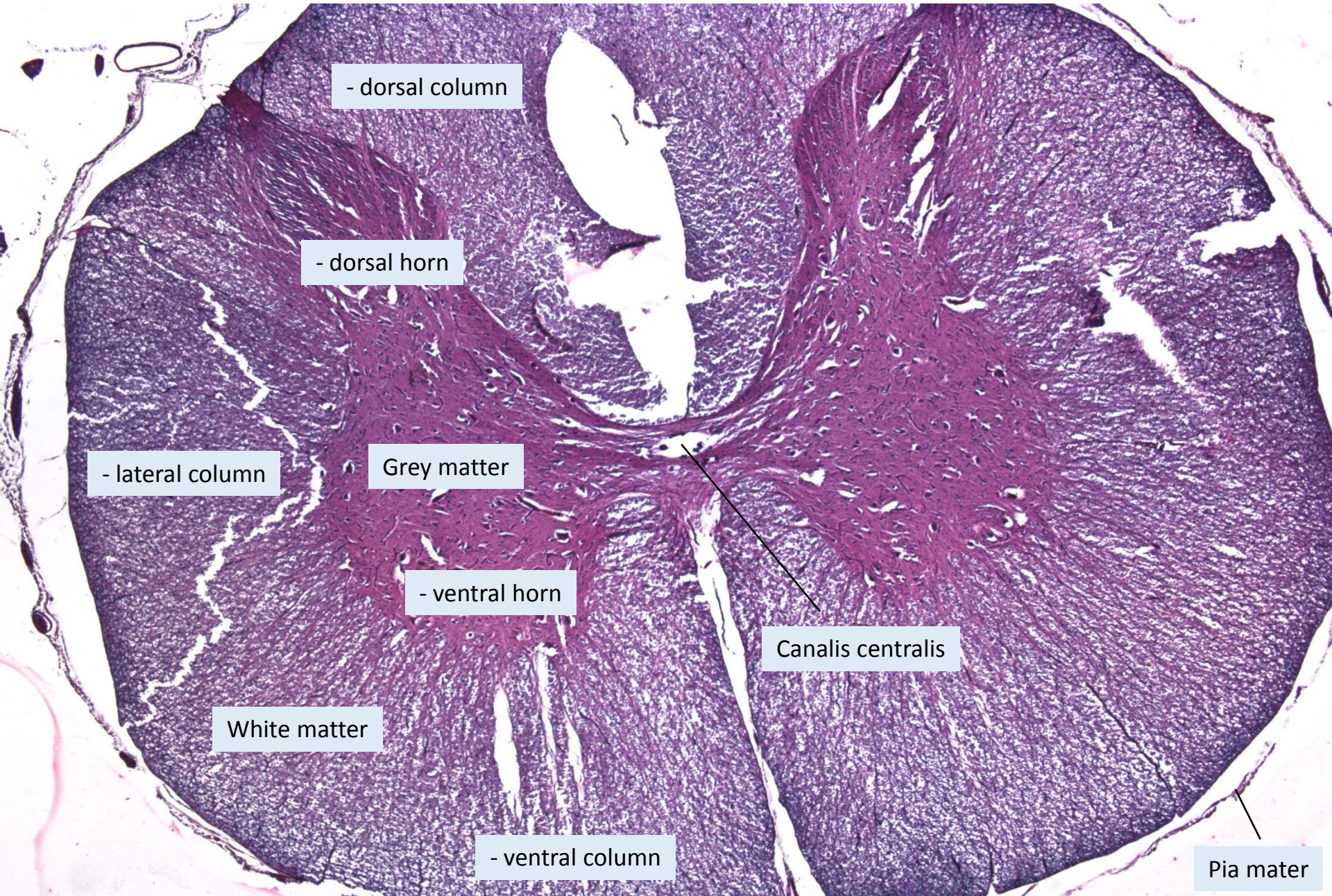
A



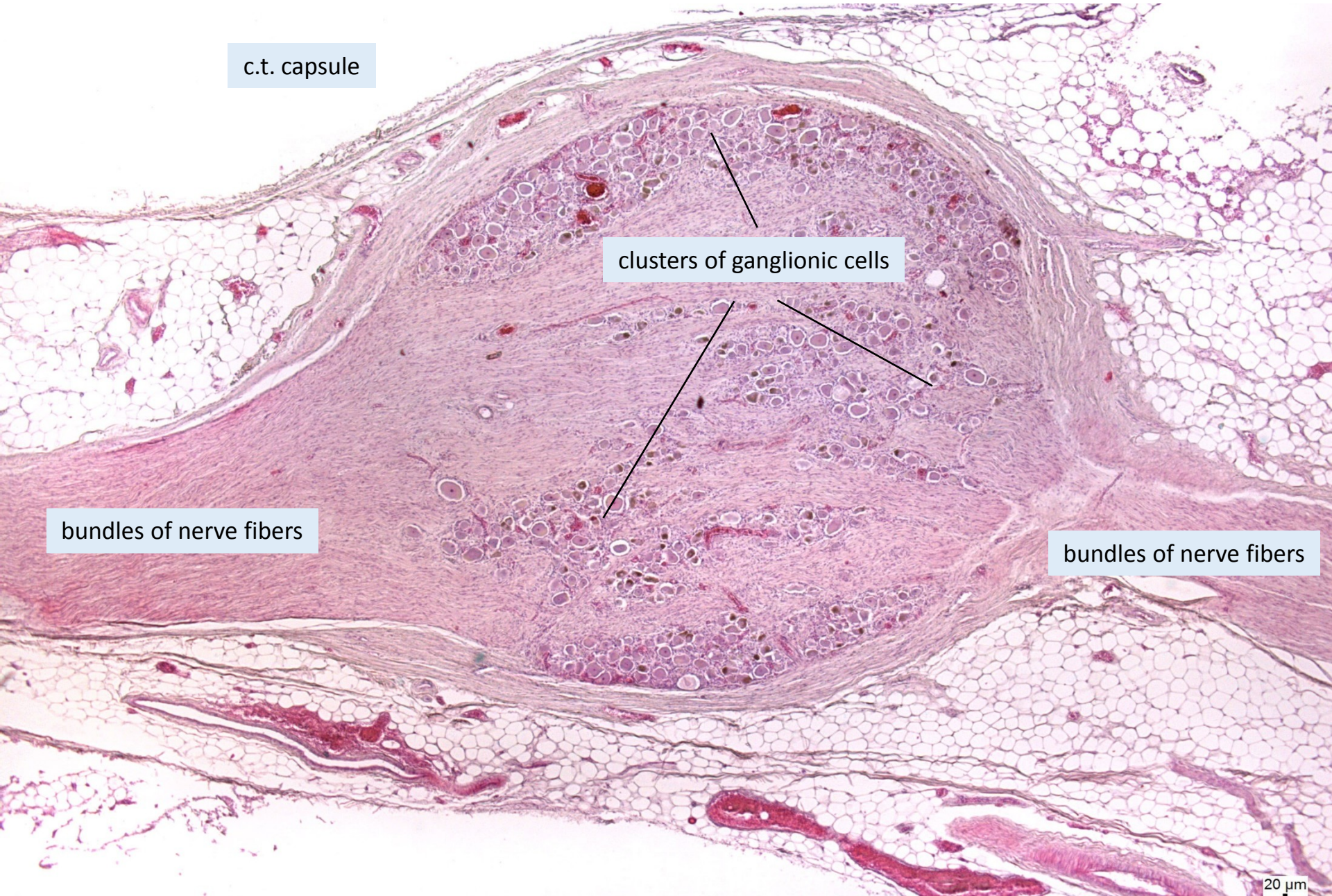
Choroid plexus



Spinal cord



Spinal ganglion



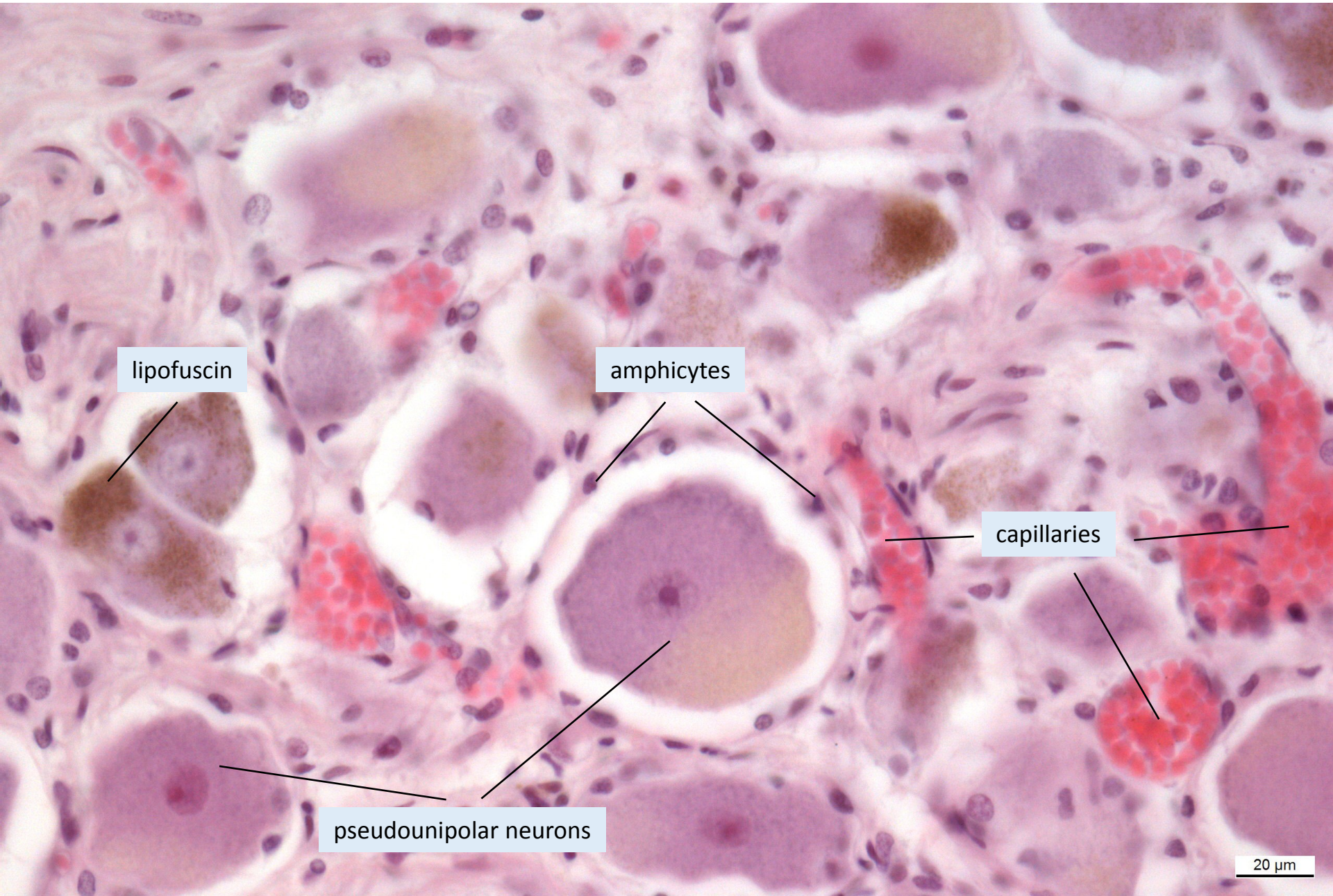
c.t. capsule

clusters of ganglionic cells

bundles of nerve fibers

bundles of nerve fibers

Spinal ganglion



lipofuscin

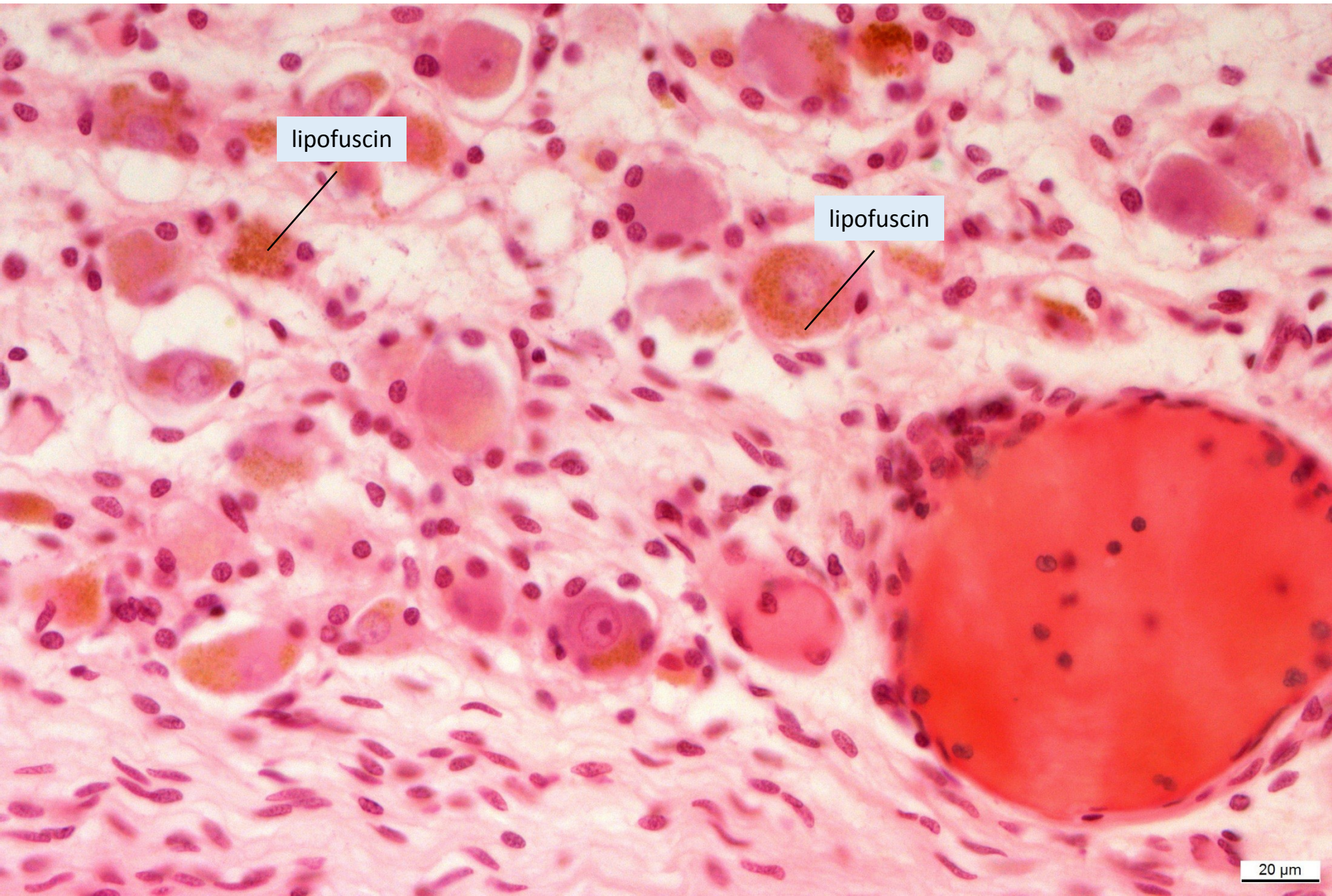
amphicytes

capillaries

pseudounipolar neurons

20 μ m

Spinal ganglion - lipofuscin

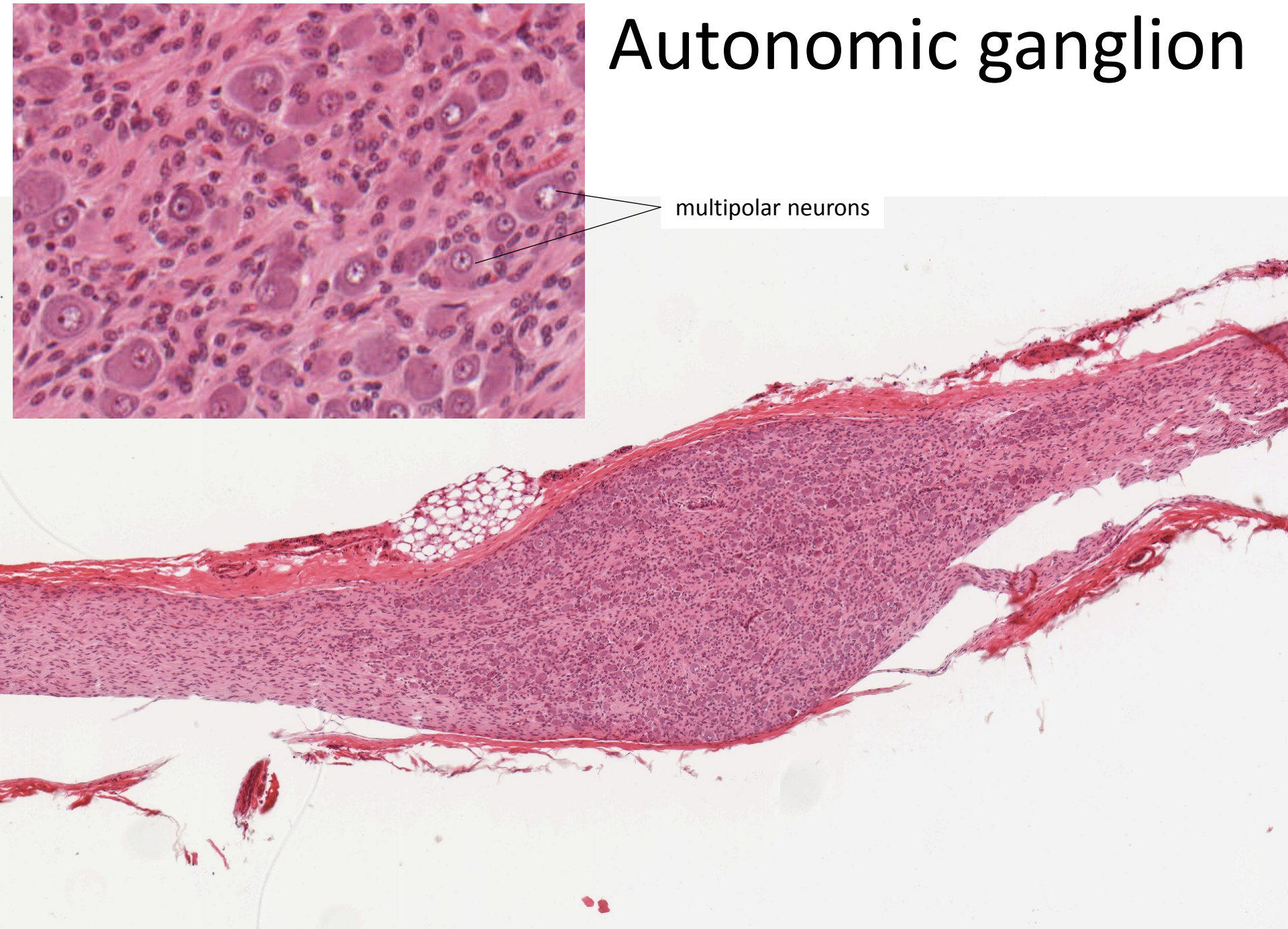


lipofuscin

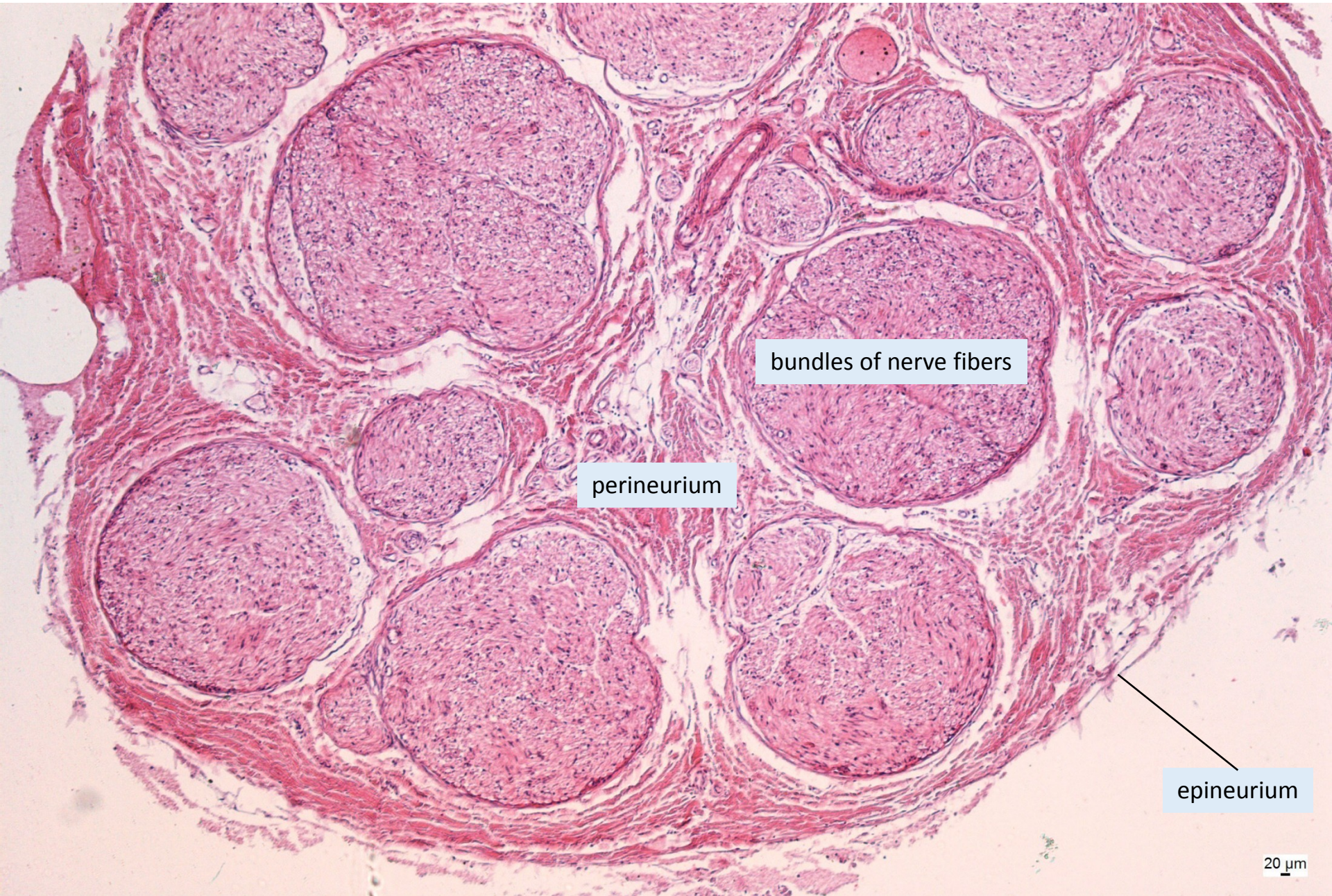
lipofuscin

Autonomic ganglion

multipolar neurons



Peripheral nerve



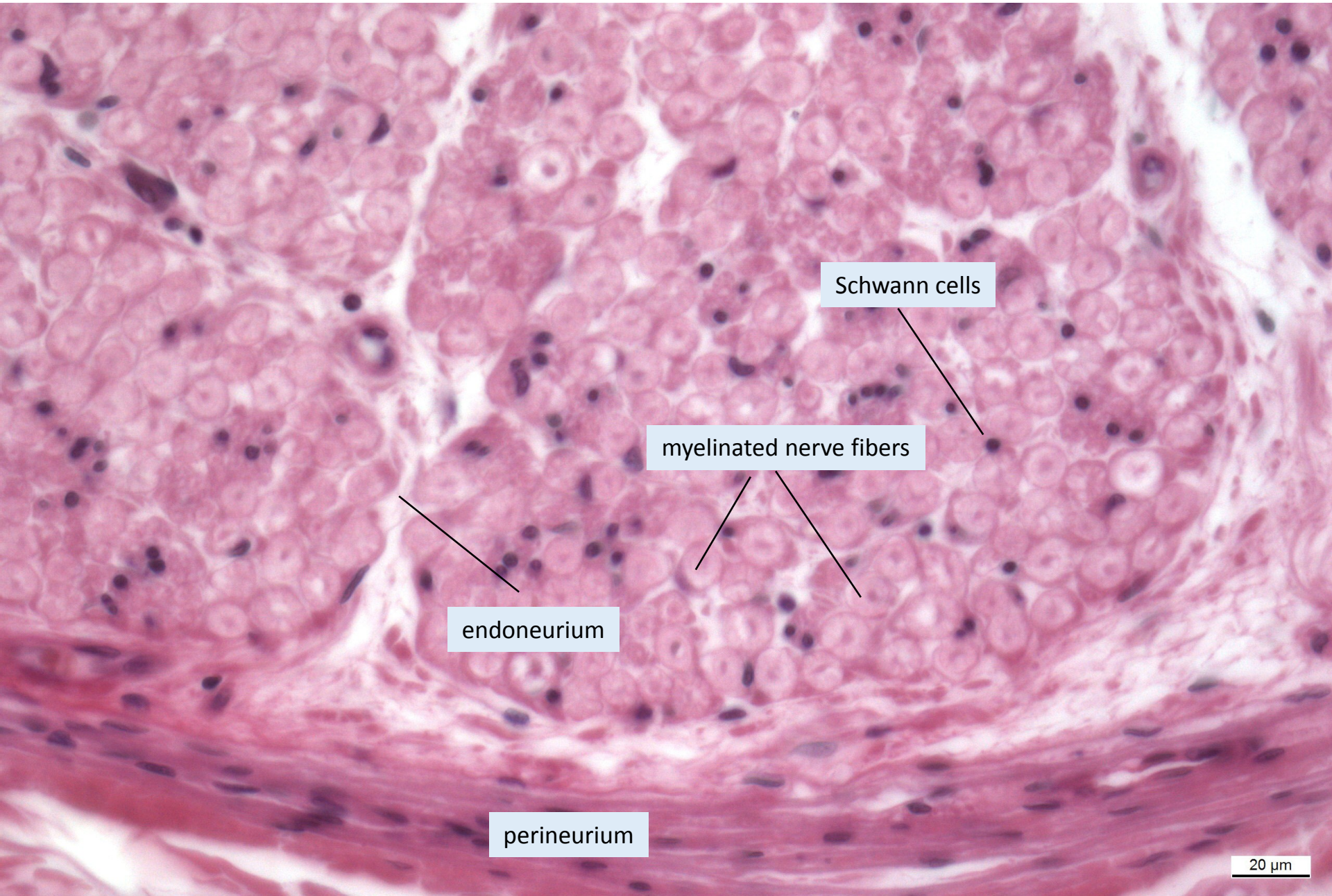
bundles of nerve fibers

perineurium

epineurium

20 μ m

Peripheral nerve



Schwann cells

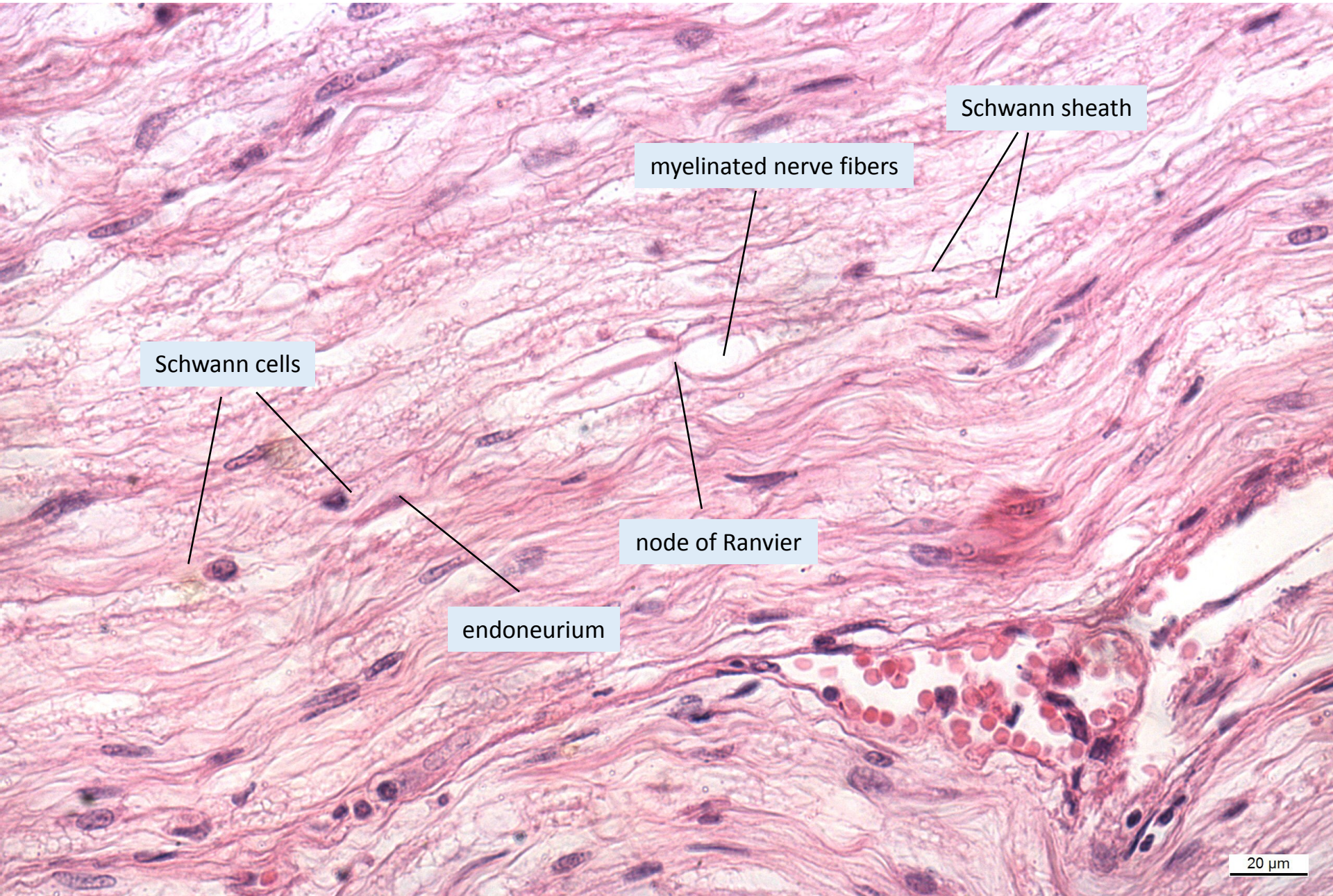
myelinated nerve fibers

endoneurium

perineurium

20 μ m

Peripheral nerve



Schwann cells

myelinated nerve fibers

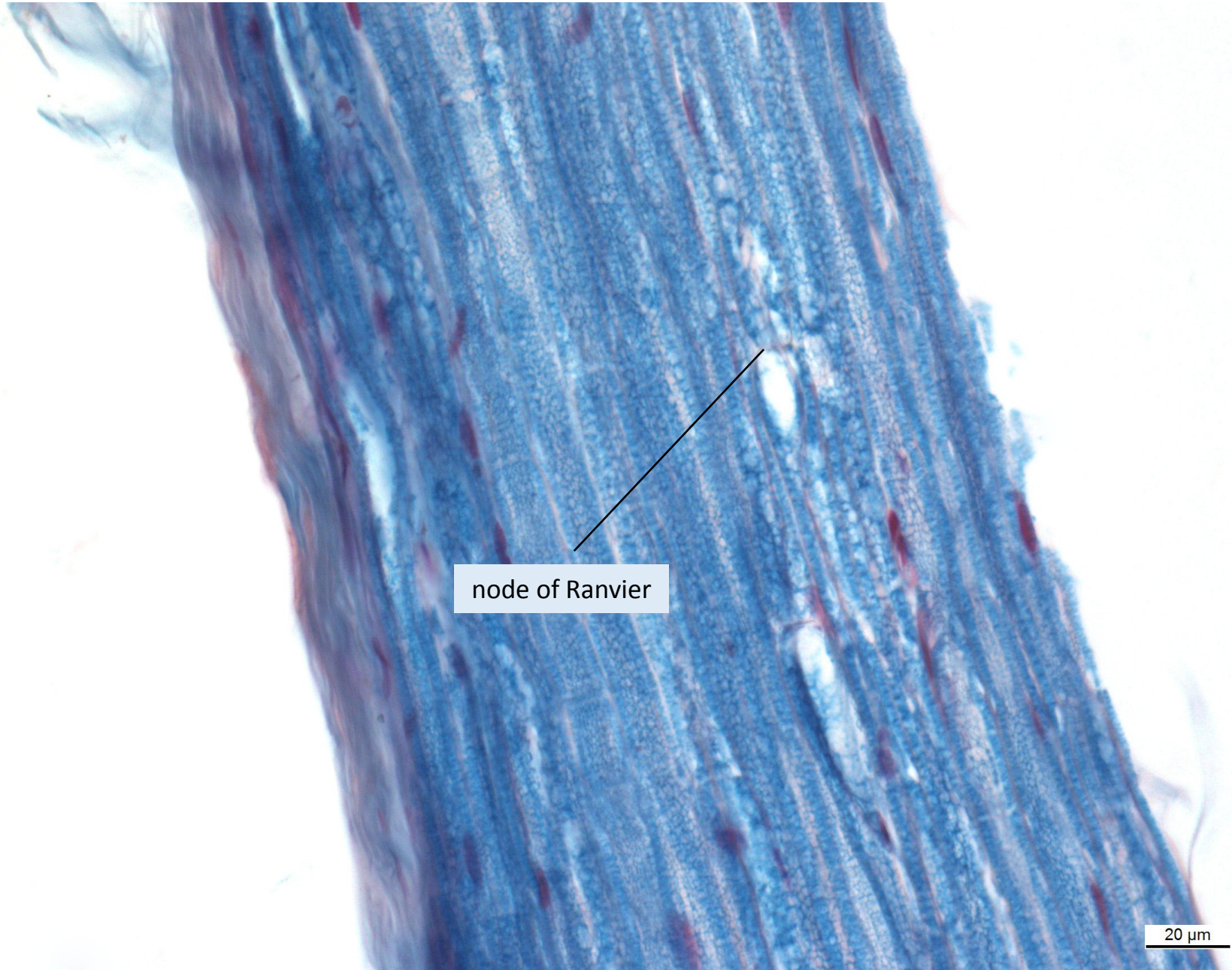
Schwann sheath

node of Ranvier

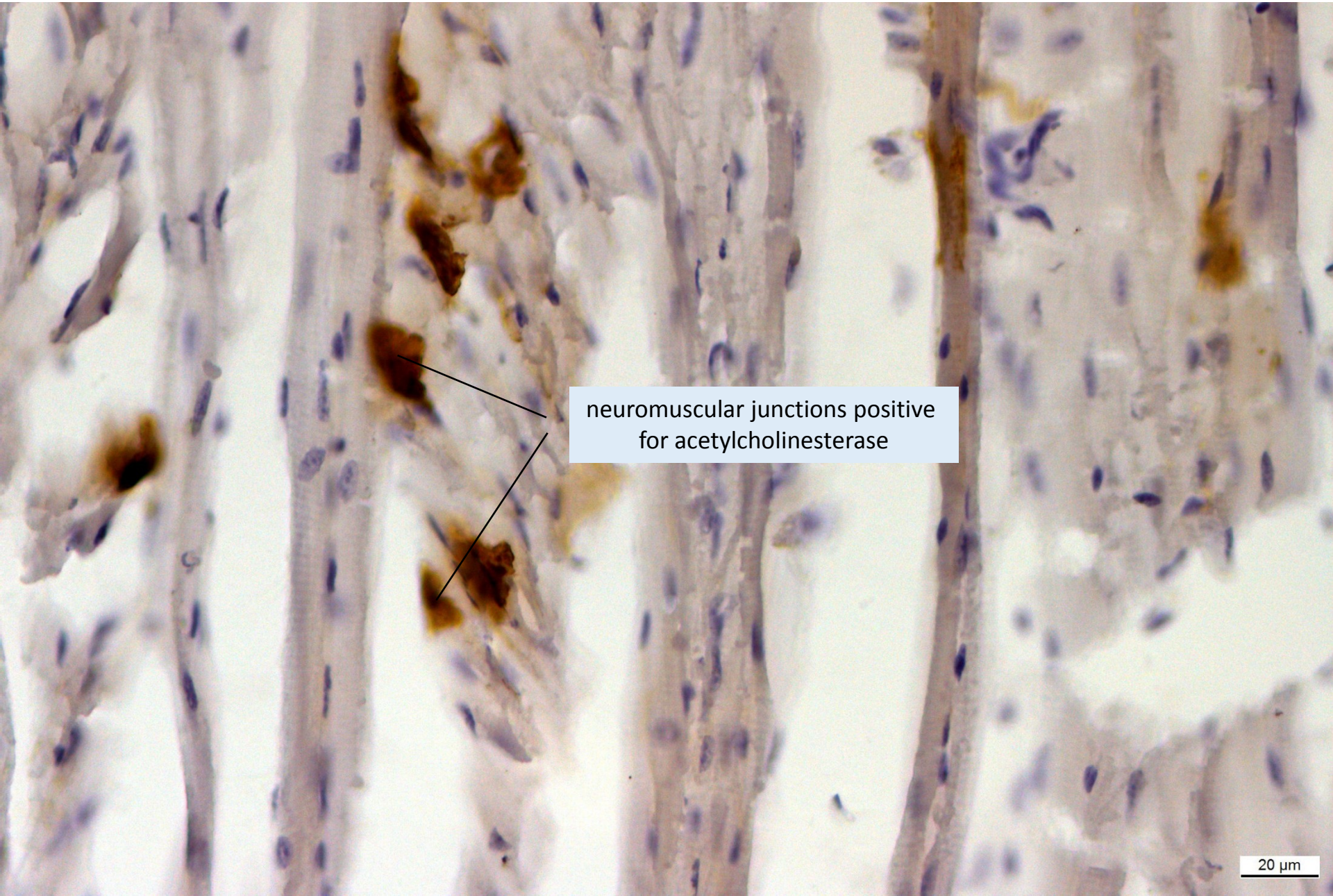
endoneurium

20 μ m

Peripheral nerve



Neuromuscular junction

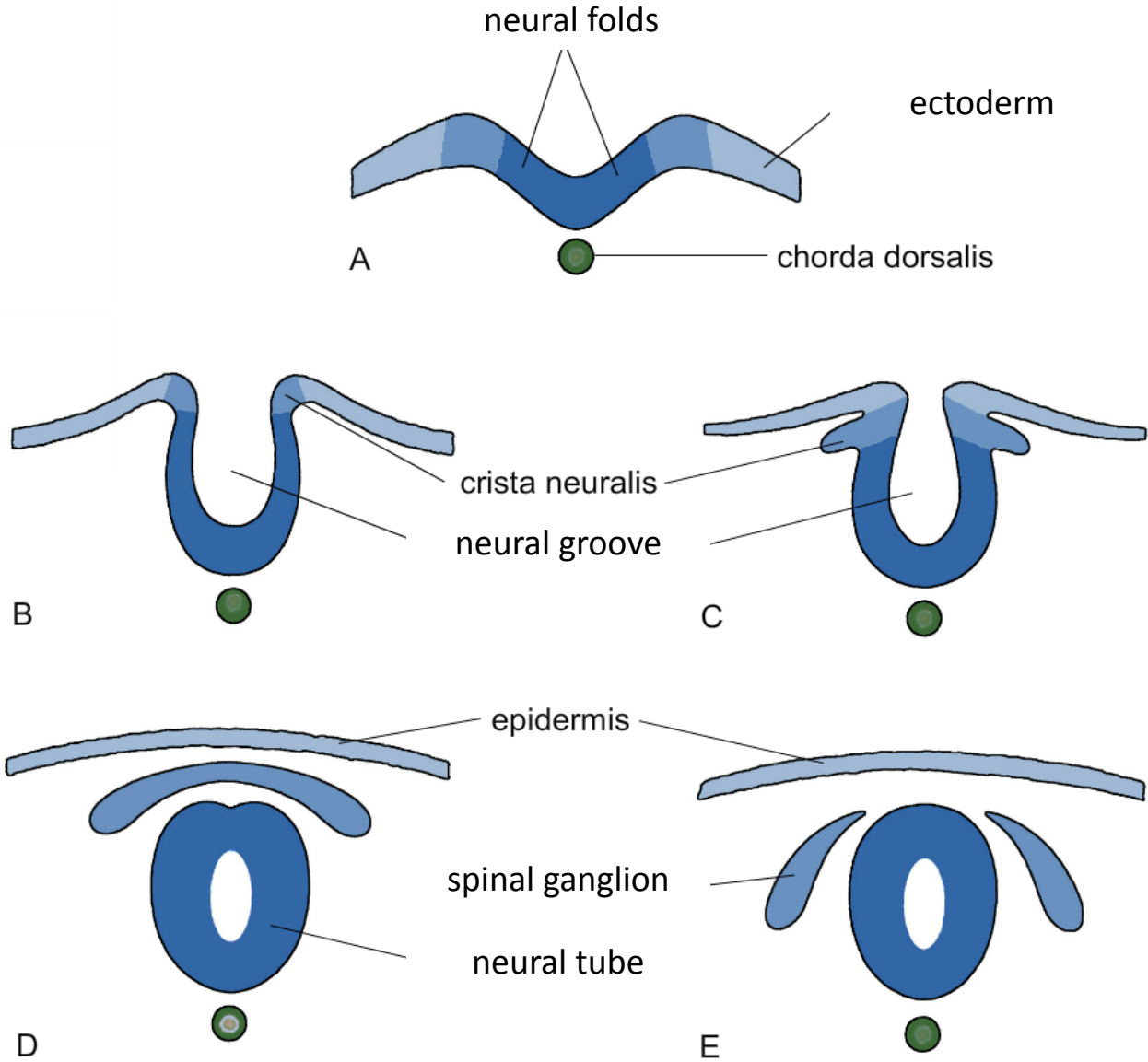


neuromuscular junctions positive
for acetylcholinesterase

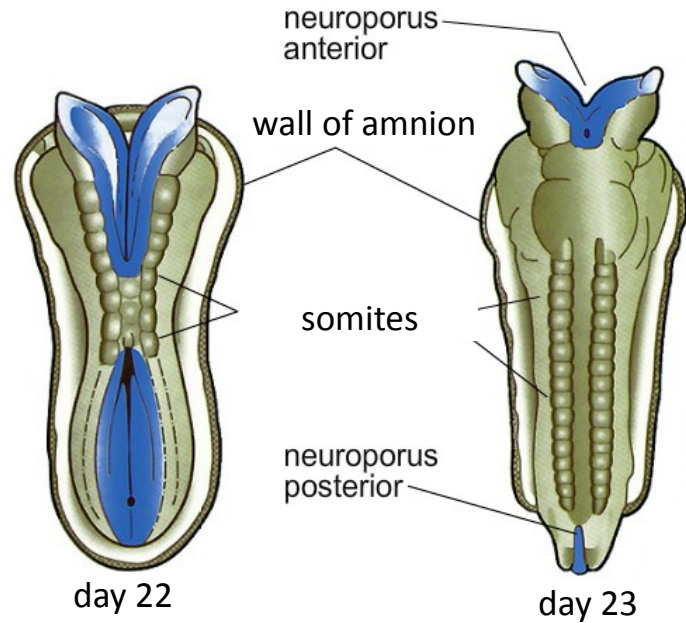
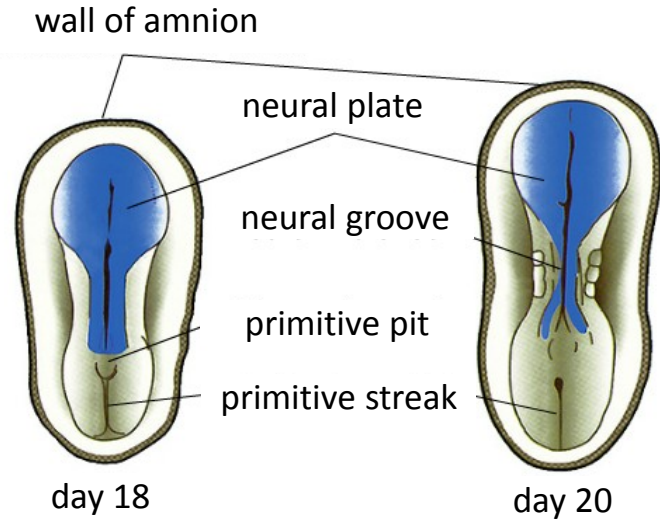
List of slides

- 75. Cortex cerebri
- 76. Cortex cerebri (impregnation)
- 77. Cerebellum (impregnation)
- 78. Cerebellum (Nissl substance)
- 79. Medulla spinalis
- 80. Plexus choroideus
- 81. Ganglion spinale
- 82. Ganglion spinale (impregnation)
- 83. Ganglion autonomic
- 84. Peripheral nerve – cross section
- 85. Peripheral nerve – cross section (myelin)
- 86. Peripheral nerve – longitudinal section
- 87. Peripheral nerve – longitudinal section (myelin)

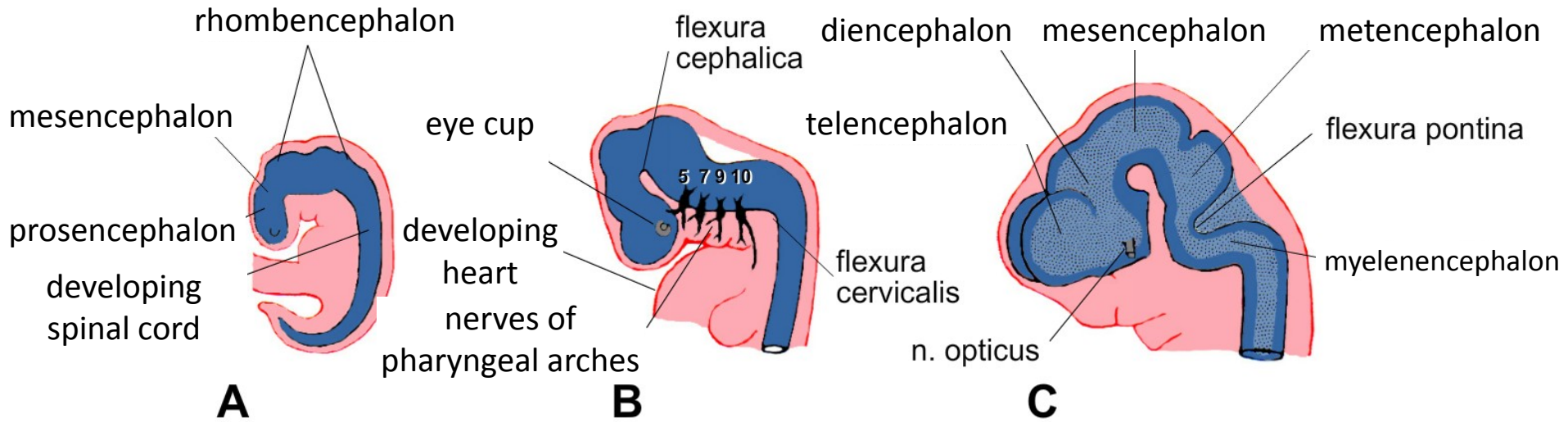
Development of neural tube



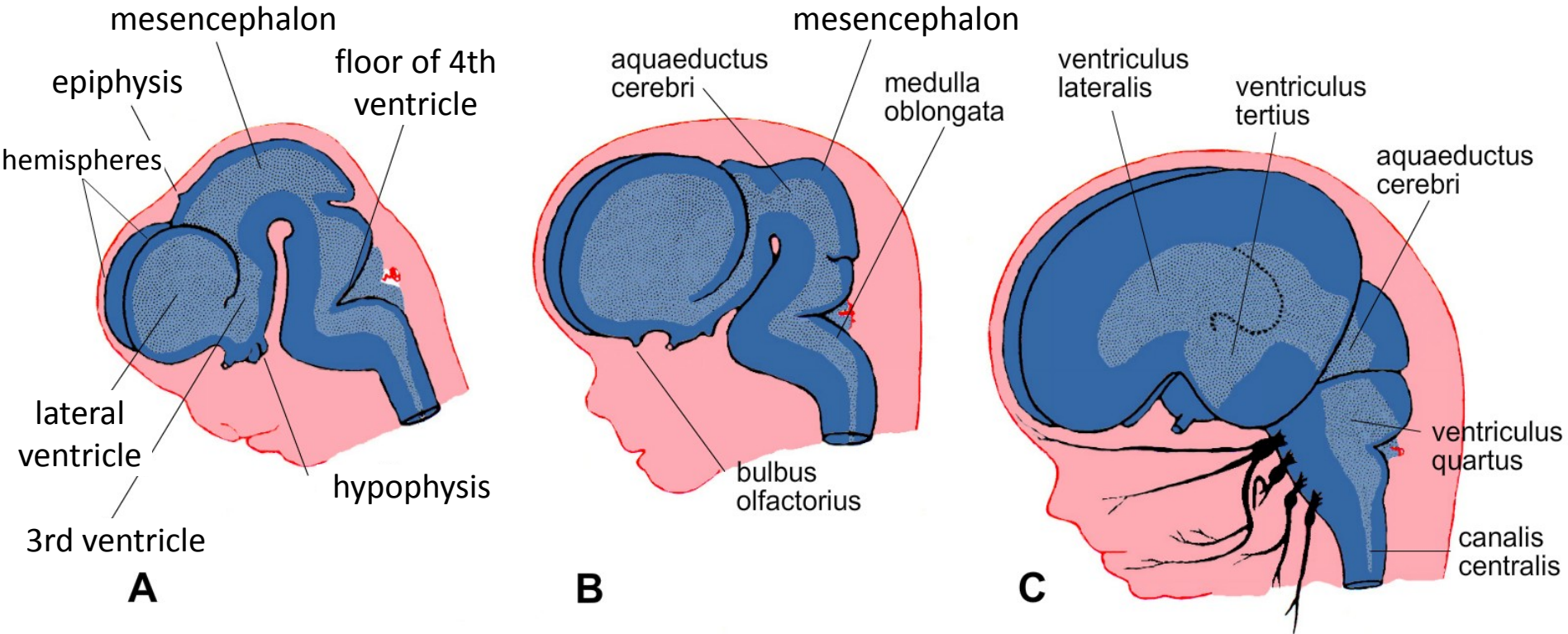
Closing of neural tube



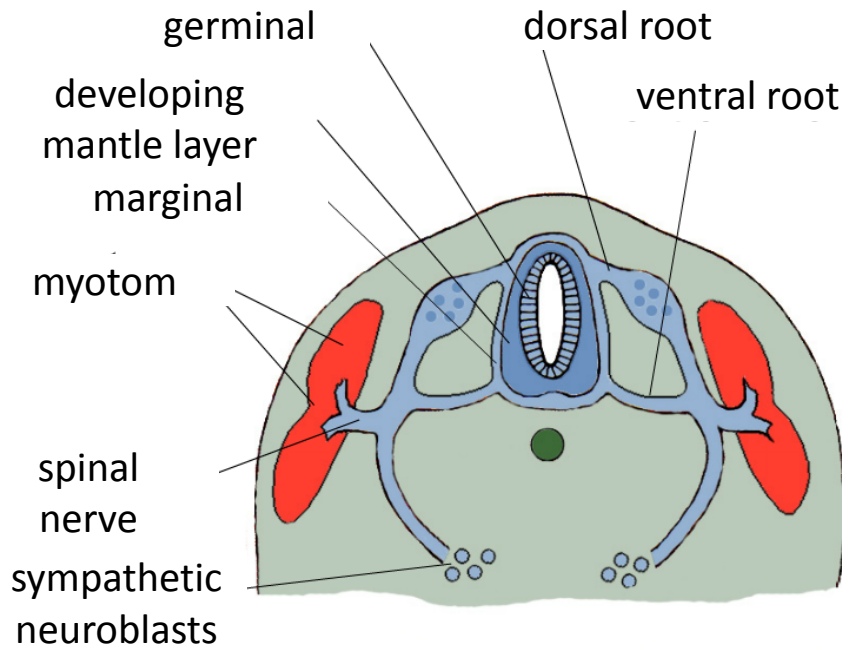
Development of brain



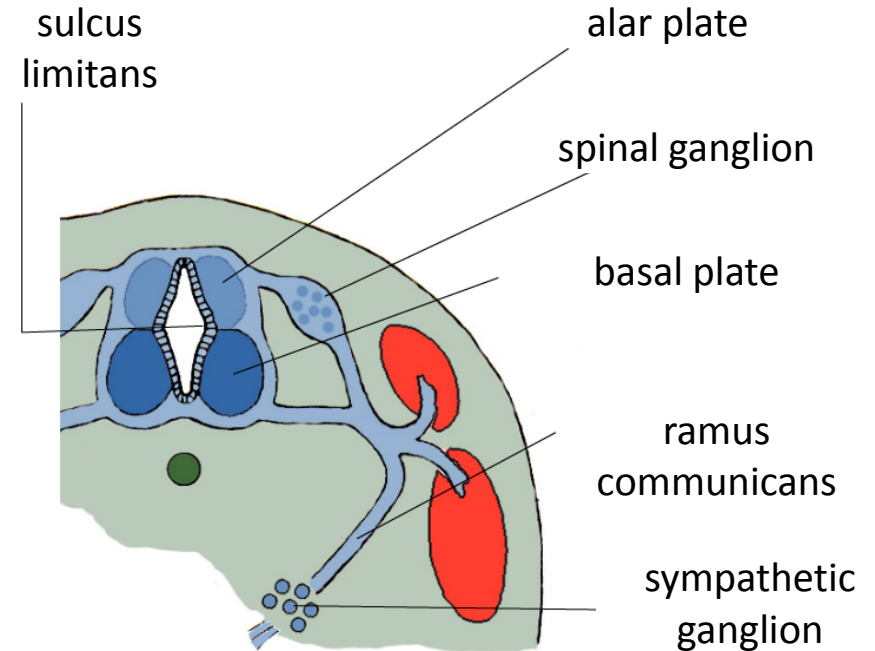
Development of brain



Development of spinal cord



A



B