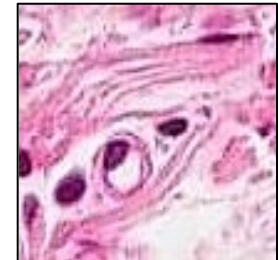

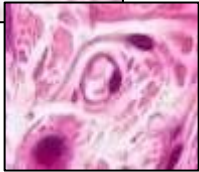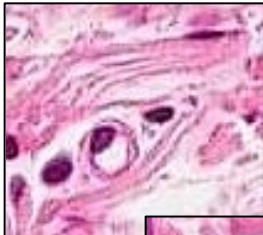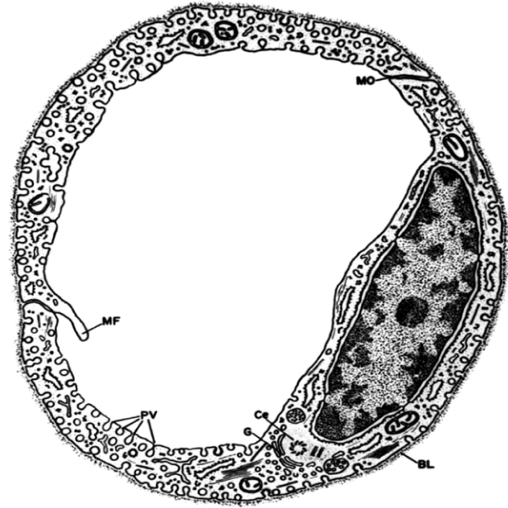


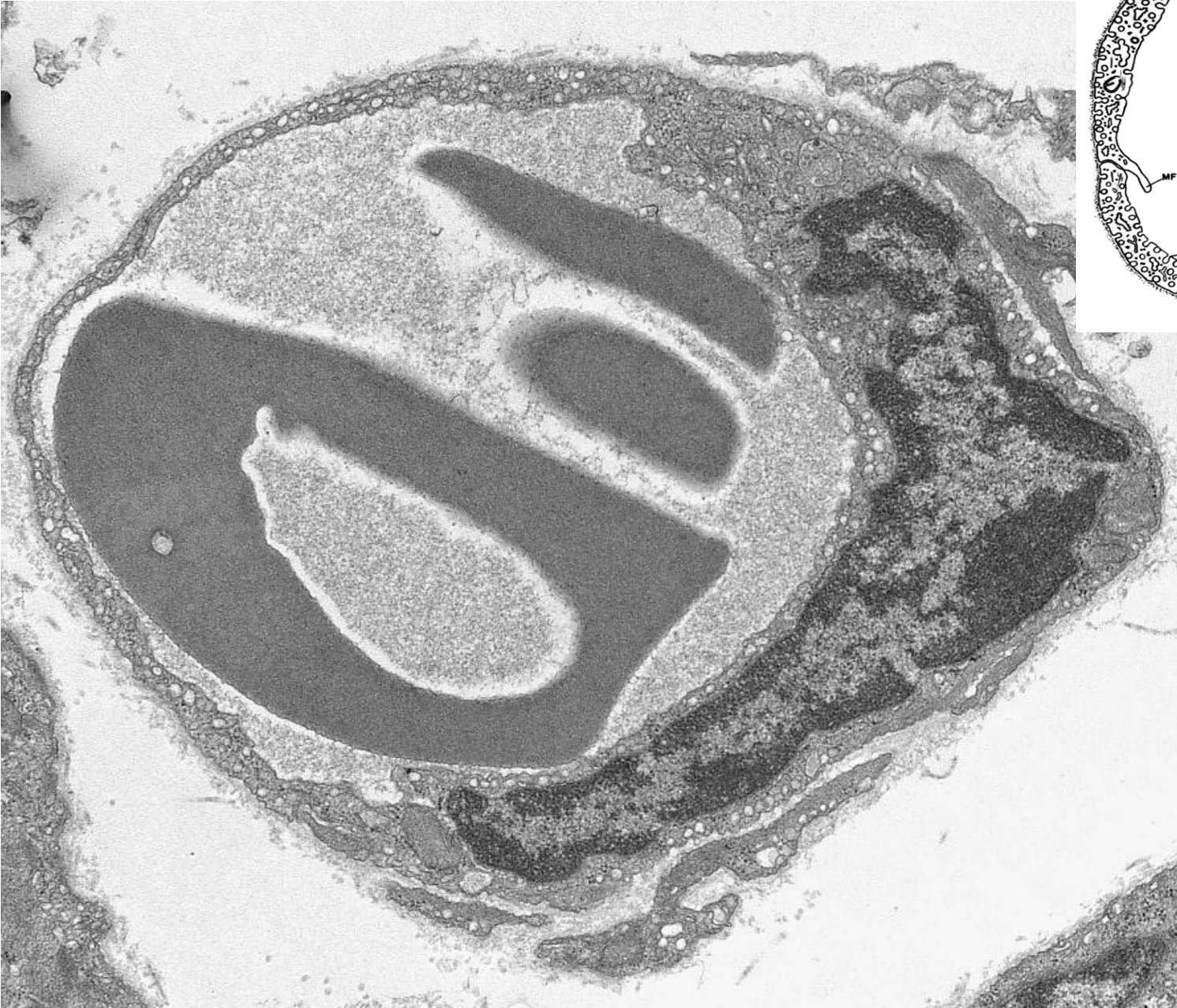CARDIOVASCULAR SYSTEM

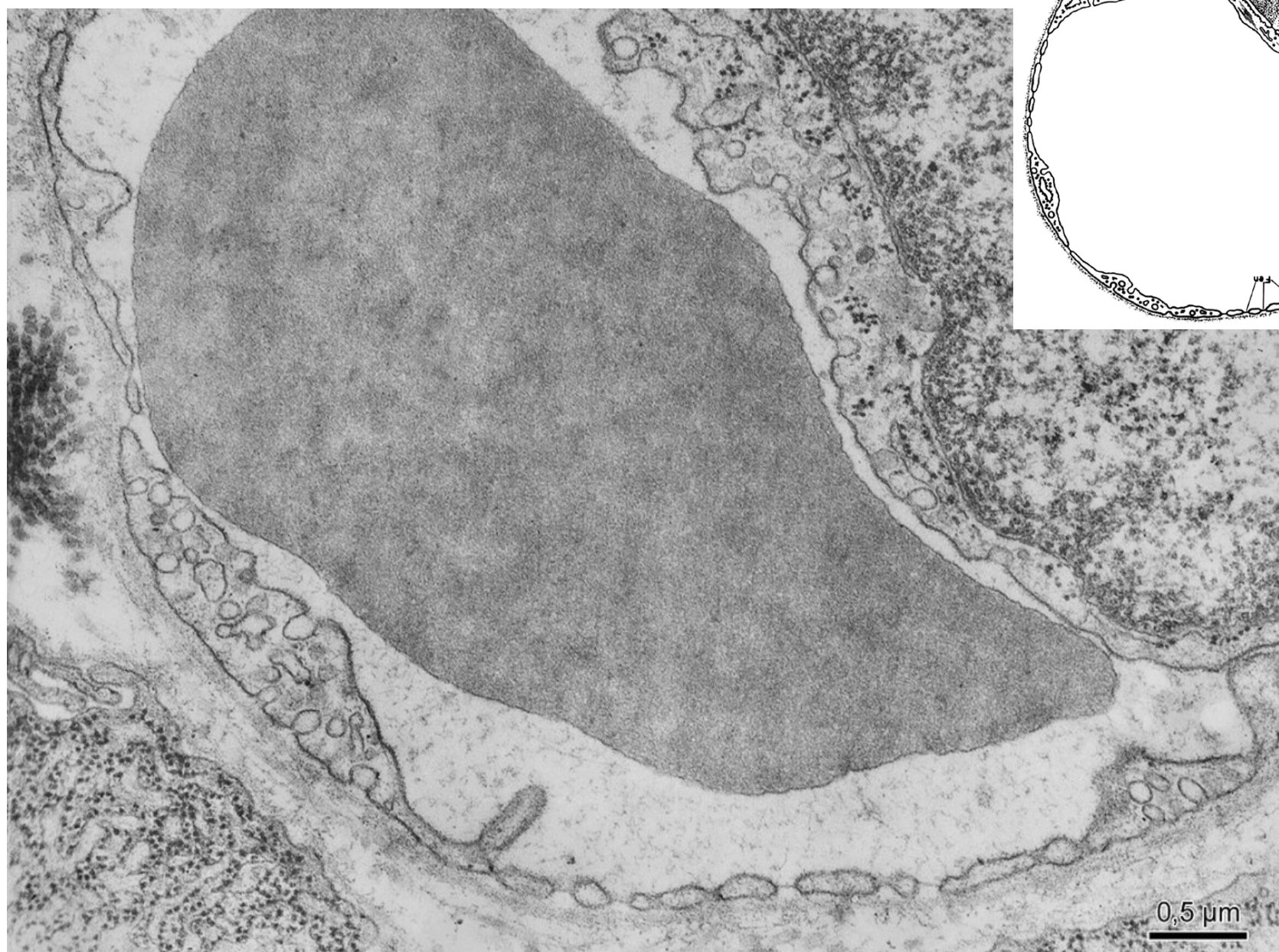
- Heart
- Vessels
 - arteries
 - veins
 - capillaries
 - continuous
 - fenestrated
 - sinusoids



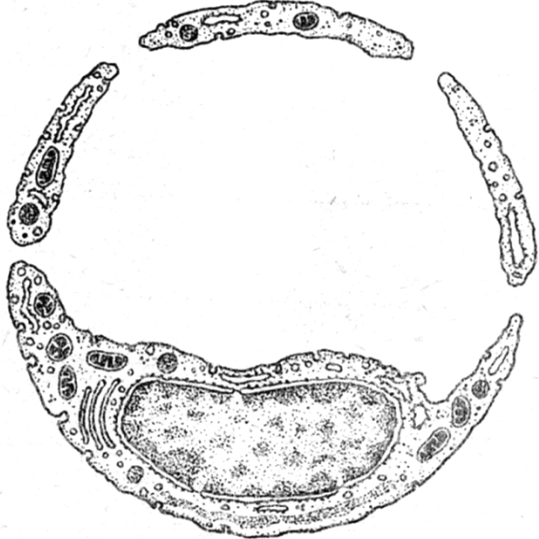
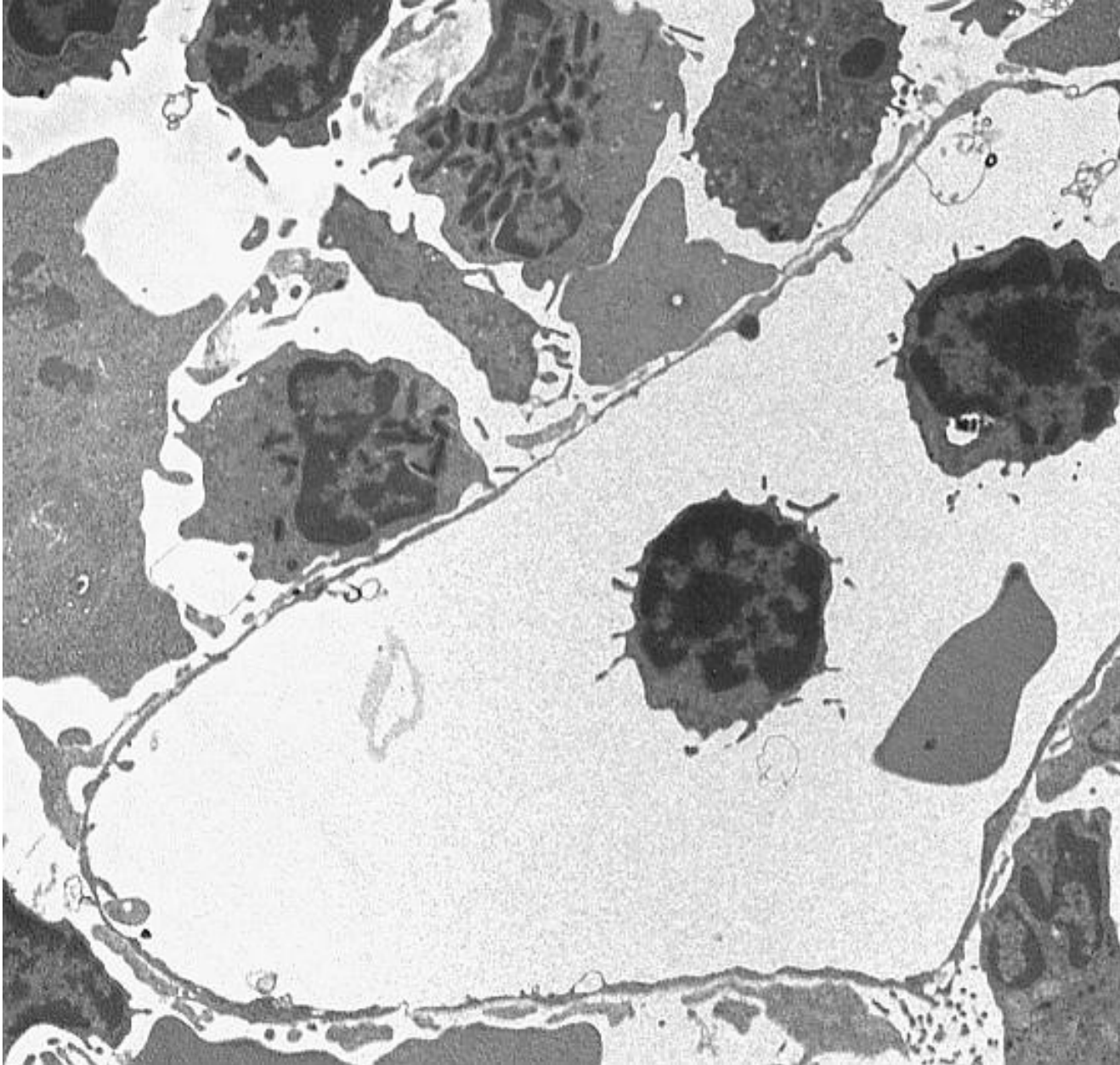
Continuous capillary



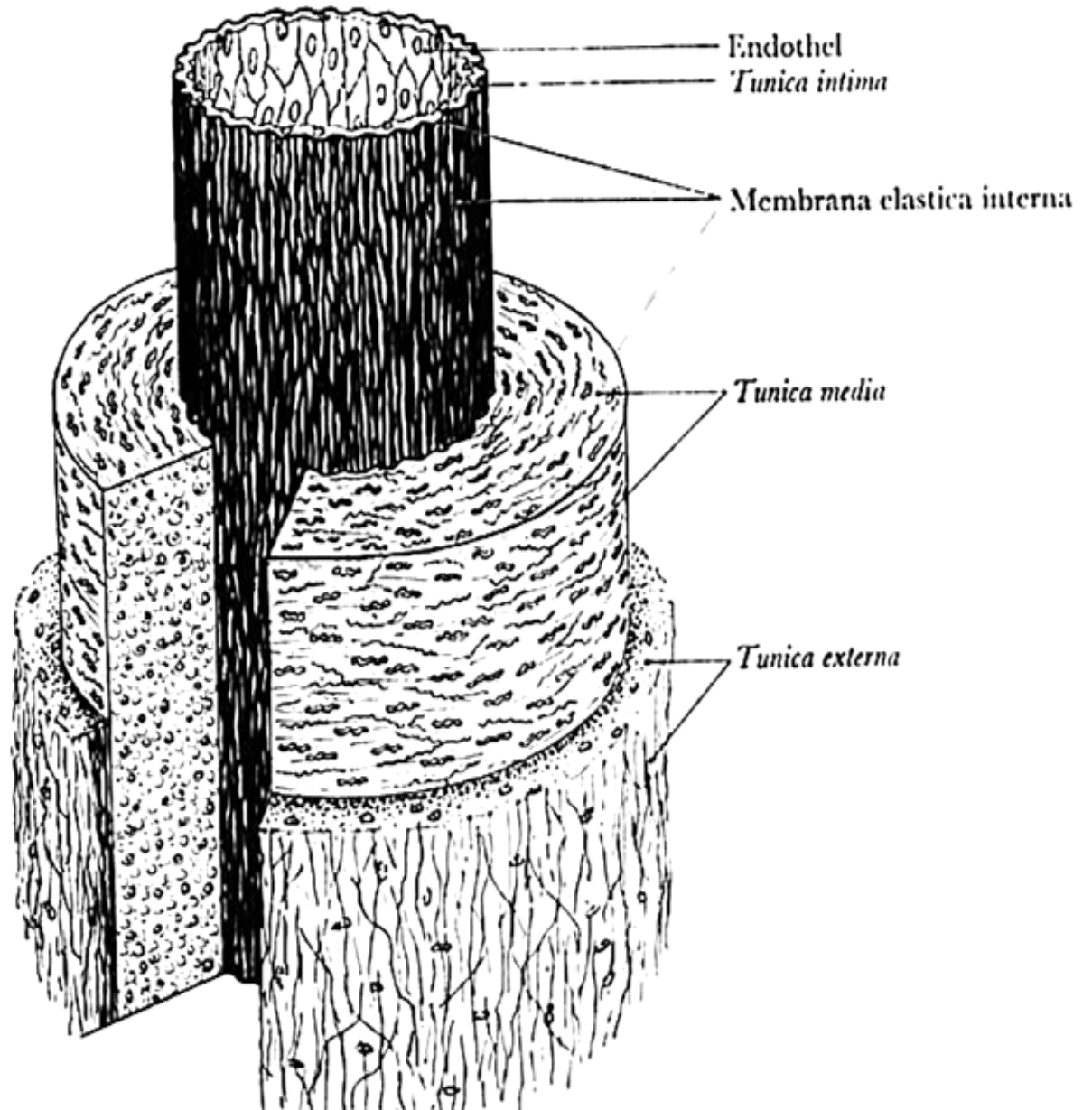
Fenestrated capillary



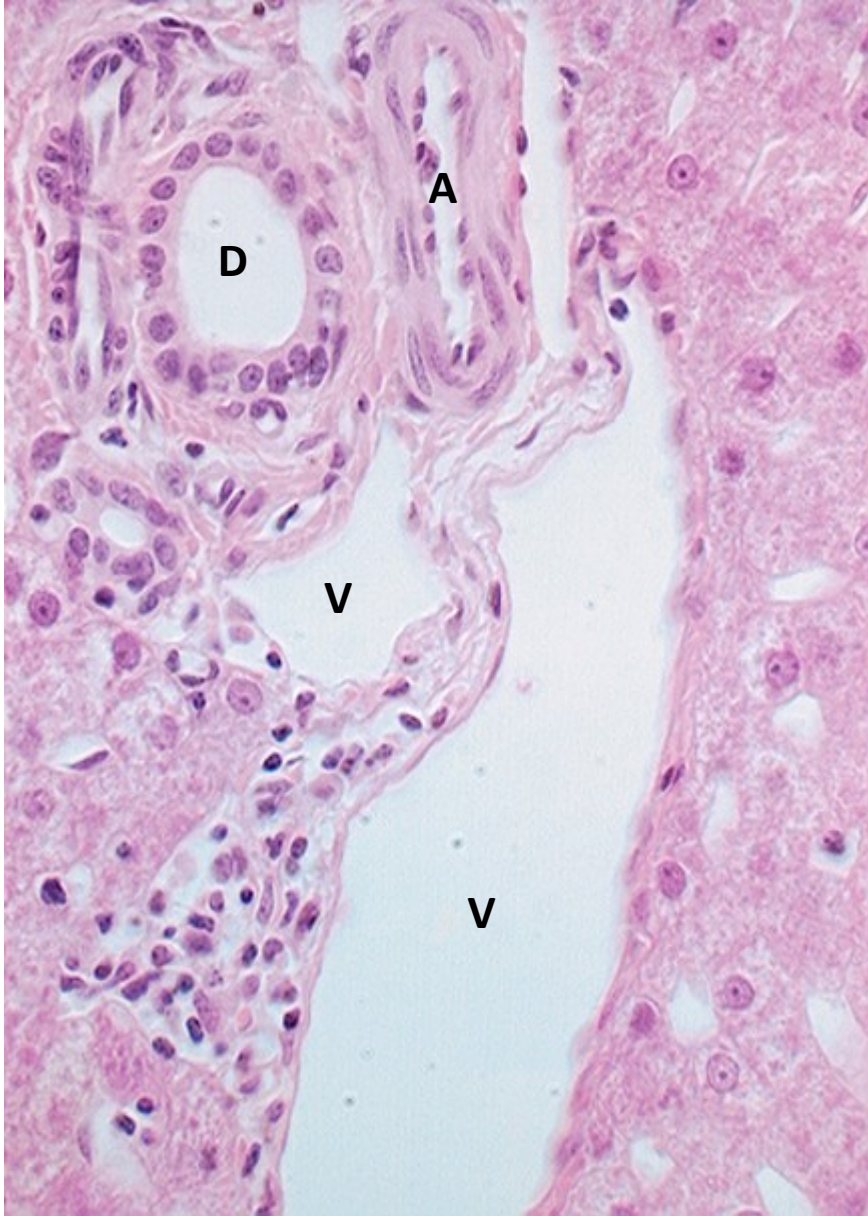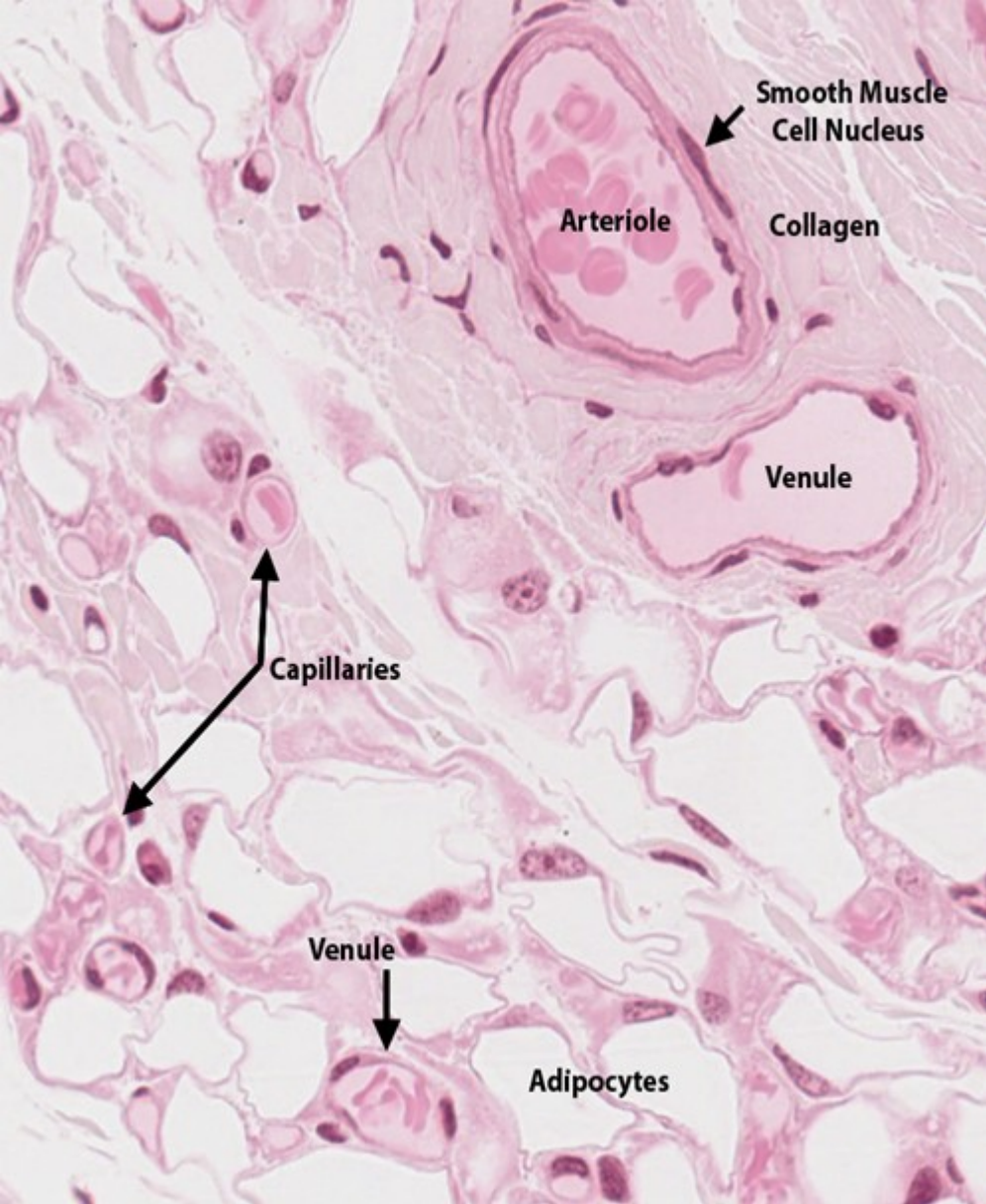
Sinusoid



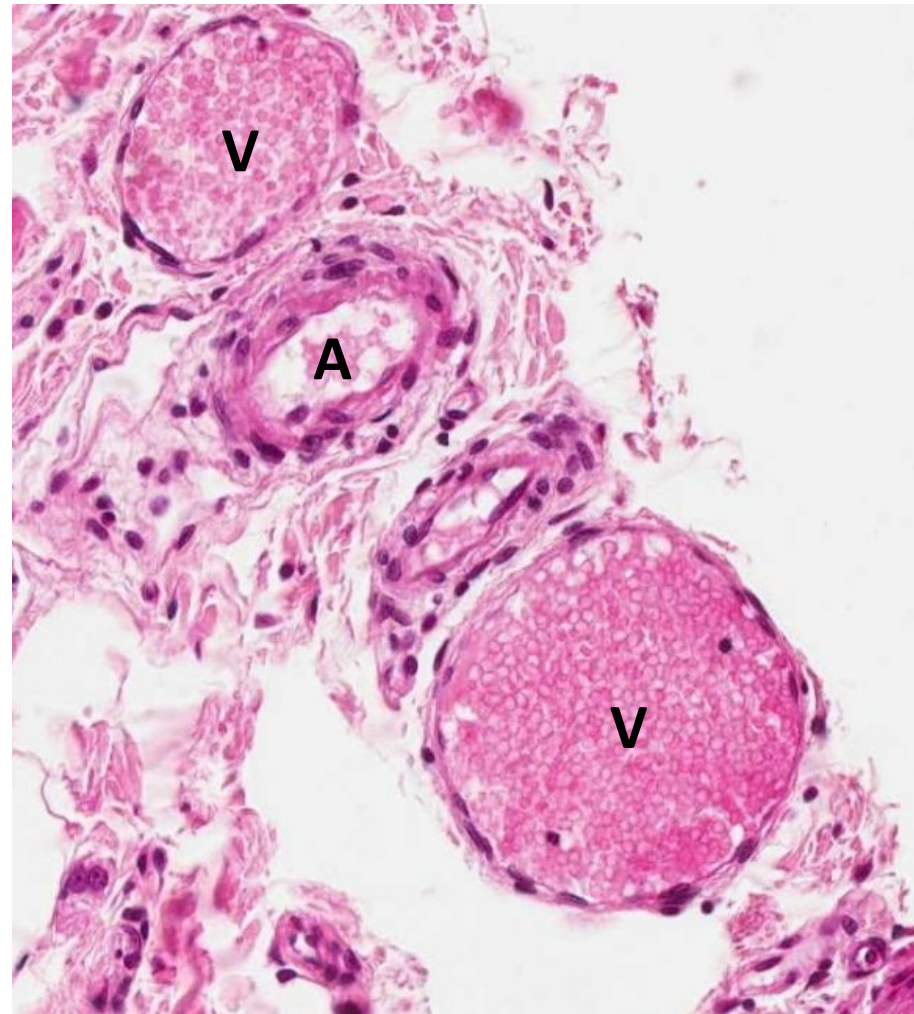
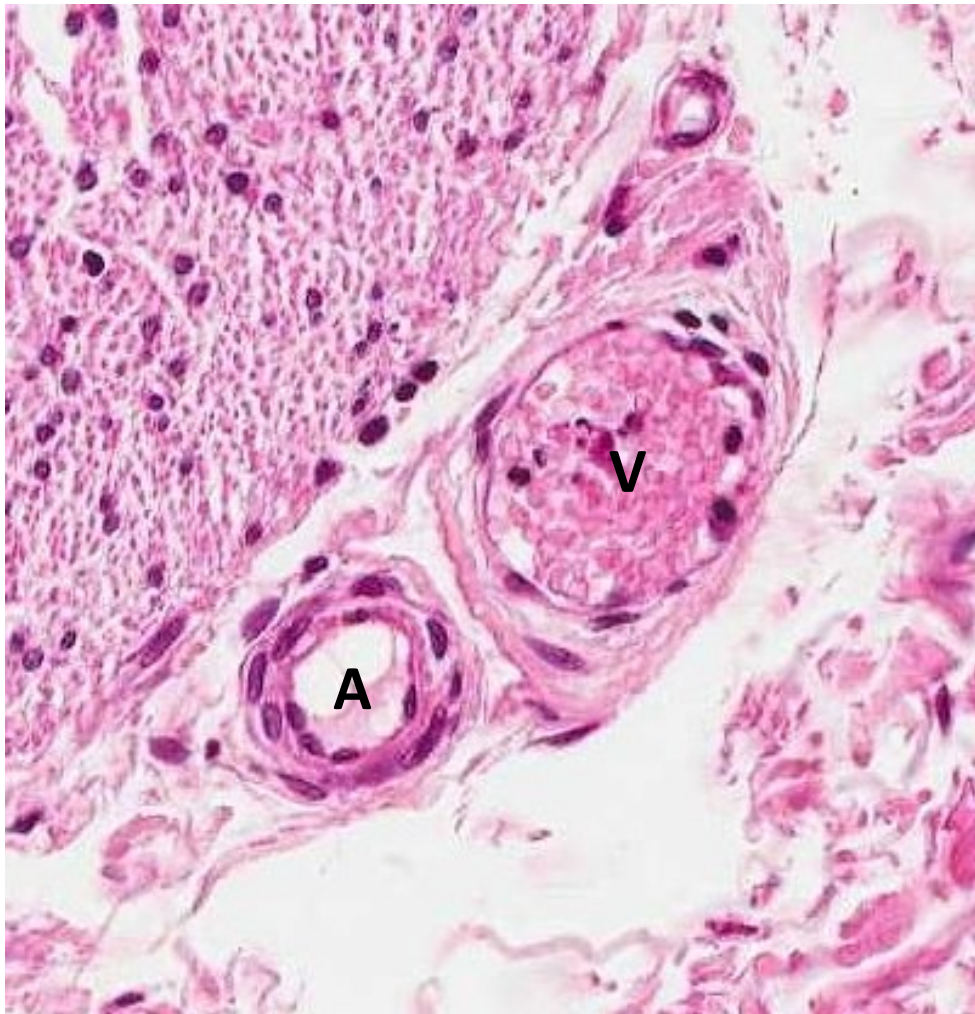
General structure of blood vessels



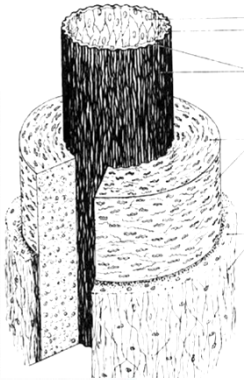
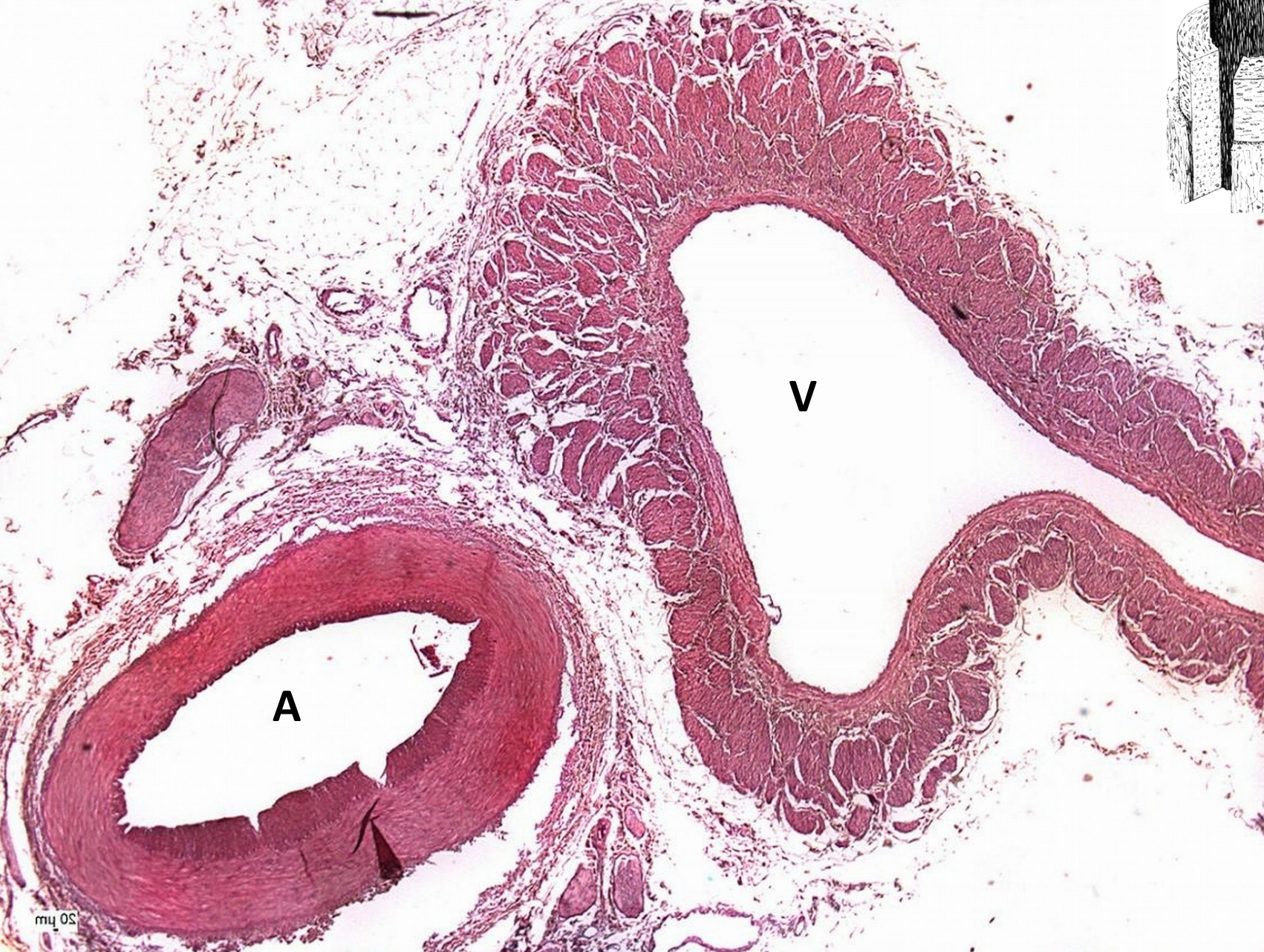capillaries, arterioles, venules [endothelium], ducts [epithelium]



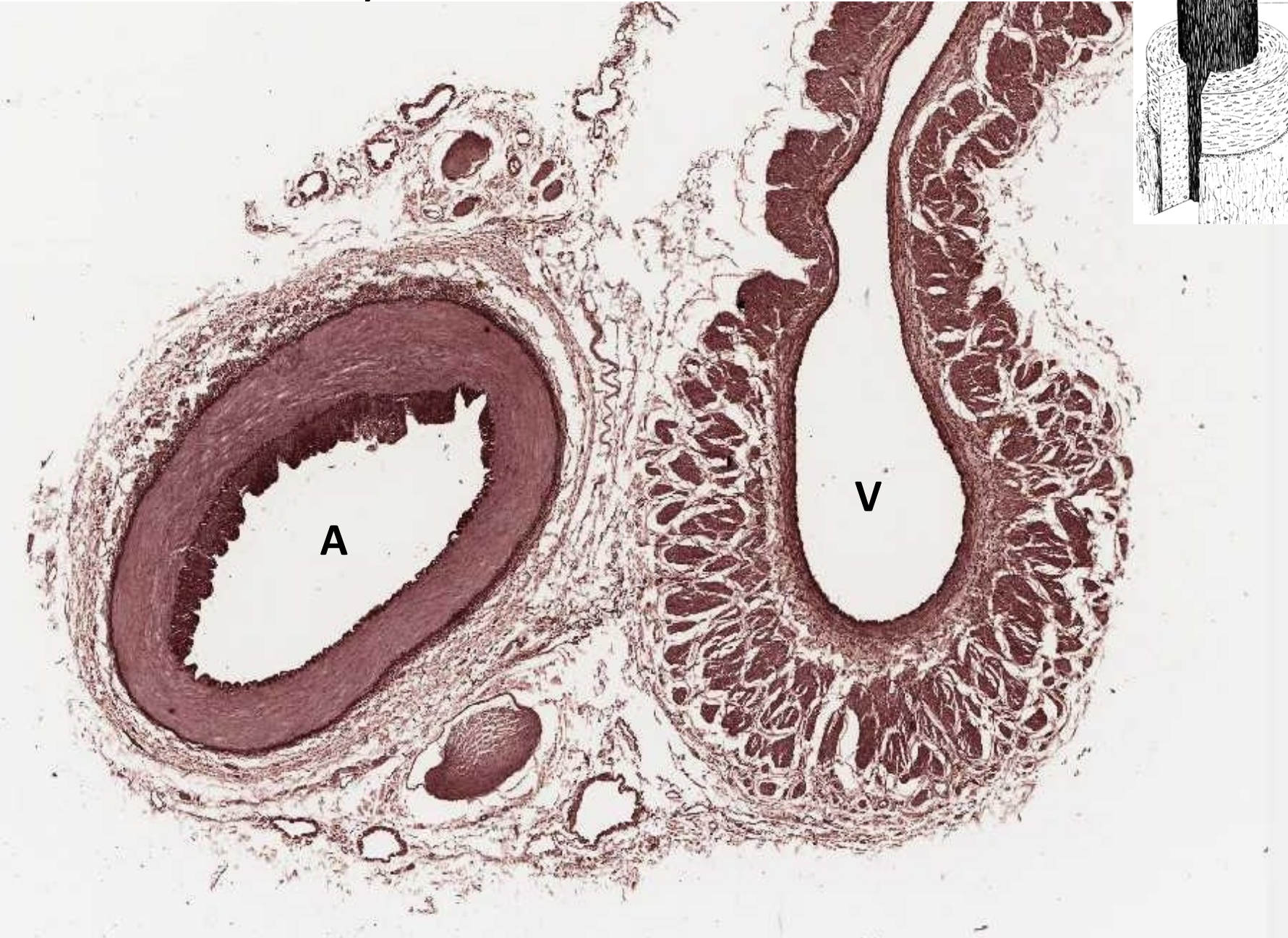
arteriole and venule



muscular artery and vein - HE



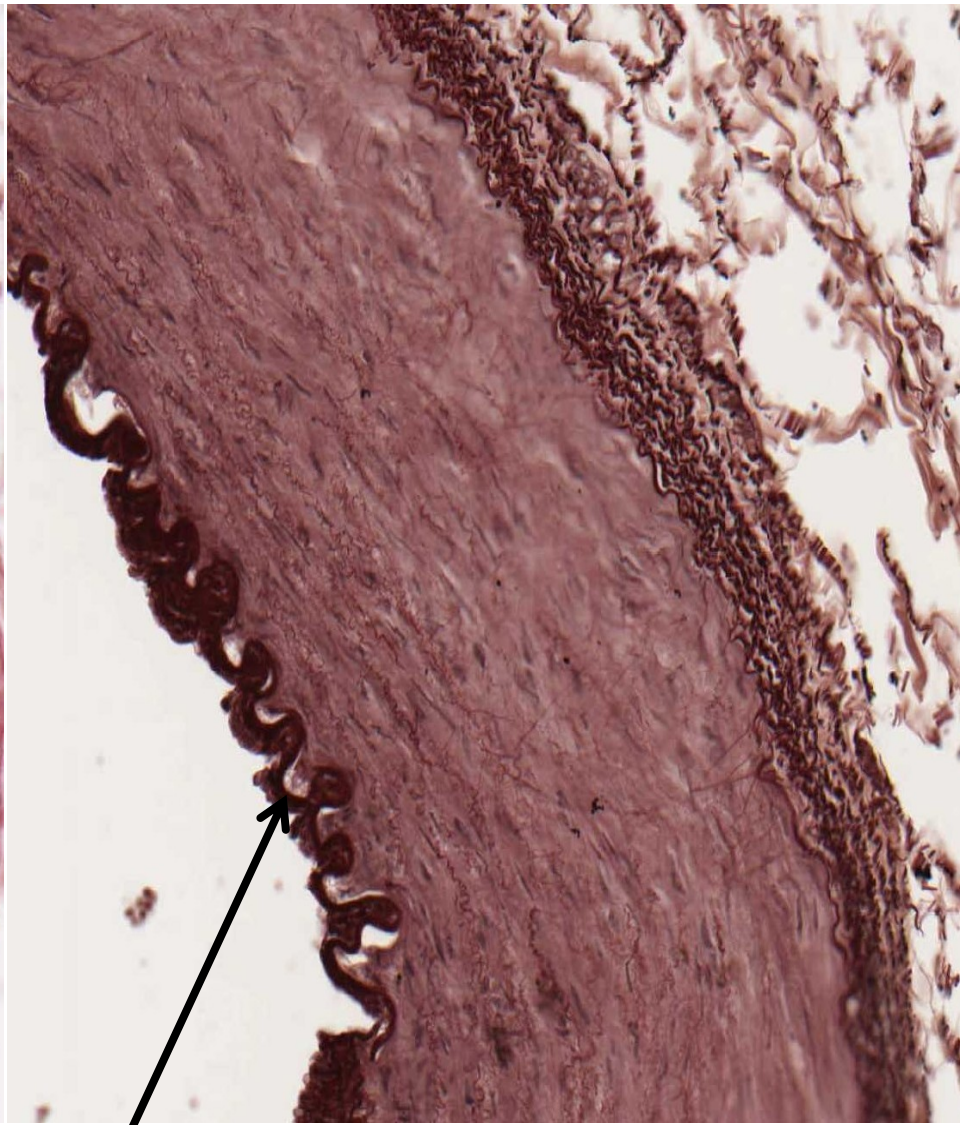
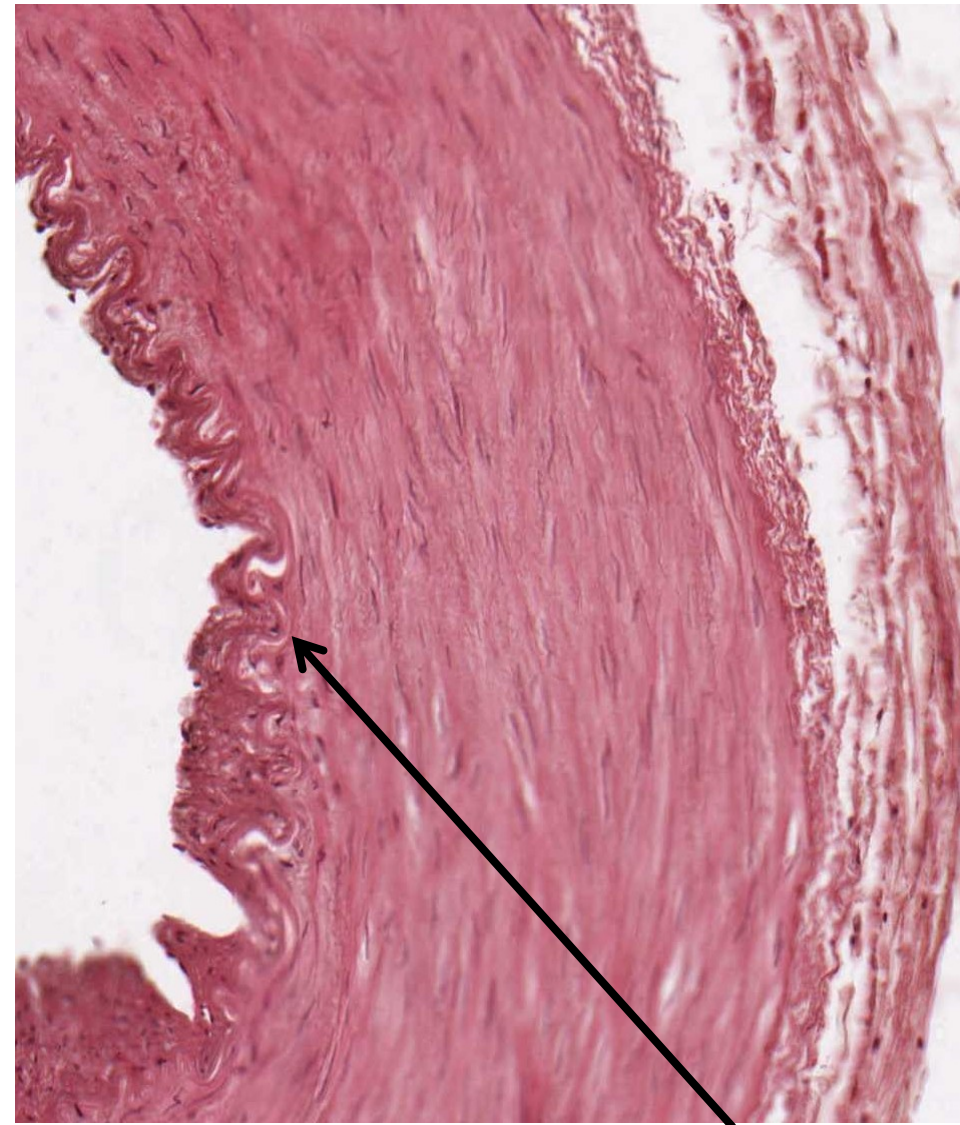muscular artery and vein - orcein



muscular artery

HE

orcein

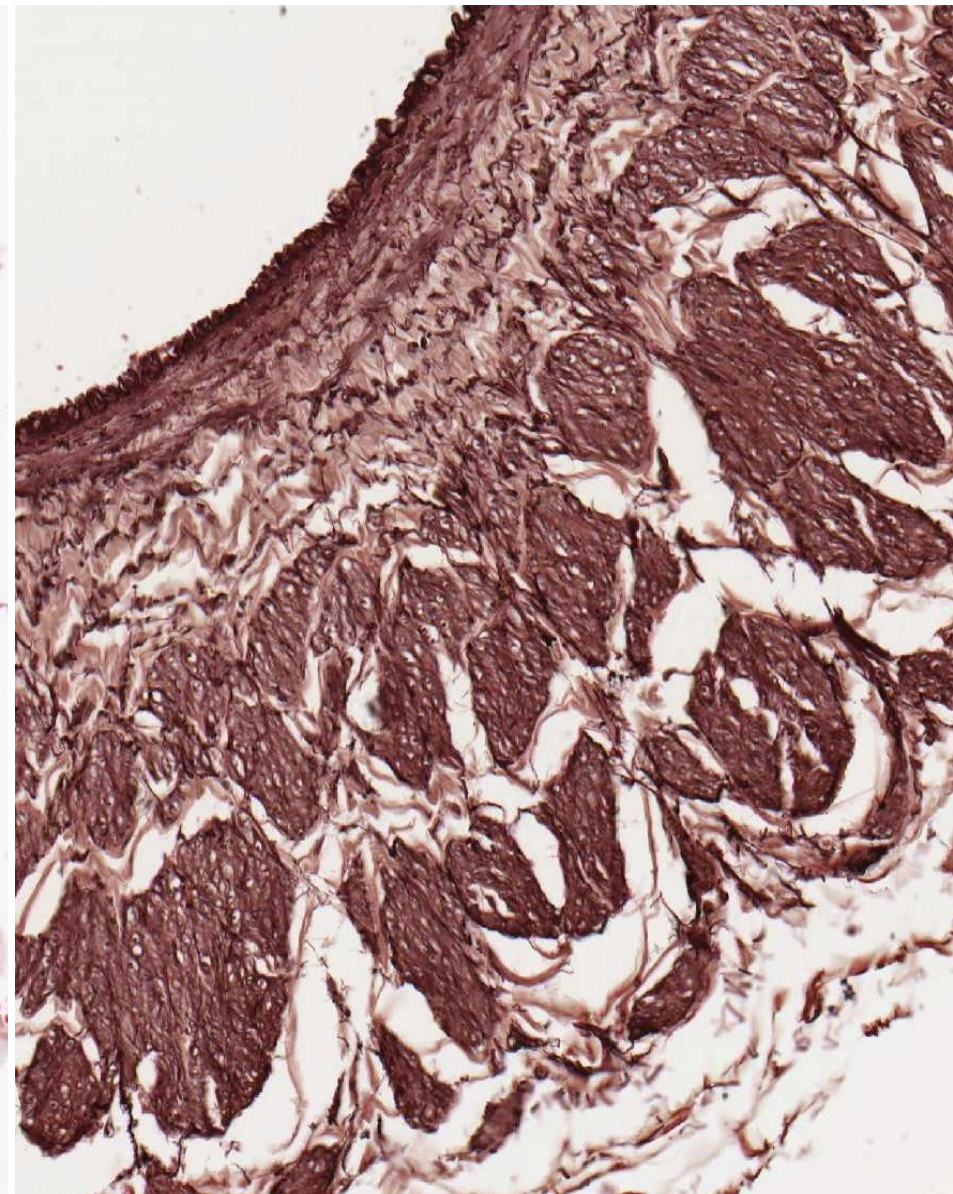
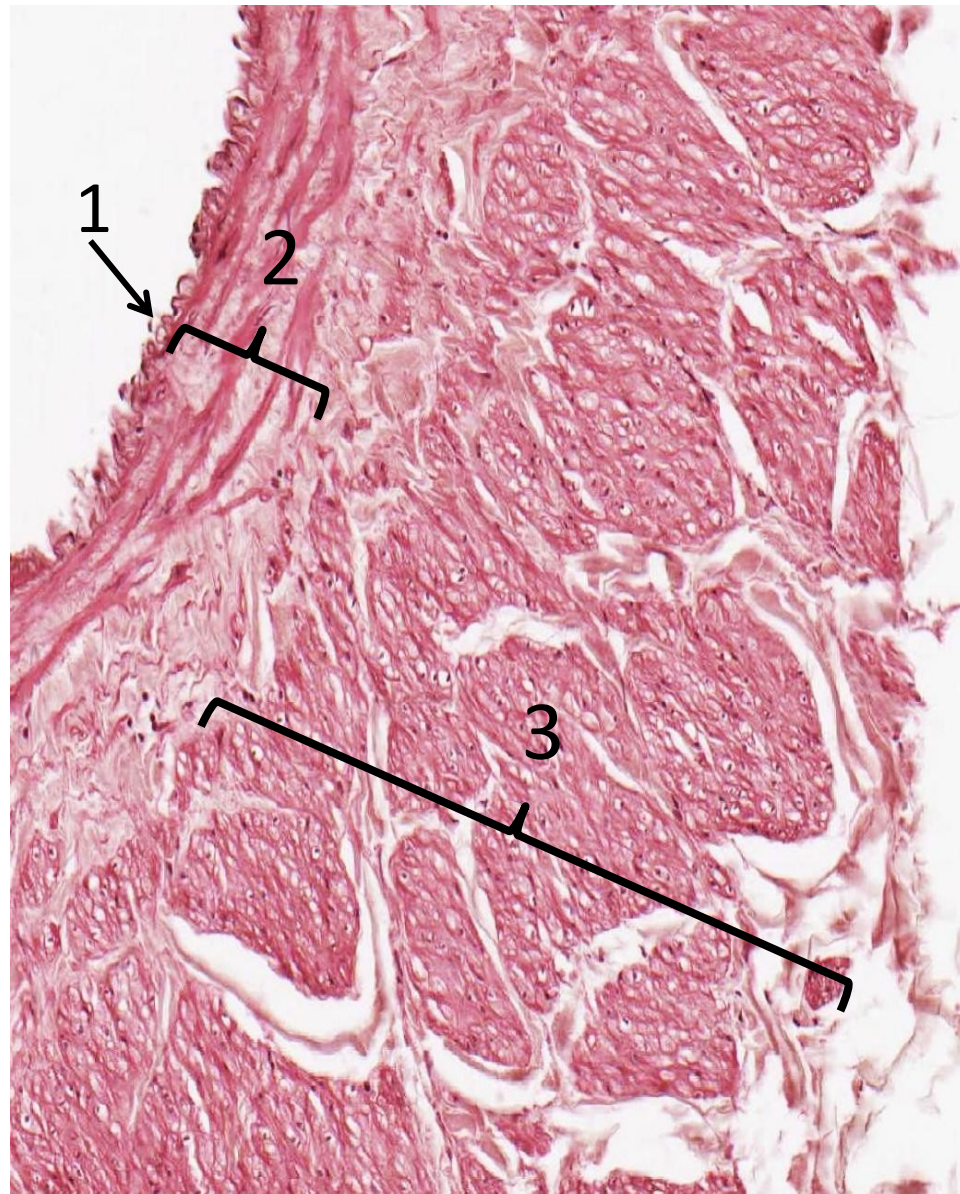


membrana elastica interna

vein (1-intima, 2-media, 3-adventitia)

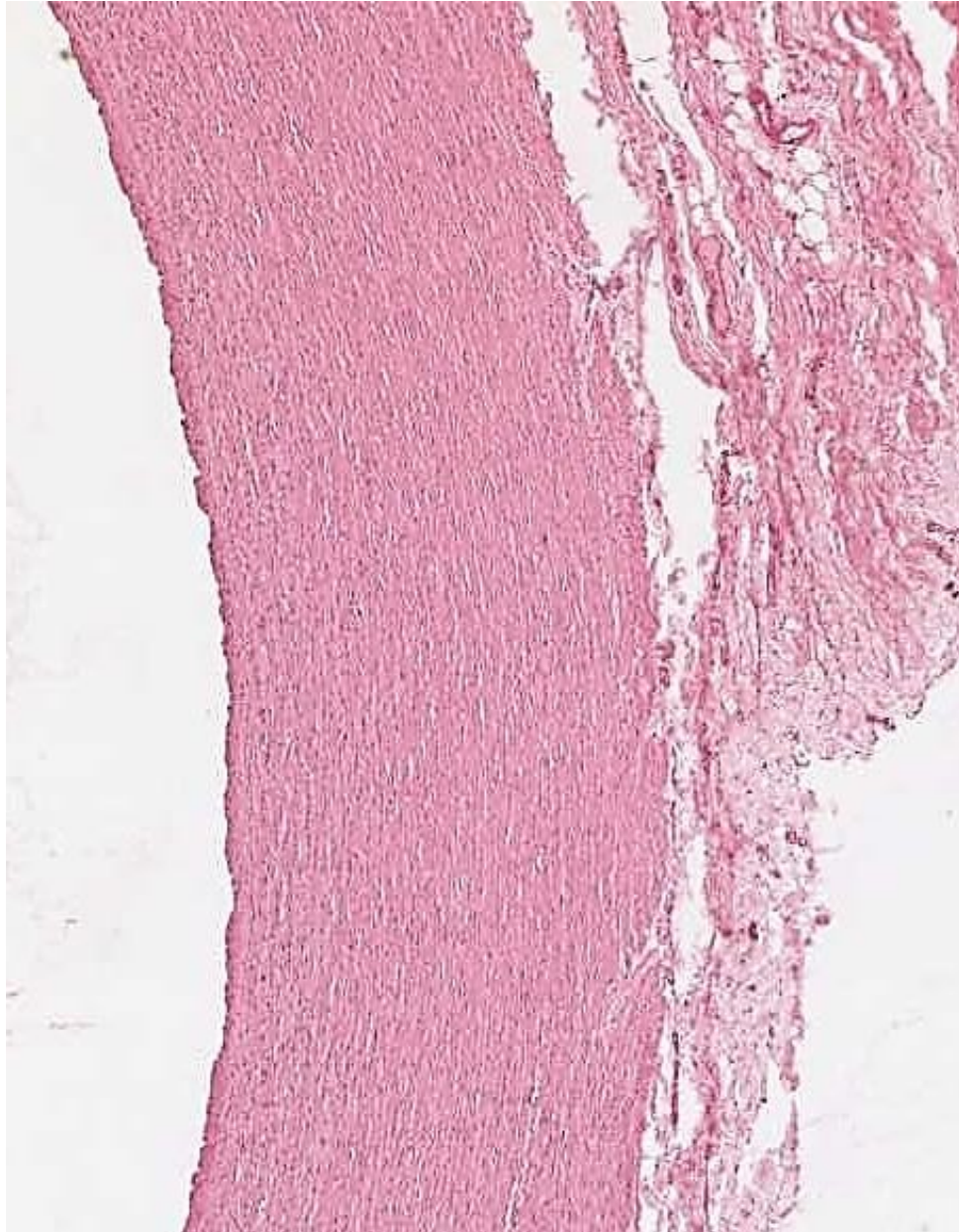
HE

orcein

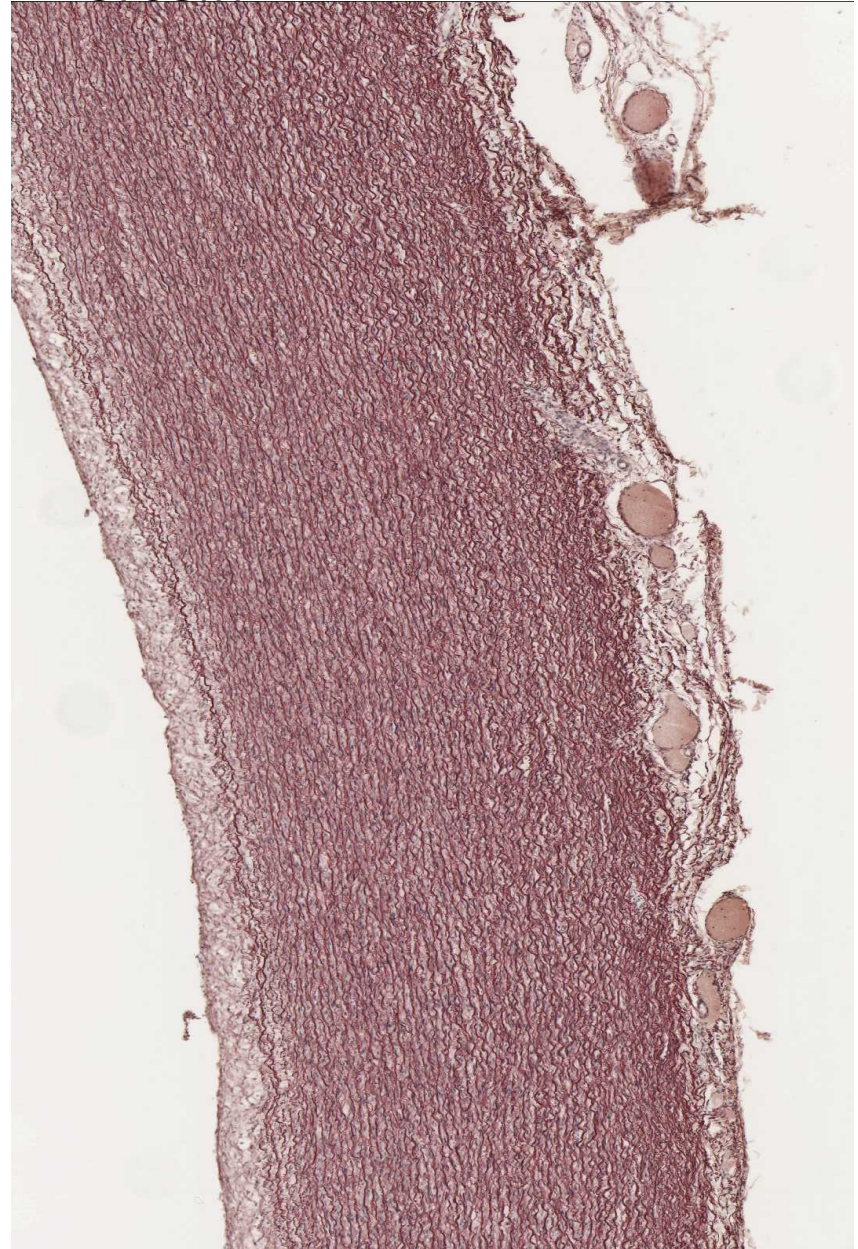


aorta

HE

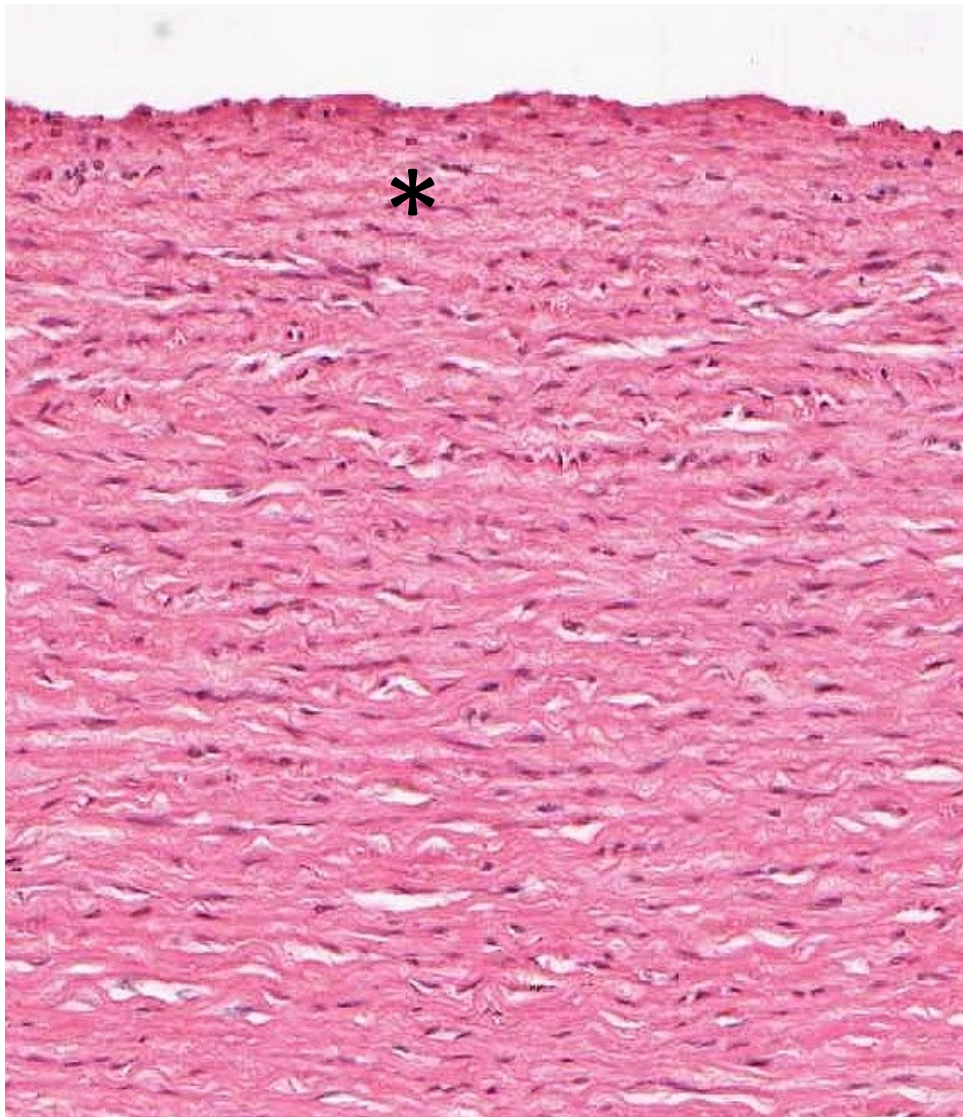


orcein

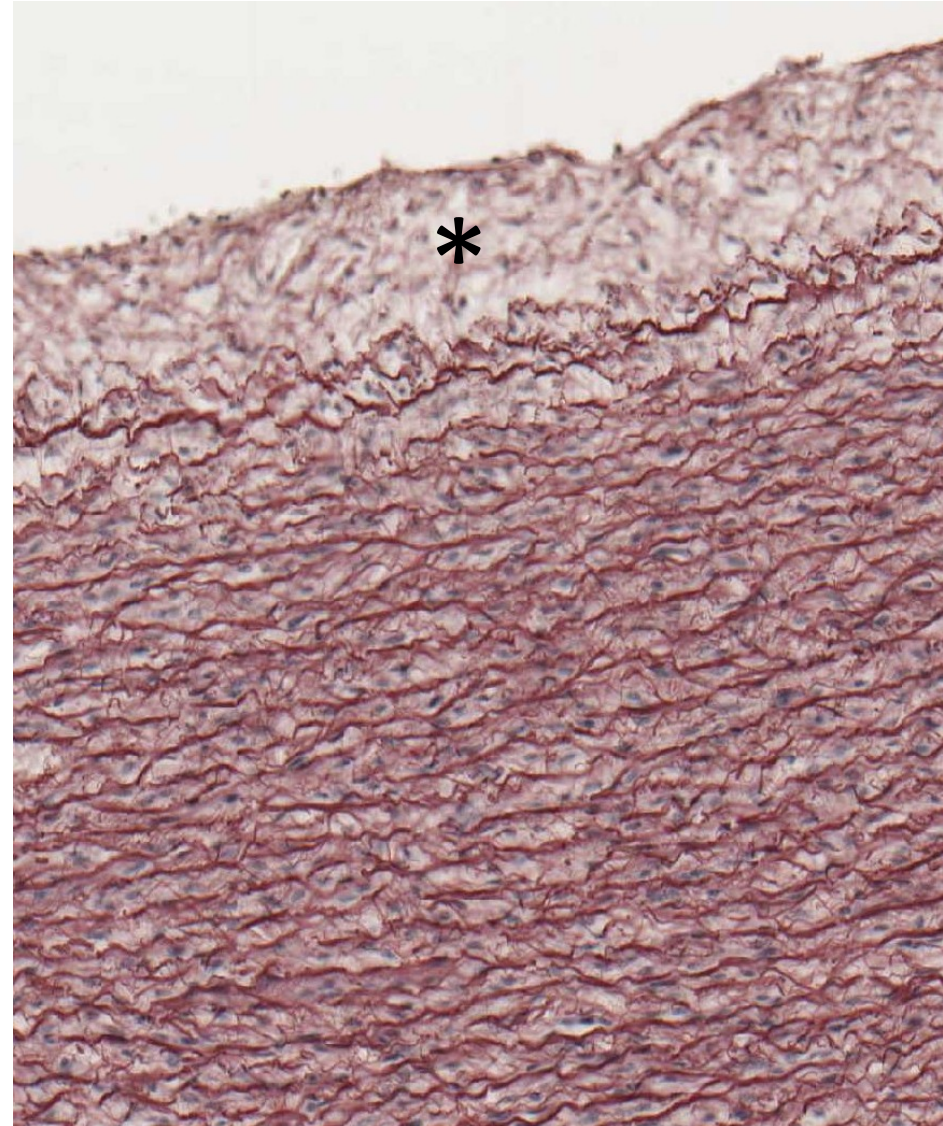


aorta – intima *

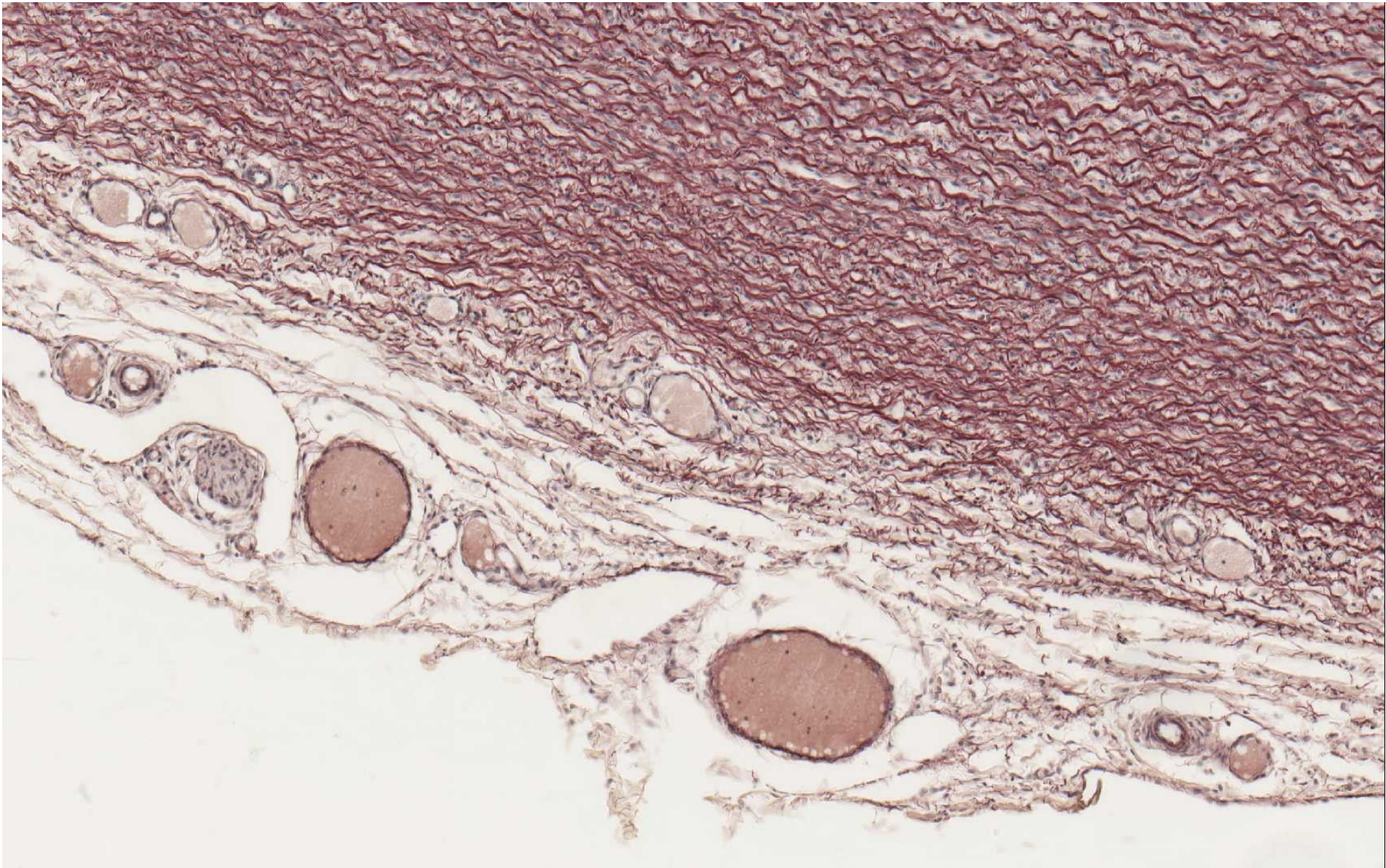
HE



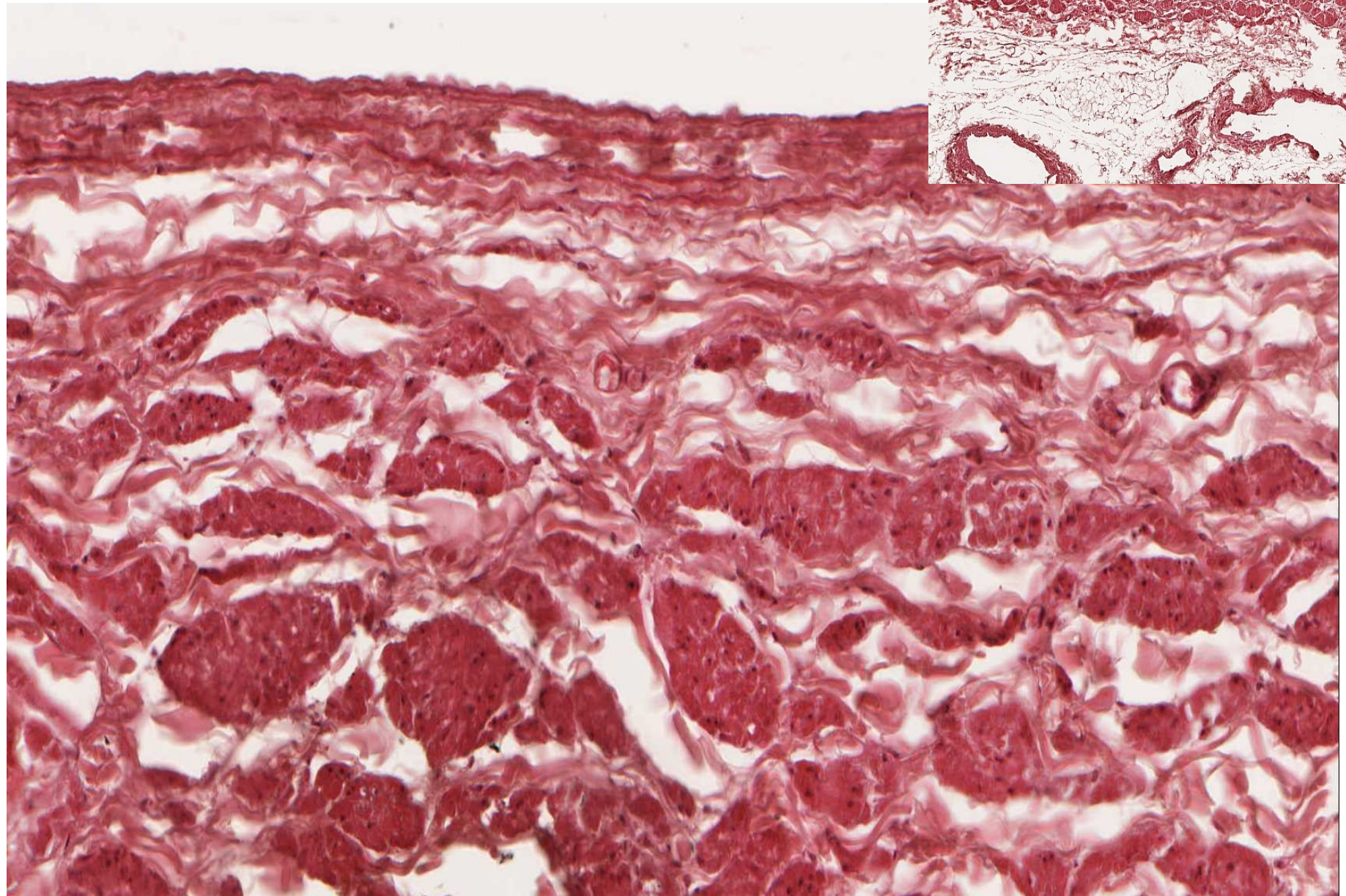
orcein



aorta (orcein) – adventitia, vasa vasorum, nervi vasorum

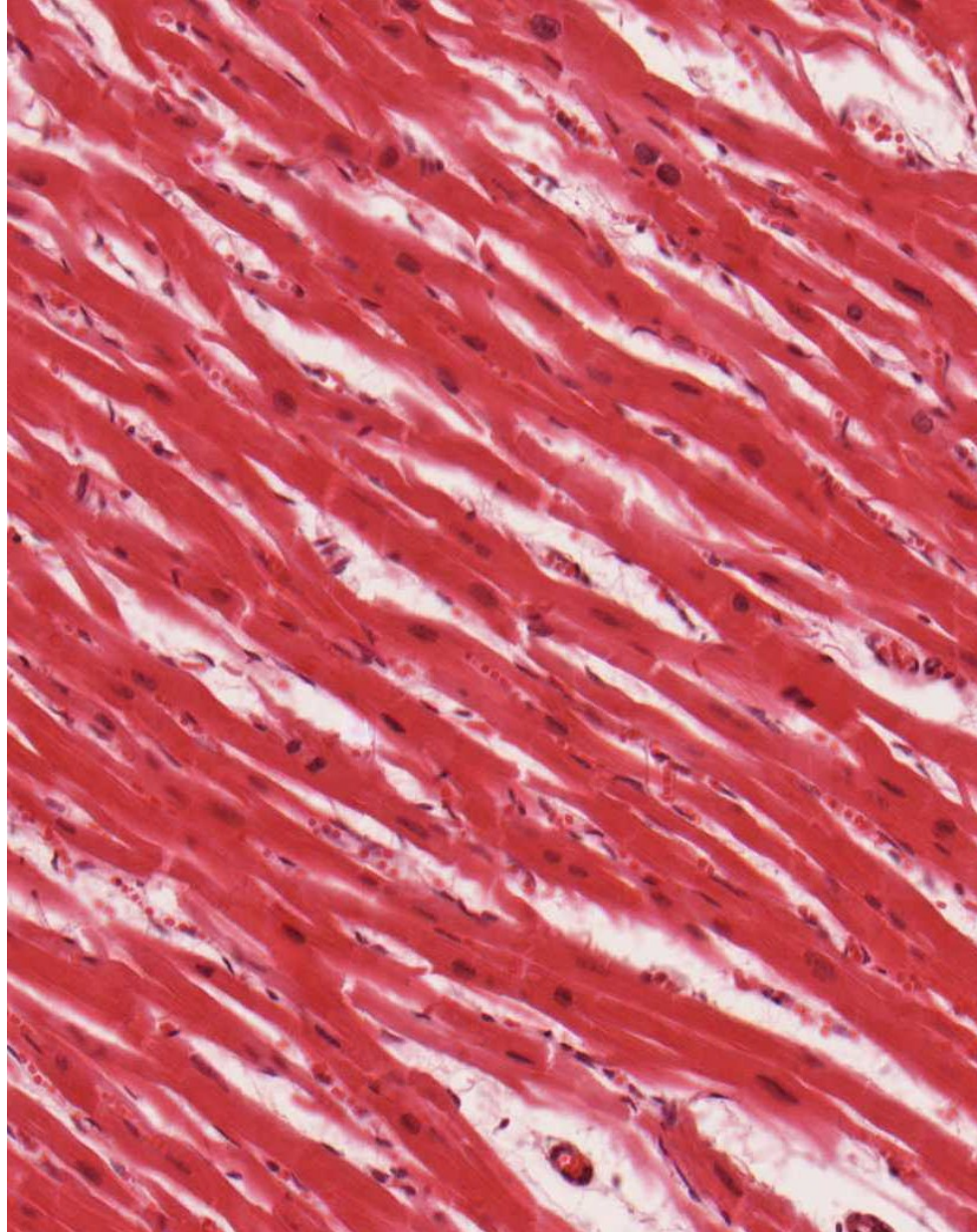


vena cava (HE)




myocardium


HE



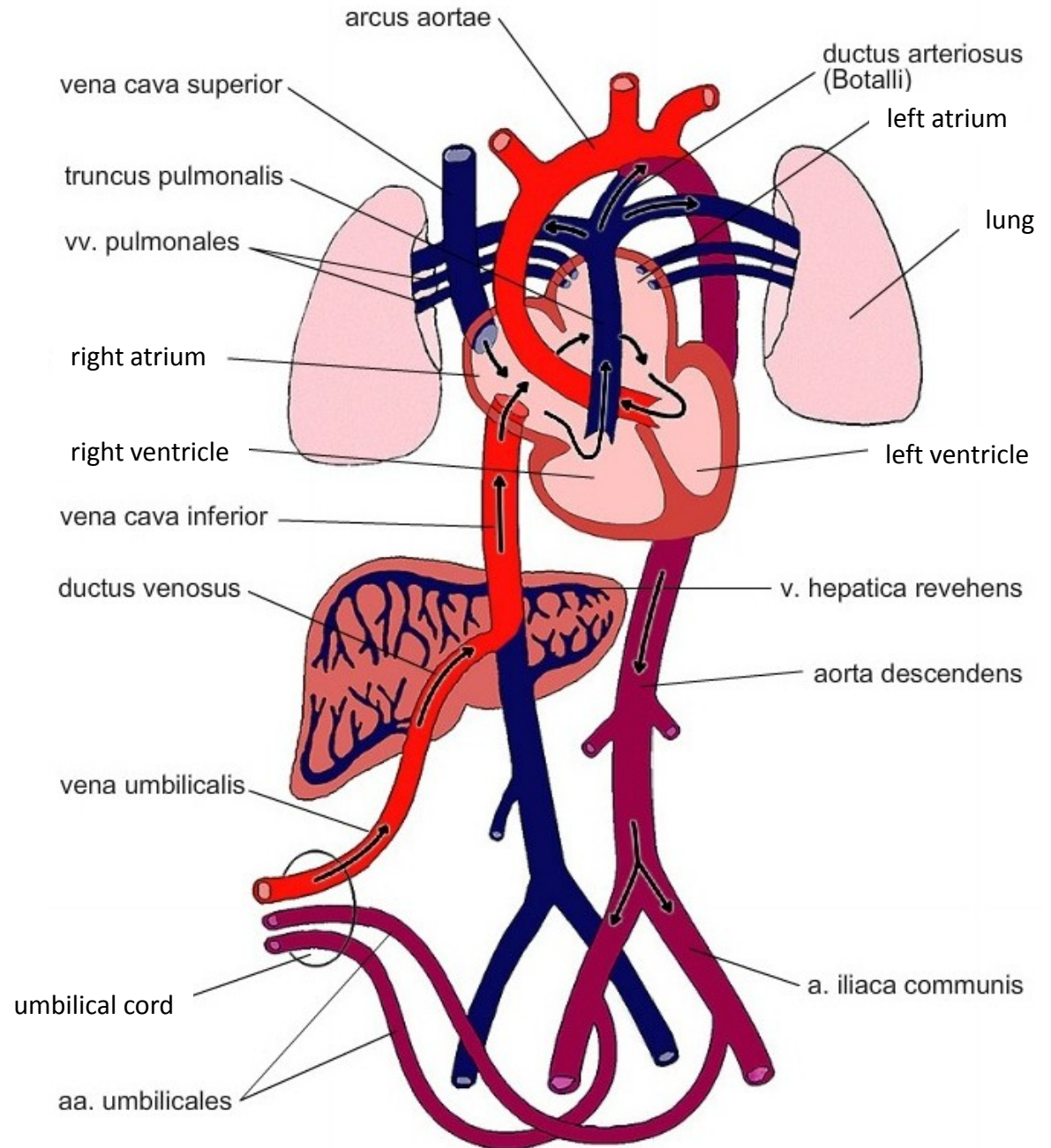
Heidenhain



cardiomyocyte (TEM)



Fetal blood circulation





CARDIOVASCULAR SYSTEM

Slides

Muscular artery and vein (59 – HE, 60 - orcein)

Aorta (61 – HE, 62 - orcein)

Vena cava (63 - HE)

Myocardium (64 – HE, 65 - Heidenhain)

Atlas EM:

Arteriole (59)

Continuous capillary (55)

Fenestrated capillary (56, 57)

Sinusoid capillary (58)

Cardiomyocyte (44-46)

Development of heart, embryonic and fetal blood circulation (91-93)