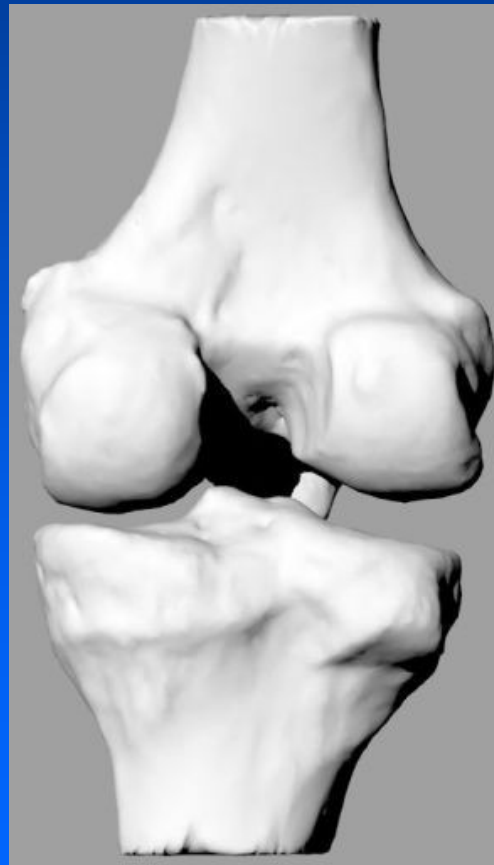
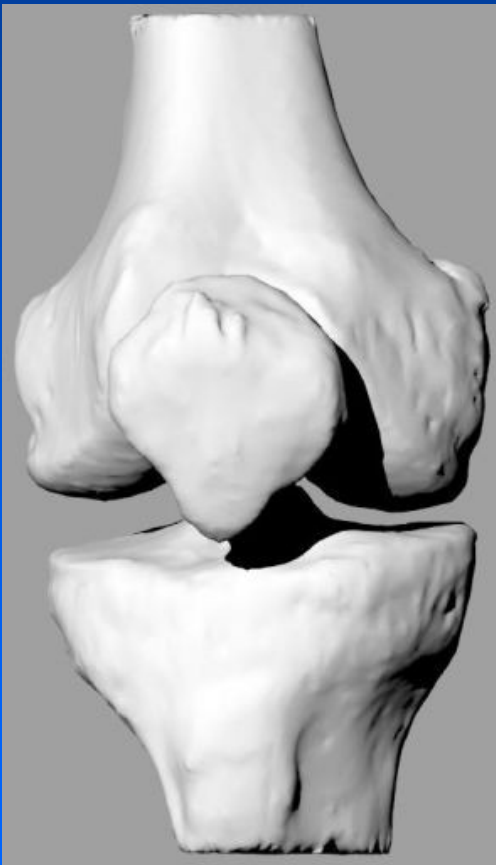

Total knee replacement

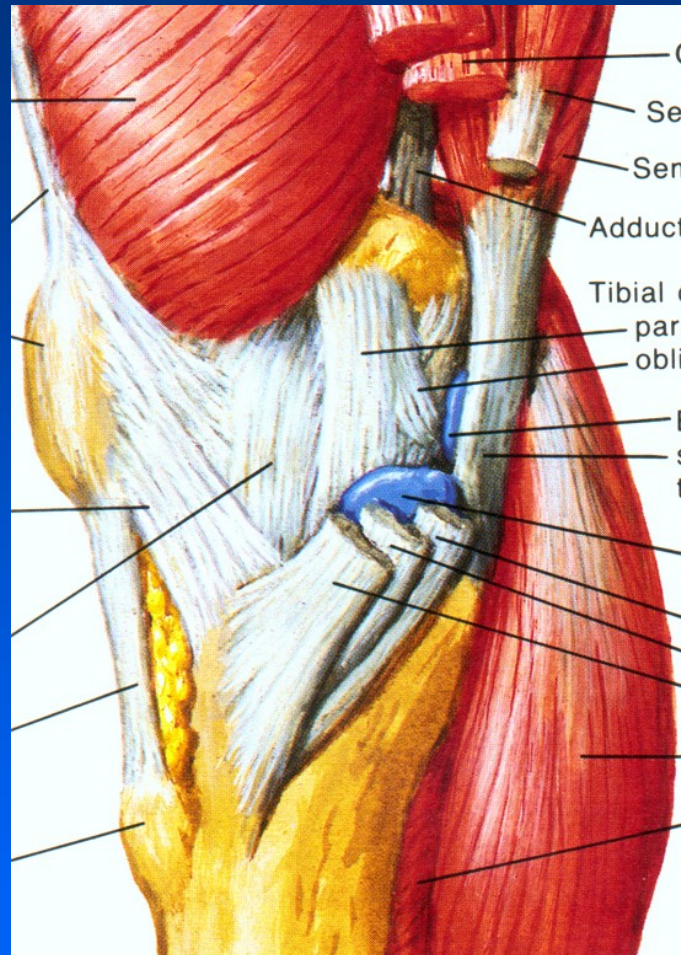
Z. Rozkydal, L. Nachtnebl,
T. Tomáš, P. Janík

Knee has a complicated structure

Articulating bones: Femur, tibia and patella

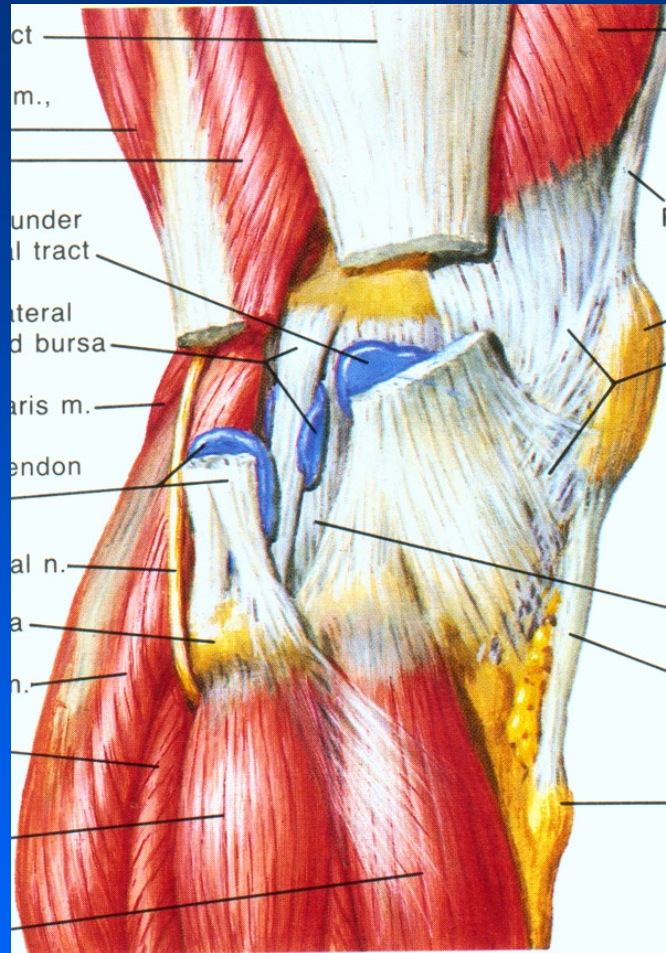


Stability of the knee



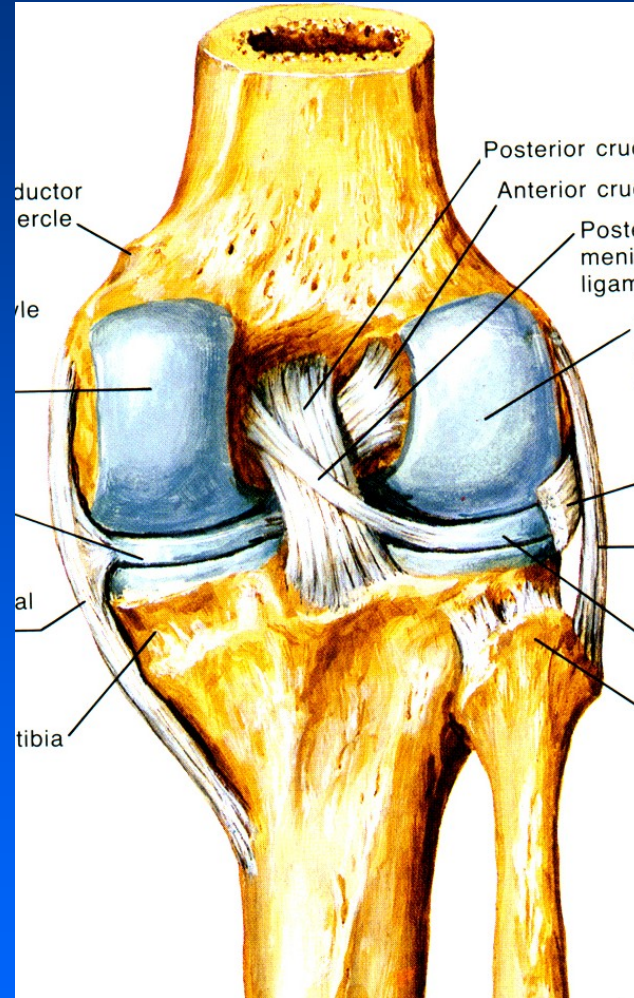
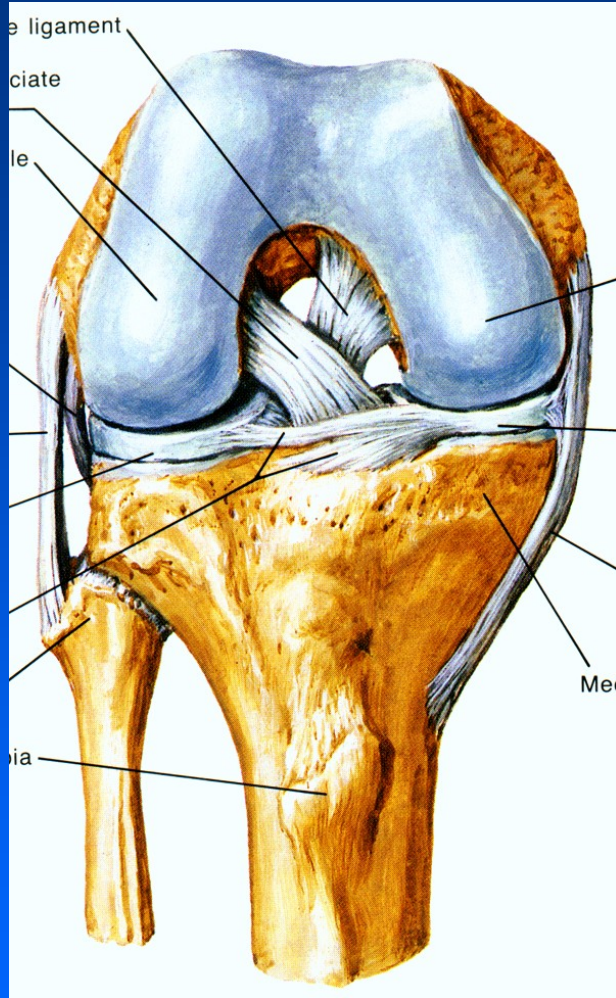
Medial side

Stability of the knee



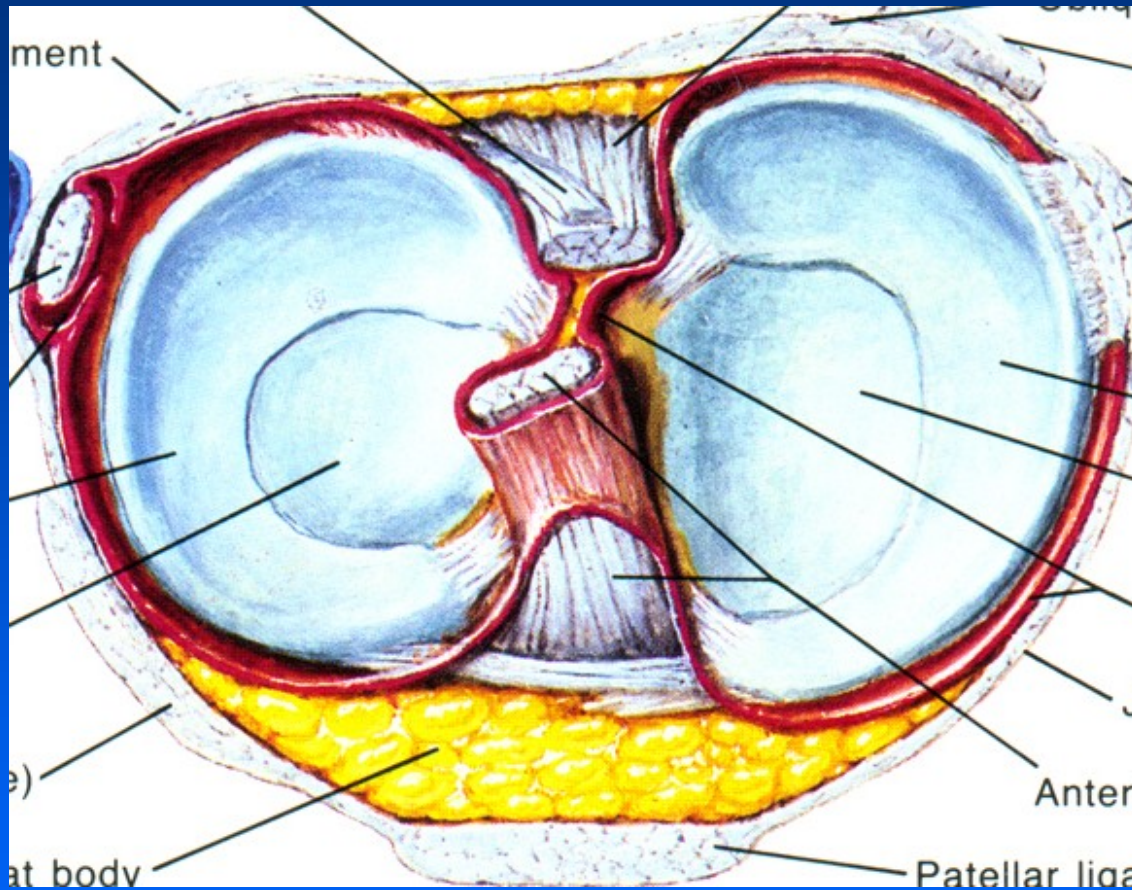
Lateral side

Stability of the knee



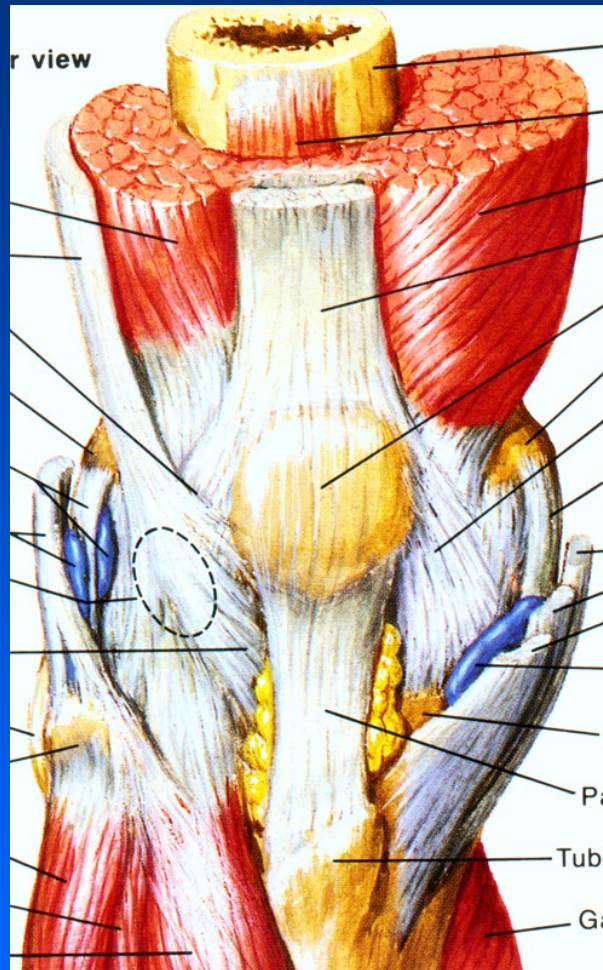
Cruciate ligaments

Stability of the knee



Menisci

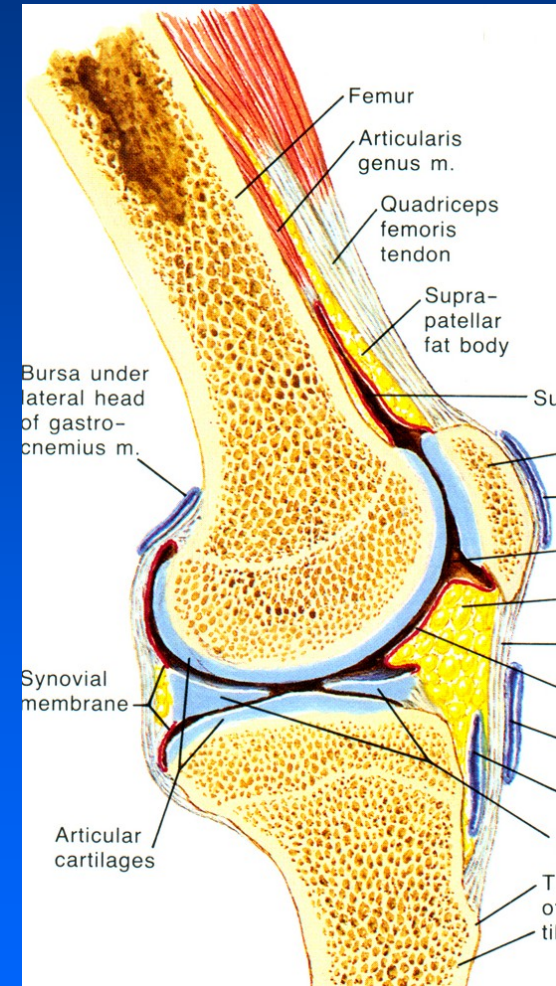
Stabilita kolena



Muscles

Movements in the knee joint

Level	Movement
Sagittal	flexion/extension rolling gliding
Transversal	ext./ internal rotation
Frontal	adduction /abduction

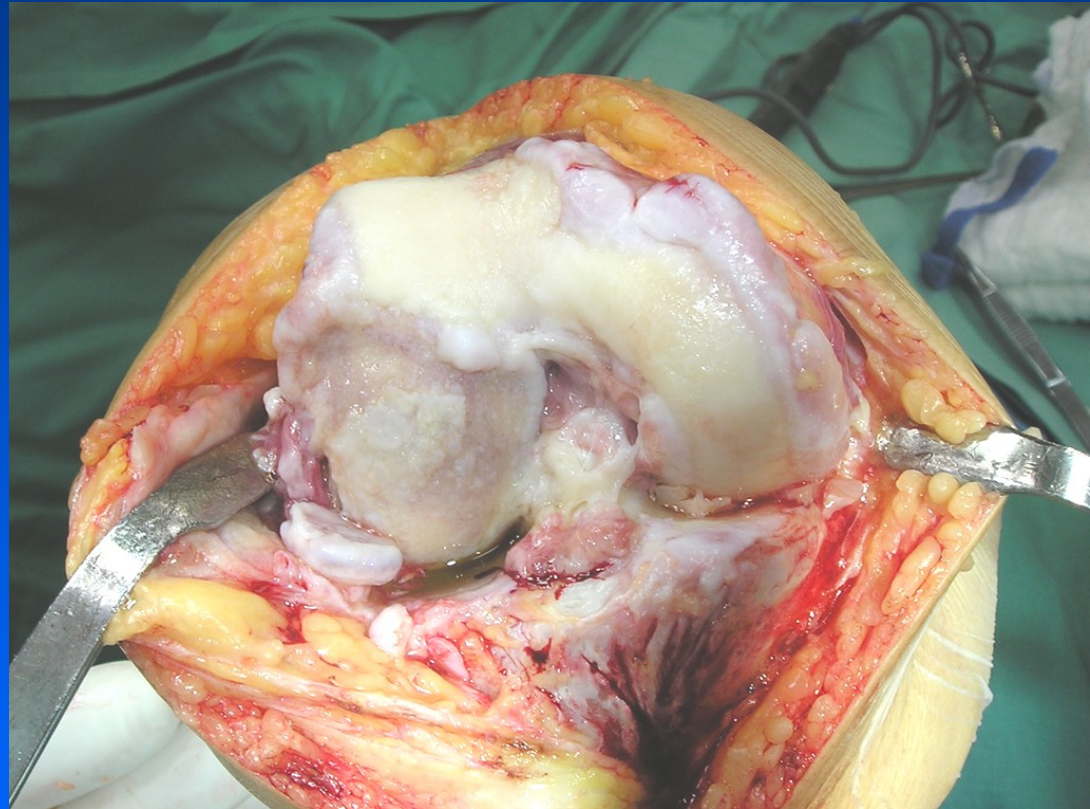


Indications for TKA

Painful condition
+ unsuccessful
conservative treatment

No other procedures
for maintaining of good
function are available

Severe dyscomfort



Indications

Osteoarthritis

- primary
- secondary

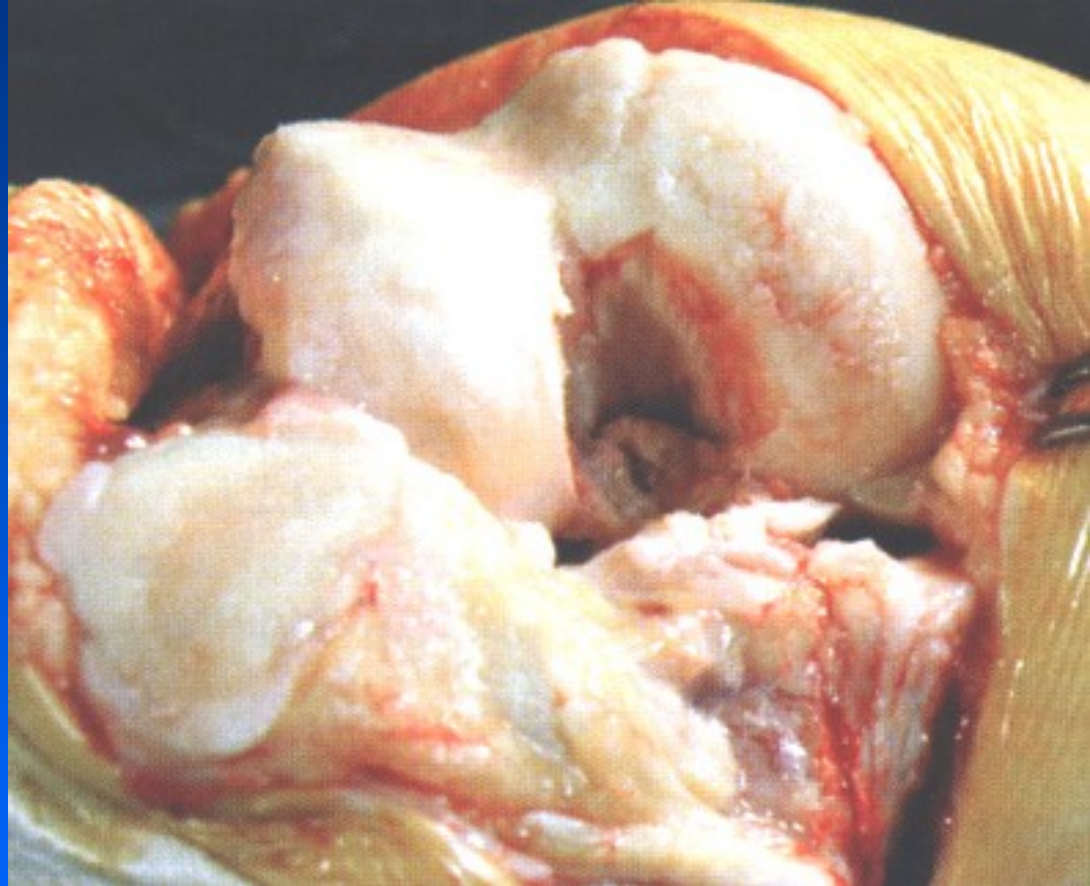
Aseptic necrosis of femoral condyle

Rheumatoid arthritis

Psoriatic arthropathy

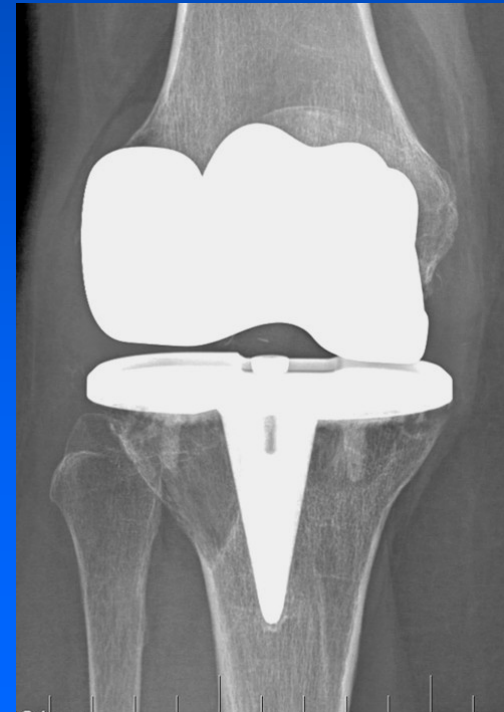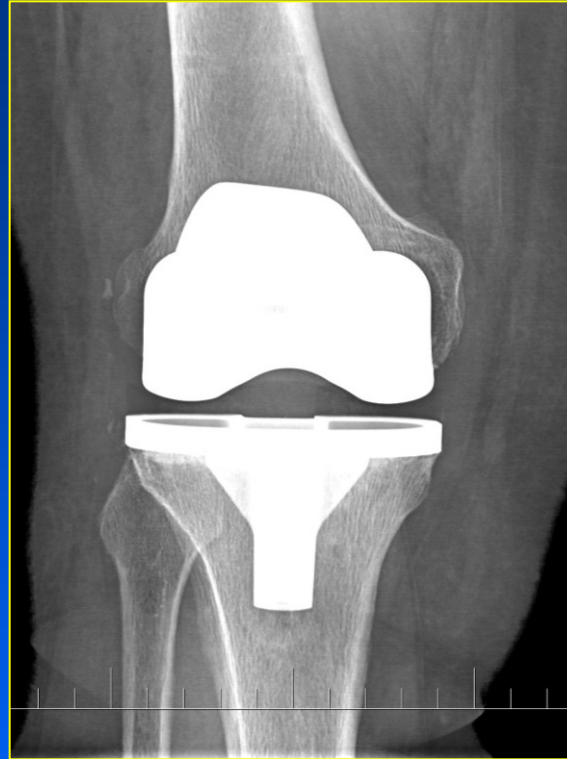Tumors

Haemophilic arthropathy



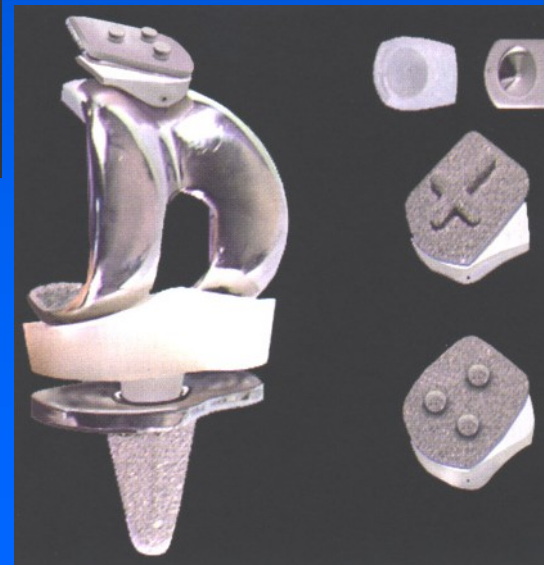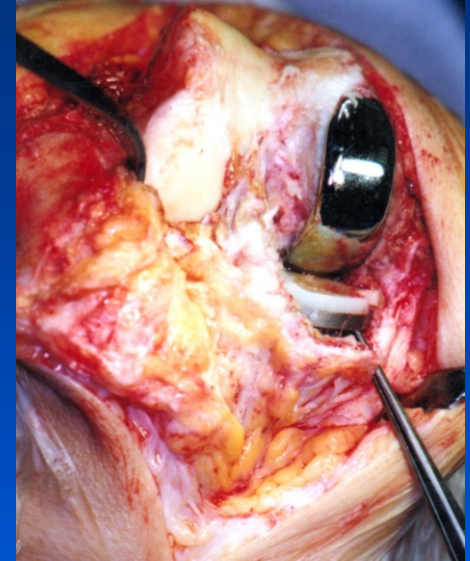
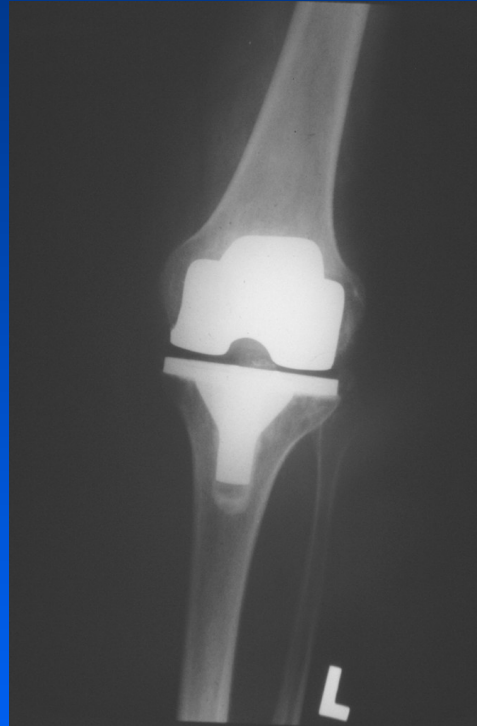
TKA

- Cemented
- Hybrid
- Uncemented



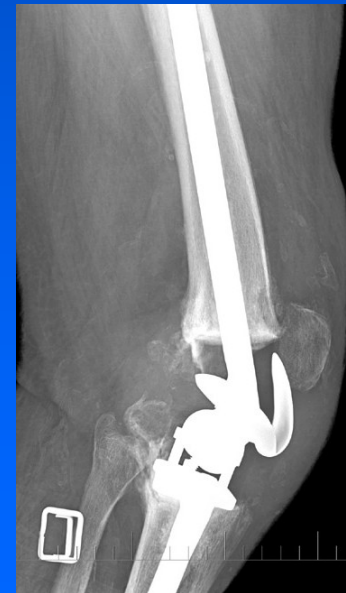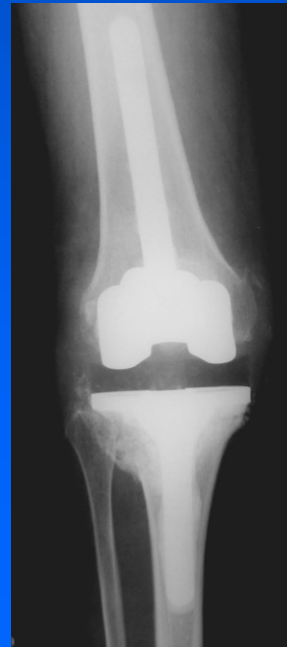
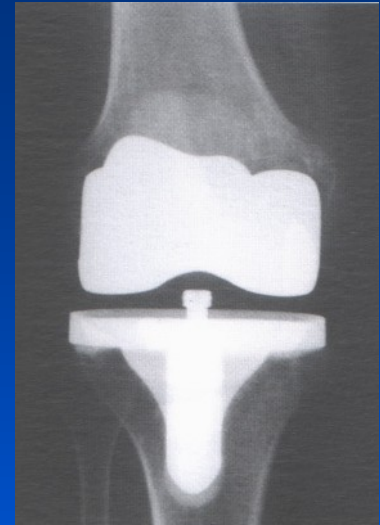
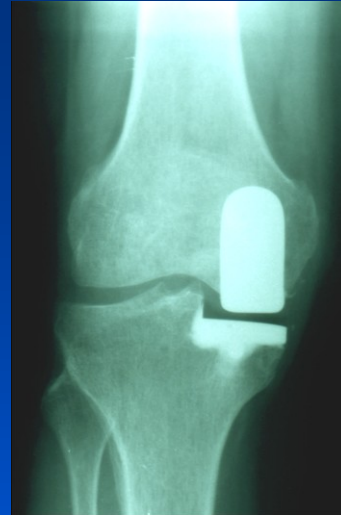TKA

- Unicompartmental
- Bicompartmental
- Tricompartmental

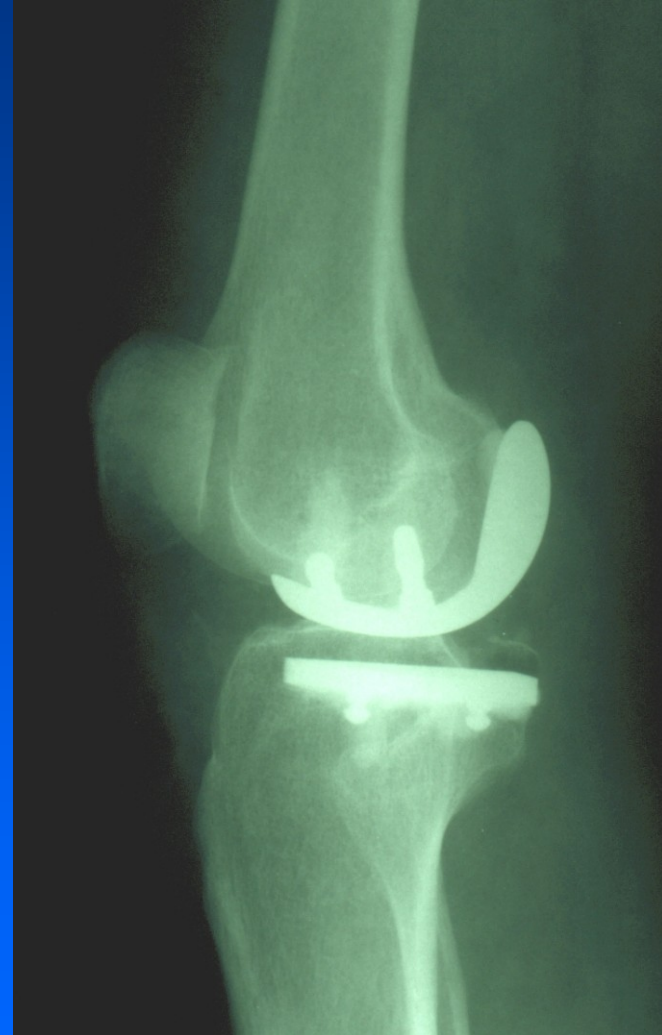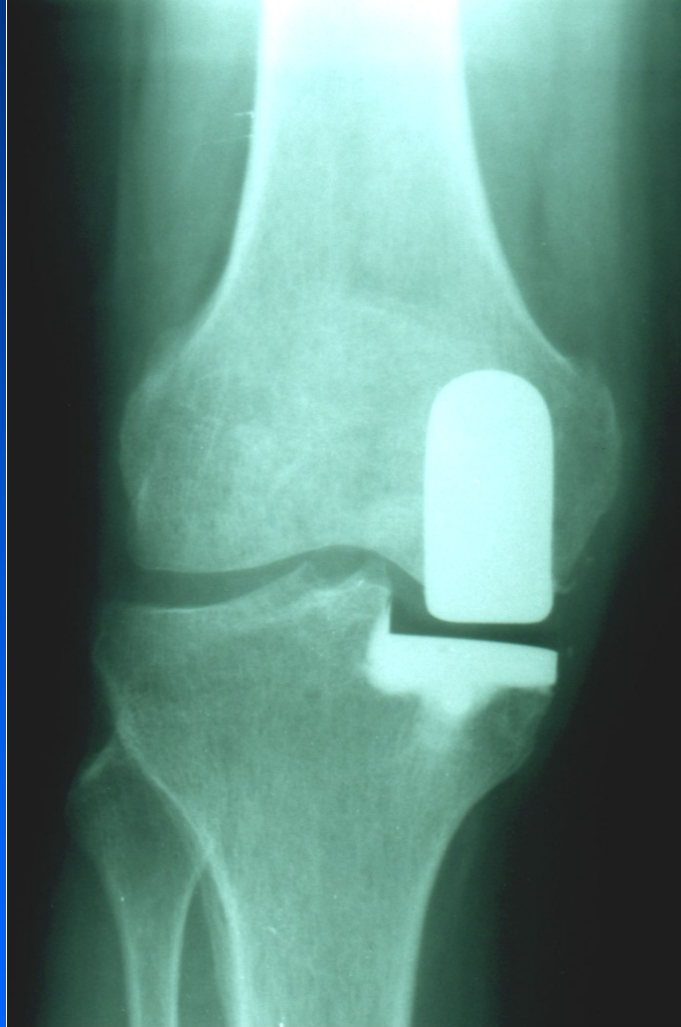


TKA

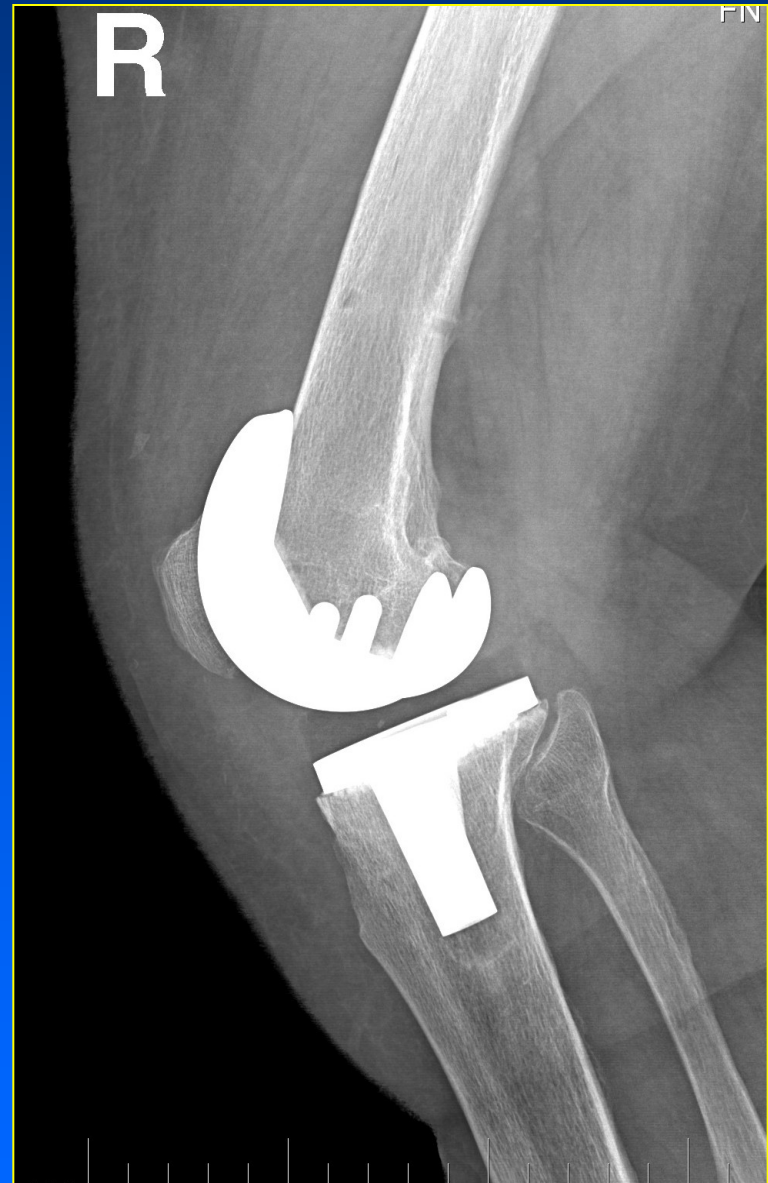
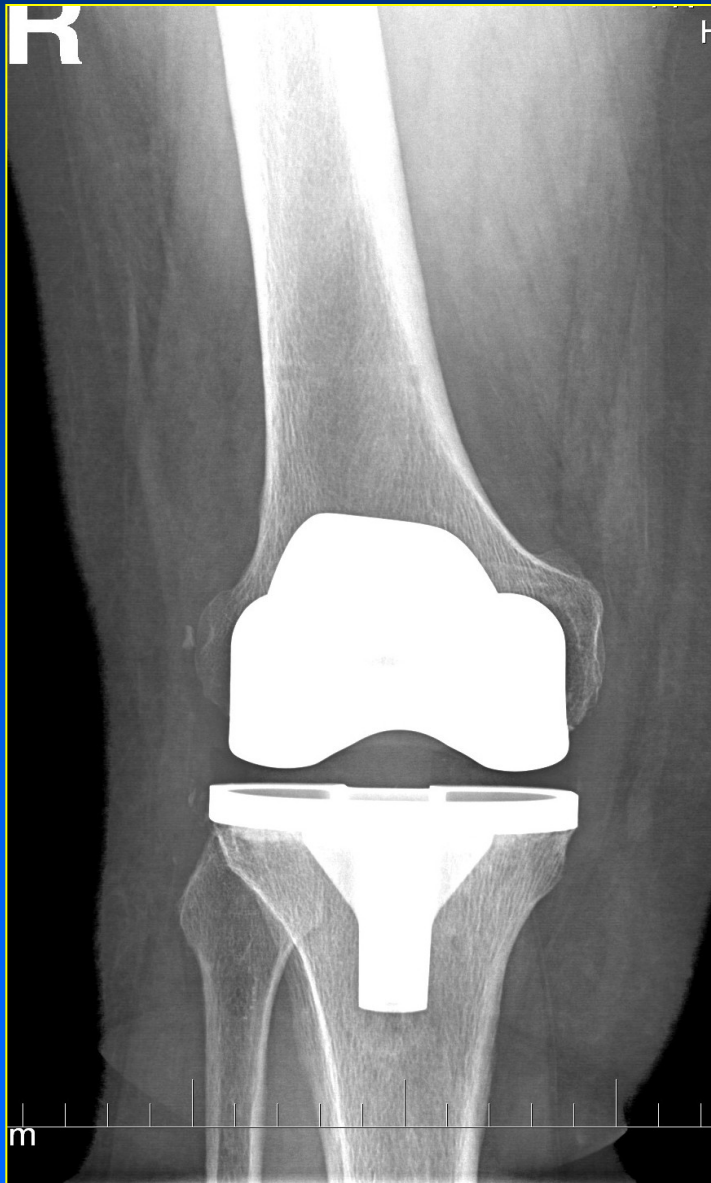
- Unicondylar
- Condylar
 - PCL retaining
 - PCL sacrificing
- Condylar with stem
- Hinge
- For tumors



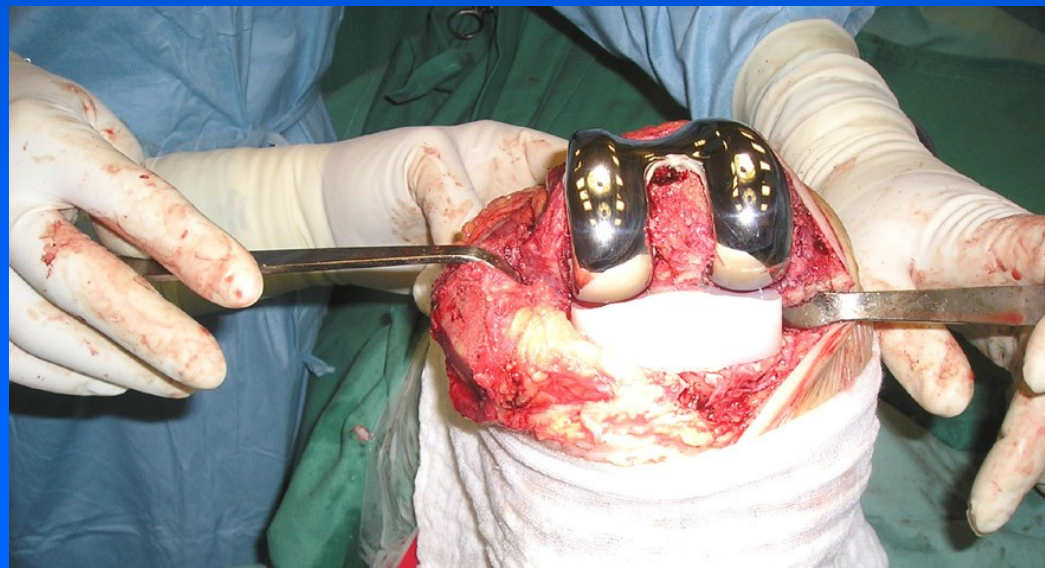
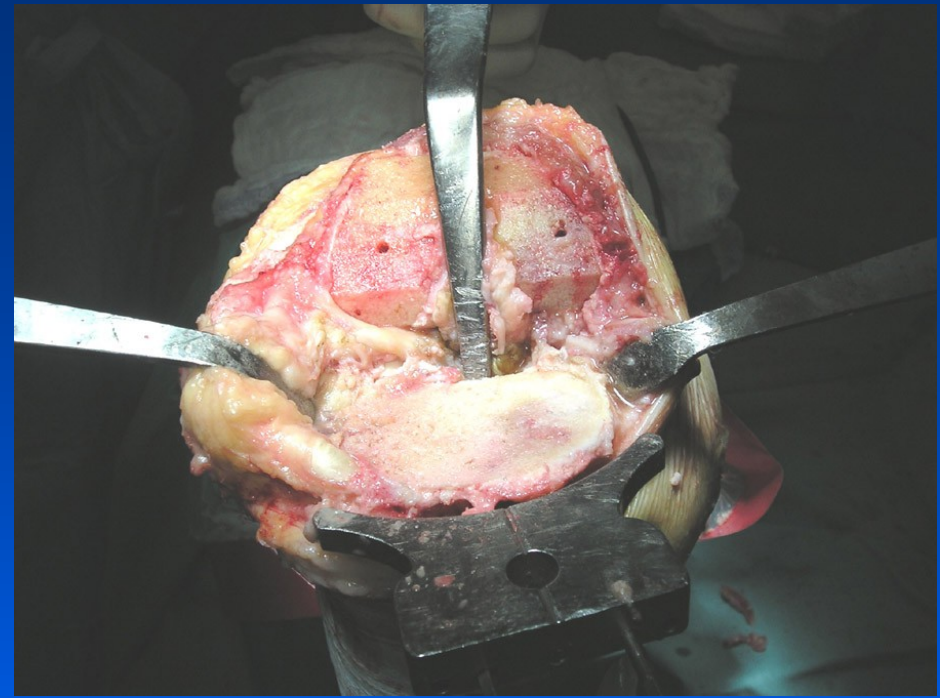
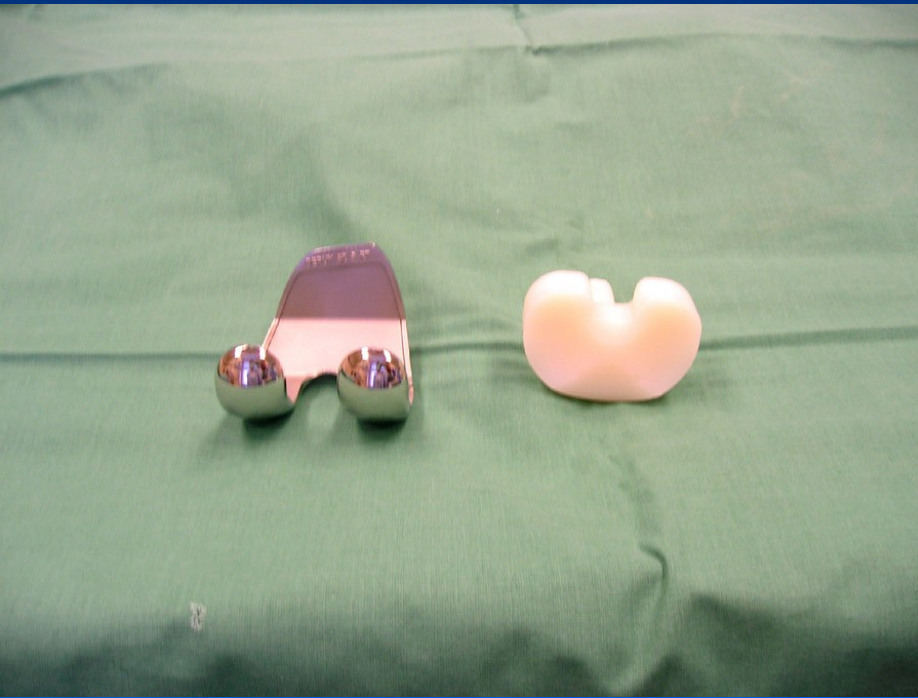
Unicondylar replacement TKU



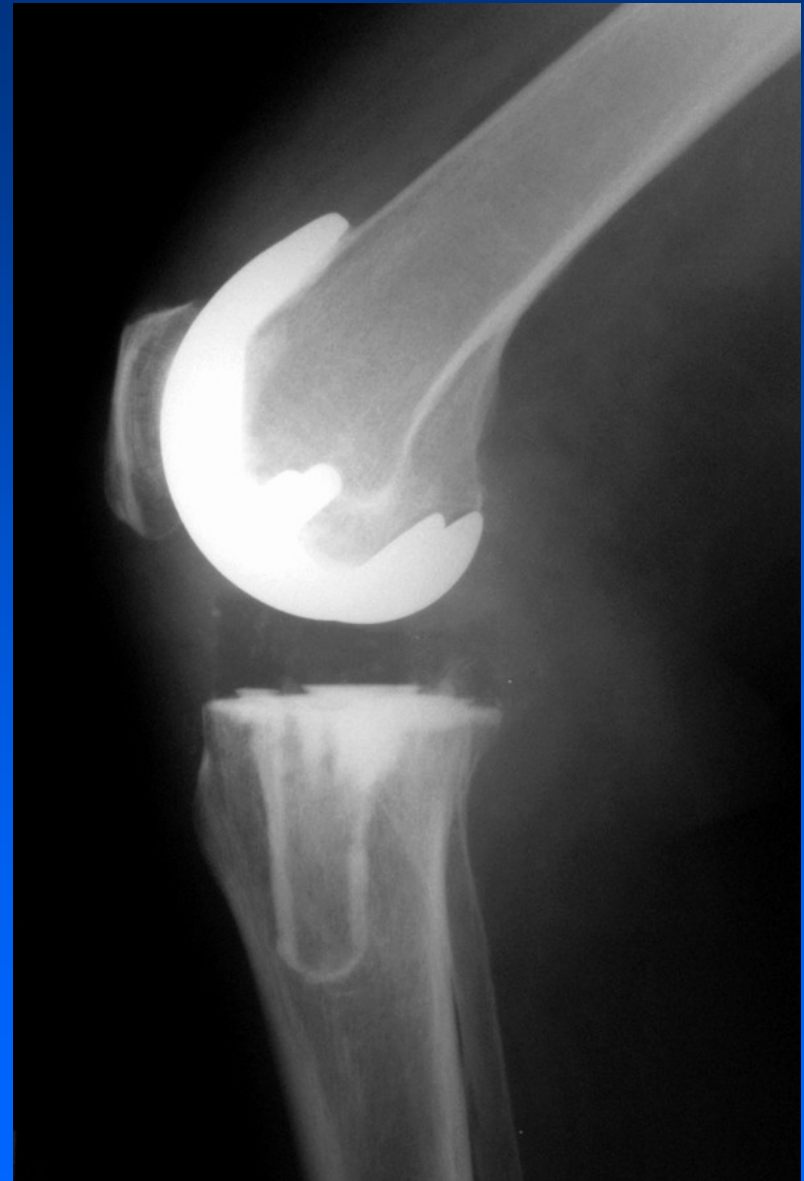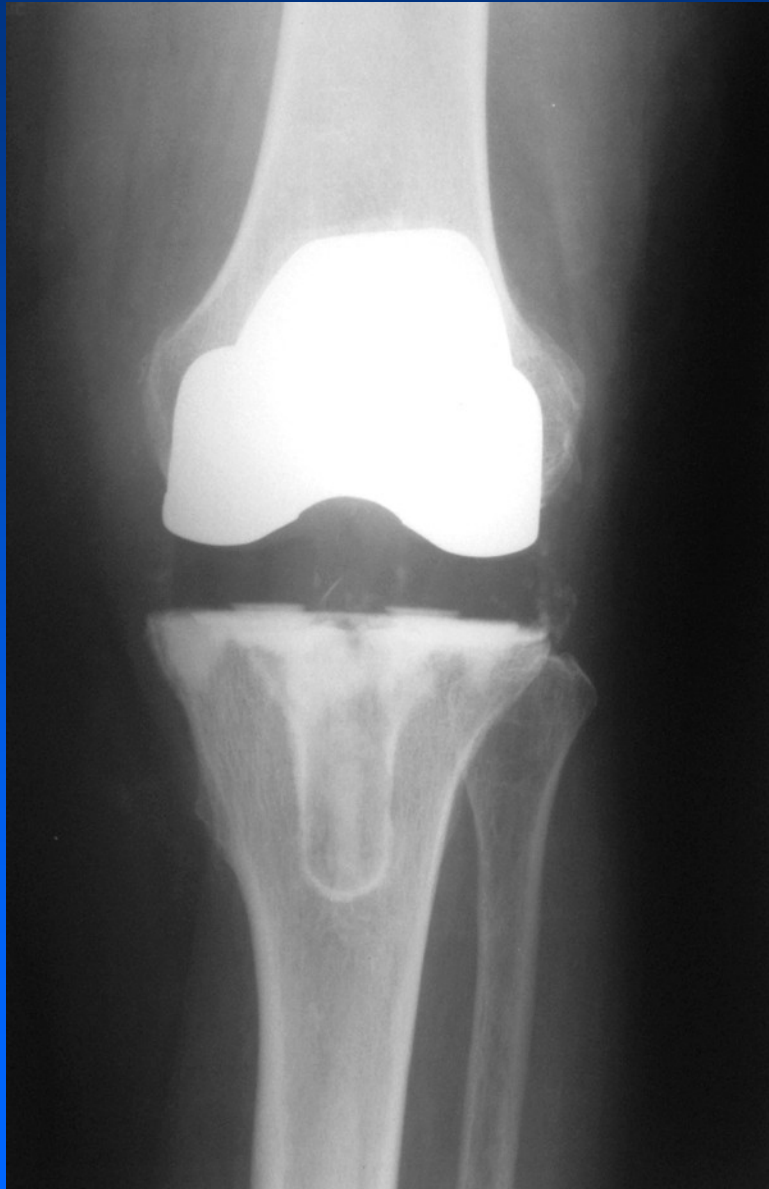Condylar – PCL retaining



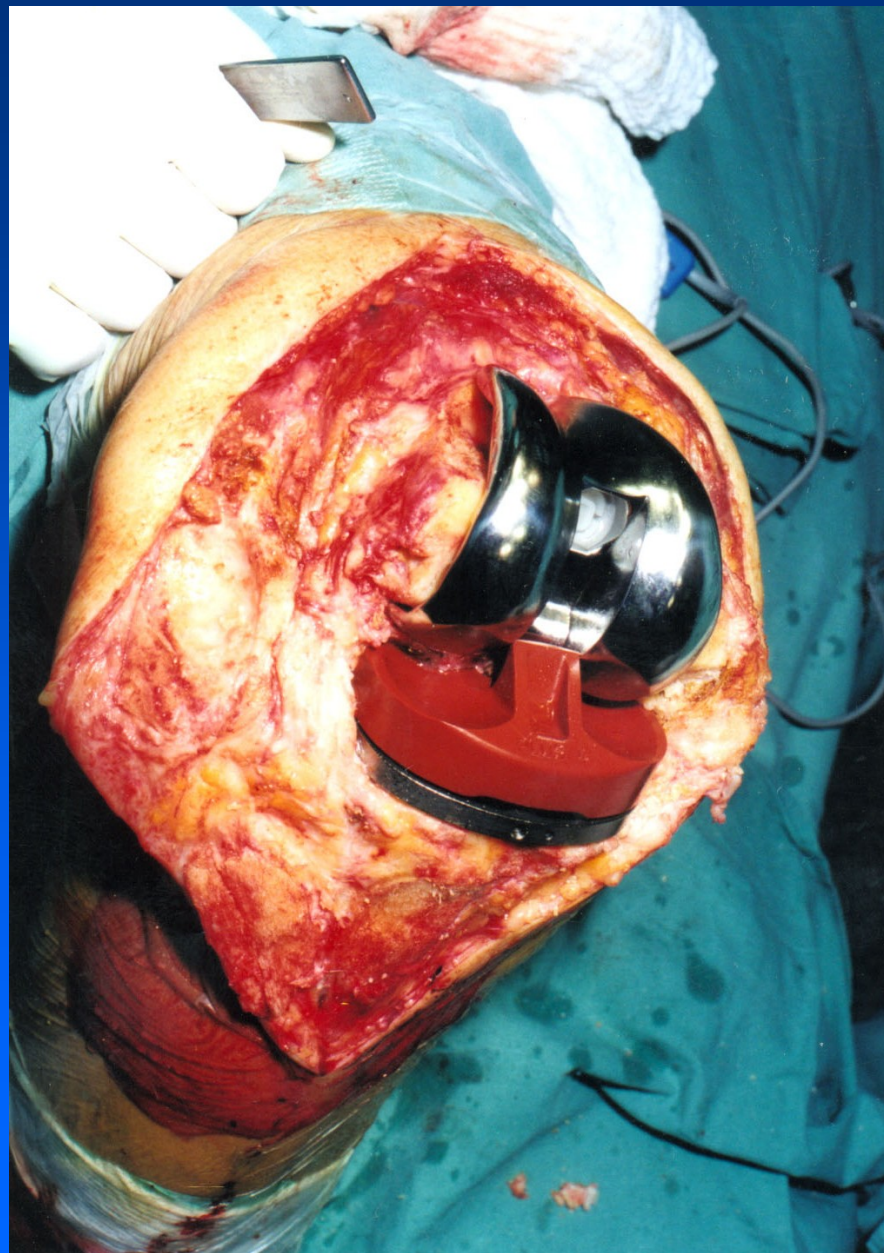
TKA – all poly type



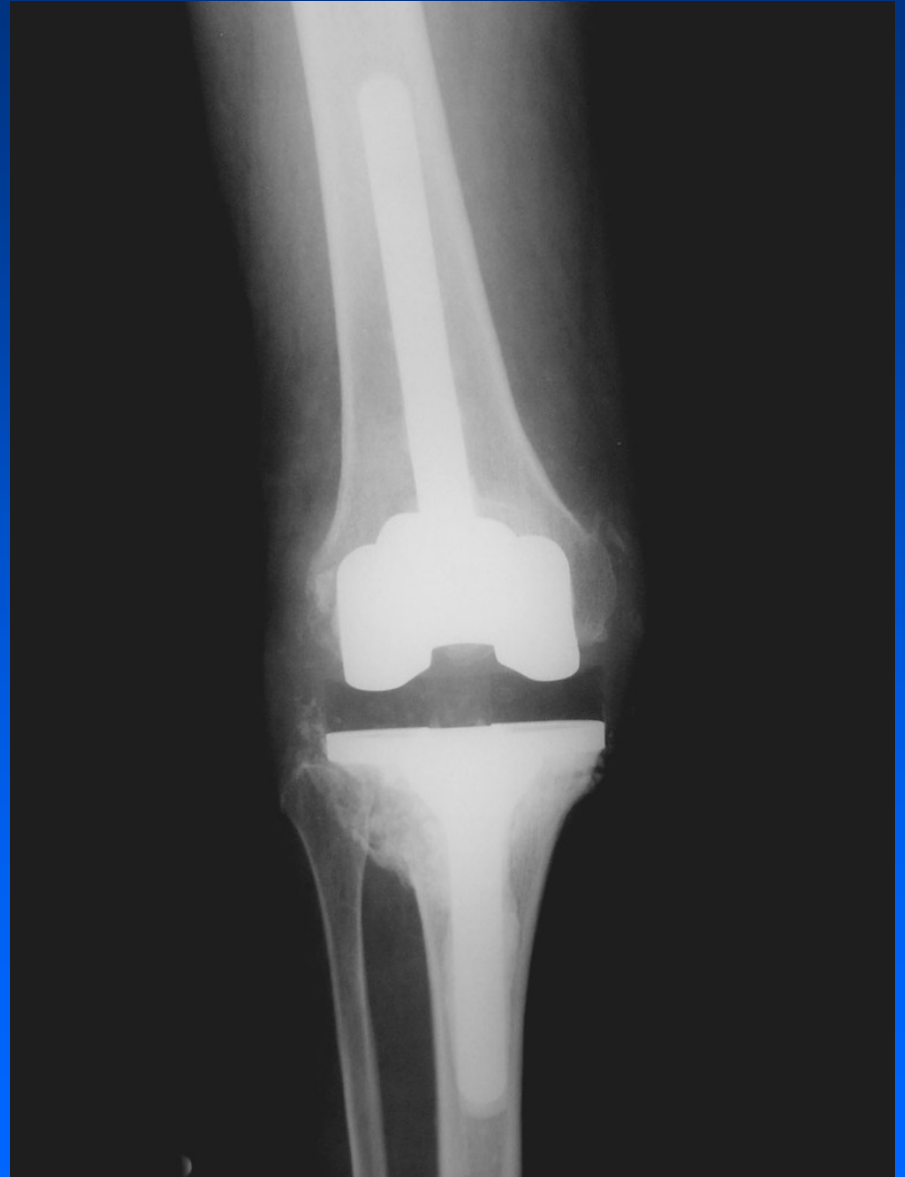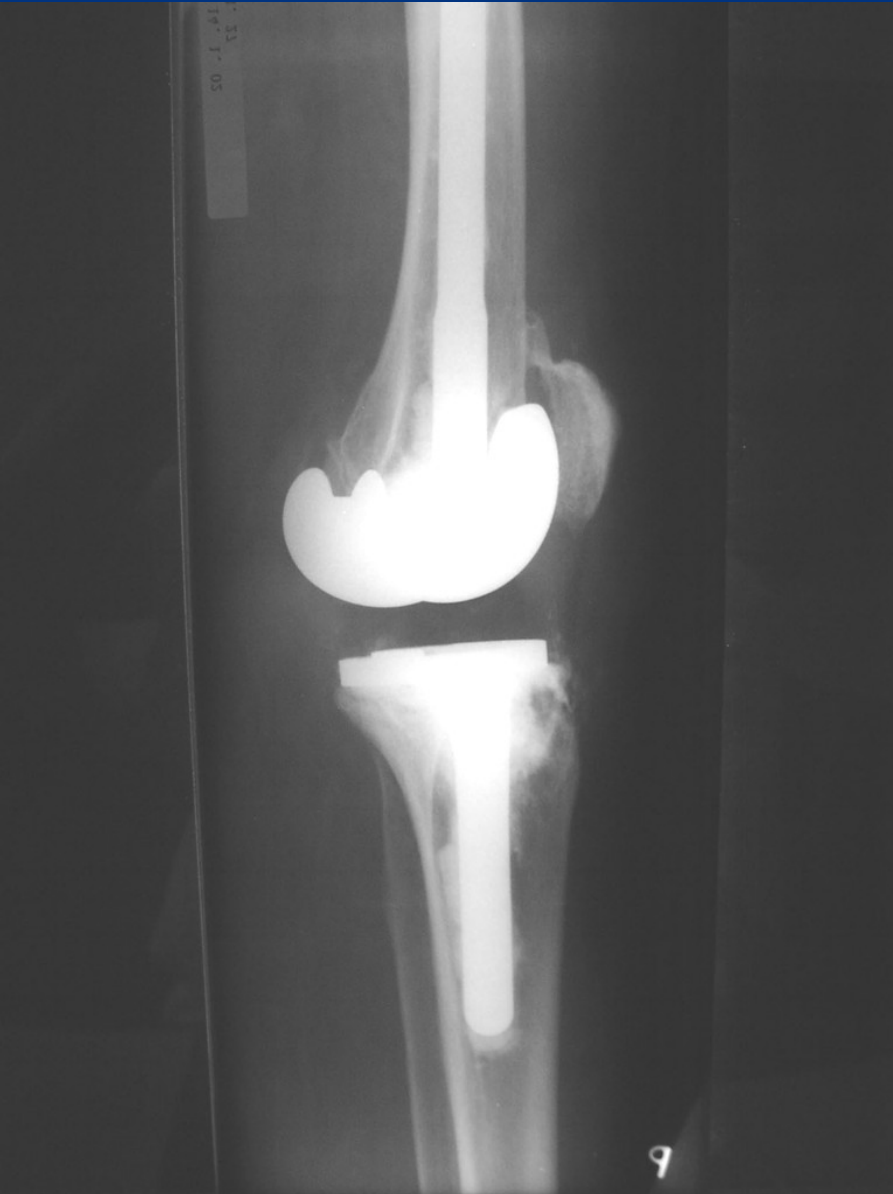TKA – all poly type



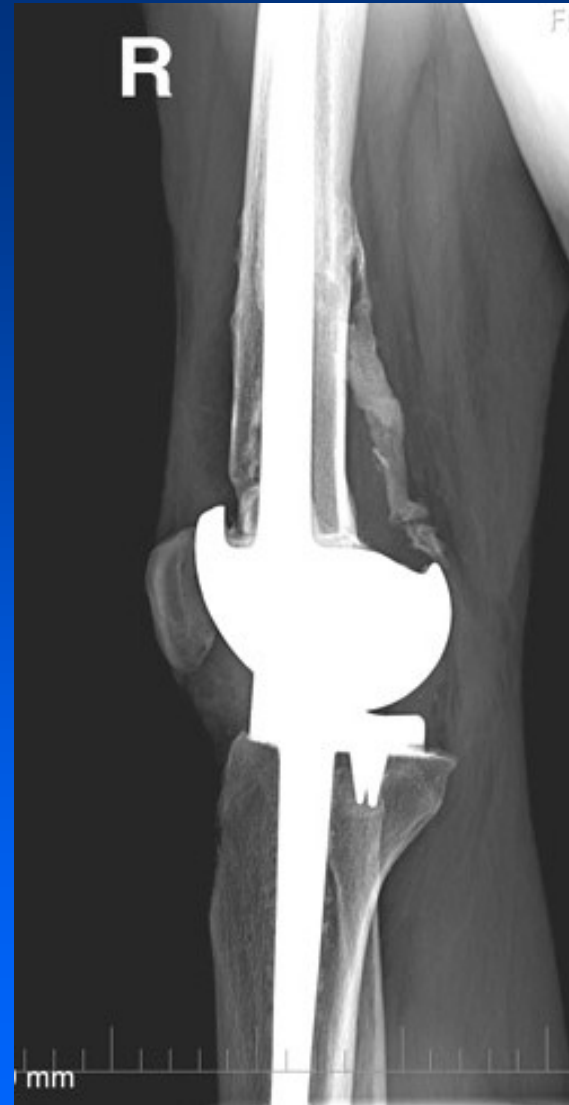
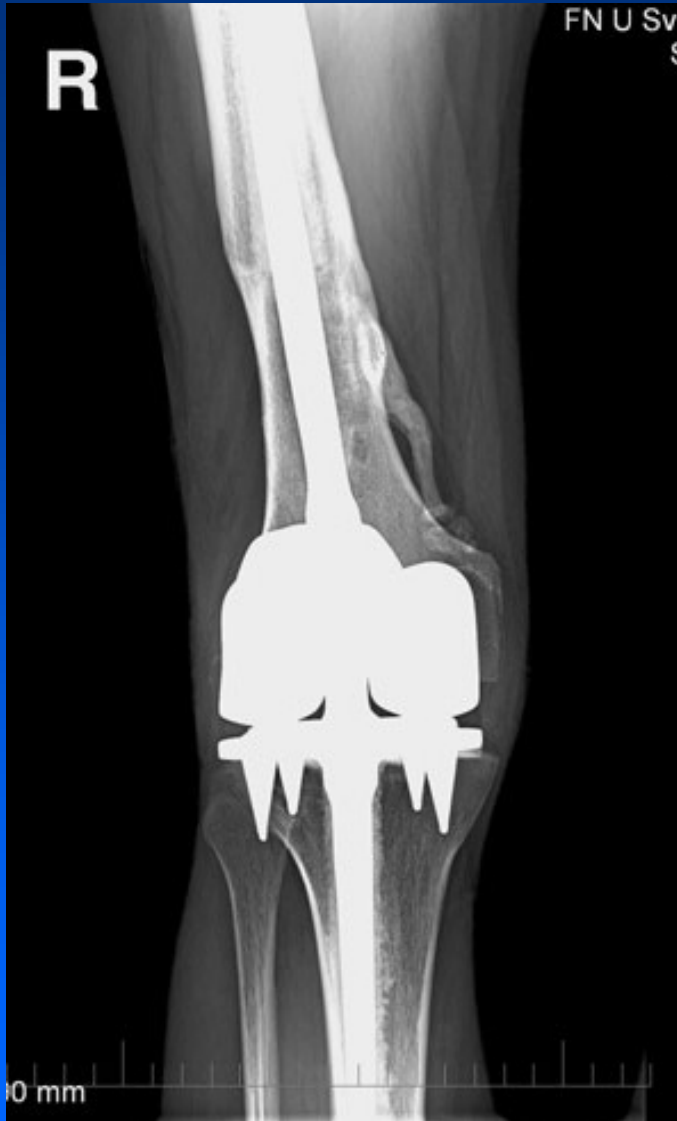Condylar TKA – PCL sacrificing



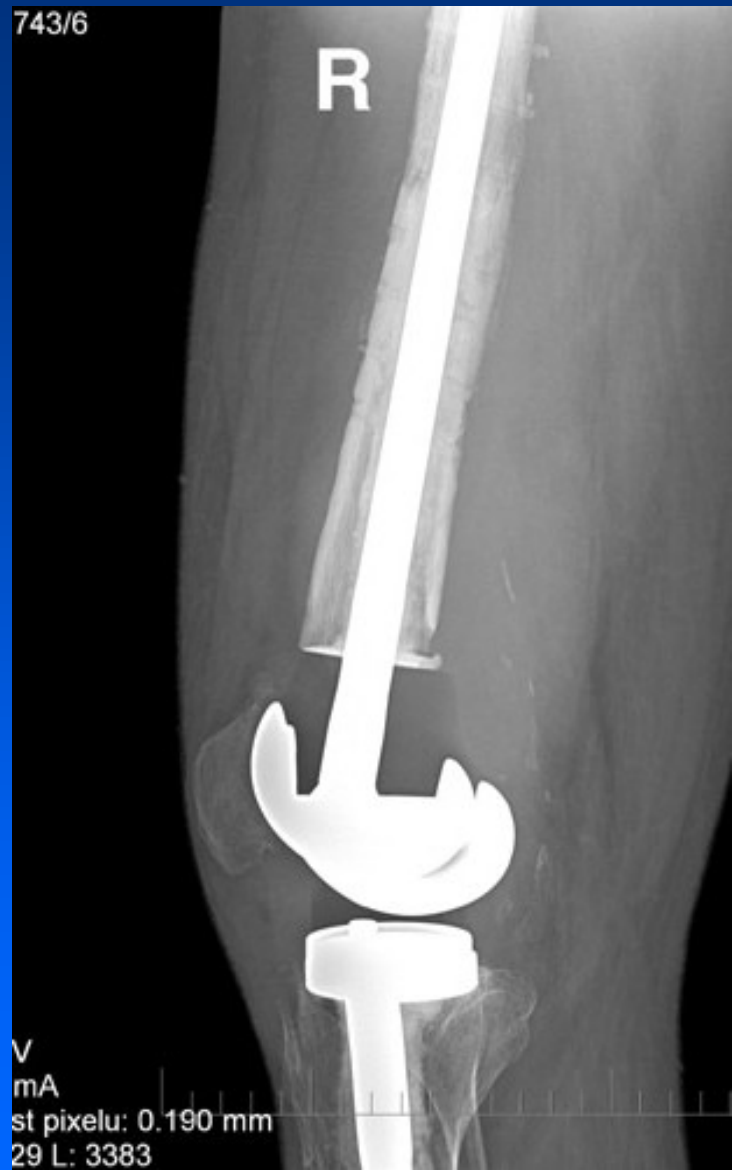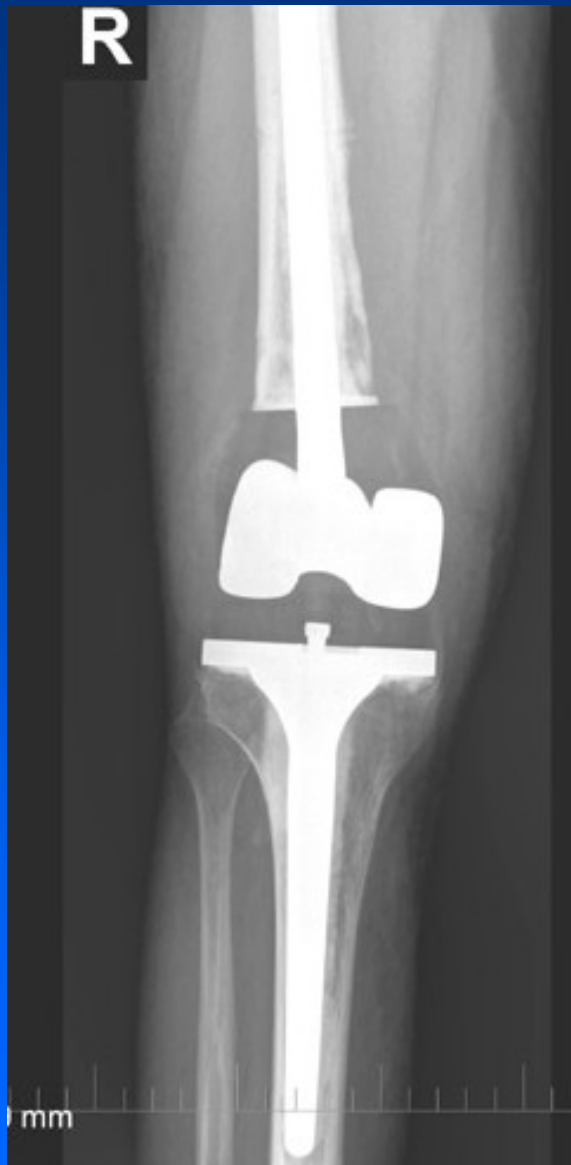Condylar TKA with stems



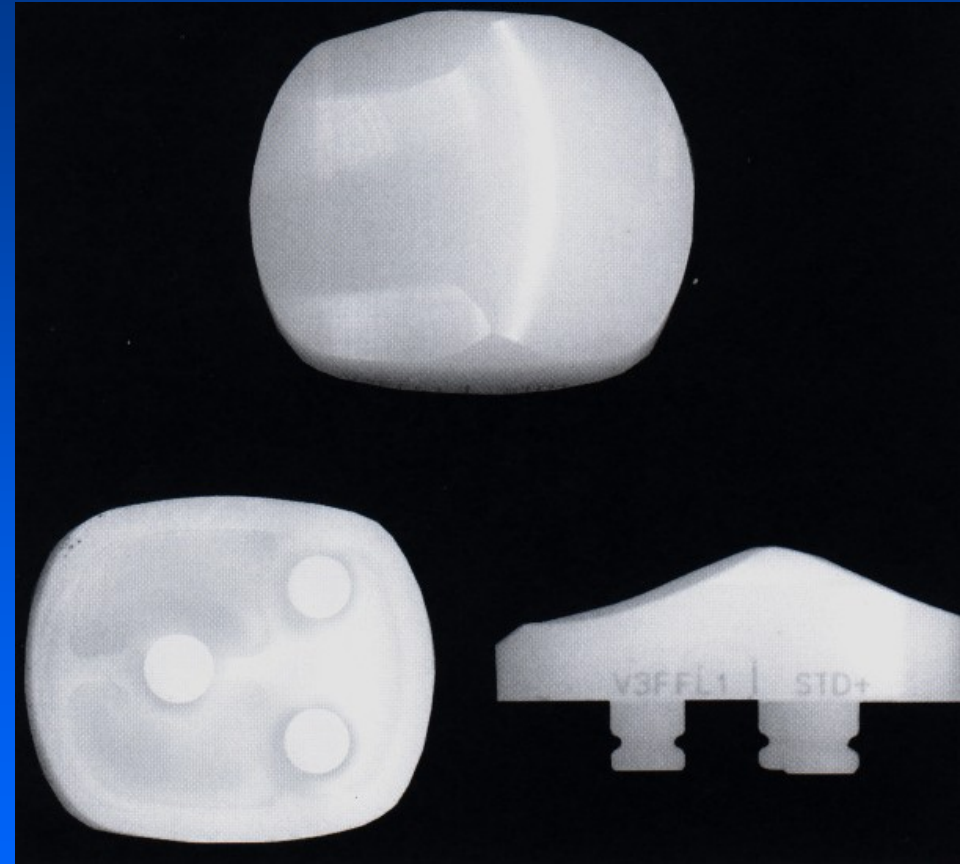

TKA for tumors



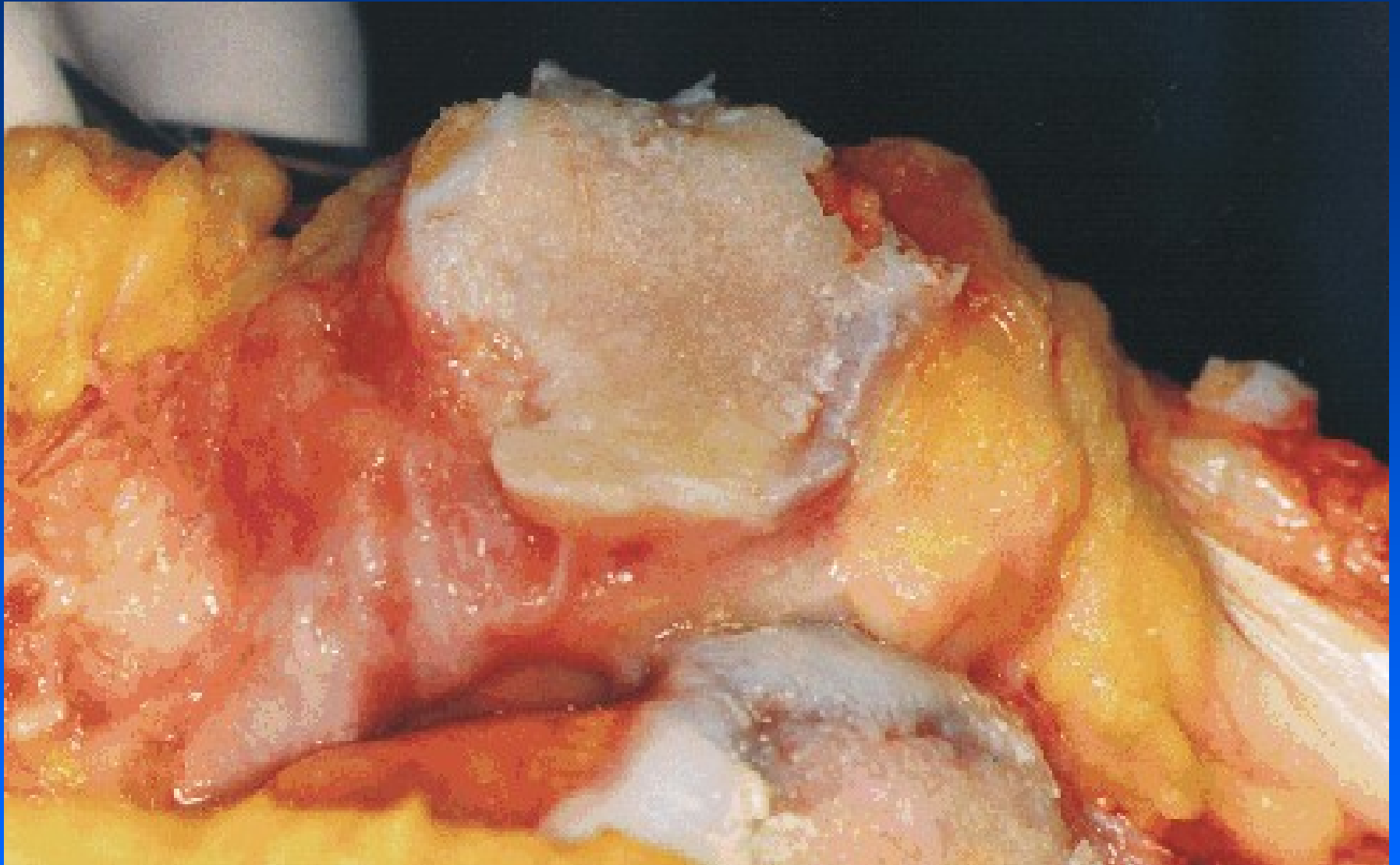TKA for tumors



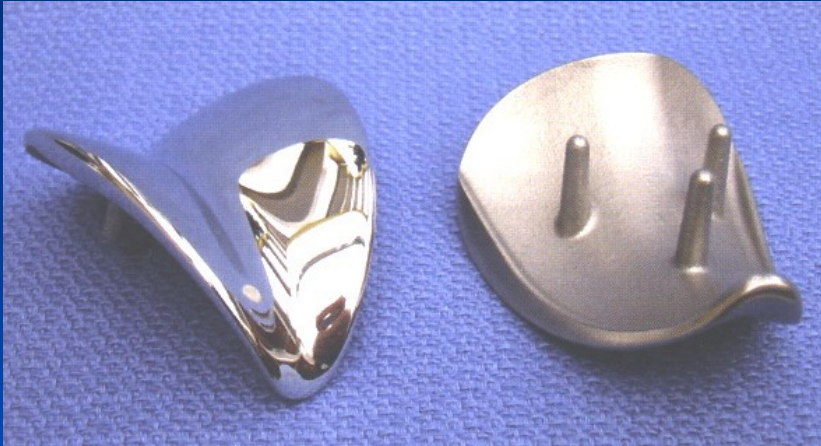
Replacement of the patella



Resection of the patella



Femoropatellar replacement



TKA Sigma Johnson + Johnson company

Standard PE plateau

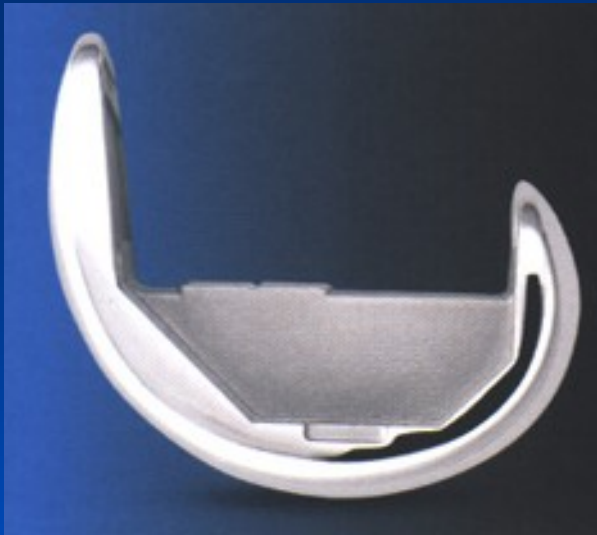PS variant of the plateau

Rotating plateau

- standard
- PS variant



PS variant – TKA Sigma Fixed plateau




TKA Sigma Johnson + Johnson

Rotating plateau

- standard
- PS varianta



Search – Evolution Aesculap



TKA Innex - Zimmer company

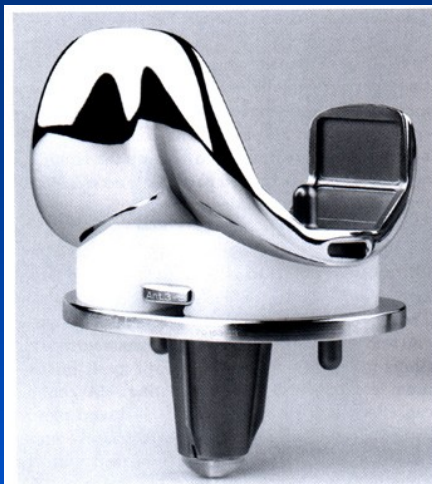

Fig. 1.24. INNEX CR

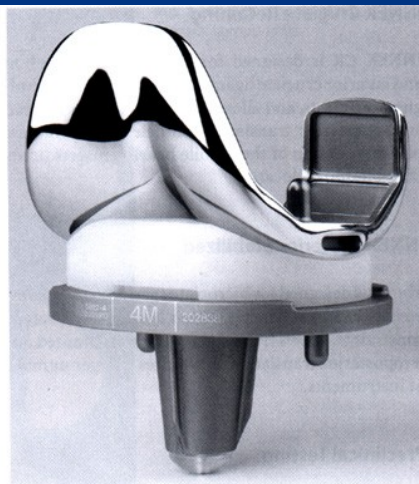

Fig. 1.26. INNEX Fix CR

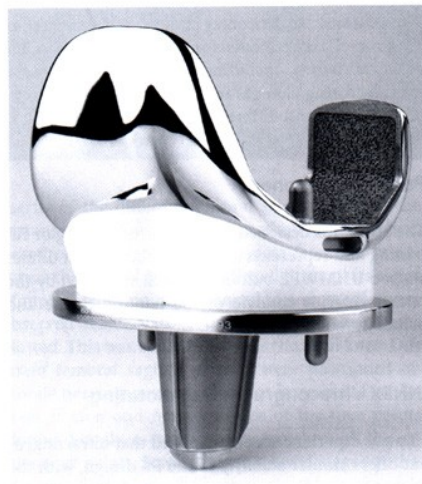


Fig. 1.25. INNEX UCOR

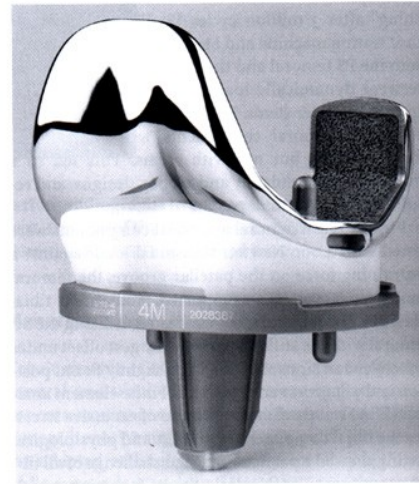
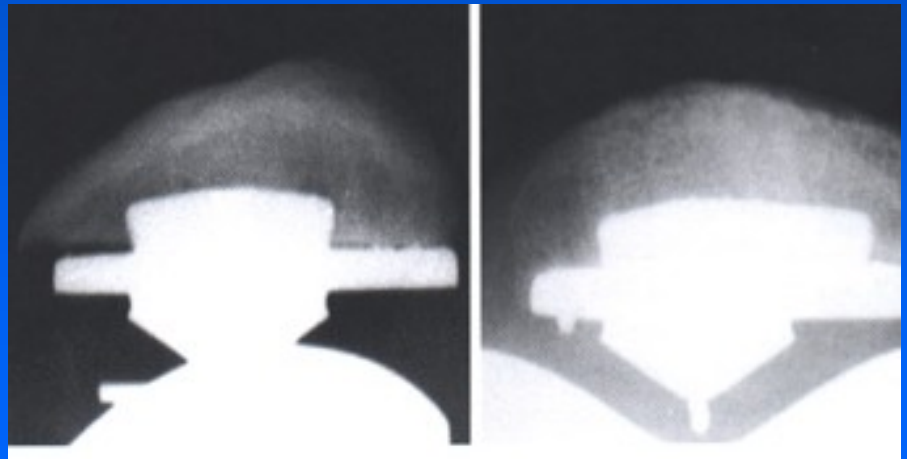
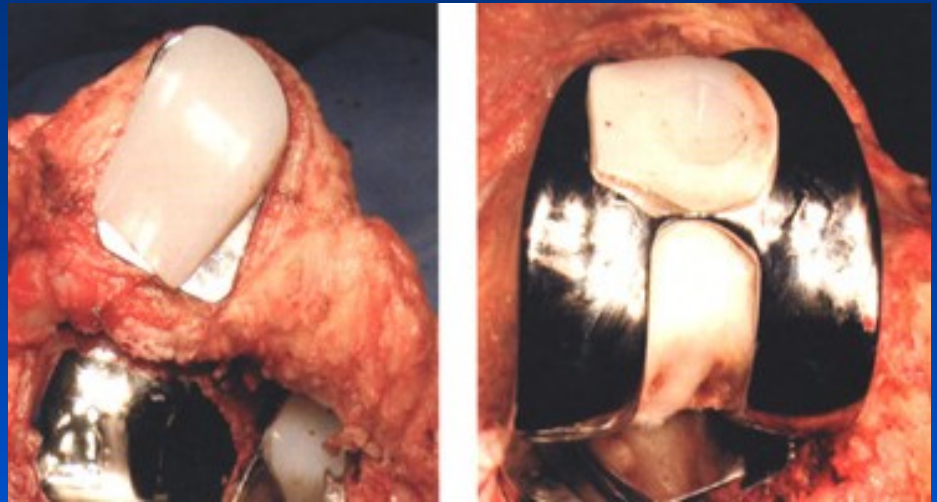
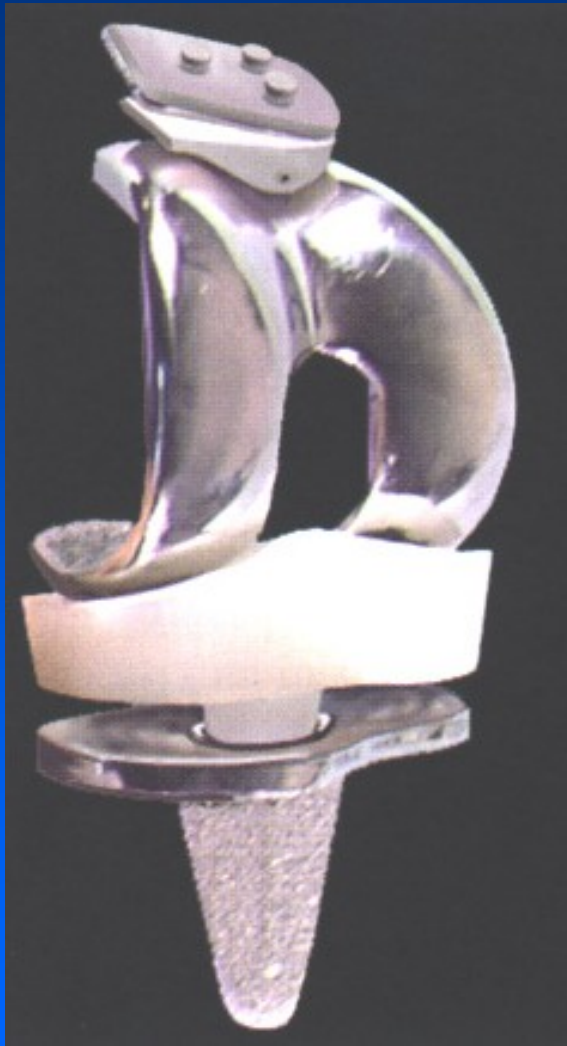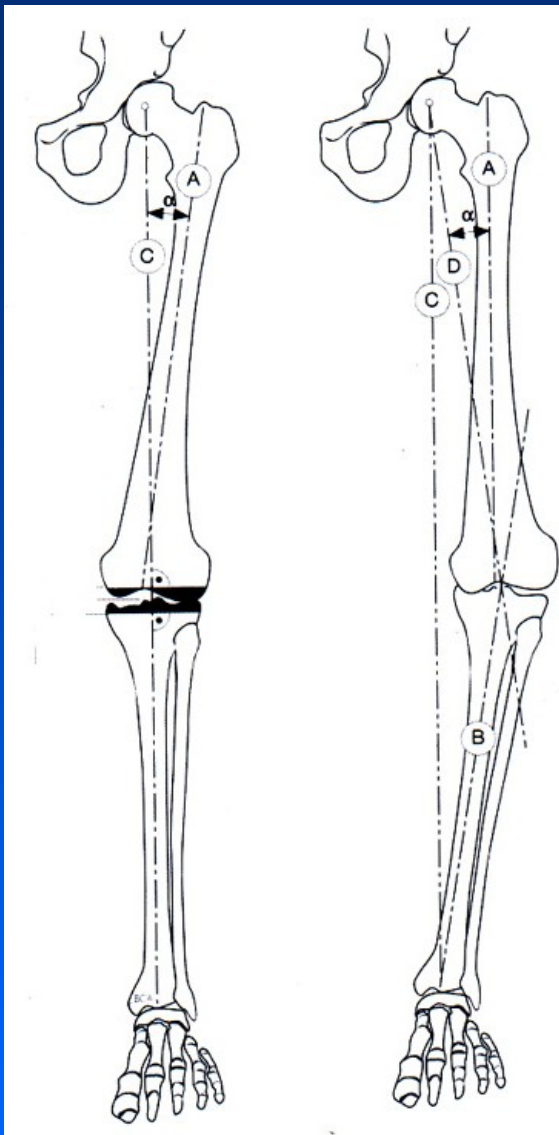


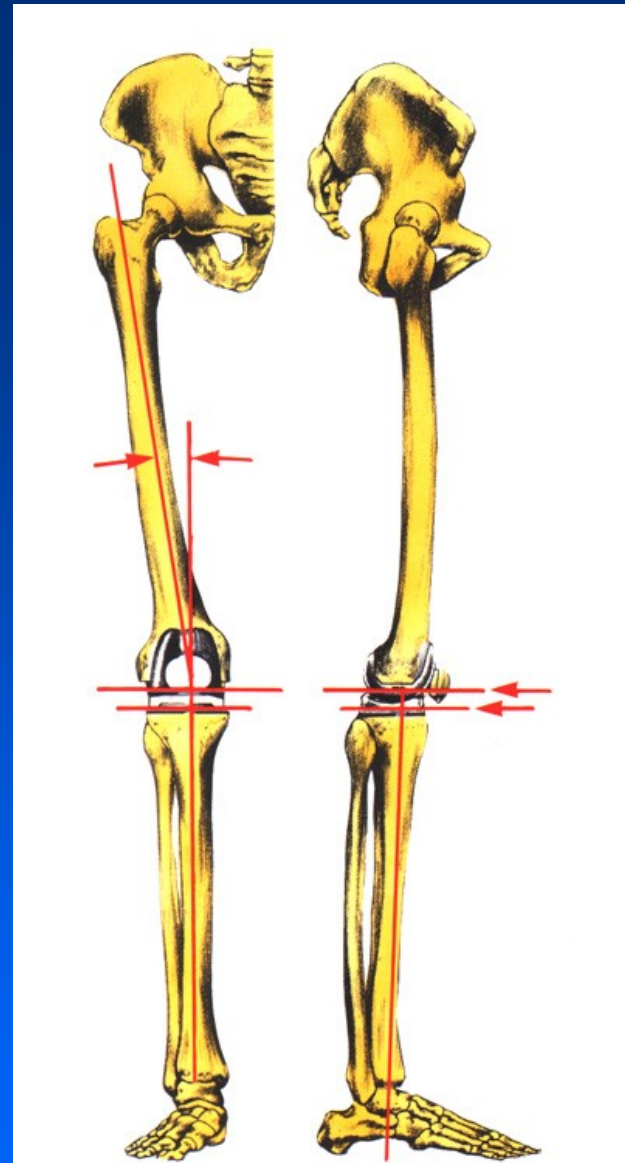
Fig. 1.27. INNEX Fix UC

LCS TKA



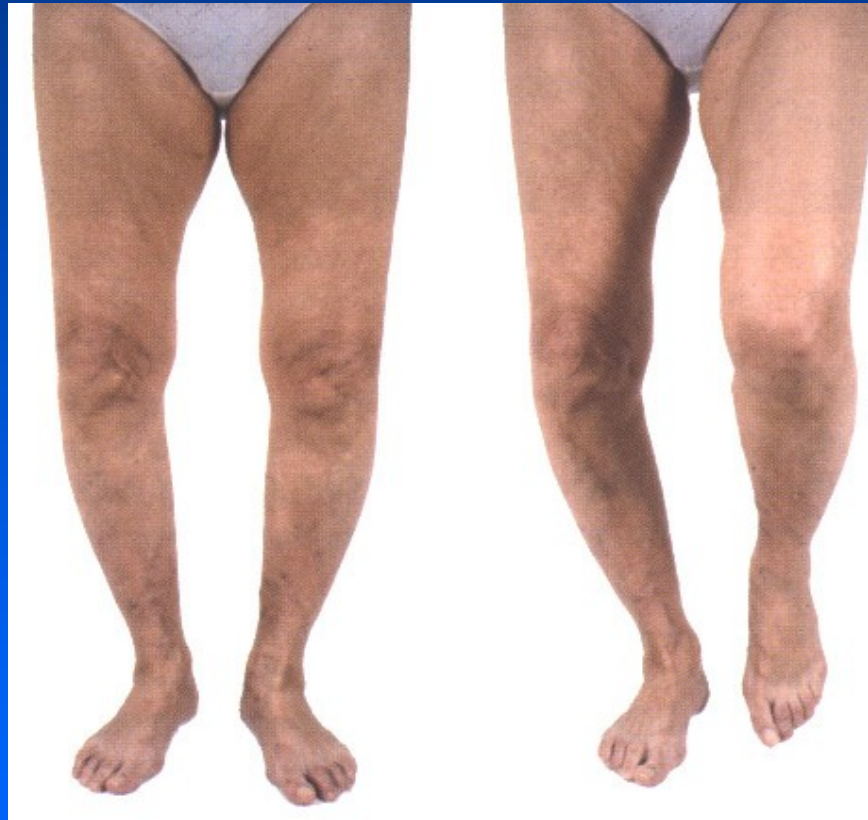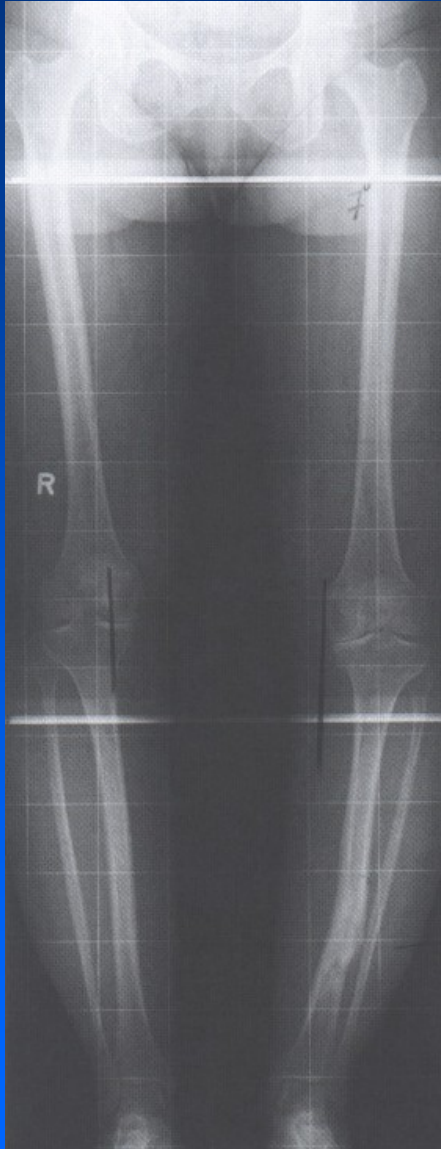


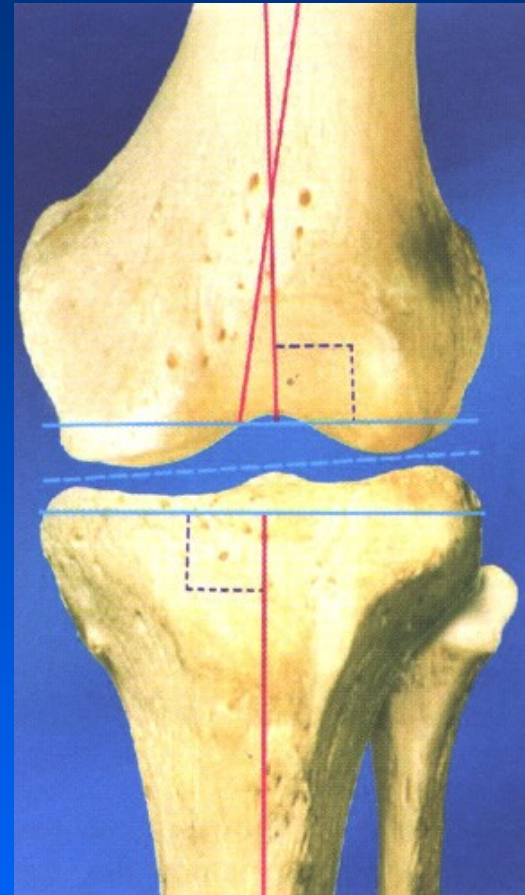
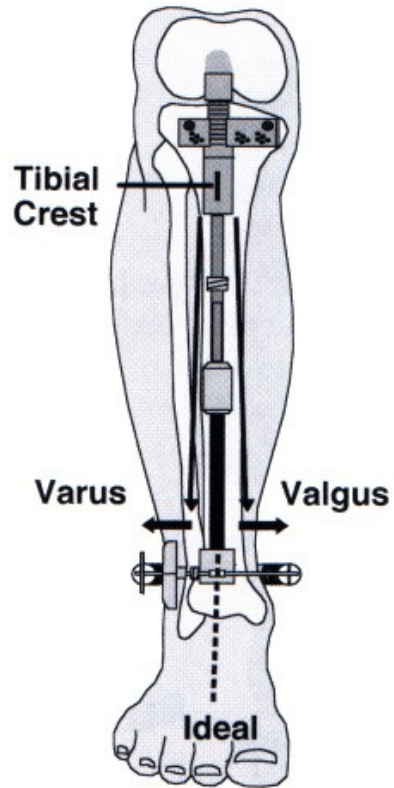
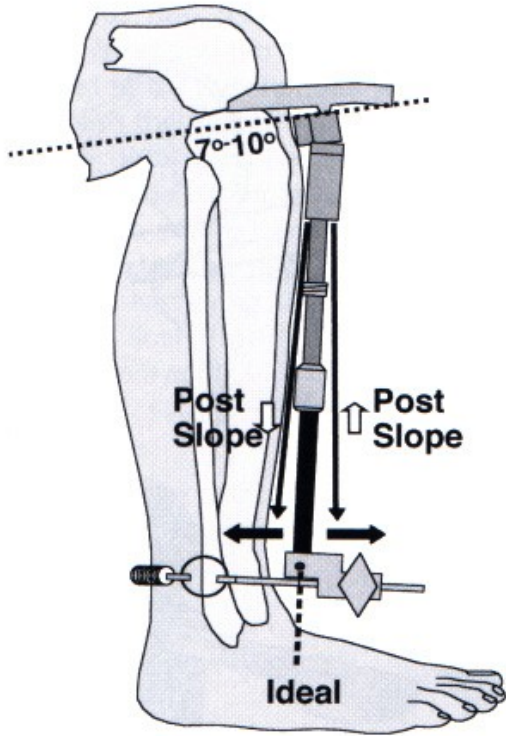
Mechanical alignment



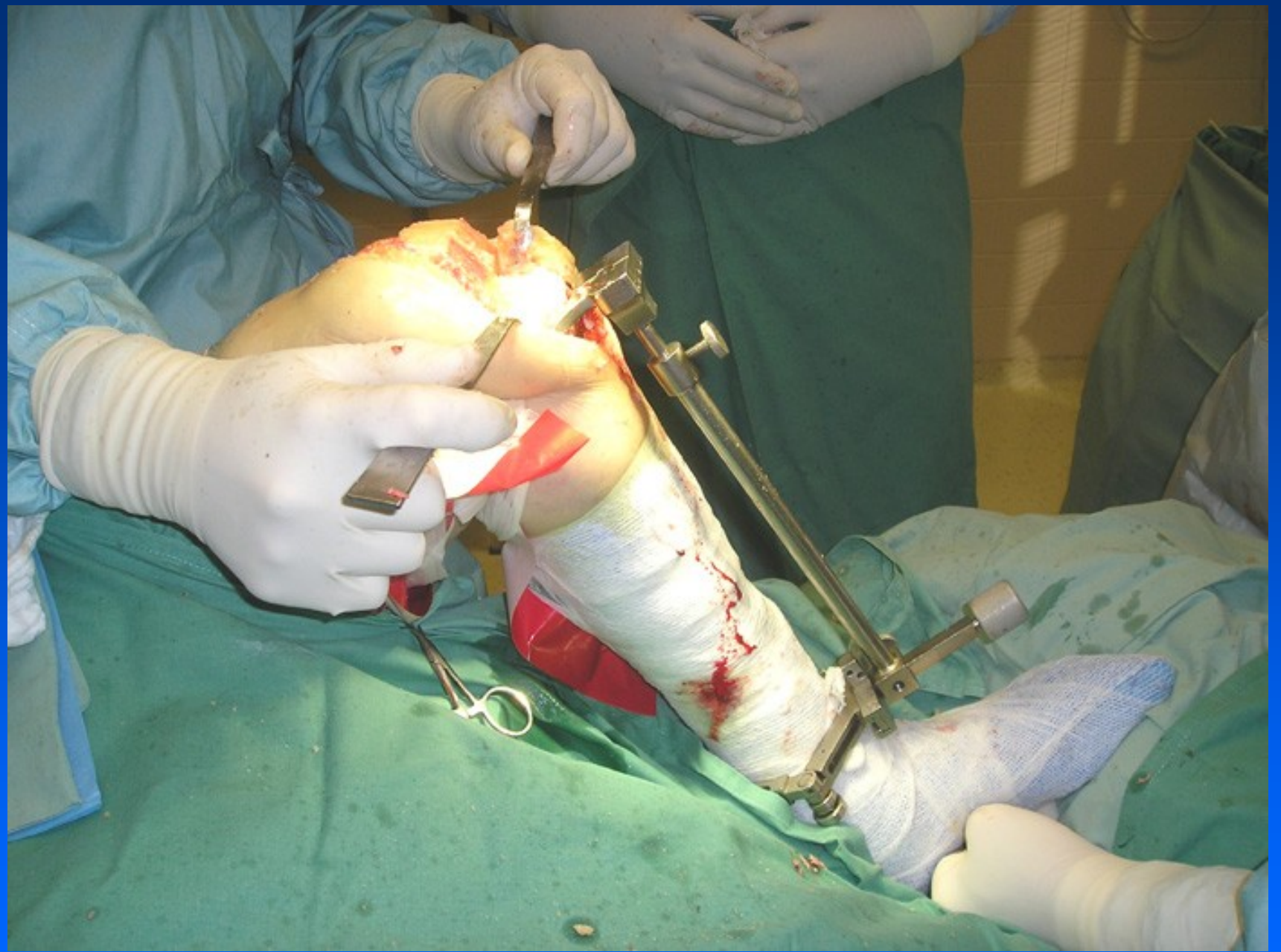
Anatomical alignment

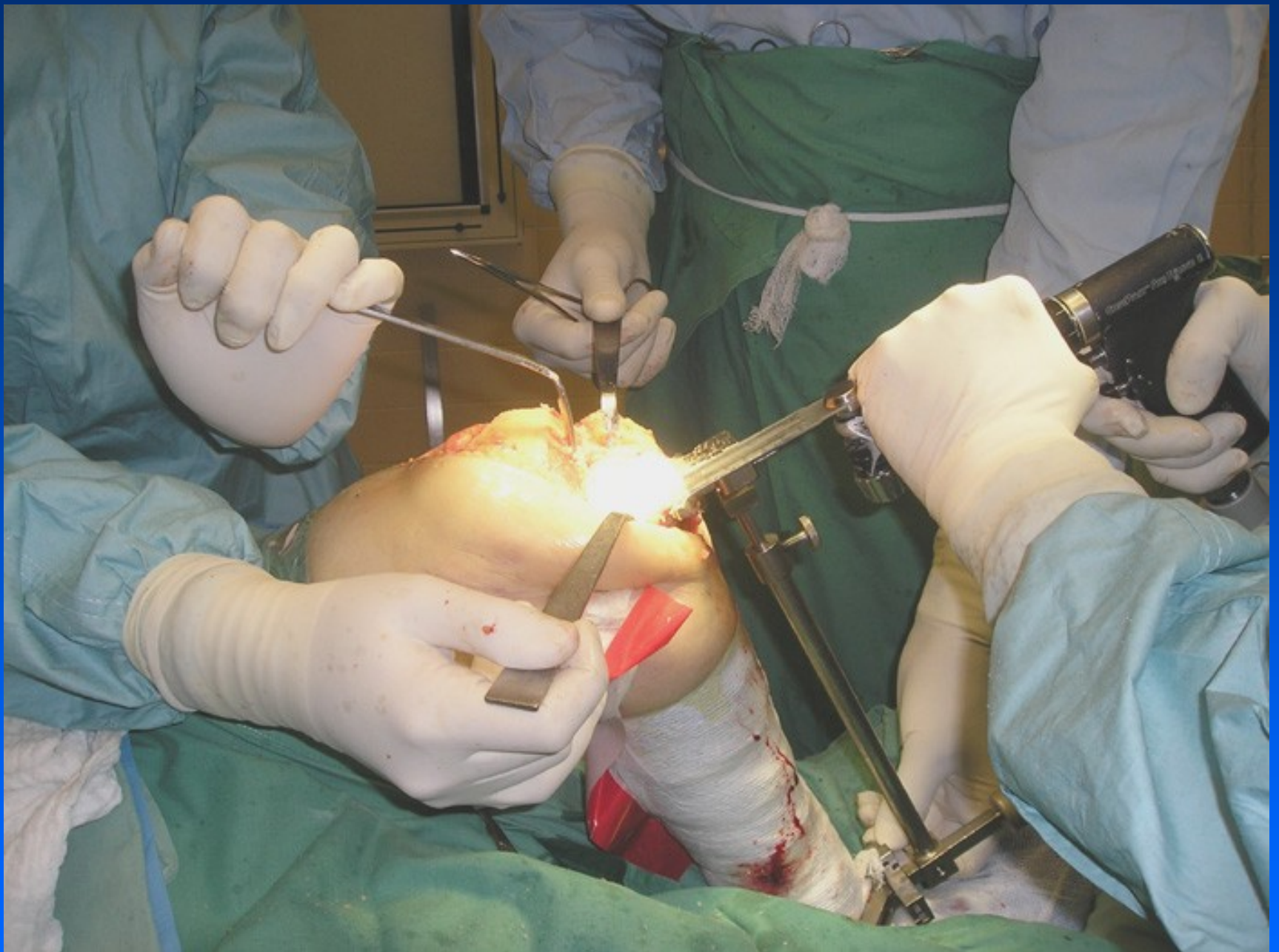
X ray in standing position

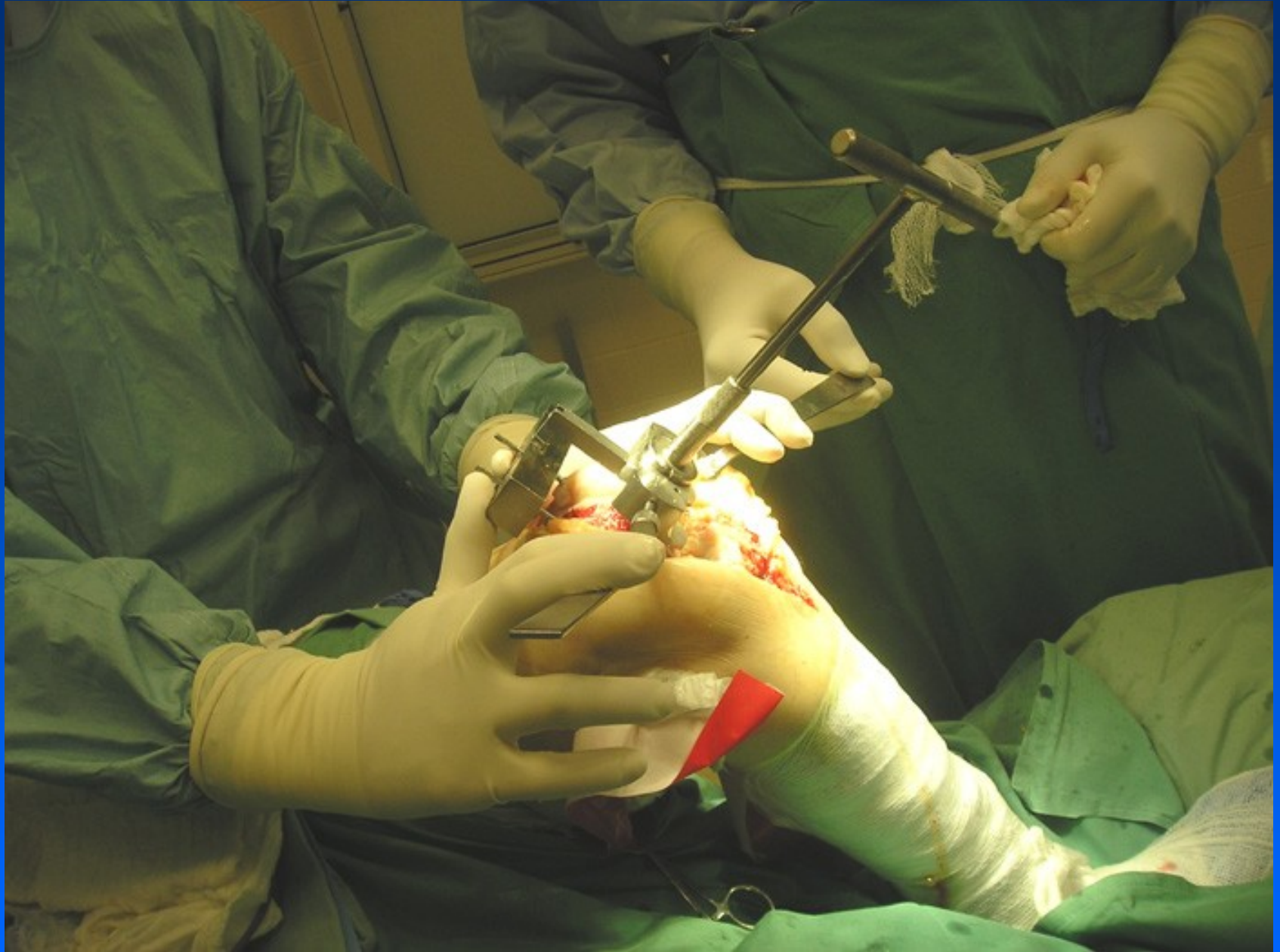

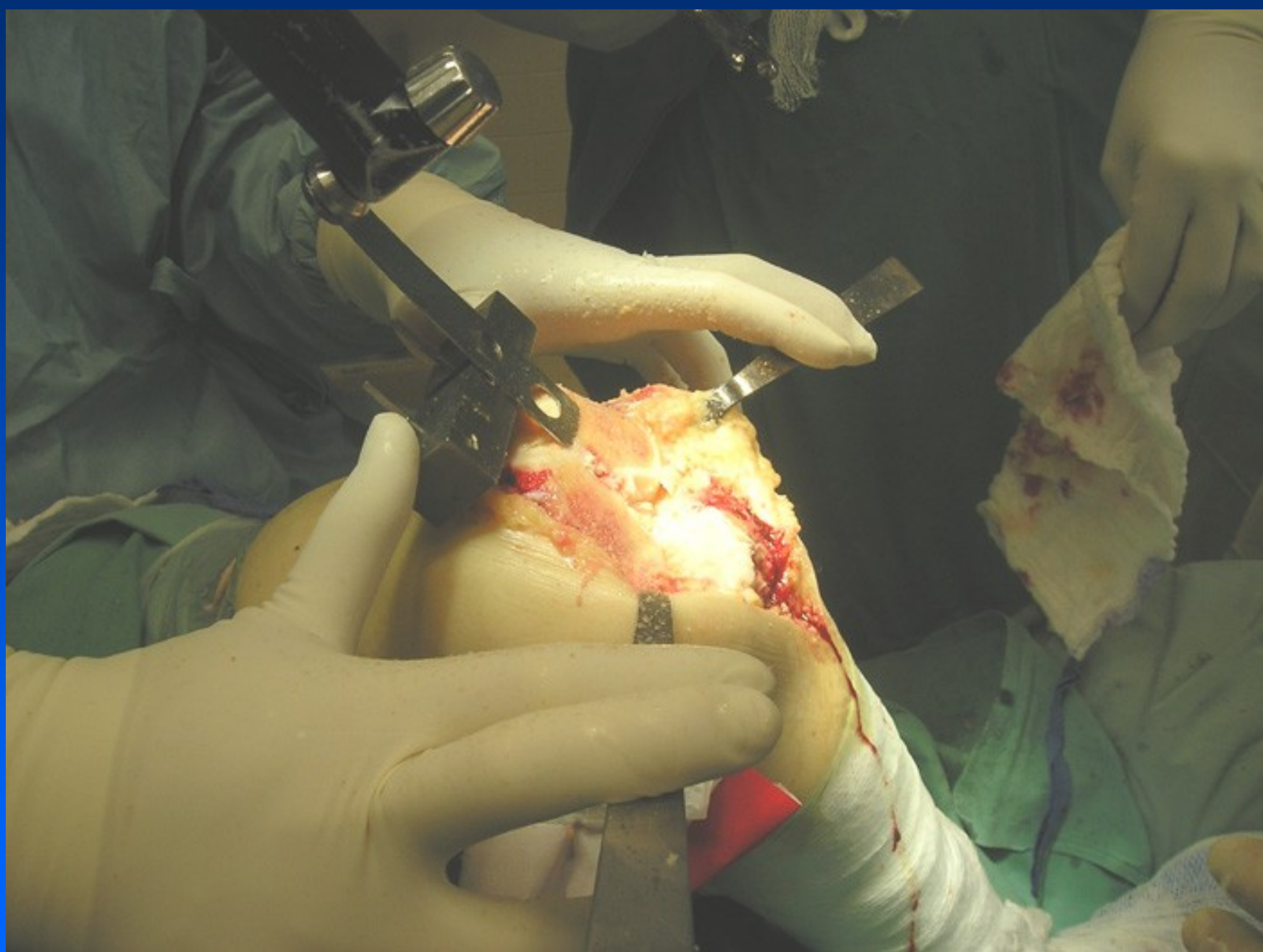


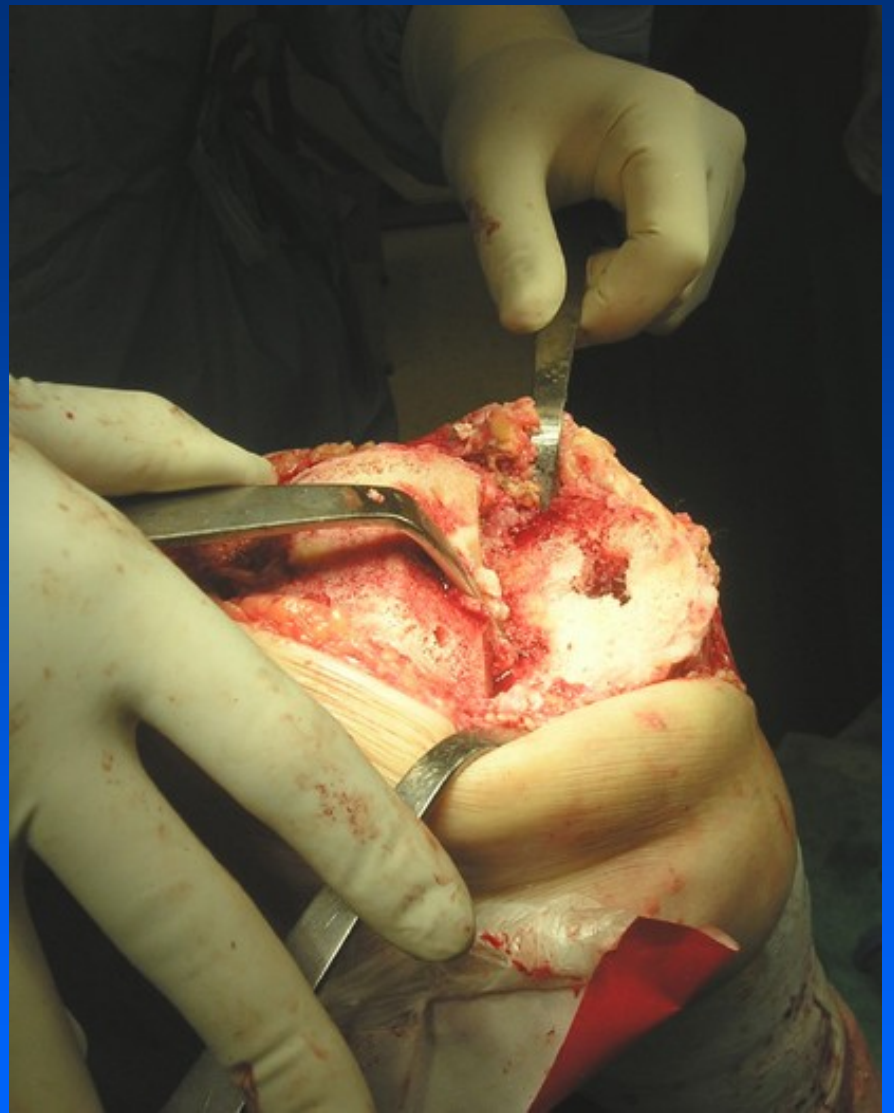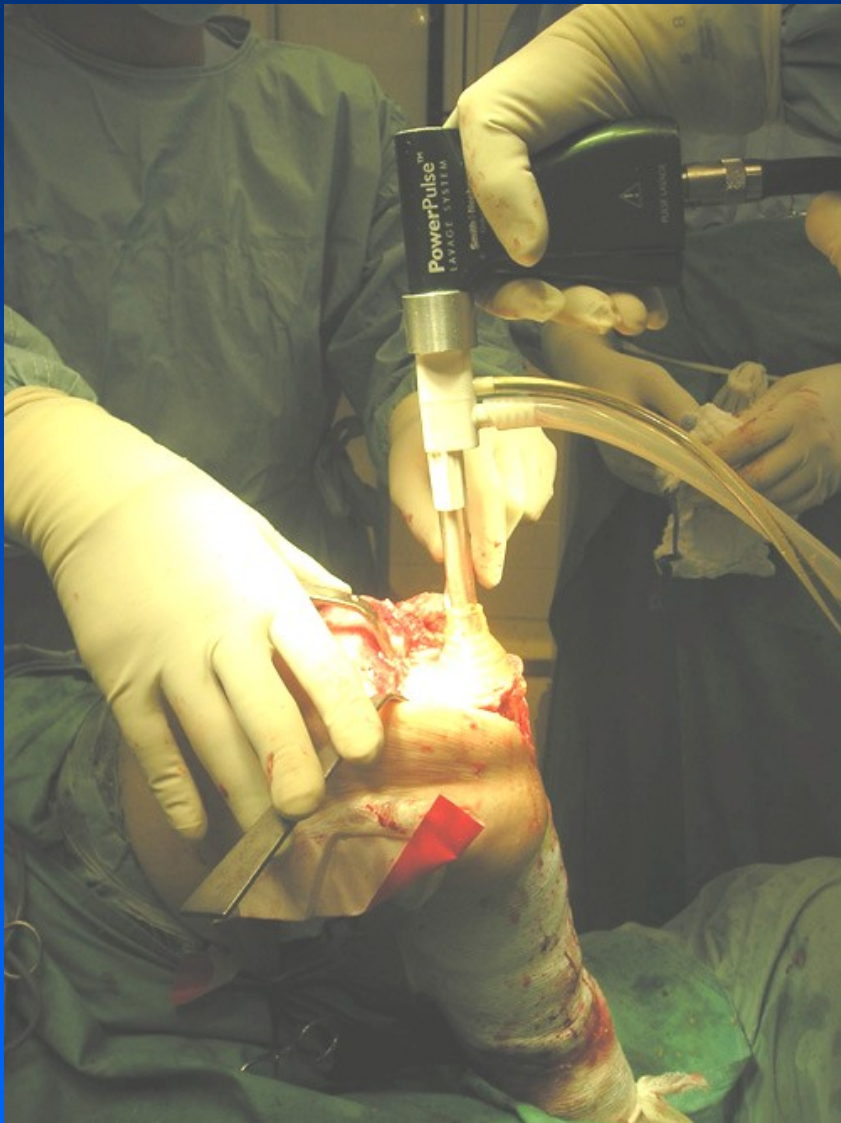
Resection levels

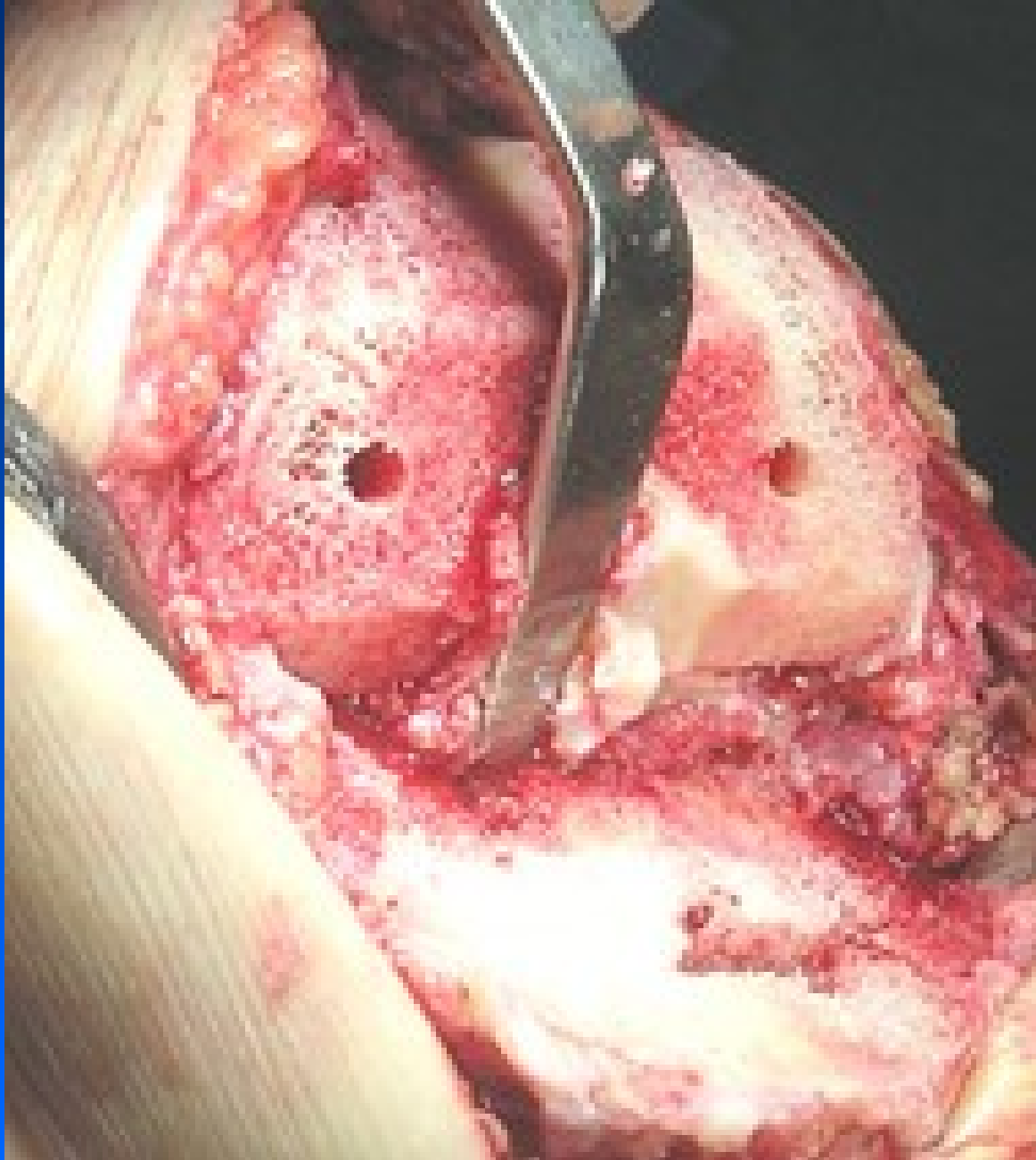


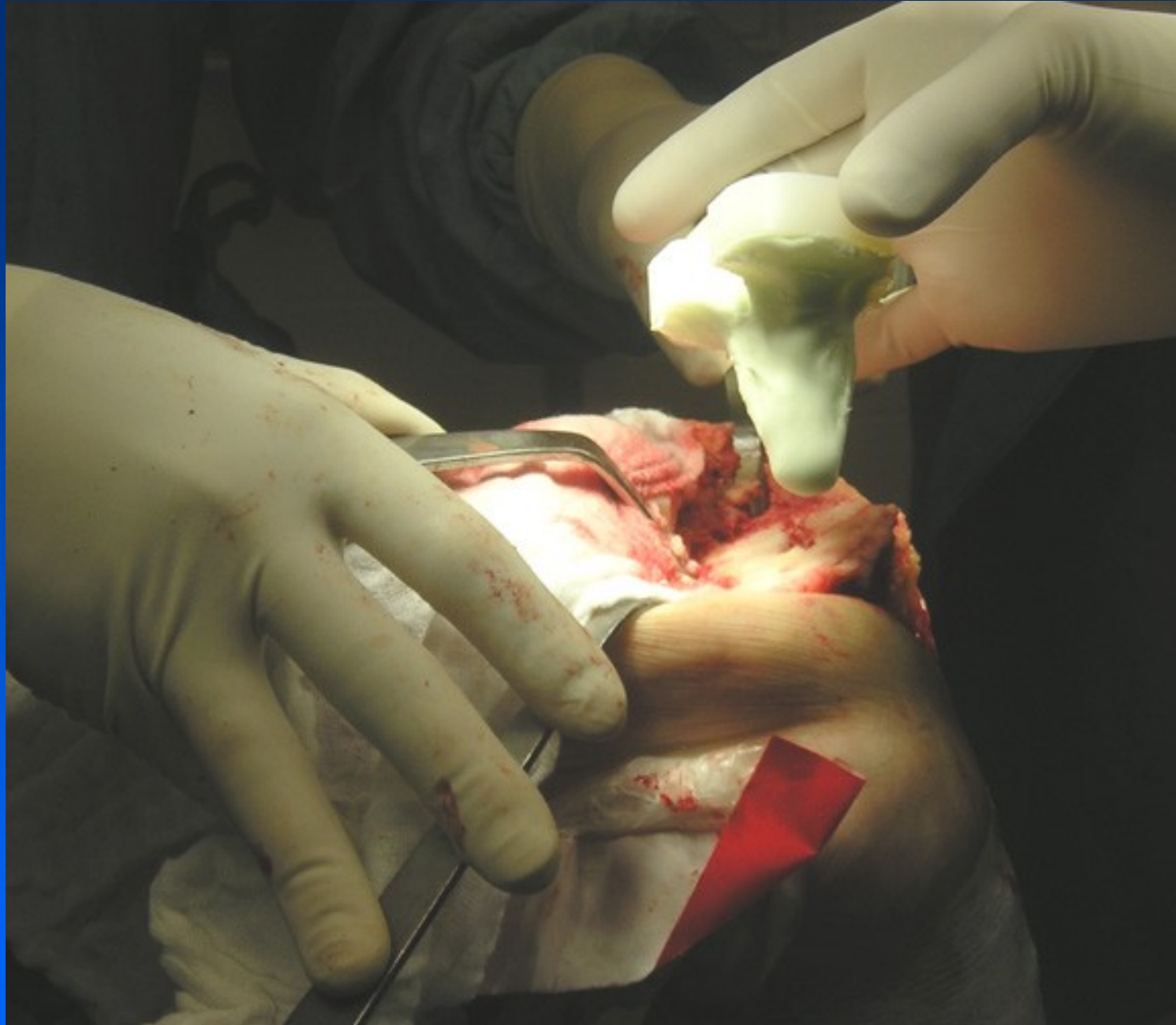
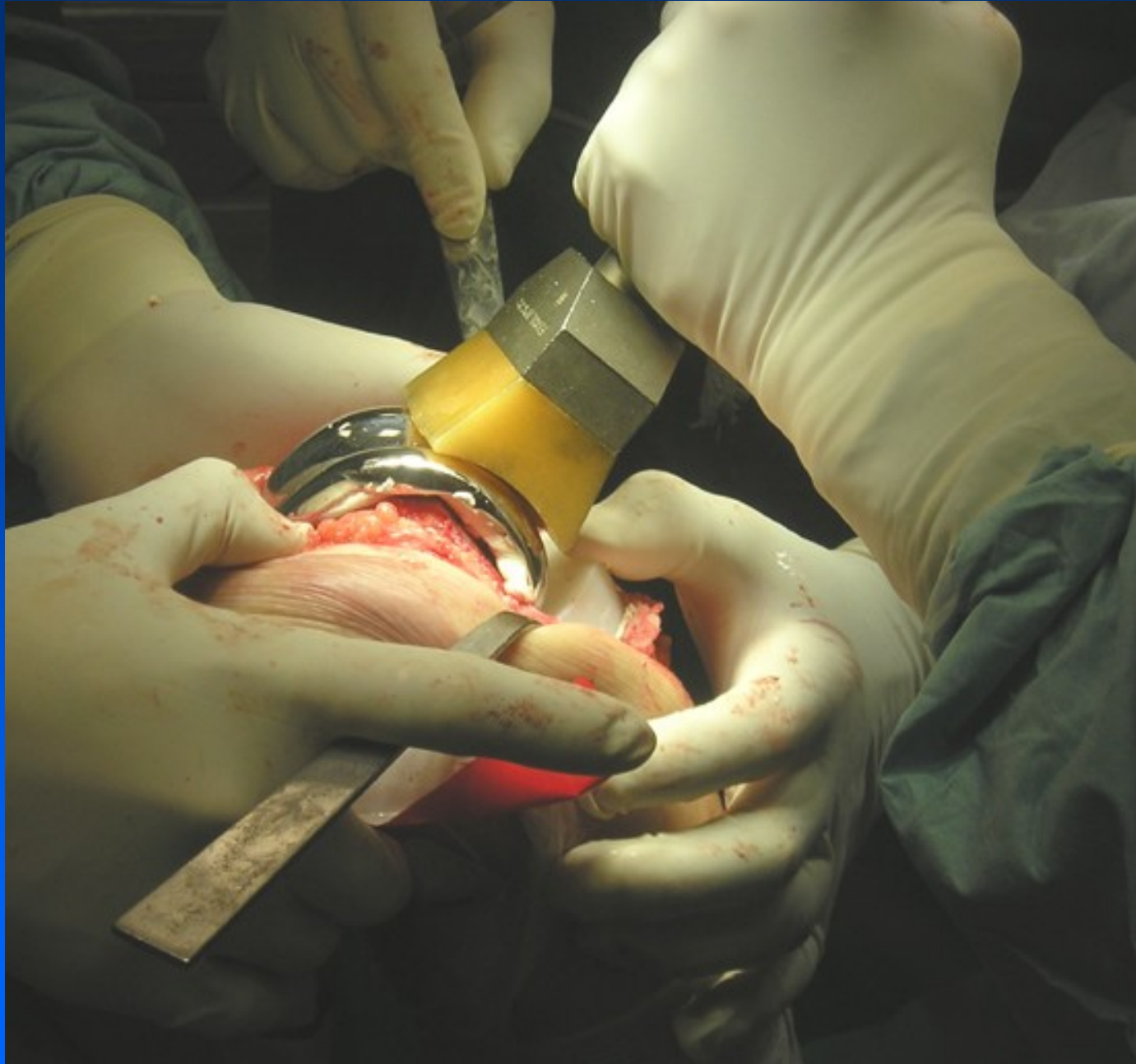


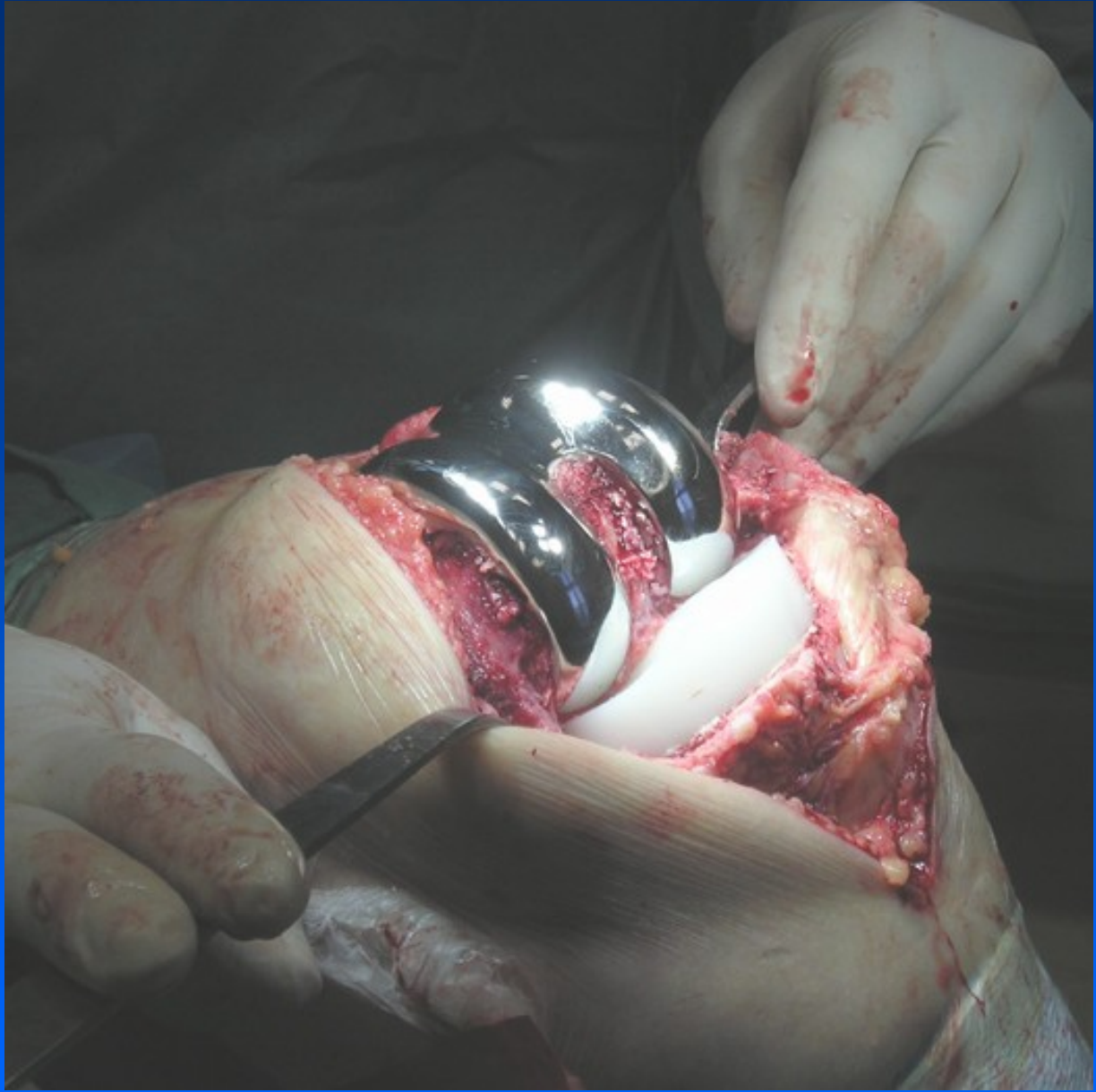




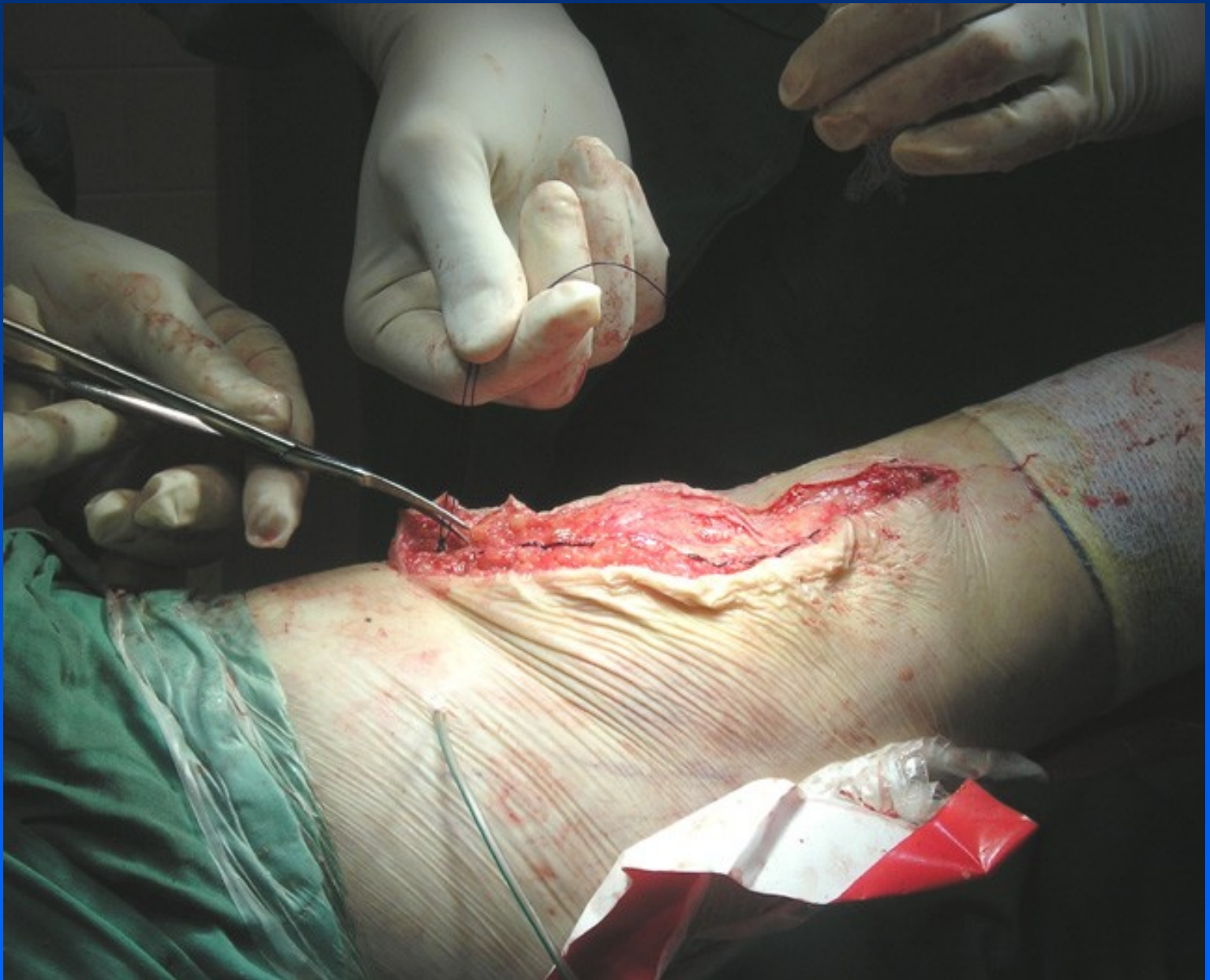



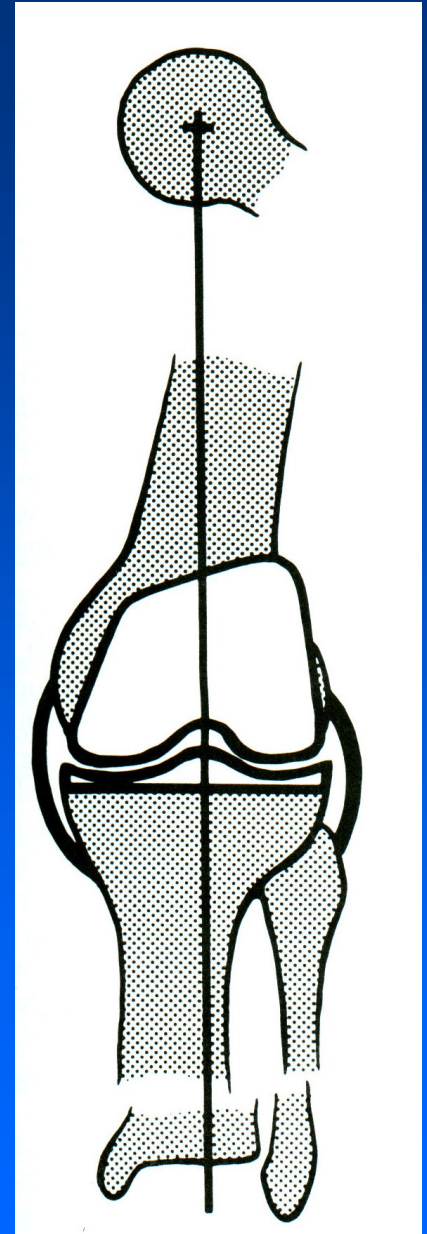




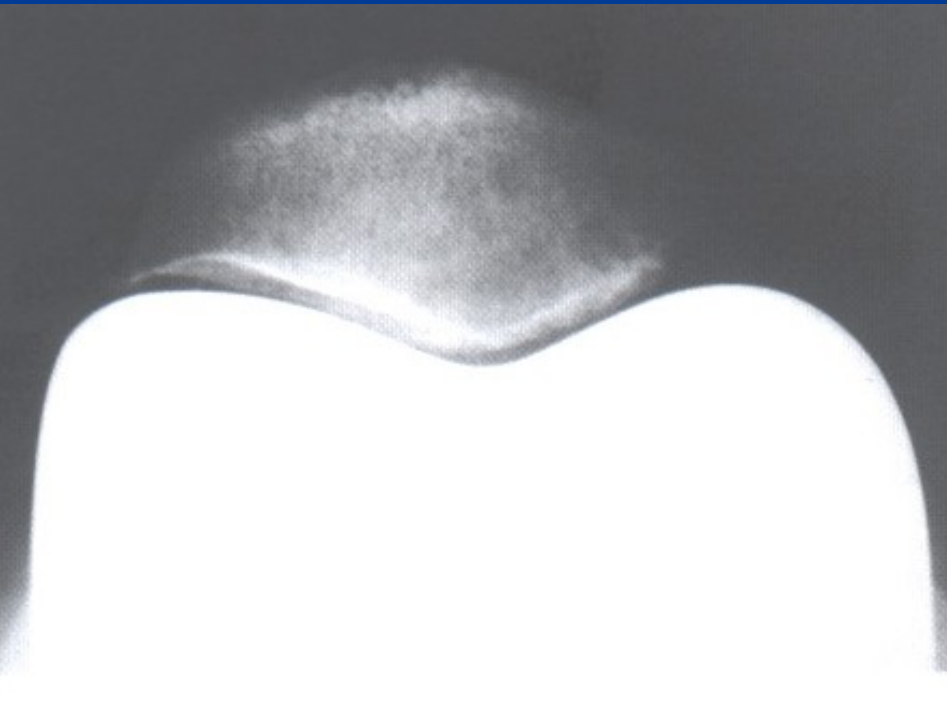


Principles

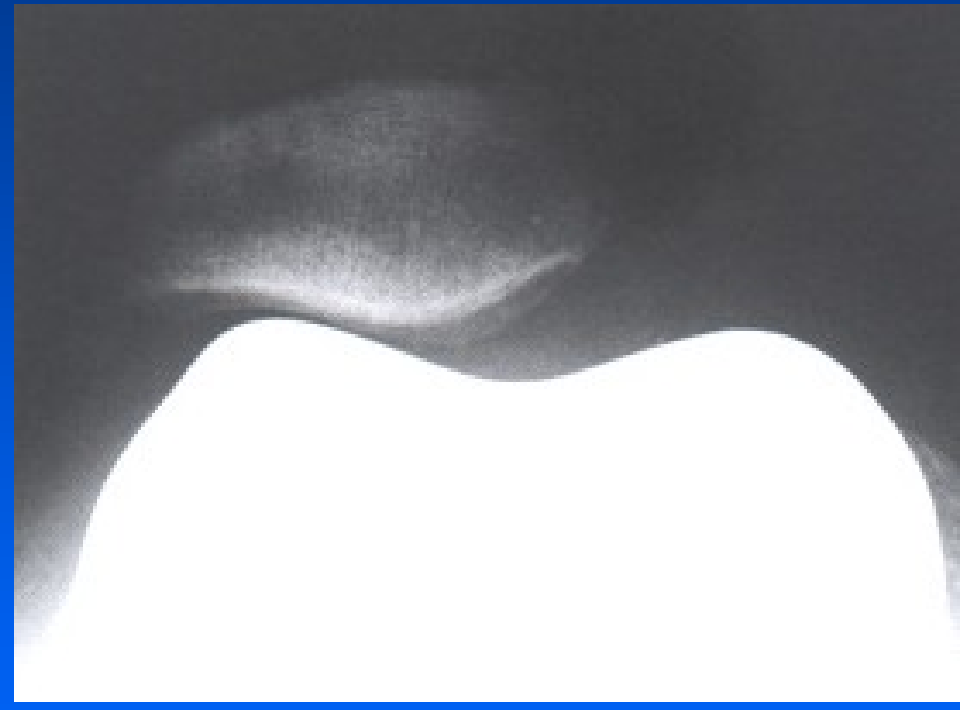
- Correct tension of soft tissues
- Correct alignment 5 -7° valgus
- Correct joint level



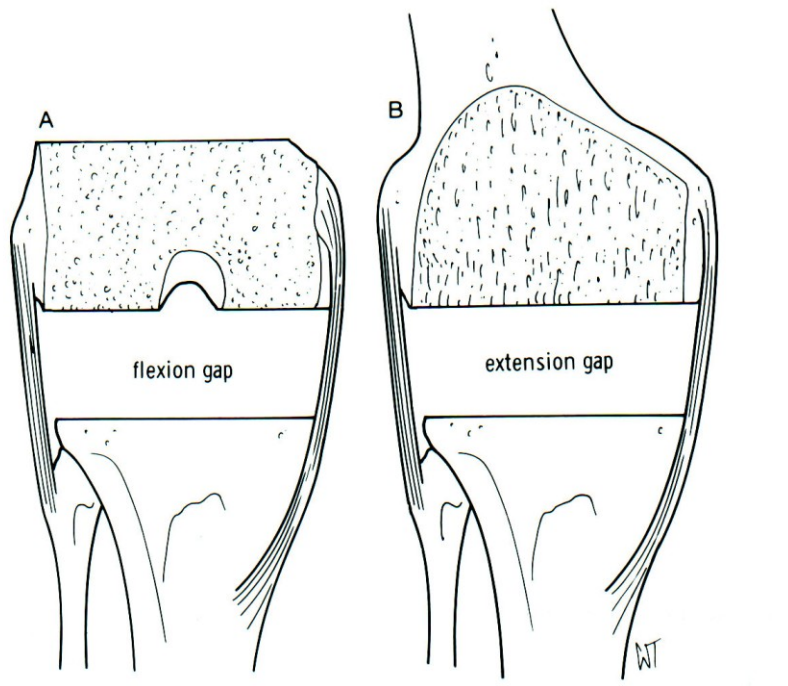
Patellar tracking



Correct



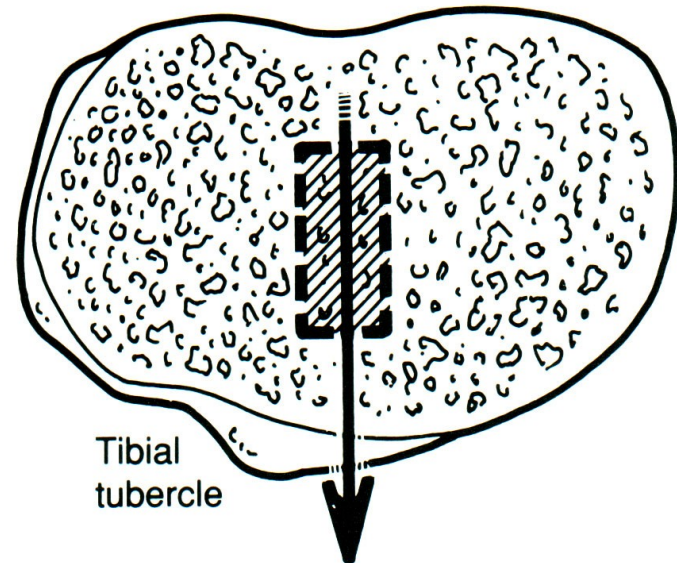
Incorrect



Flection gap

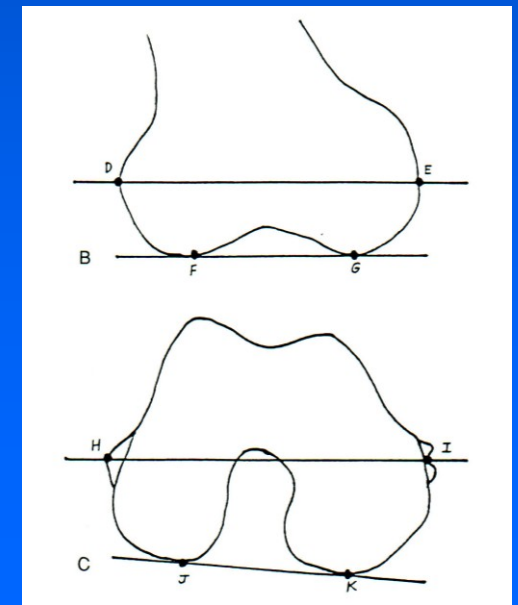
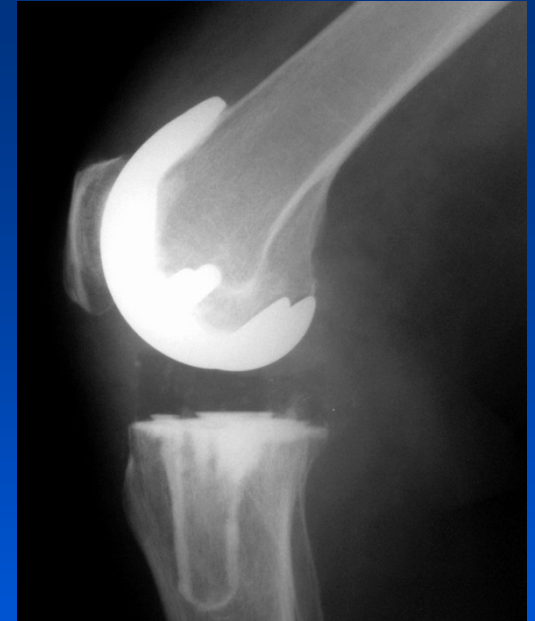Extension gap

External rotation
of tibial component



Femoral component

- On anterior cortex
- Parallel with transepicondylar line
- External rotation 3

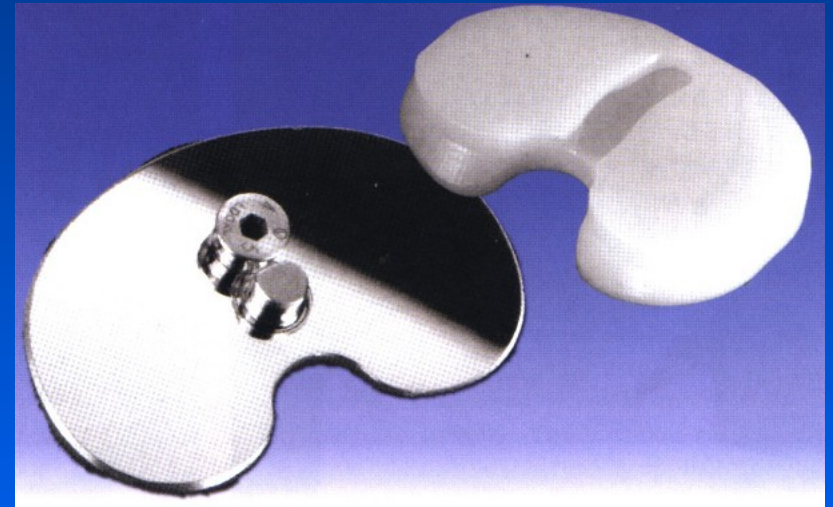

Modern trends

PC navigation

Miniinvasive surgery

Rotating plateau

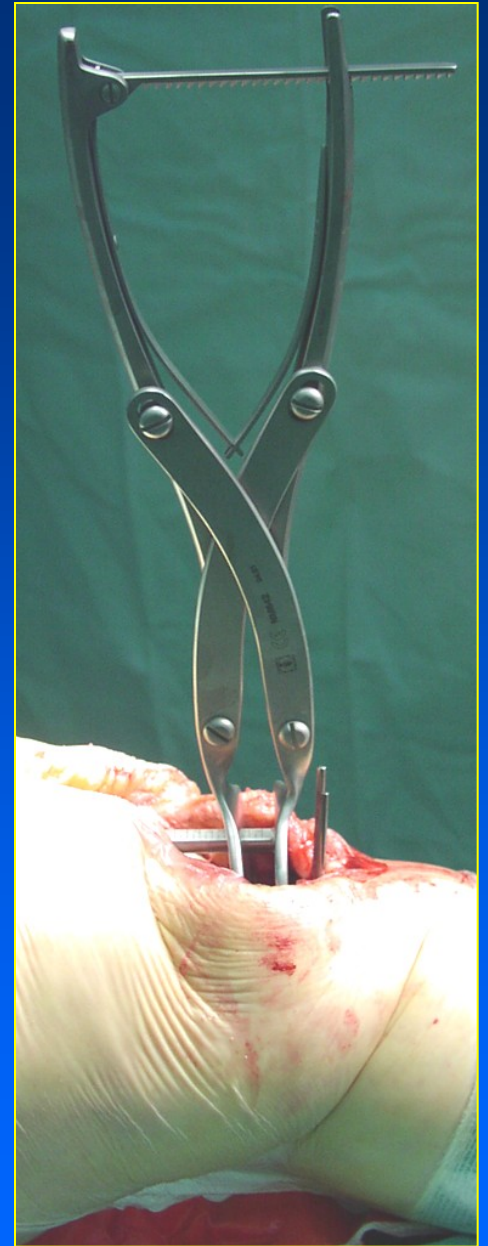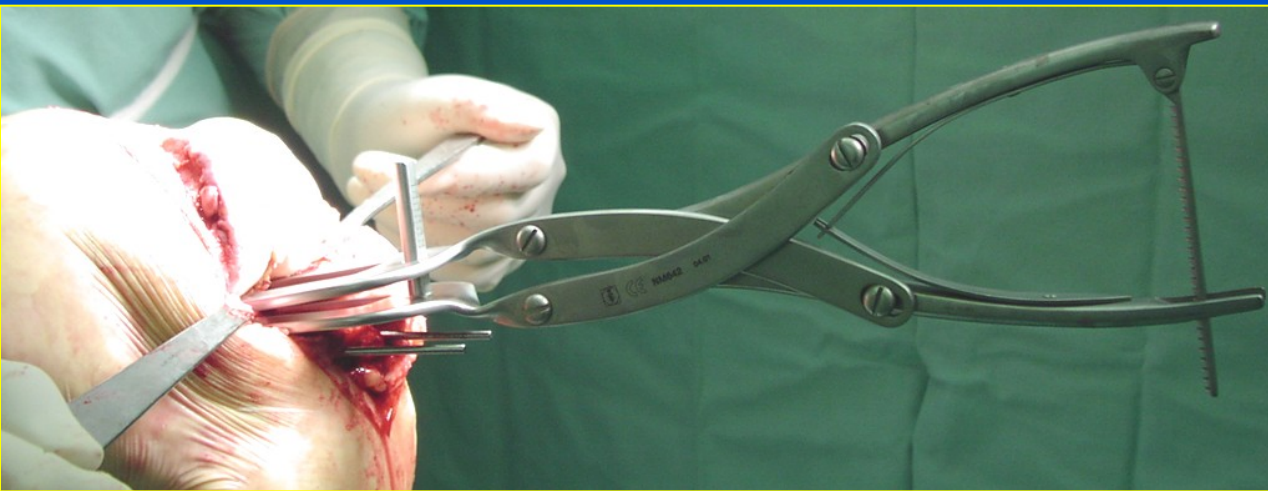


TKA Search Evolution - rotating plateau



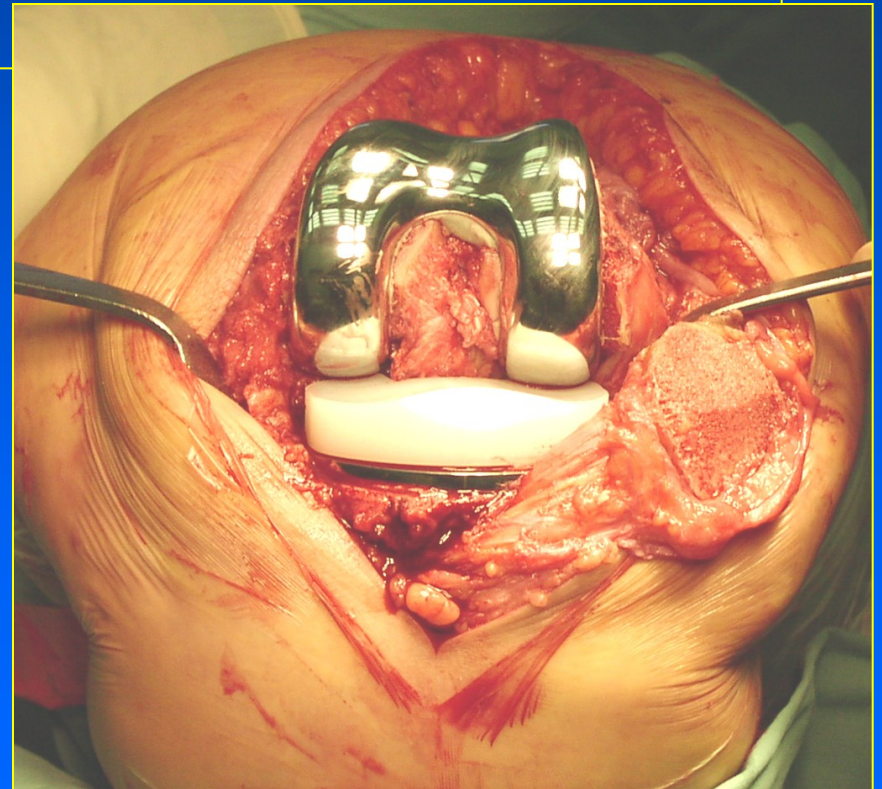
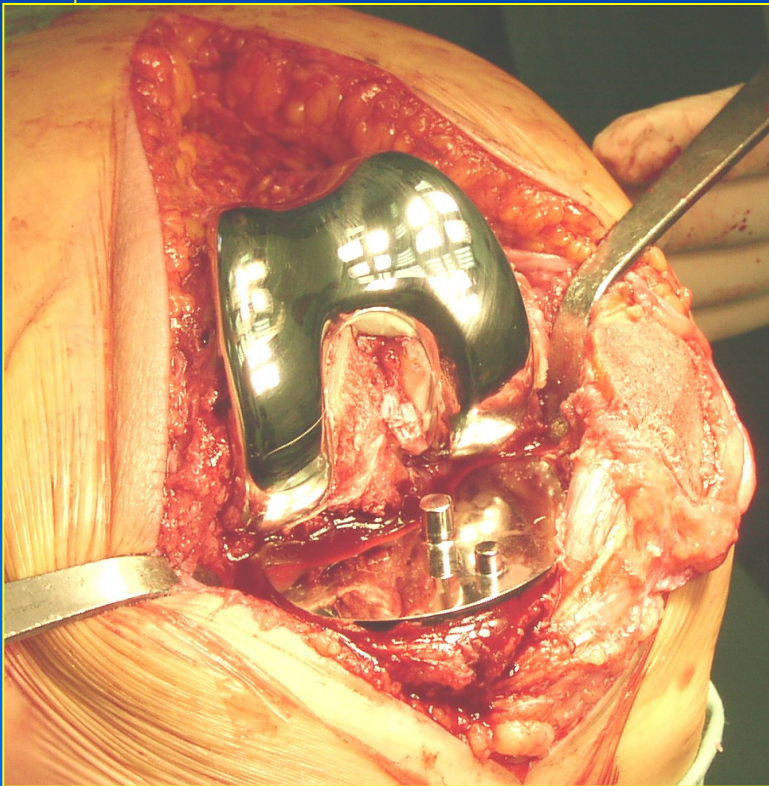
Implantation

- Flexion and extension gap

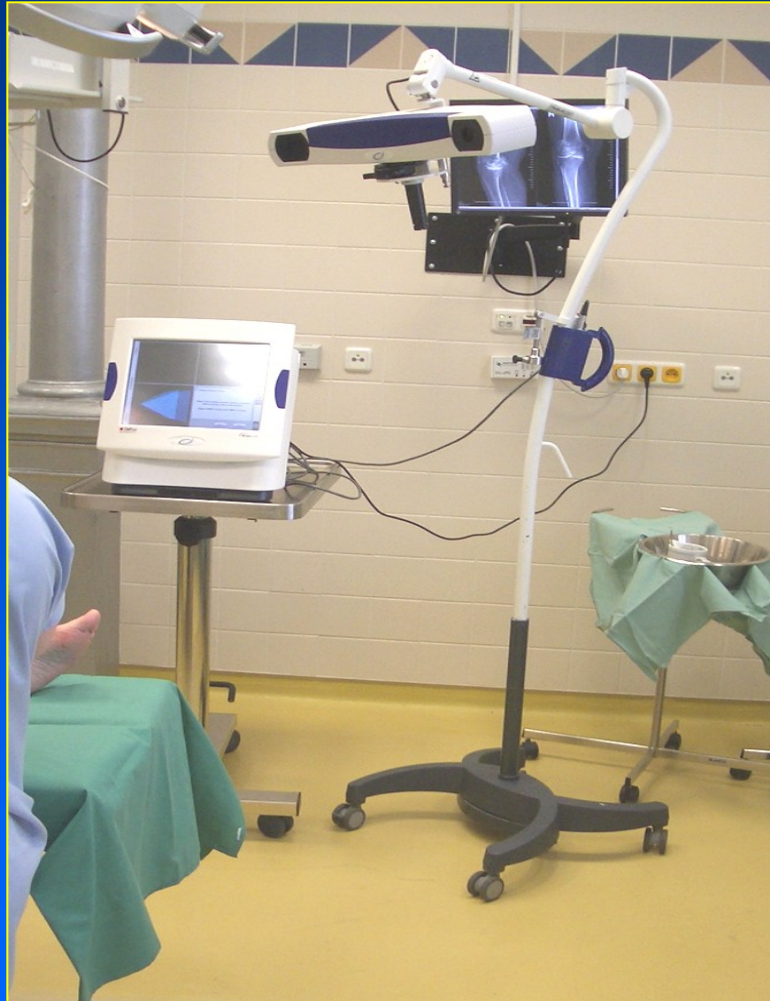


Implantation

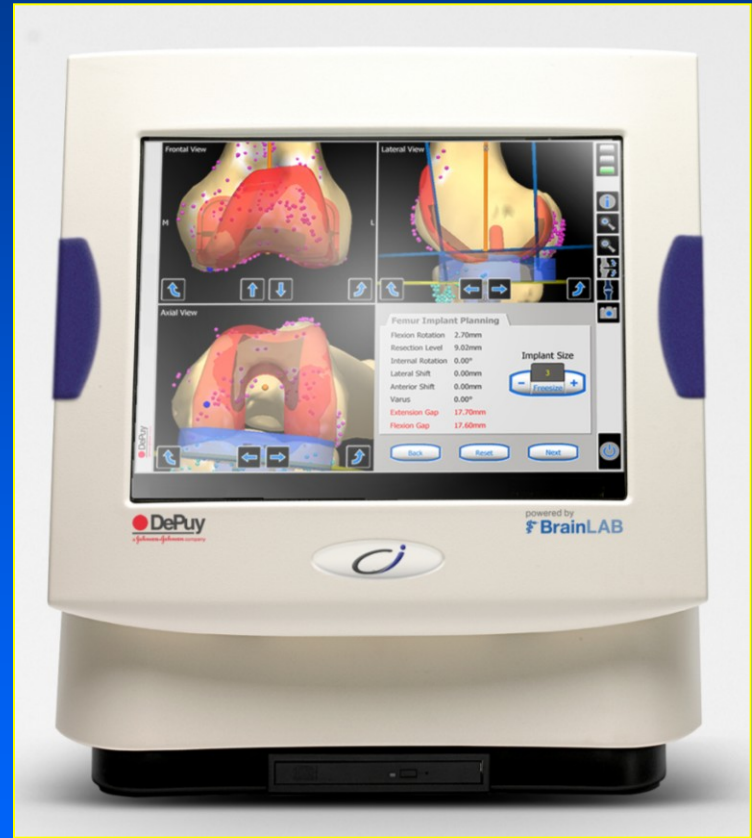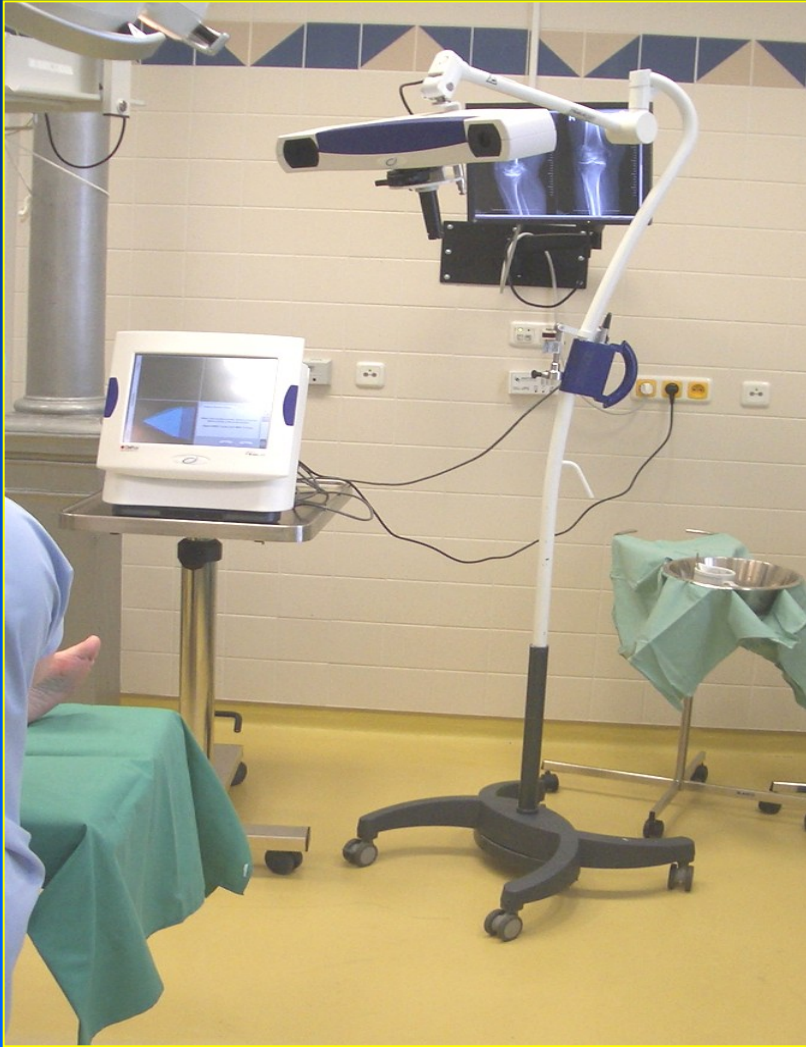
balancing of soft tissue



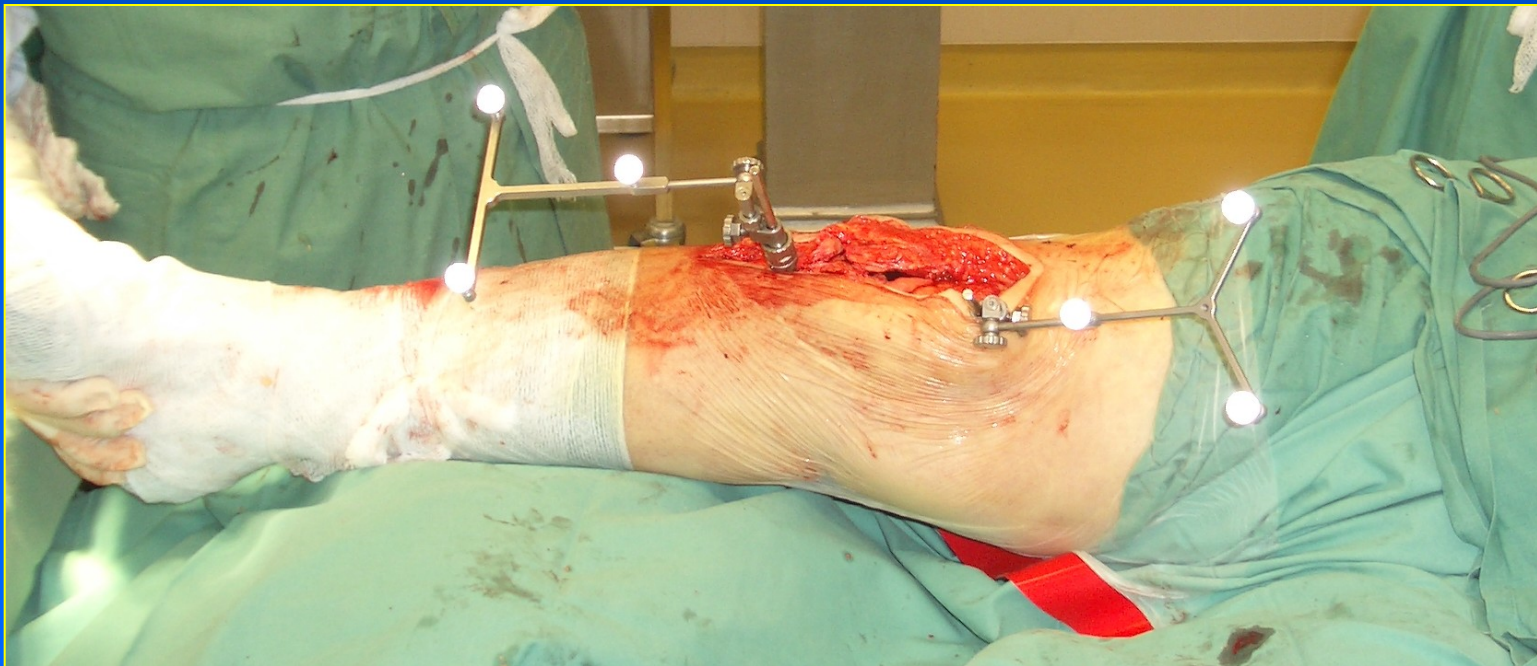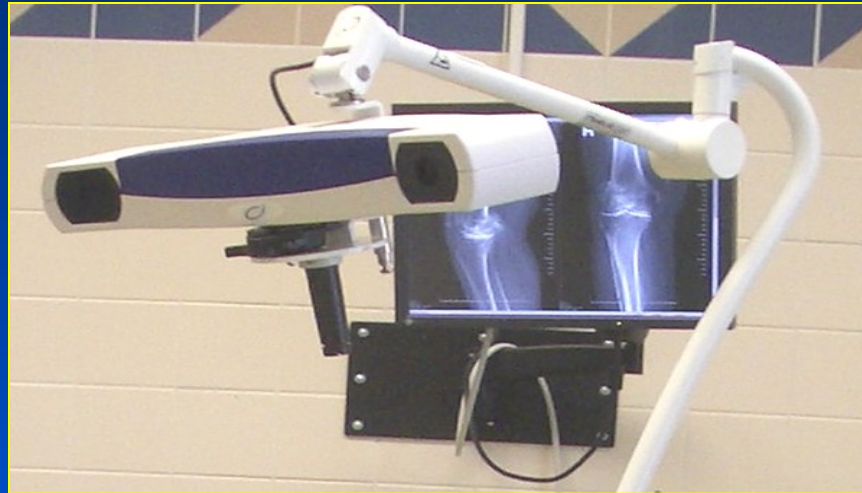
PC navigation



CI

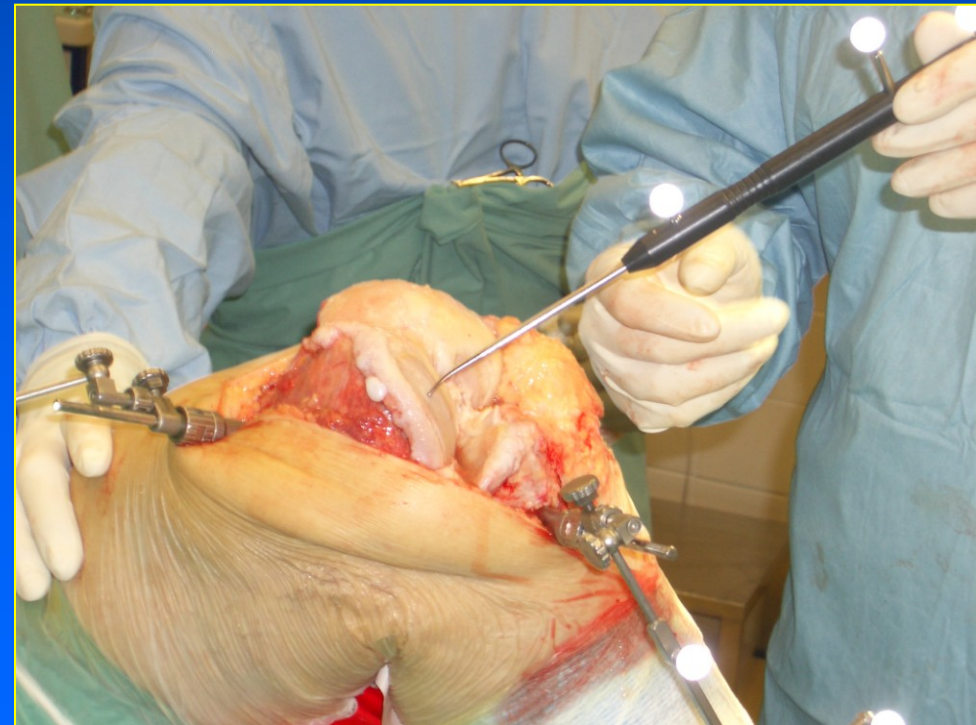
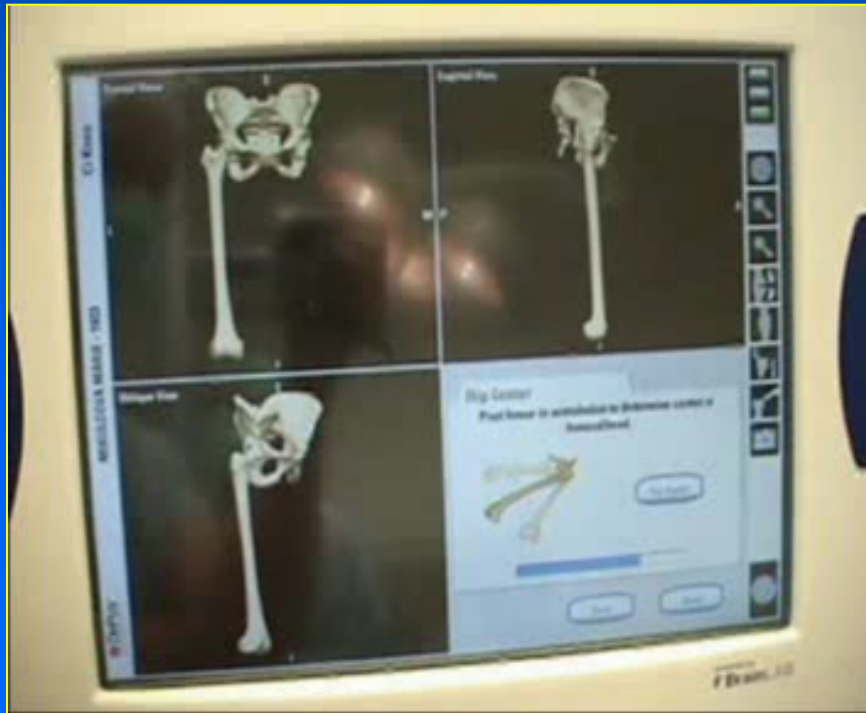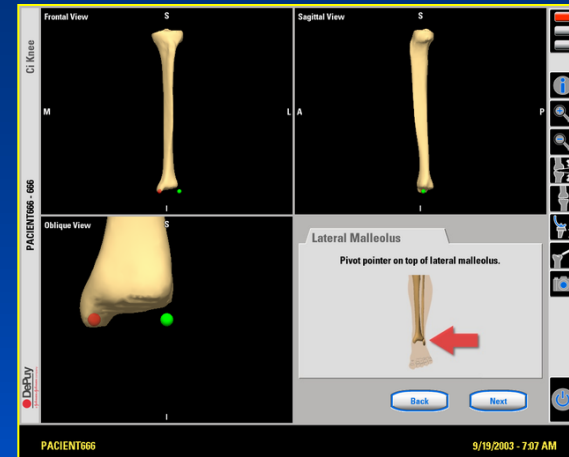


CI navigation

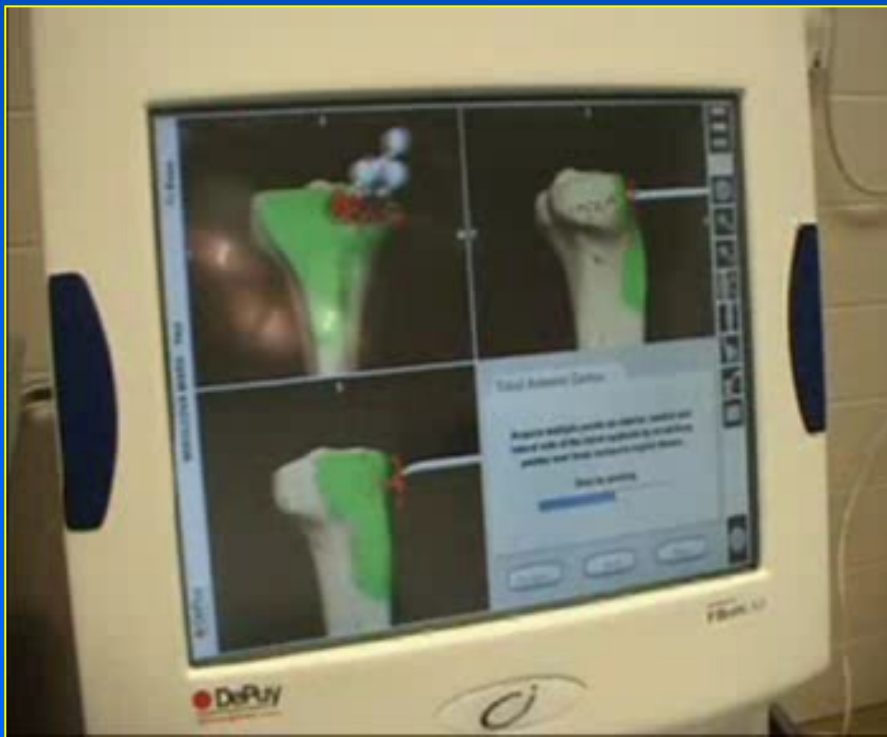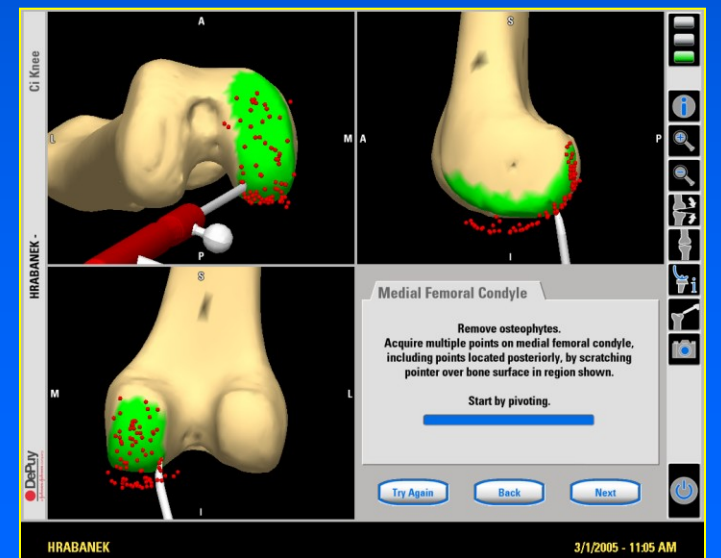
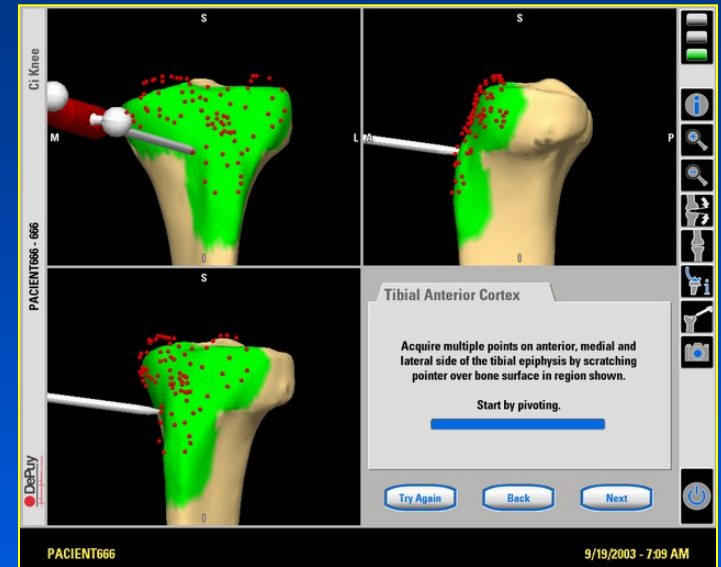


Pointer

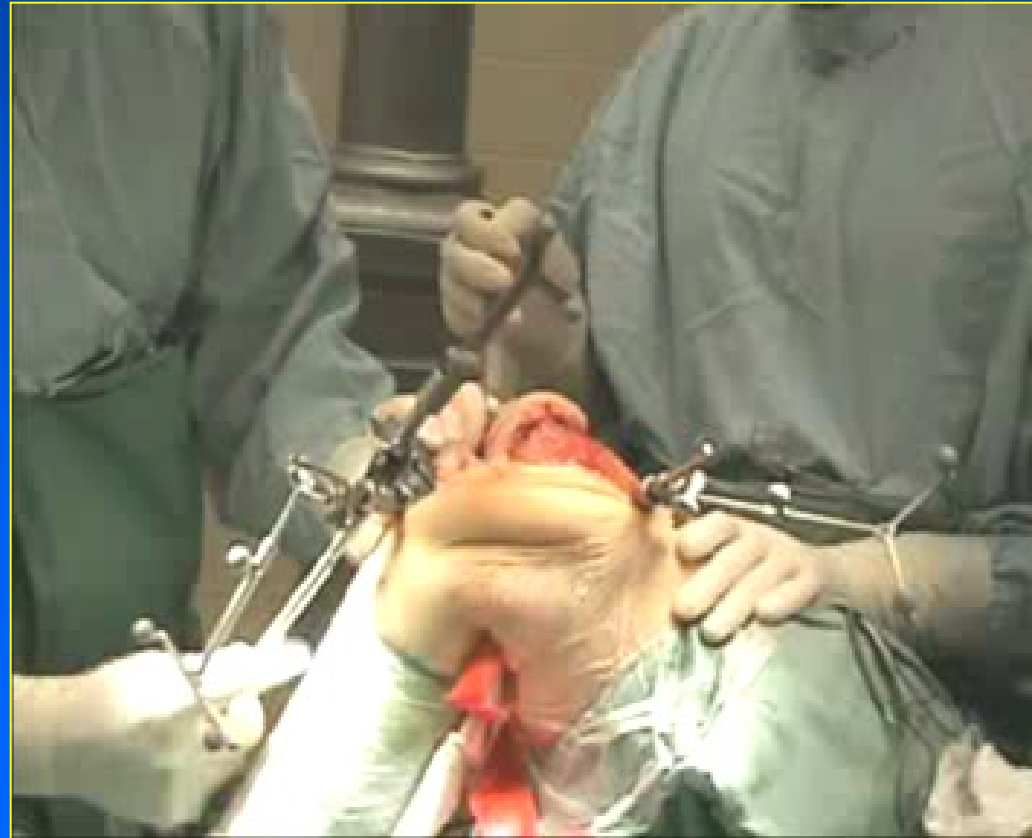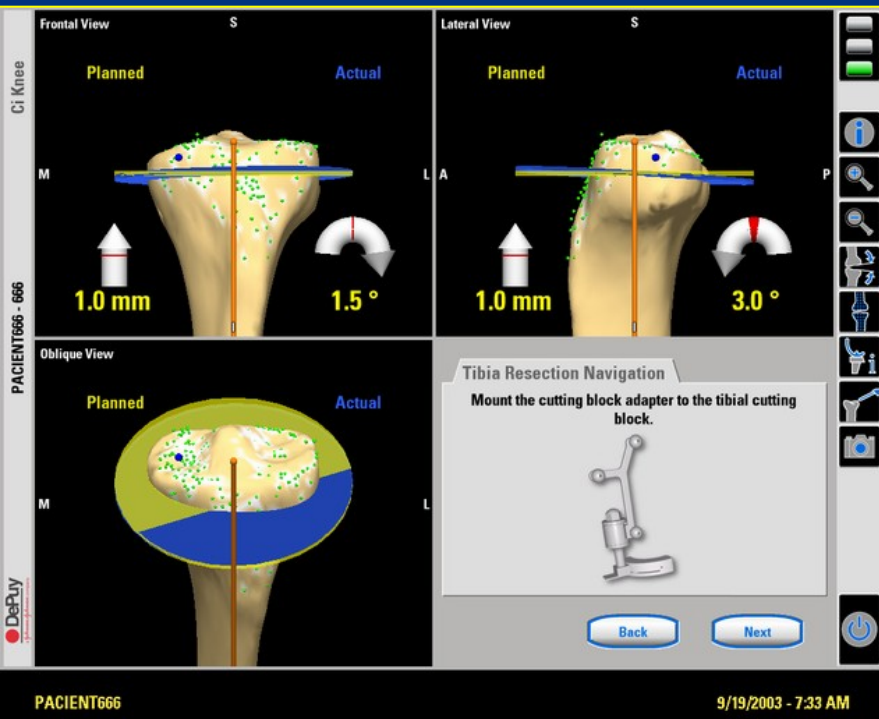
- Centre of the hip
- Centre of the ankle
- Centre of the knee



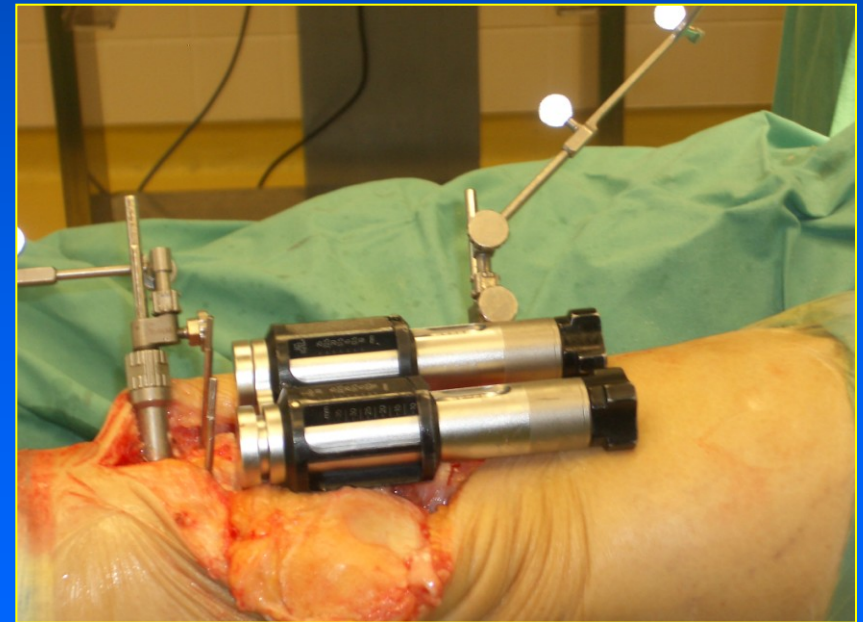
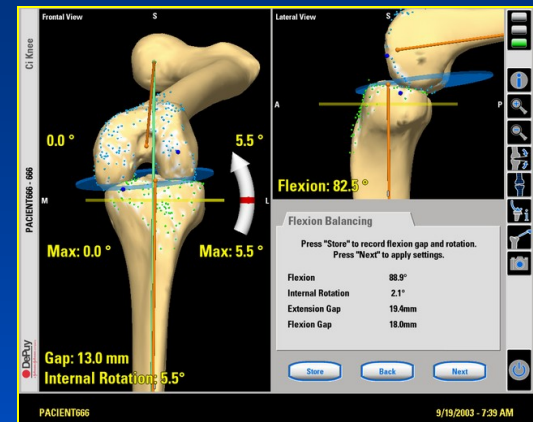
Multiple points



Tibial resection



Balancing of soft tissues



Resection of the femur

CI Knee
CI PACIENT - 1
DePuy

Frontal View
Planned Actual
3.0 mm 7.5°

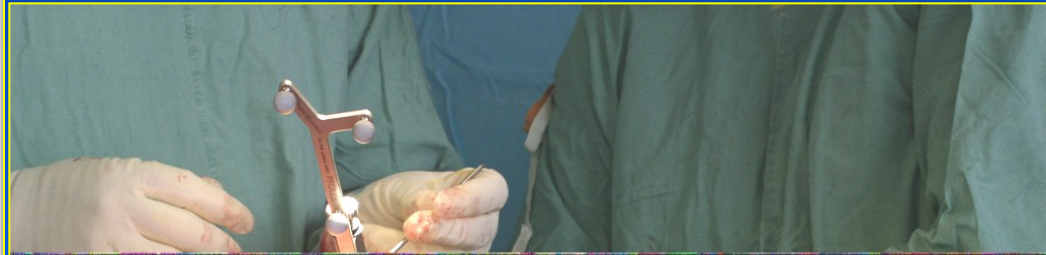Lateral View
Planned Actual
3.0 mm 16.0°

Oblique View
Planned Actual

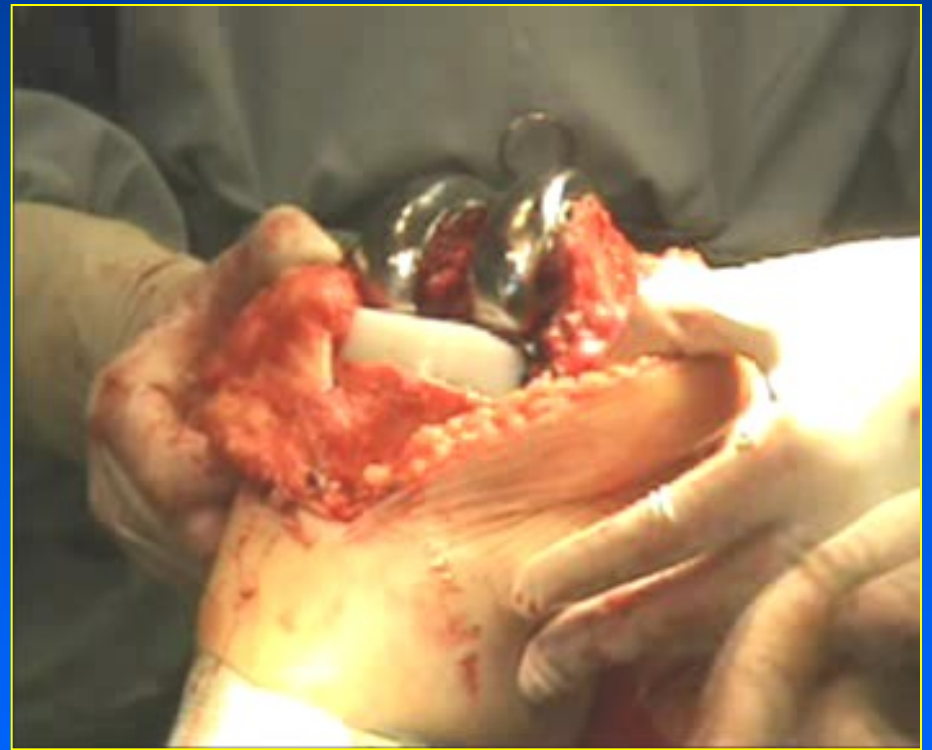
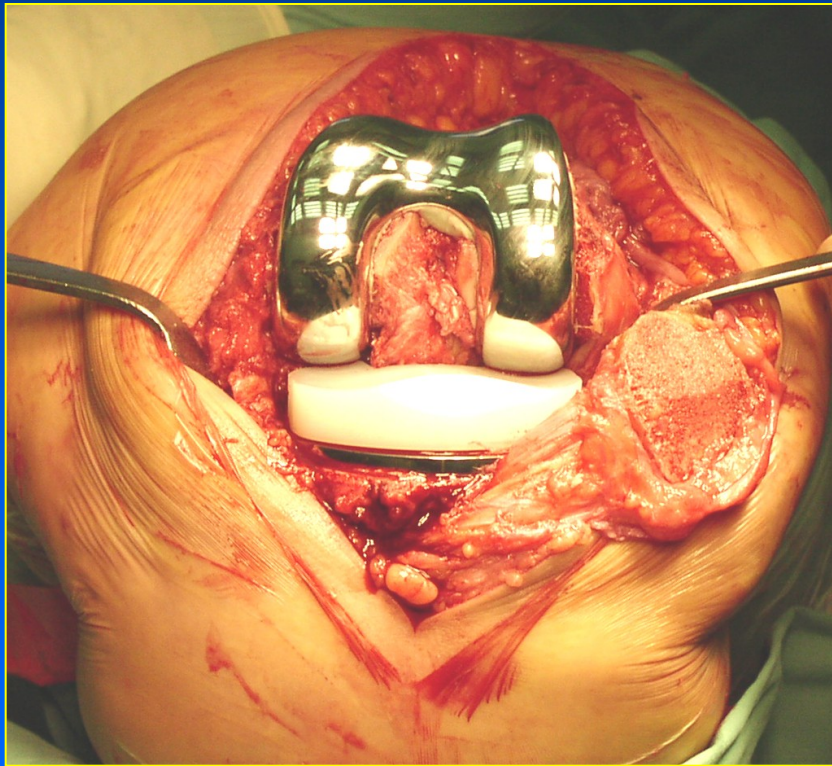
Distal Femoral Resection
Mount the cutting block adapter to the distal cutting block.

Back Next

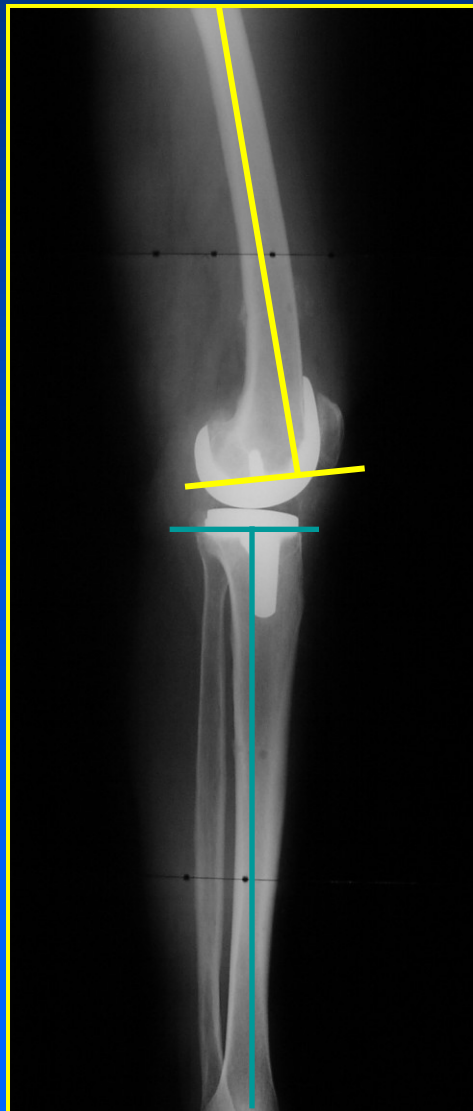
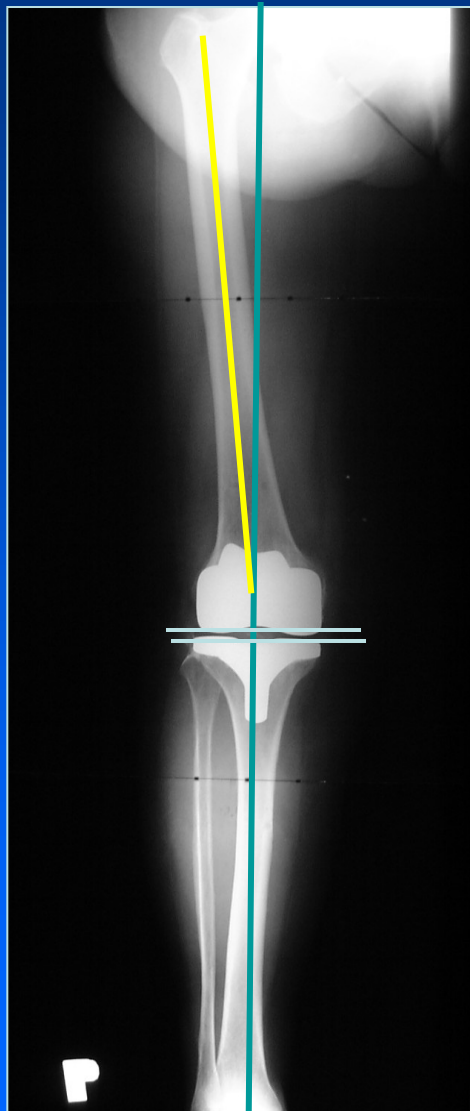
CI PACIENT 9/17/2003 - 10:38 AM



Implantation



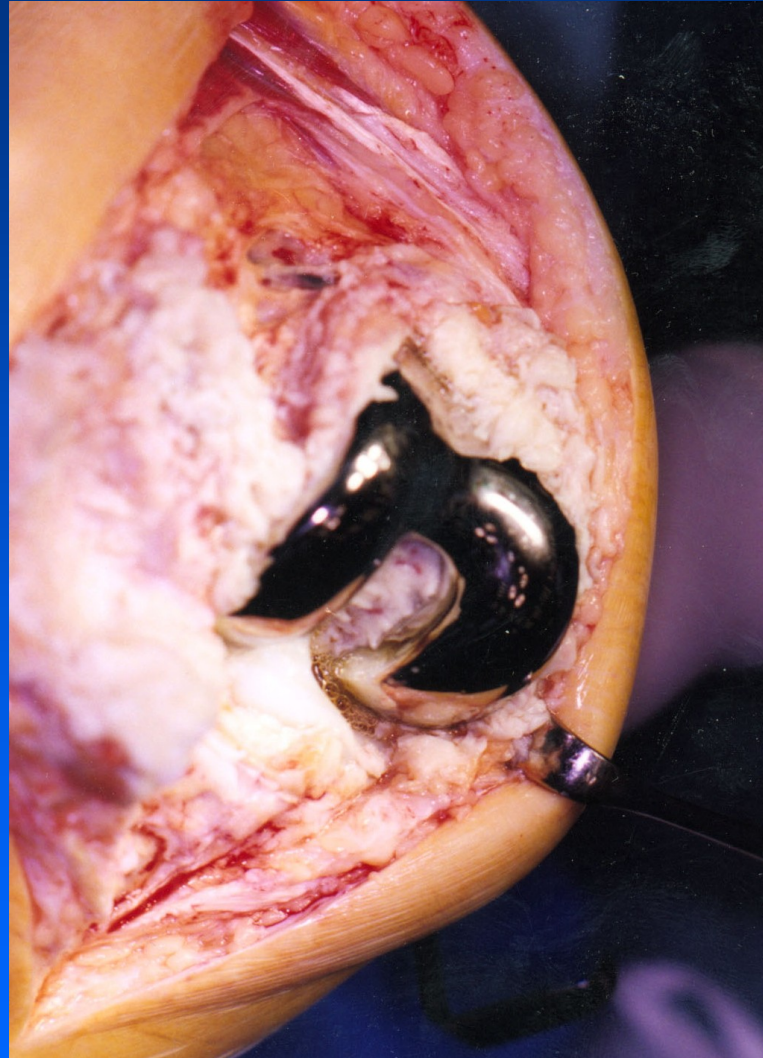
Alignment of the knee

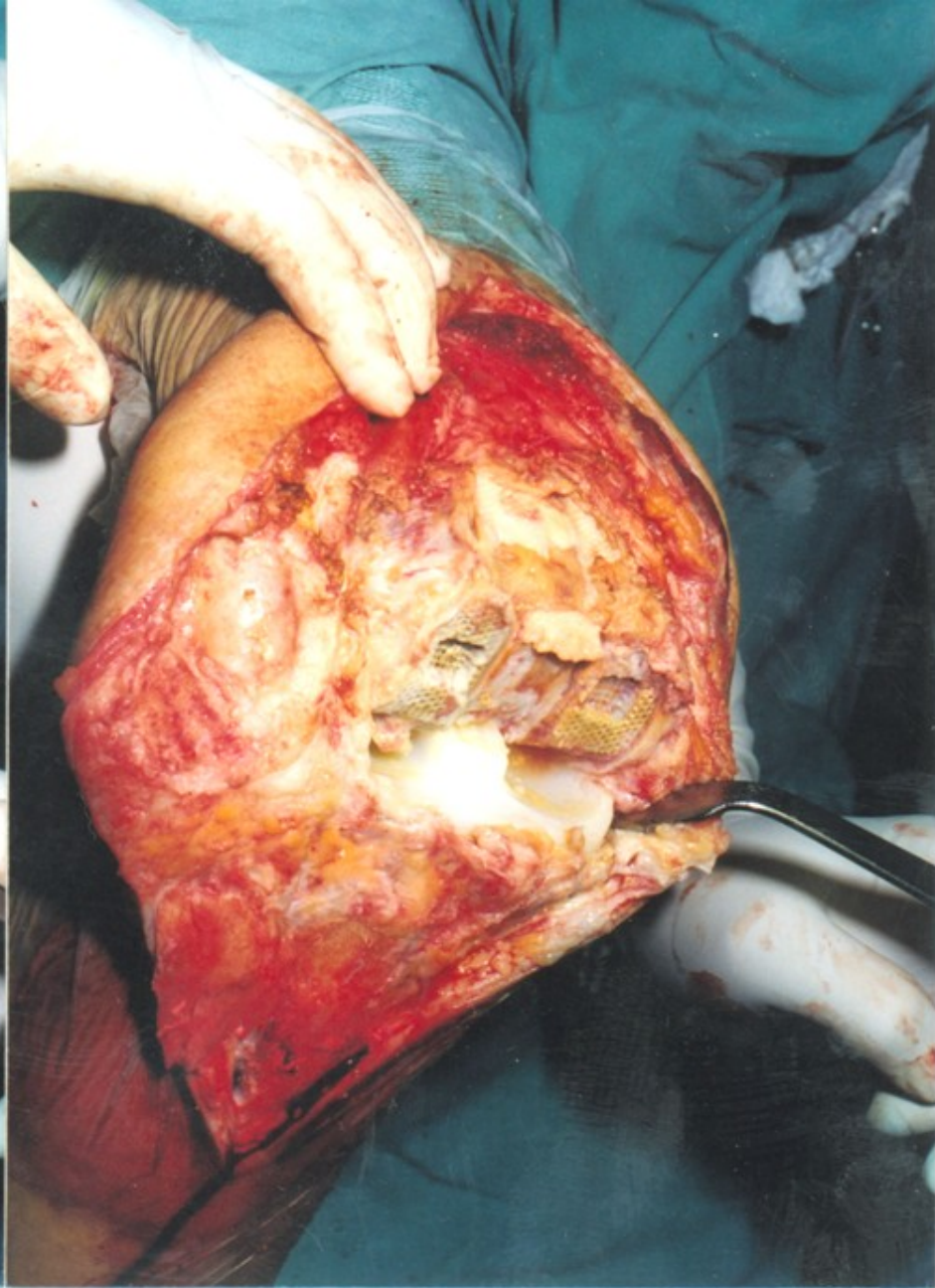
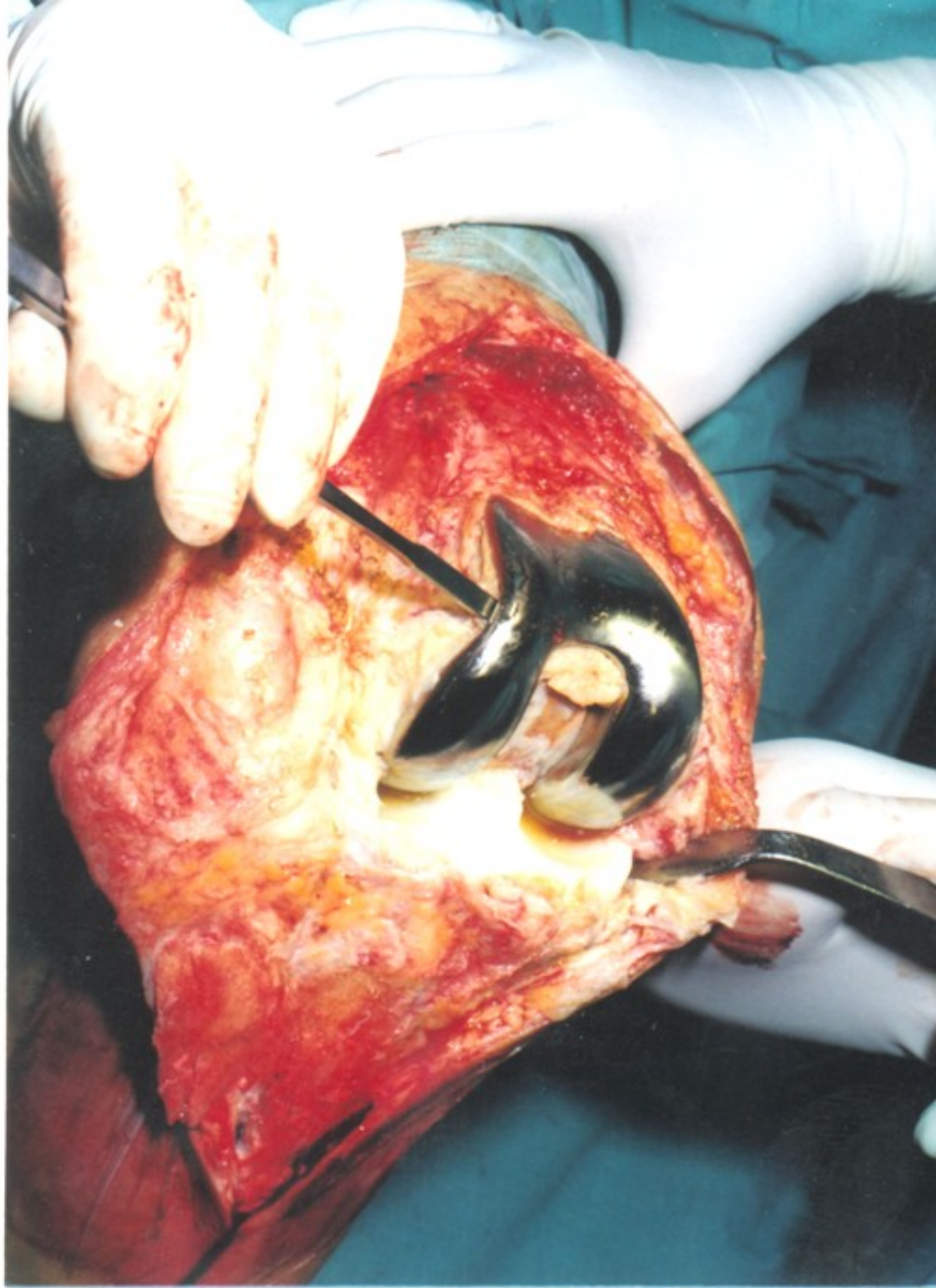


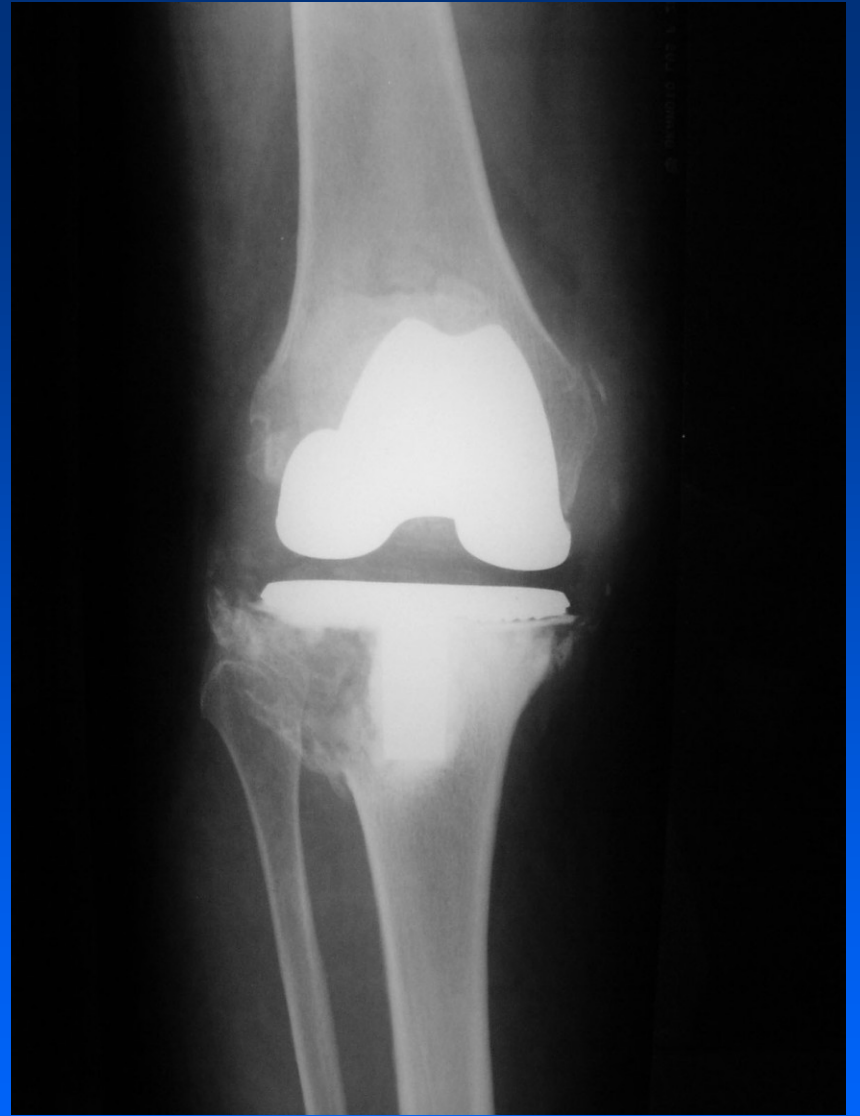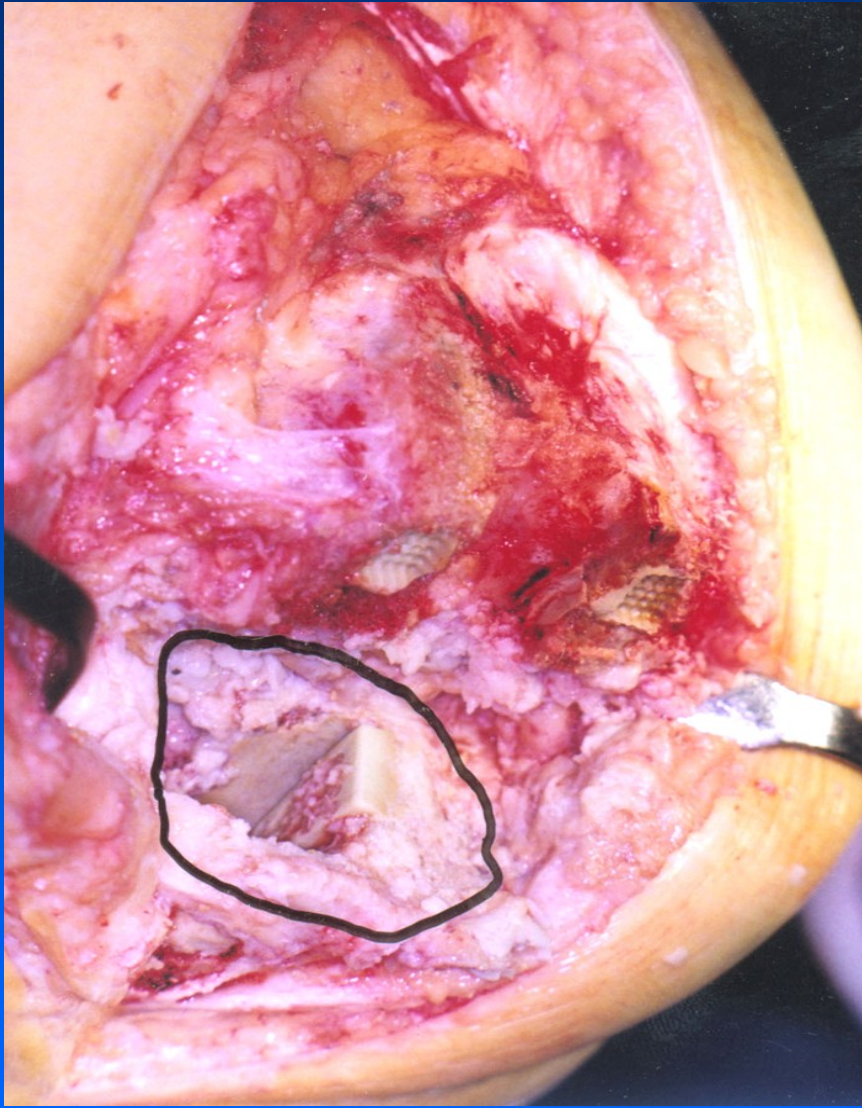
Complications - local

- Perioperative: nerve lesions, vessel lesions,
- bleeding
- Postoperative: hematoma, wound problem, early infection
- Late: PE wear, osteolysis, aseptic loosening
- instability, limited joint movement
- patellar pain
- periprosthetic fracture, dislocation
- infection

Aseptic loosening

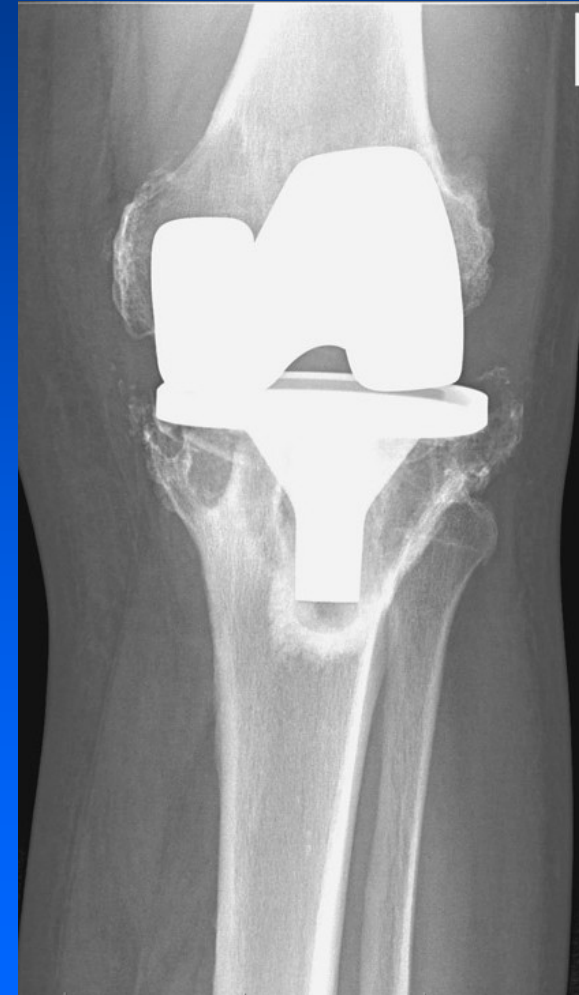





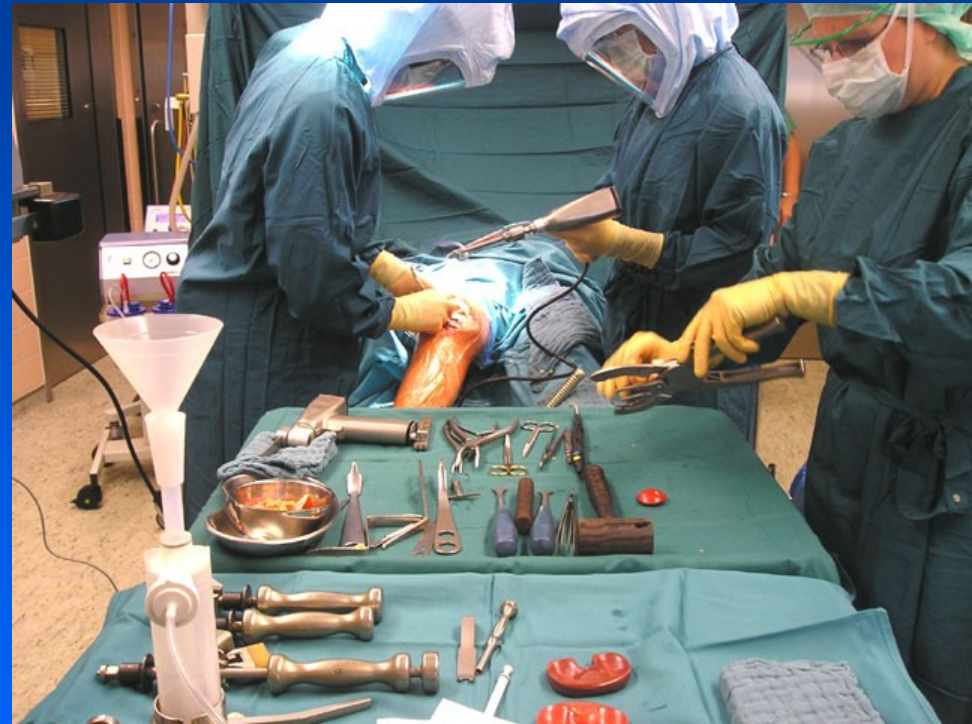Prevention of aseptic loosening

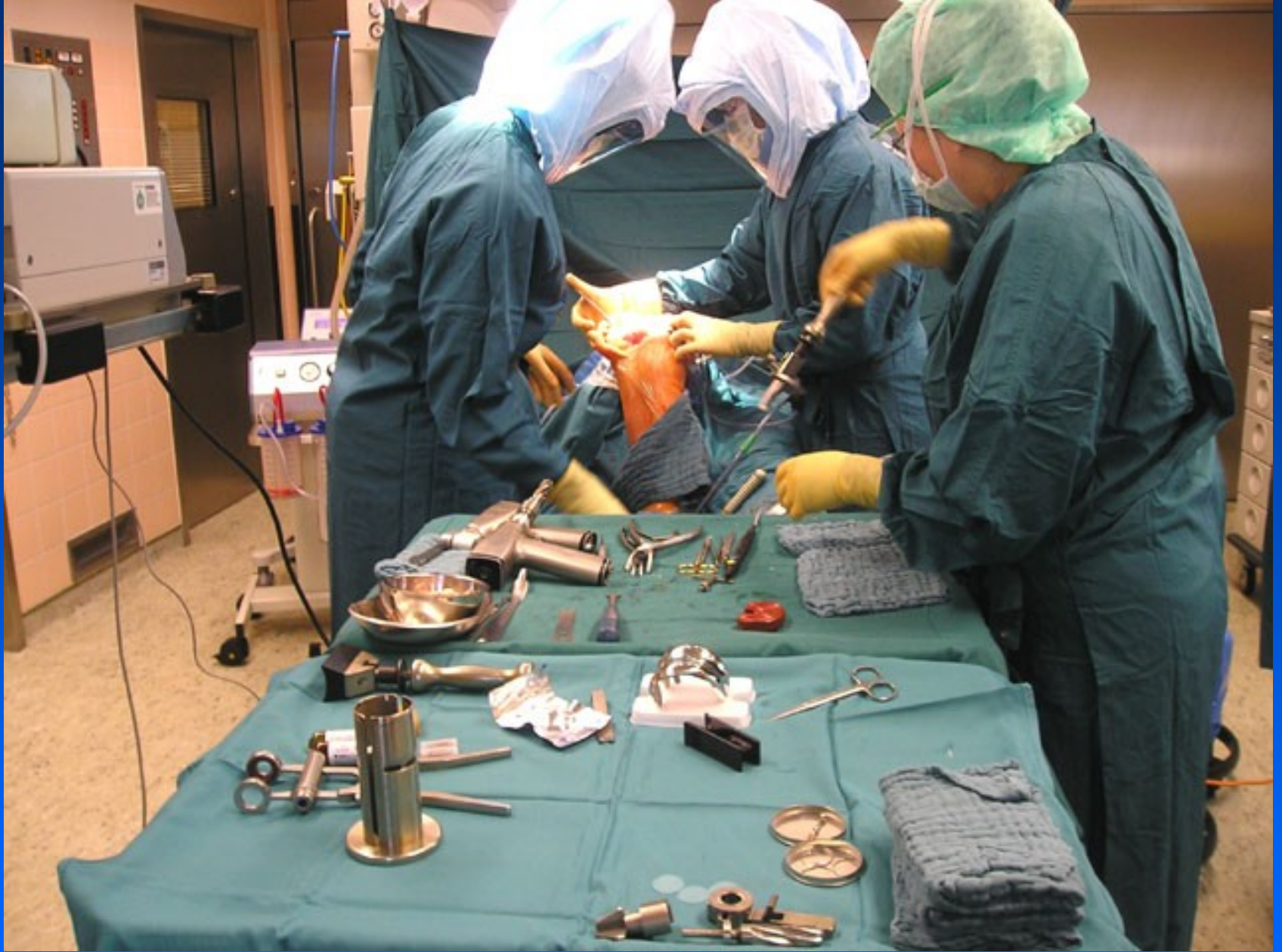- Correct technique
- Quality of PE
- Correct alignment
- Soft tissue balancing
- Pulsatile lavage
- Regular follow - up



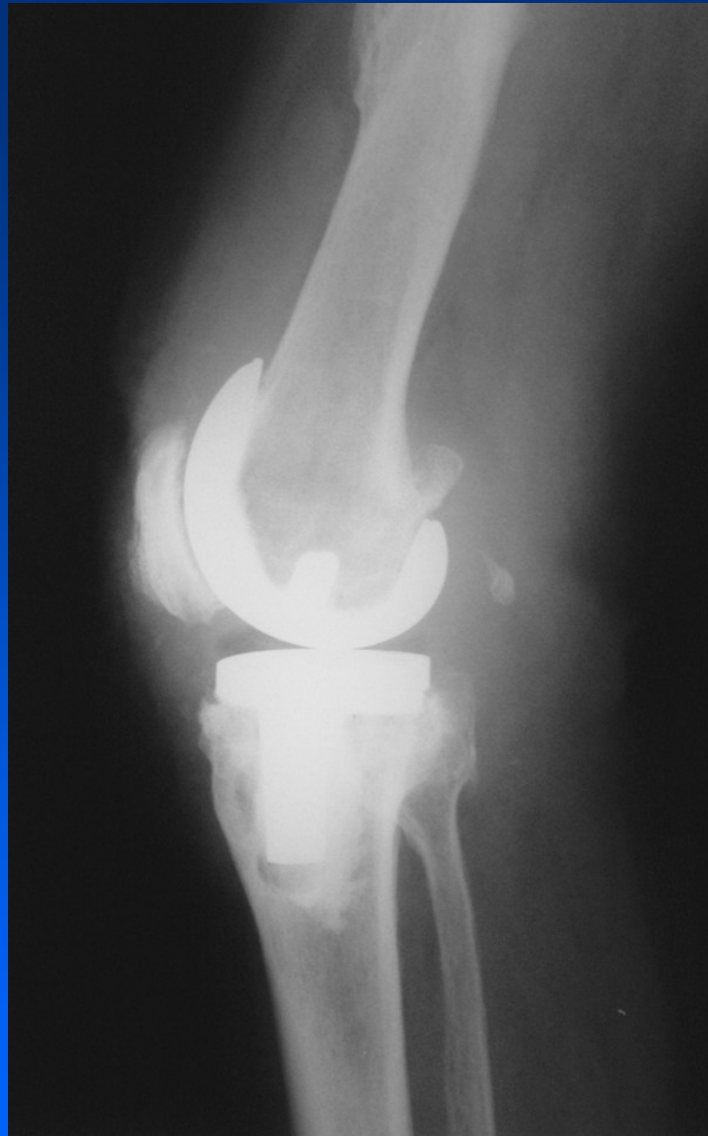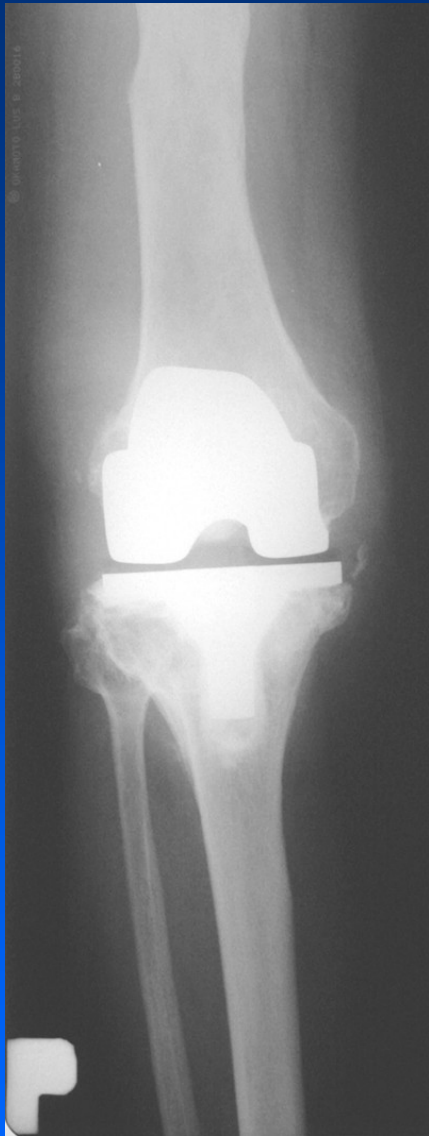
Prevention of the infection

Preop. examination
Asepsis in operating theatre
Perioperative antibiotics
Correct technique
Cement with antibiotics

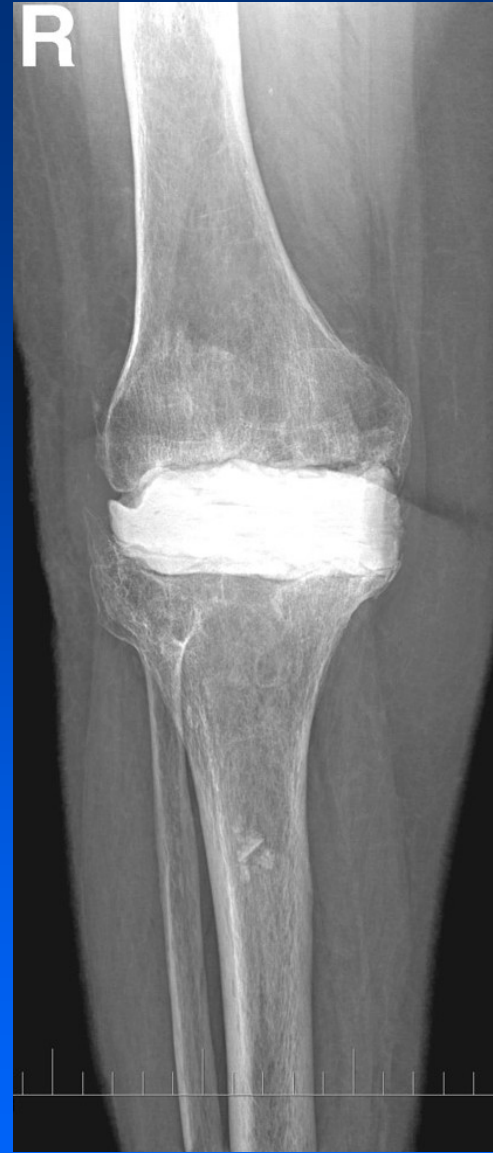
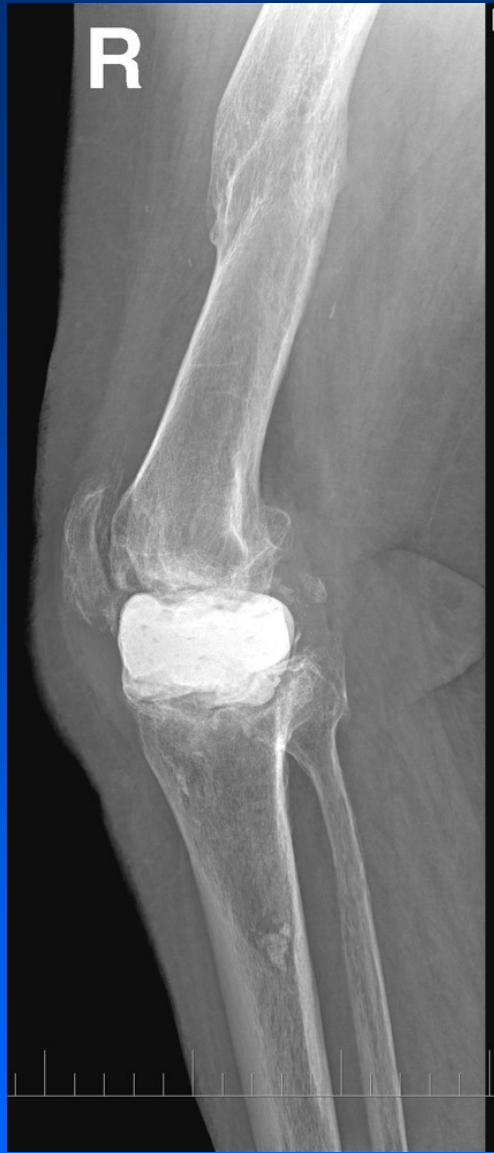


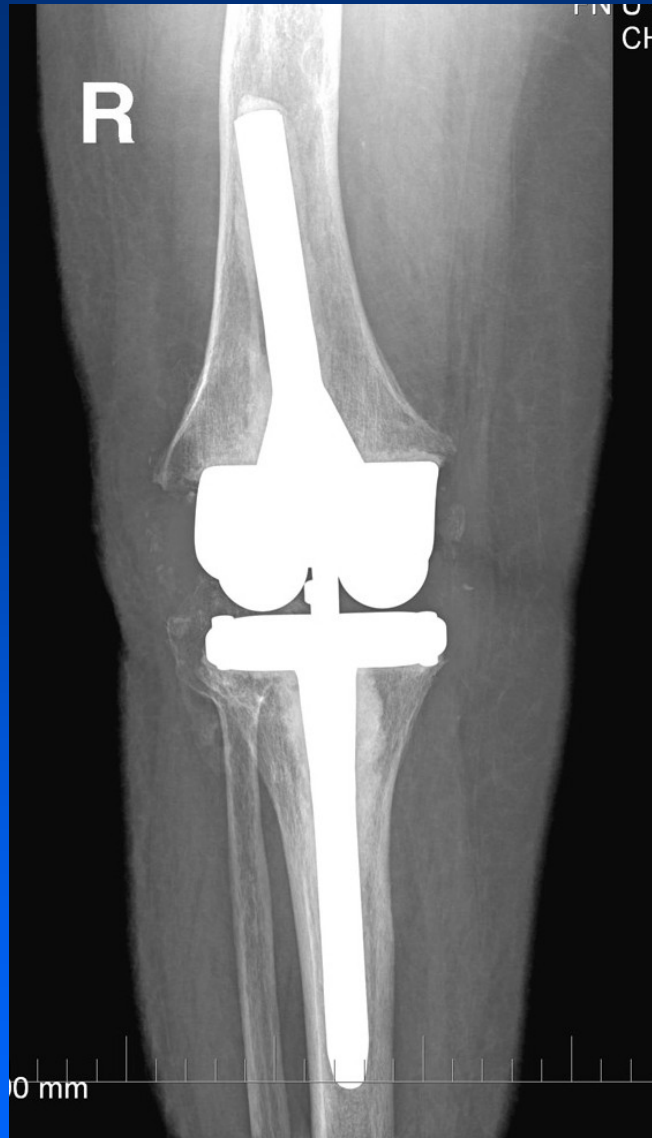
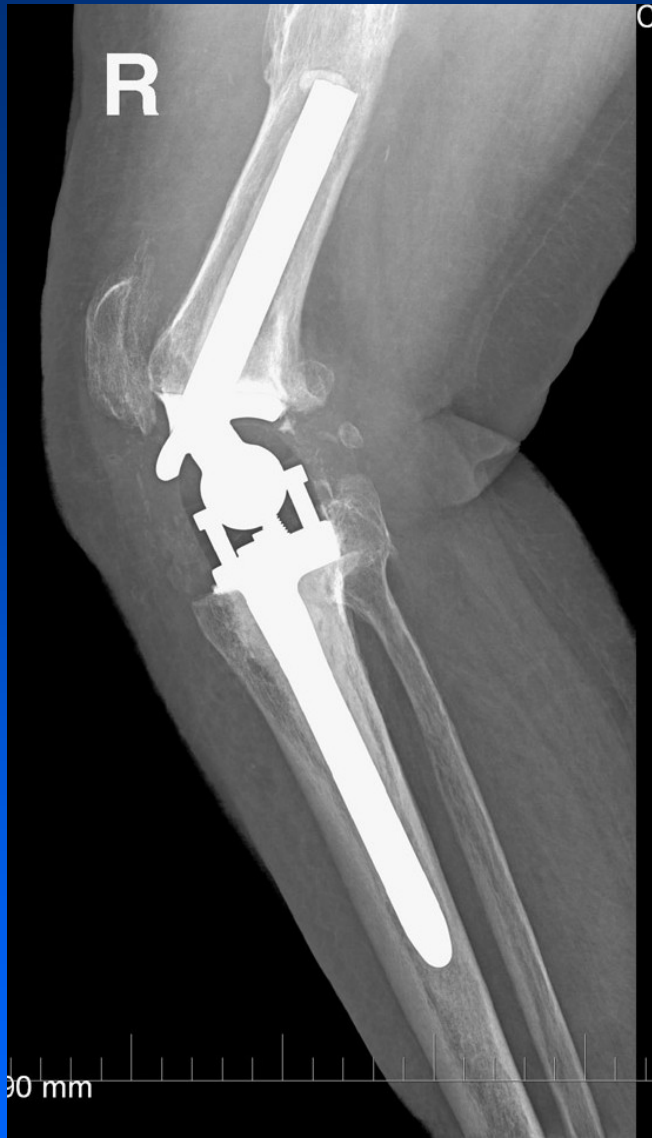Klinikum Neustadt



Septic loosening

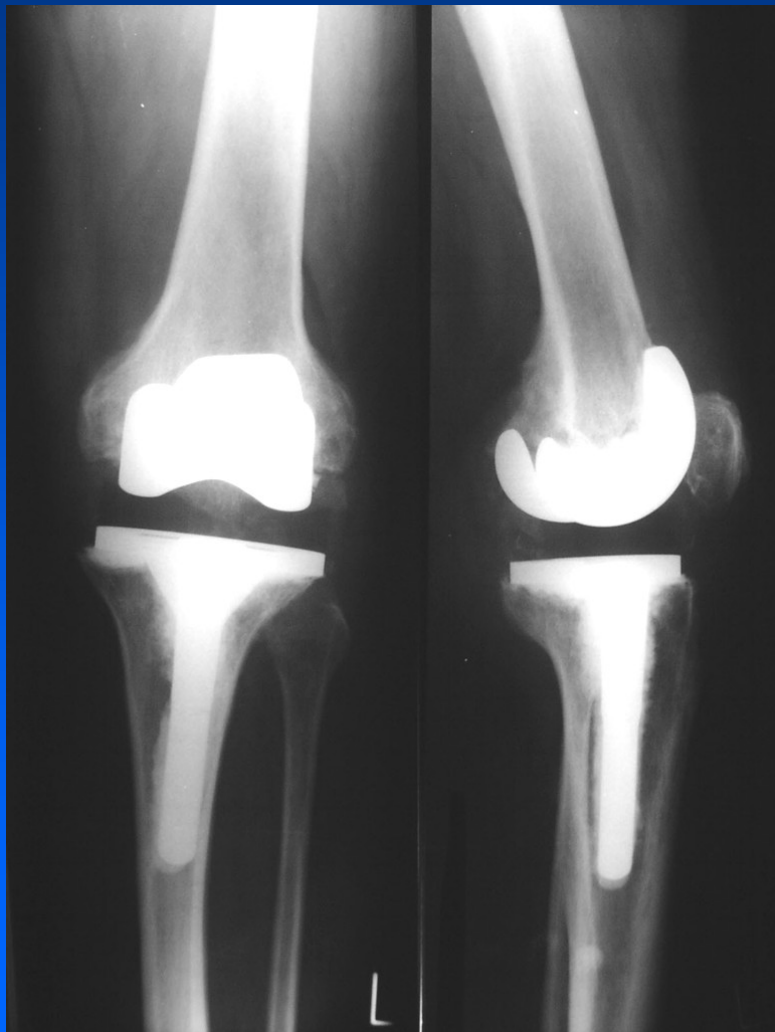


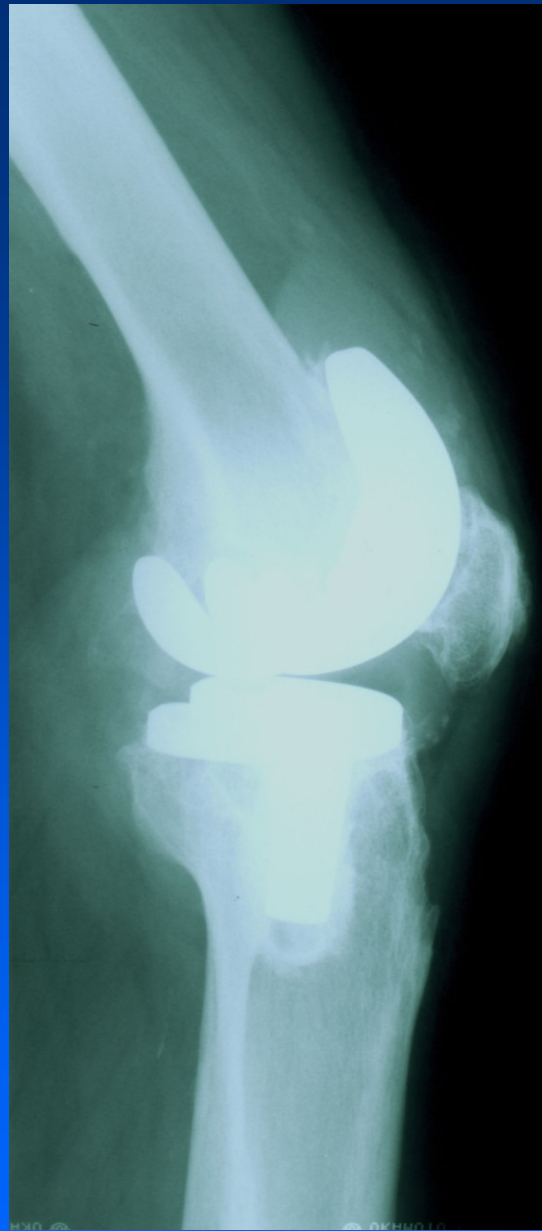
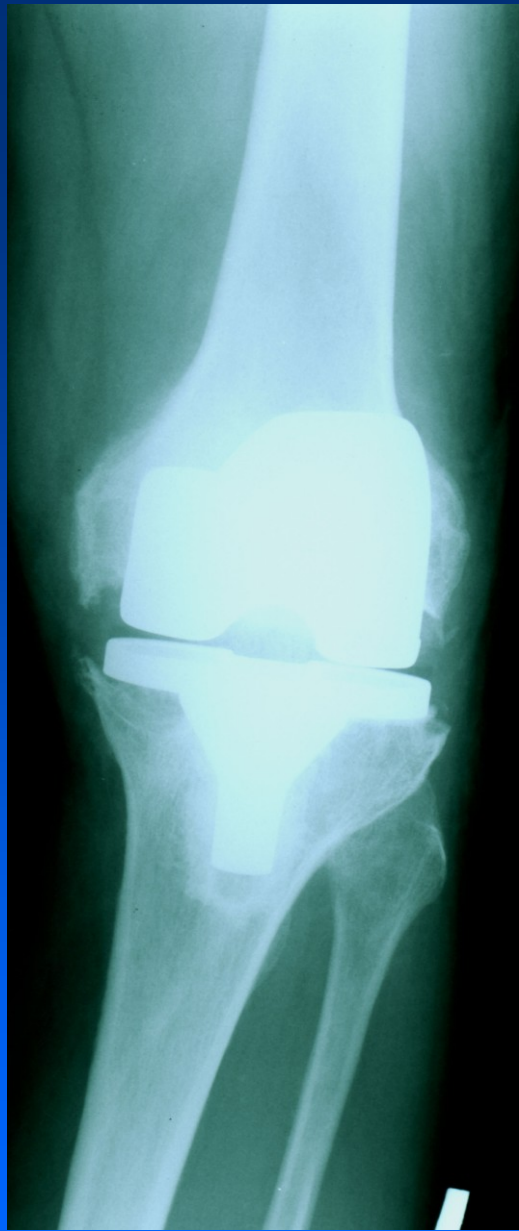Cement spacer



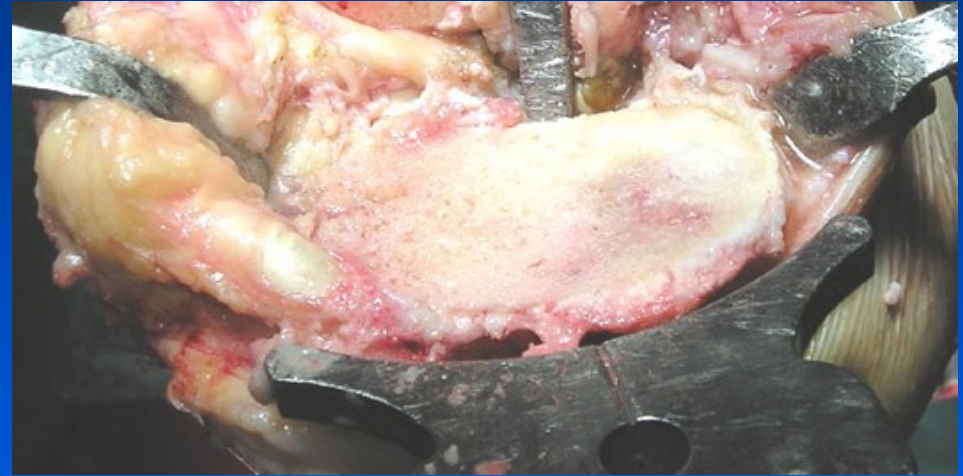
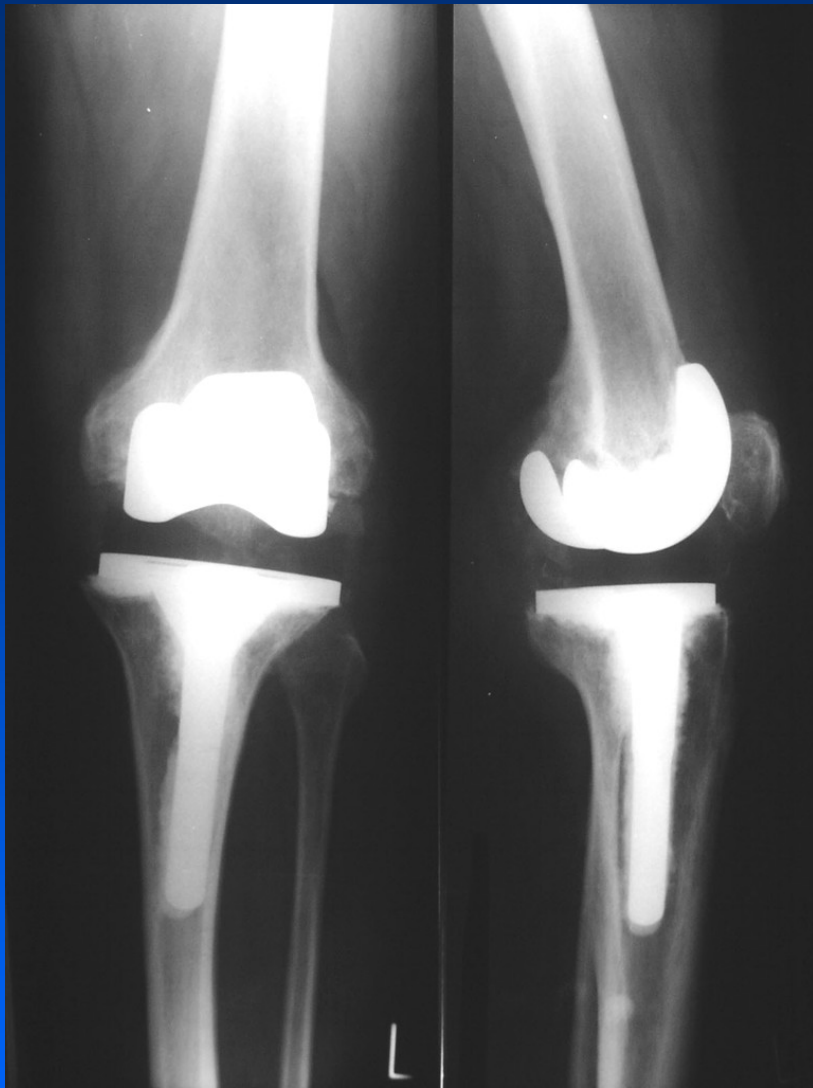
Revision TKA

Revision TKA



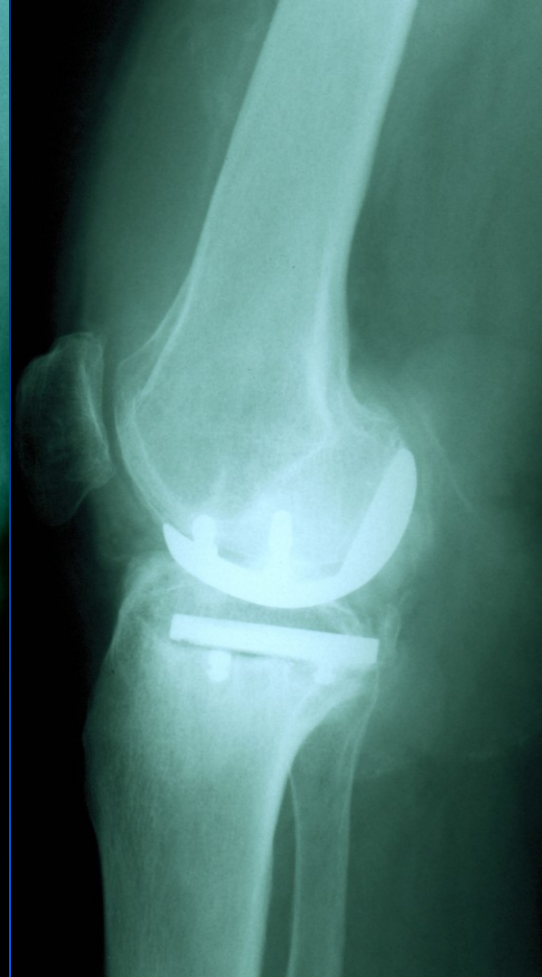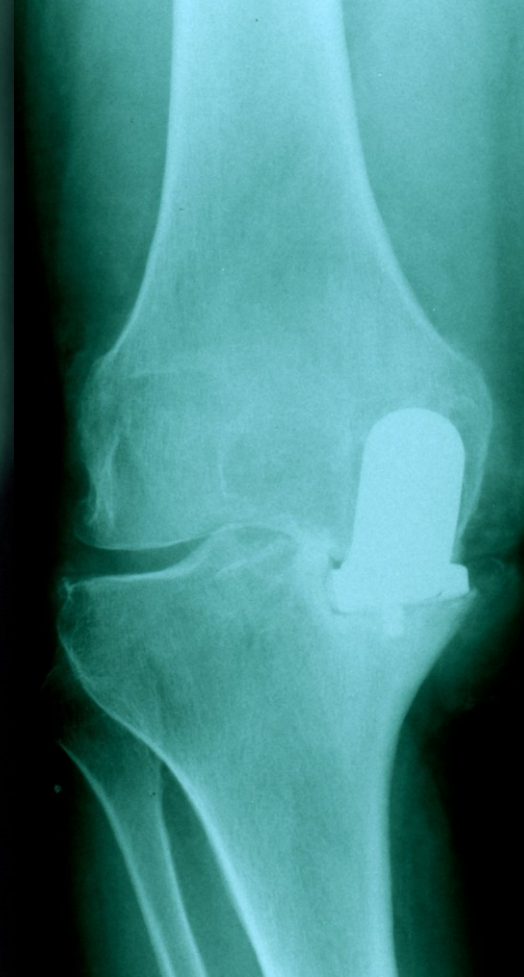

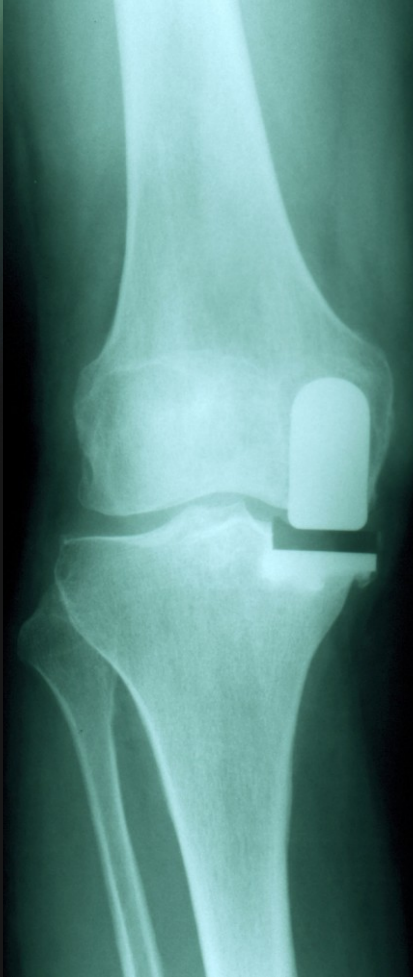
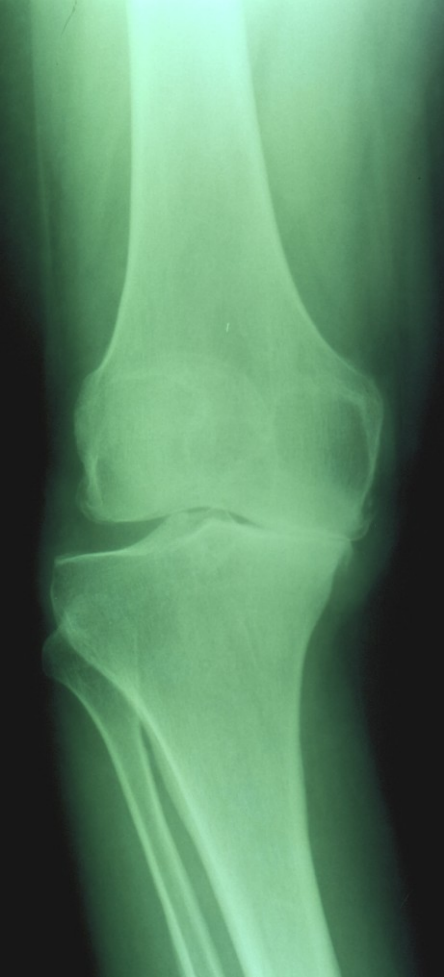M., 62 y., primary TKR 1995



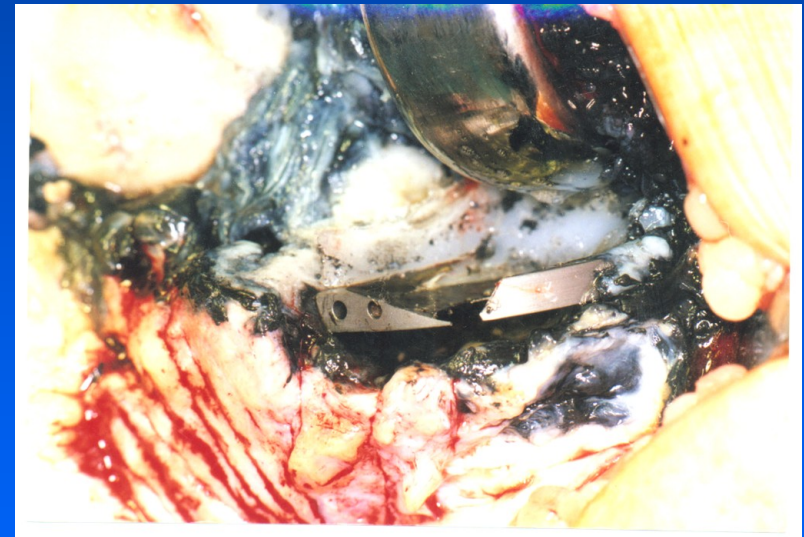
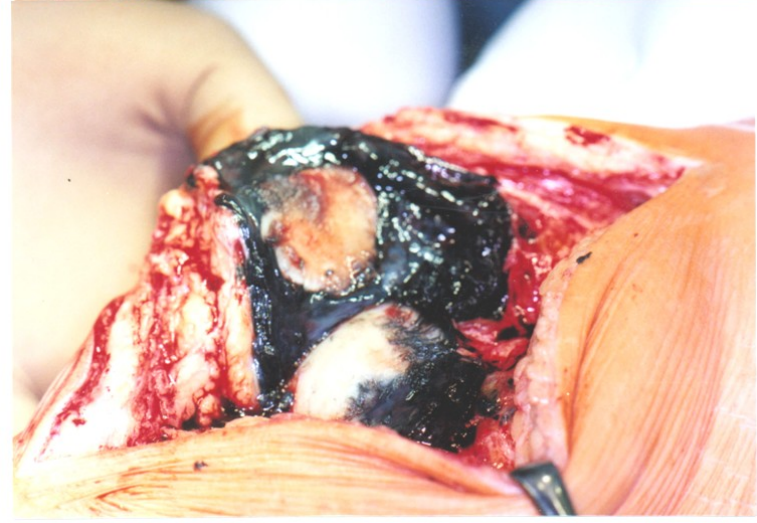
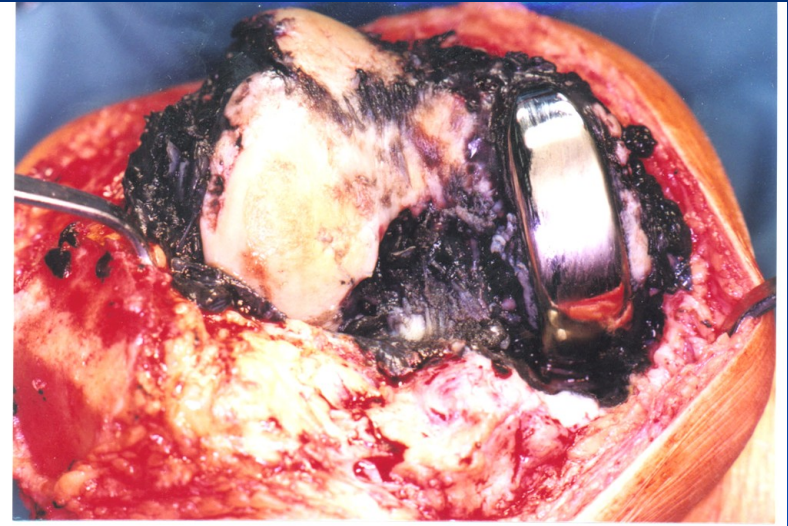
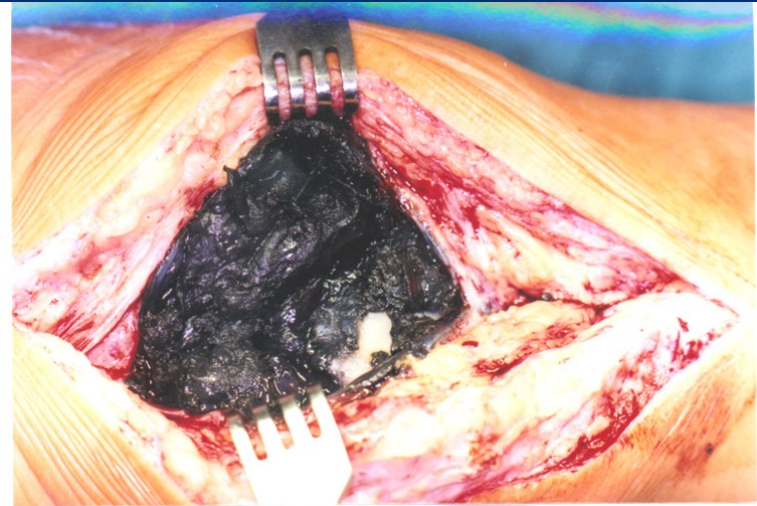
Small resection
Good metaphyseal bone

Revision with PFC Σ Modular knee system,
30 (60) mm cemented tibial stem



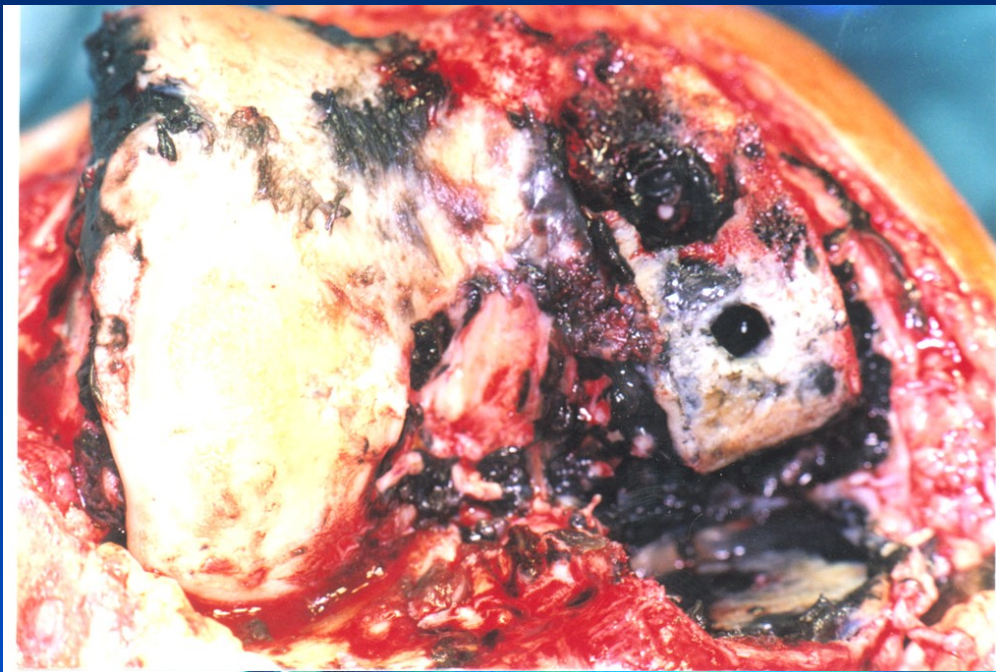
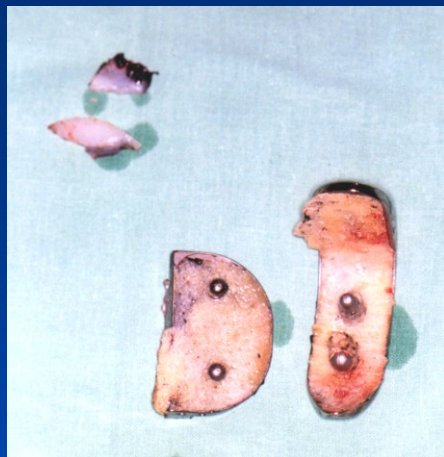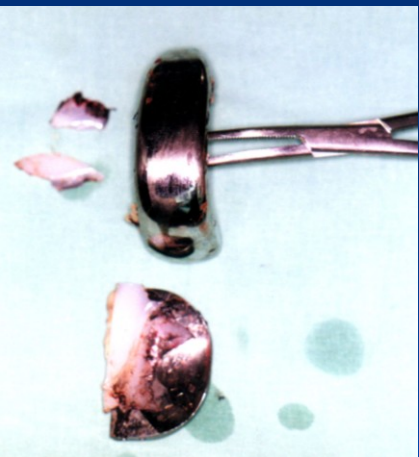
F., 66 y., 1995

2000, aseptic loosening of UNI TKR



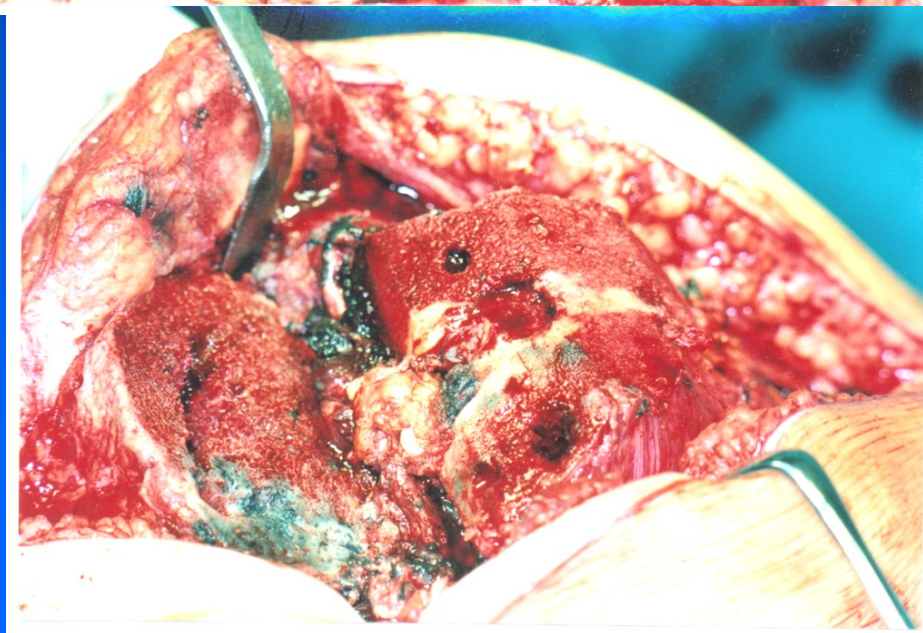
Metallosis

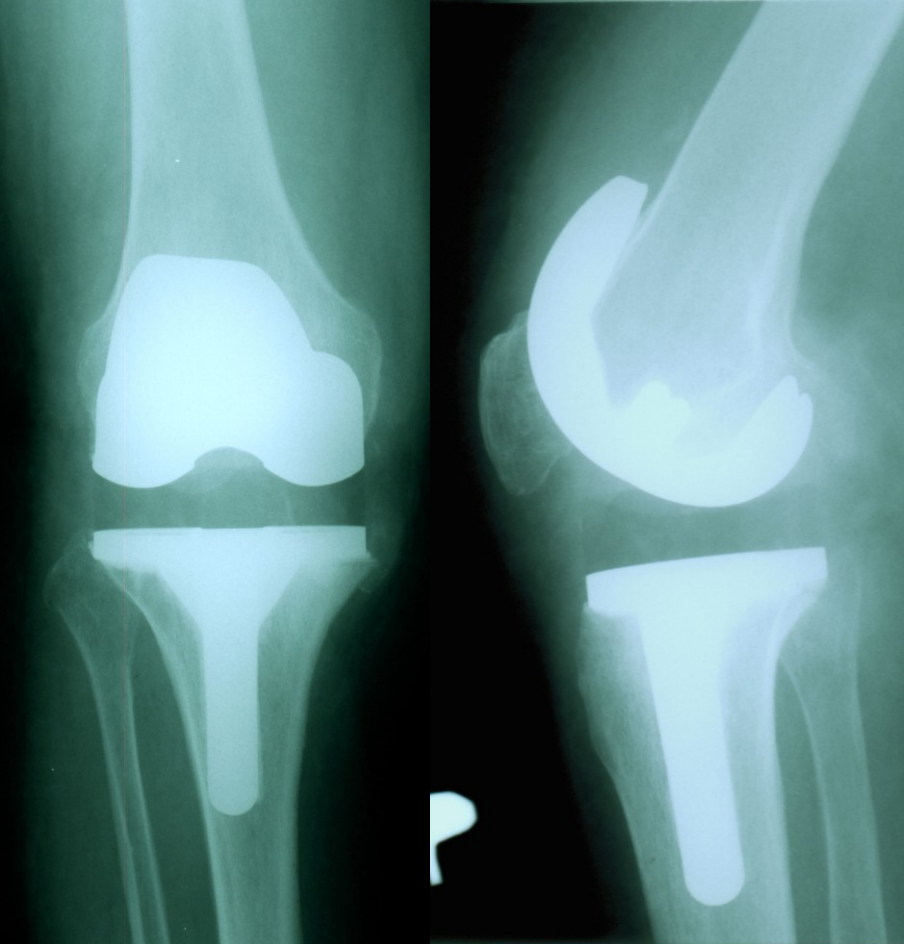
Contact of metal components



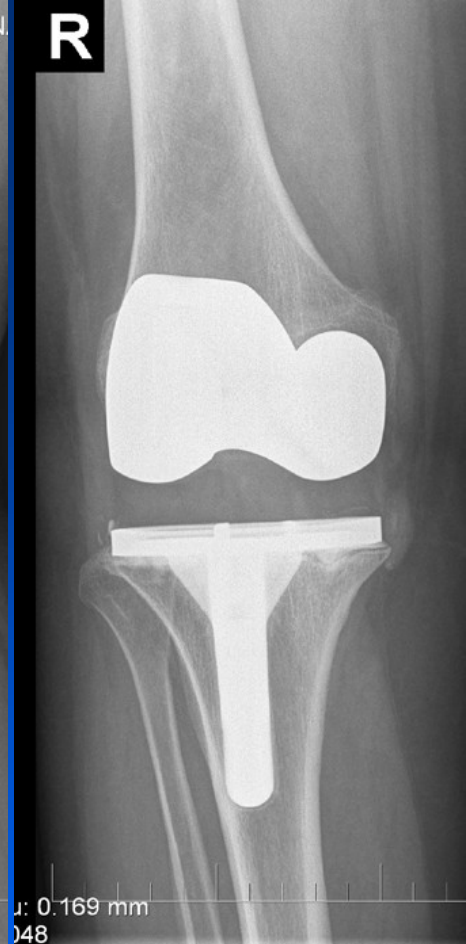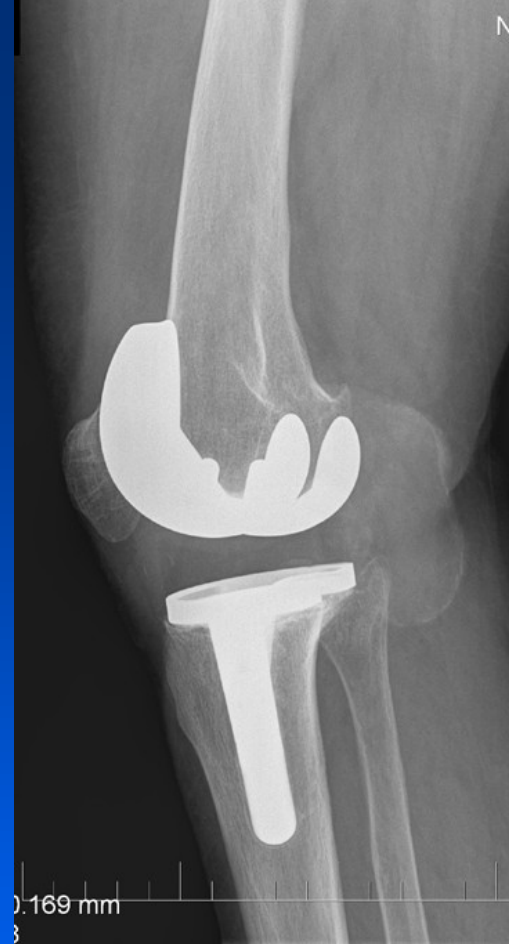Destruction of
PE insert

Synovectomy
Good quality of
trabecular bone of the tibia



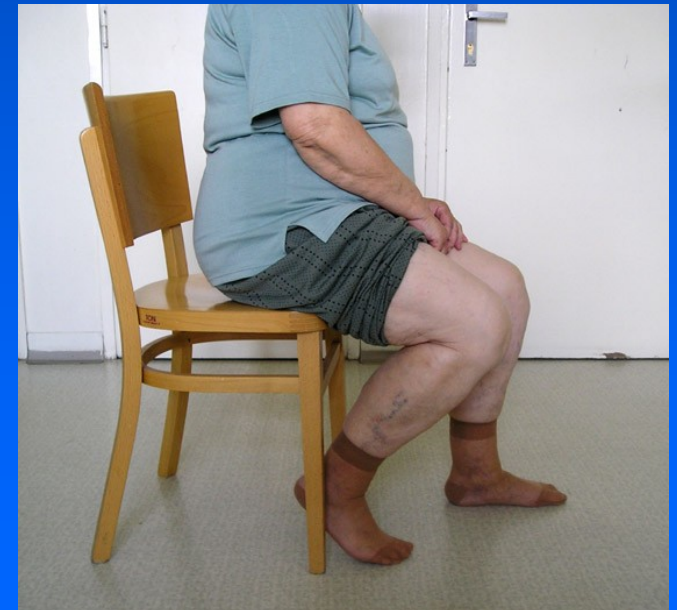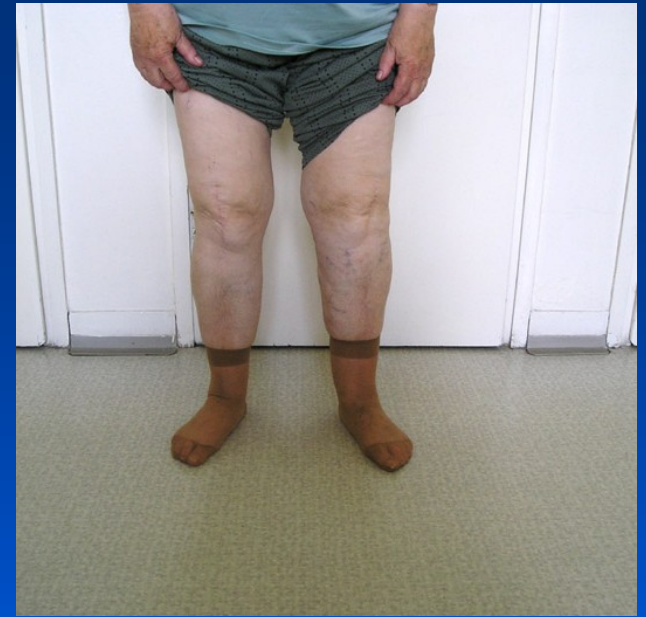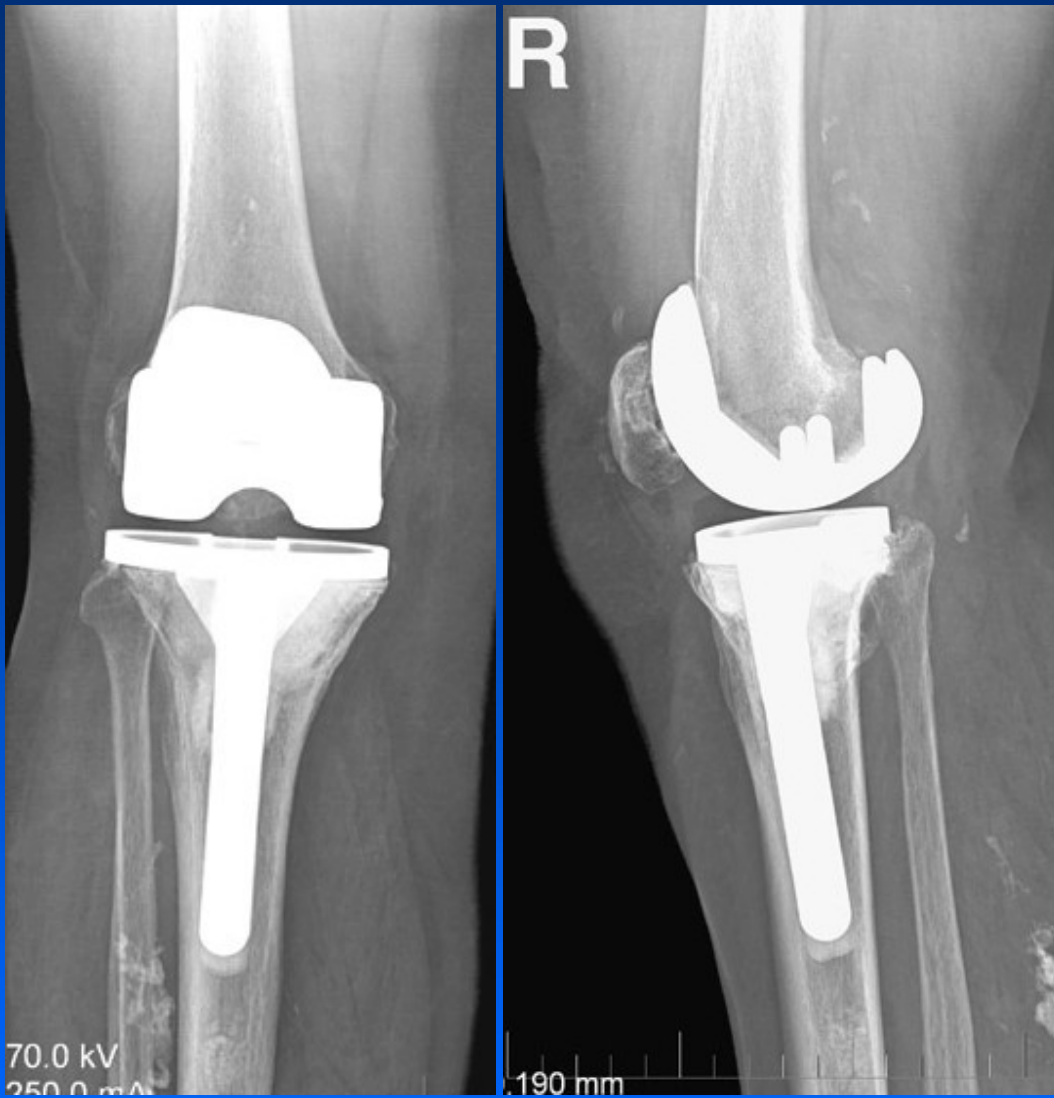


2000



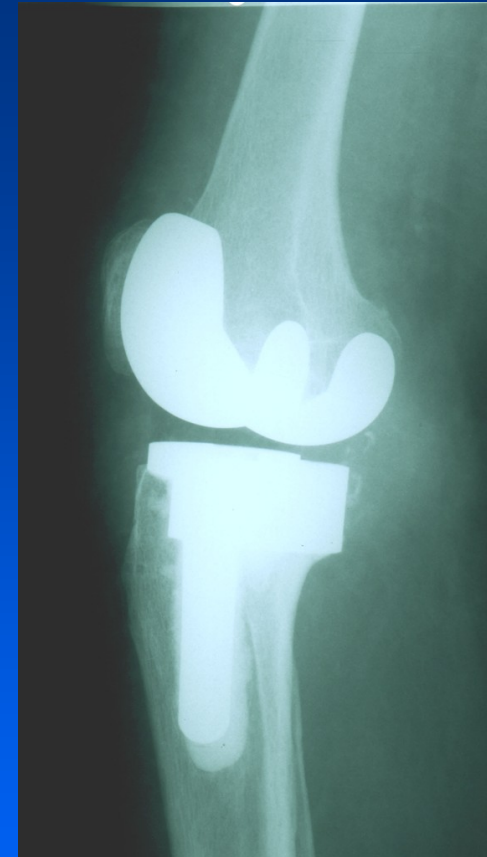
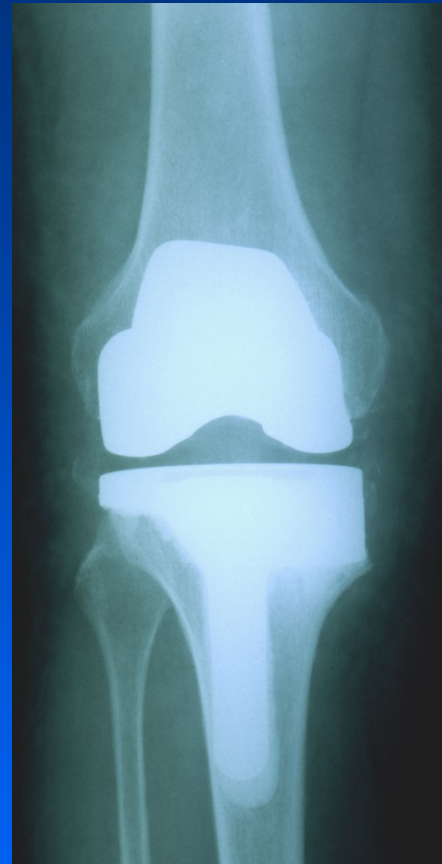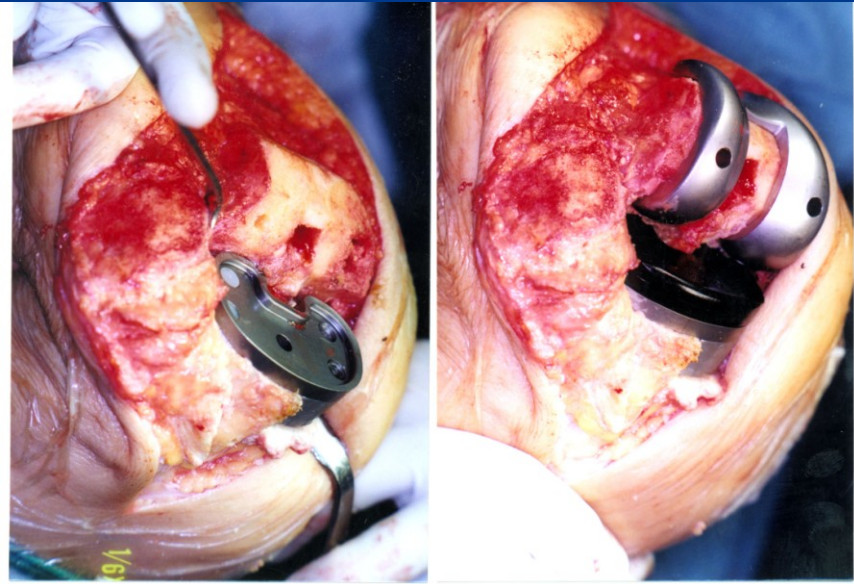
2006

Revision surgery, PFC Σ Modular Knee System
Short cemented tibial stem
Good result

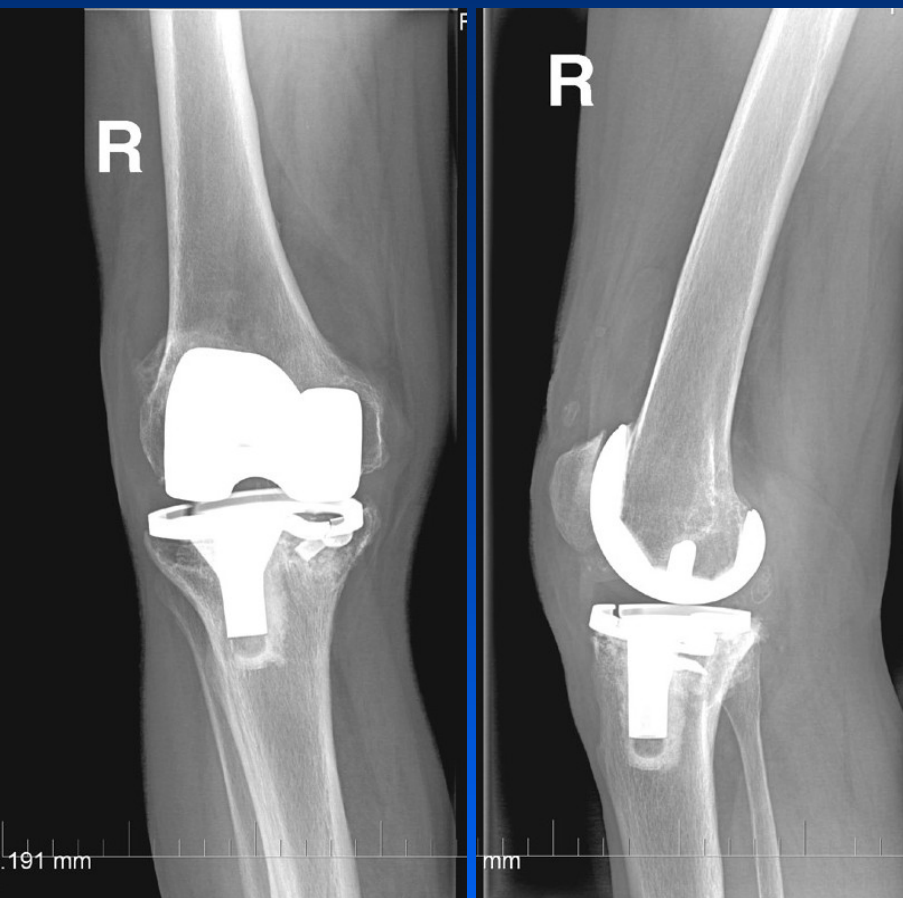


2006

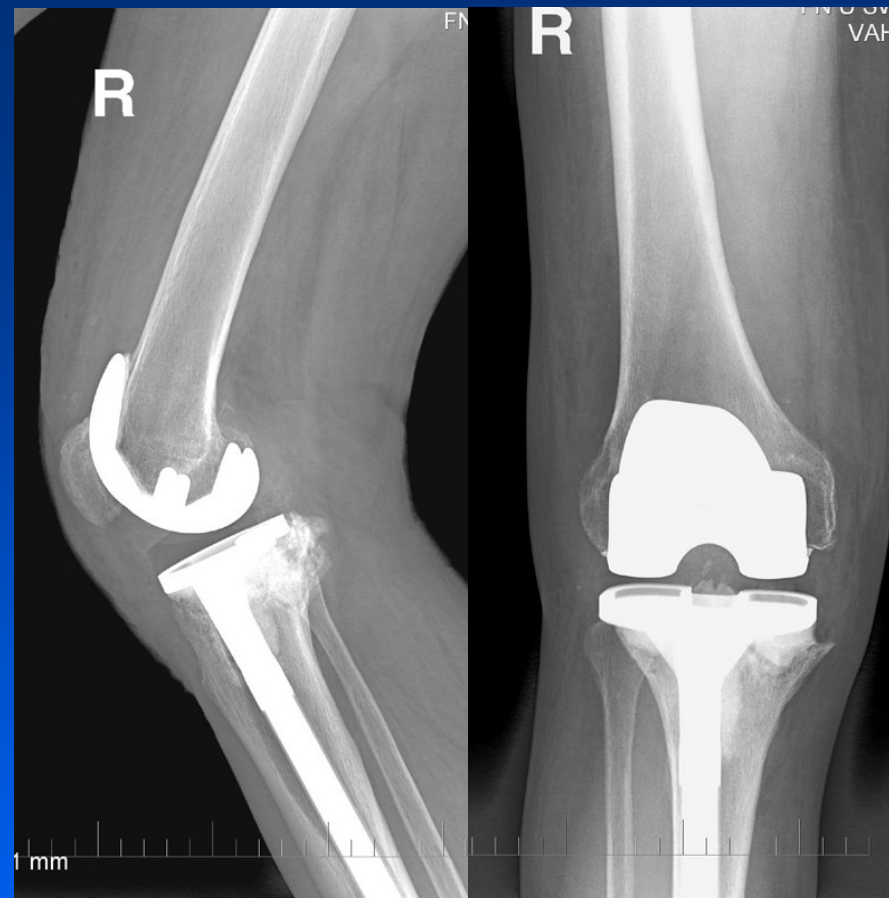
No progression of radiolucency
on medial side of the tibia, good result



Augmentation of tibial bone loss, PFC Σ Modular Knee System



2004

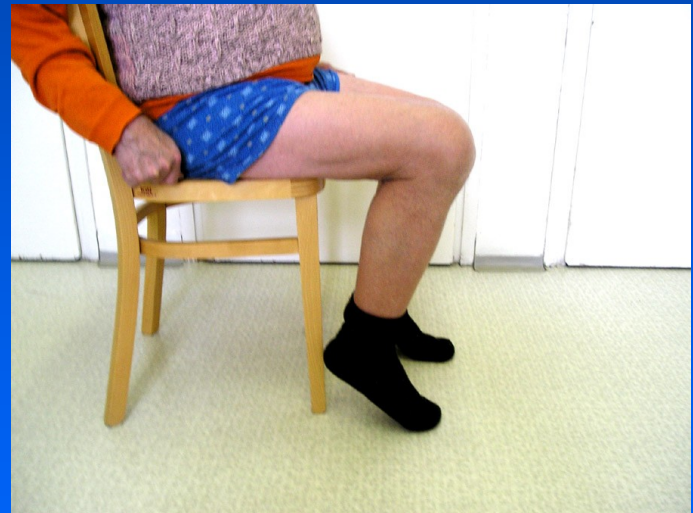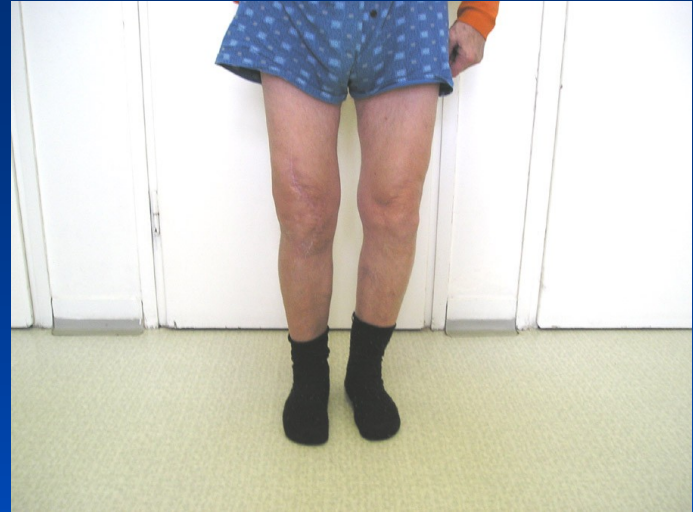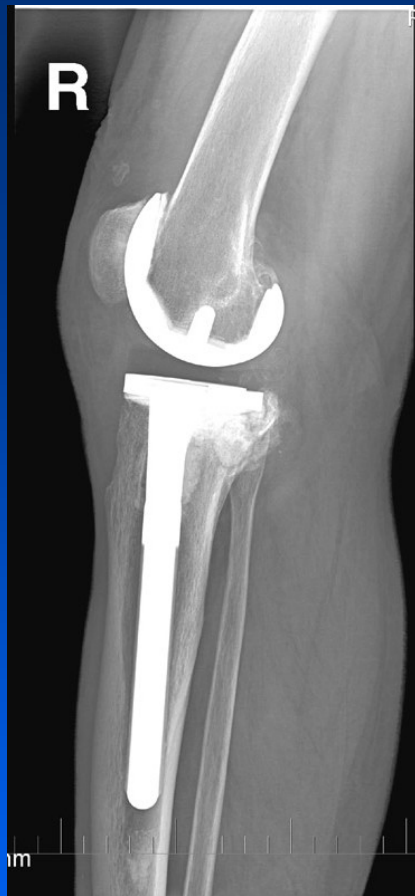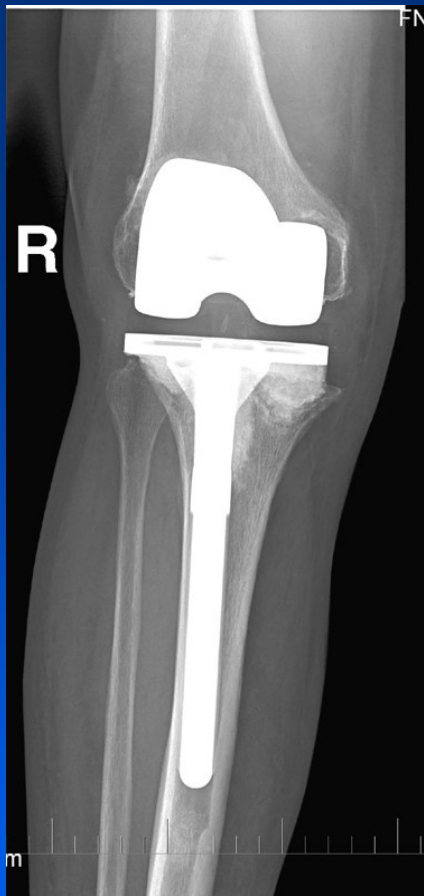


2005

M, 1942, primary TKR 1993

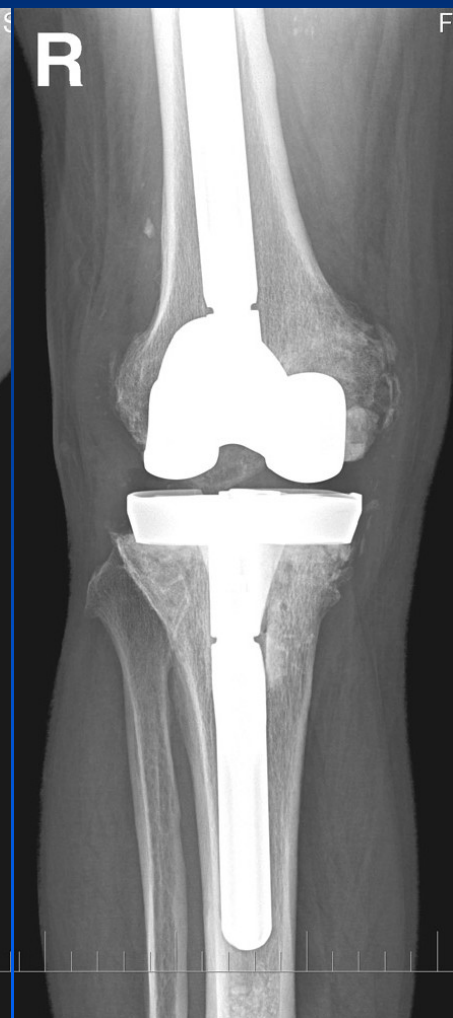
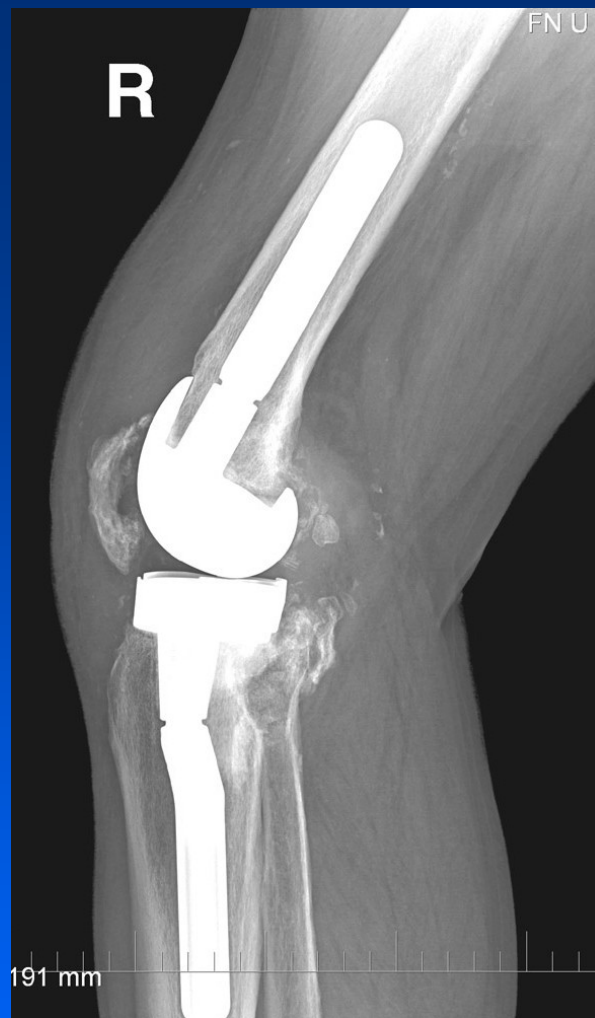
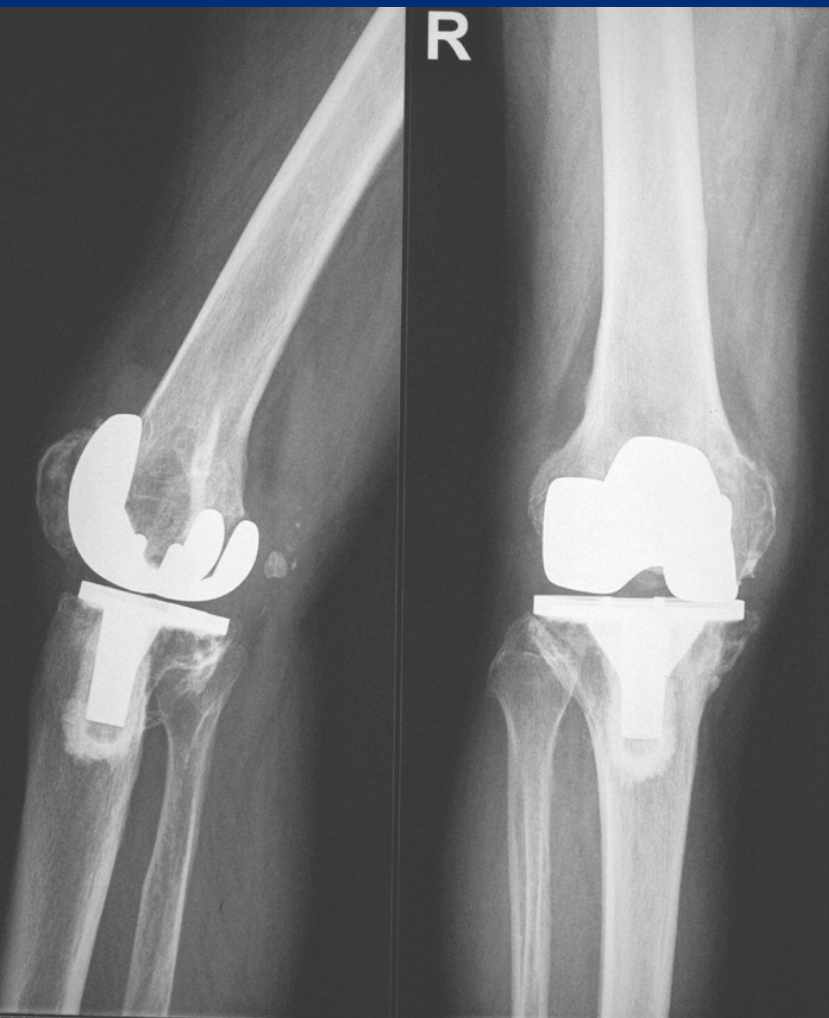
Fracture of the tibial tray, PFC Σ Modular Knee system, 1/2005

Cortical contact of the uncemented stem,

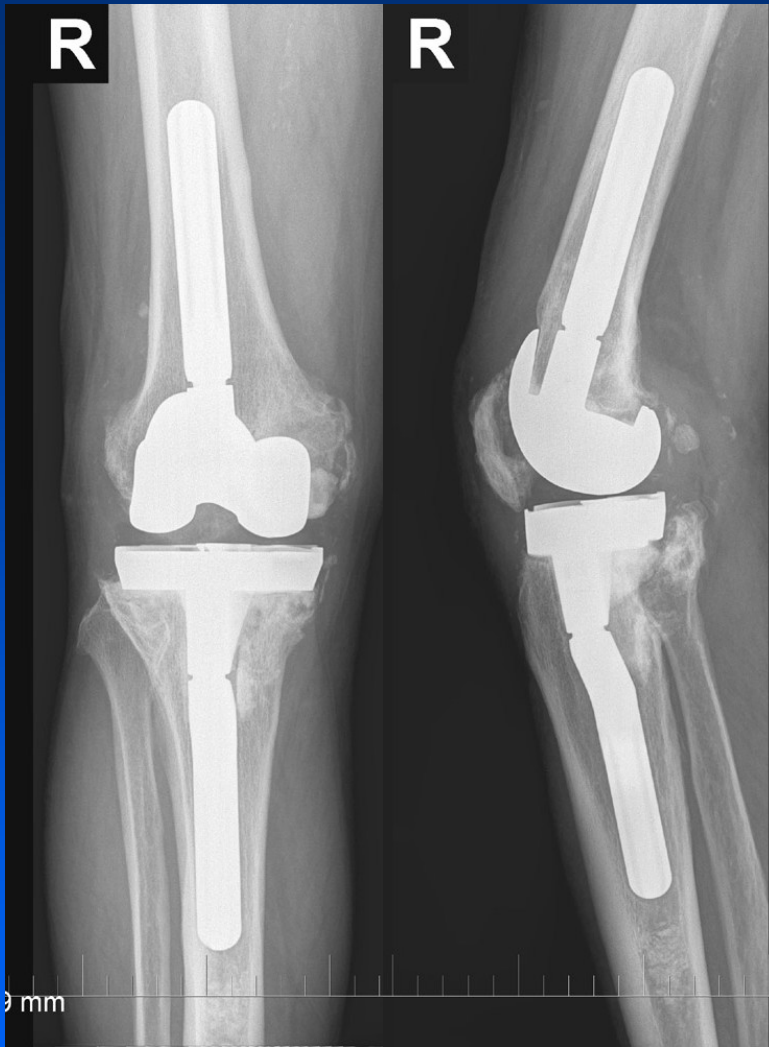

2006

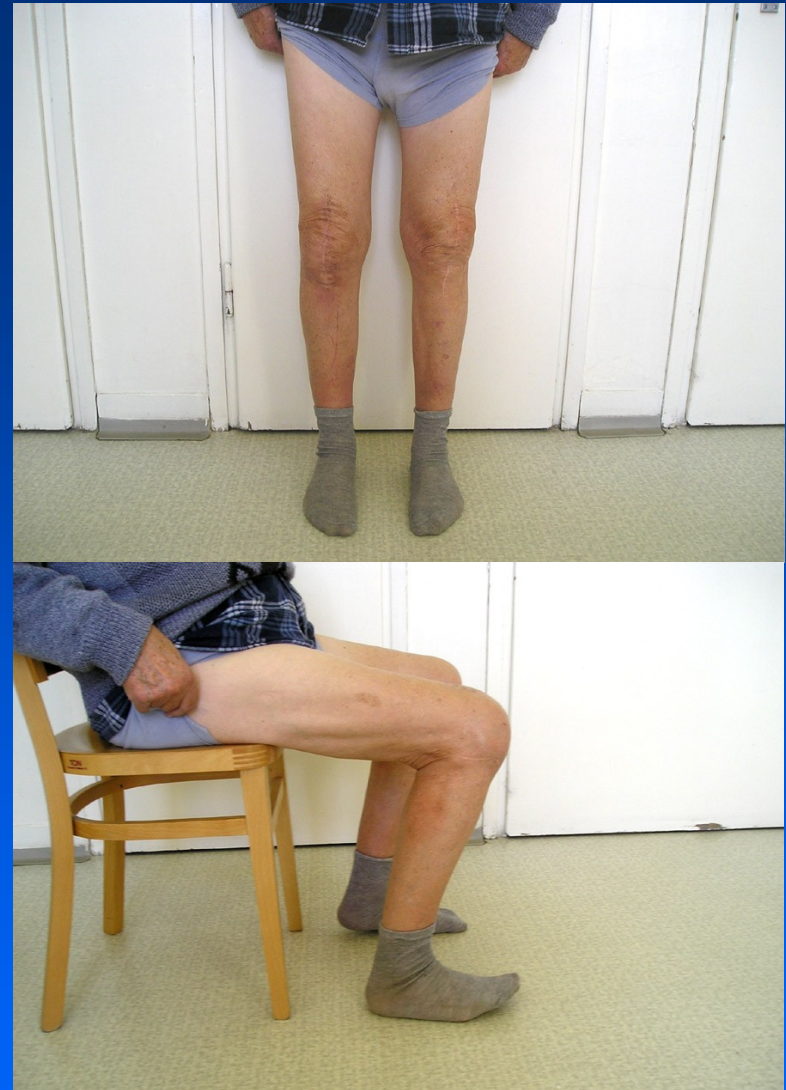M., 1942, PFC Σ Modular Knee system,
Cortical contact of the uncemented stem,
Less amount of bone cement in metaphyseal region, good result.



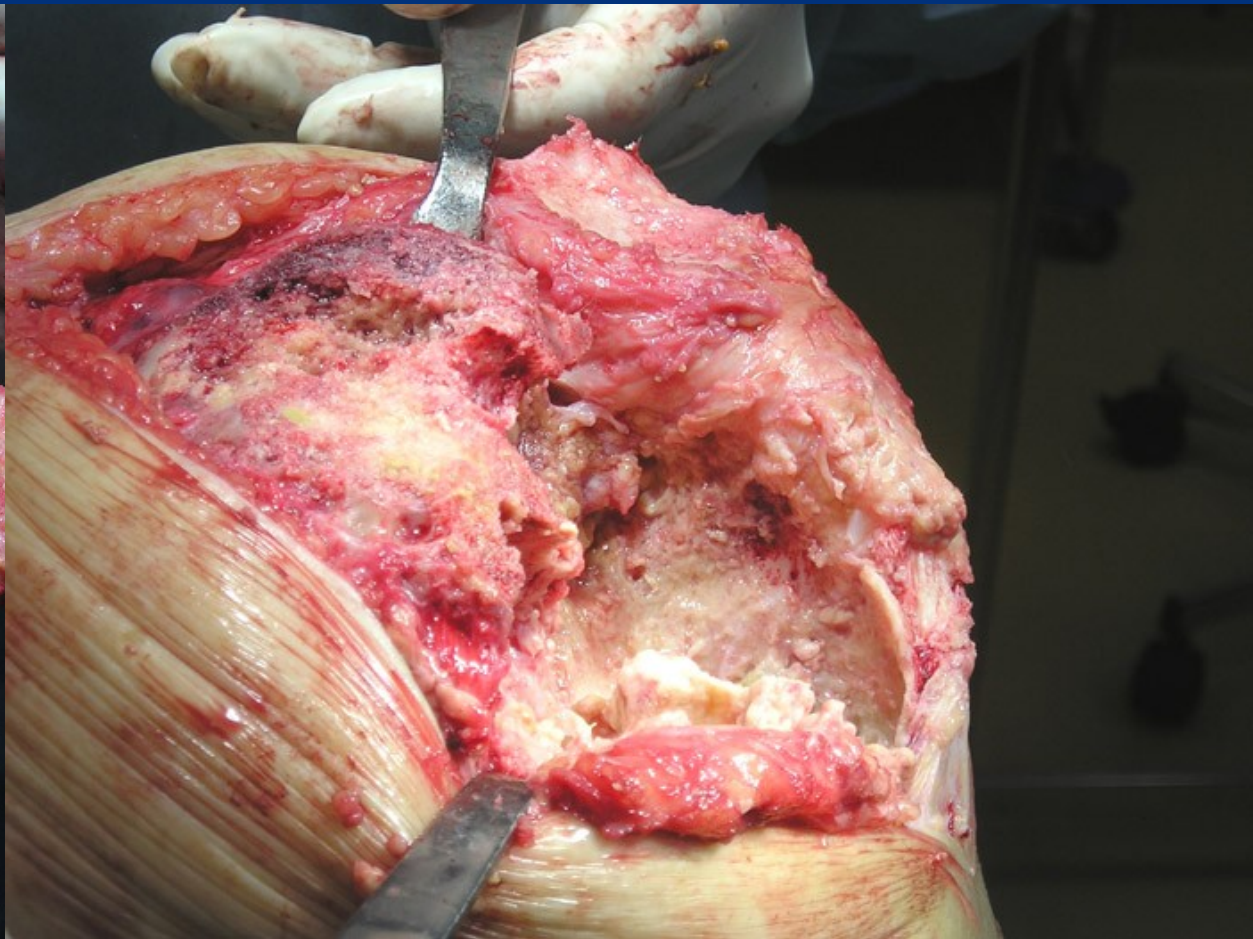
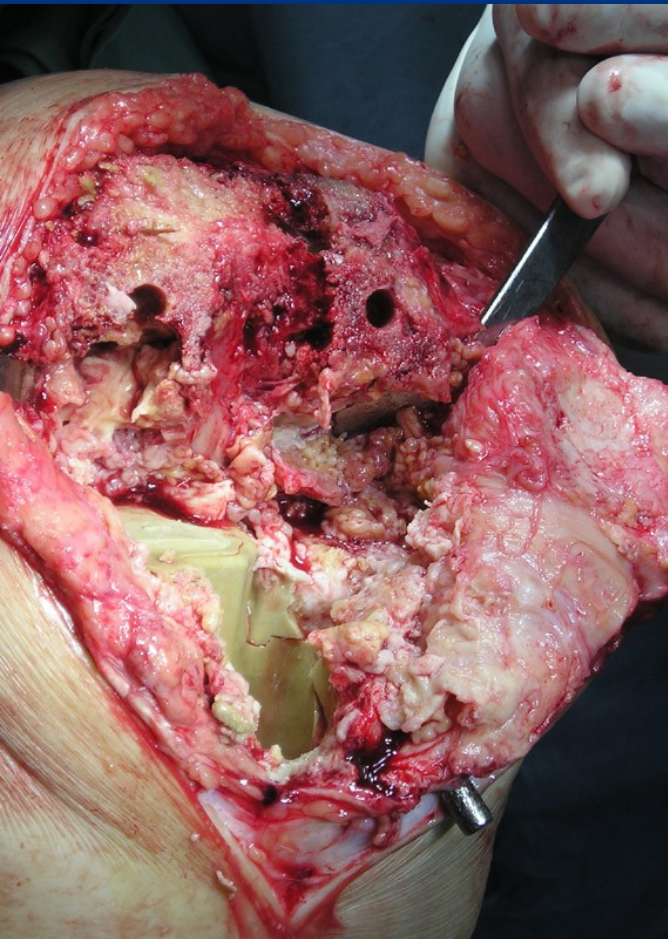
M, 1933, primary TKR 1996, R.A. 1/2005
Osteolysis on both sides
Revision TKR with LCCK, Next Gen, Zimmer, PS type, 1/2005,
patela baja, good position of tibial tray on bone, wide stems with cortical contact



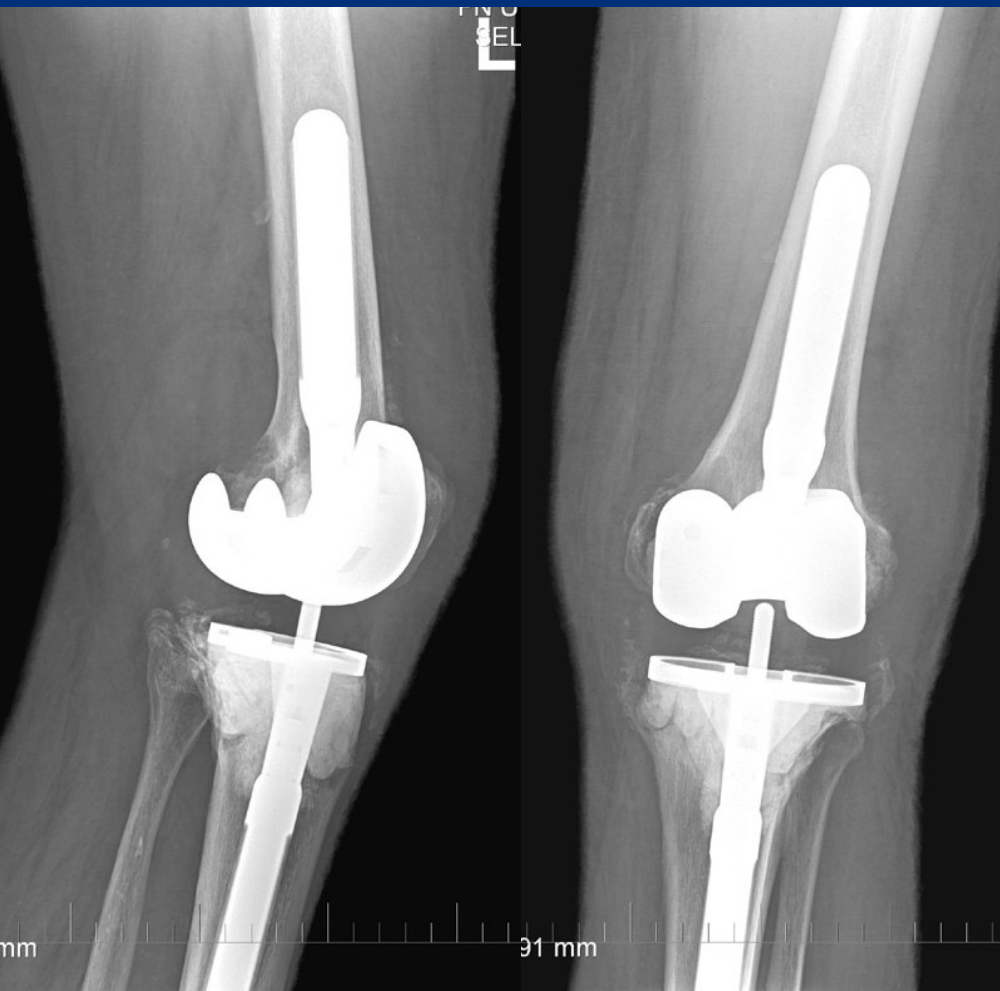4/2006



Revision of TKR with LCCK, Next Gen, Zimmer patela baja, good position of tibial tray on bone, Wide stems with cortical contact, good result

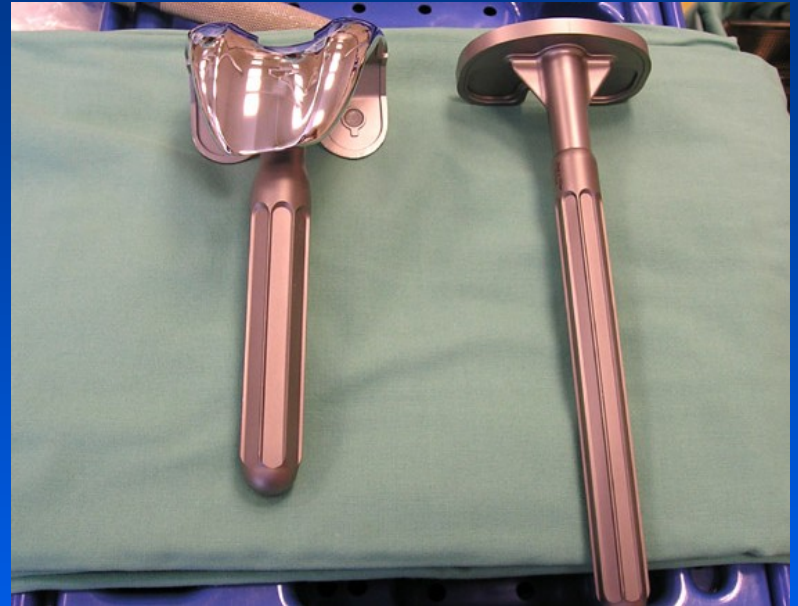

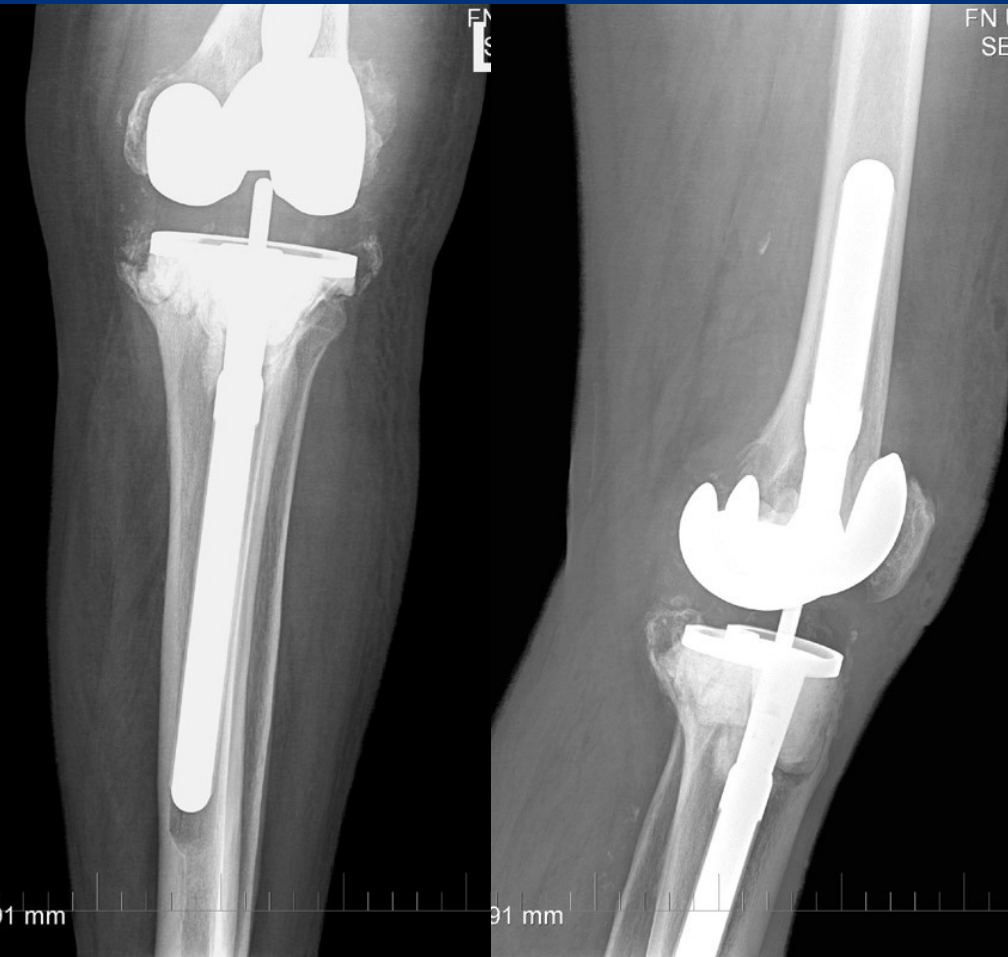M., 1927., primary TKR in 1997
Large defect of bone in the tibia



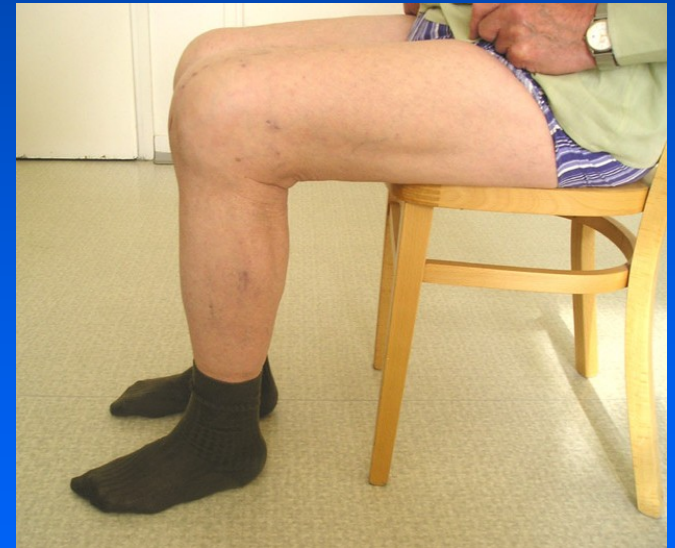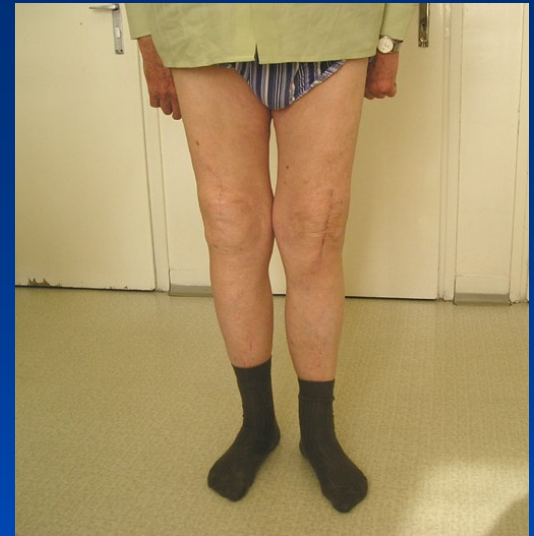2004

Revision TKR ,PFC Σ Modular Knee System
Bone cement in the tibia





2006



M., 1927., revision TKR ,PFC Σ Modular Knee System
Bone cement in tibia, cortical contact of the stems