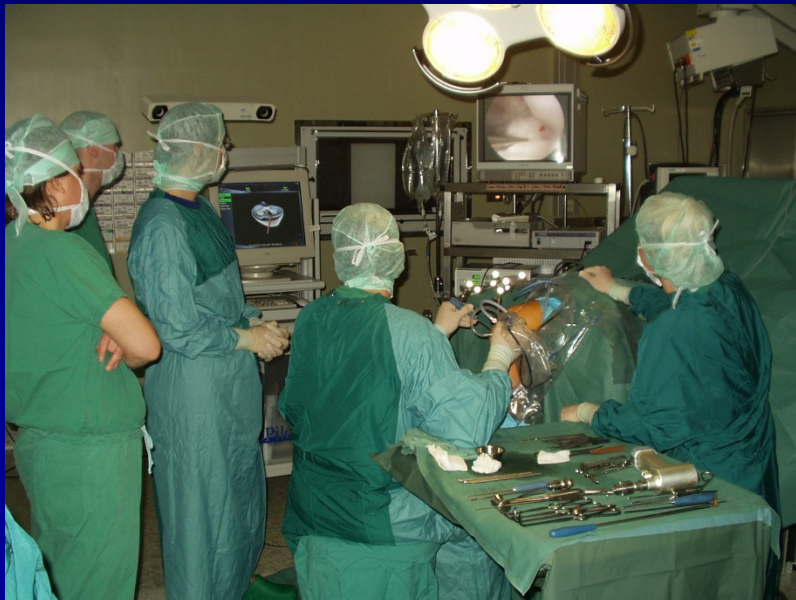

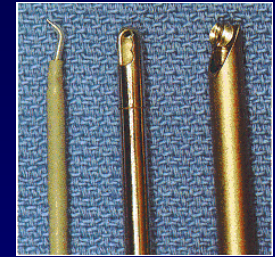
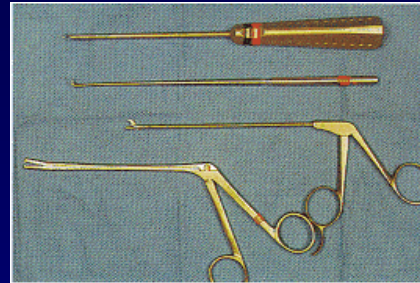

ARTHROSCOPY

- Endoscopic method
- Imaging and treatment
- In general or spinal anesthesia

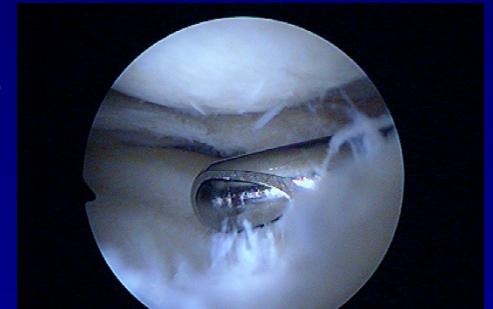

- knee
- shoulder
- ankle
- elbow
- wrist
- hip
- small joints

Arthroscopy



- Camera
- Arthroscope – rigid tube with a lens 30° or 70 °
- Xenon light with optic cable
- ASC pump
- Instruments
- Shaver
- Vaper
- Printer, VIDEO, DVD



Diagnostic arthroscopy

Cartilage

Ligaments

Menisci

Other intraarticular structures

Synovial membrane

Biopsy

Operative arthroscopy

Menisci

Chondropathy- shaving, debridement,
abrasion arthroplasty,
microfractures

Plasty of ligaments

Suture of rotator cuff

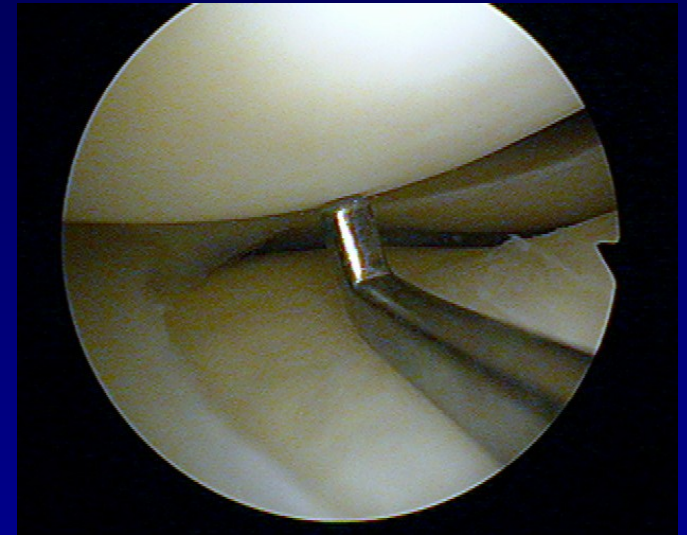
Instability of shoulder

Repair of transchondral lesions

Support in treatment of intraarticular fractures

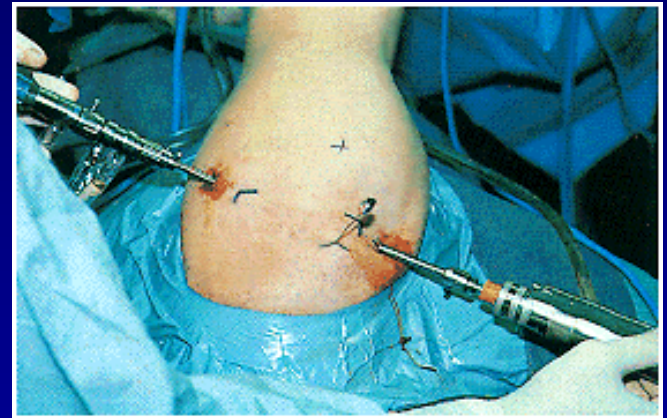
Advantages

- Perfect visualisation
- Less postoperative pain
- Fast physiotherapy
- Small incision



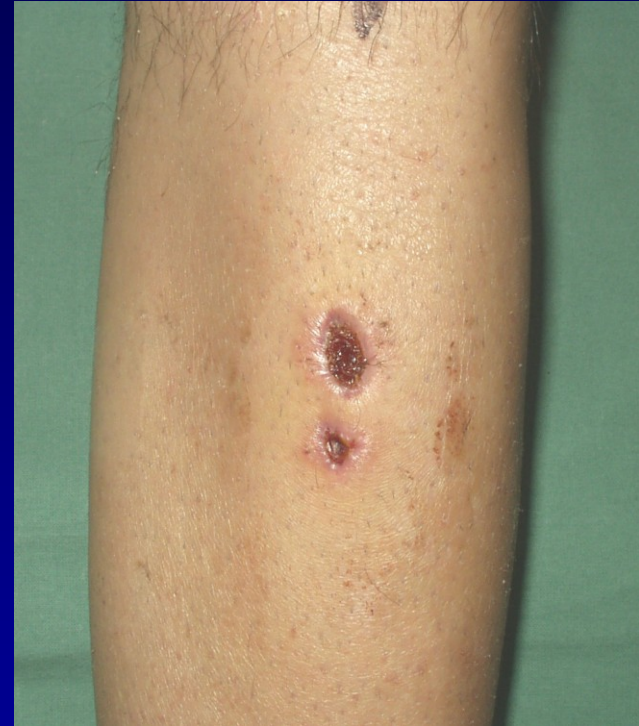Disadvantage

- Invasive method
- Intraarticular surgery
- Turniquet



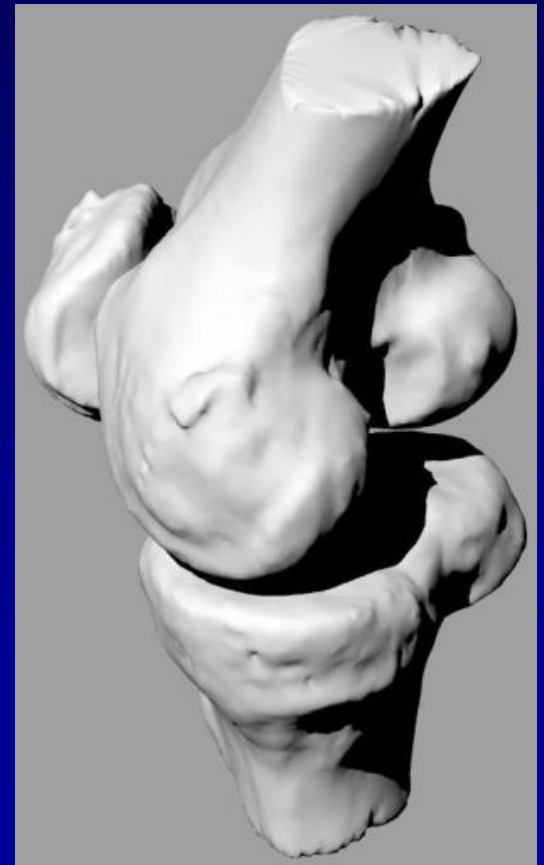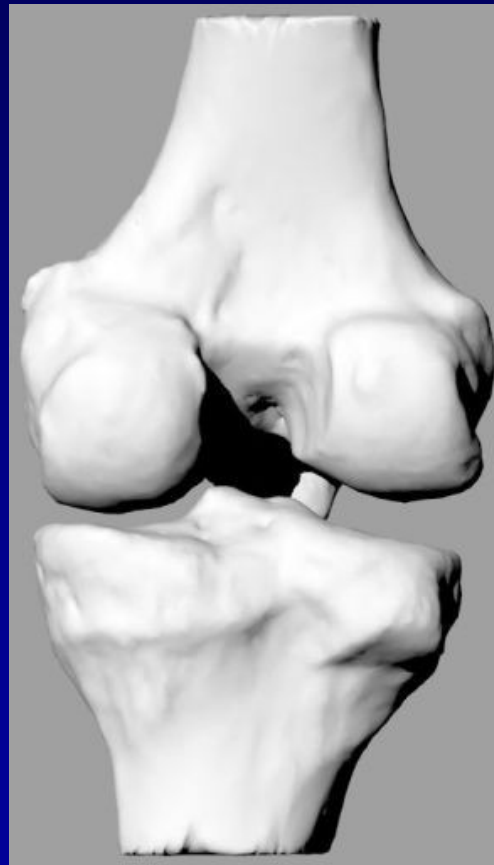
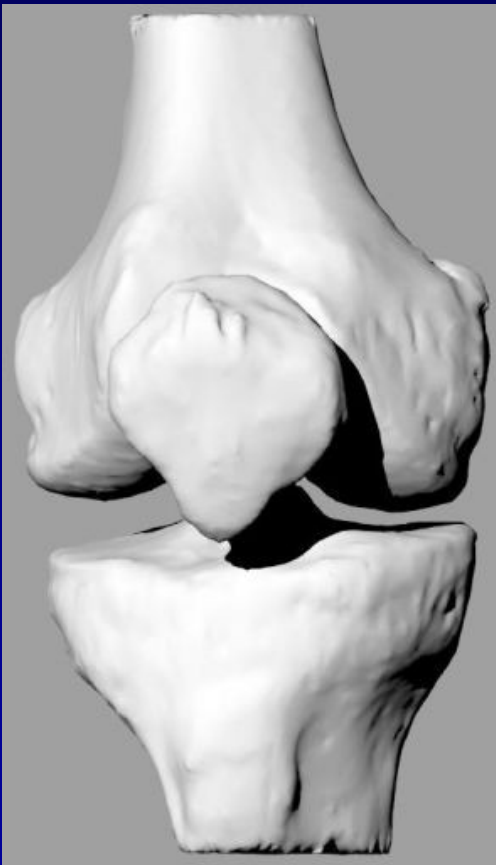Complications

- Wound healing
- Nerve lesions
- Vessels lesions
- Phlebotrombosis
- Effusions
- Infection

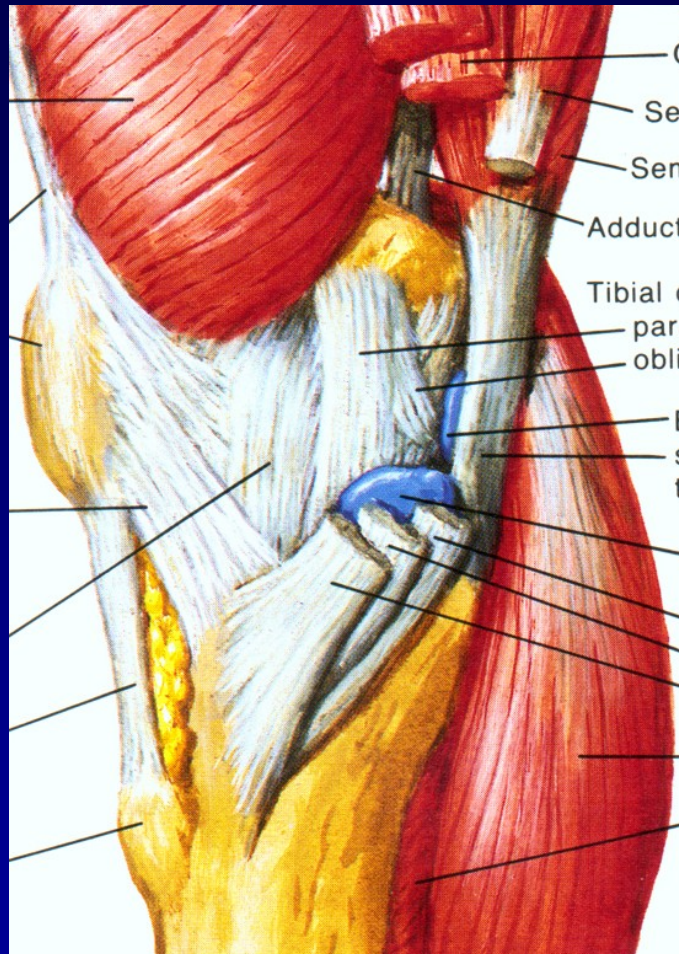


The knee joint- complicated structure

Articulating bones: Femur, tibia and patella

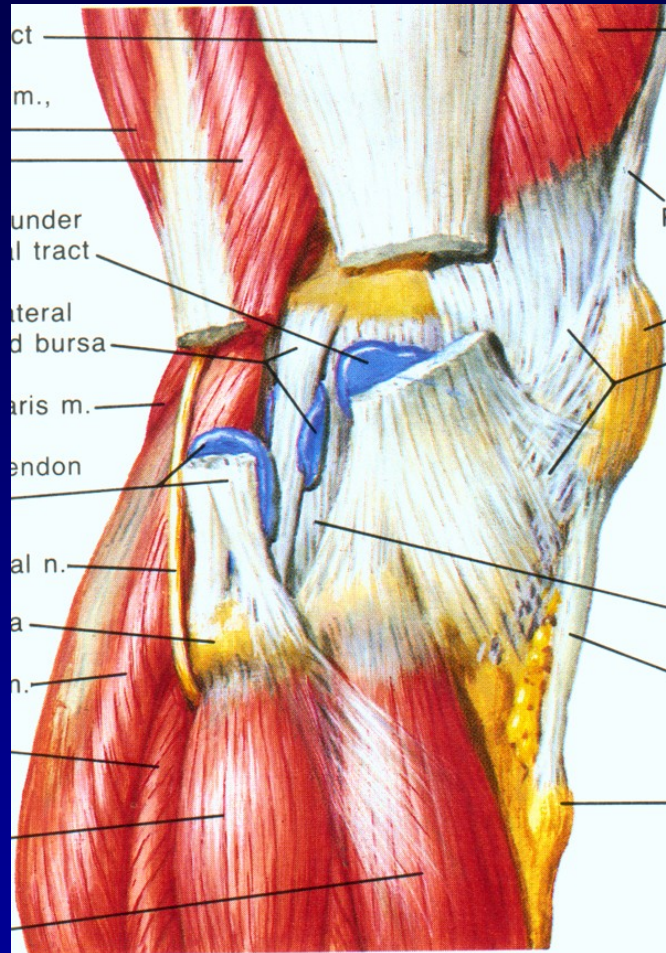


Stability of the knee



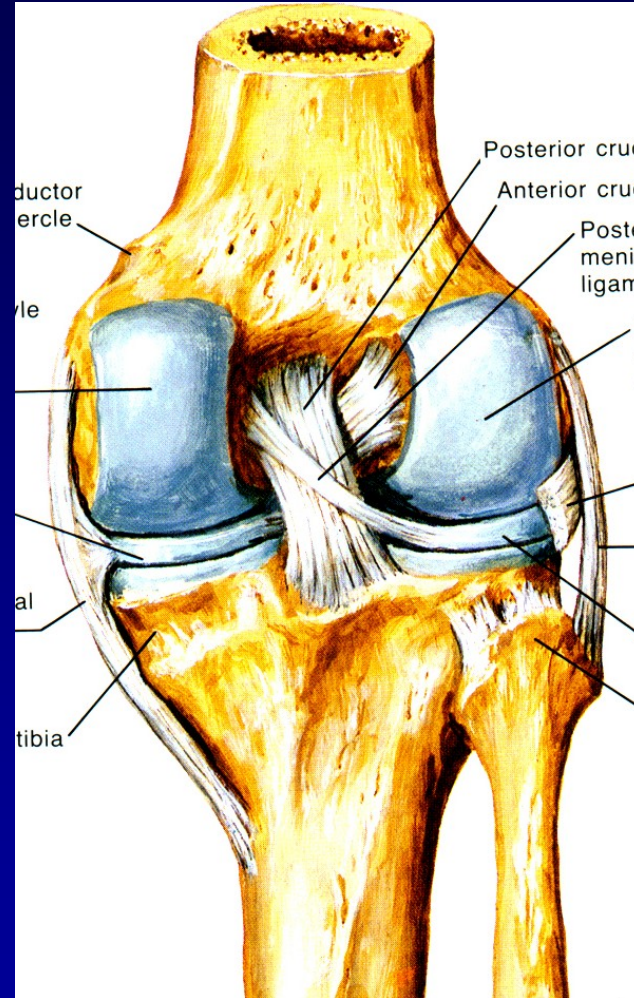
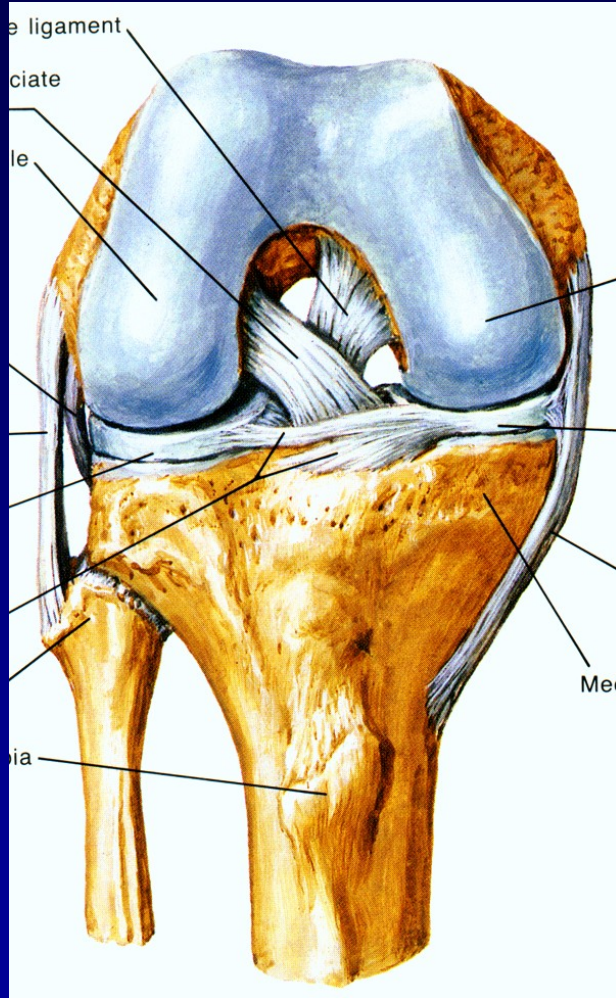
Medial side

Stability of the knee



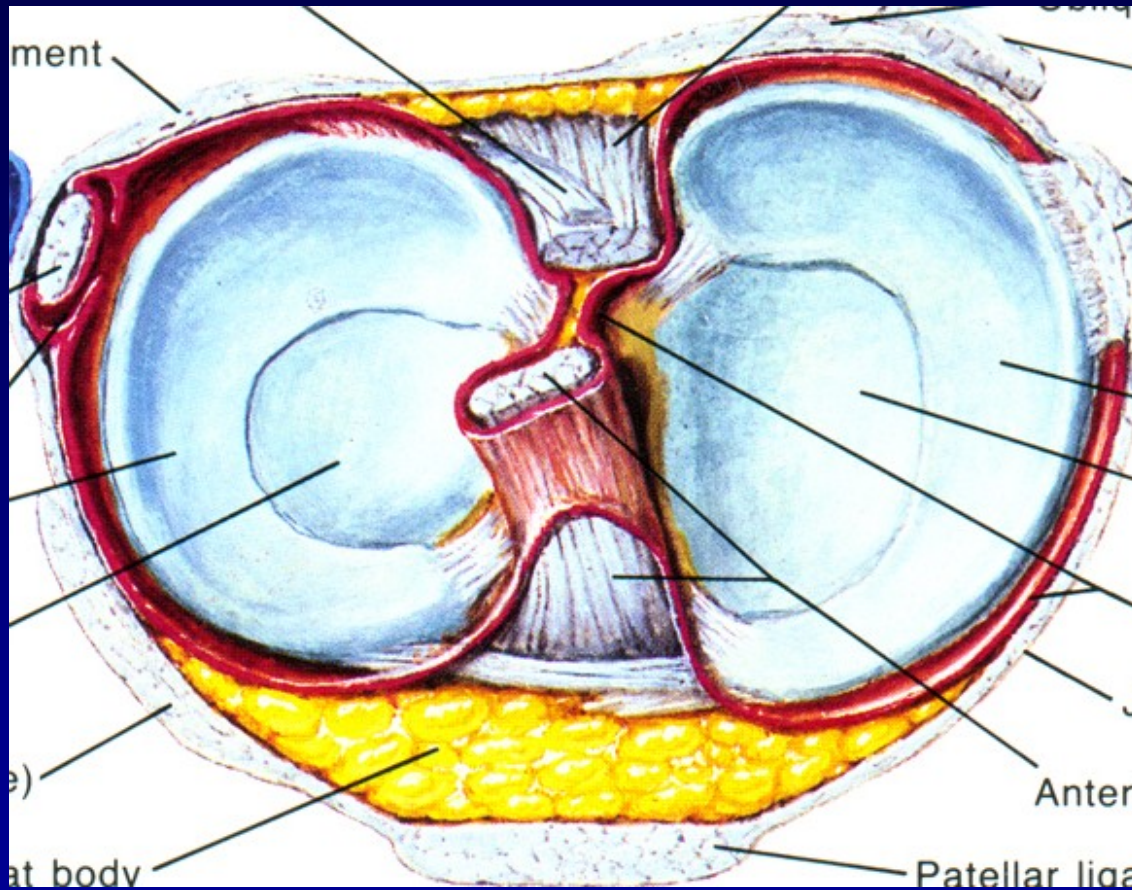
Lateral side

Stability of the knee



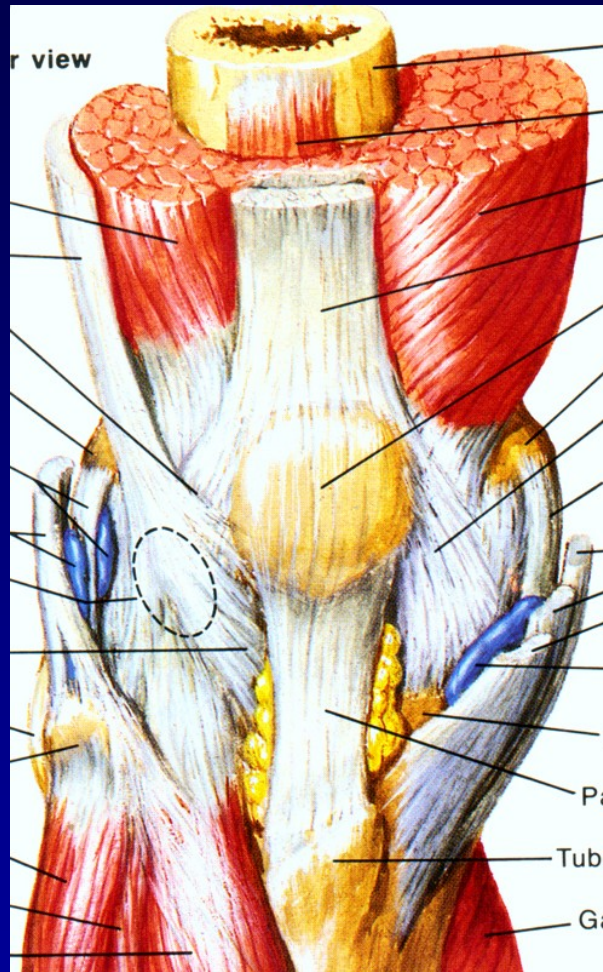
Cruciate ligaments

Stability of the knee joint



Menisci

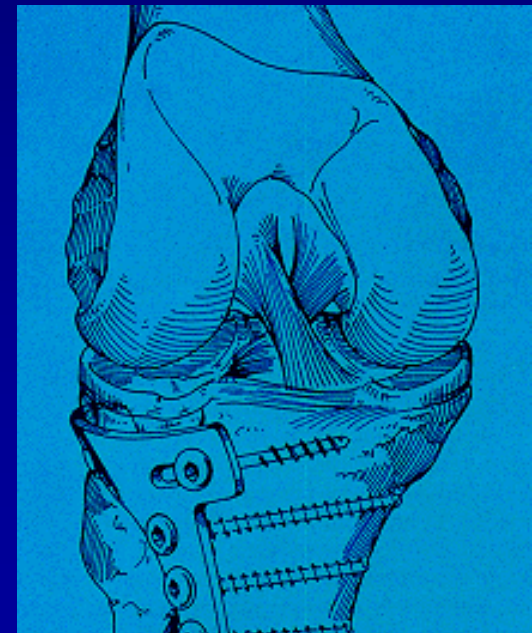
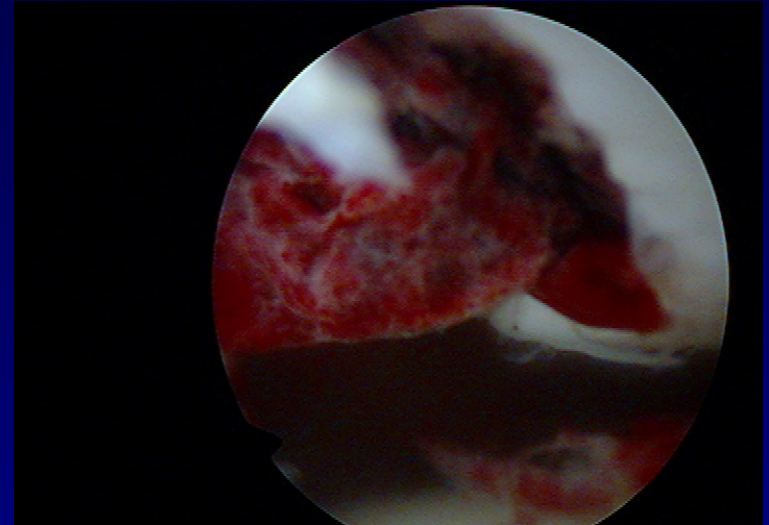
Stability of the knee



Muscles

The knee joint

- Traumatology
- Chondropathy
- Degenerative findings



Traumatology

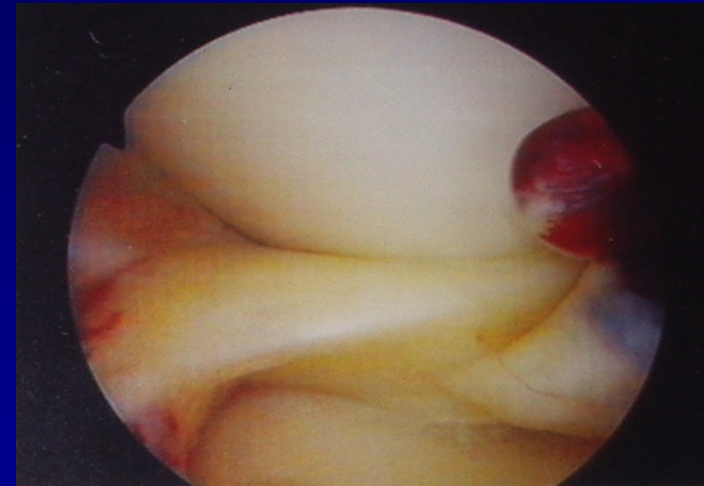
Haemarthrosis

Meniscus lesion

Rupture of ligaments


Dislocations of the patella

Transchondral fractures



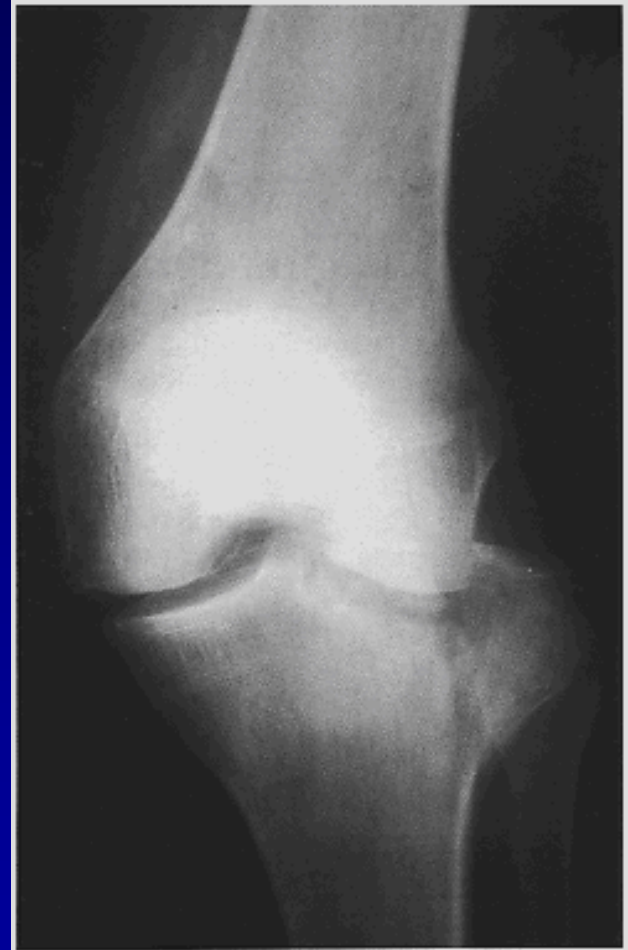History

- History
- Mechanism of injury



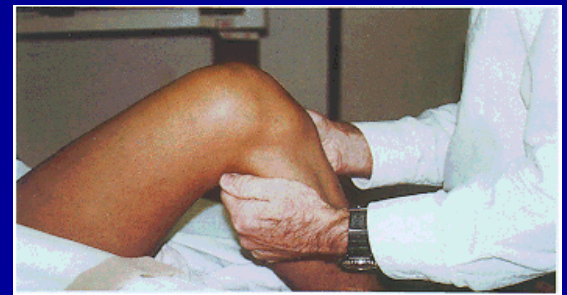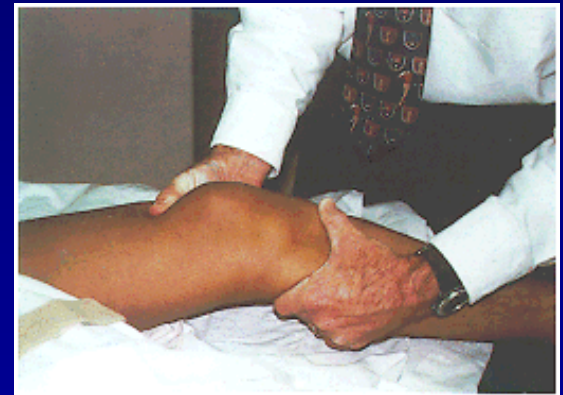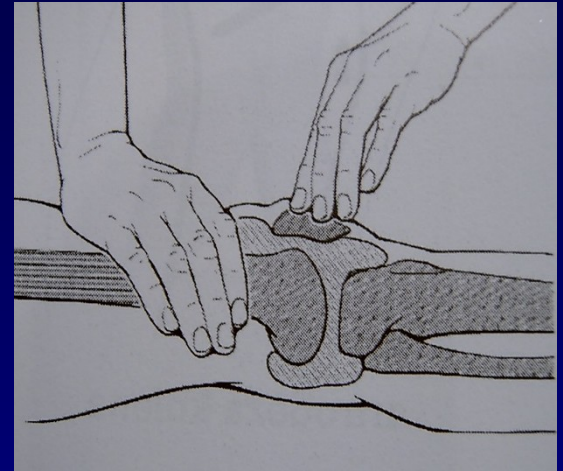
Examination

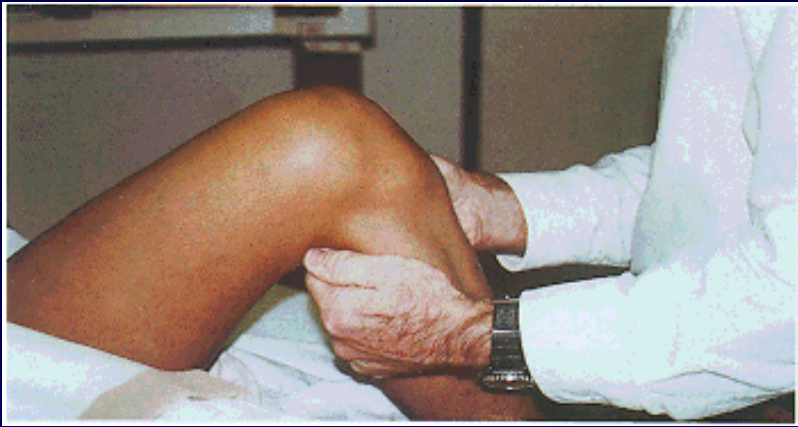
- Clinical examination
- Aspiration
- Blood patches
- X- ray
- MRI
- Ultrasonography



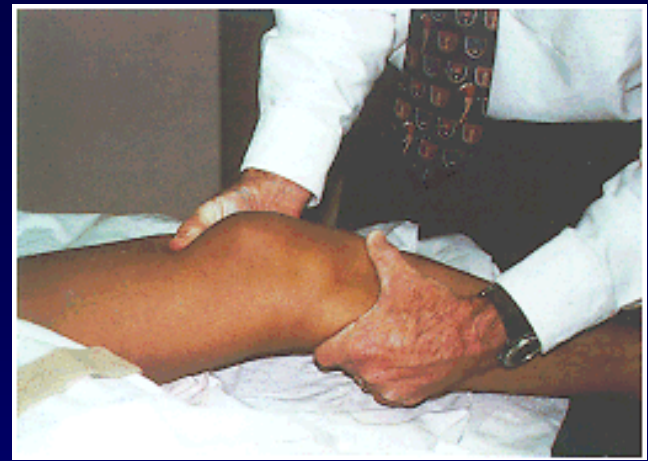Clinical examination

- Swelling, haematoma
- Effusion
- ROM
- Tenderness
- Stress test for stability
- Maneuvers
- Patella examination

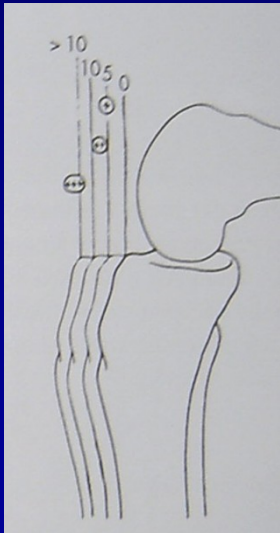




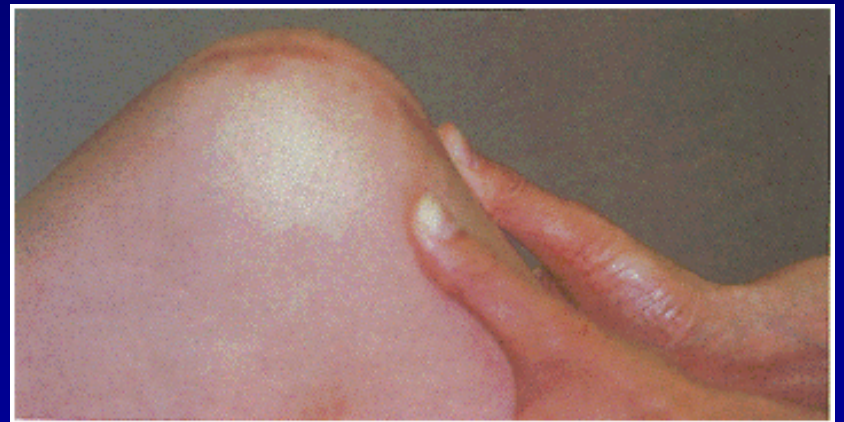Anterior drawer sign



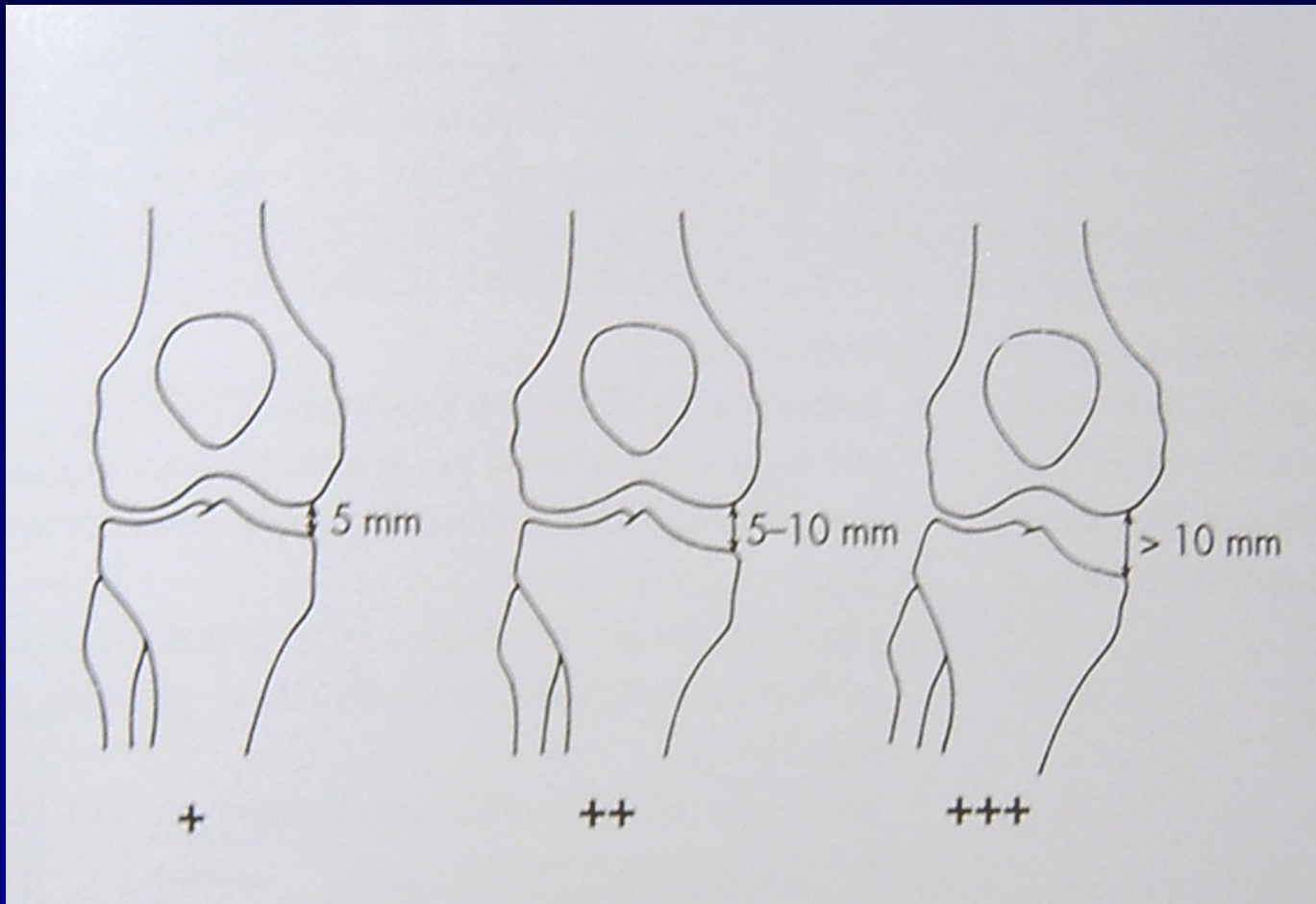
Lachman test



Anterior drawer sign, pivot shift test



Posterior drawer sign



Valgus stress test
Varus stress test

Meniscus

Mechanism of injury

Tests: Mc Murray

Steinmann I

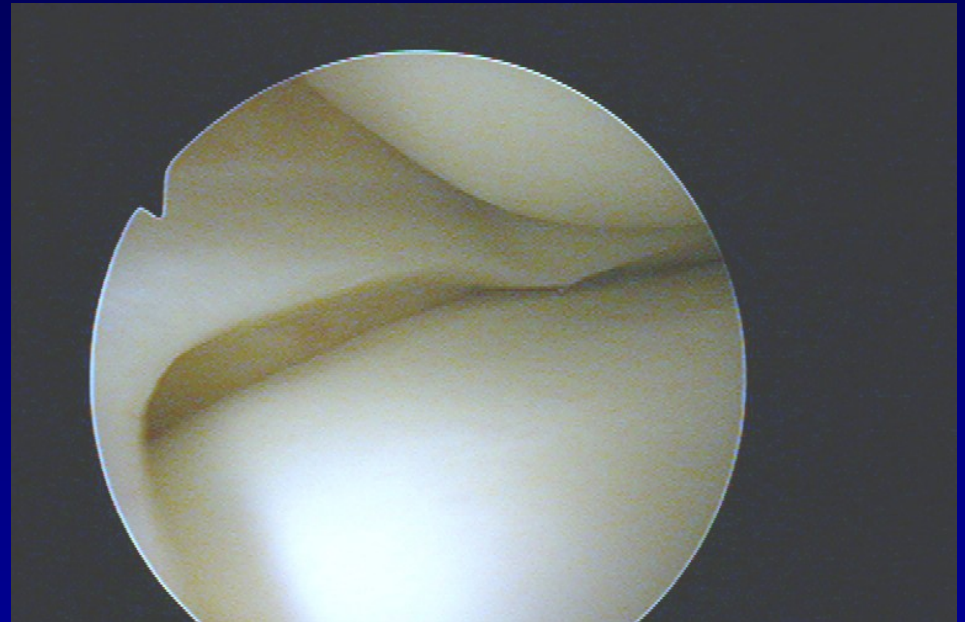
Steinmann II

Appley

Turner

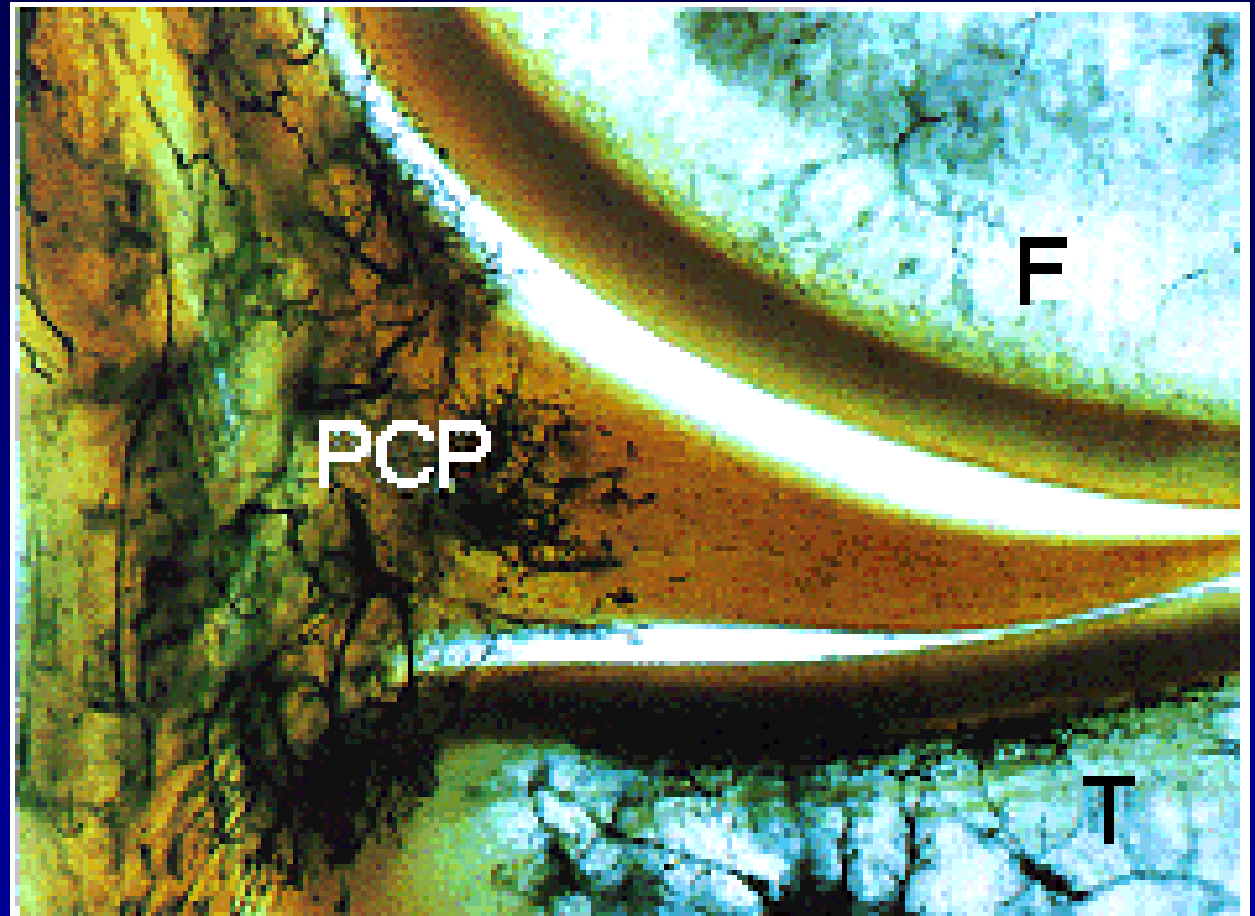
Payer

Childress- squat test



Meniscus

- Fibrocartilago
- High elasticity
- Paracapsular zone
 - vessels

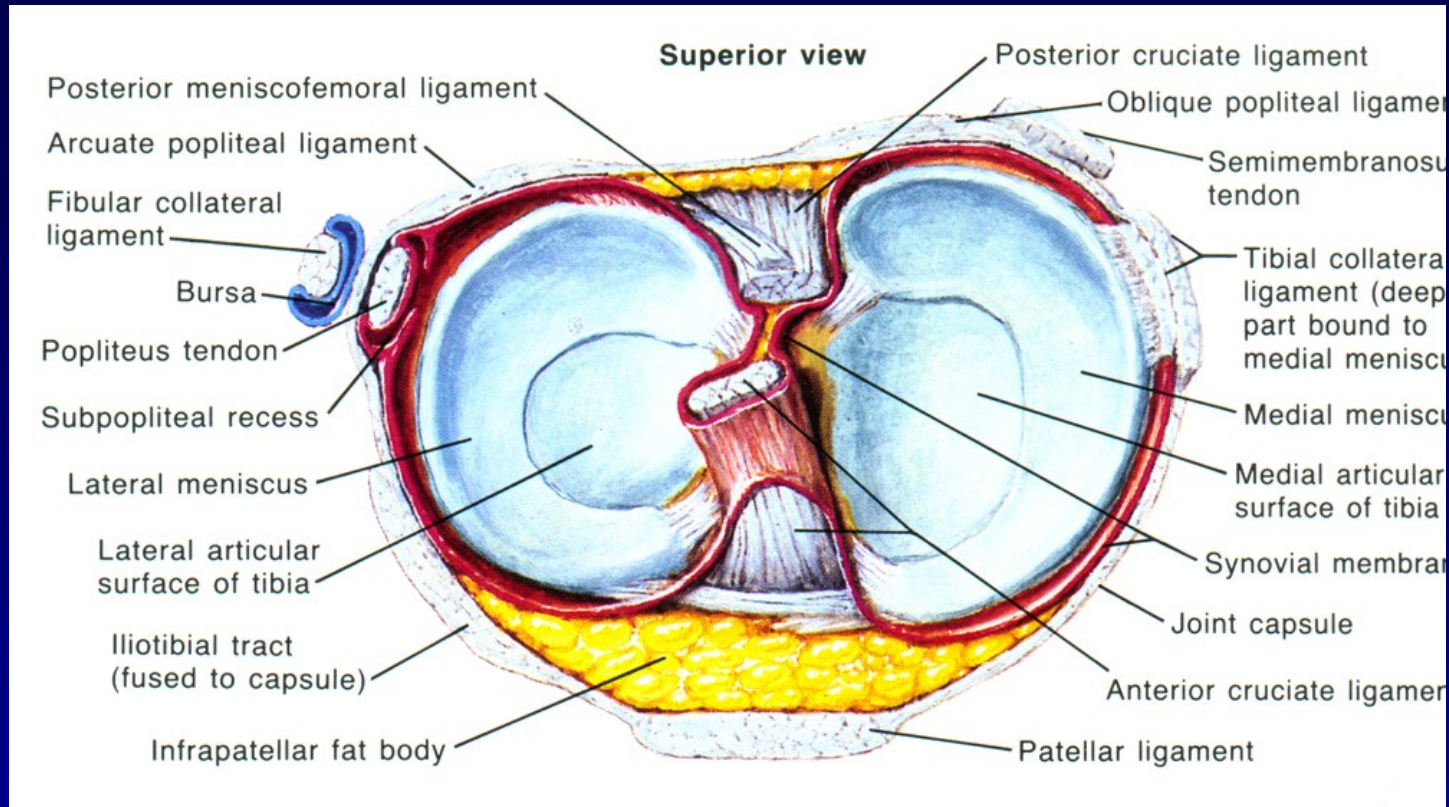


Red zone

red- white zone

white zone

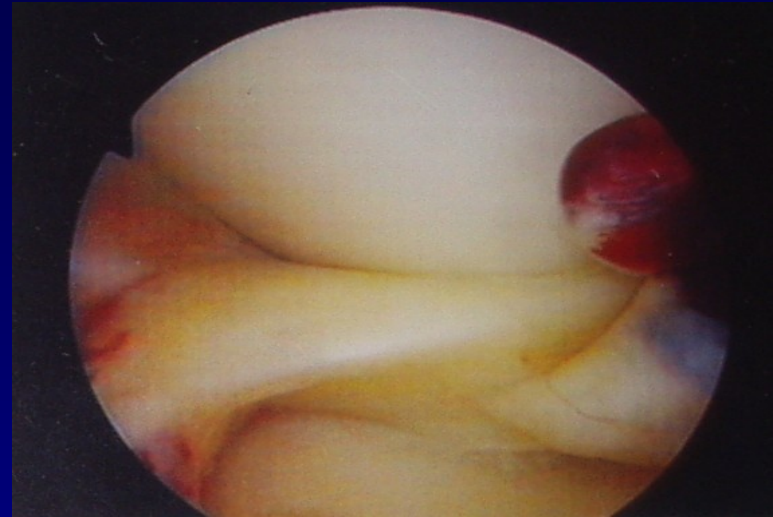

Functions



- Bumper
- Stabilisator
- More congruency
- Distribution of synovial fluid
- LM – more mobile
- MM – prone for injury

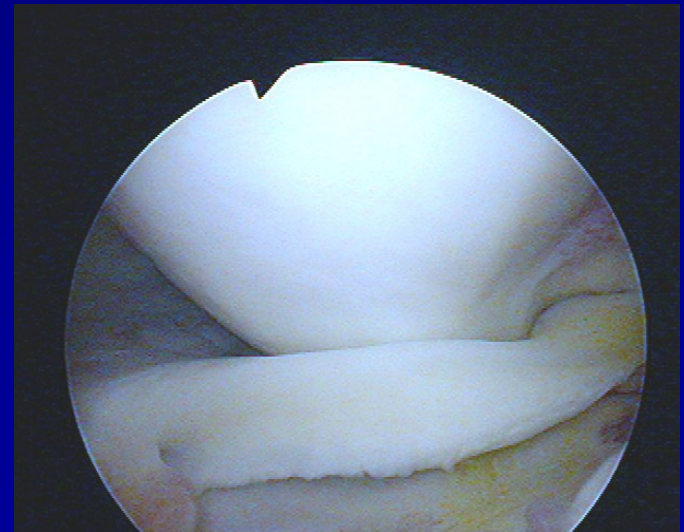
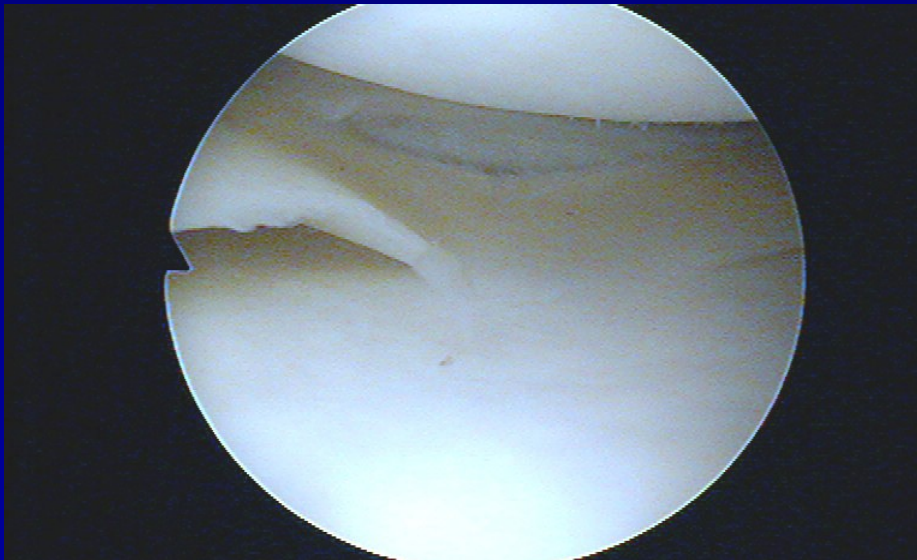
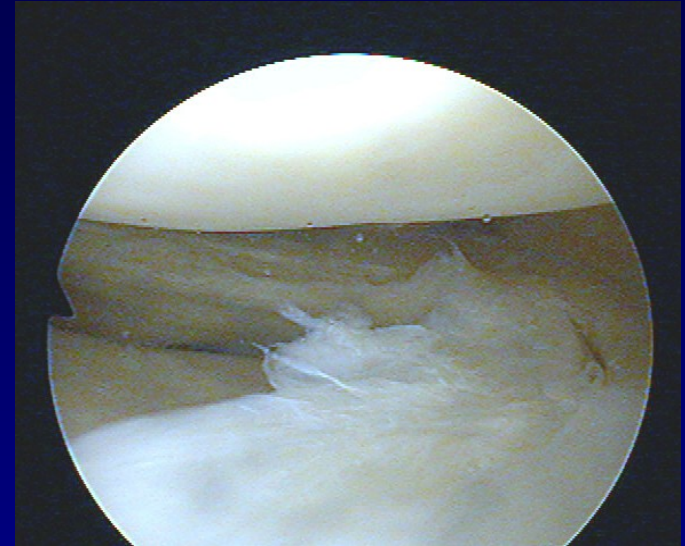
Ruptures of menisci

- Longitudinal, horizontal, radial
- „bucket handle type“
 - Typical blockage
- Degenerative lesions
- Discoid meniscus



Ruptures of menisci

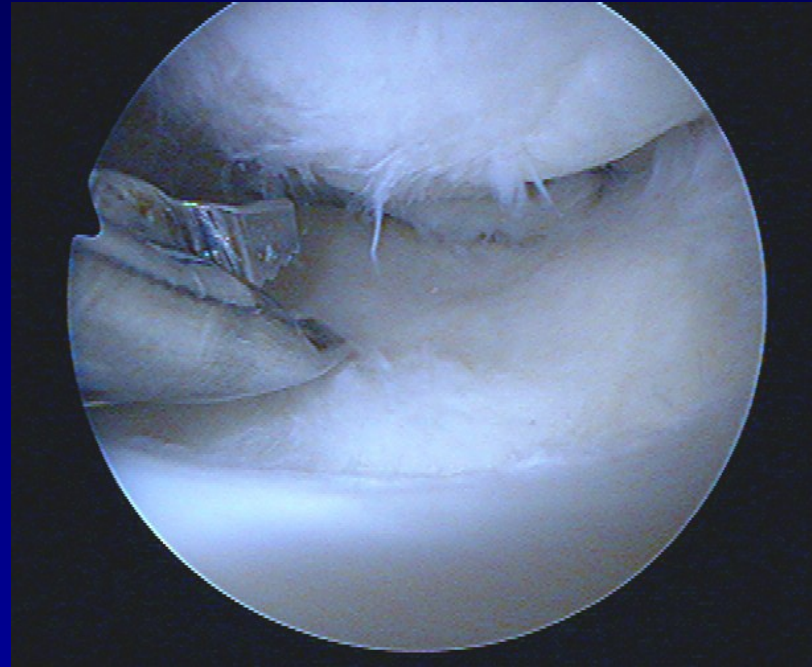
- Longitudinal, horizontal, radial
- „bucket handle type“
 - Typical blockage
- Degenerative lesions
- Discoid meniscus



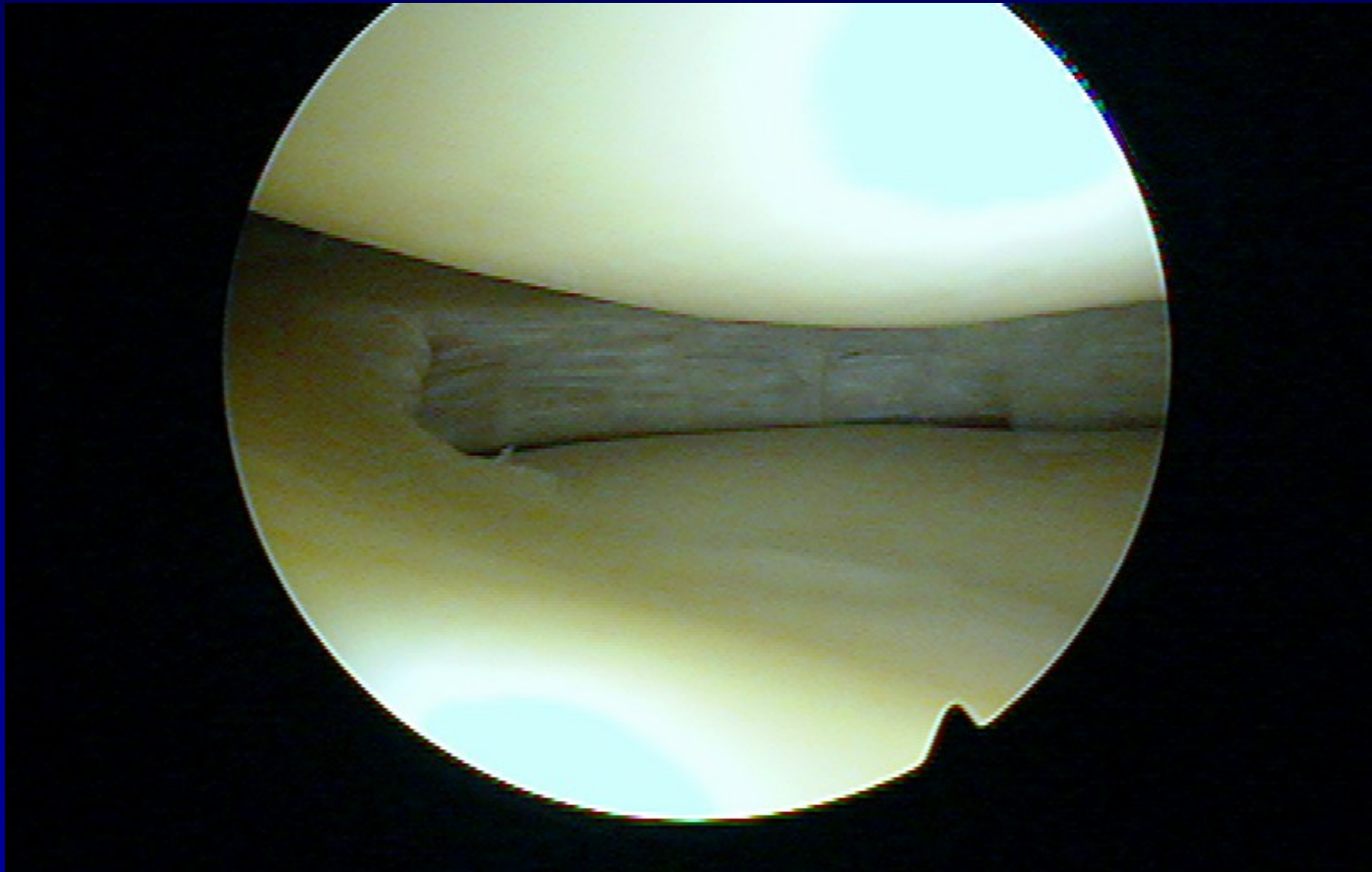
Meniscus treatment

Meniscectomy

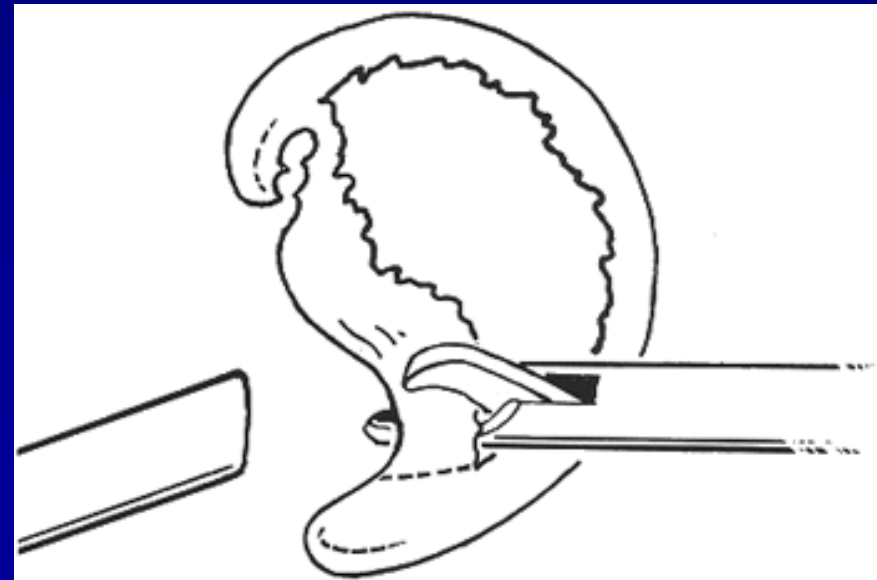
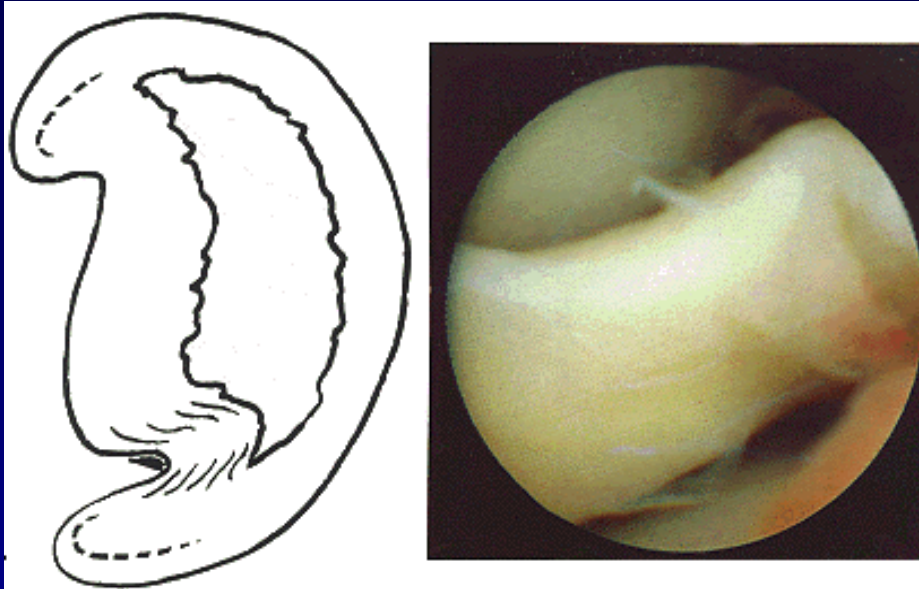
- partial
- subtotal
- complete



Partial meniscectomy



Subtotal meniscectomy

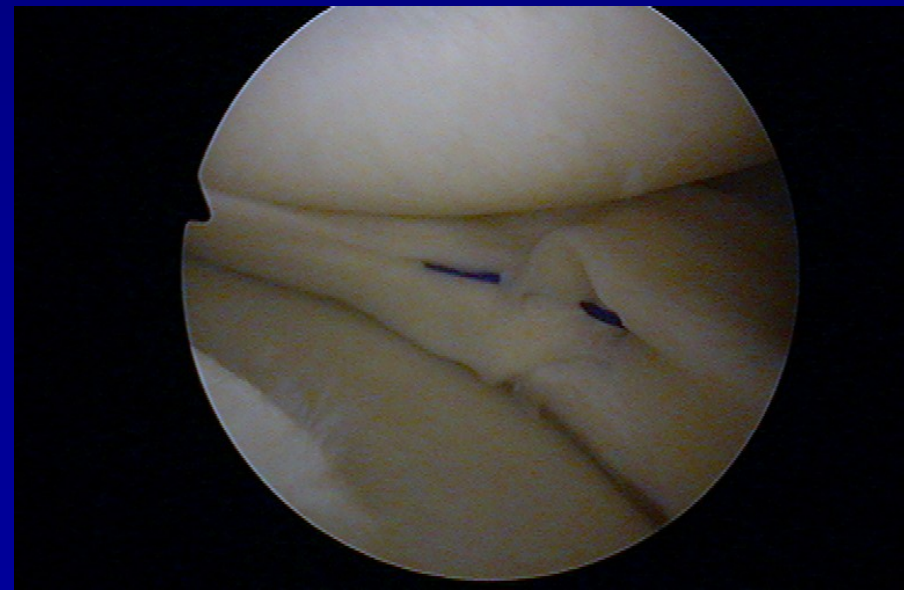
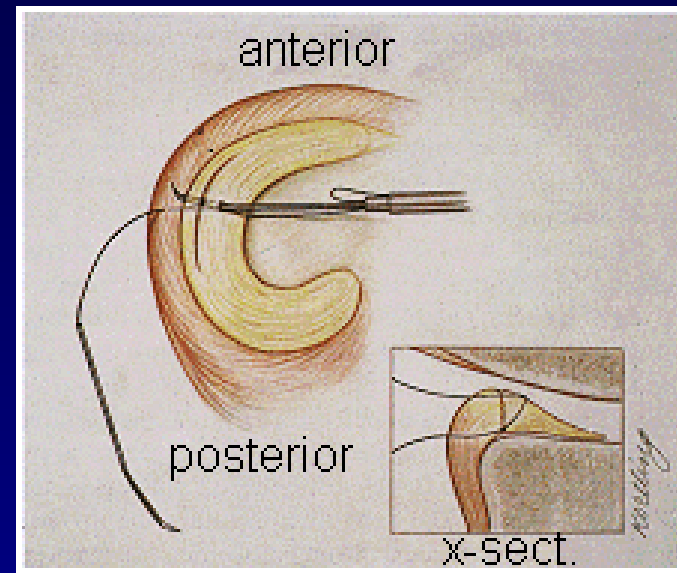


Suture of meniscus- meniscopexis

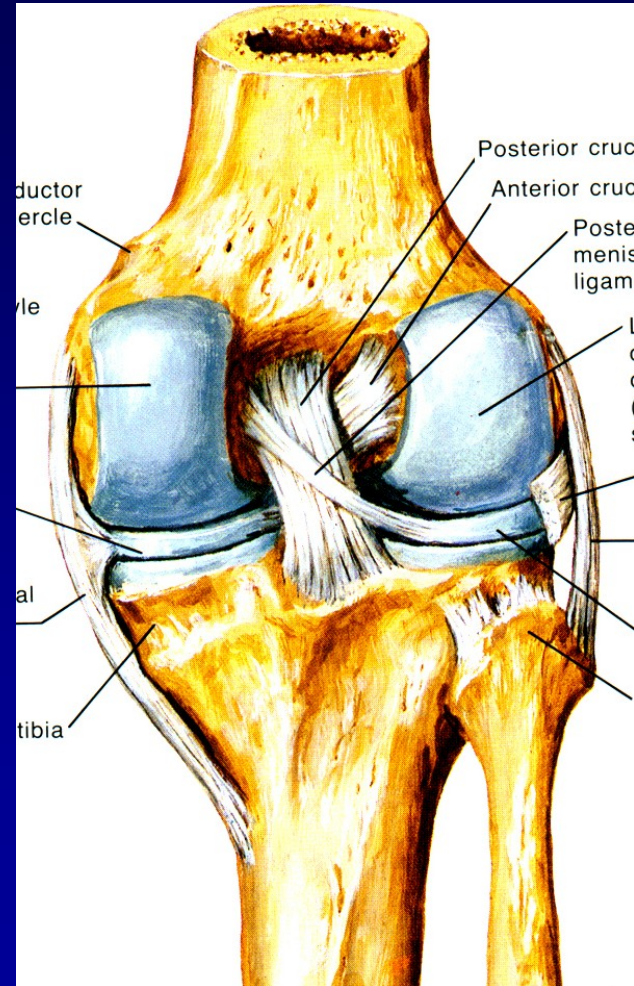
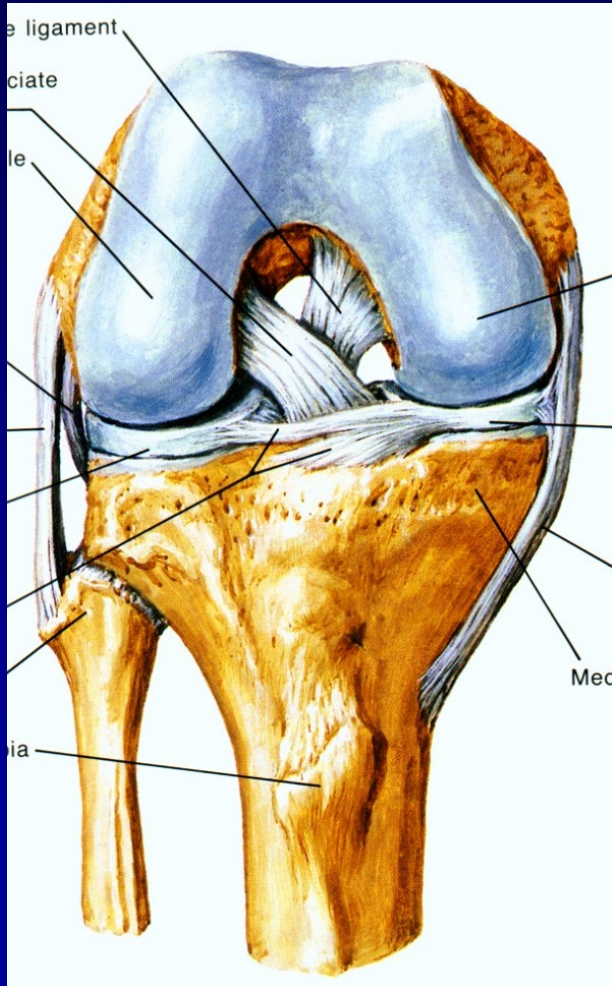
outside-in

inside-out

all-inside

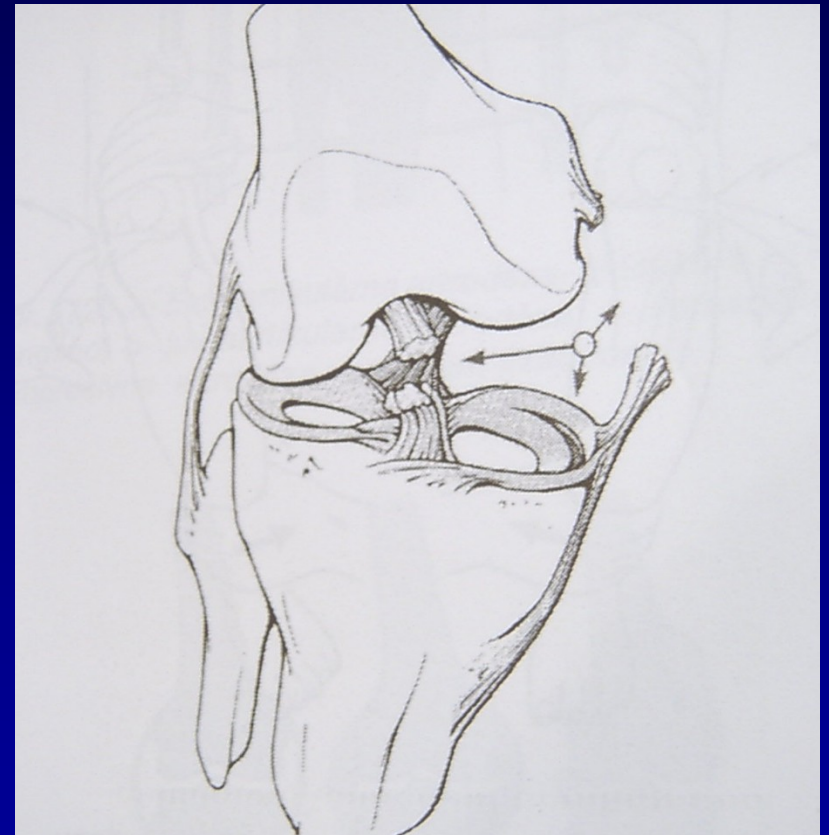

Ligaments- ACL, PCL



Rupture of ligaments

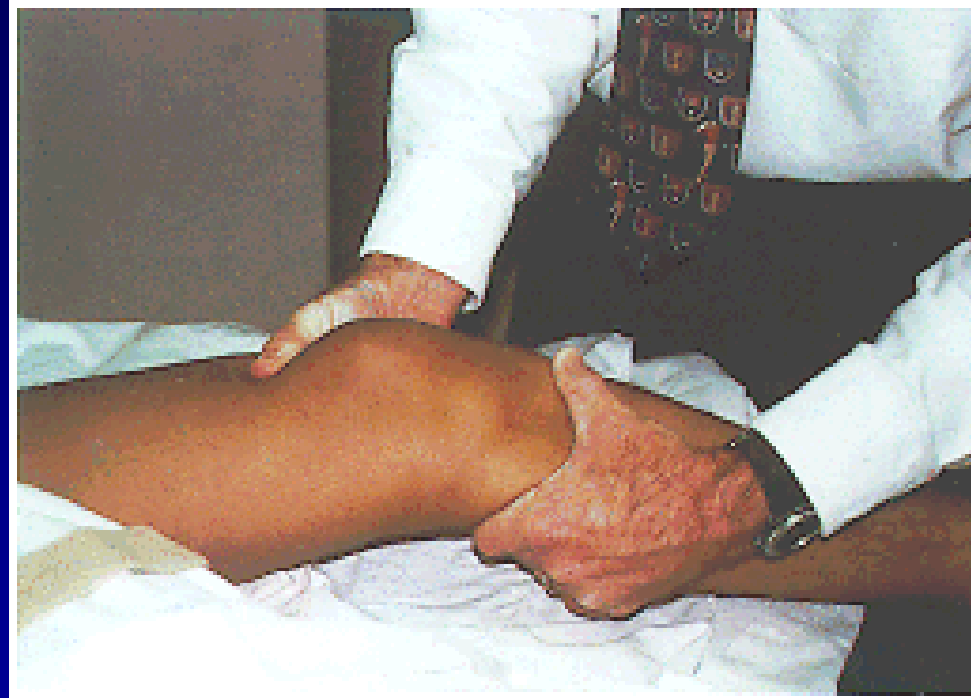
- **Sprain**
- **partial rupture**
total rupture
- Mechanism of injury
- Tests of stability



„Unhappy trias“

Rupture of ACL

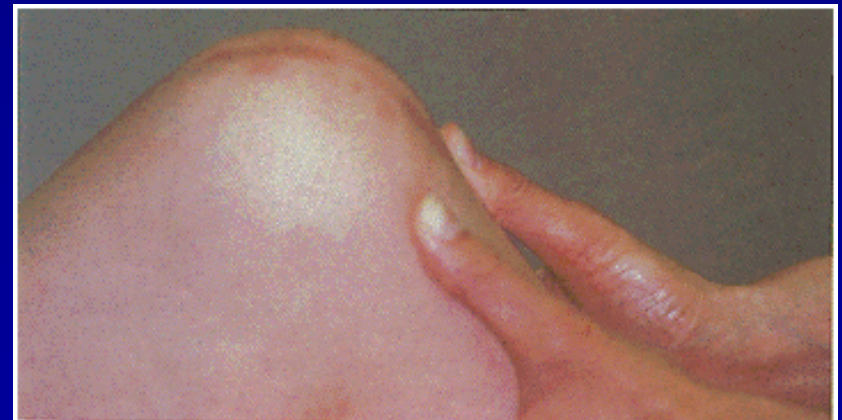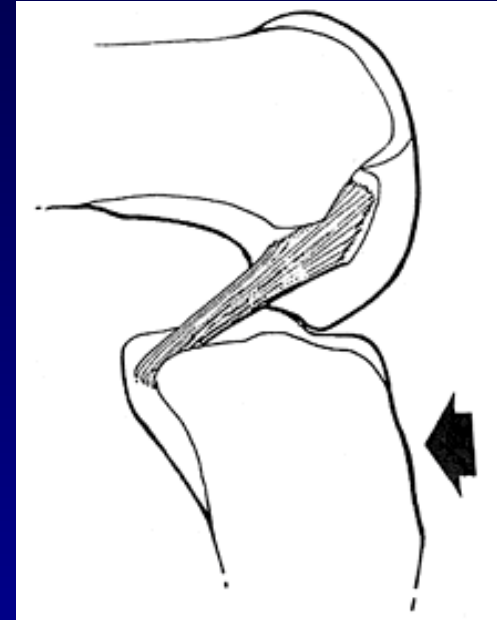
- Tests of stability
- Lachman test
- Anterior drawer sign
- Pivot-shift test



Lachman test

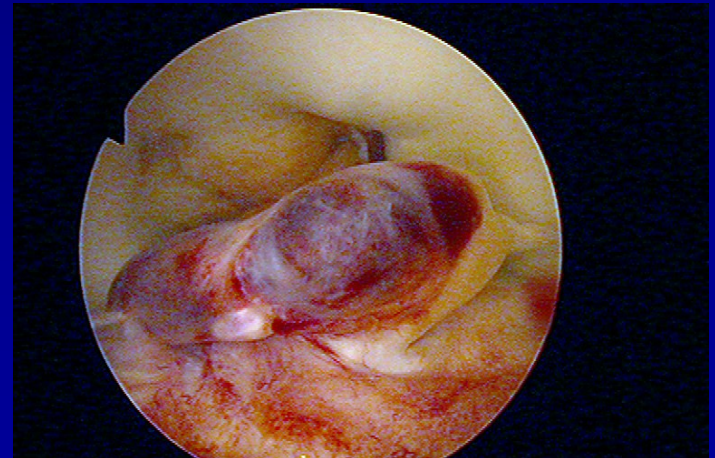
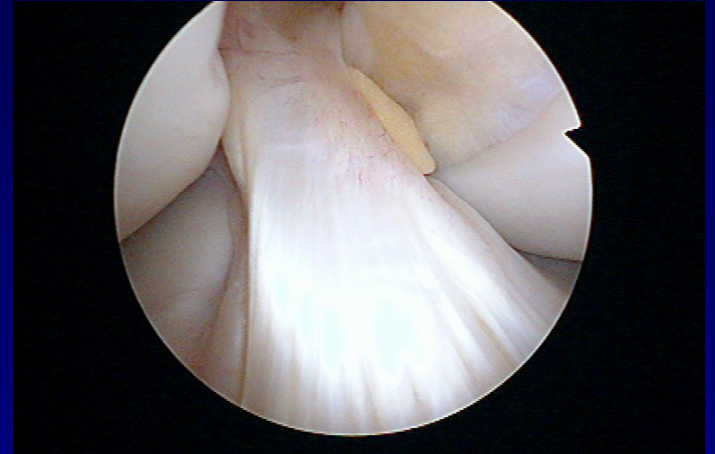Rupture of PCL

- In **dashboard injury**
- Posterior drawer sign



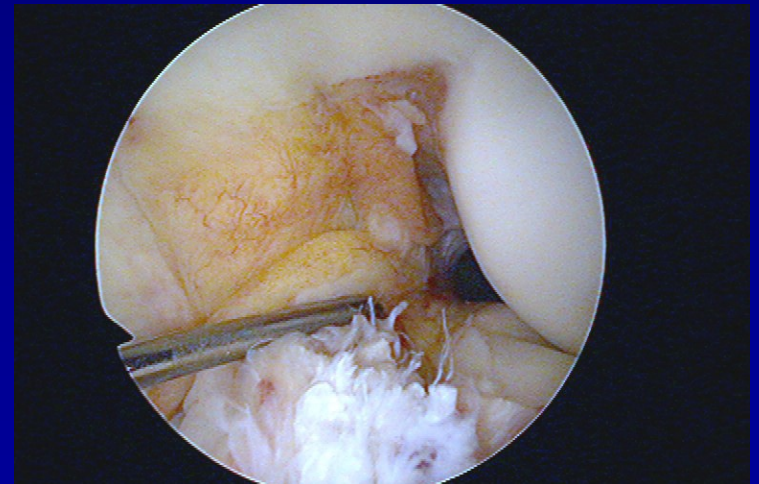
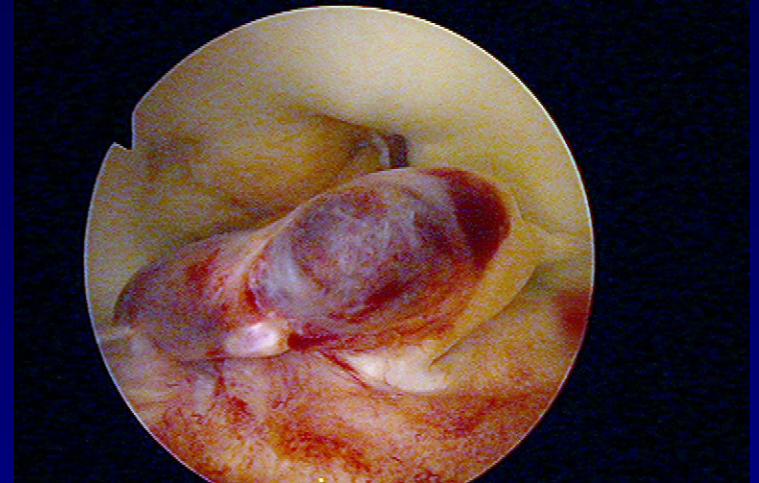
Rupture of ACL

- Frequent injury



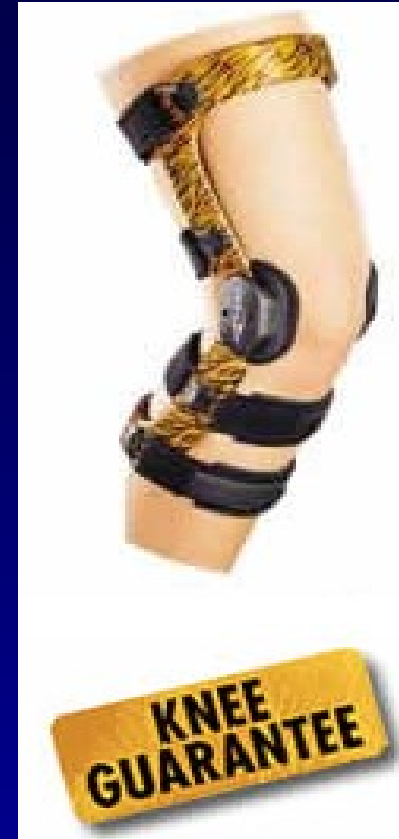Acute rupture of ACL

- Debridement
- Physiotherapy
- Limited activity
- Orthosis





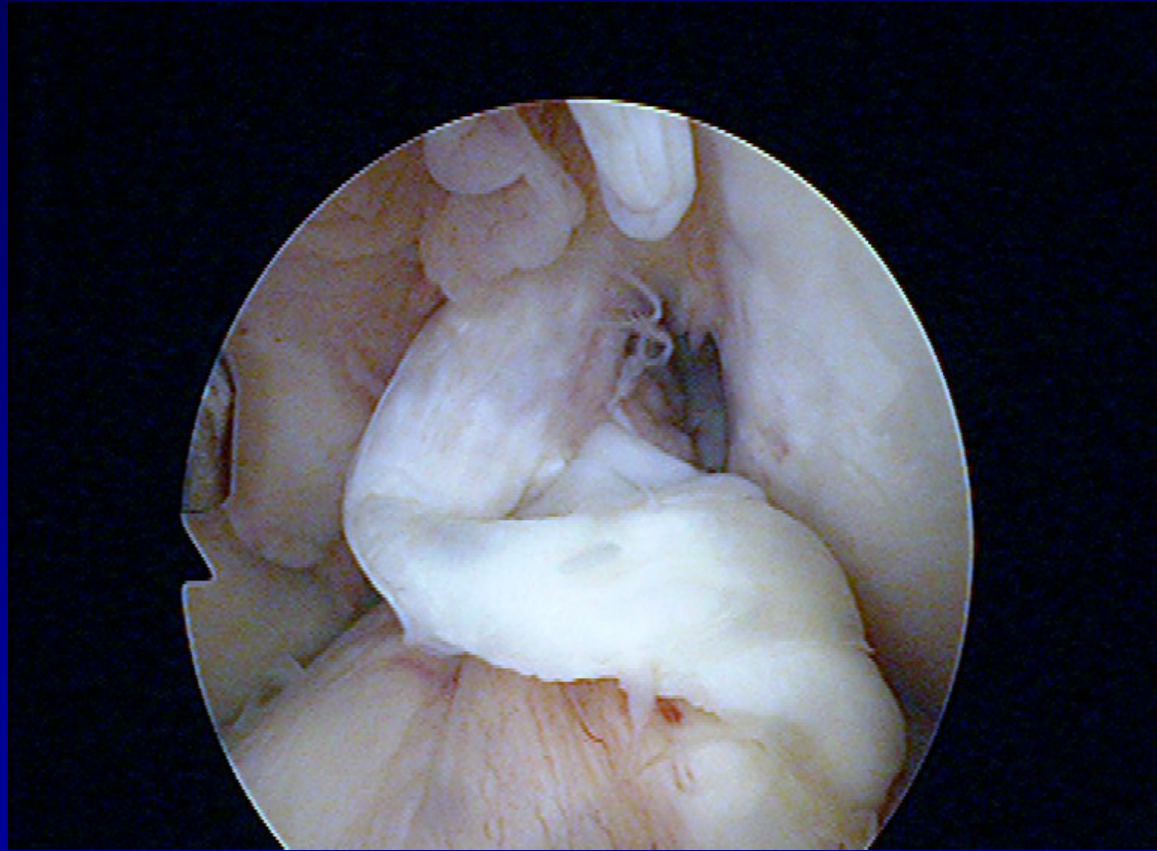

Physiotherapy



Orthosis

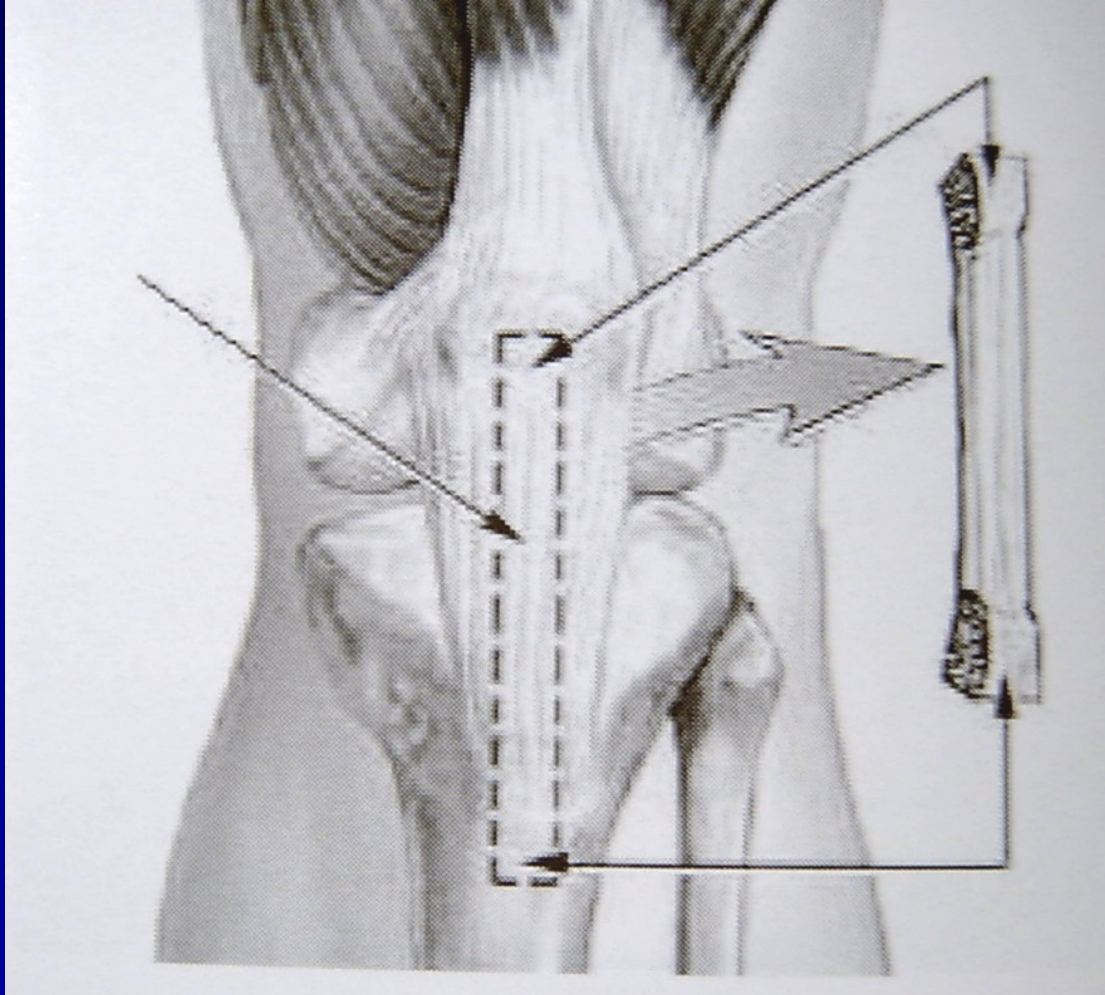
Indication for reconstruction

- 1/3 of cases



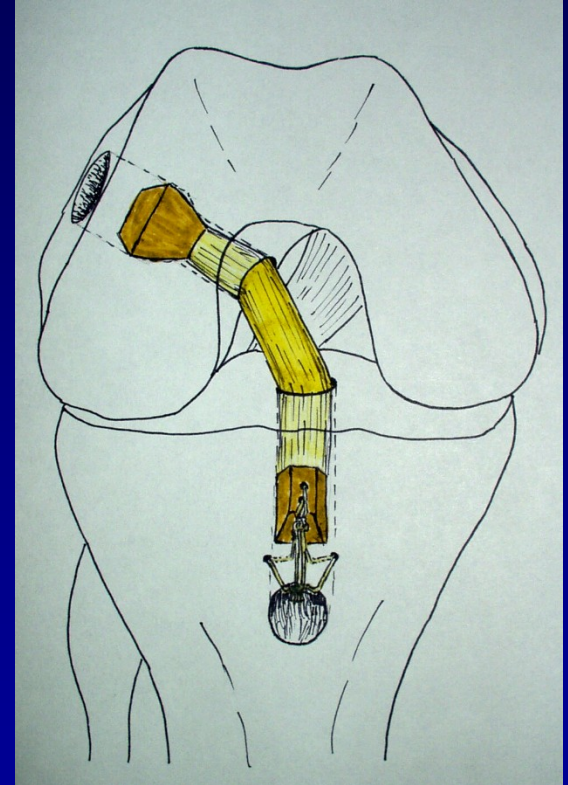
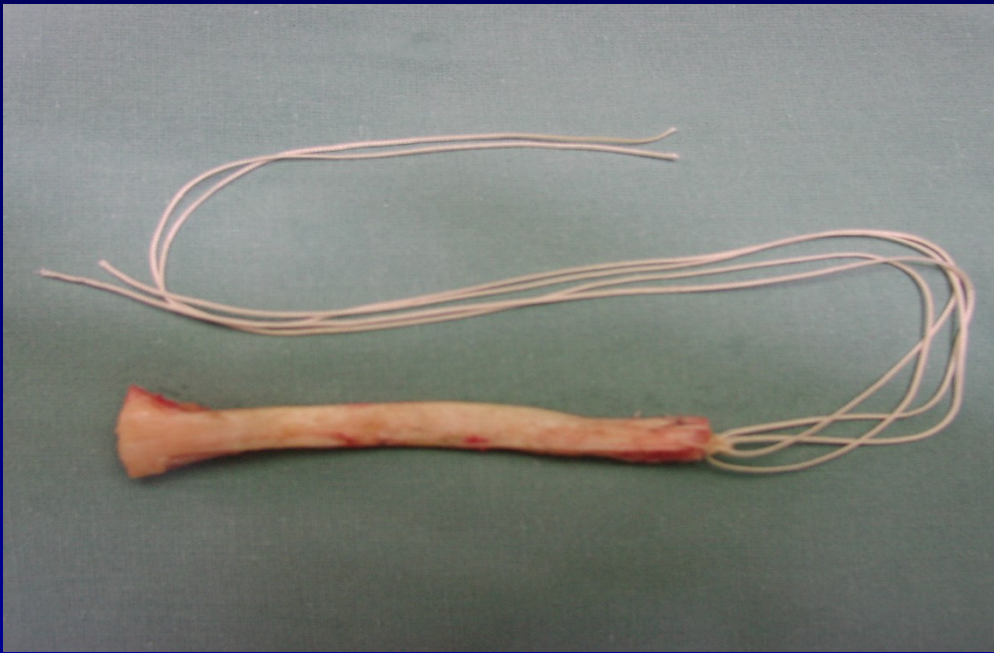
BTB graft

- Bone-Tendon-Bone



BTB graft

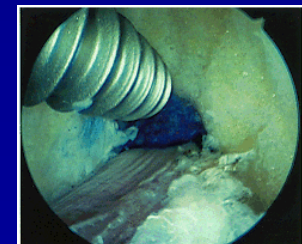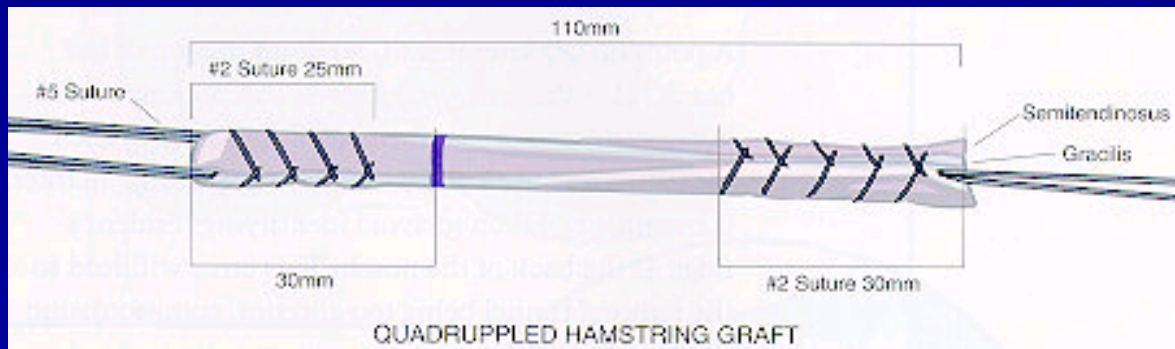
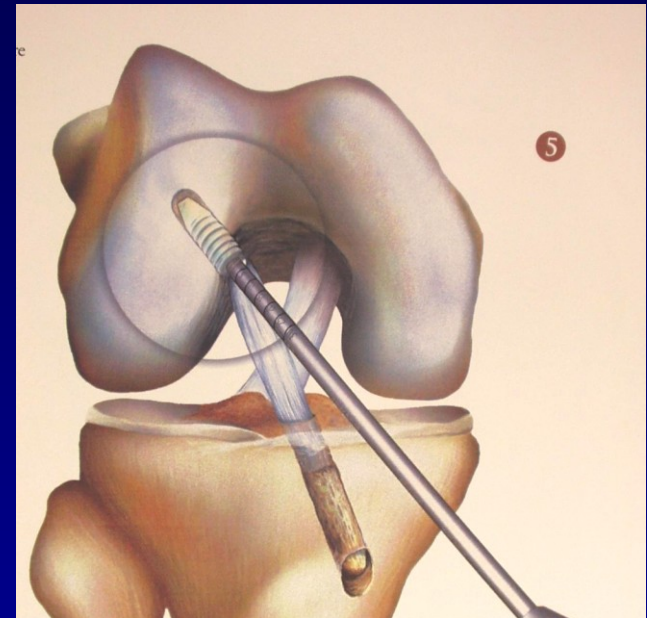
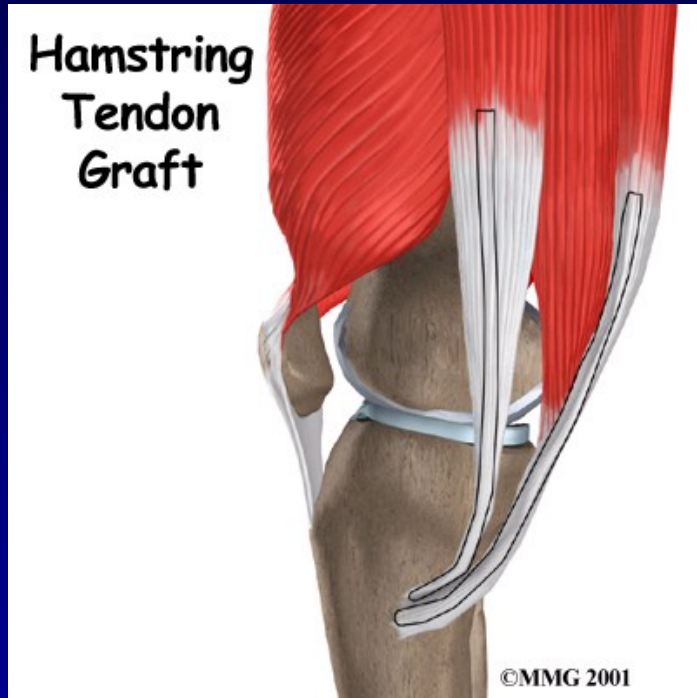
- Bone-Tendon-Bone



Press fit technique

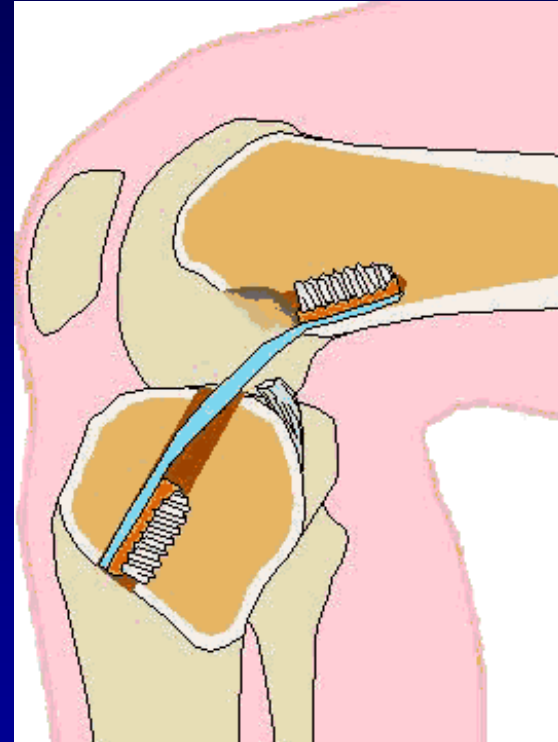
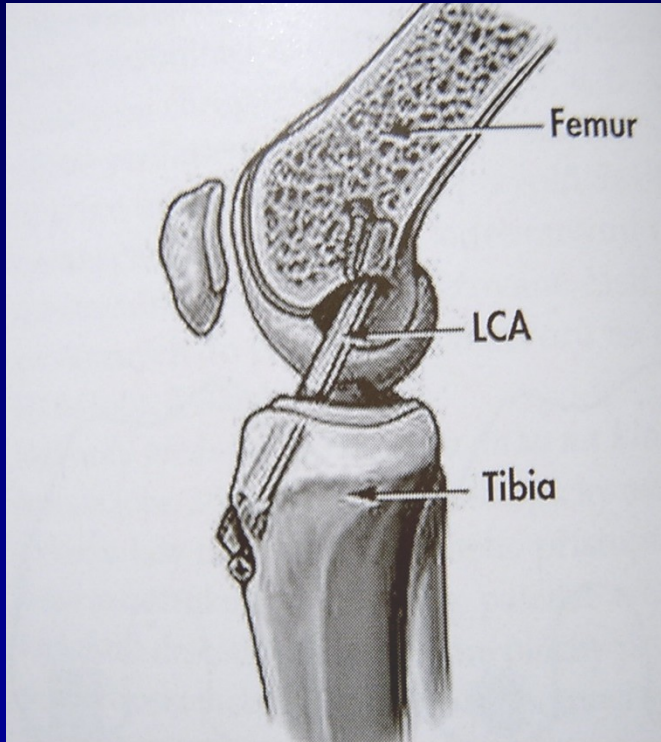
Hamstrings

(m. semitendinosus + m. gracilis)

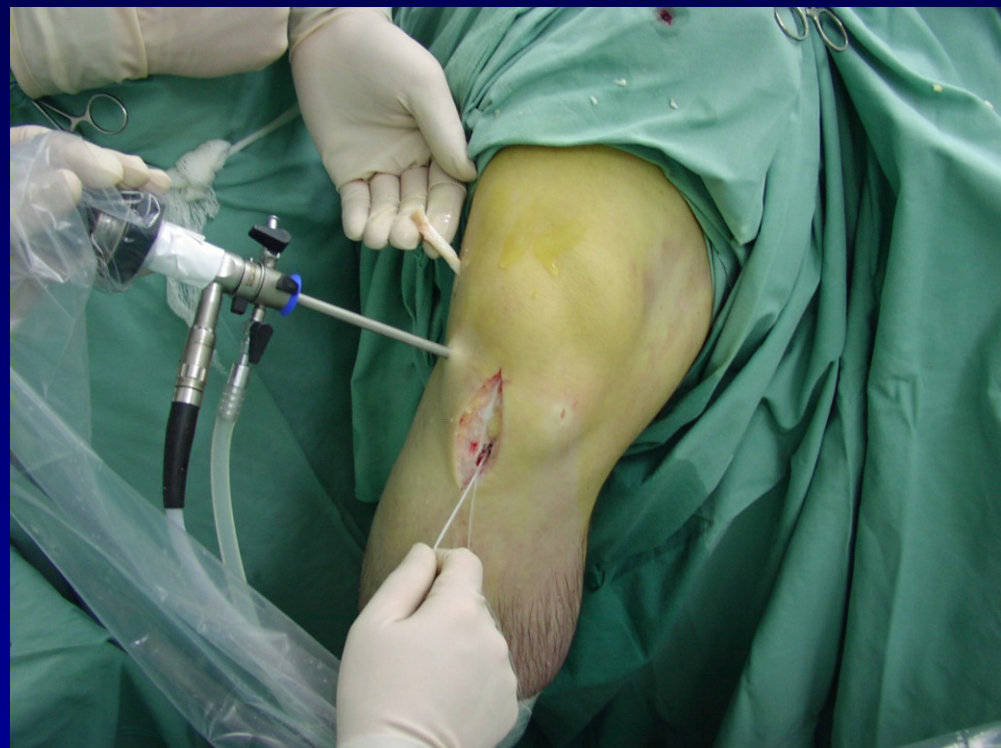
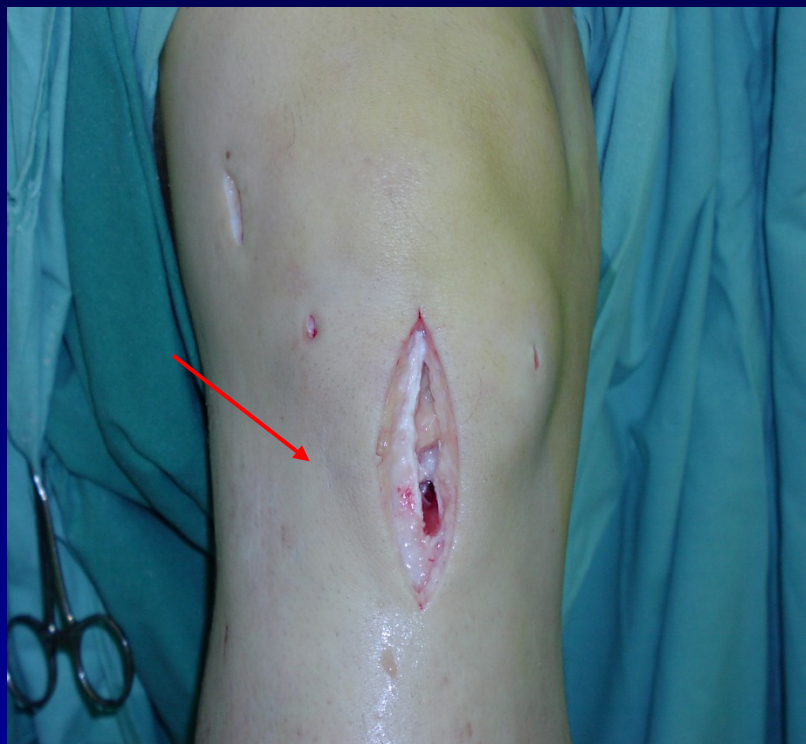
Fixation by screws

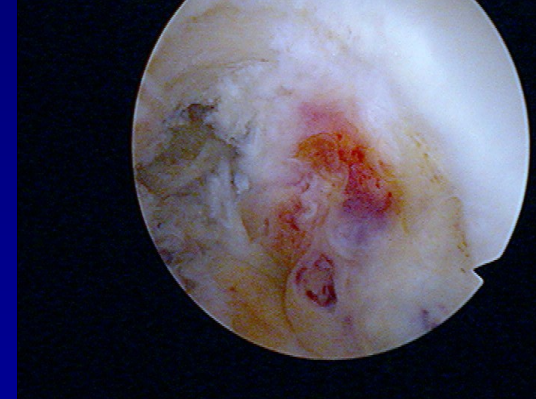
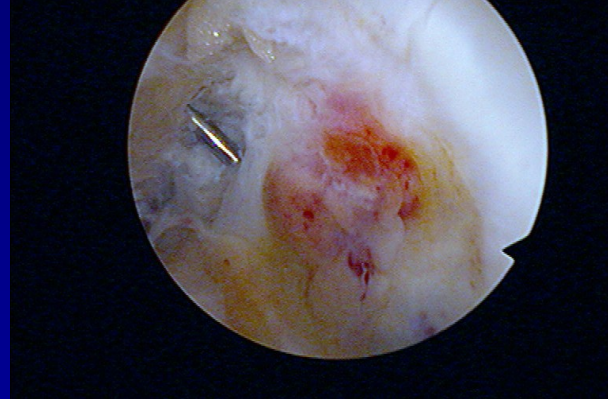
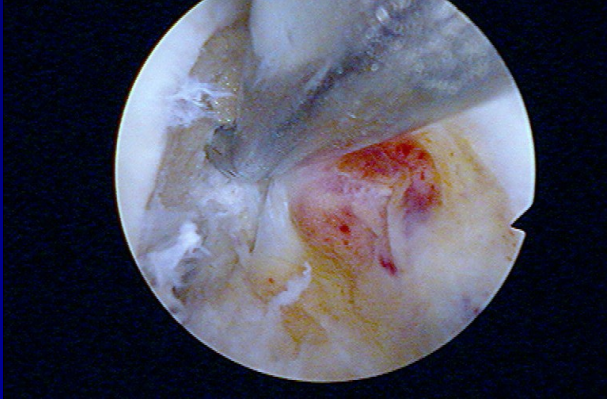
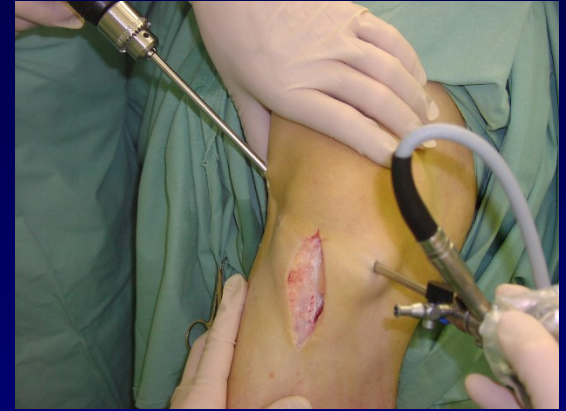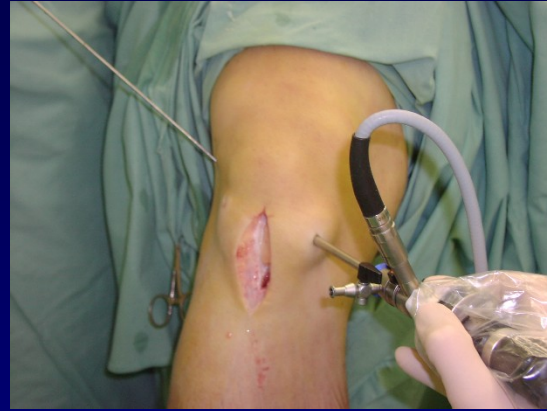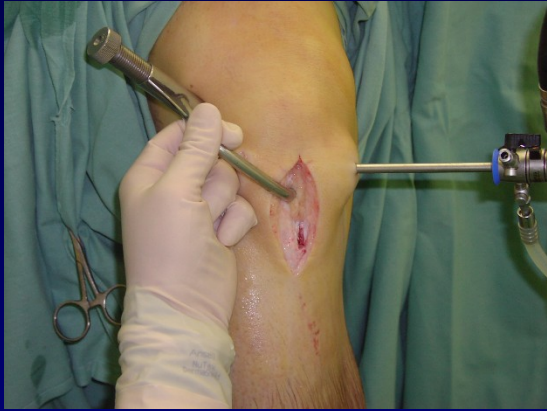Technique



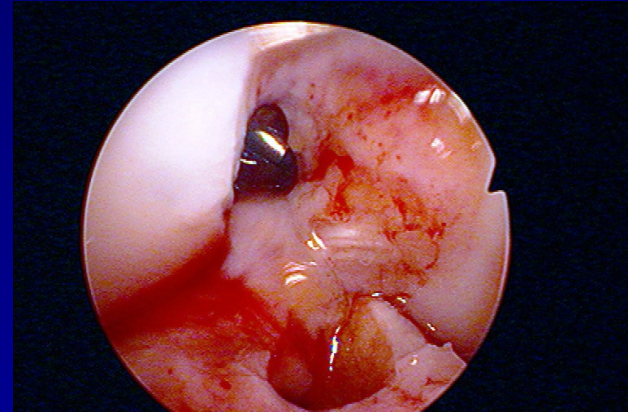
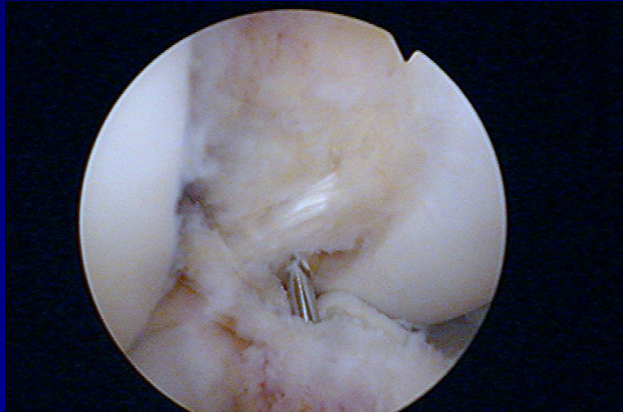
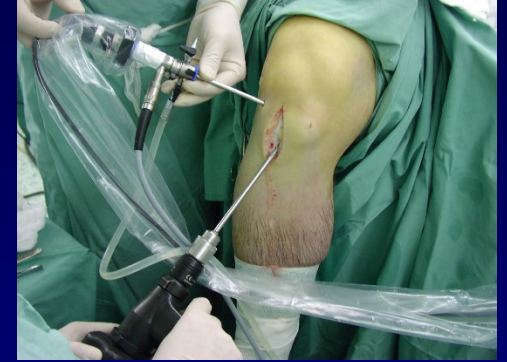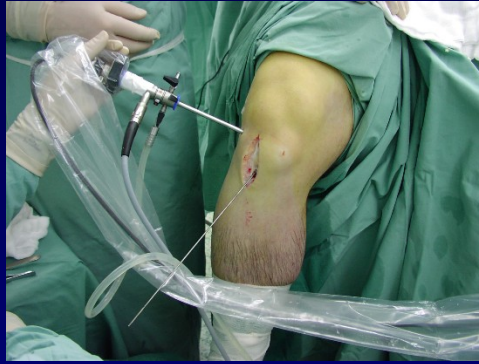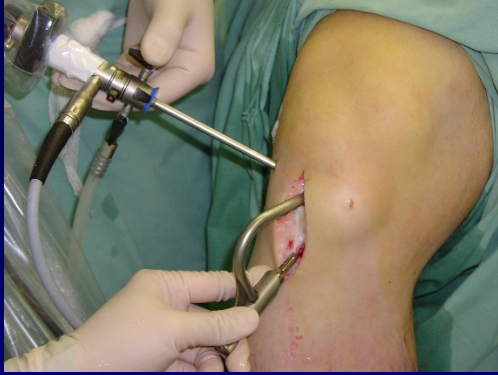ACL plasty- press fit technique



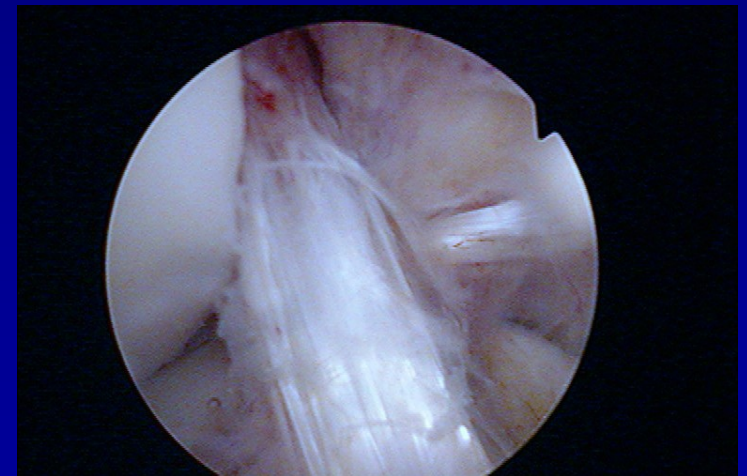
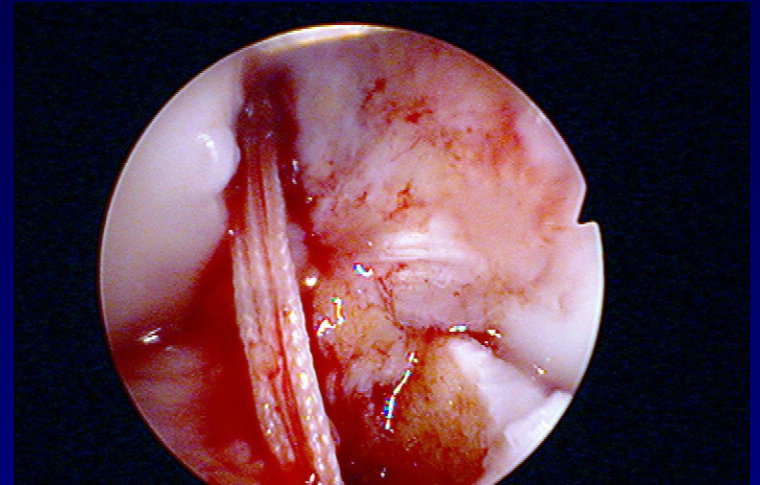
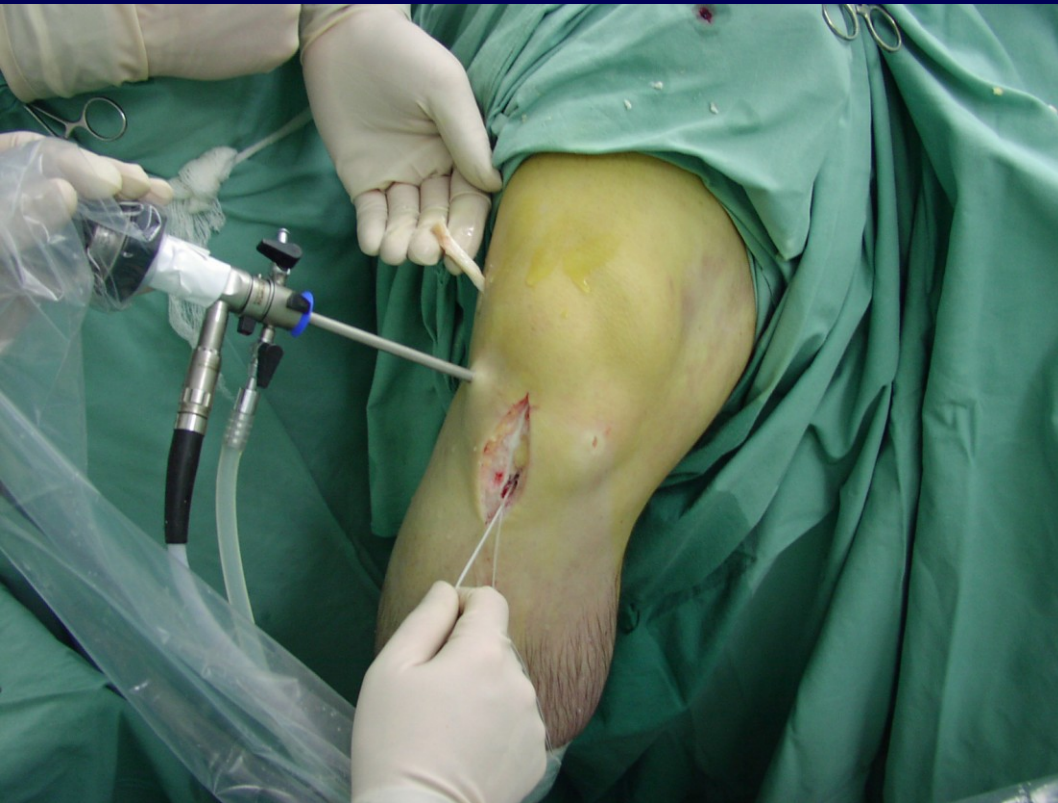Femoral canal



Tibial canal



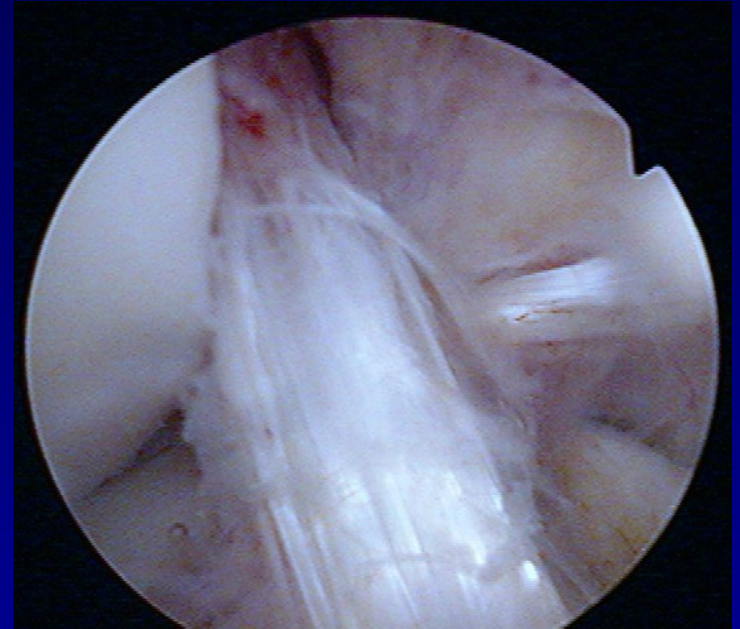
Tightening of the graft



Graft in situ

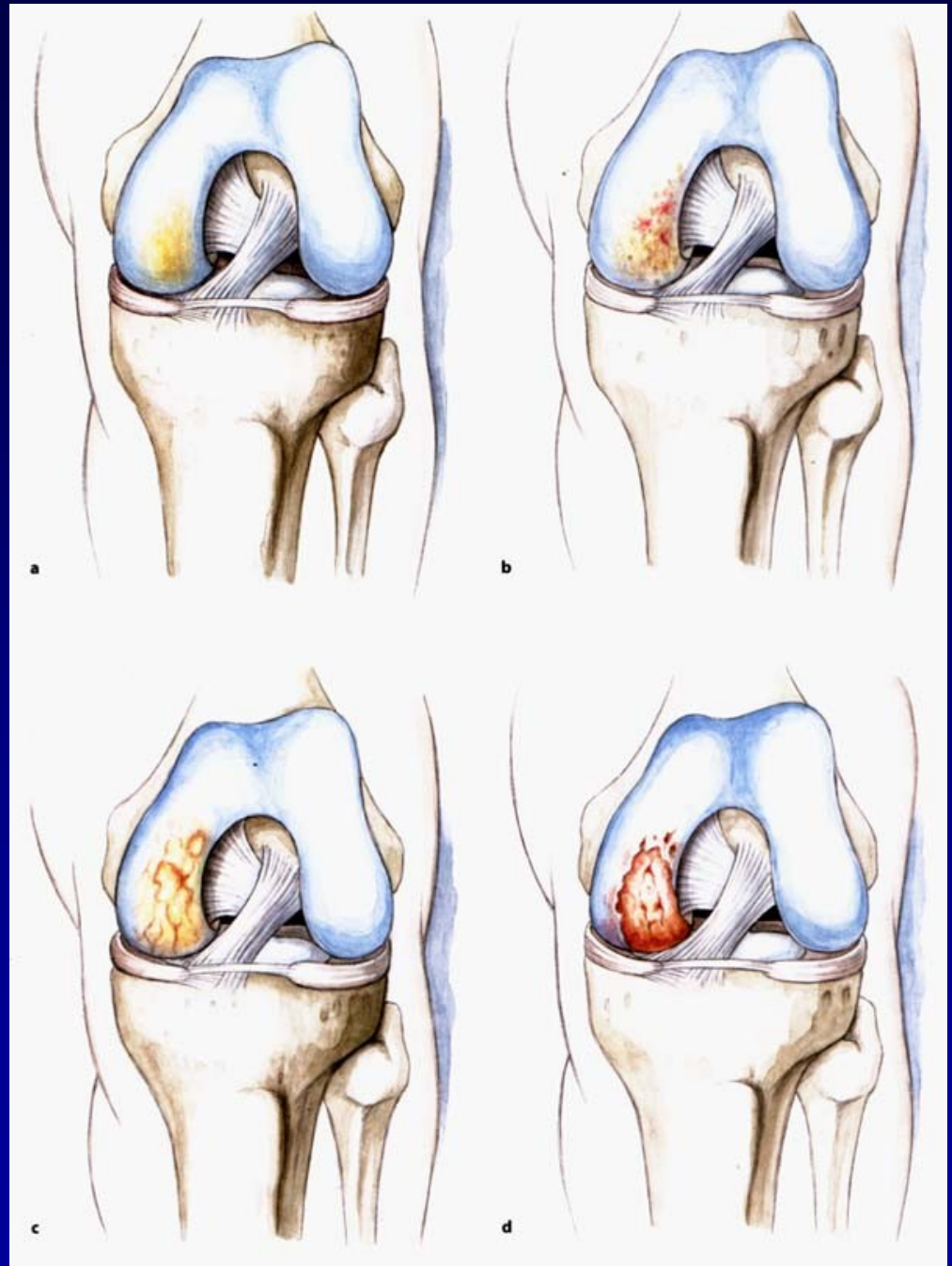
Aftertreatment

- 6 weeks orthosis
- Weight bearing after 6 weeks
- Sports activity after 9 months

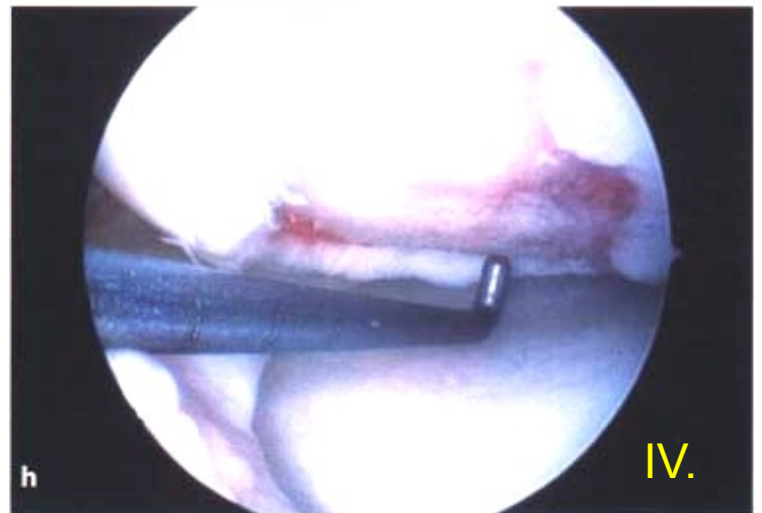
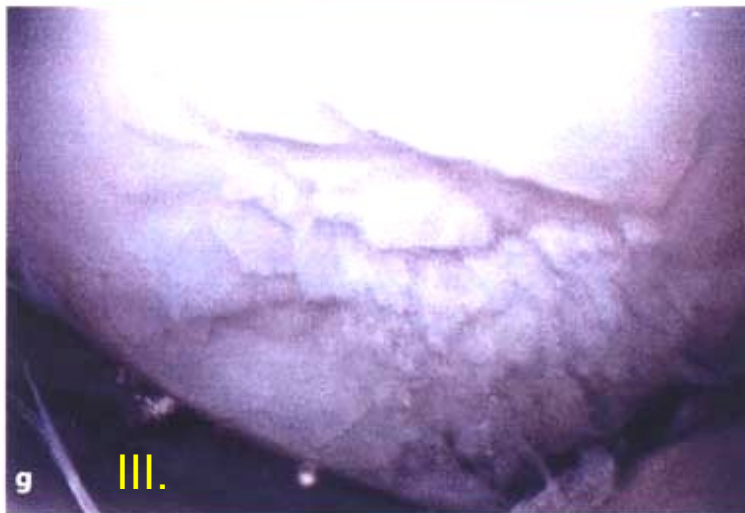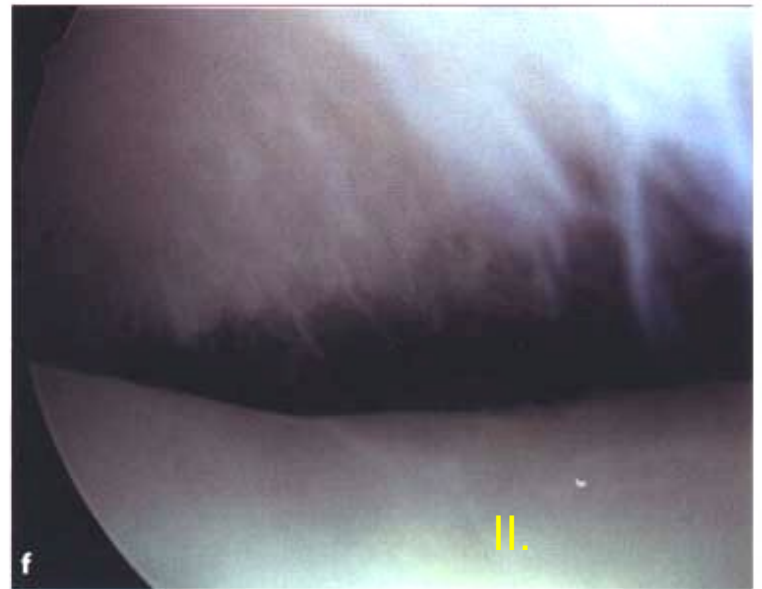
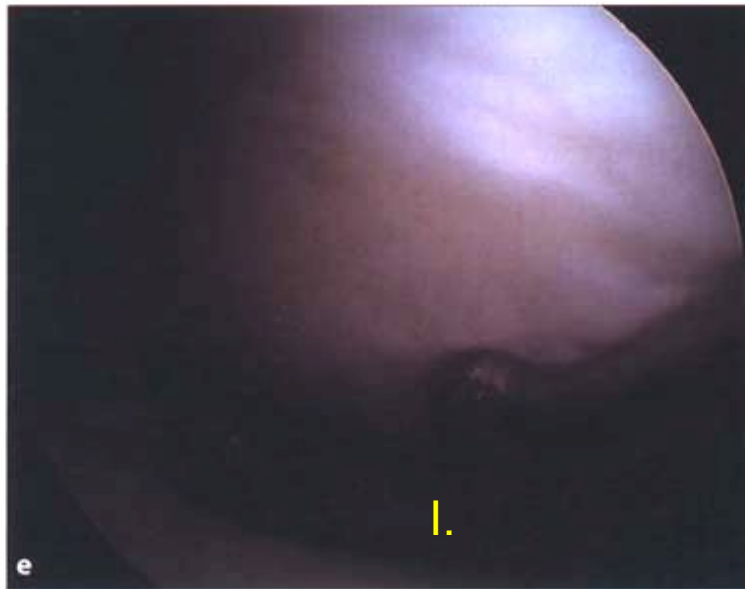


Chondropathy

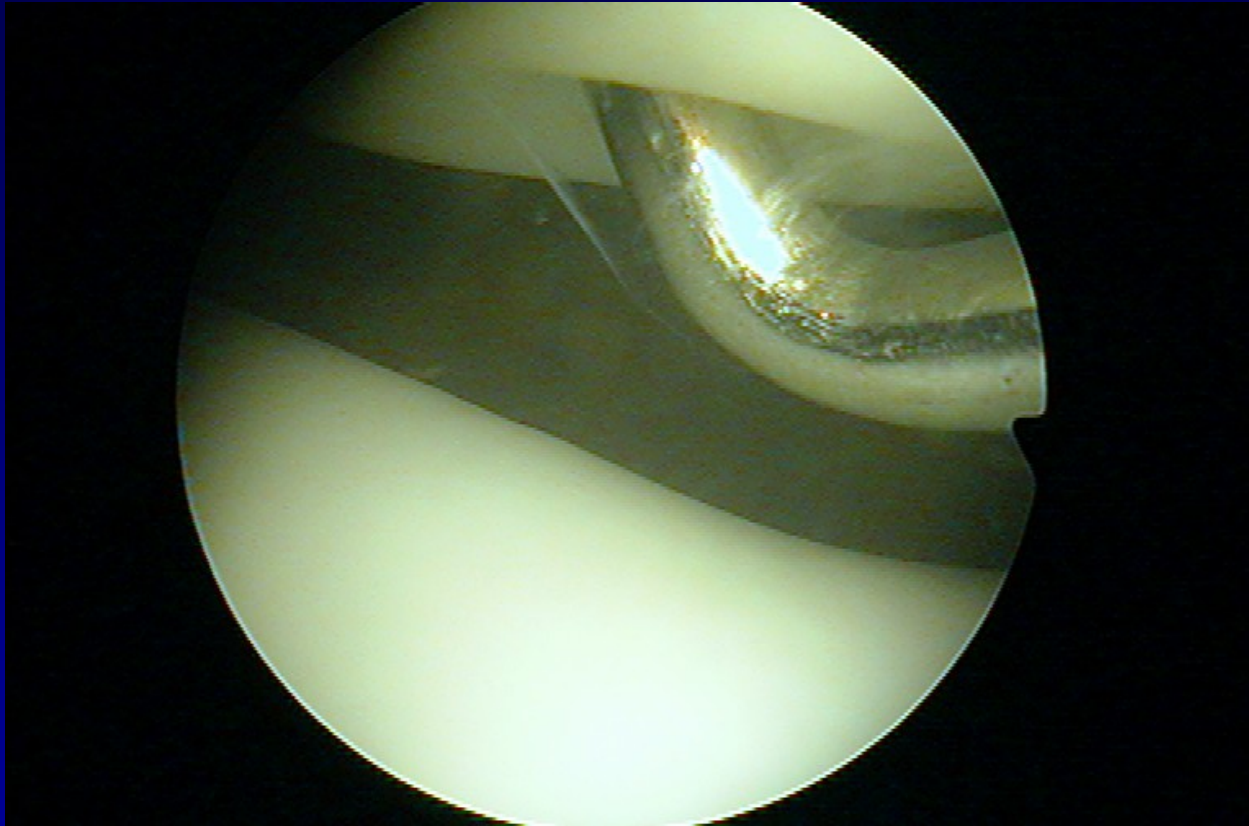
Outerbridge. H.K.



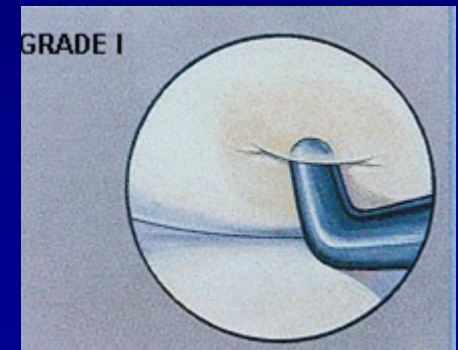
Chondropathy



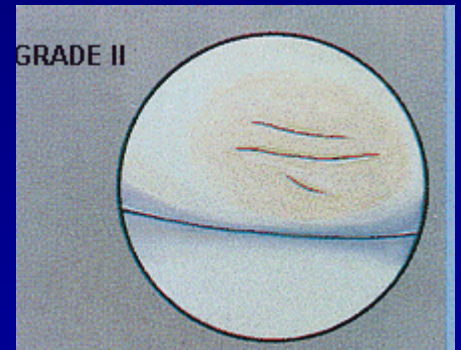
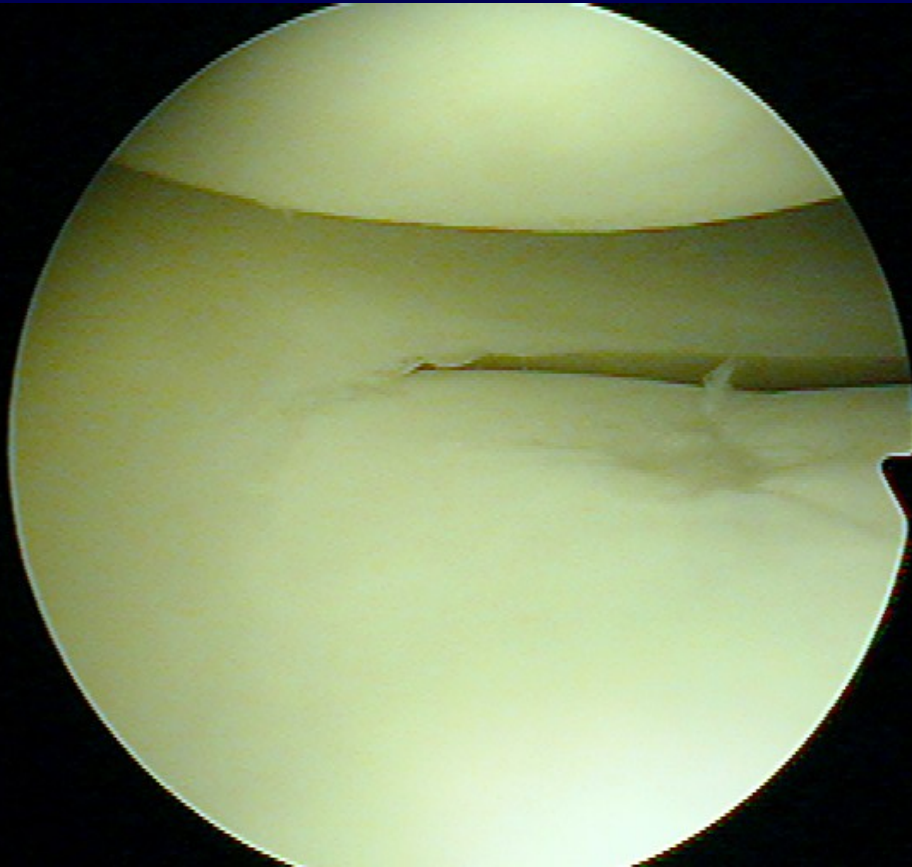
Chondropathy I. st.



Soft cartilage

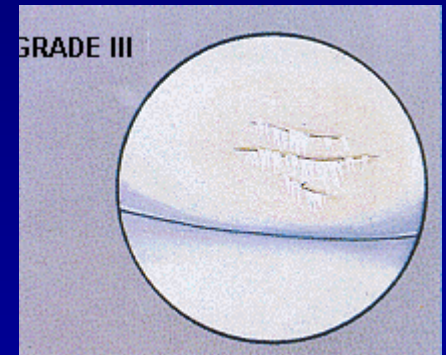
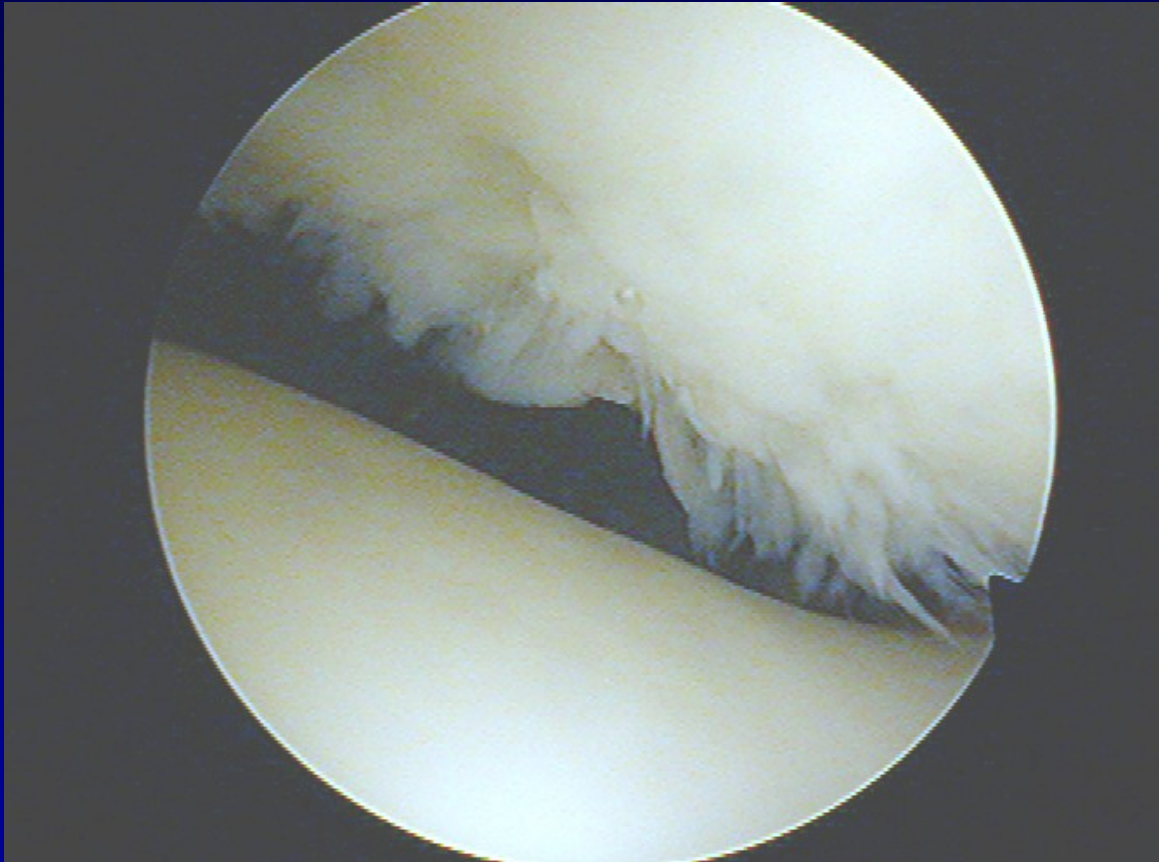


Chondropathy II. st.



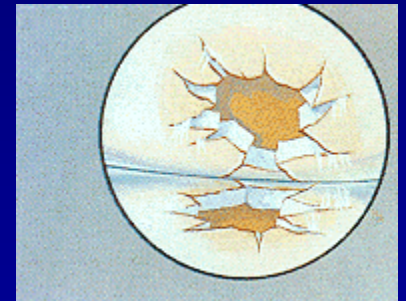
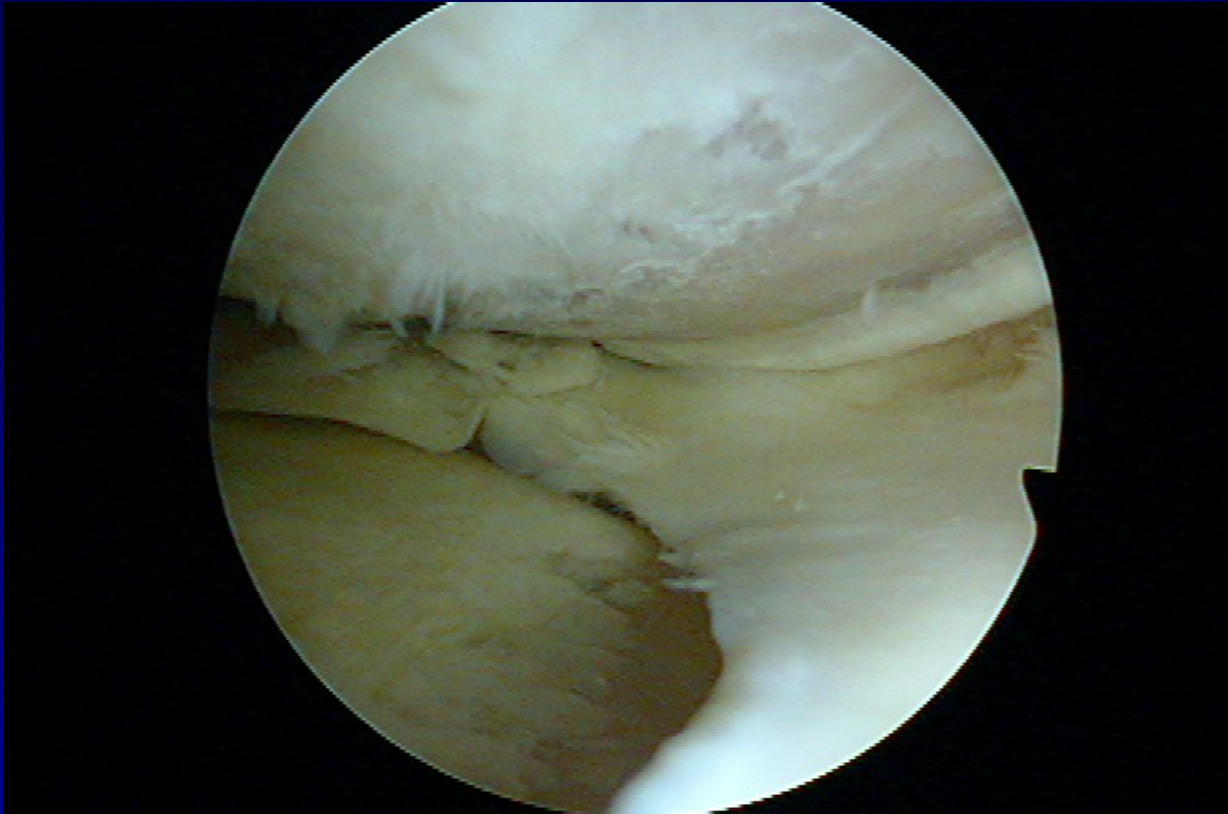
Fissures in the cartilage

Chondropathy III. st.



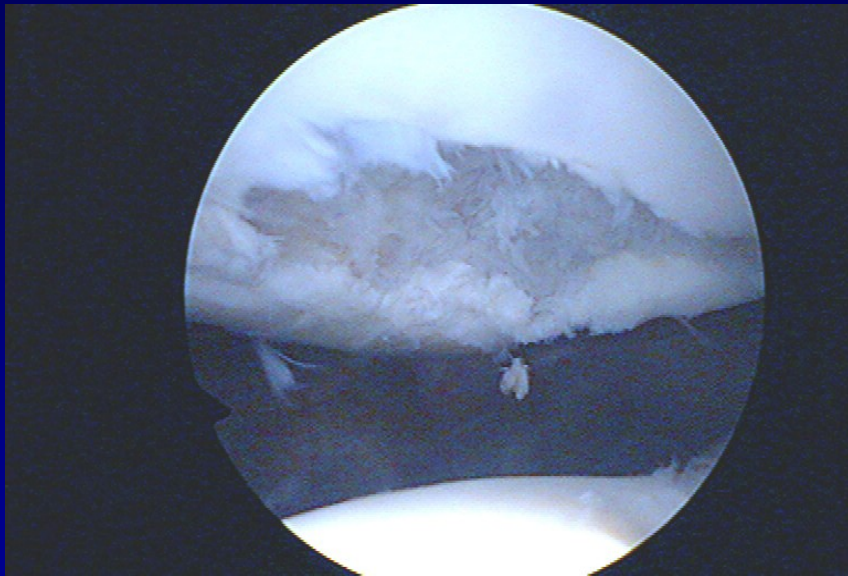
Fibrillation- „ crab meet“

Chondropathy IV. st.

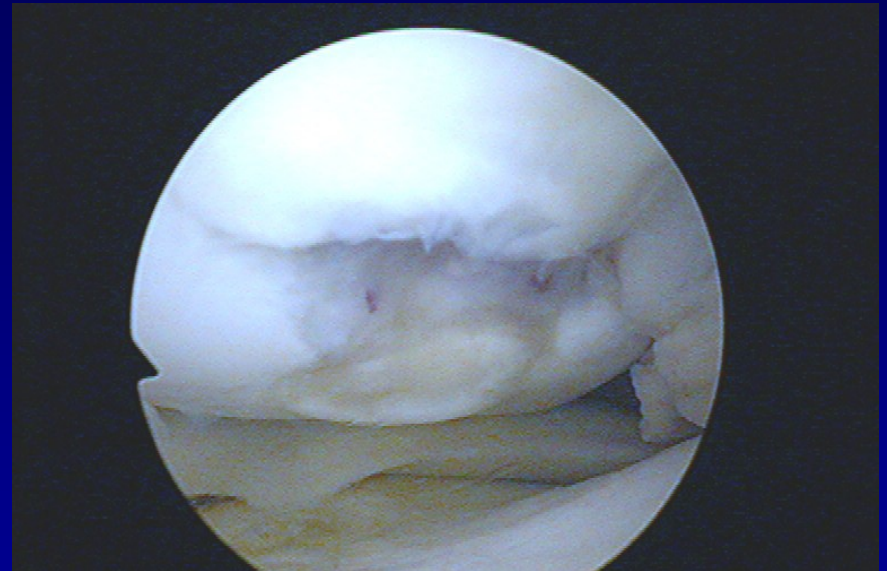


Defects to subchondral bone

Defects of cartilage

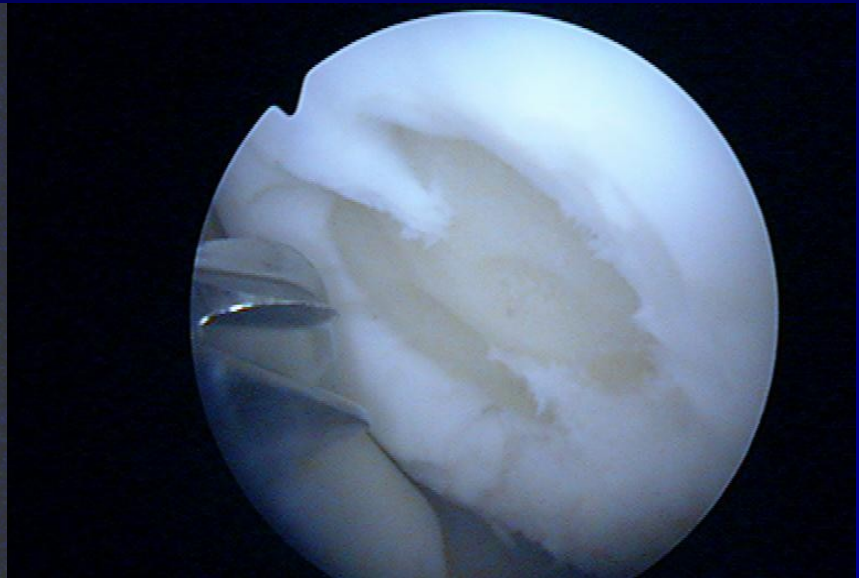
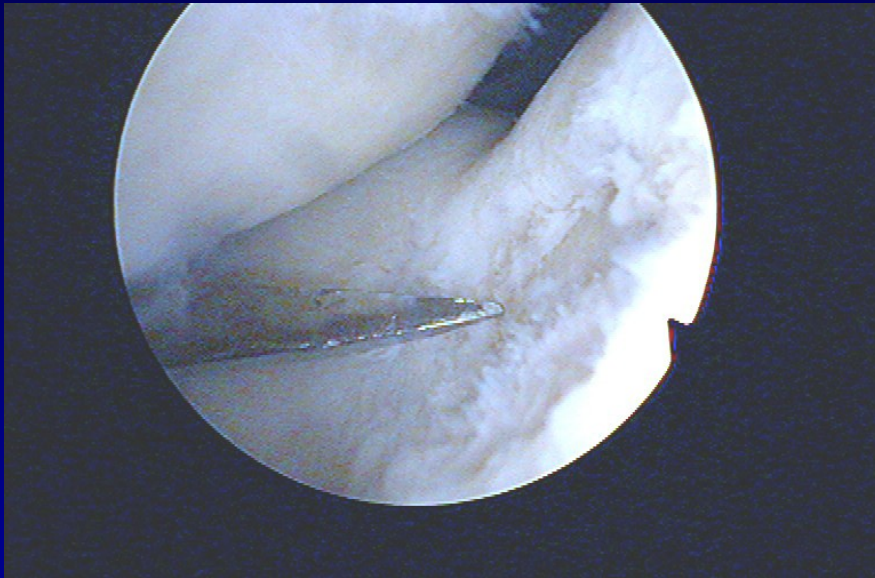


Patella



Medial condyle

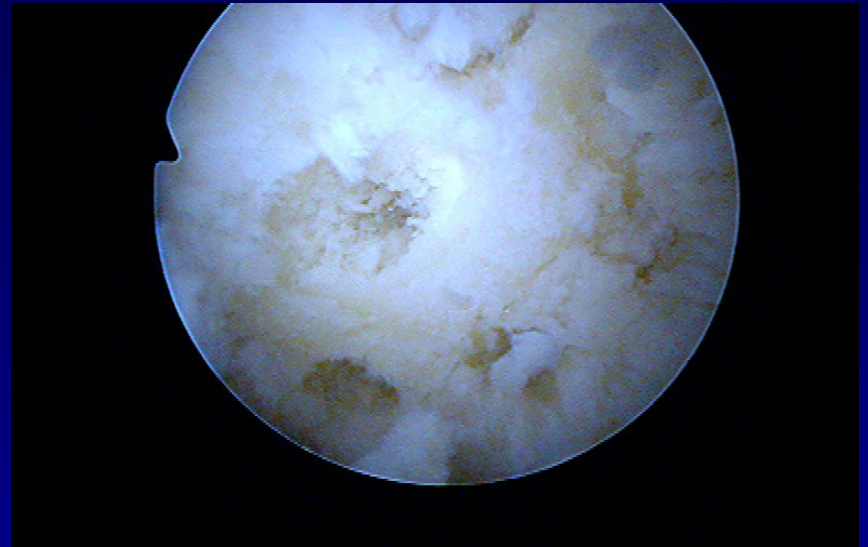
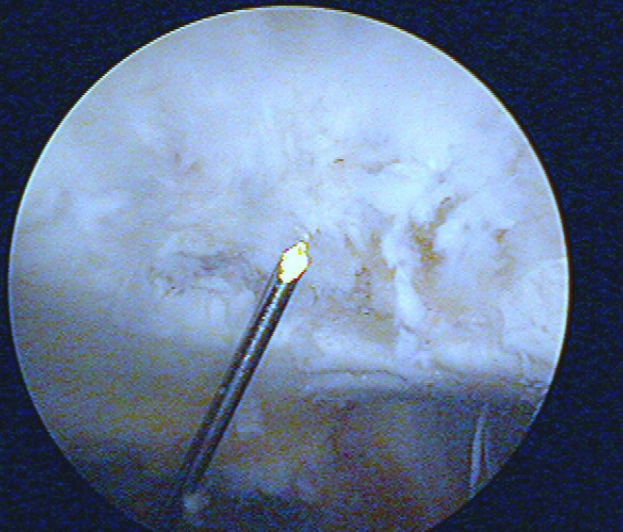
Shaving and drilling



-

-

Drilling

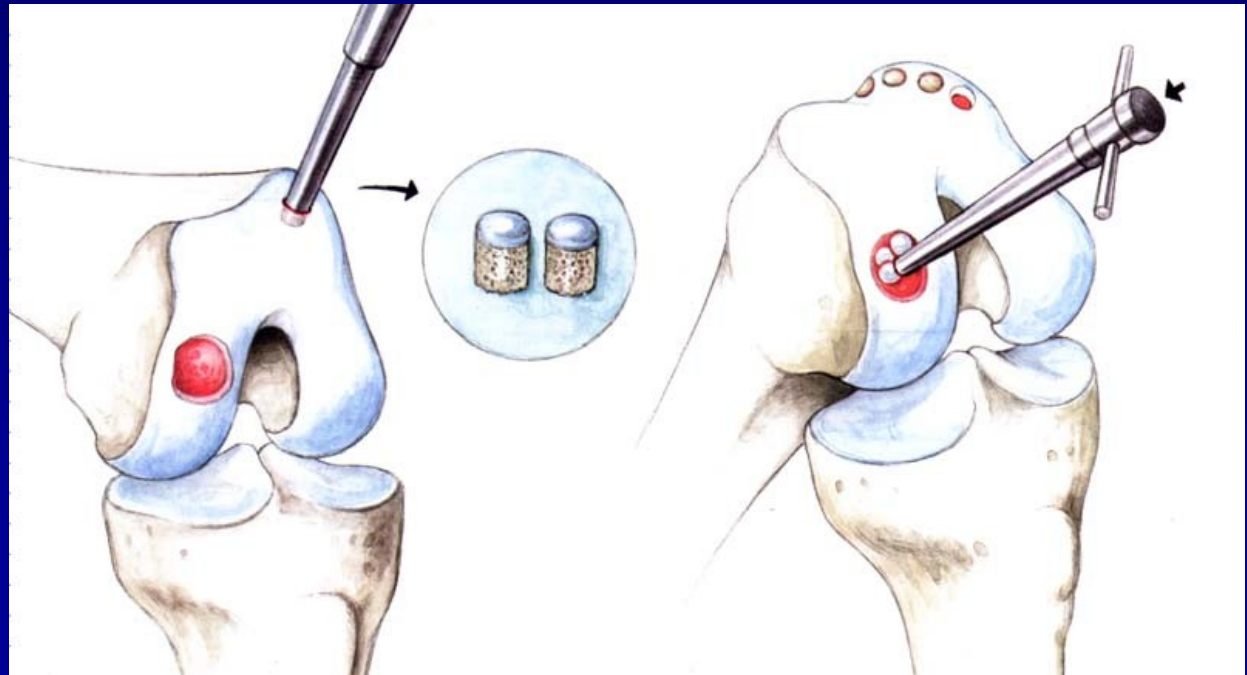


-

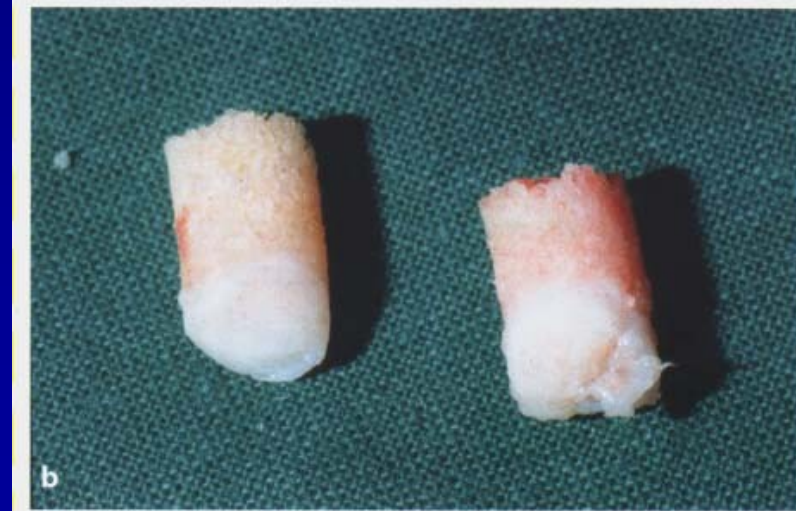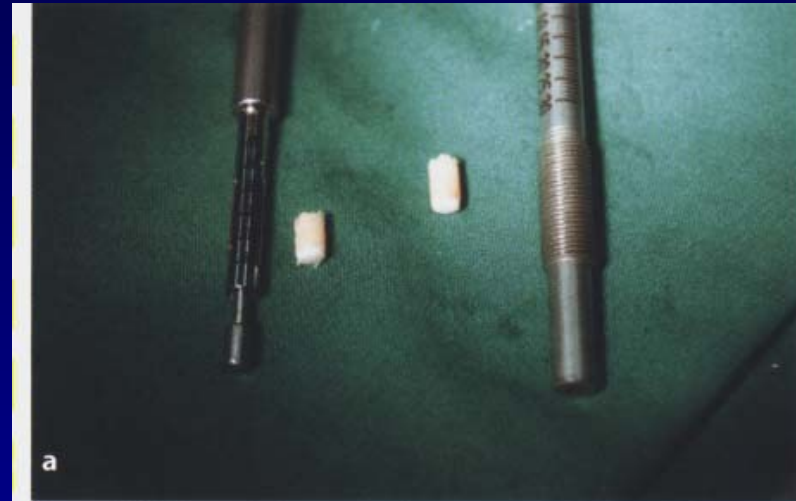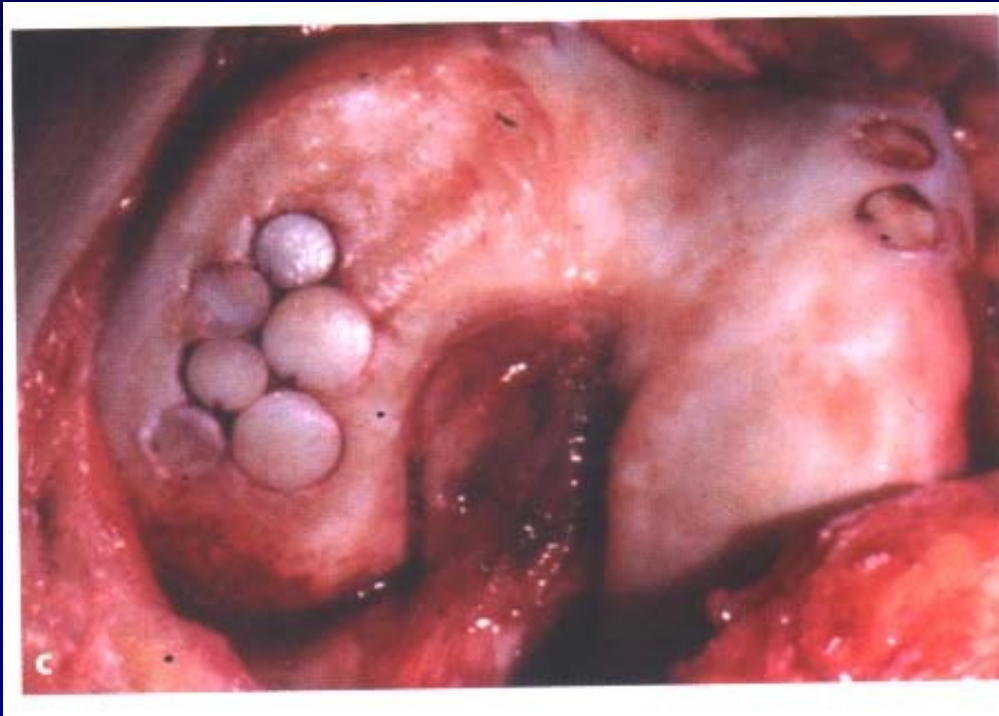Osteochondral autograft transfer- OAT Mosaicplasty

Hangody, L., 1992

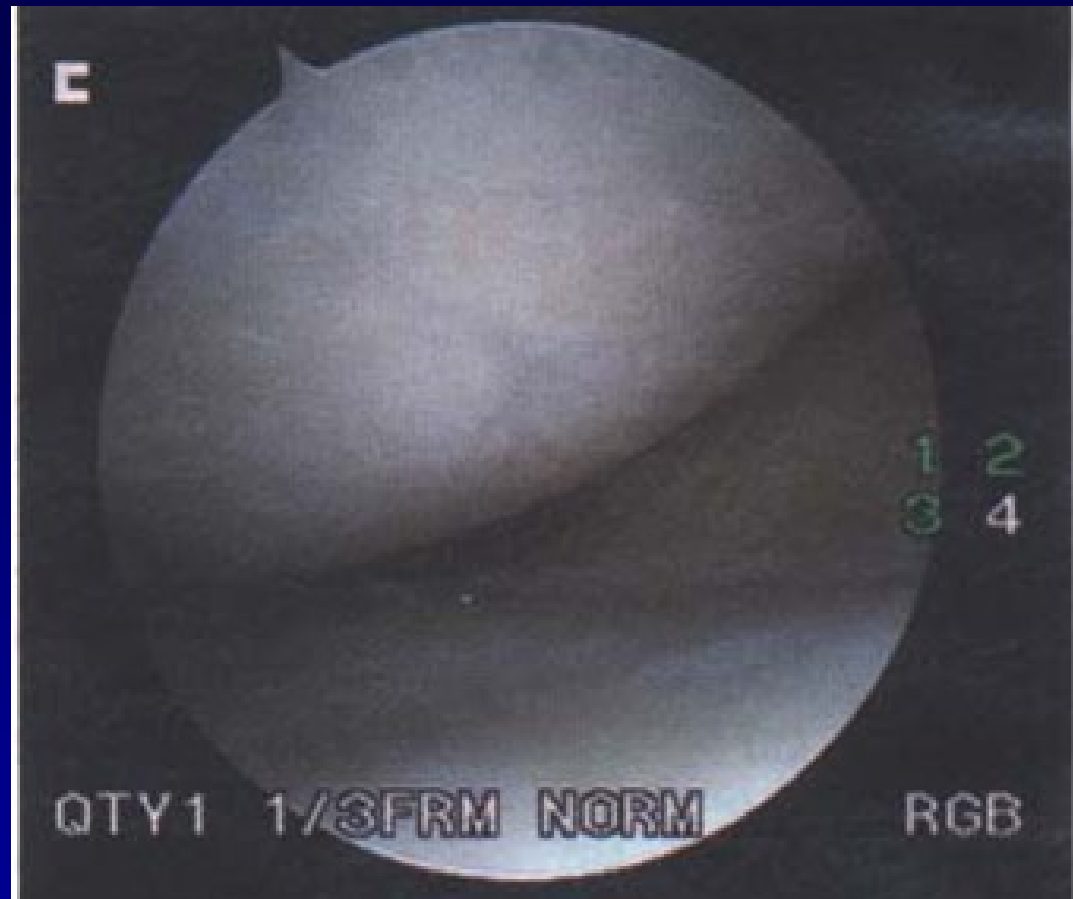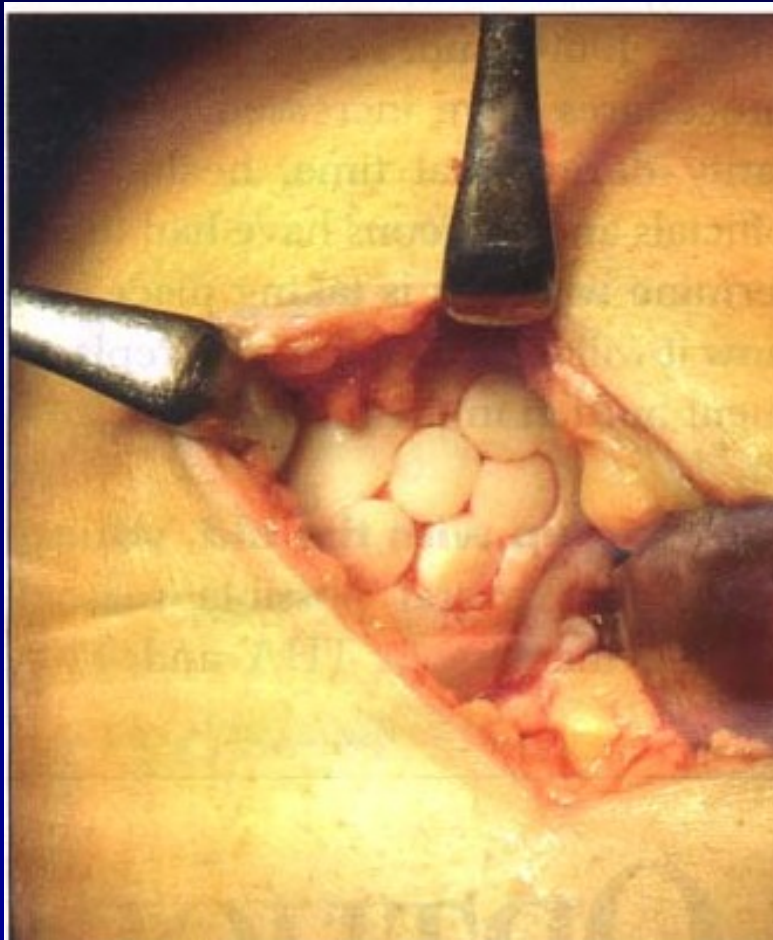
Defects up to 2 - 4 cm²



Osteochondral autograft transfer- OAT



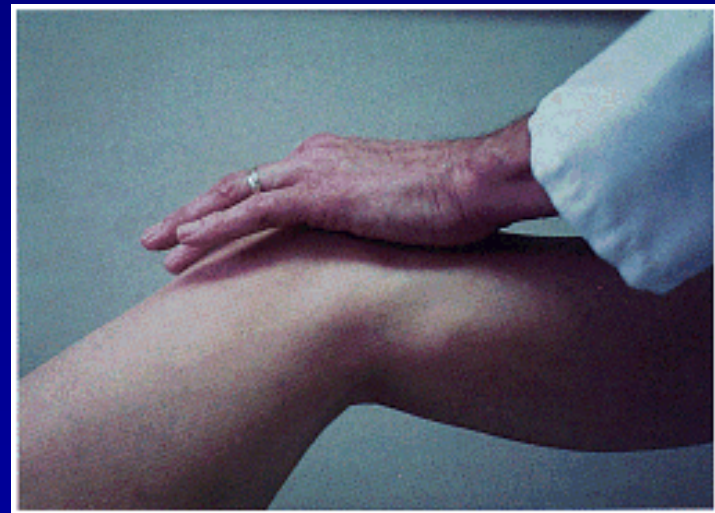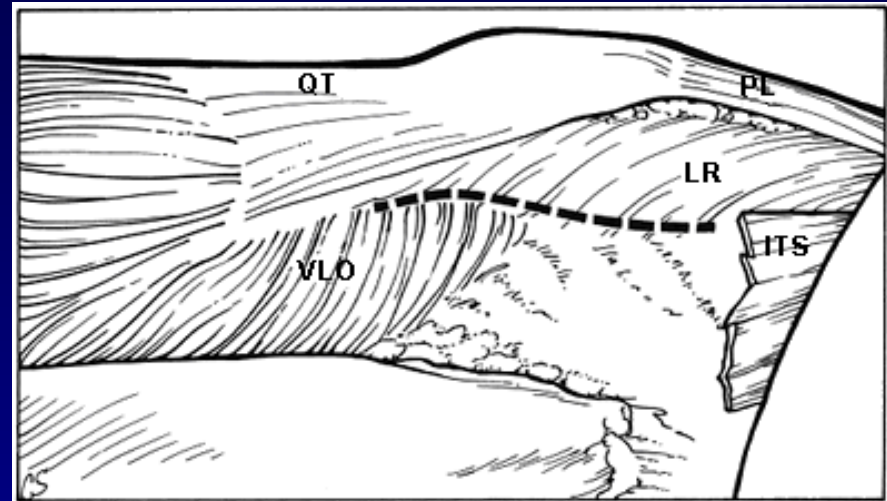
OAT



4 years after surgery

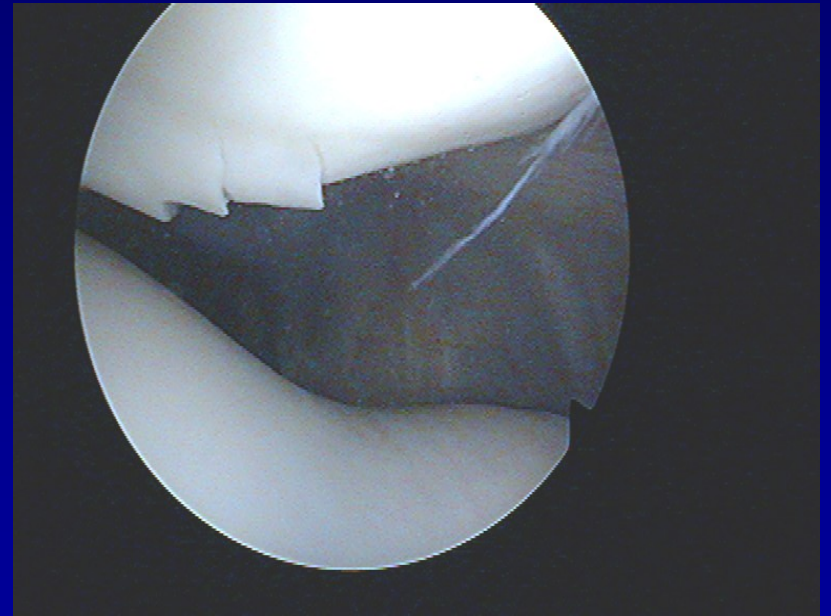
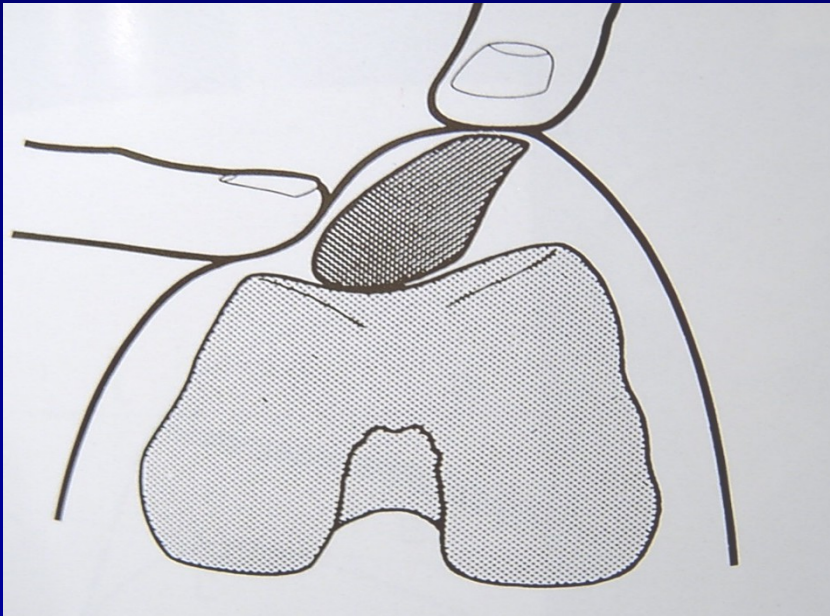
Patella

- Chondropathy
- Subluxation
- Dislocation



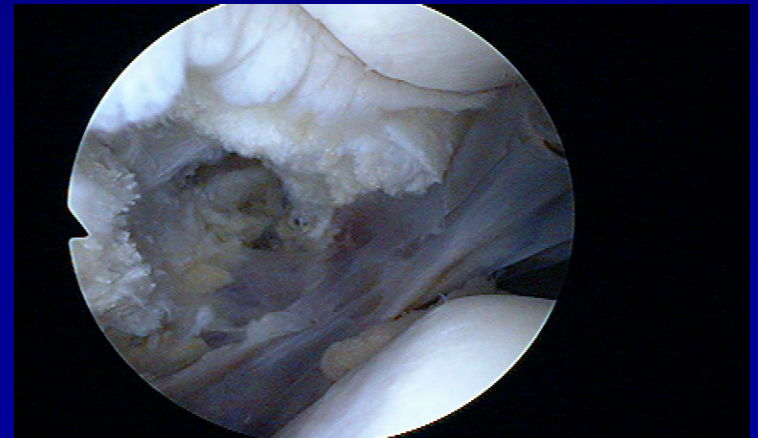
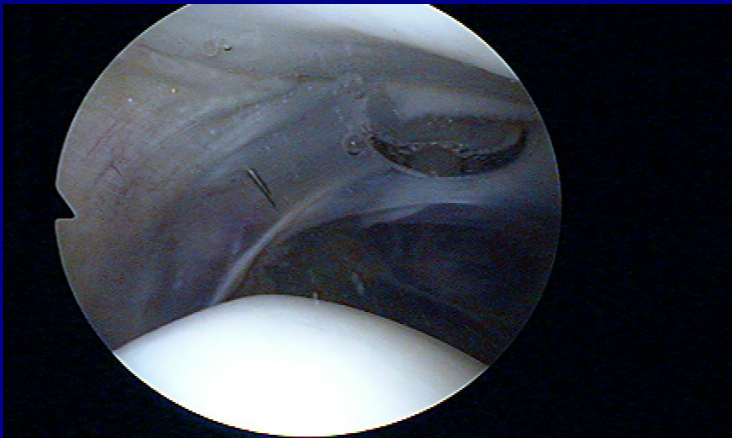
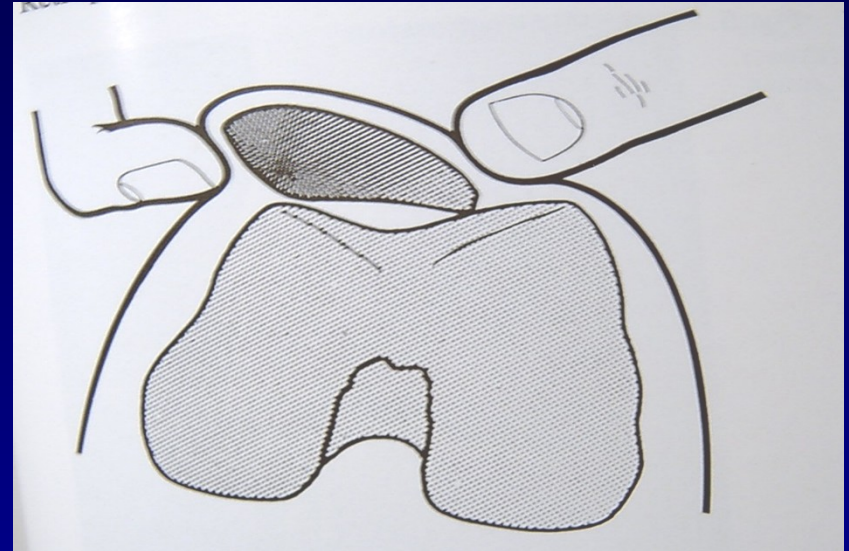
Chondropathy of the patella

Clinical symptoms

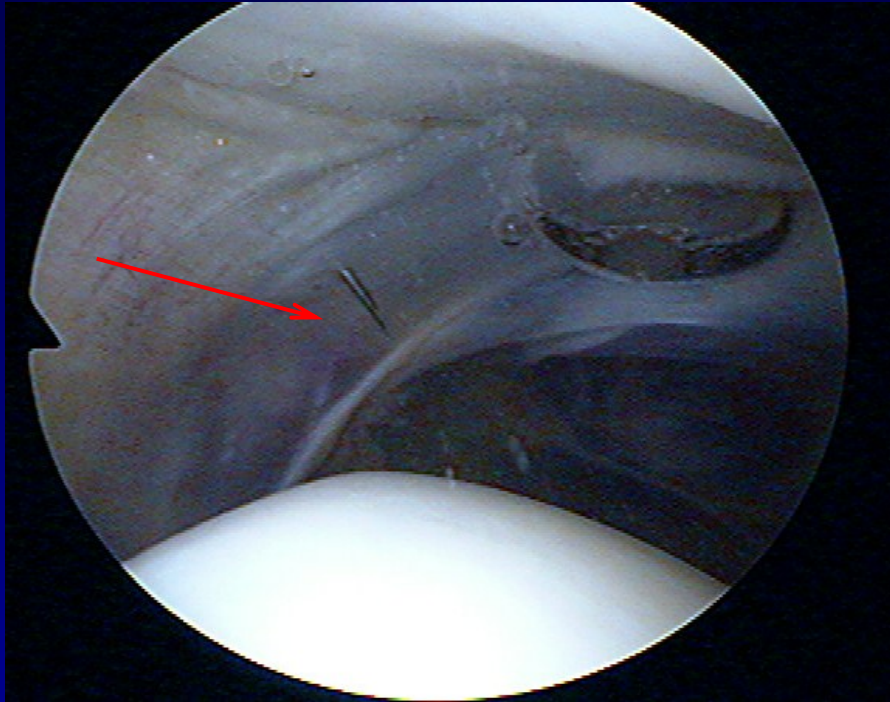


Chondropathy of the patella

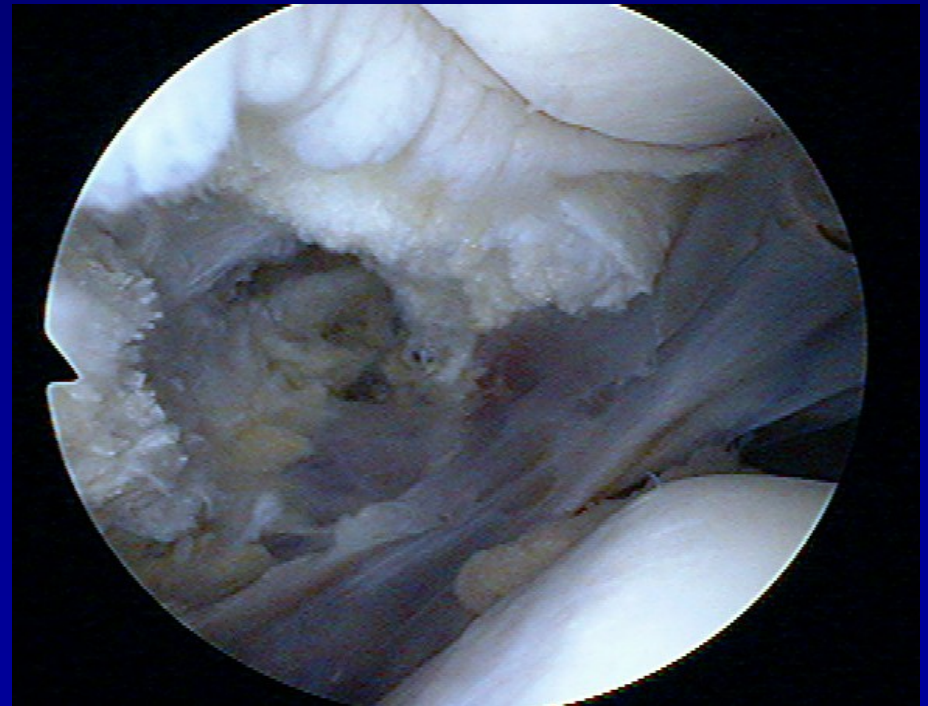- Lateral hyperpression
- Lateral release



Lateral release

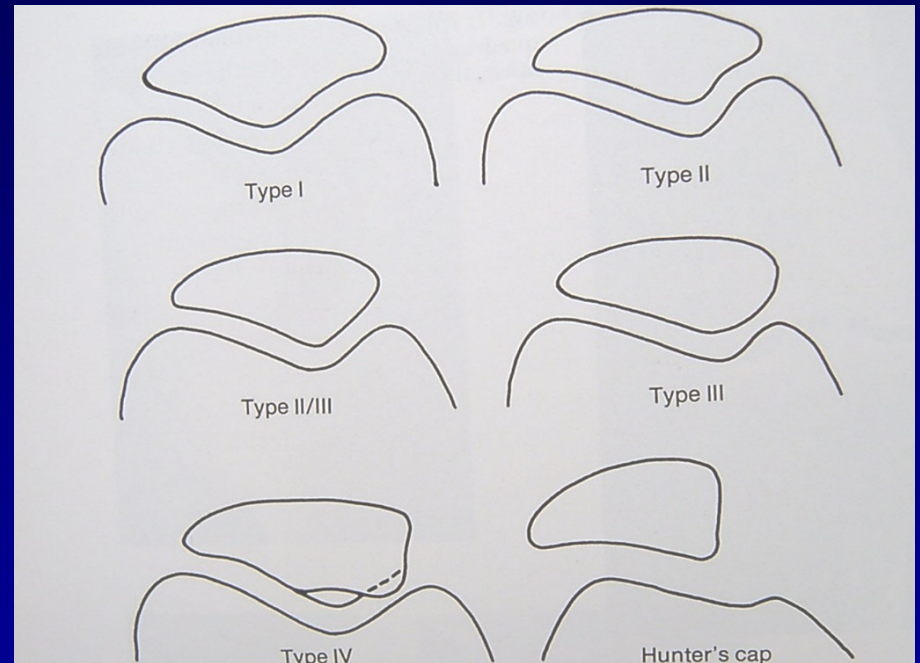


- Incision of lateral retinaculum



Traumatic dislocation of the patella

- Always laterally
- Conservative treatment
- Operative treatment

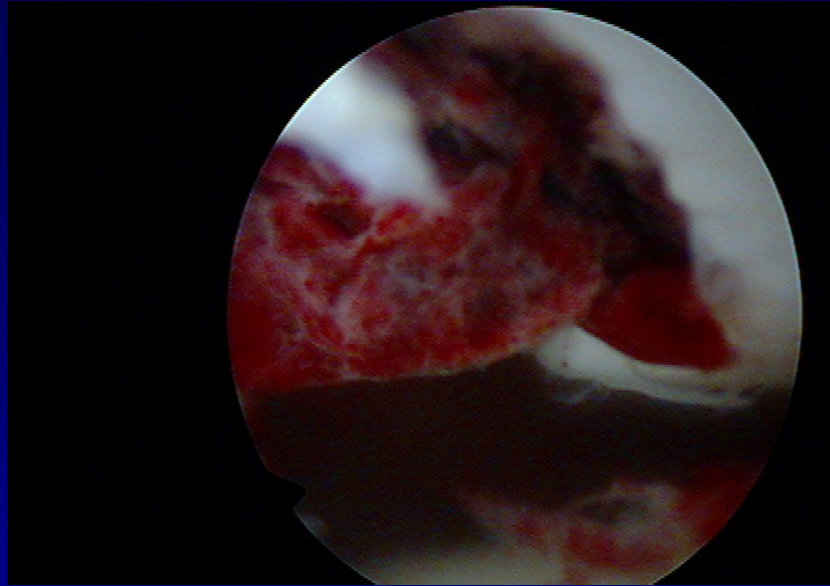


Types of patella

Recurrent dislocation of the patella

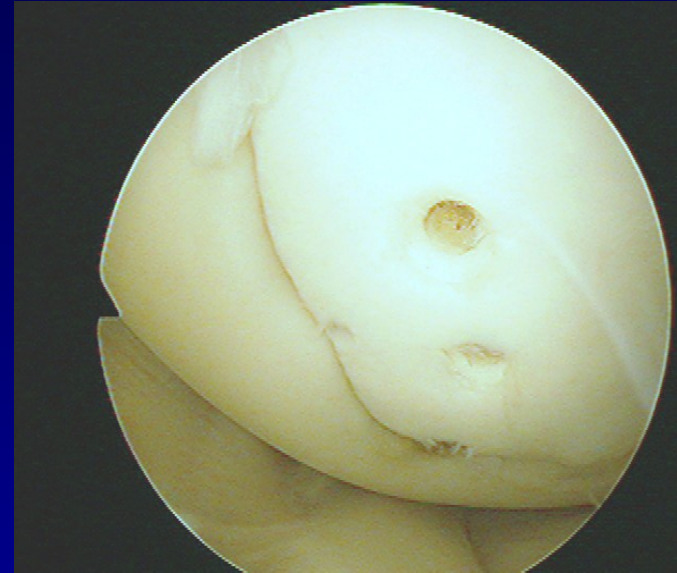
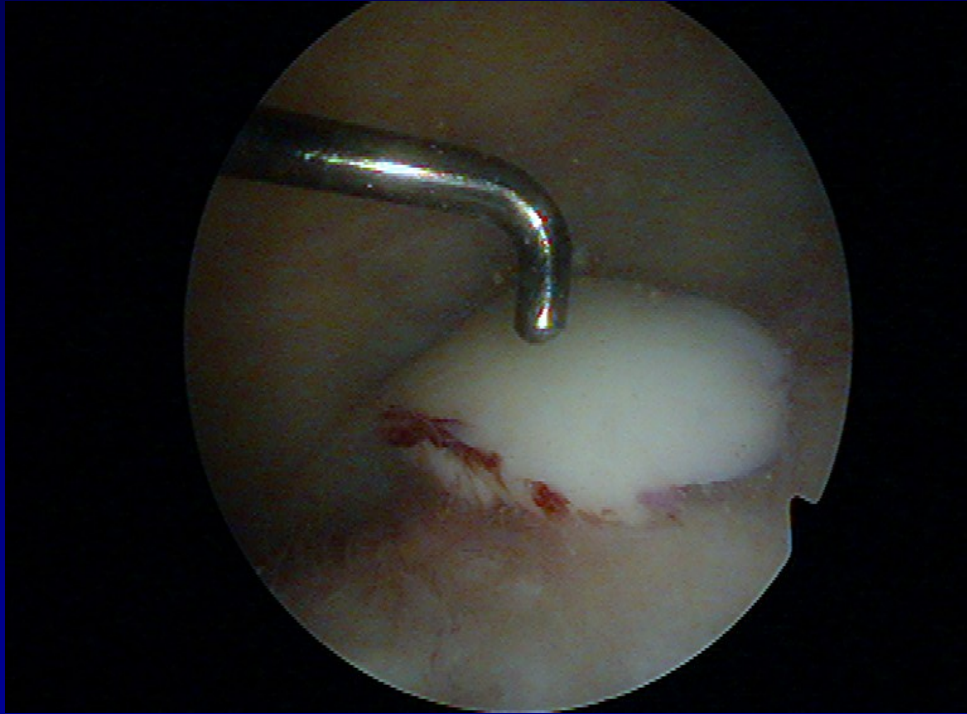
- posttraumatic
 - congenital
 - habitual
- ASK – lateral release + medial capsuloraphy
- Open surgery

Transchondral fracture



Removal of destroyed cartilage

Osteochondral fractures



Fixation by pins



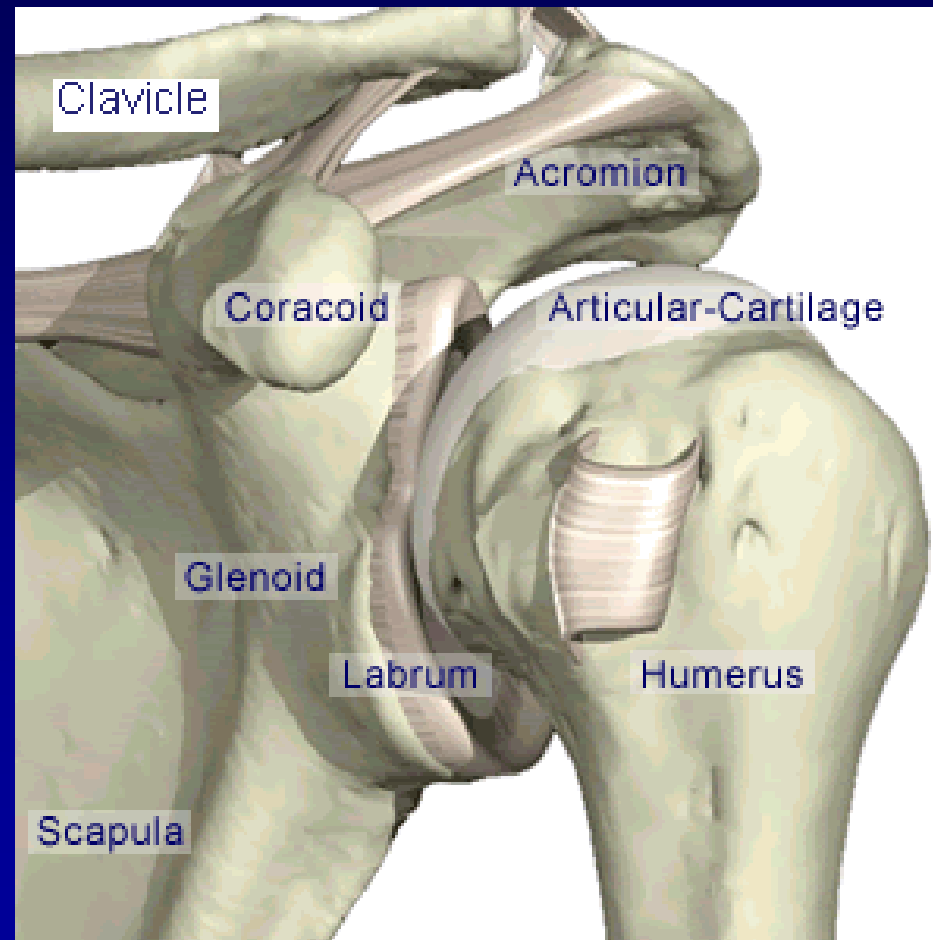
Arthroscopy of the shoulder

Subacromial decompression

Suture of rotator cuff

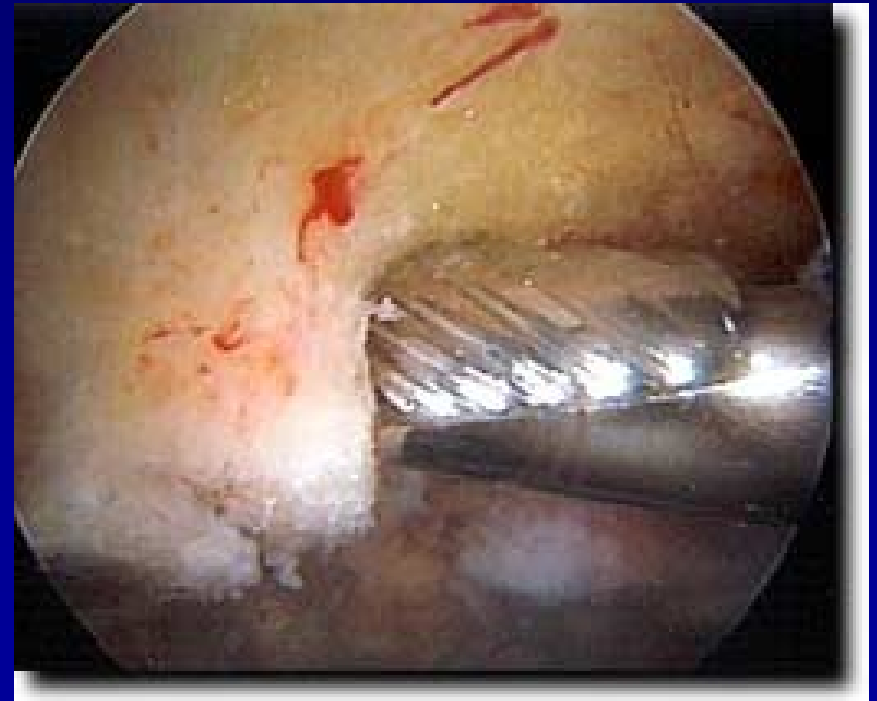
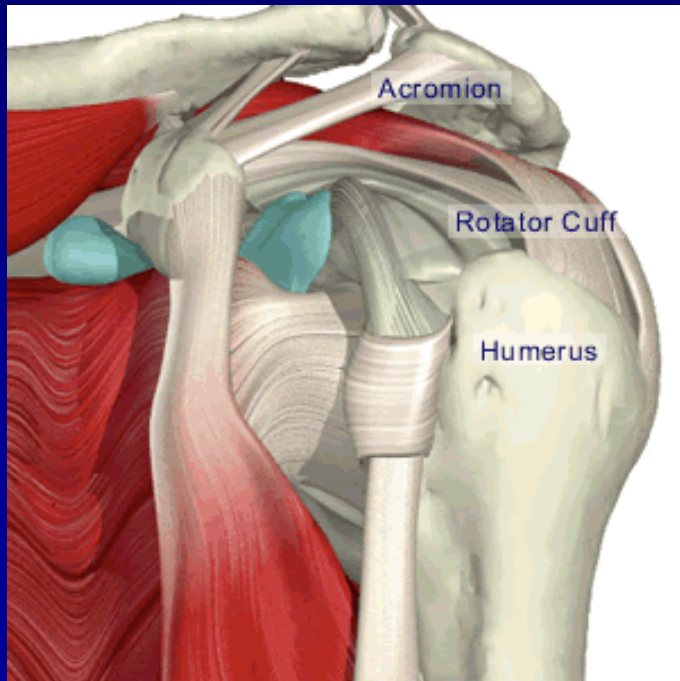
Chronic instability

SLAP lesion



ASAD – arthroscopic subacromial decompression

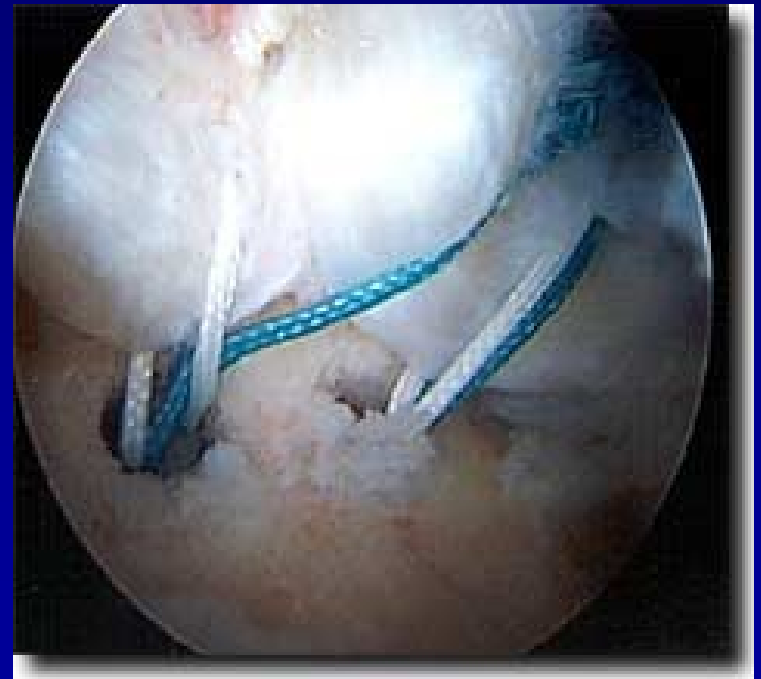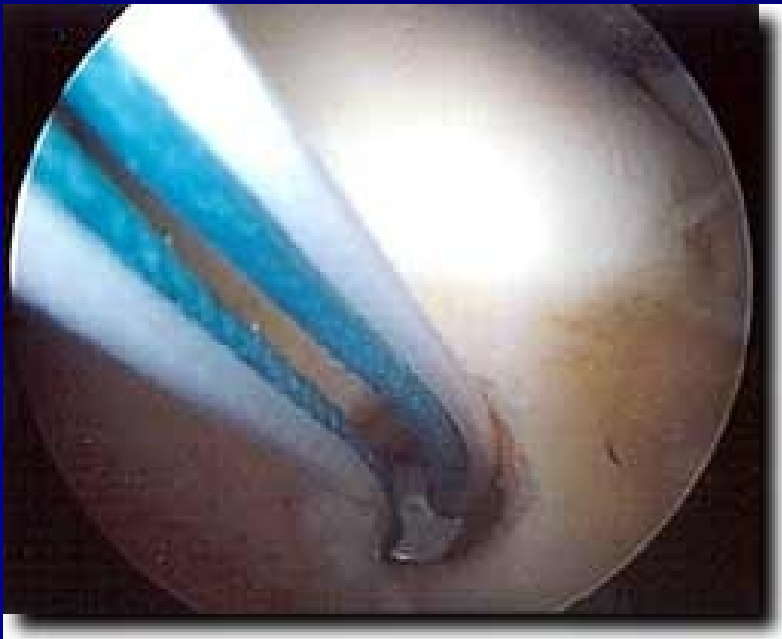- Removal of bursa
- Acromioplasty - shaver



Rupture of rotator cuff

Suture:

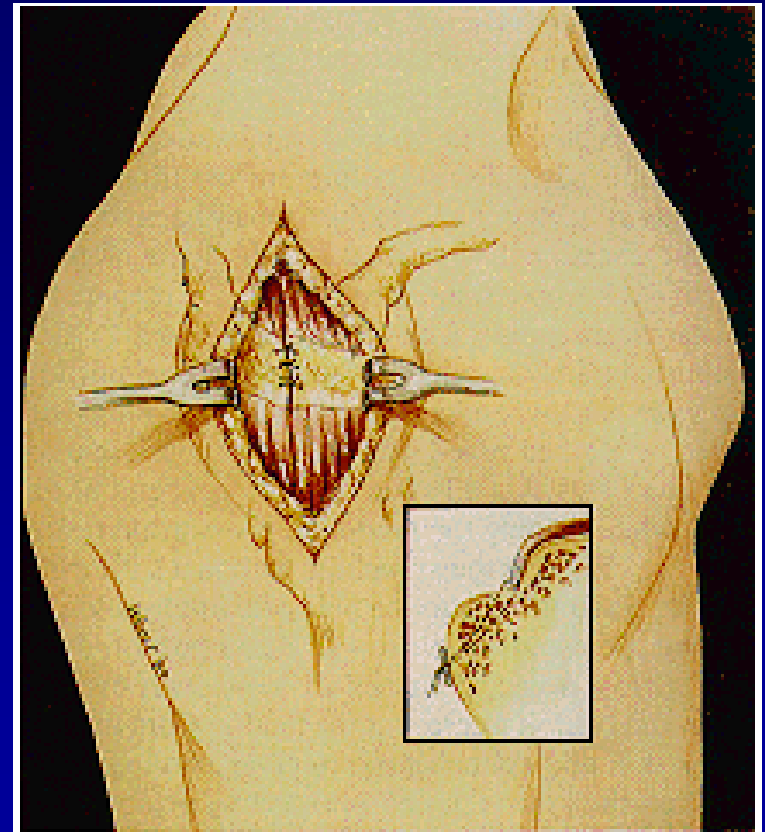
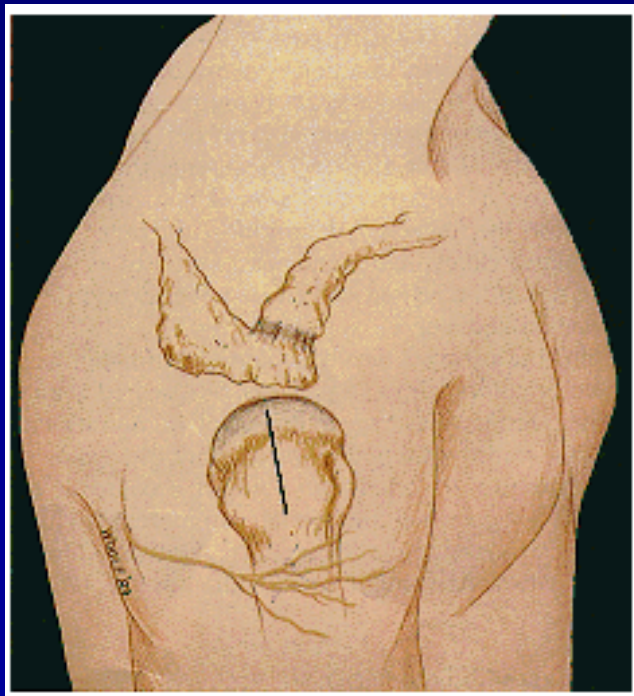
- arthroscopically



Rupture of rotator cuff

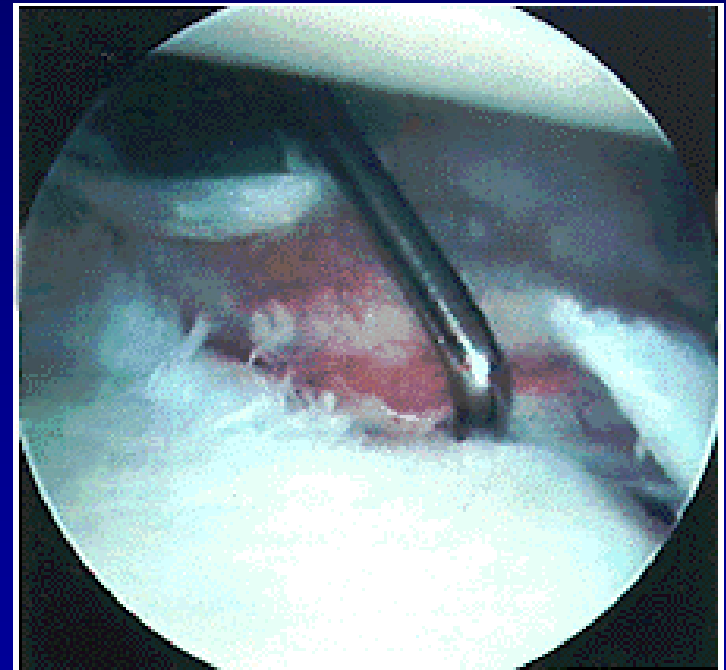
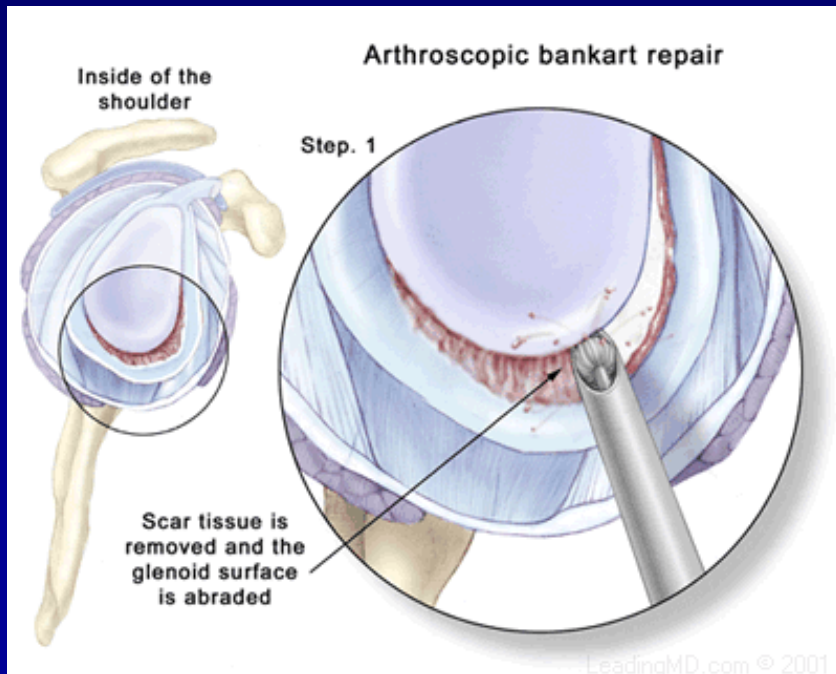
Suture:

- from small incision



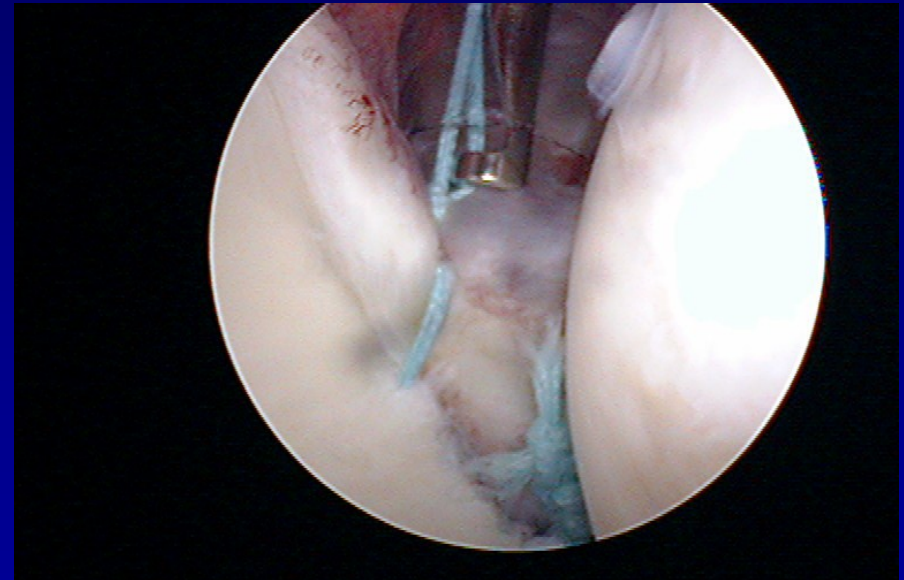
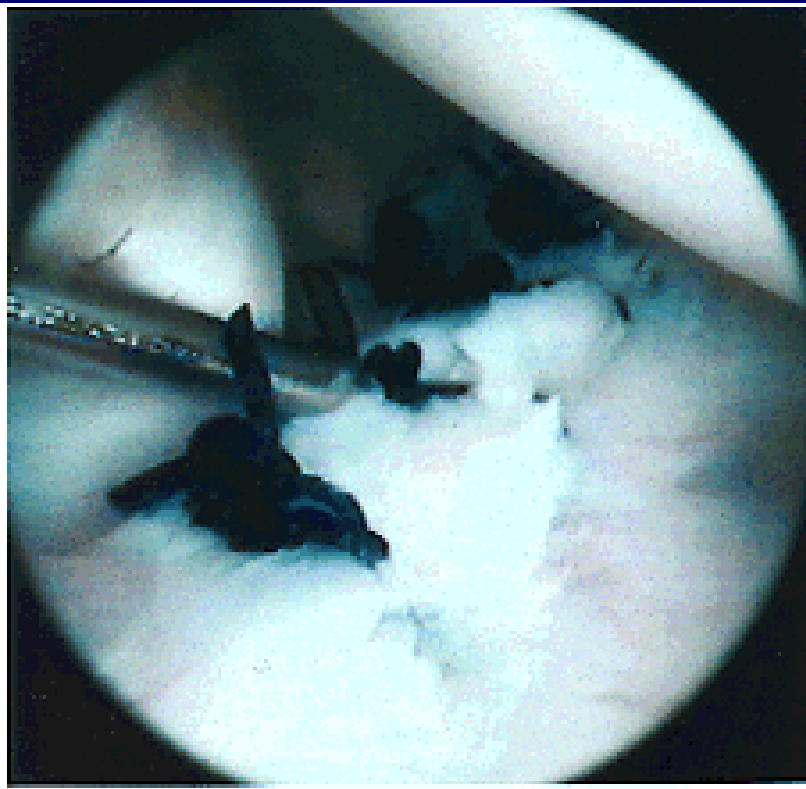
ASC- stabilisation

Fixation of the labrum to the bone – stitches and arrows



ASC- stabilisation

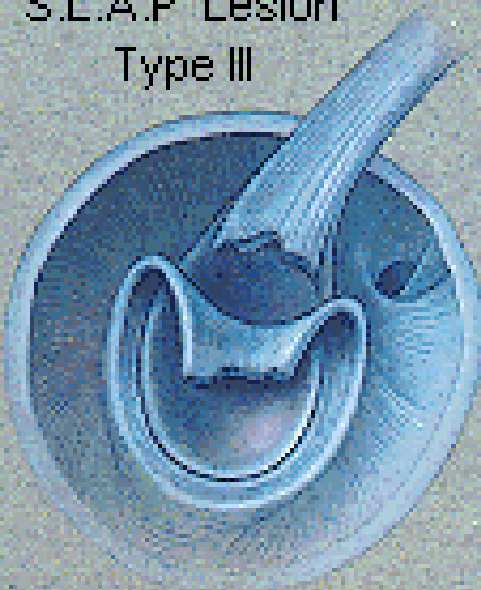- Fixation of the labrum to the bone – stitches, arrows



SLAP lesion

Rupture of insertion of the tendon of long head of biceps

S.L.A.P. Lesion
Type III



S.L.A.P. Lesion
Type IV

