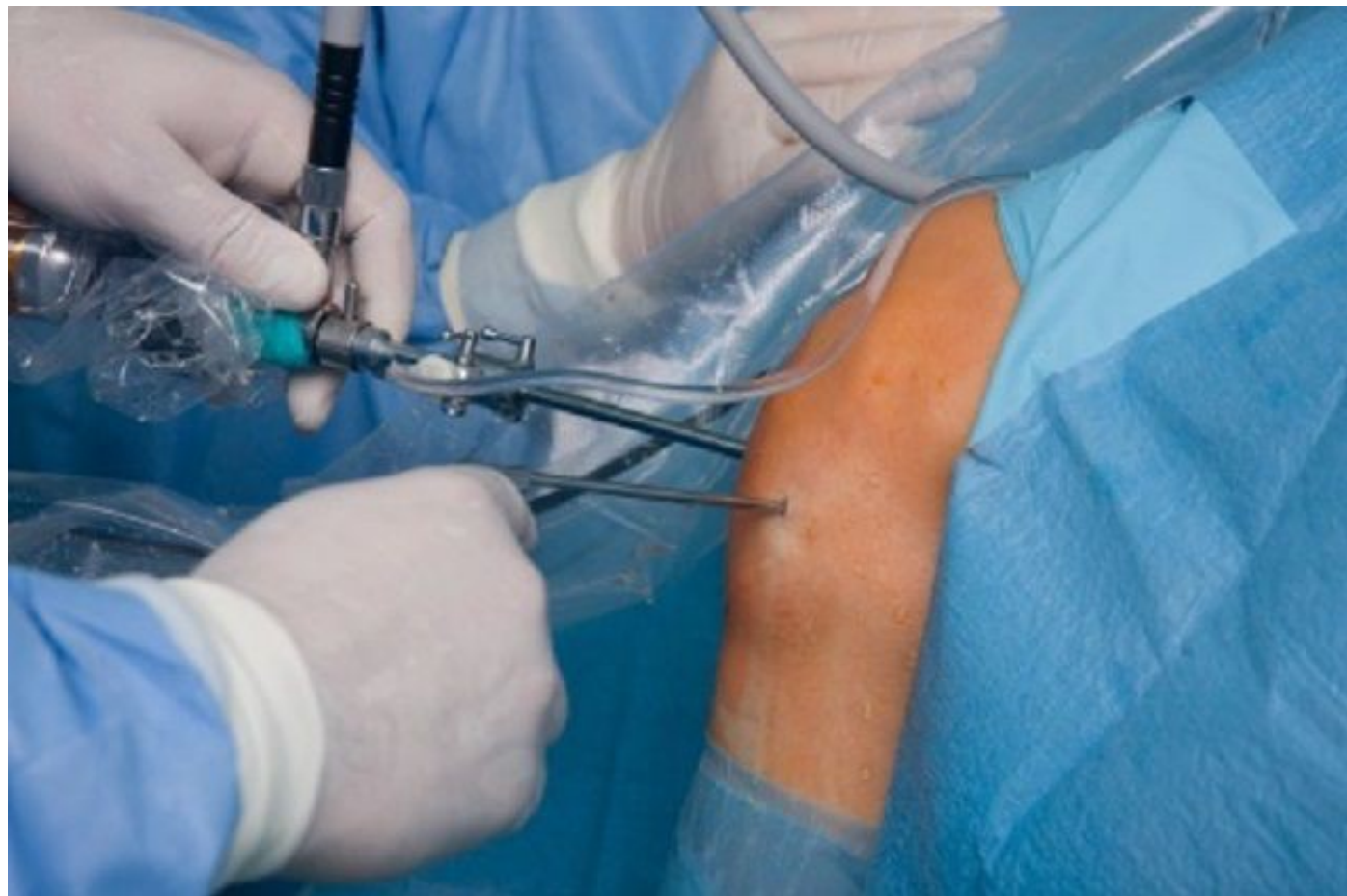

Arthroscopy

„key-hole“ surgery“



Vyskočil R., Rouchal M., Ryba L., Vališ P., Nýdrle M., Filipovič M.,

Ortopedická klinika FN Brno

Přednosta: Prof. MUDr. Martin Repko Ph.D.

Endoscopic surgical procedure

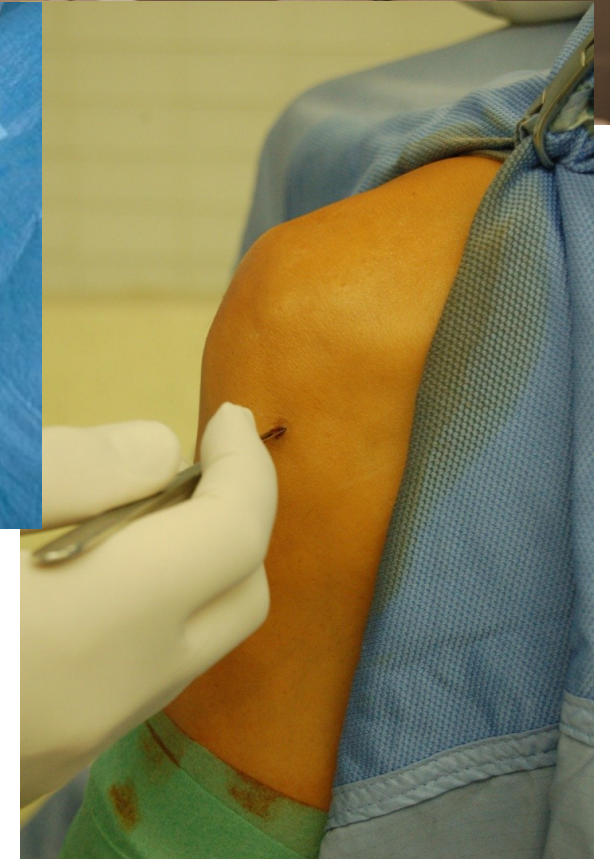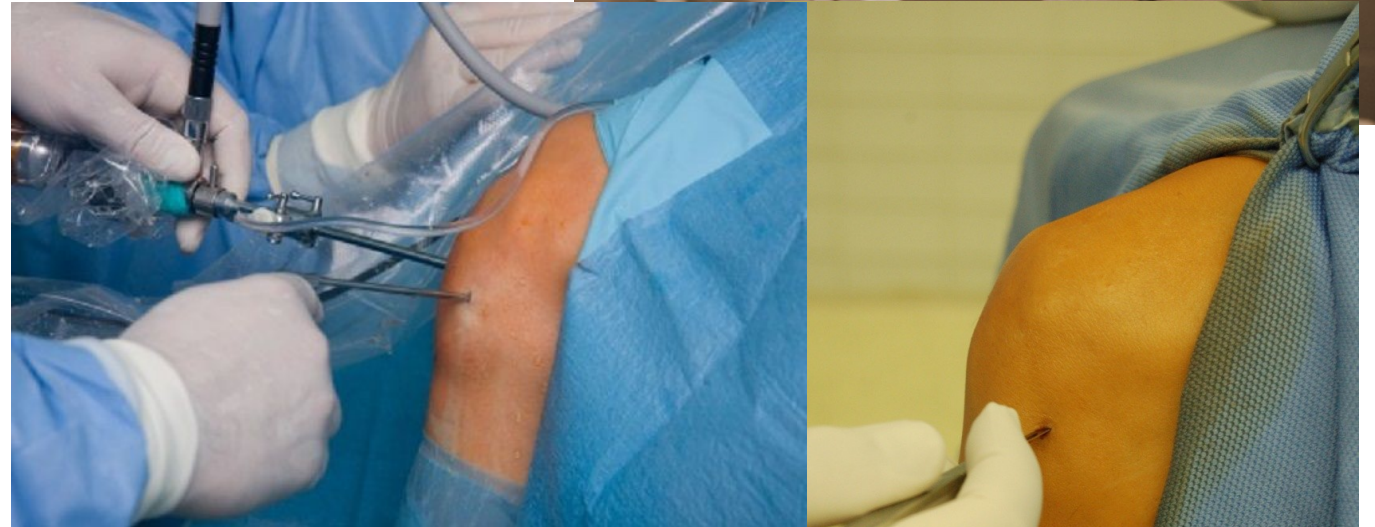
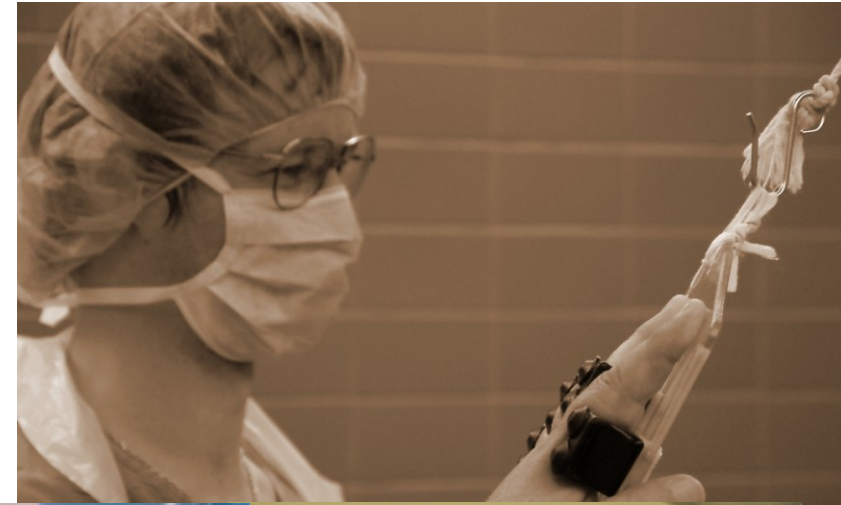□ 2 /or 3/ small incisions:

optics

/ camera + source of light /

instruments

/ probe, punch, shaver, wiper.. /



History

- **1918 Kenji Takagaki**

Cystoscope used into knee joint

- **1920 Eugen Bircher**

Diagnostic Arthroscopy

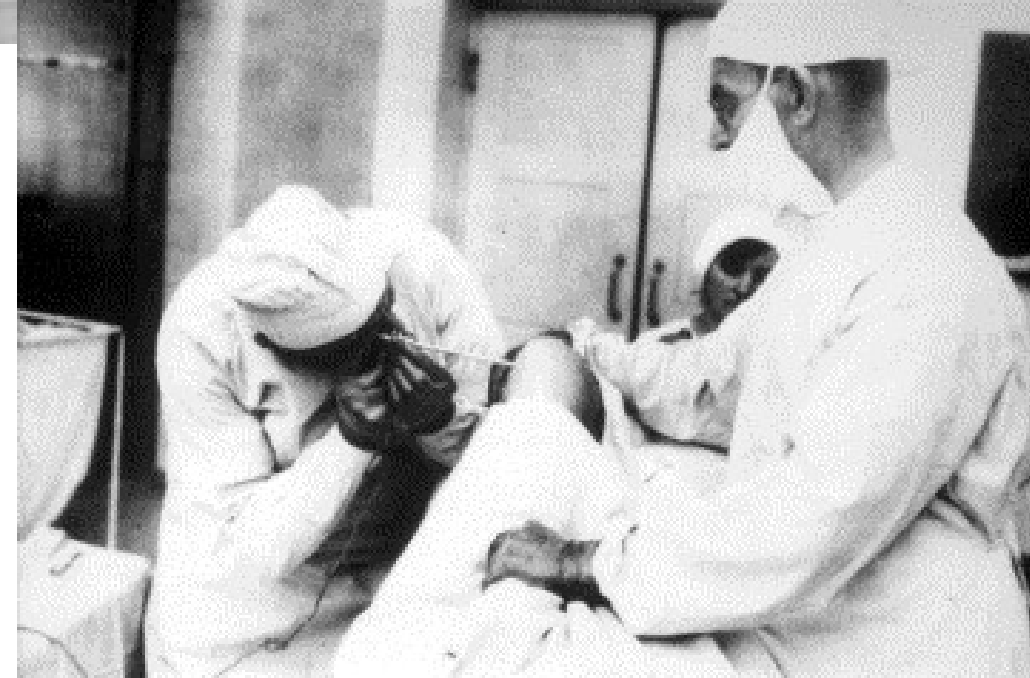
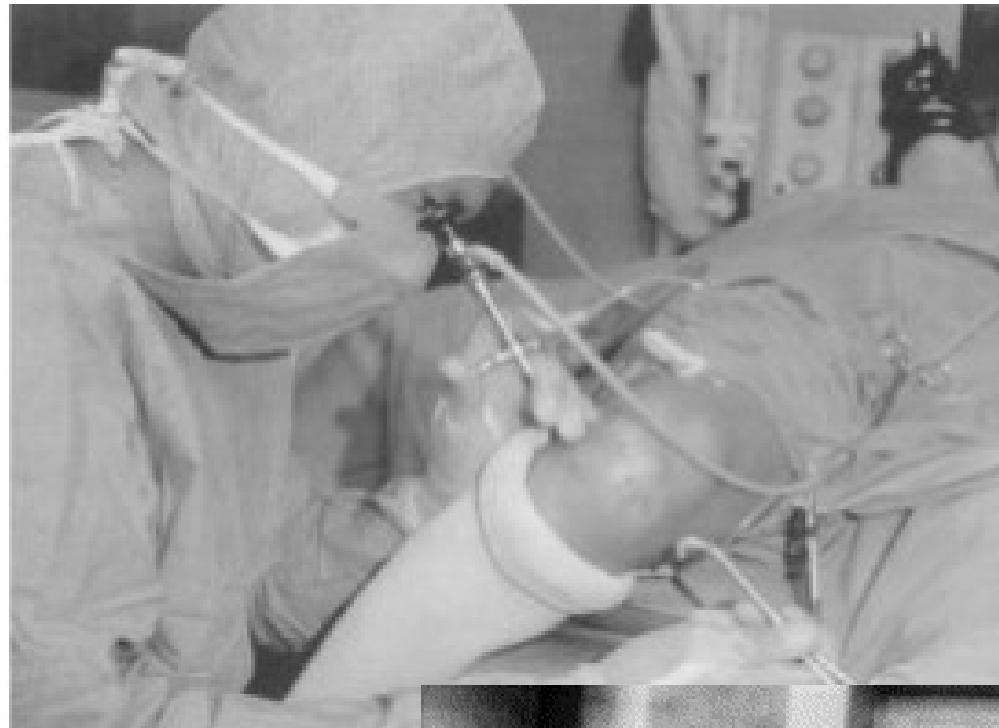- **1931 M.S. Burman**

AS of shoulder on the cadaver

- **1950 - Masaki Watanabe**

Modernisation of Arthroscopes and usage in clinical work

- **1970 - first usage of arthroscopic camera**



Knee

Shoulder

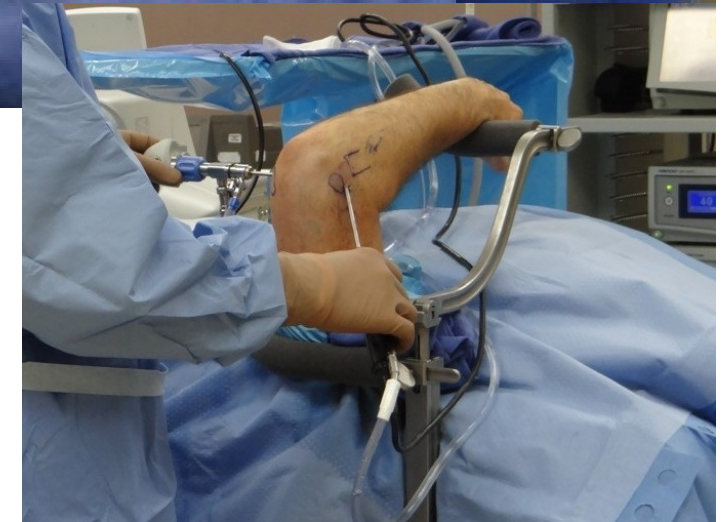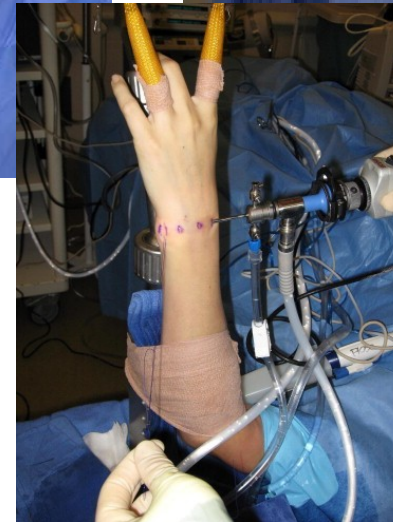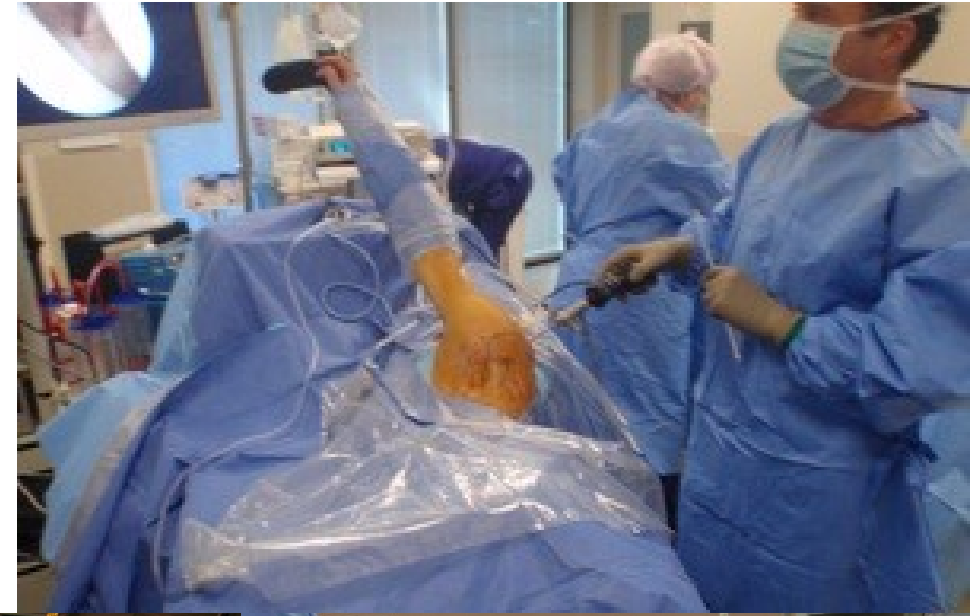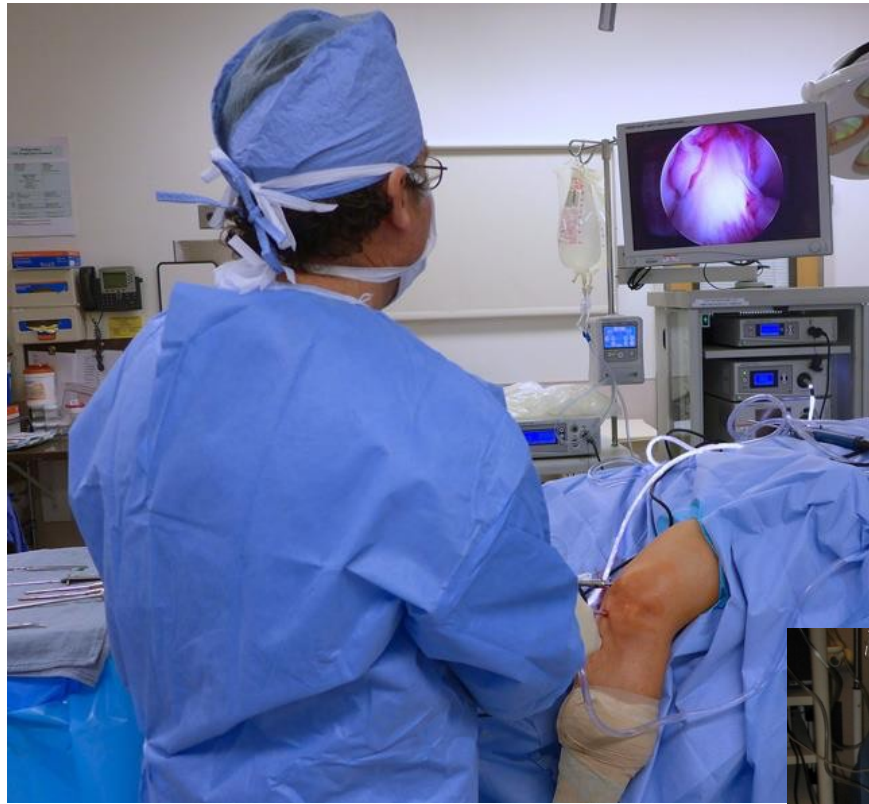Wrist

Elbow

Hip

Para-articular spaces

/ Achilles tendon, carpal tunnel – CTD /



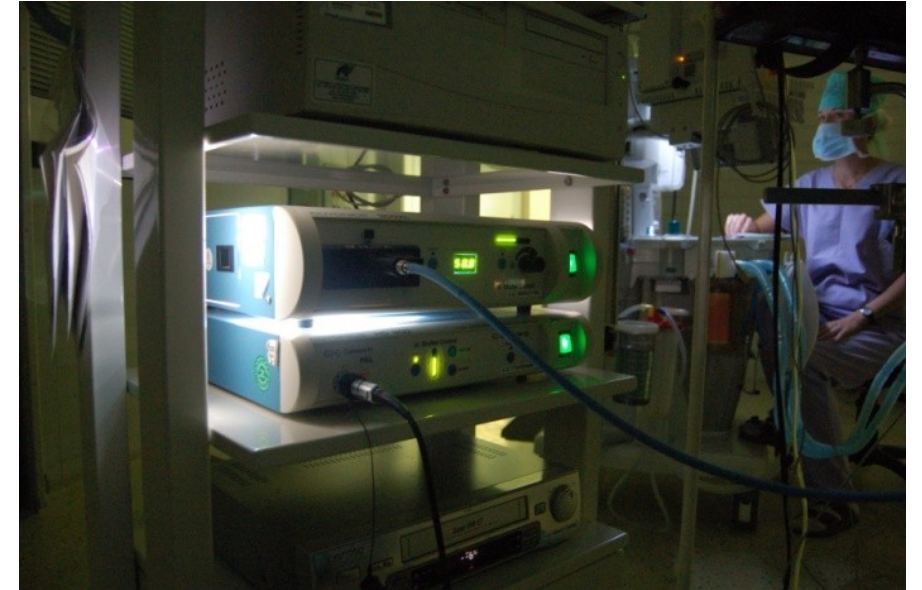

monitor

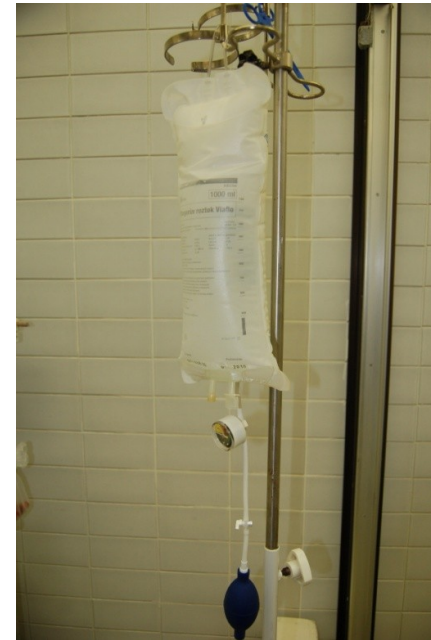PC

light source

processor of the camera





Pump


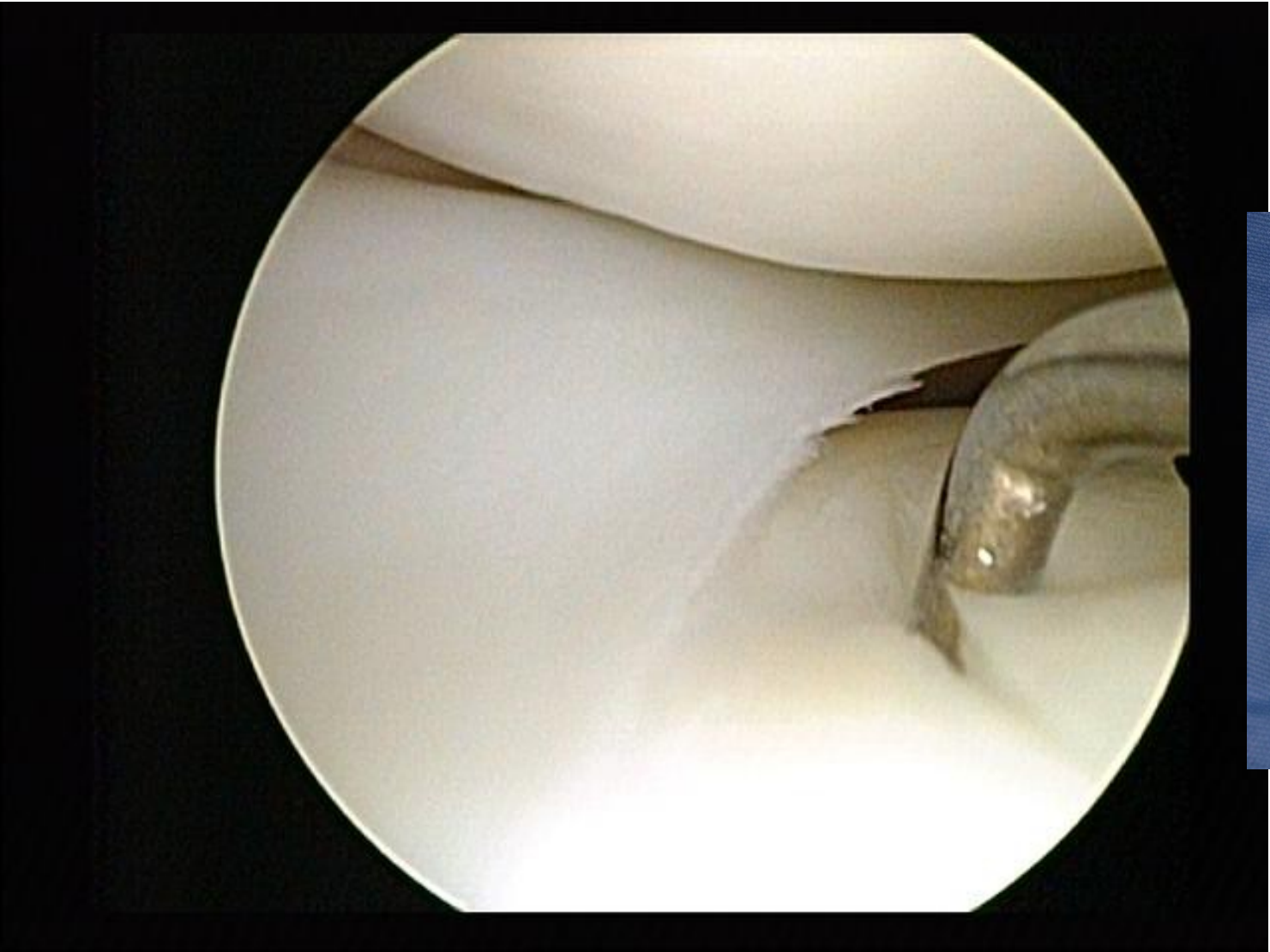


Shaver

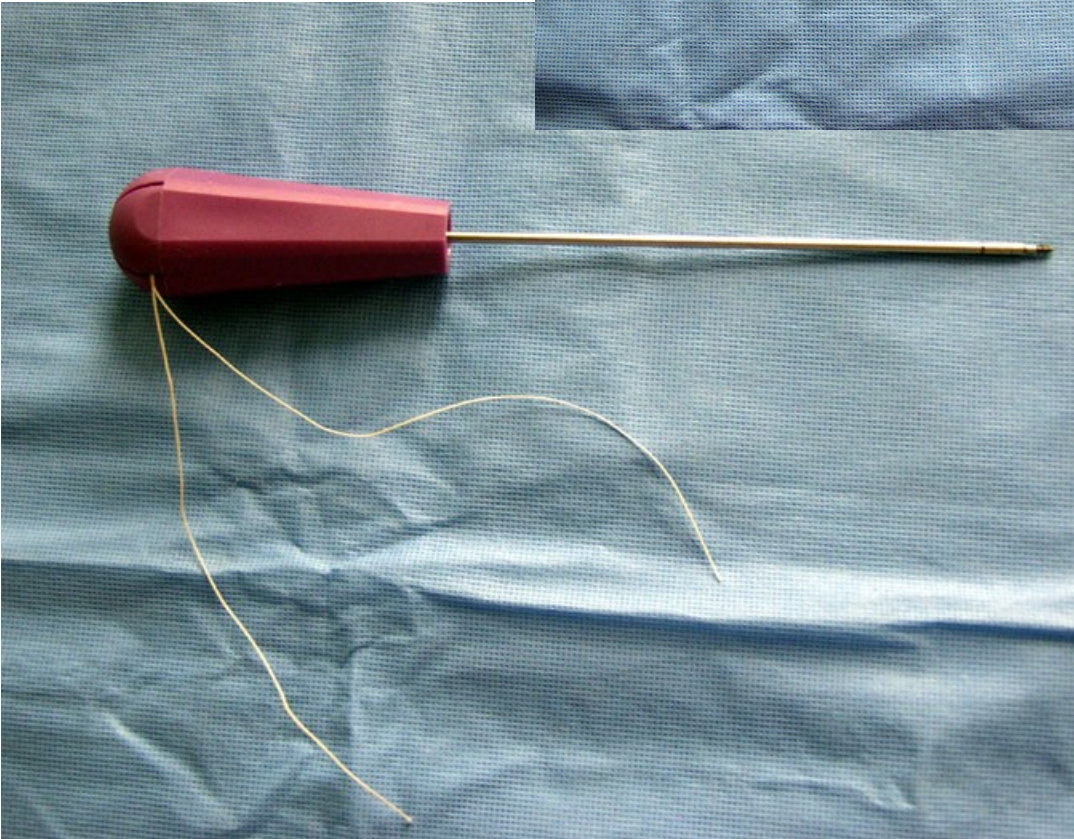


optics 30





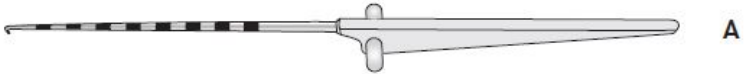
Instruments



Titanium Anchor



Absorbable Anchor



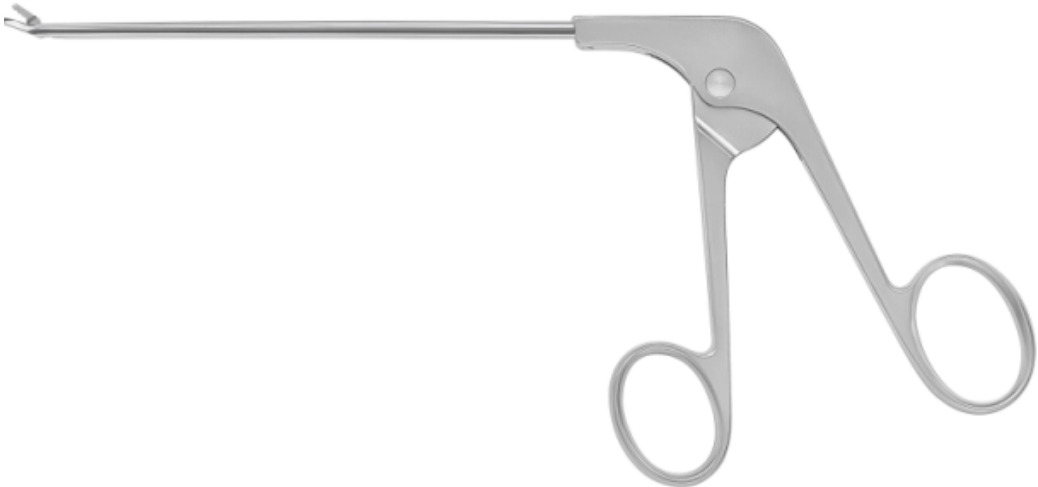A



B

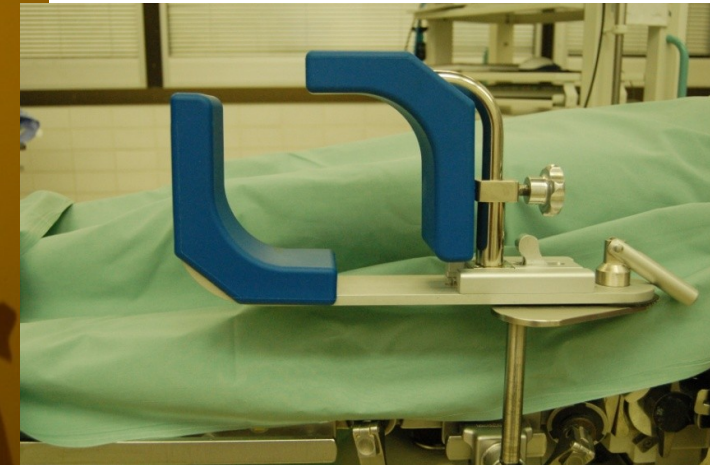


C





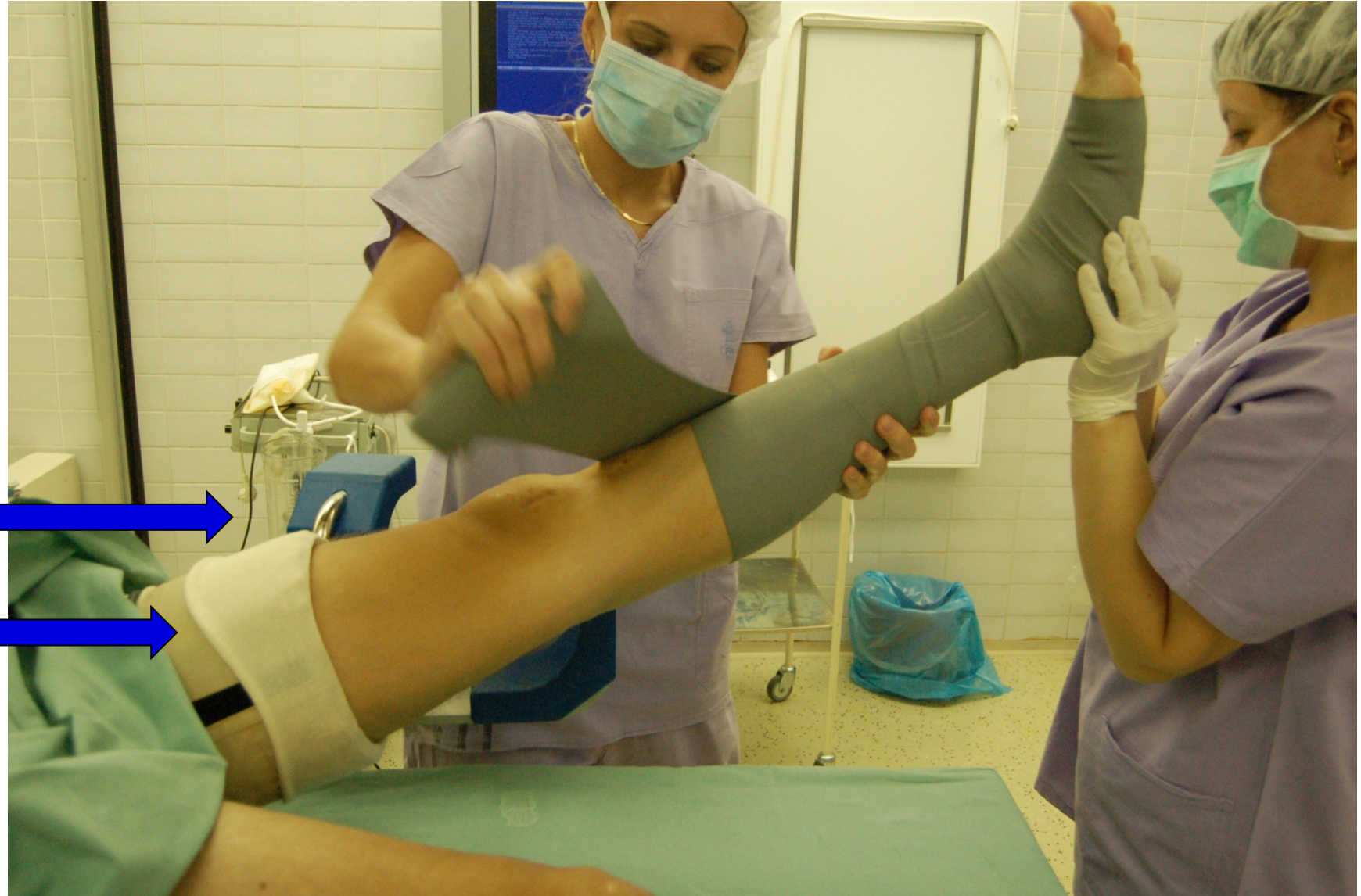Turniquet

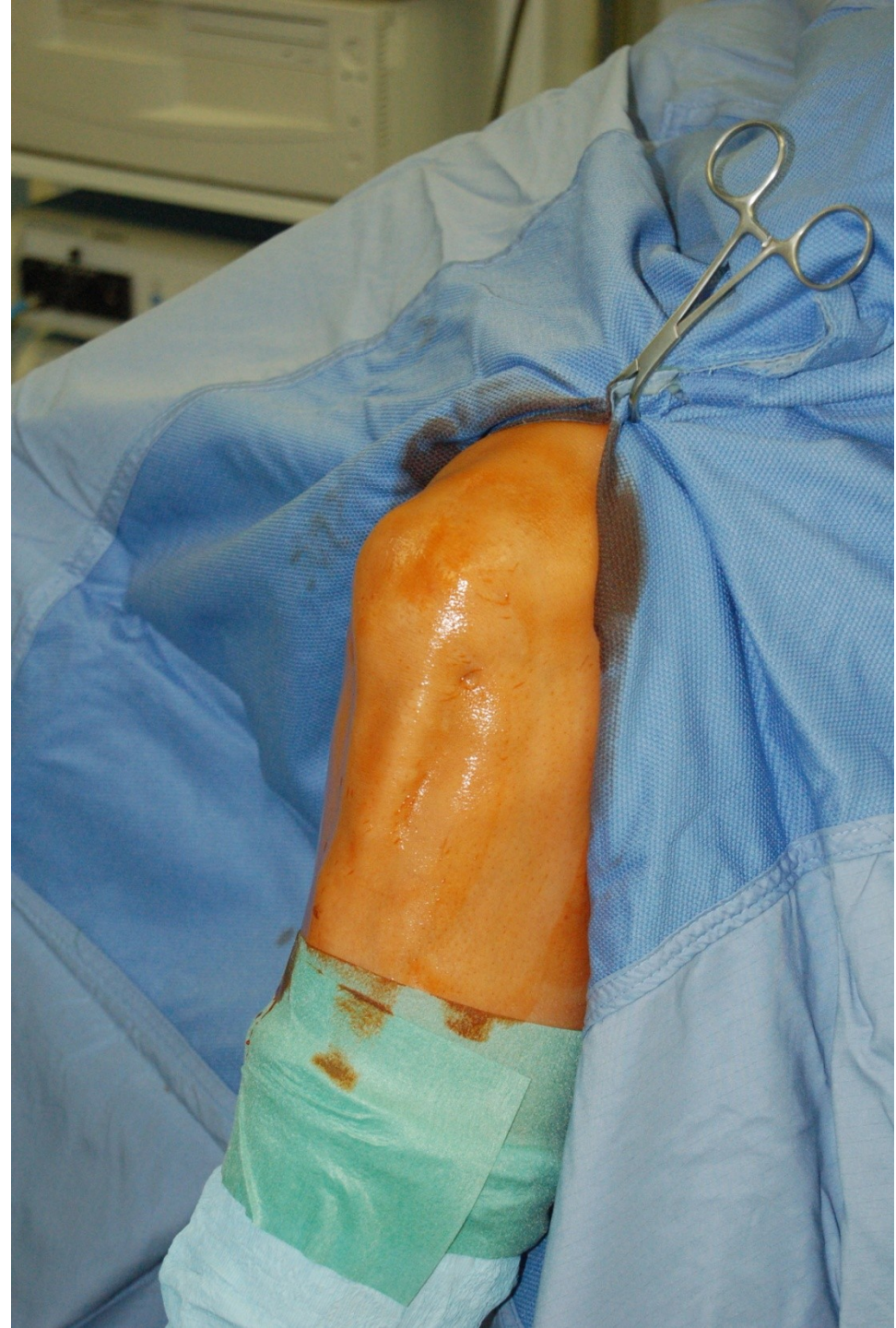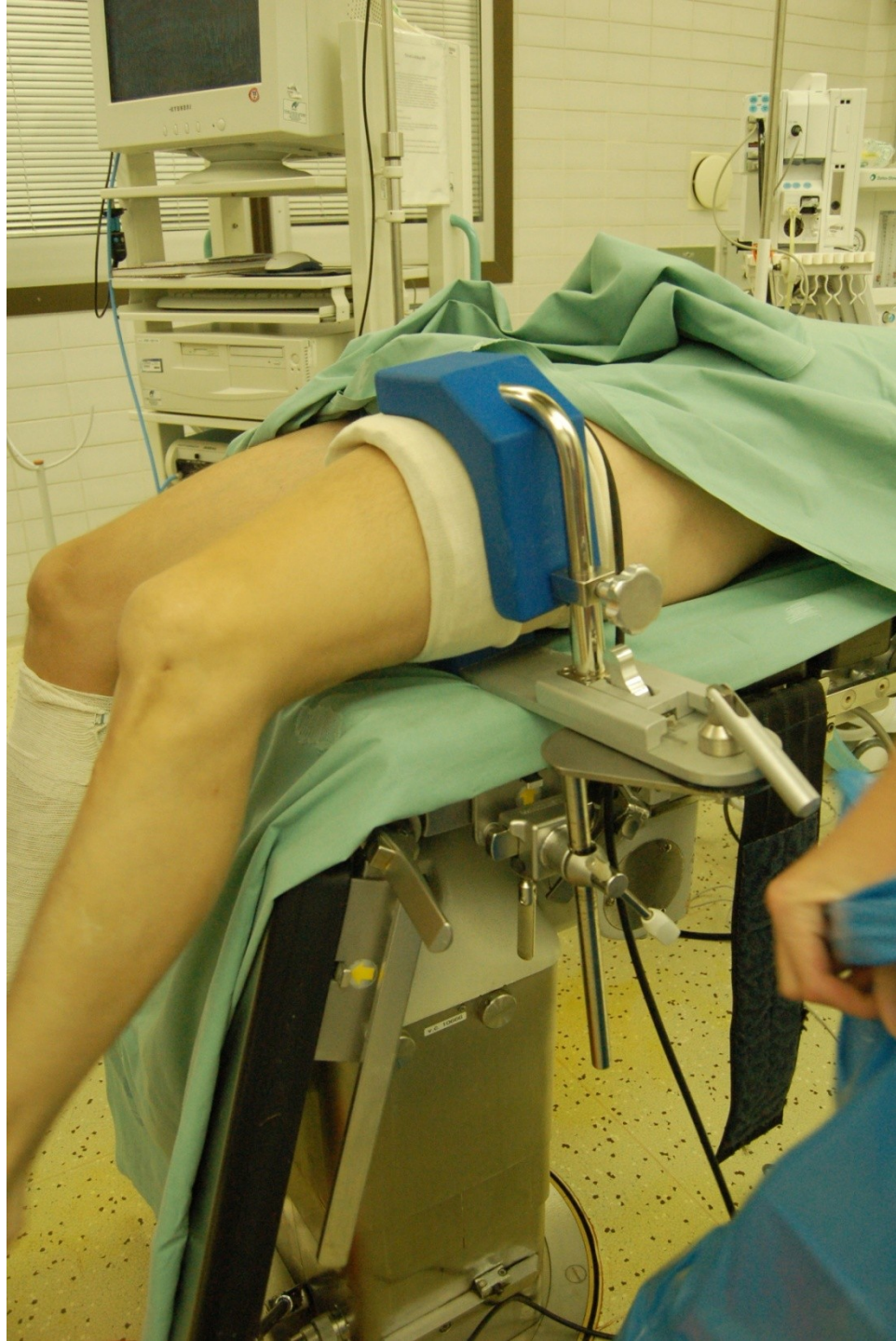- Ischemisation of the leg
„bloodless“ procedure
- 250 Torr / Systolic BP + 100 /
- Maximum 90 min
- Knee, ankle, foot ASC

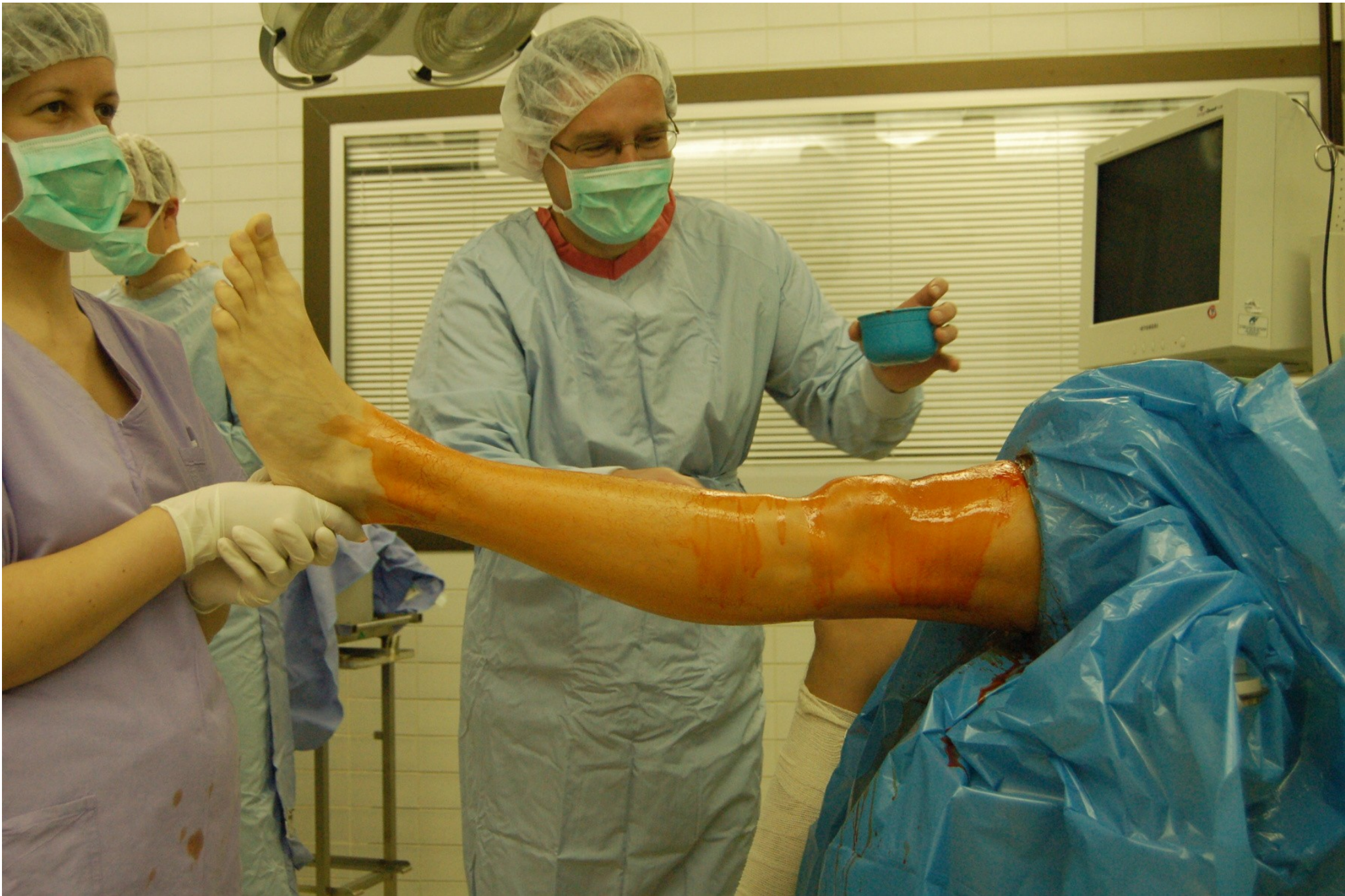

Preparation

- Knee scope
- Supine position
- Thigh holder 
- Turniquet 



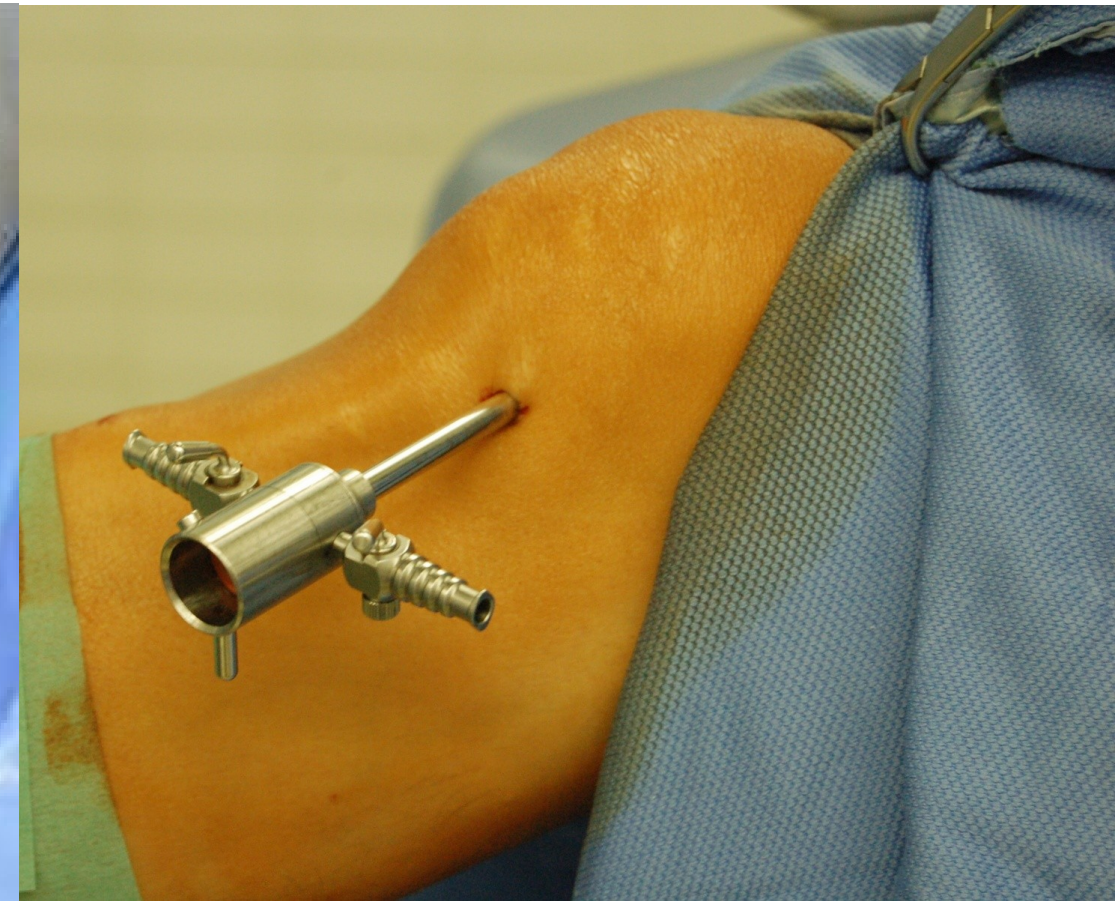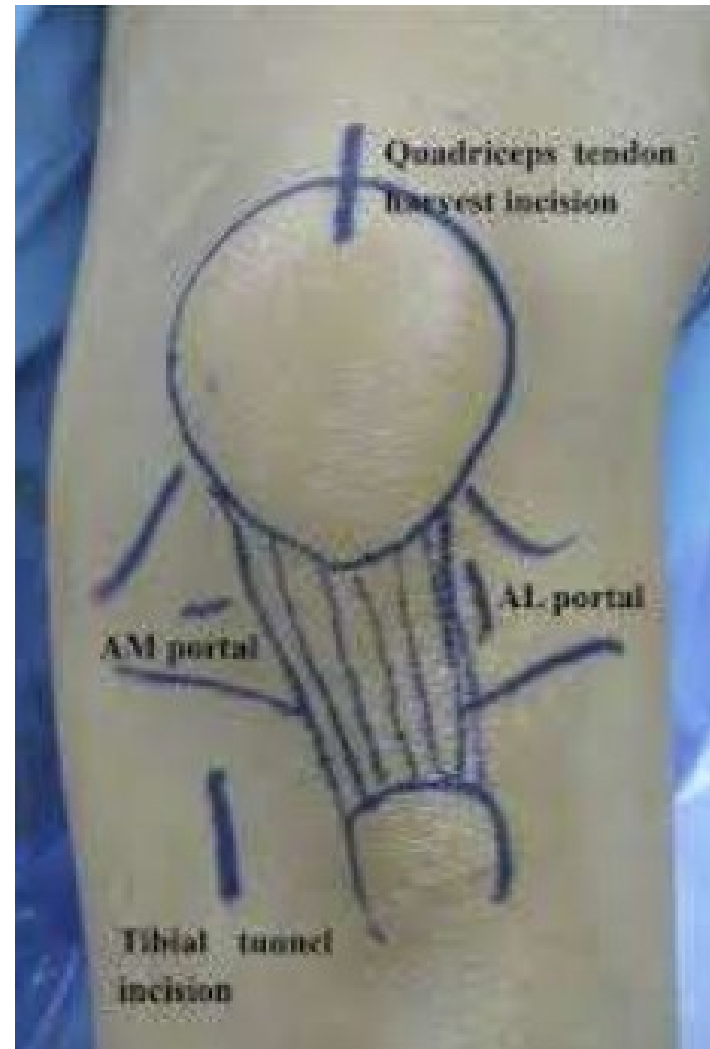



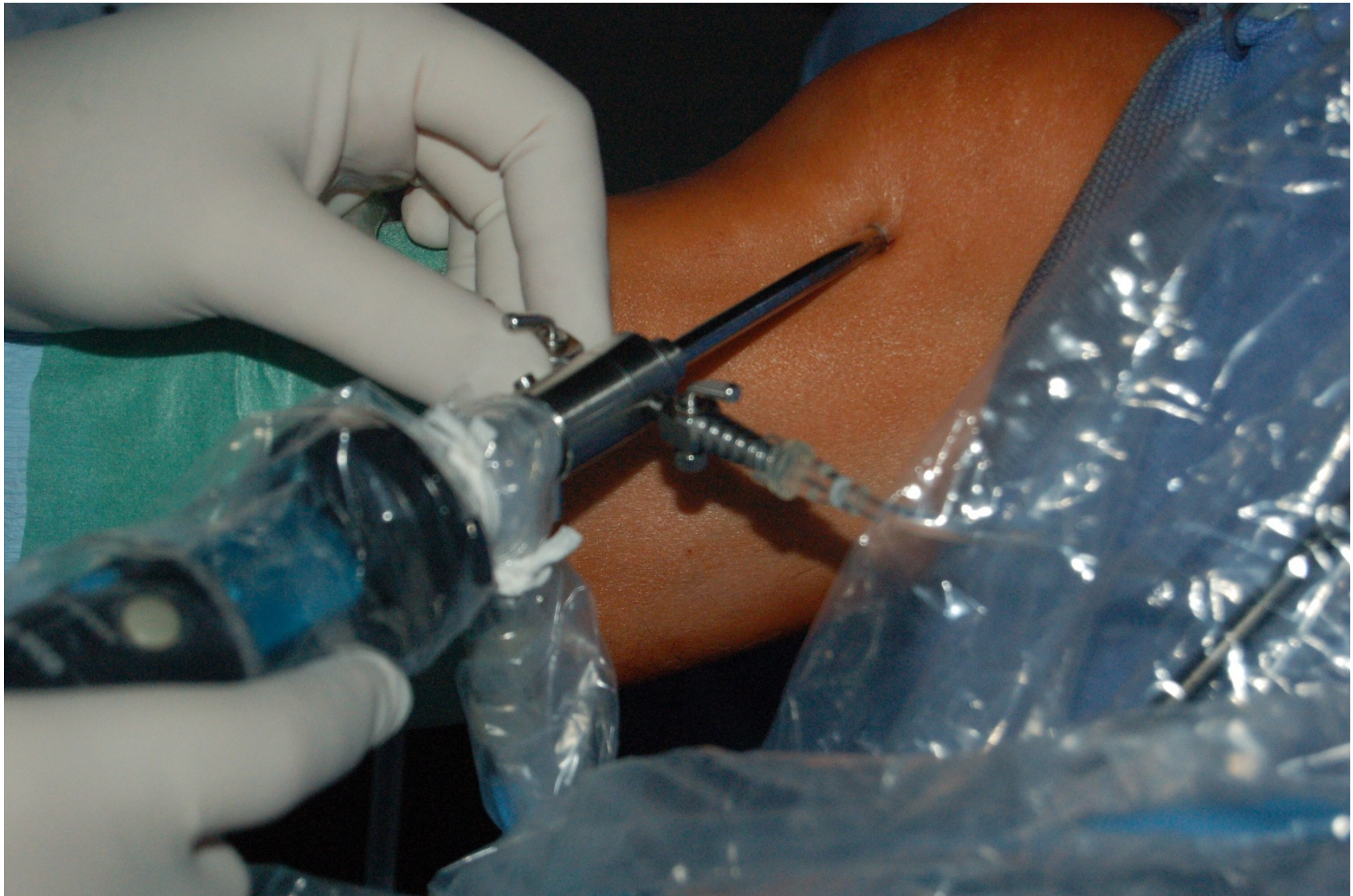
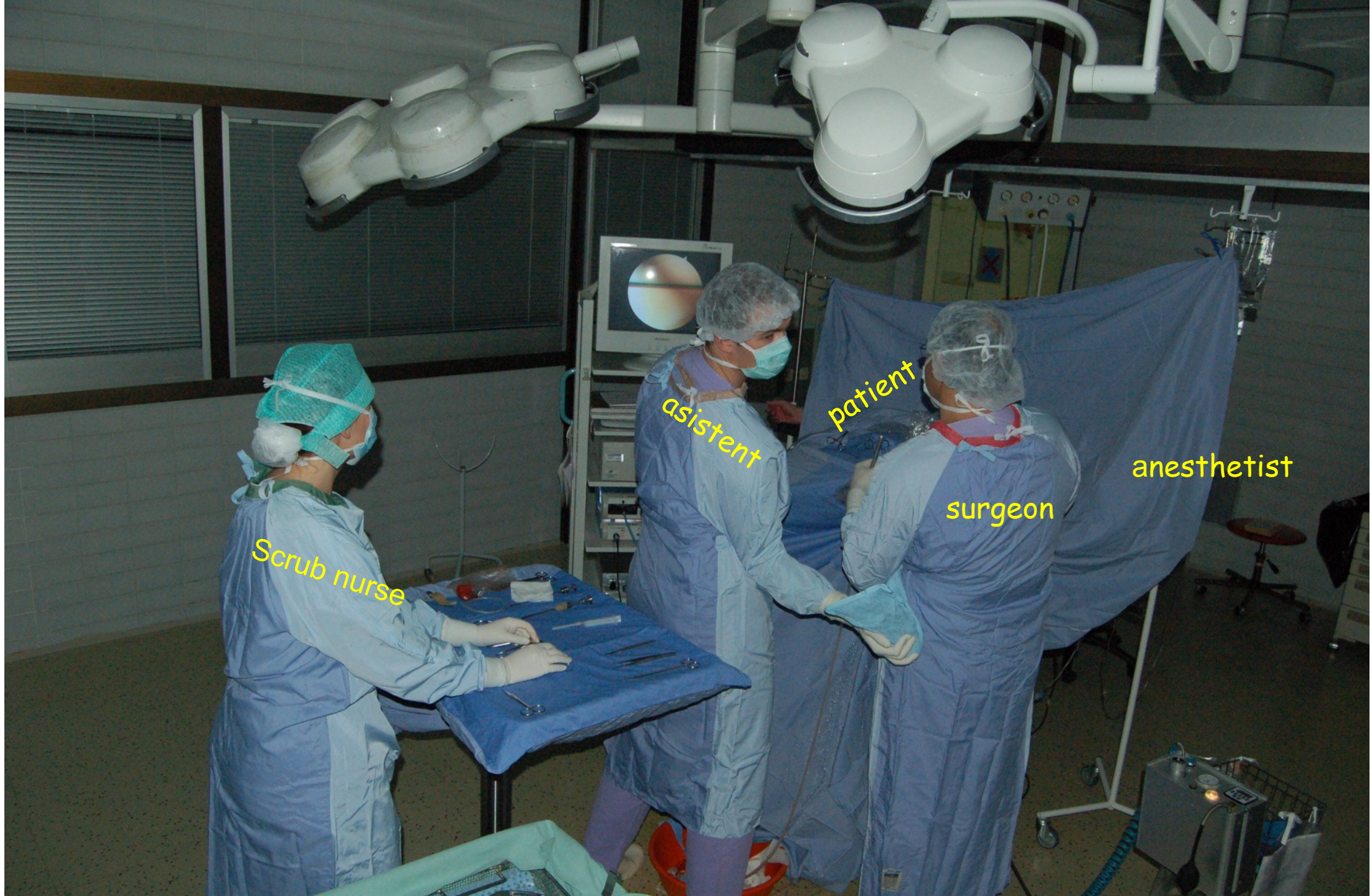Basic 2 portals

□ For Optics – *AL*

□ Instruments – *AM*







Scrub nurse

asistent

patient

surgeon

anesthetist

Upper limb

Shoulder

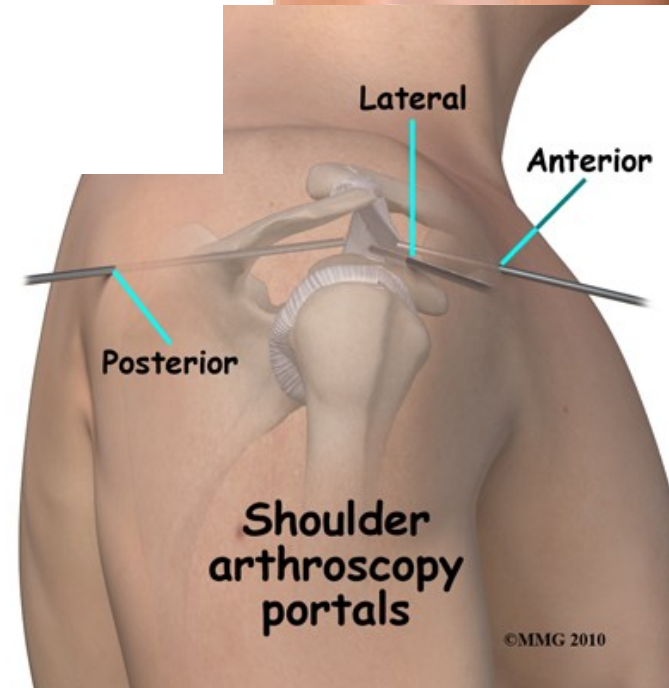
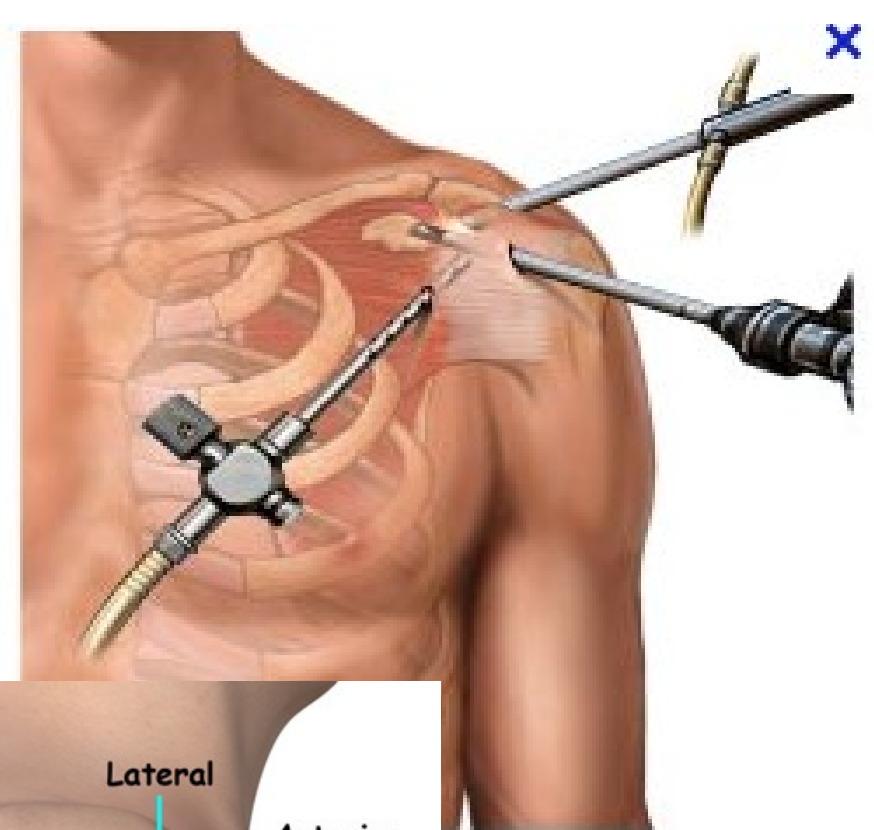
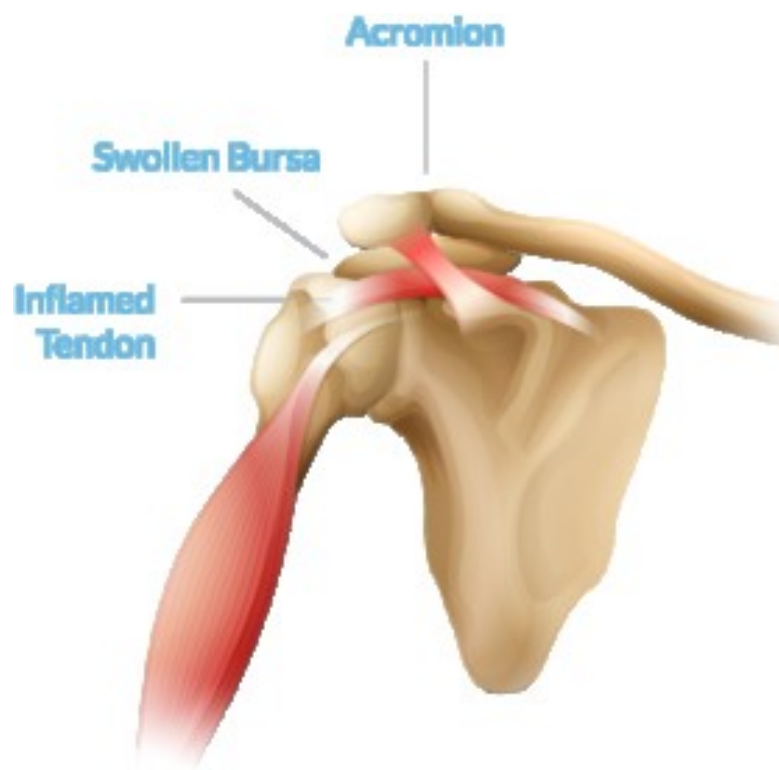Indication:

Degeneration

Trauma, post – traumatic pathology

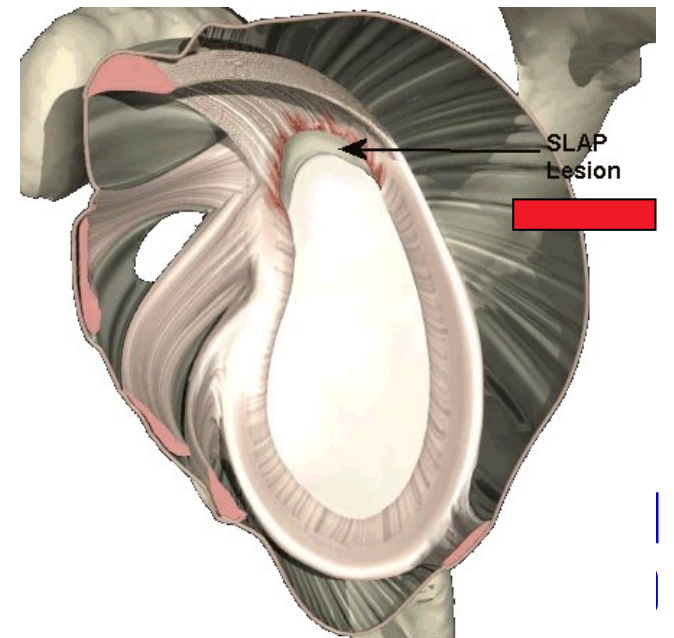
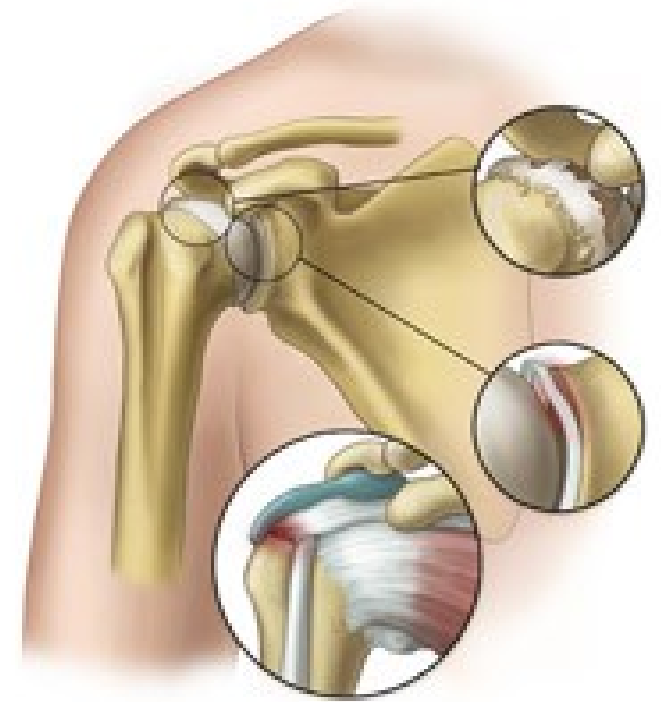
Infection - lavage

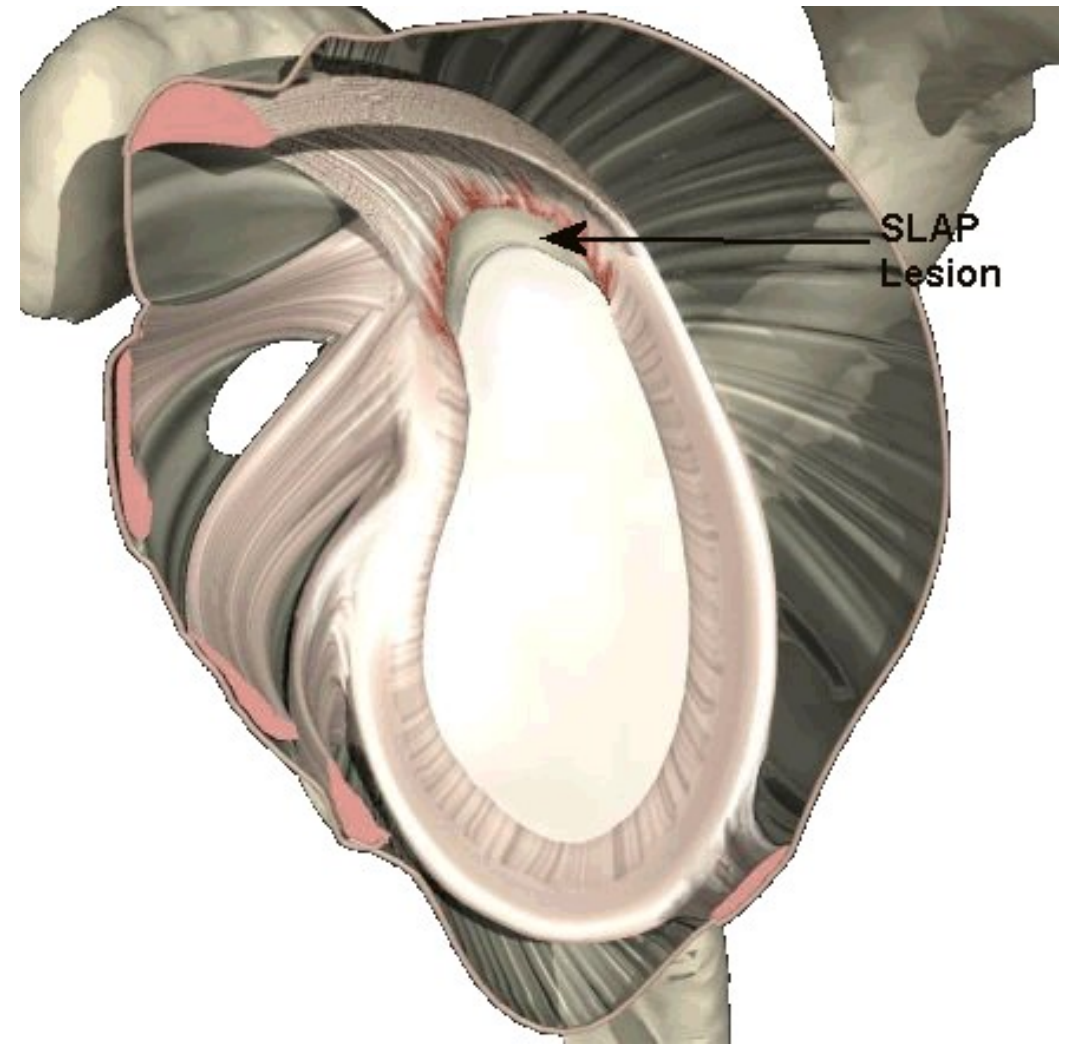
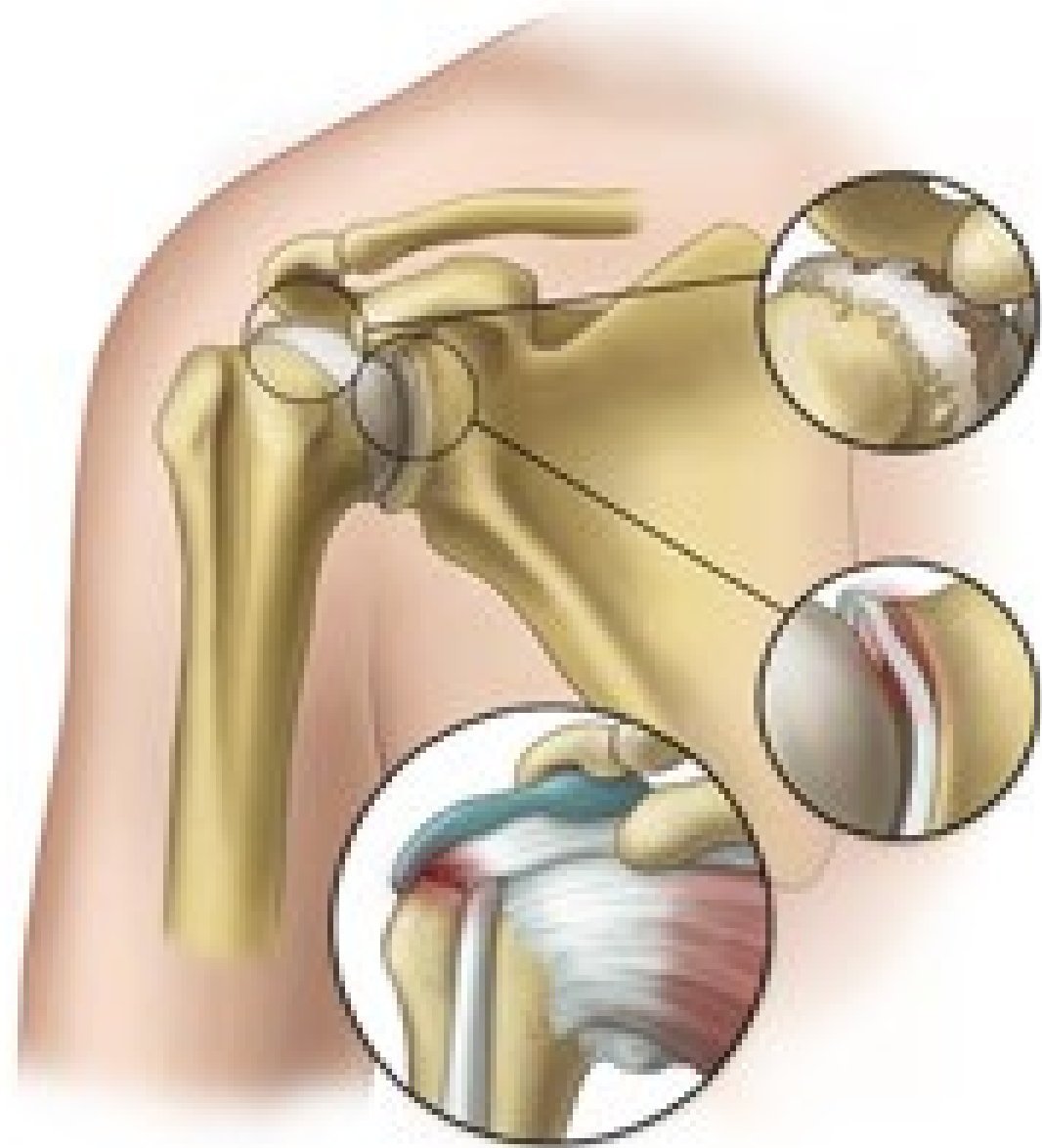
Tumour - biopsy



Most common diagnosis of shoulder Arthroscopy:

- Repeated shoulder dislocations – „Bankart“ lesion
ventral labrum tear
- Slap lesion Superior – „superior labrum antero-posterior“
upper labrum tear
- Rotator cuff pathology – tear, rupture
- Pathology of SA space – „Shoulder Impingement“
- Osteoarthritis, degeneration

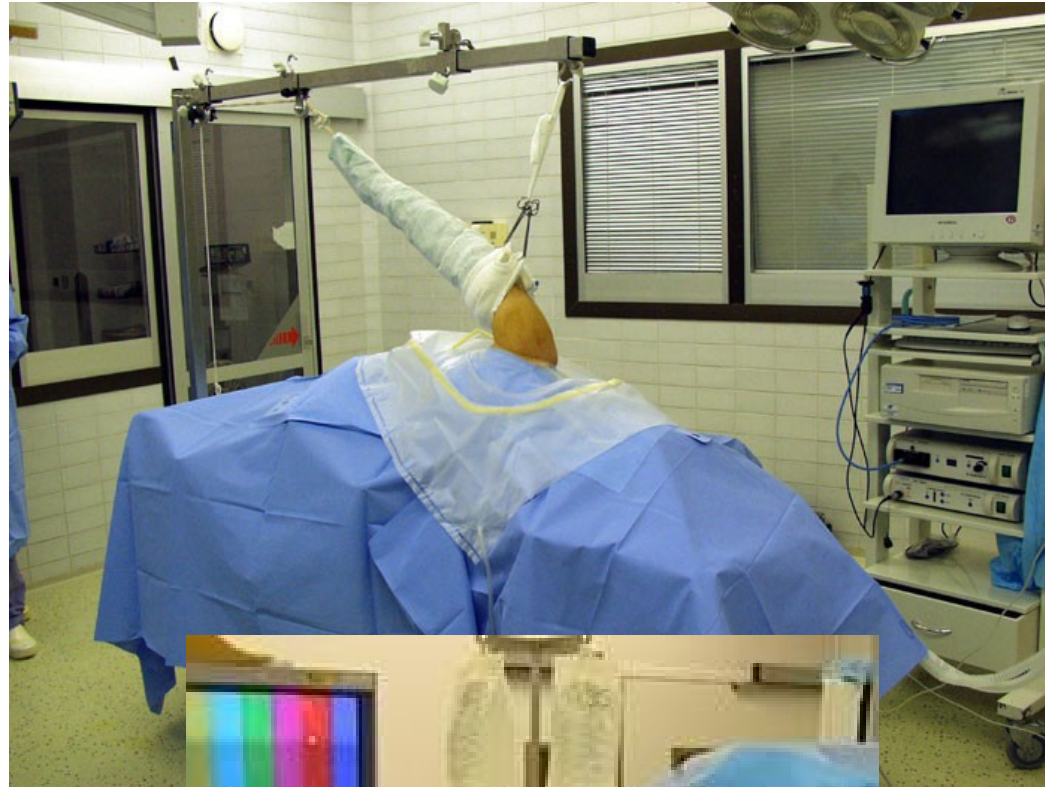



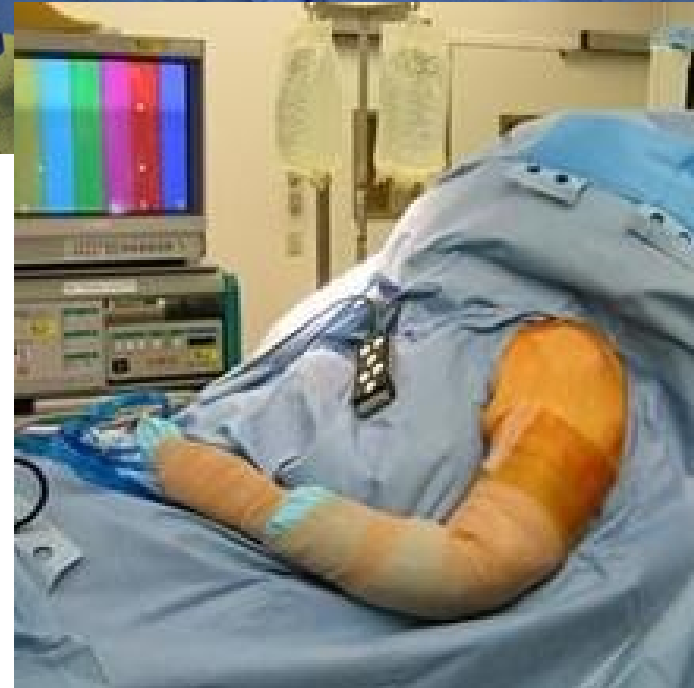position on the table

1. lateral decubitus

traction of operated limb

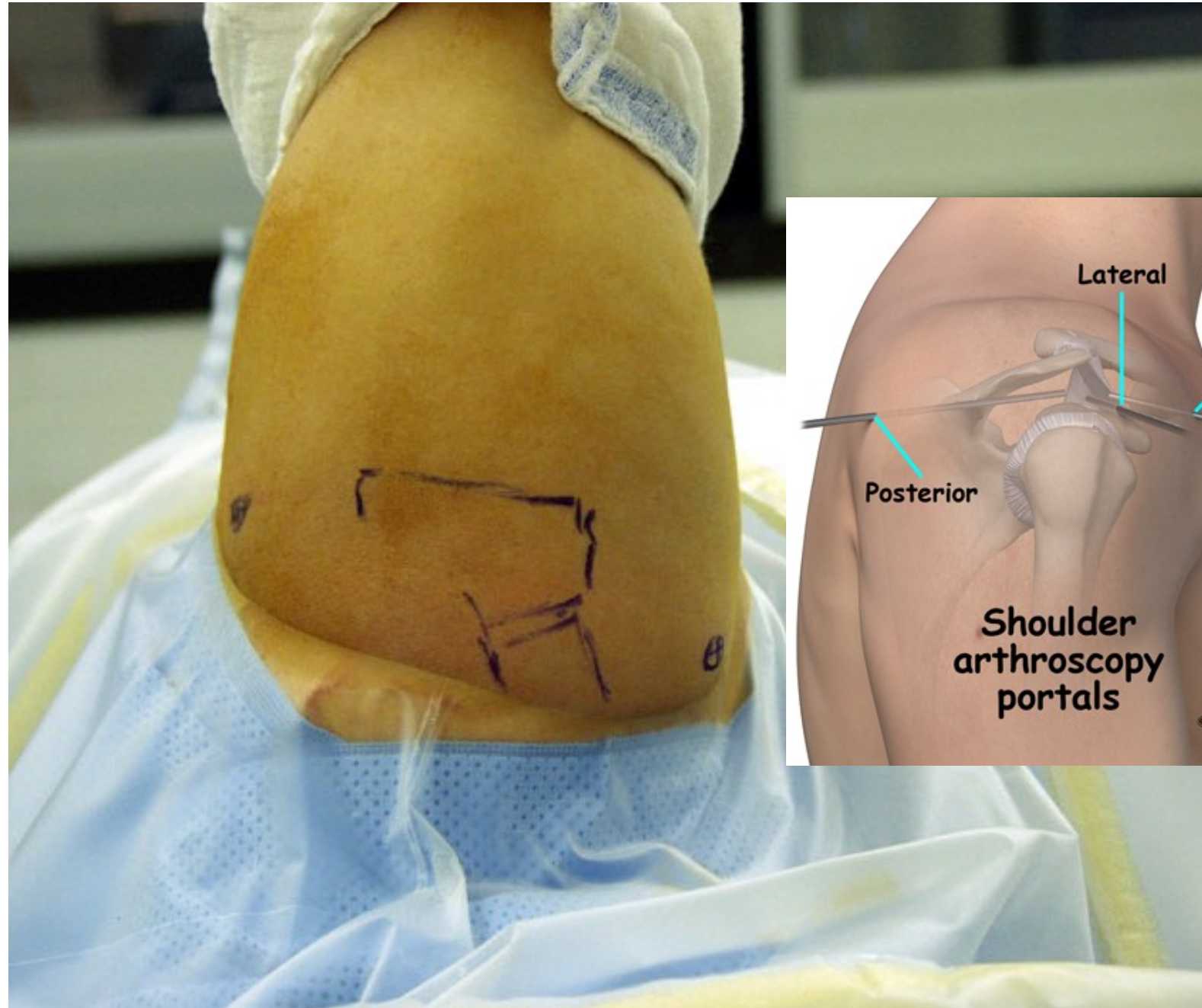


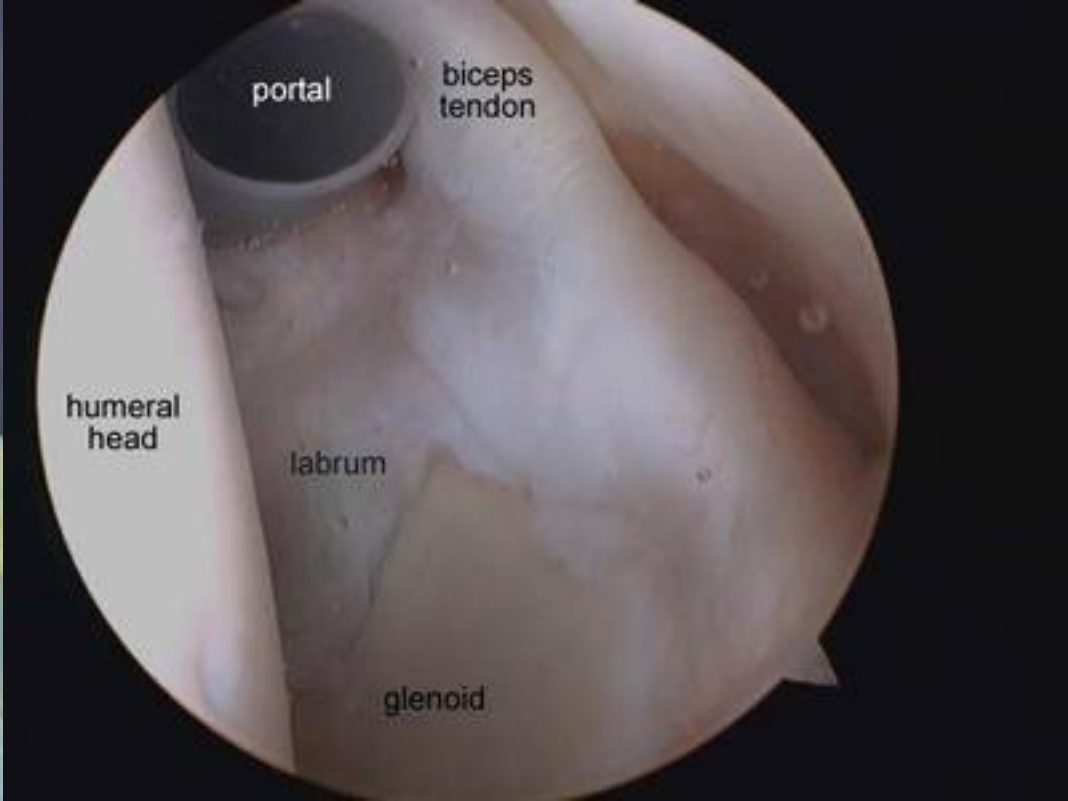
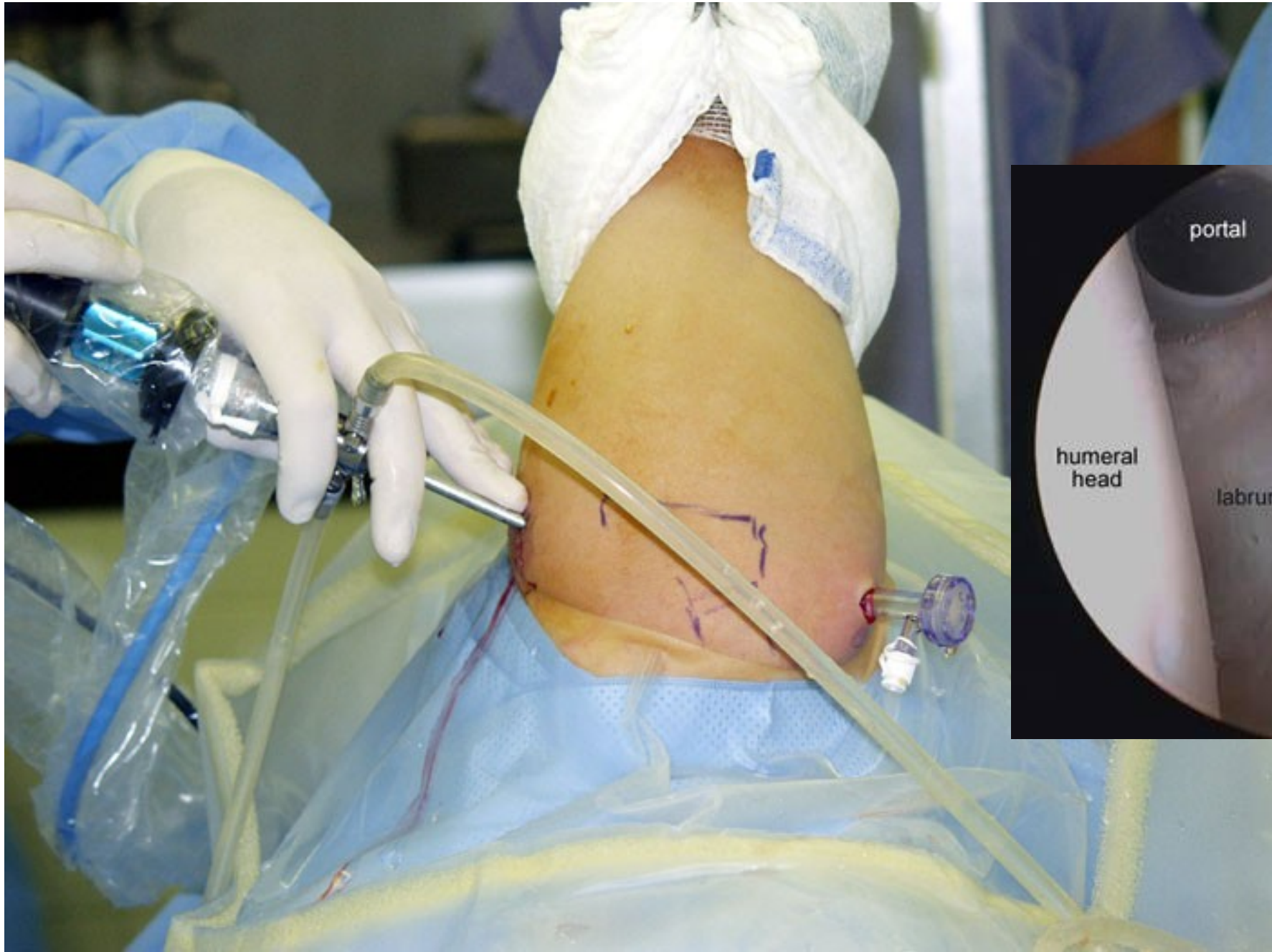2. „beach chair“ position



ASC portals:

- Dorsal/posterior
- Ventral/anterior
- Lateral /SA space/

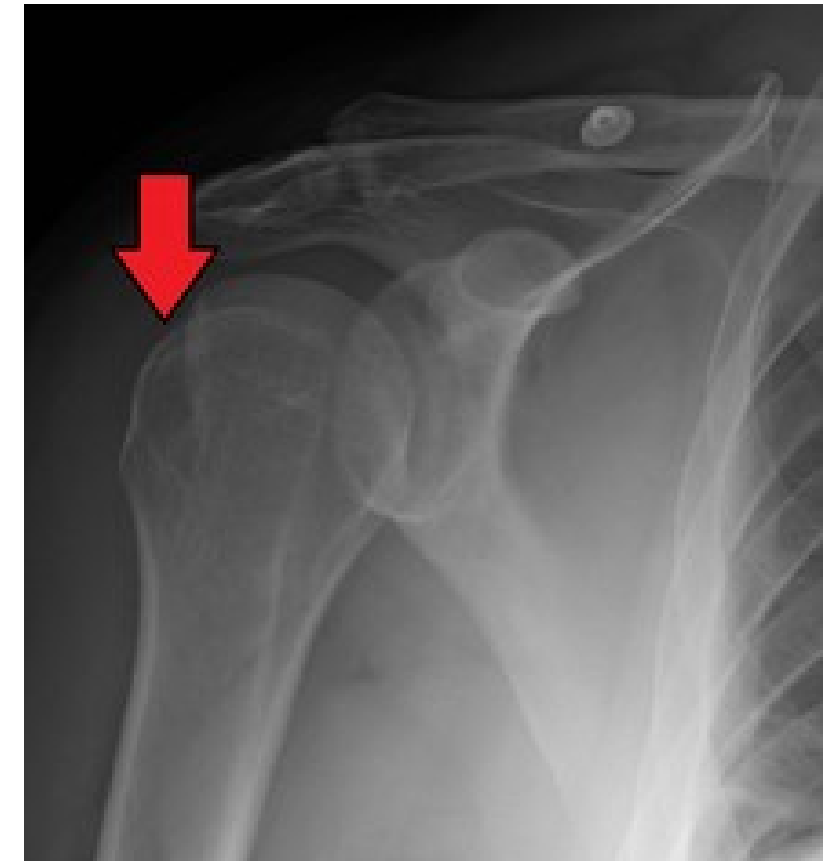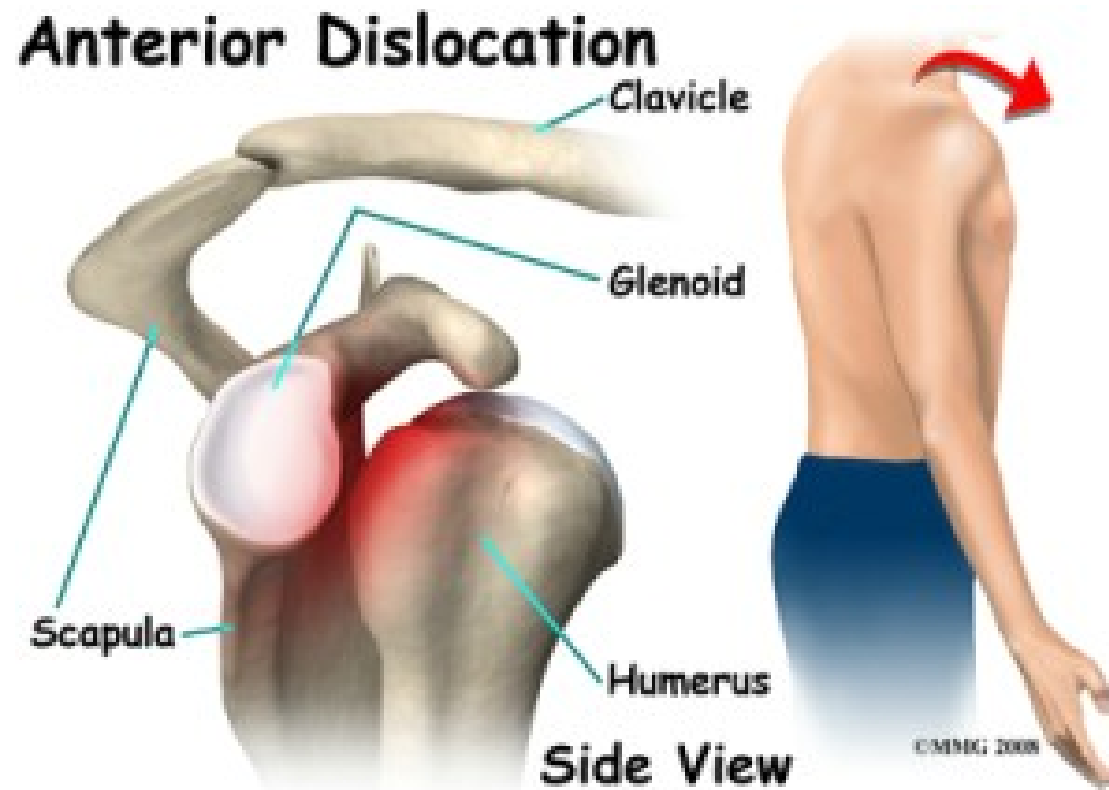




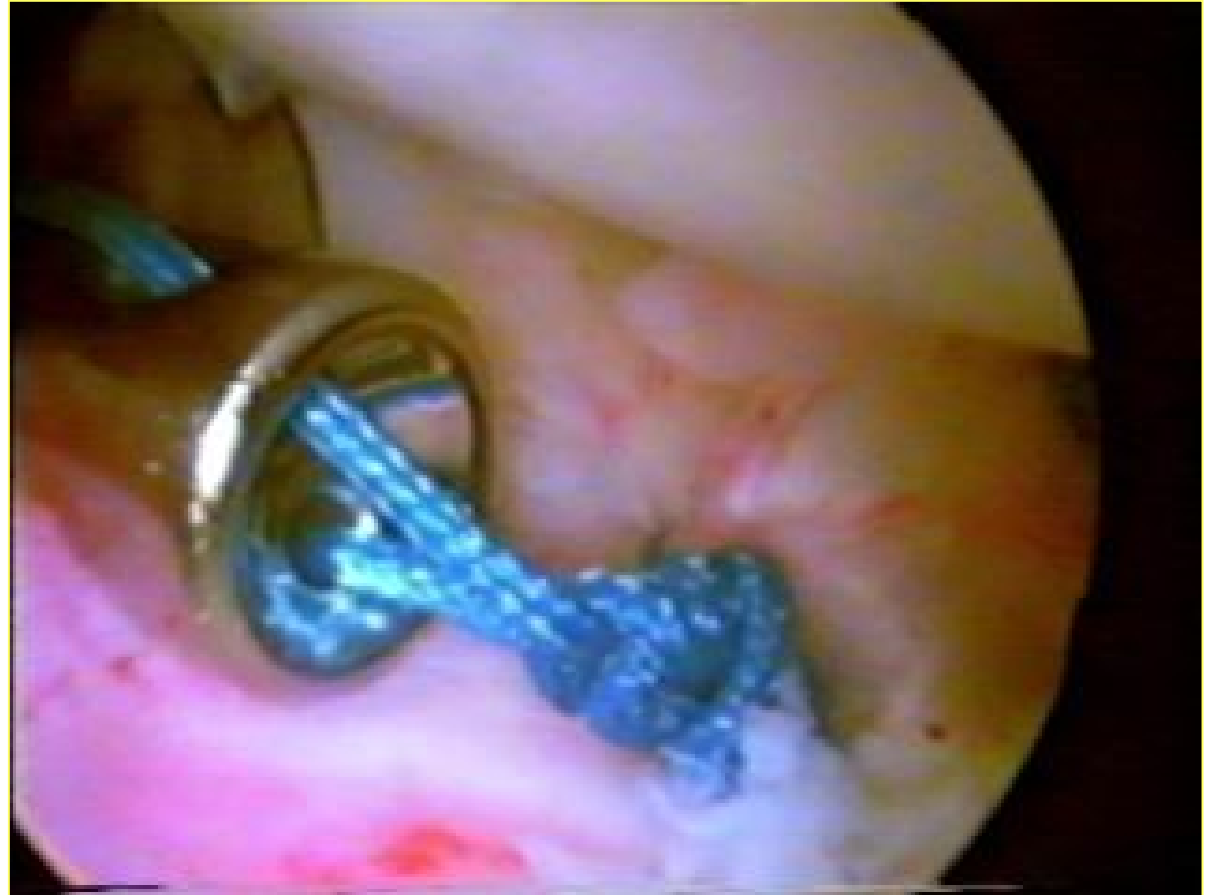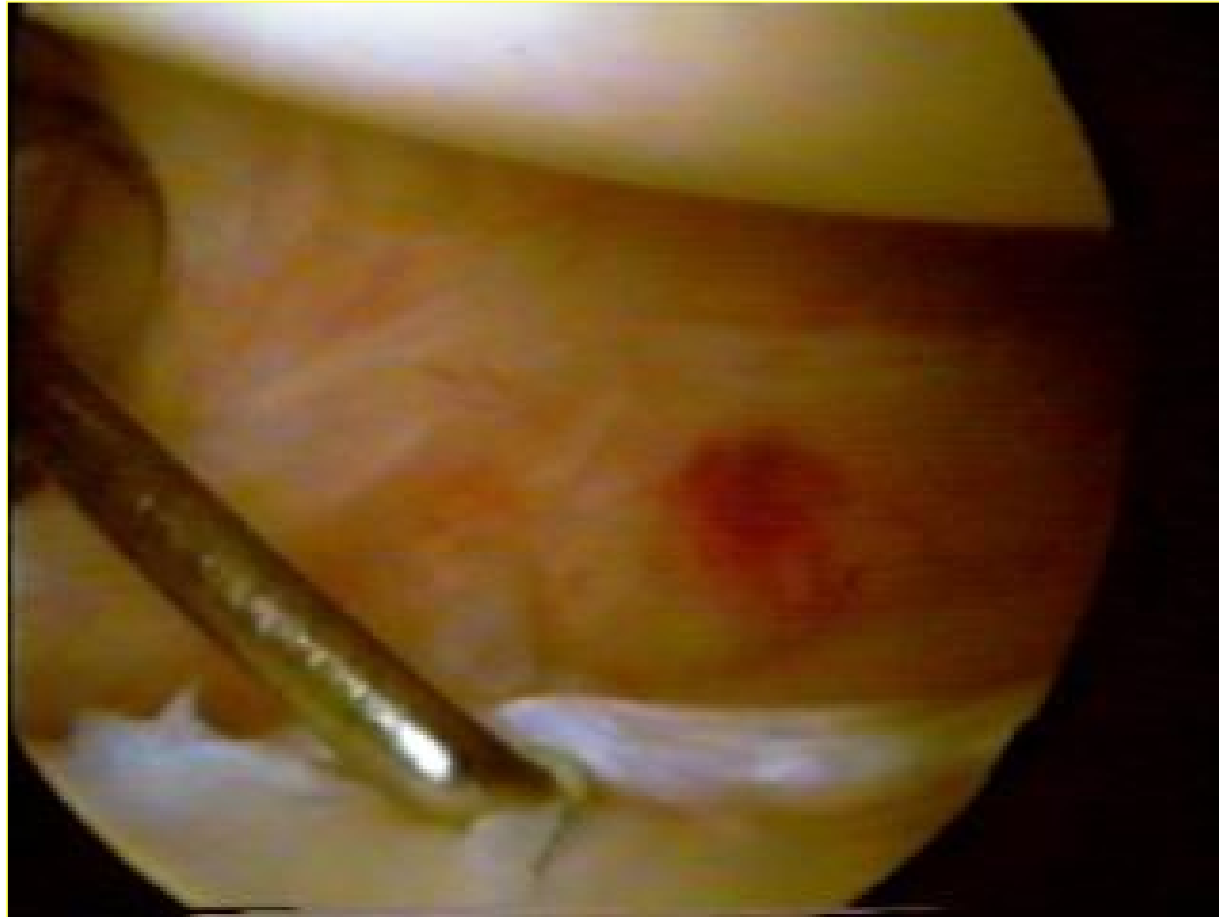Ventral defect of the labrum – **Bankart lesion**

→ ventral shoulder dislocation

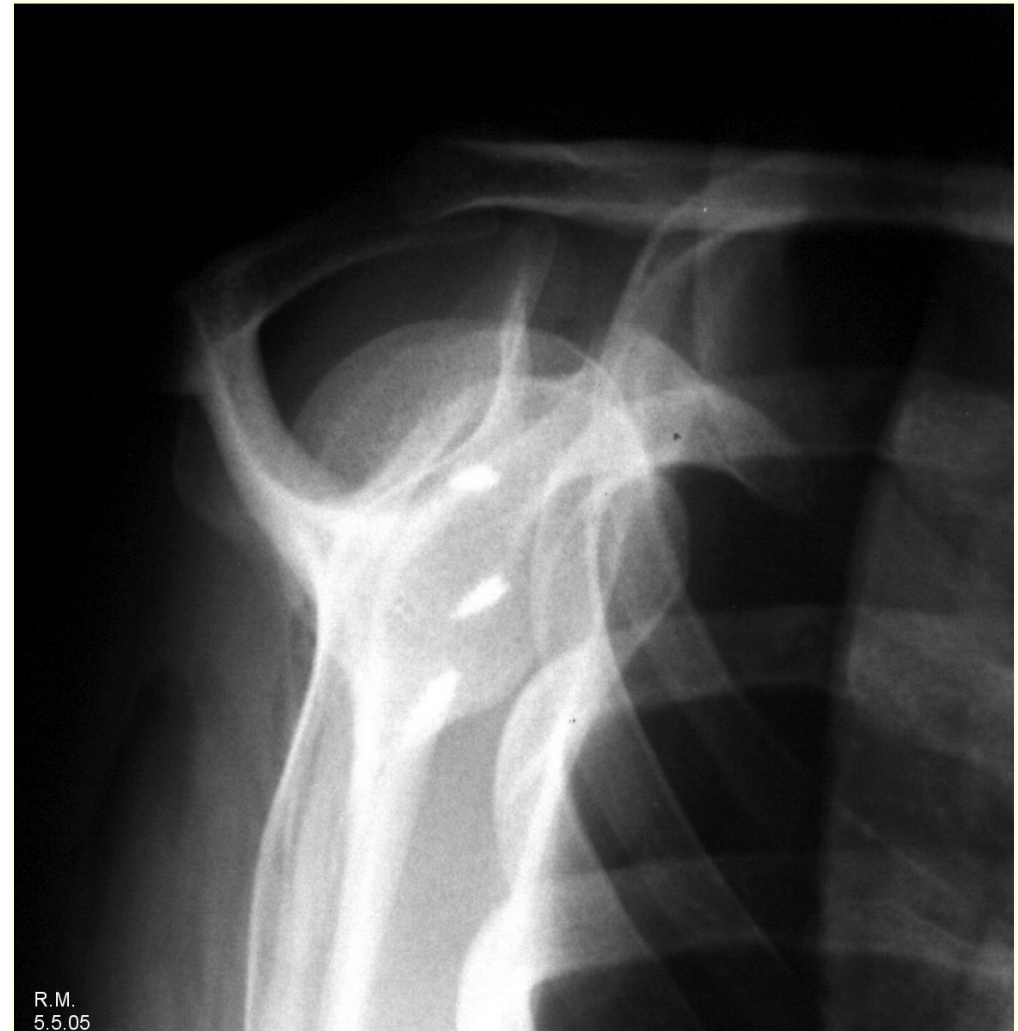
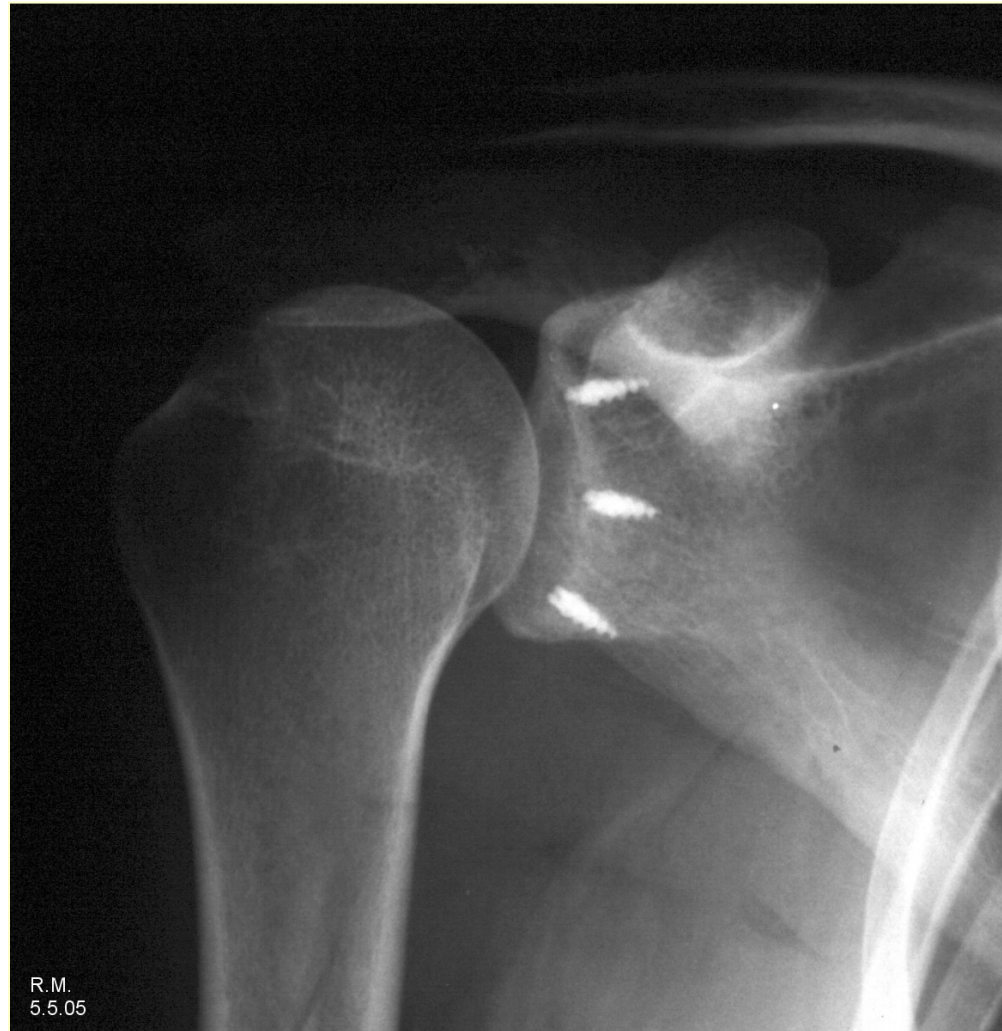Labrum destroyed / Hill Sachs lesion of the head



Restored labrum + capsule and fixed with anchors

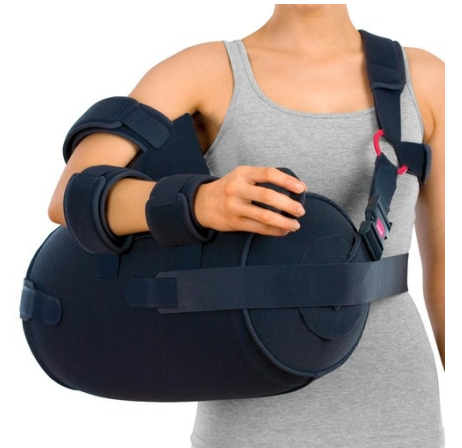
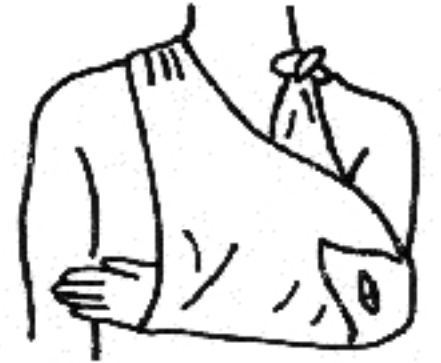
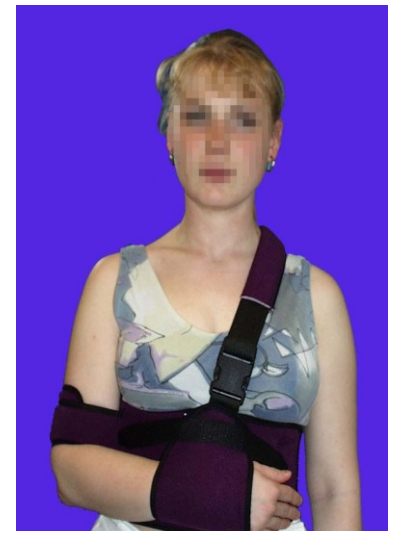Post op X ray



Post op fixation

- Labrum reconstruction - **Dessault orthosis** for 6/52
- SAD /decompression/ - **scarf bandage**, intensive RHB
- Rotator cuff suture - **Abduction splint** for 6/52 – 3/12



Open surgery

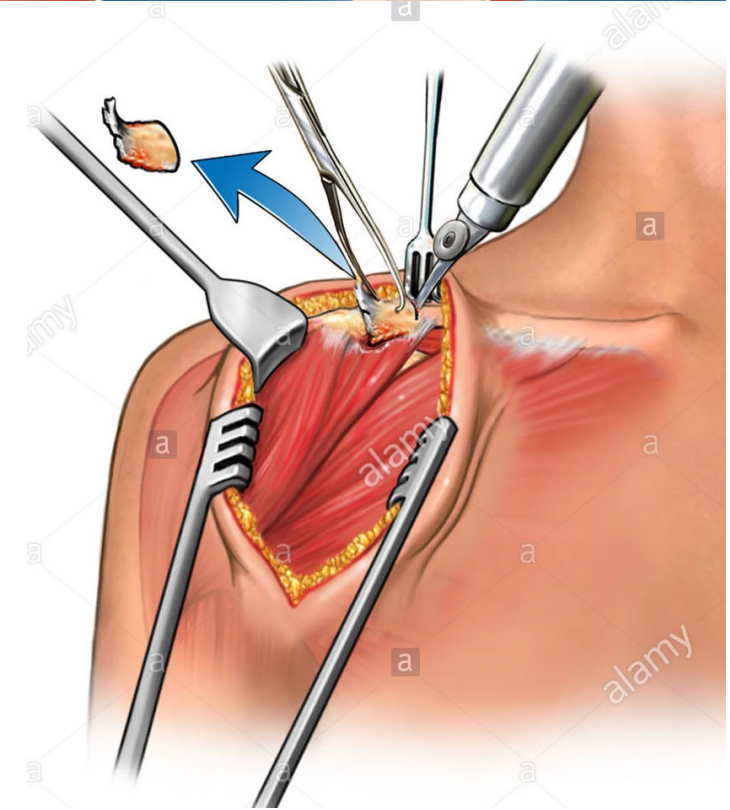
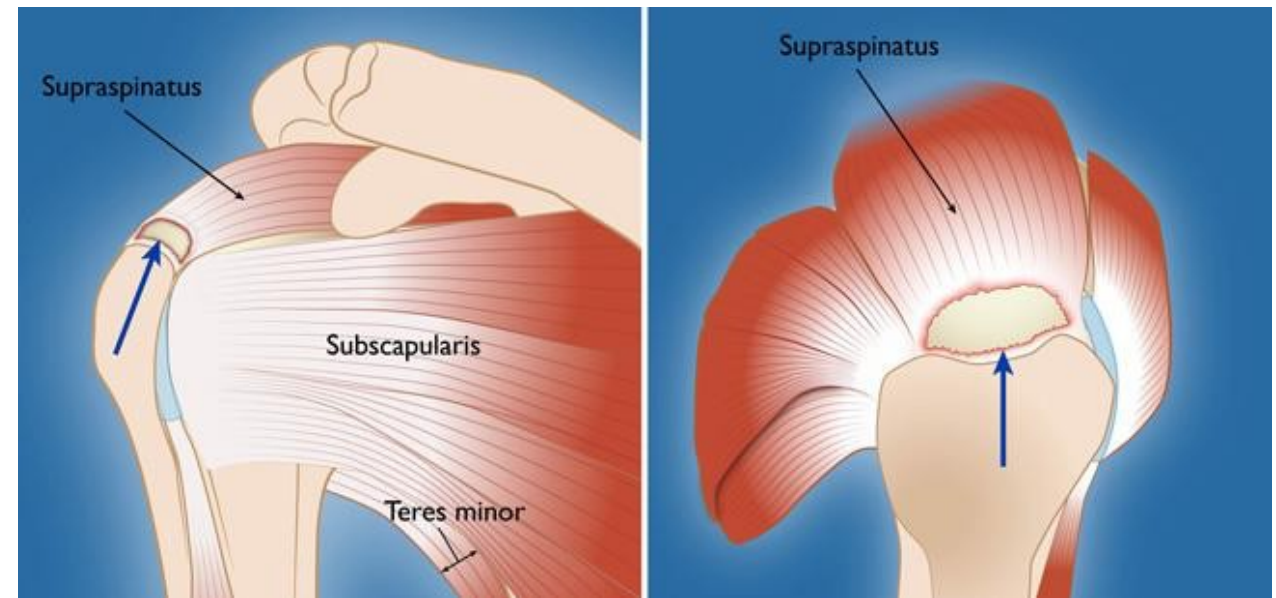
Mini-invasive approach

□ Rotator cuff repair/suture

/ **m. supraspinatus**, infraspinatus,
teres minor, subscapularis /

□ **Open Resection** of distal /lateral/ end of the clavicle

/ Stewart operation /



Wrist

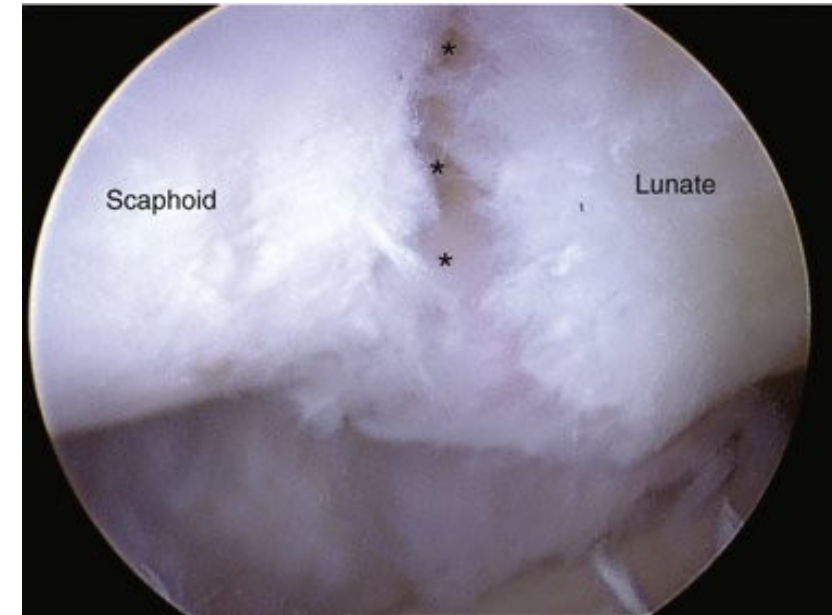
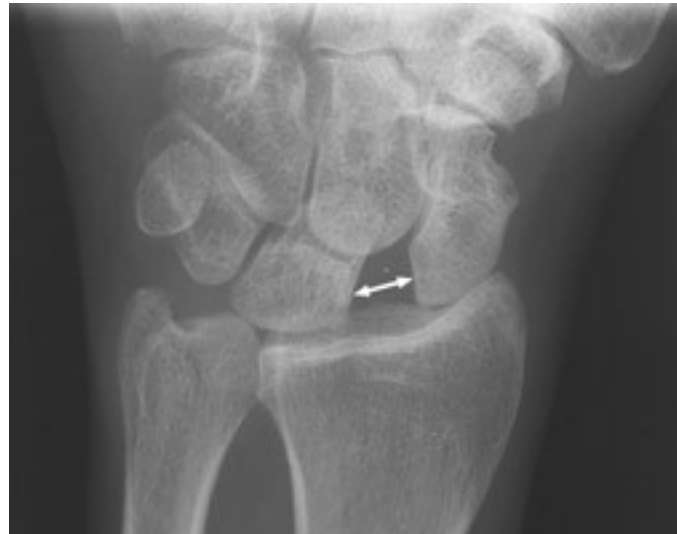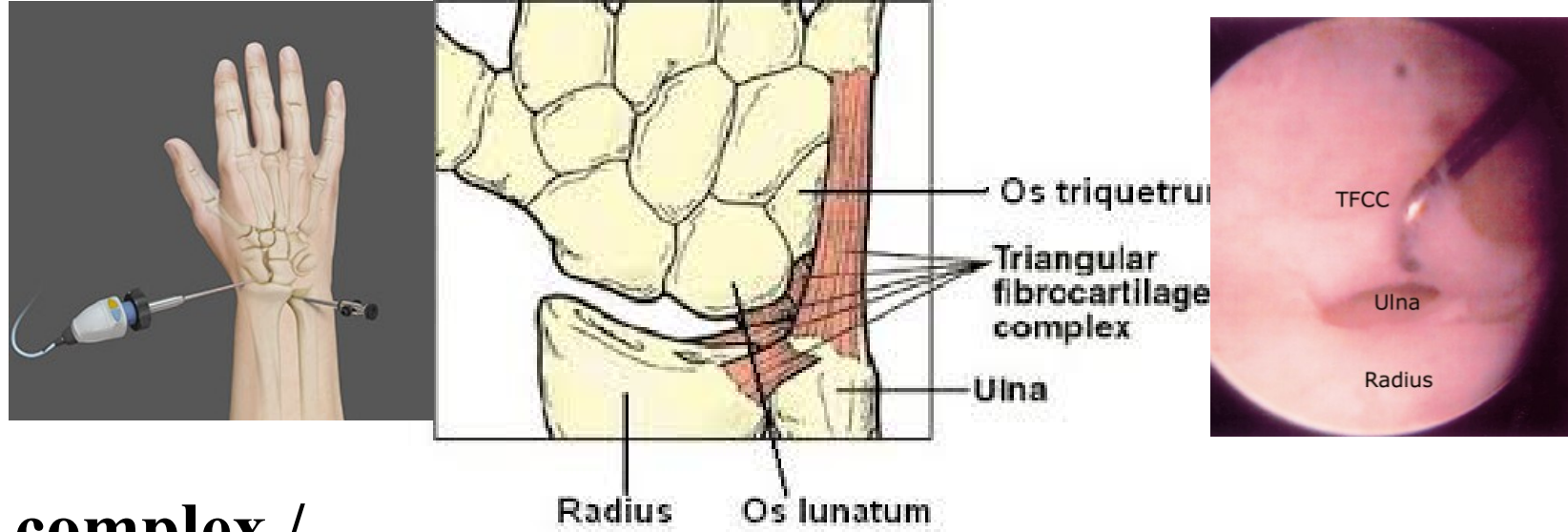
Smaller optics and instruments

No pump and tourniquet

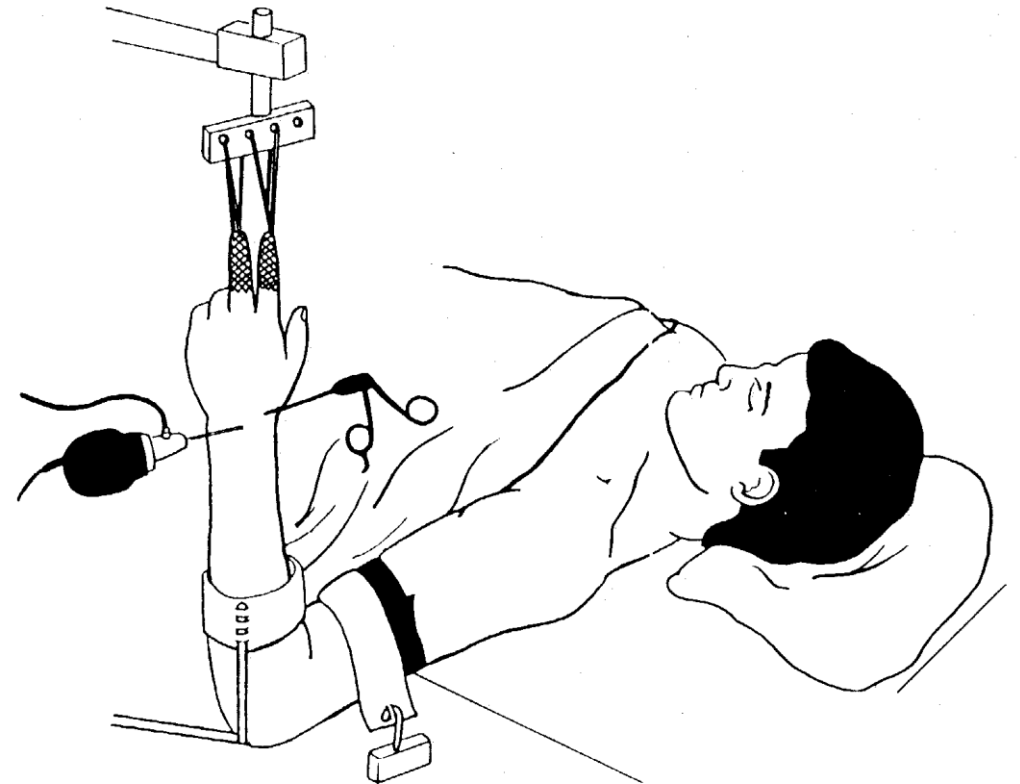
□ Pathology of TFCC

/ triangular fibrocartilage complex /

□ Scapho-lunate dissociation



- Wrist instability
- Partial excisions of the wrist
- Distal ulna/radius ostetomy
- Pseudoarthrosis ossis scaphoidei
- CTD carpal tunnel decompression
- Arthrodesis of the wrist and fingertips
- Synovectomy

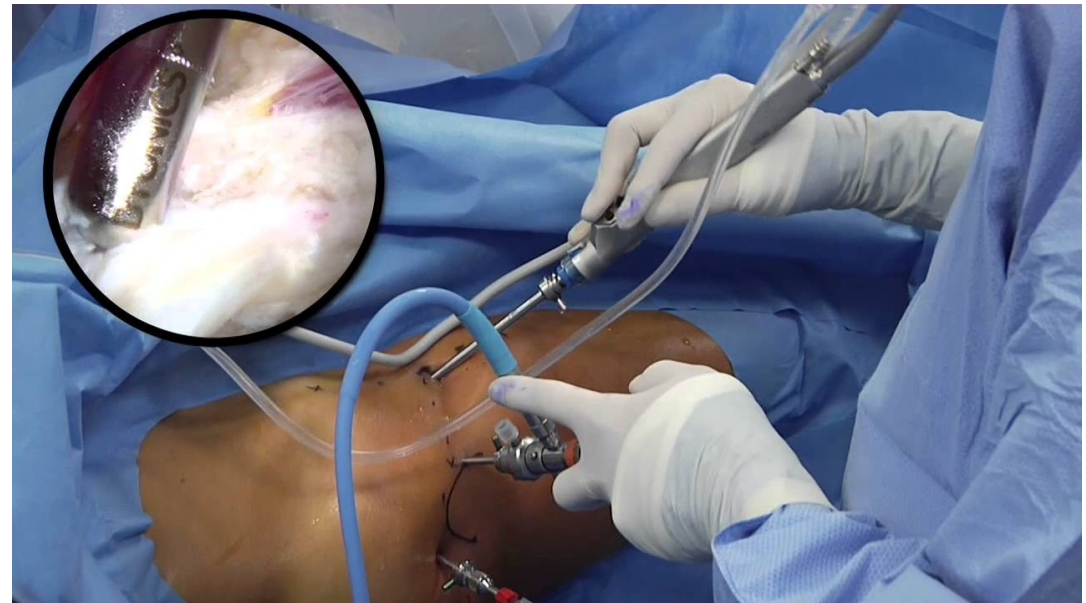
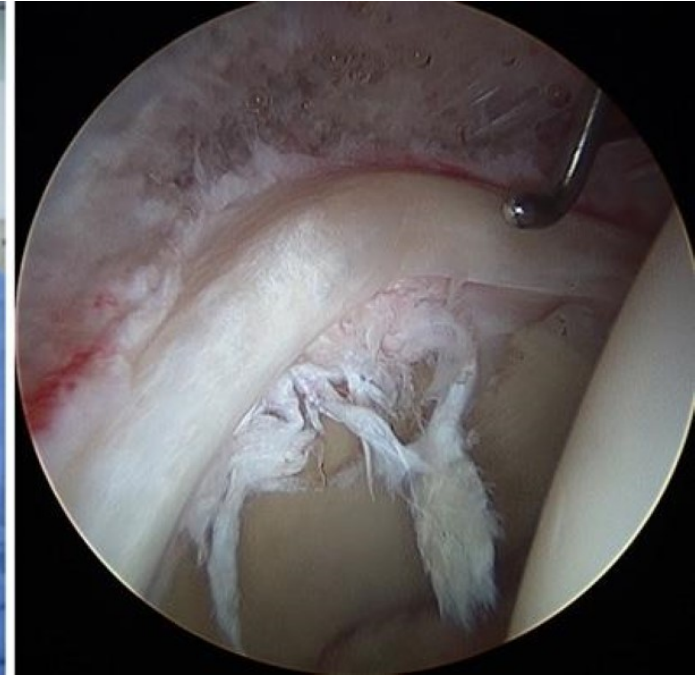
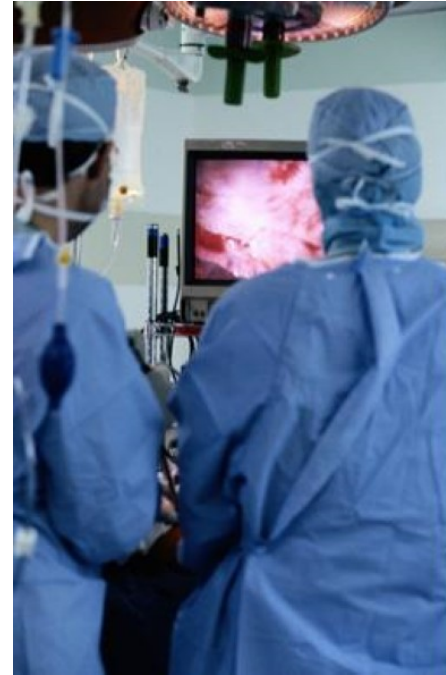open surgery...

Lower Extremity

Hip

- Post-traumatic /degenerative arthrosis
- Coxitis – debridement + lavage
- Foreign bodies removal
- Labral reconstruction
- FAI – Femoro-acetabular impingement repair



Knee

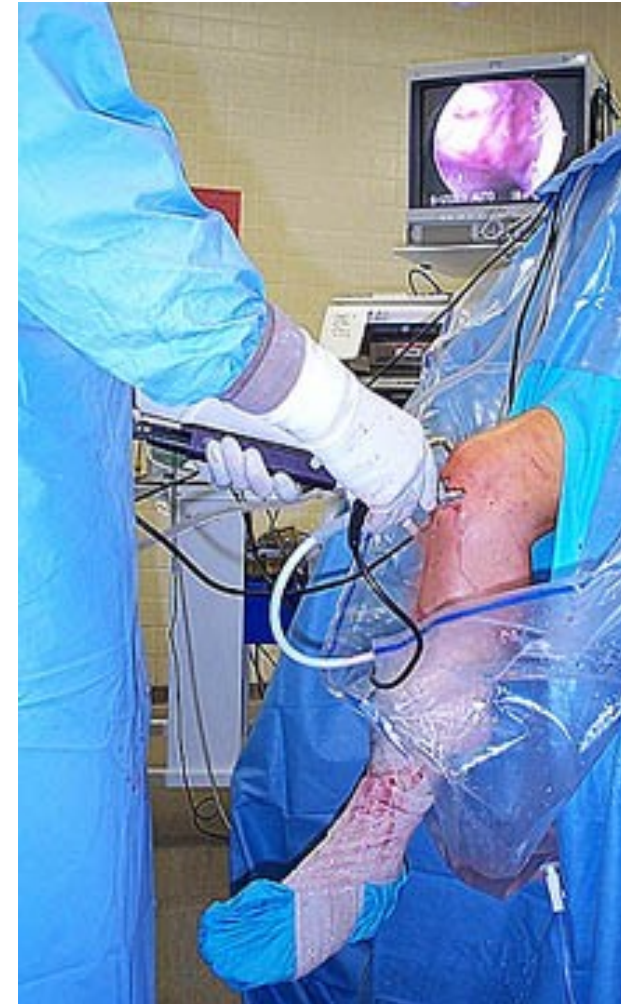□ Acute trauma: haemarthros

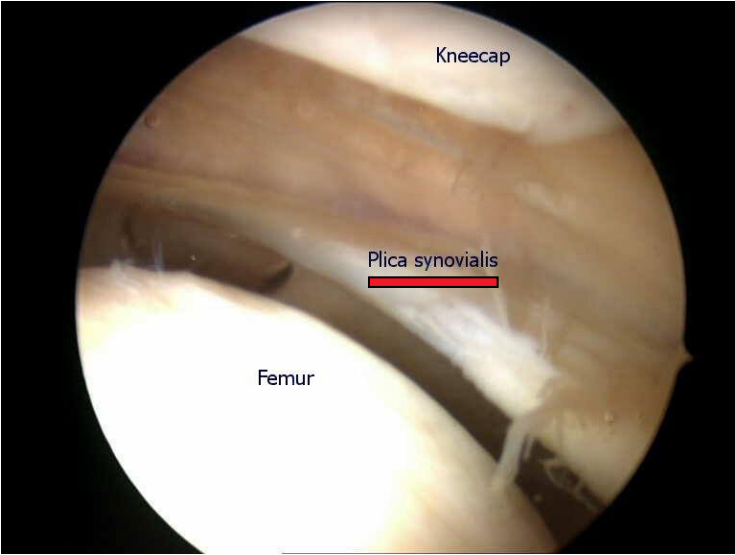
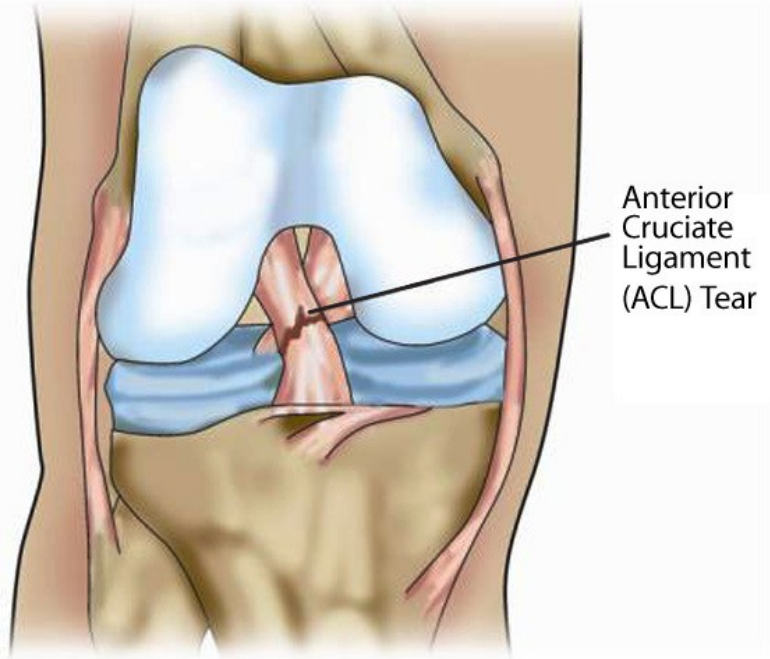
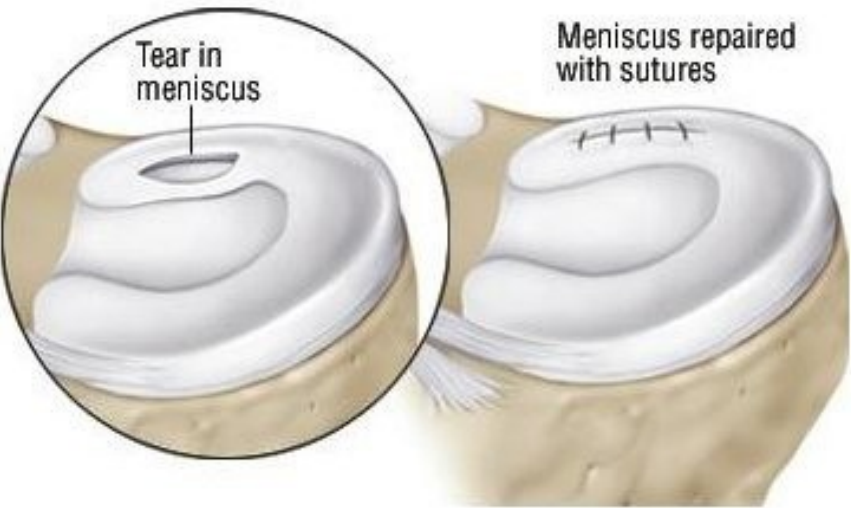
Instability – rpt ACL/PCL

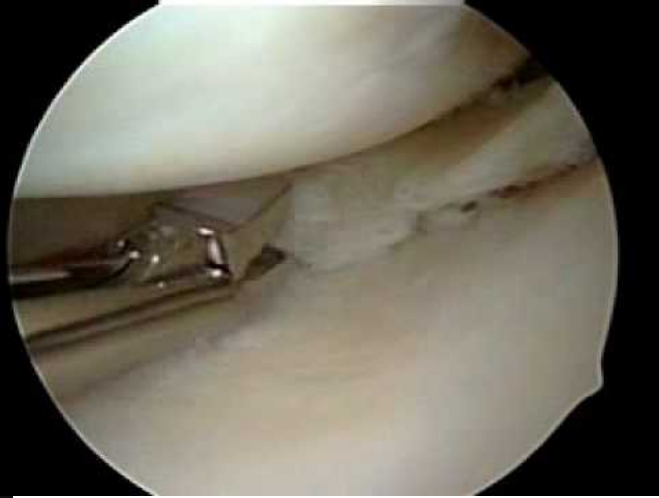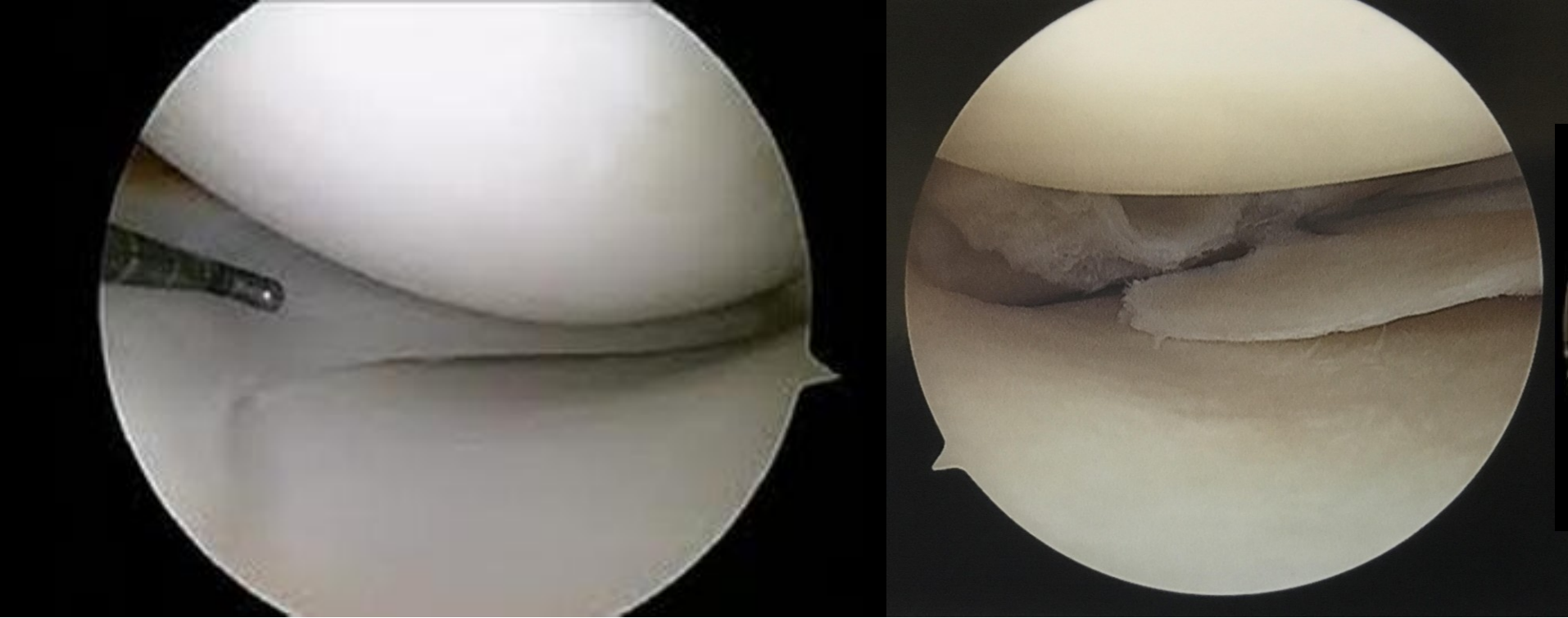
□ Infection / gonitis - lavage

□ Osteoarthritis - debridement

□ **Meniscus repair/resection, LCA/PCL reconstruction, plica resection, chondral defects, foreign bodies removal, patellar release,....**







ACL /Ligamentum cruciatum anterius/ reconstruction – sec. Brückner

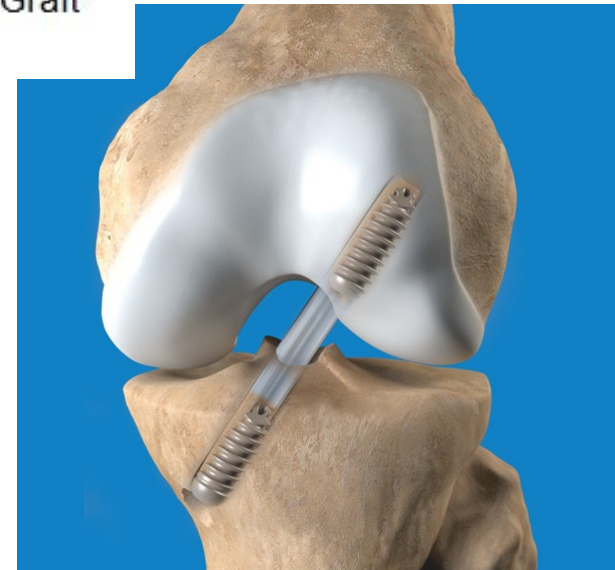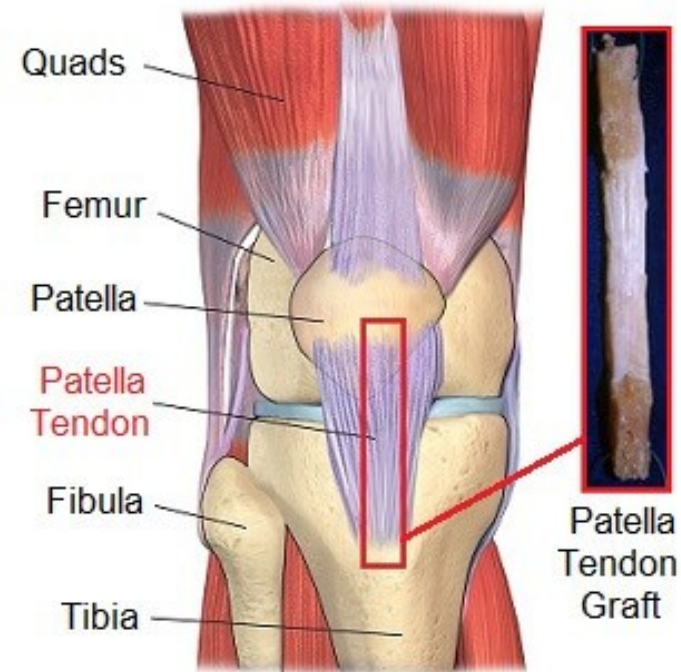BTB – Bone - Tendon – Bone

Bony parts for patella and tibial tubercle

Tendon graft from lig.patellae

Stronger graft compared to hamstrings

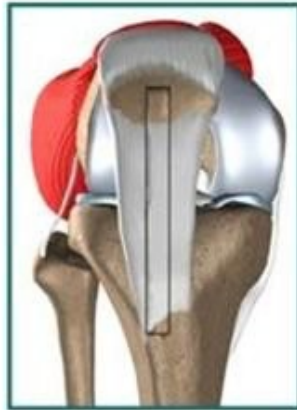/ m. gracilis, m semitendinosus /



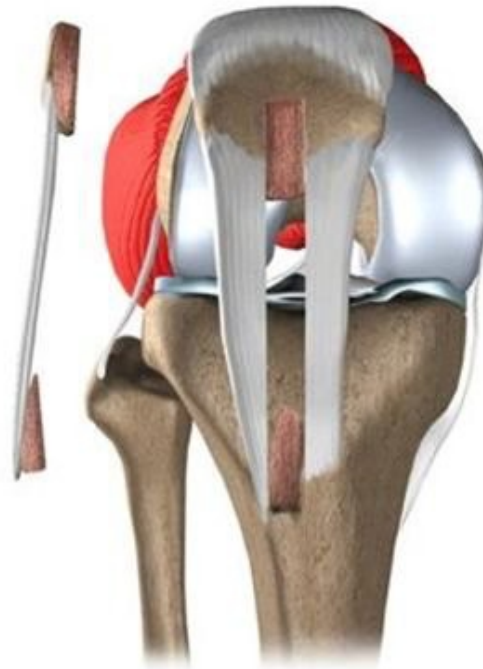ACL Repair Anatomy

Patellar Tendon Graft

Ipsilateral middle third patellar tendon.¹



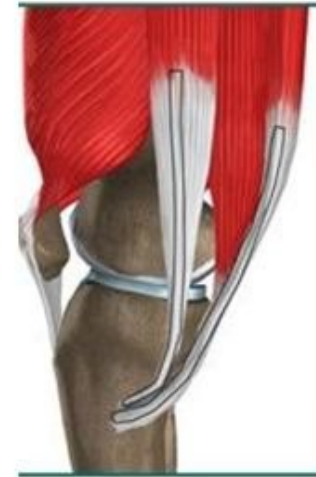Middle third of patellar ligament cut and removed



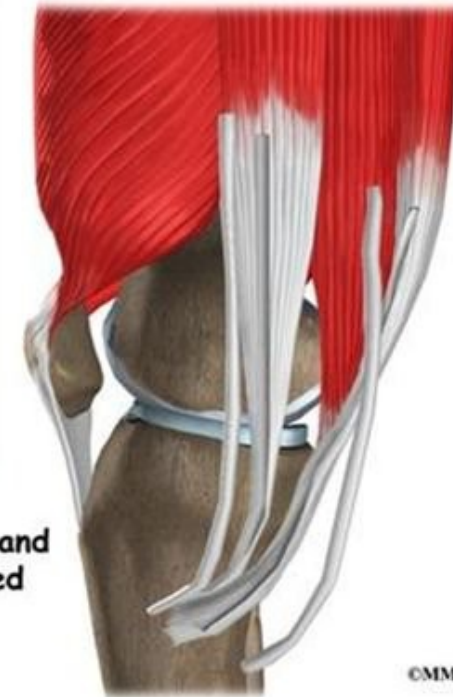
©MMG 2000

Hamstring Graft

4-strand gracilis/semitendinosus tendons¹



Parts of semitendinosus and gracilis tendons removed



©MMG 2000

Chondral defects

□ Mosaicplasty

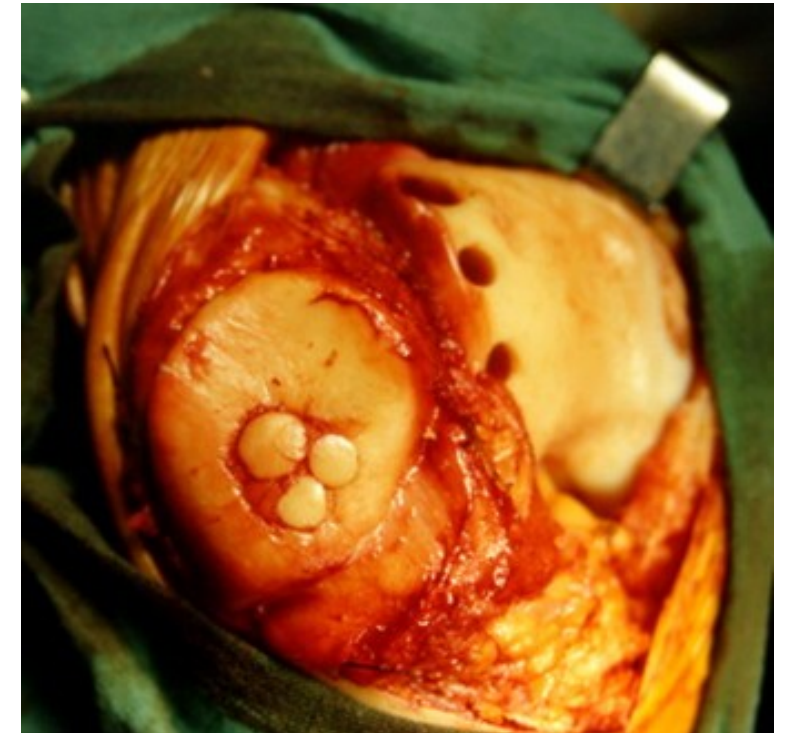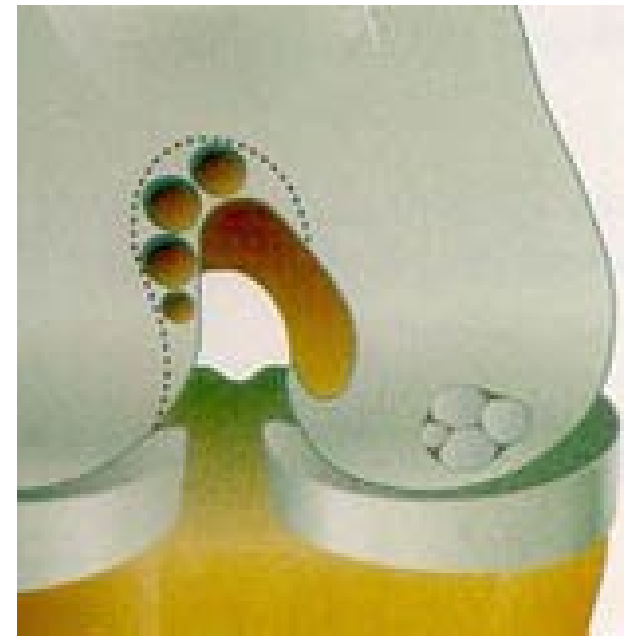osteochondral blocs taken from non-bearing zone

□ Autologous chondrocytes transplantation

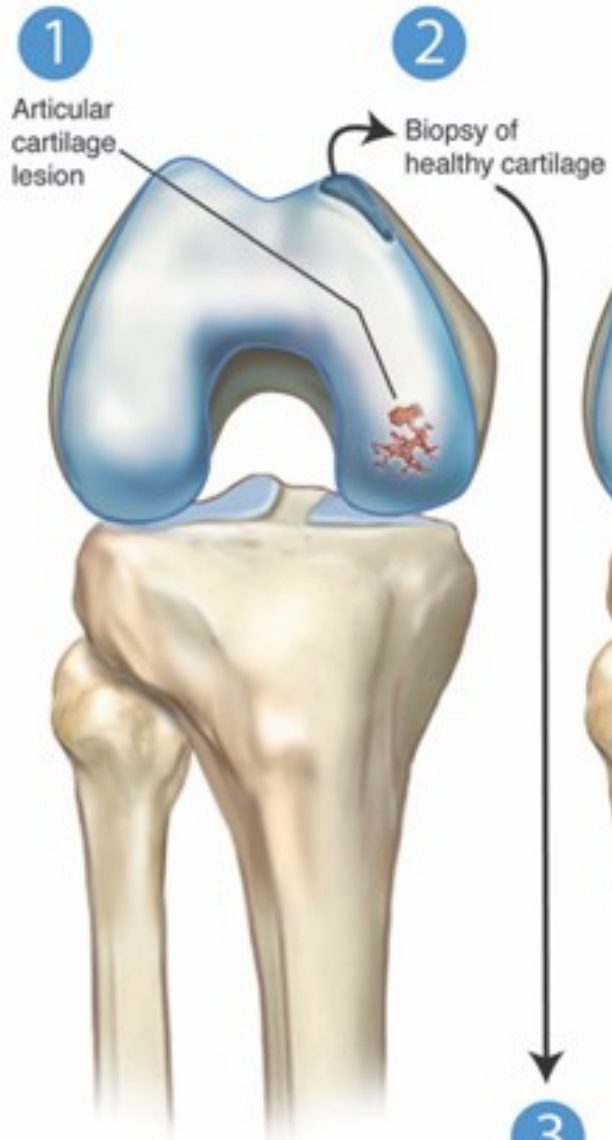
taken healthy parts of cartilage – multiplication
after 6 weeks open implantation on the carriers –
scaffolds to the defect

□ Allogeneic chondrocytes transplantation

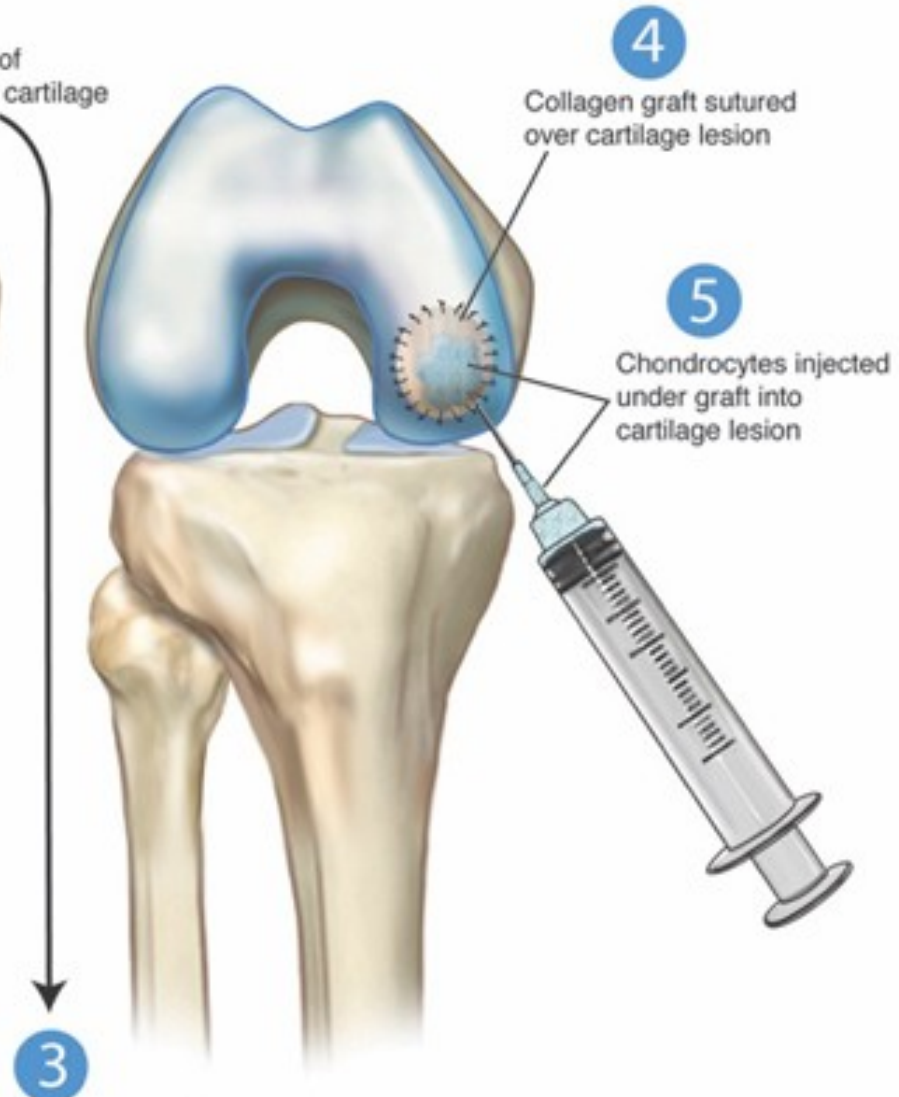
(USA)



ARTHROSCOPIC BIOPSY

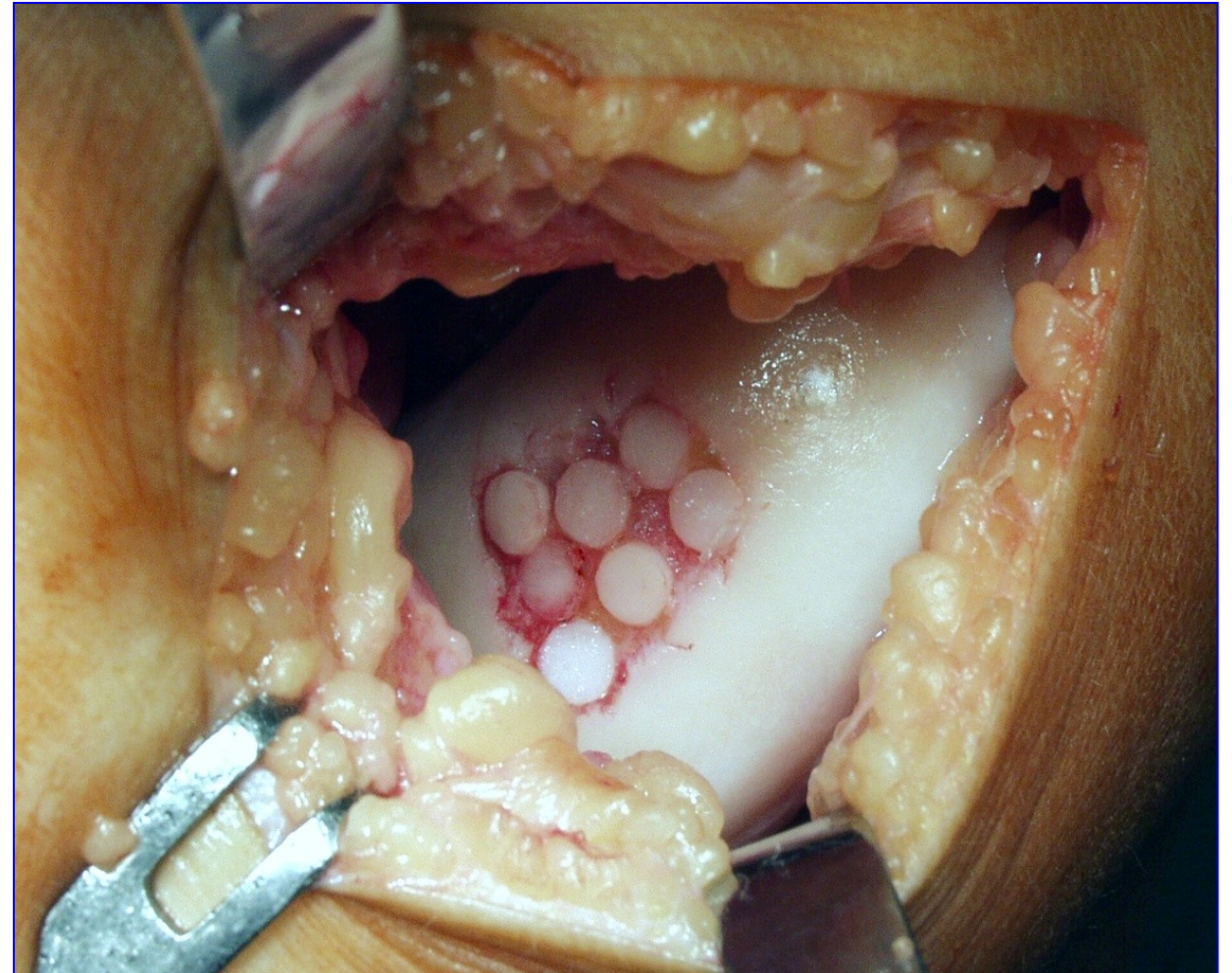
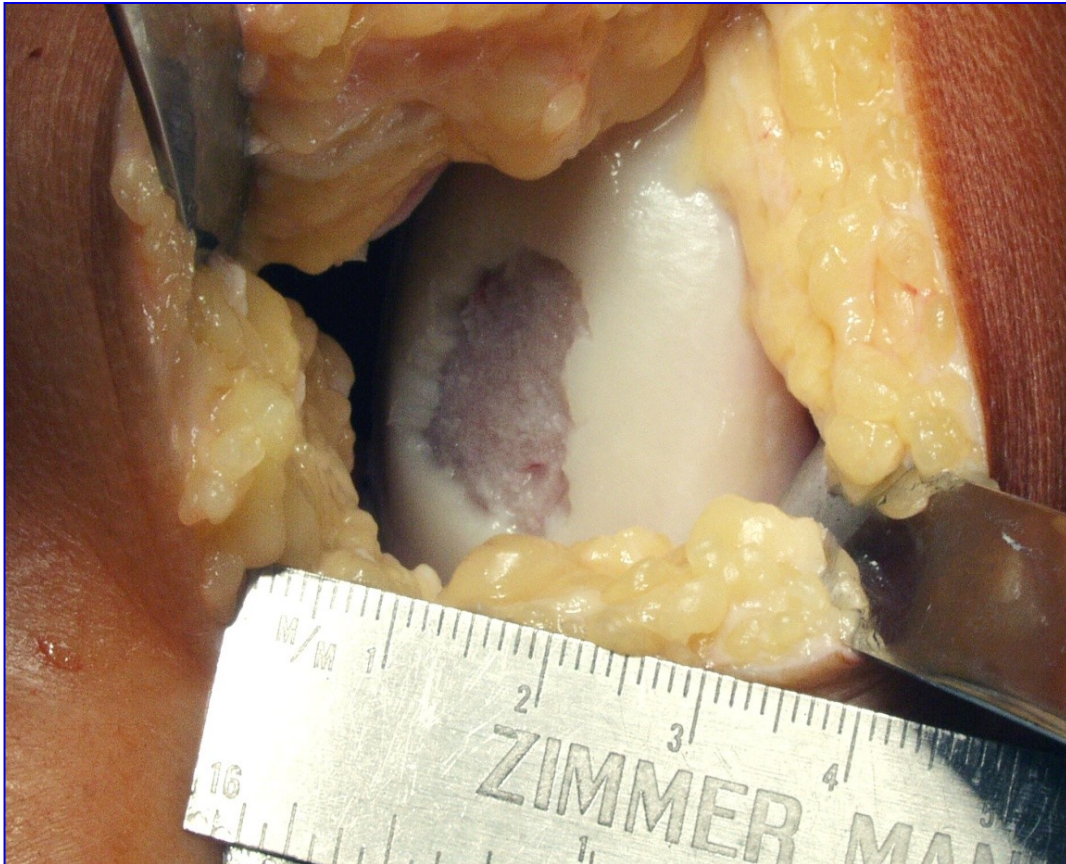


OPERATION

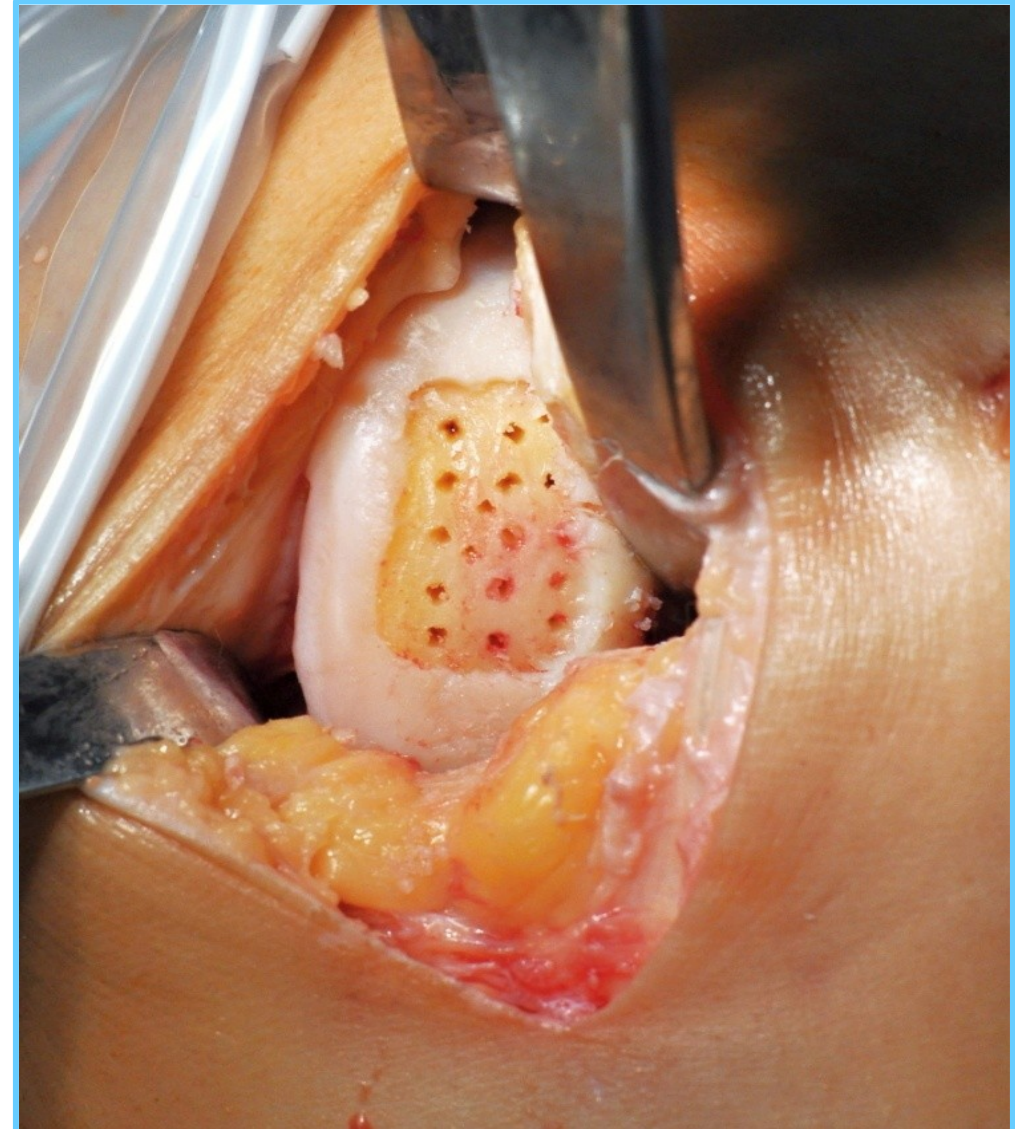
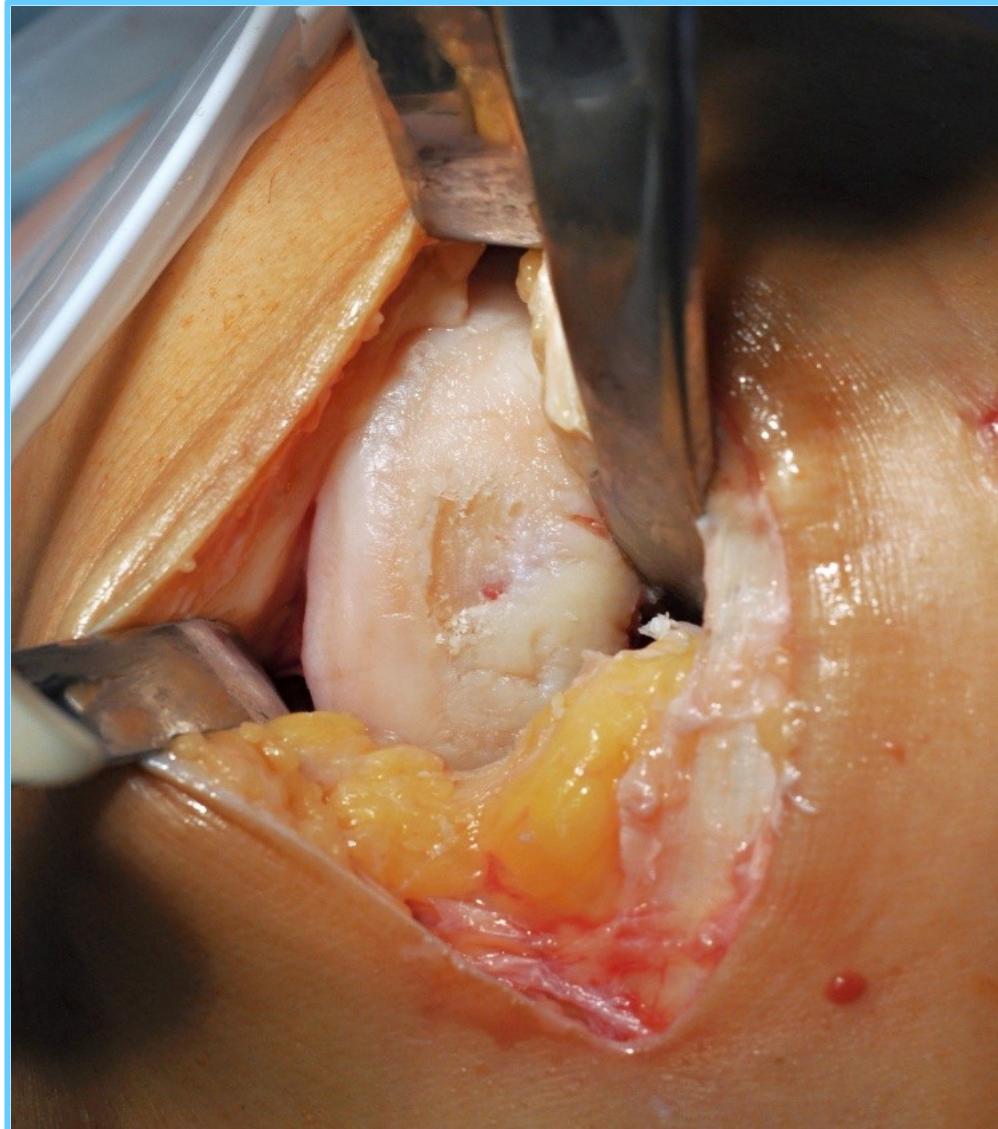


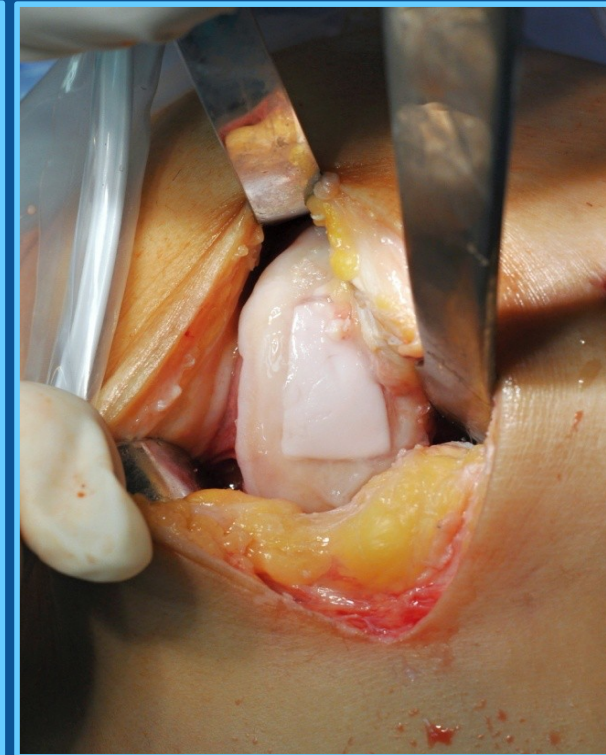
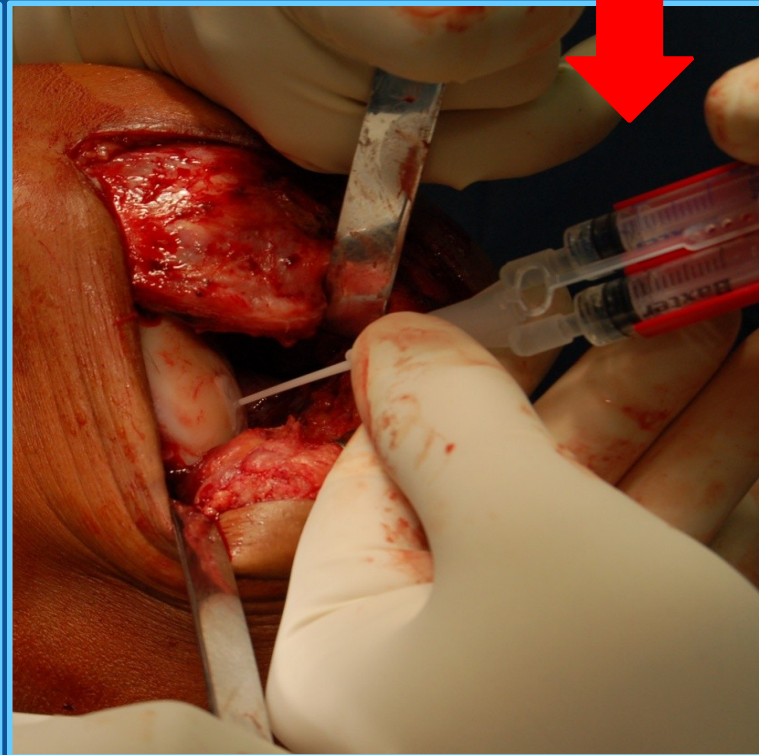
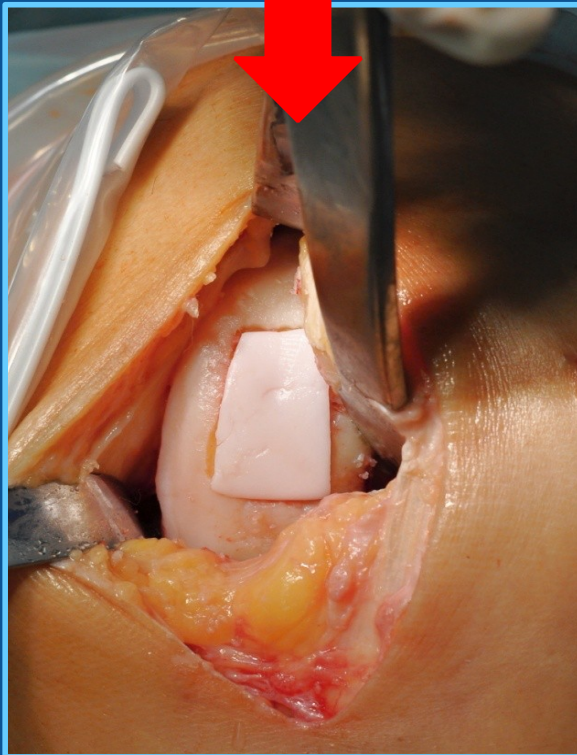
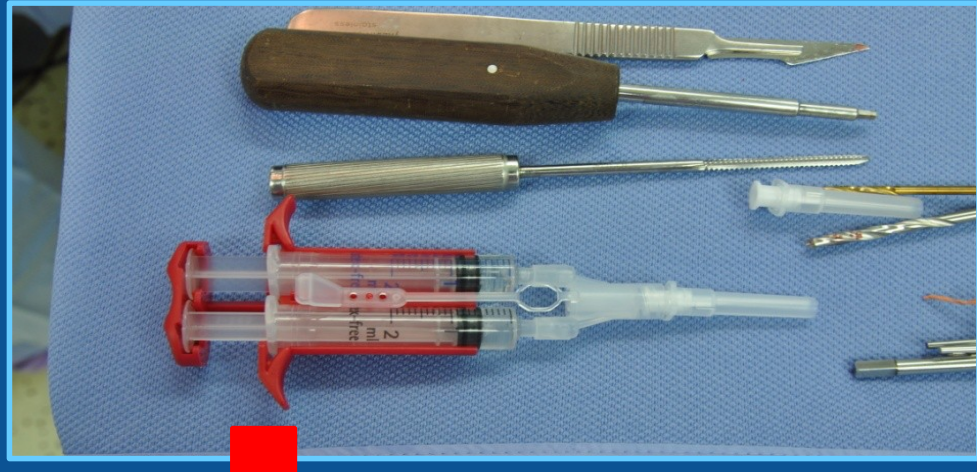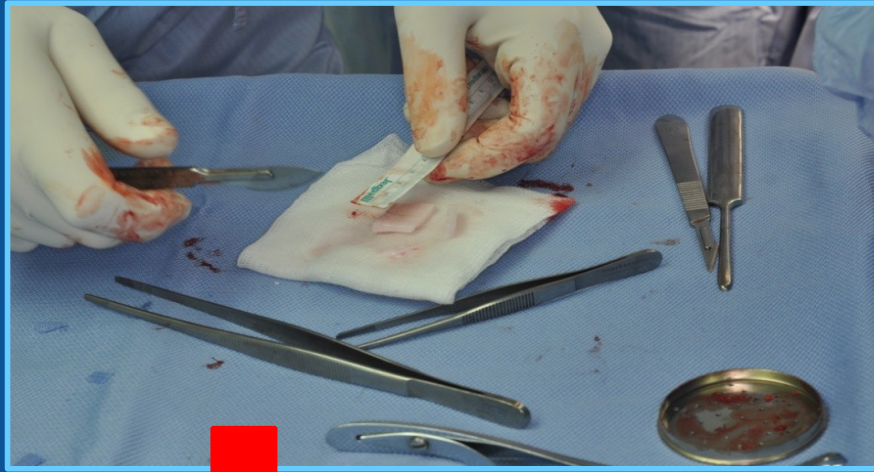
Cartilage cells sent to laboratory, millions of chondrocytes grown

□ Mosaicplasty



□ Autologous chondrocytes transplantation - **chondrograft**





ATC – Ankle Arthroscopy

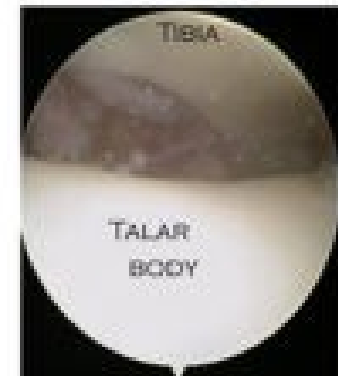
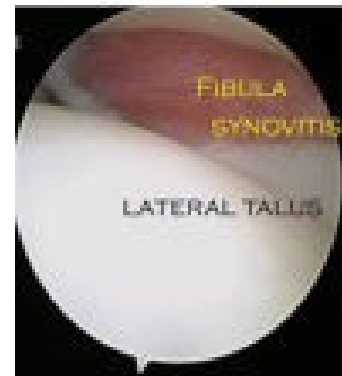
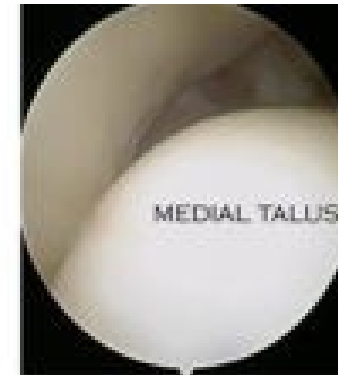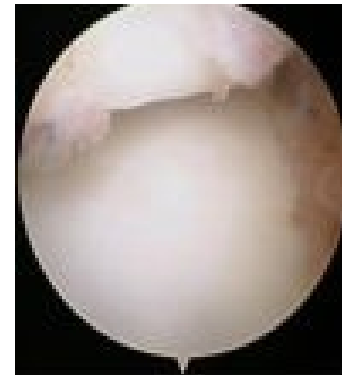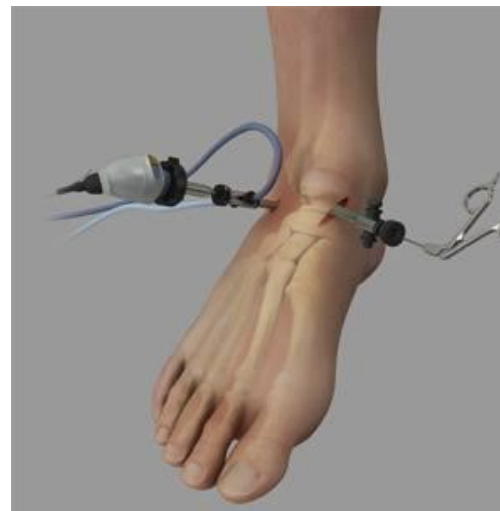
□ Acute injury

□ Degeneration

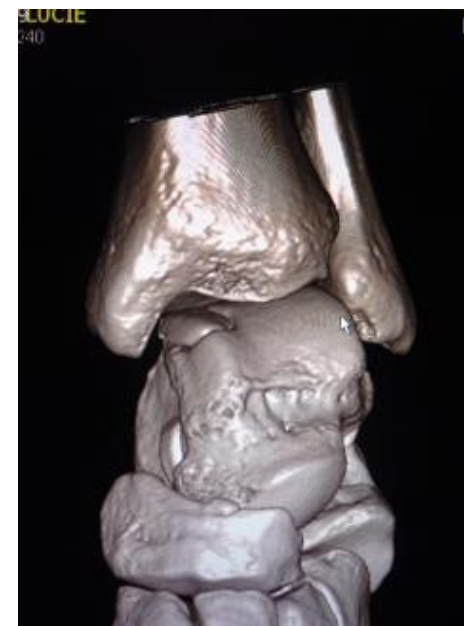
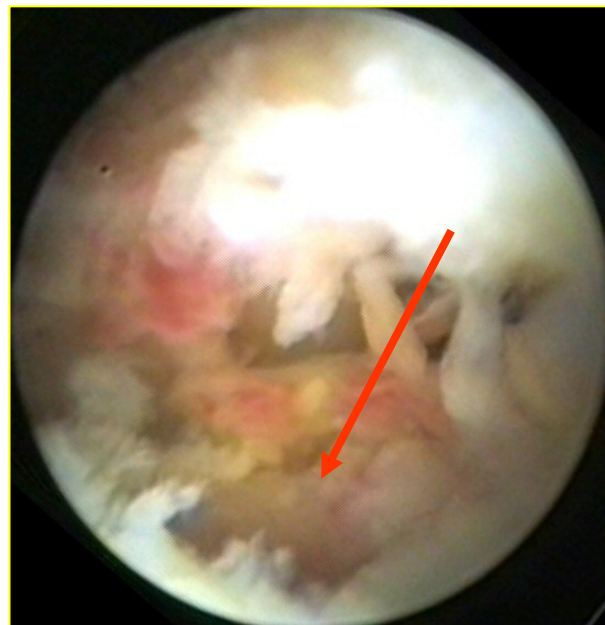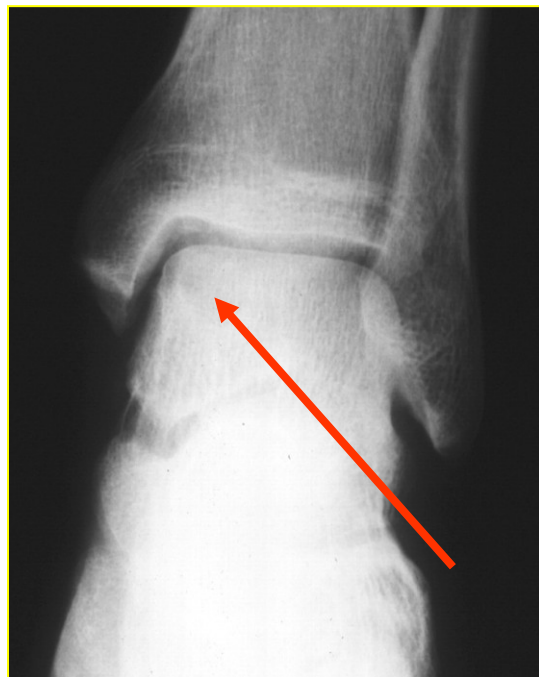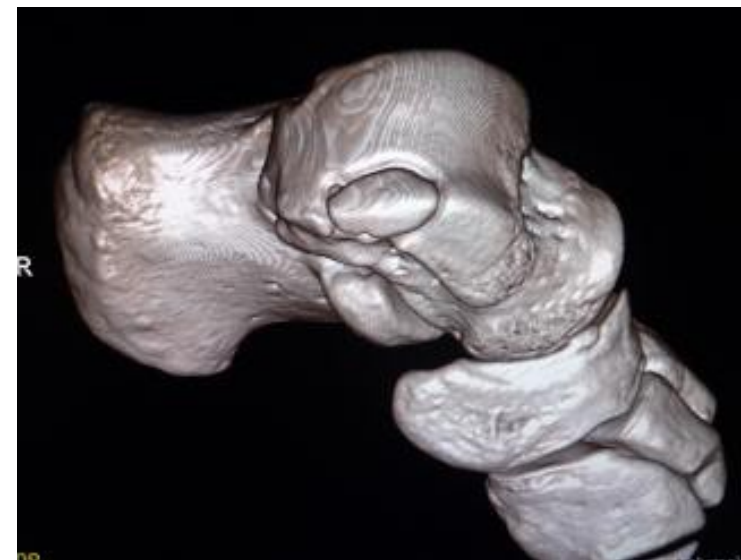
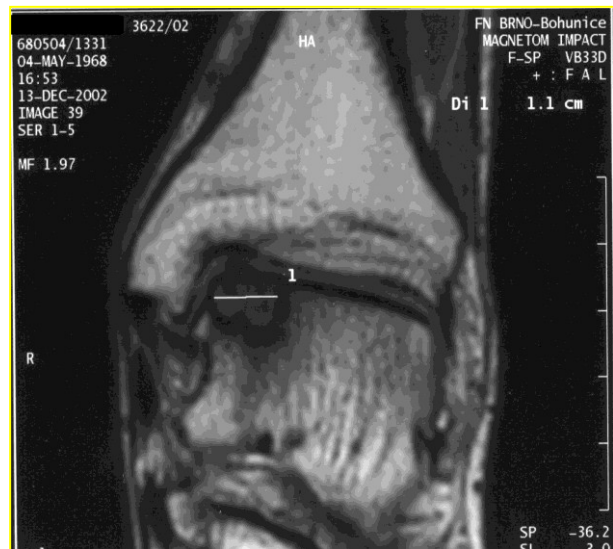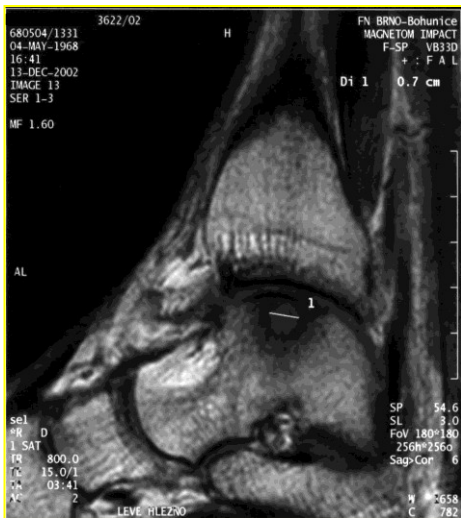necrosis

ostechondritis dissecans

chondral defects



Osteochondrosis dissecans / OCHD /

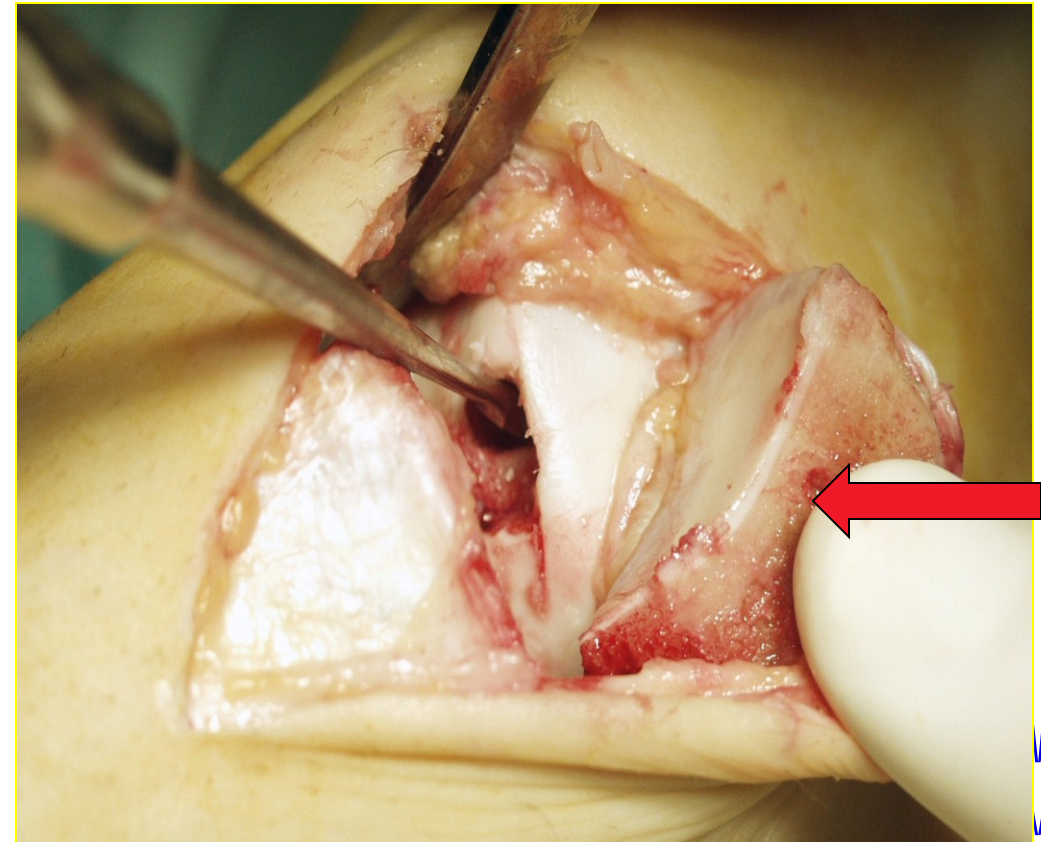
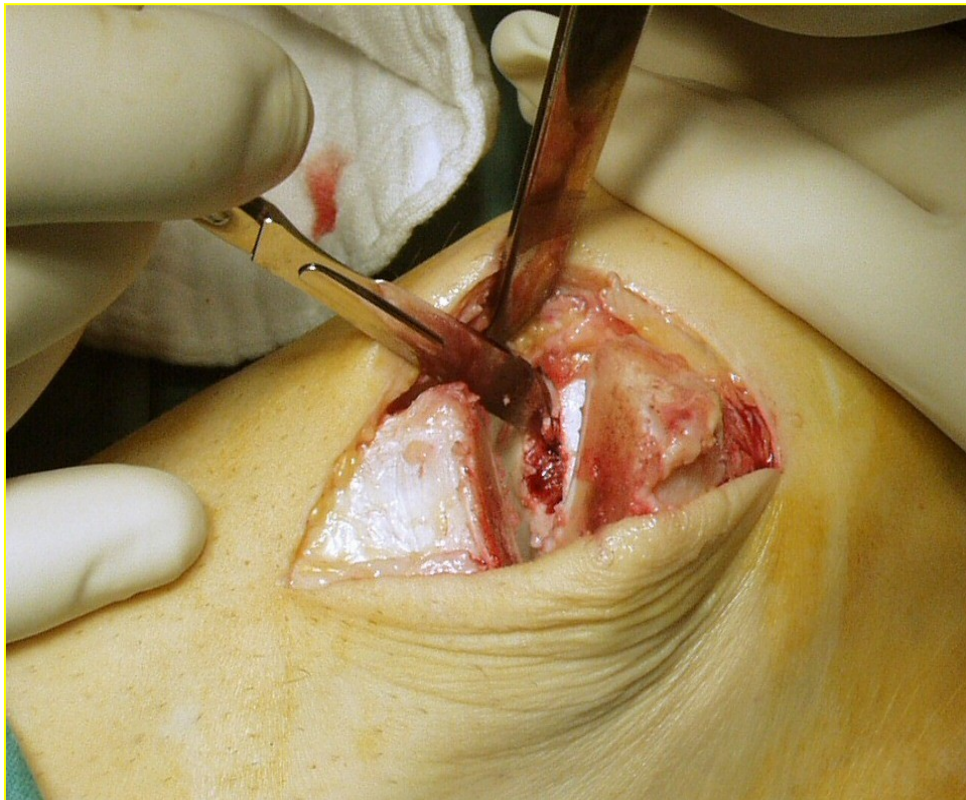


OCHD

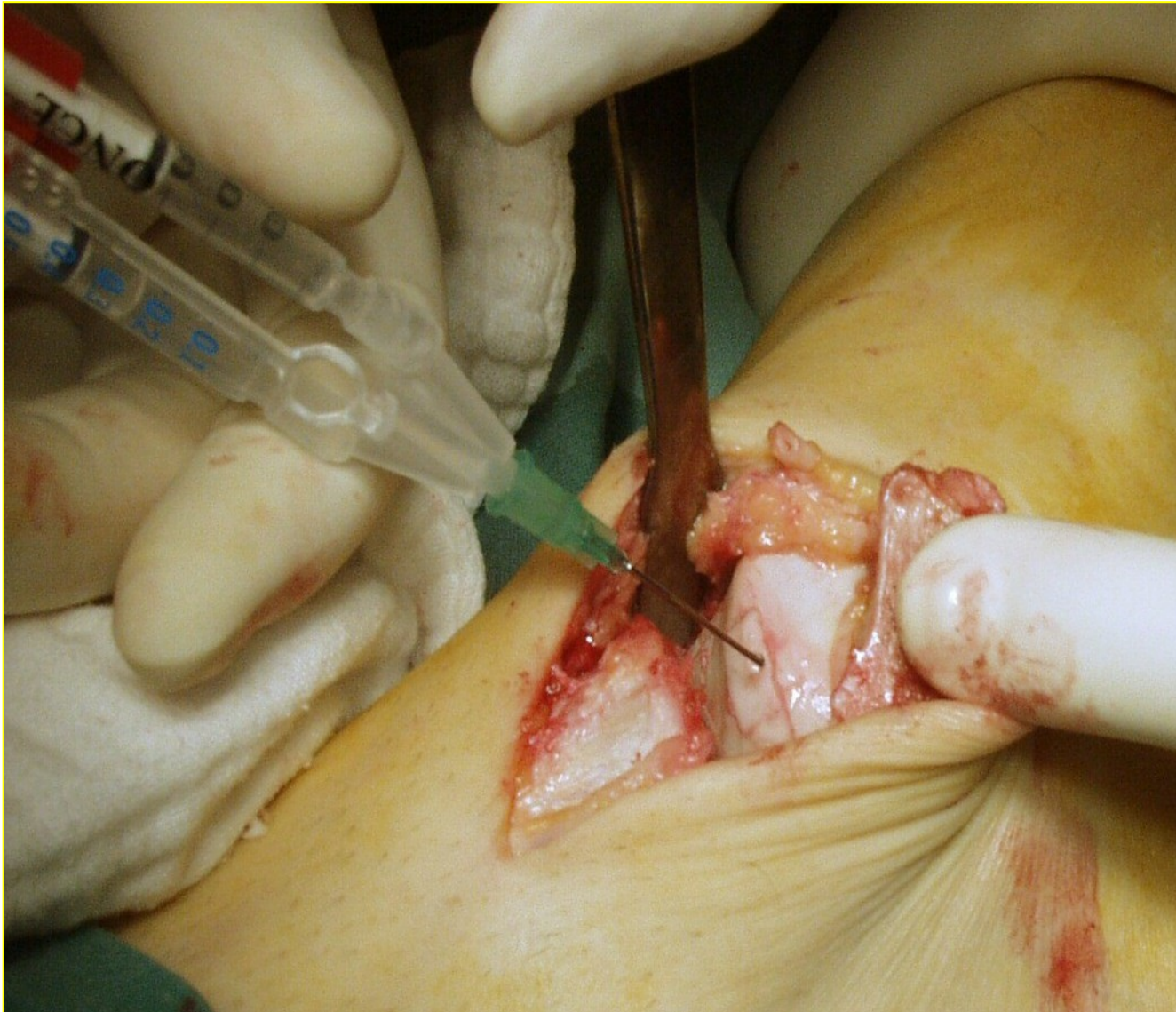
➡ necrotic bone – debridement, use chondrograft

➡ healthy bone – fixation back with the screw

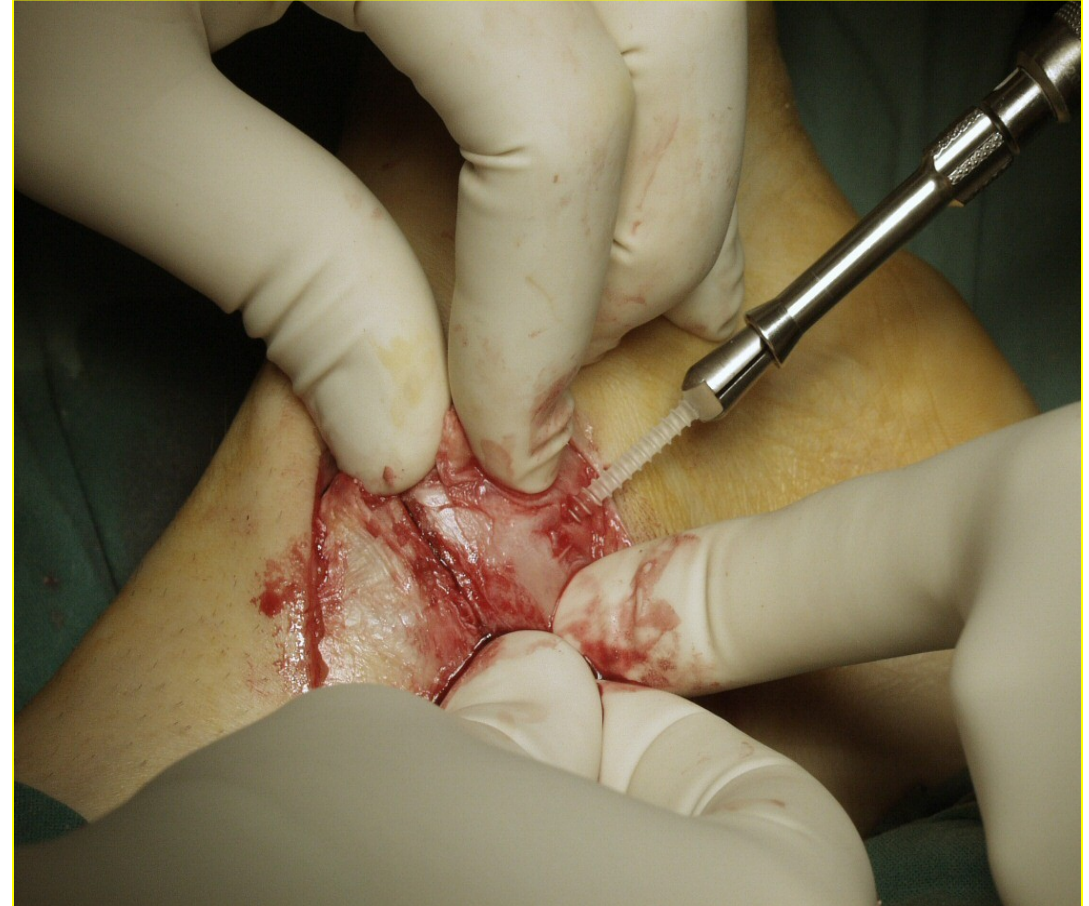Medial Malleolus ostetomy



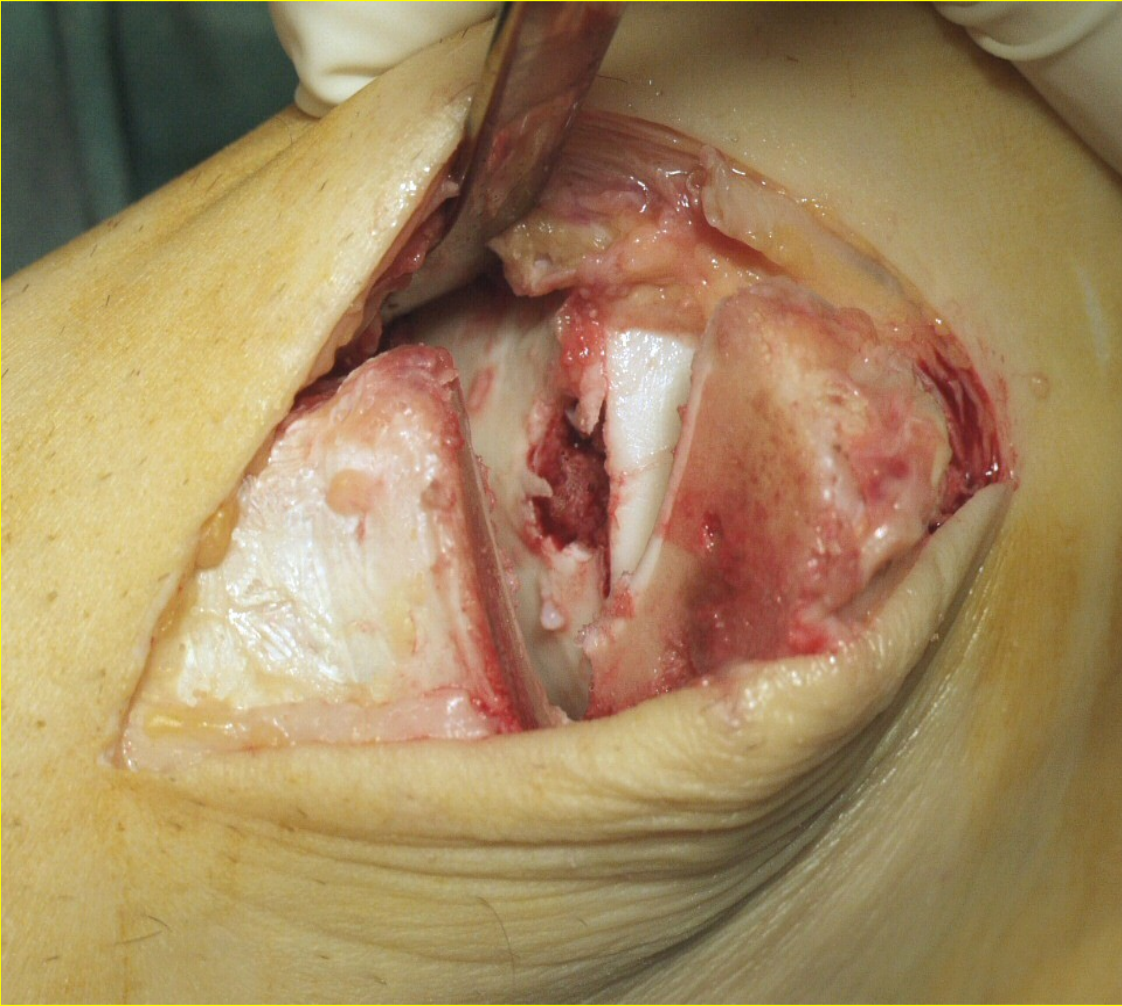
Chondrograft fixation



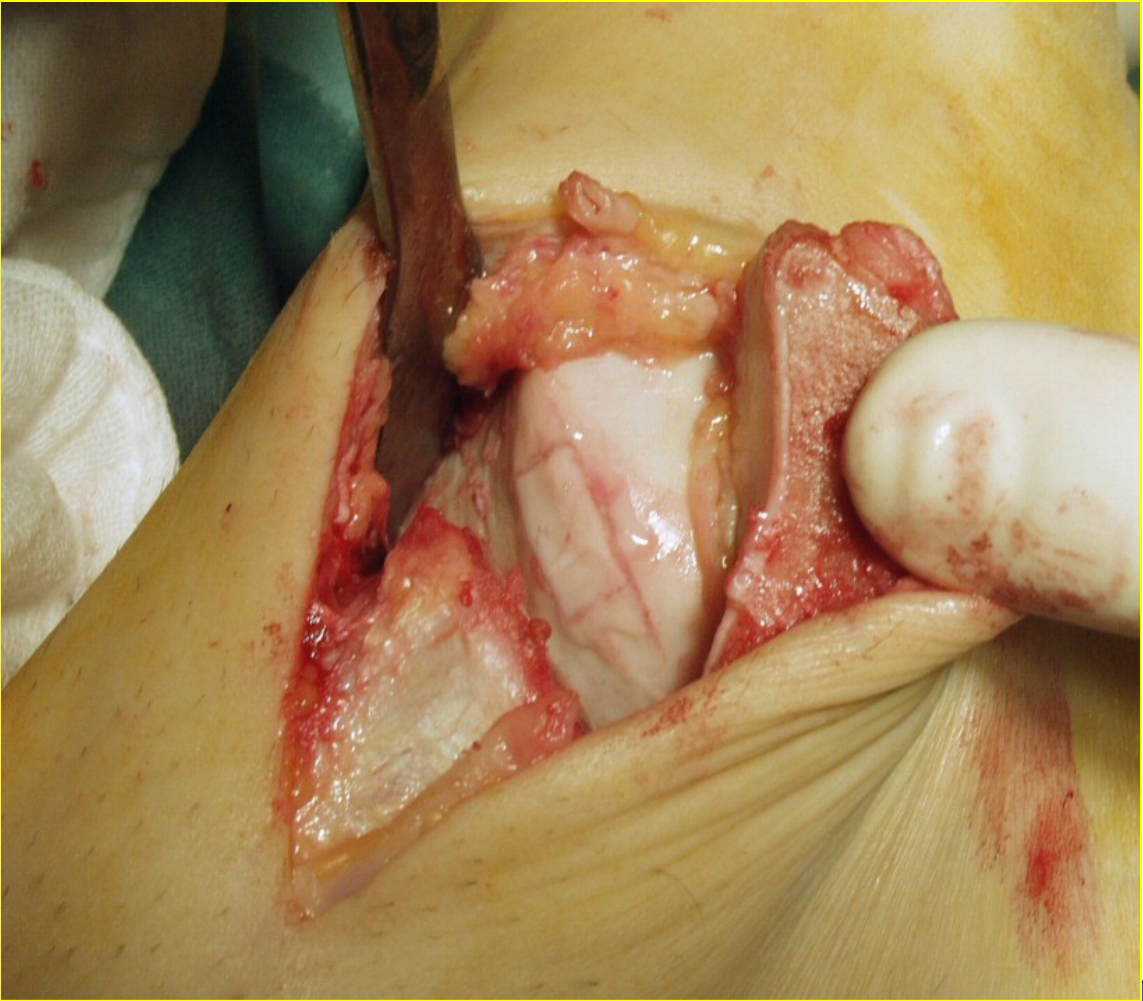
Screw fixation of medial malleolus



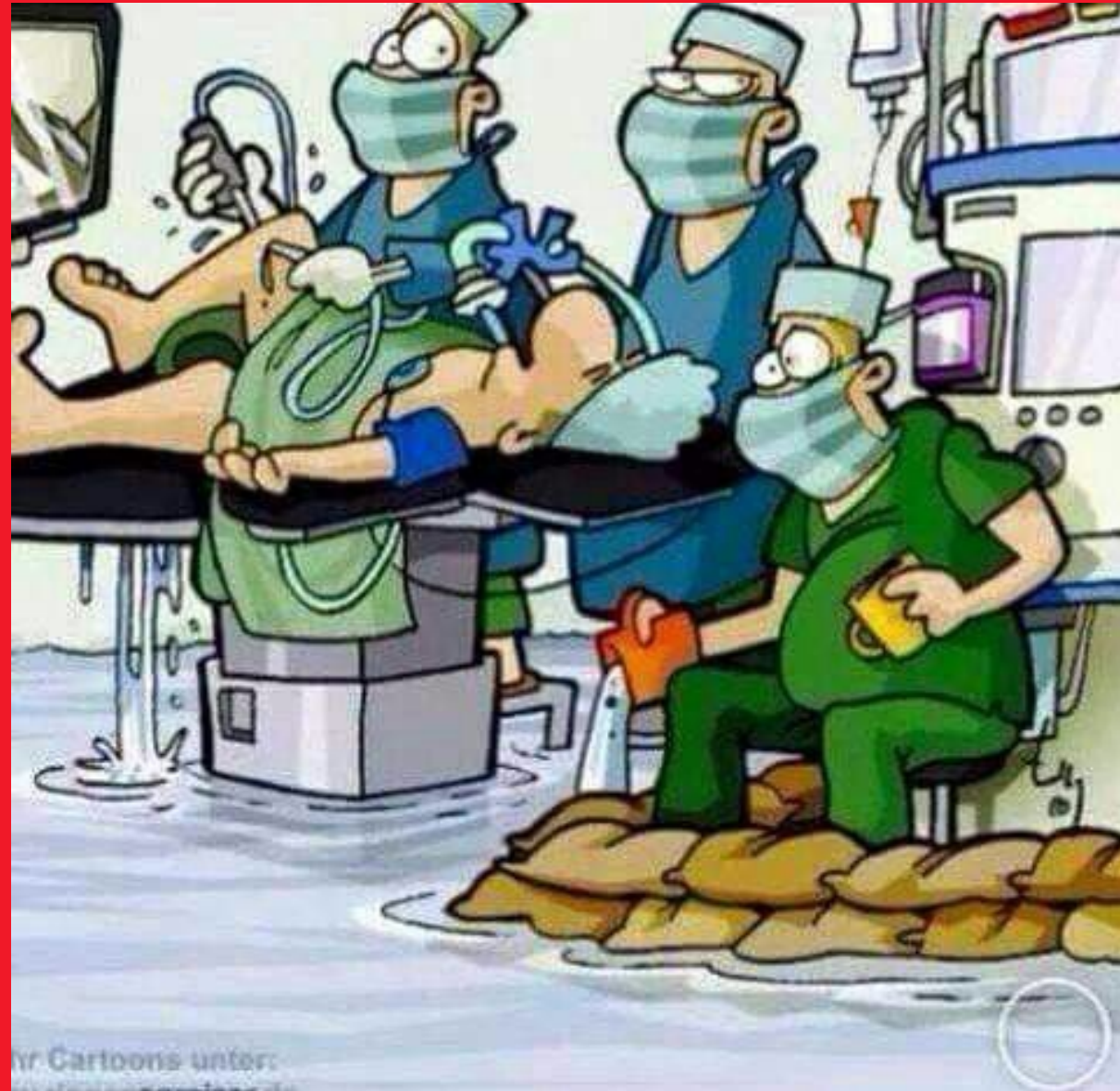
before



after



MUNI
MED



Thank you for your attention

M A S A R Y K O V A
U N I V E R Z I T A