

# IMMUNOLOGIC DEFICIENCY SYNDROMES

V. Žampachová  
I. PAŮLF MU

# IMMUNODEFICIENCY

## Presentation as infections

- Serious
- Persistent
- Unusual
- Recurrent

# PRIMARY IMMUNODEFICIENCY

- genetically determined
- humoral and/or cellular arms of adaptive immunity (mediated by B and T lymphocytes) – defects in maturation and/or activation
- defense mechanisms of innate immunity (NK cells, phagocytes, complement)

# PRIMARY IMMUNODEFICIENCY

- manifestation mostly in infancy, (6-24 months)
- susceptibility to:
  - recurrent infections by opportunistic pathogens
  - systemic inf. by microorg. normally superficial,
  - unusually extensive inf. by common pathogens
- autoimmune diseases (disorder of regulation)

# T-cell defect

- Bacterial sepsis
- Cytomegalovirus, Epstein-Barr virus, severe varicella, chronic infections with respiratory and intestinal viruses
- *Candida, Aspergillus, Pneumocystis jirovecii*
- Aggressive disease with opportunistic pathogens, failure to clear infections

# B-cell defect

- Streptococci, staphylococci, *Haemophilus* –skin, respiratory tract
- Enteroviral enteritis, encephalitis
- Severe intestinal giardiasis (protozoan), other GIT infections
- Recurrent sinopulmonary infections, sepsis, chronic meningitis
- panhypogammaglobulinemia x selective deficiency
- ! immunization w. live vaccines (polio, etc.)

# Granulocyte defect

- Staphylococci, *Pseudomonas*
- *Candida*, *Nocardia*, *Aspergillus*
- Leukocyte adhesion deficiency
- Defects in phagolysosome function
- Defects in microbicidal activity

# Complement defect

- Neisserial infections, other pyogenic infections
- Defects in complement components
- Defects in complement system regulators



## PRIMARY IMMUNODEFICIENCY

- **mainly B-cell defect:** X-linked agammaglobulinemia of Bruton, transient hypogammaglobulinemia of infancy, selective IgA deficiency, common variable immunodeficiency (CVID)
- **mainly T-cell defect:** DiGeorge syndrom (thymic hypoplasia), hyper-IgM syndrome
- **B- and T-cell defect:** severe combined immunodeficiency (SCID), Wiskott-Aldrich syndrome (immunodeficiency with thrombocytopenia and eczema – systemic disorder)
- **defect in phagocyte function:** chronic granulomatous disease, leukocyte adhesion deficiency, myeloperoxidase deficiency
- **primary complement deficiencies**

# Severe combined immunodeficiency

## SCID

- defects in both humoral and cell-mediated immunity
- recurrent, severe infections, wide range of pathogens, incl. *Candida albicans*, *P. jirovecii*, *Pseudomonas*, cytomegalovirus, varicella, many bacteria.
- morbilliform rash shortly after birth – GVH disease due to maternal T-cells
- X-linked (~ 50%), autosomal recessive
- „bubble children“, bone marrow transplantation, gene therapy (! acute T-cell leukemia)

# DiGeorge syndrome (thymic hypoplasia)

- T-cell defect; chromosomal deletion; commonly only partial hypoplasia
- failure of embryonal development of the 3rd and 4th pharyngeal pouches (thymus, parathyroids, part of thyroid clear cells → hypocalcemic tetany; heart + great vessels defects)
- T- cell zones depleted (LN – paracortical, periarteriolar sheaths of the spleen)
- ↑ fungal and viral infections

# Common variable immunodeficiency

## CVID

- relatively common, heterogeneous group of disorders (dg. by exclusion), both sexes, children - adolescents
- hypogammaglobulinemia
- sporadic and inherited forms
- B cells in normal numbers, not able to differentiate into plasma cells
- intrinsic B-cell defects, abnormalities in T helper cell-mediated activation of B cells
- hyperplastic B-cell zones in lymphoid tissue

# Common variable immunodeficiency

- recurrent sinopulmonary pyogenic infections
- recurrent herpesvirus infections
- persistent diarrhea due to *G. lamblia*
- enterovirus meningoencephalitis
- ↑ frequency of autoimmune diseases (RA)
- risk of lymphoid malignancy

# Isolated IgA deficiency

- common immunodeficiency in Caucasians (1:600), severe reaction after blood transfusion possible
- familial or acquired after some infections (toxoplasmosis, measles, some viral inf.)
- low levels of both serum and secretory IgA
- mostly asymptomatic; possible respiratory, GIT, urogenital recurrent infections
- ↑respiratory tract allergy, autoimmune diseases

# Chronic granulomatous disease

- ↓ oxygen radicals production needed for bacteria killing in effective phagocytosis
- X-linked; other types
- ↑ pyogenic bacteria (Staph., G- rods), fungi (Aspergillus)
- respiratory, GIT, skin, ... infections – abscess, giant-cell granuloma
- liver vascular lesions → portal hypertension

# SECONDARY IMMUNODEFICIENCY

## Due to impaired synthesis and function:

- protein, vitamin and energy deficiency in malnutrition, cachexia in disseminated cancer, anorexia, alcoholism
- prevalent monoclonal Ig in some lymphoproliferative diseases
- bone marrow infiltration or fibrosis (leukemia, myelofibrosis)
- suppression of cell mediated immunity due to acute viral infection (CMV, EBV, measles, etc.), bacterial and protozoal infection – macrophagic dysfunction (leprosy, leishmaniasis)



# SECONDARY IMMUNODEFICIENCY

- **iatrogenic** (immunosuppressive and cytostatic drugs, radiotherapy, splenectomy – pneumococcus sepsis)
- diabetes mellitus and other metabolic diseases
- chronic stress
- sarcoidosis (↓ Tcell function)
- certain age groups (old, newborn, immature infants)

**Increased catabolism or loss:** nephrotic syndrome and renal failure, inflammatory intestinal diseases (IBD, lymphangiectasia)

# SECONDARY IMMUNODEFICIENCY

## Humoral immunodeficiency

- intestinal lymphangiectasia, IBD → ↓ all Ig classes, commonly + lymphopenia
- nephrotic sy, chronic diarrhea → ↓ IgG
- iatrogenic immunosuppression/cytostatic therapy
- B-cell malignancies
- Splenectomy – spleen B-cell – Ab x polysaccharide antigens – encapsulated microorg. – vaccination x pneumococci

# SECONDARY IMMUNODEFICIENCY

## Cellular immunodeficiency

- temporary after acute viral infection (CMV, EBV, measles, etc.)
- iatrogenic immunosuppression/cytostatic
- AIDS

# SECONDARY IMMUNODEFICIENCY

## Combined immunodeficiency

- Severe general metabolic problems (DM, renal insufficiency), malnutrition, anorexia, chronic alcoholics – inadequate hormones, glucose, vitamins level

# SECONDARY IMMUNODEFICIENCY

## Defect of phagocytosis

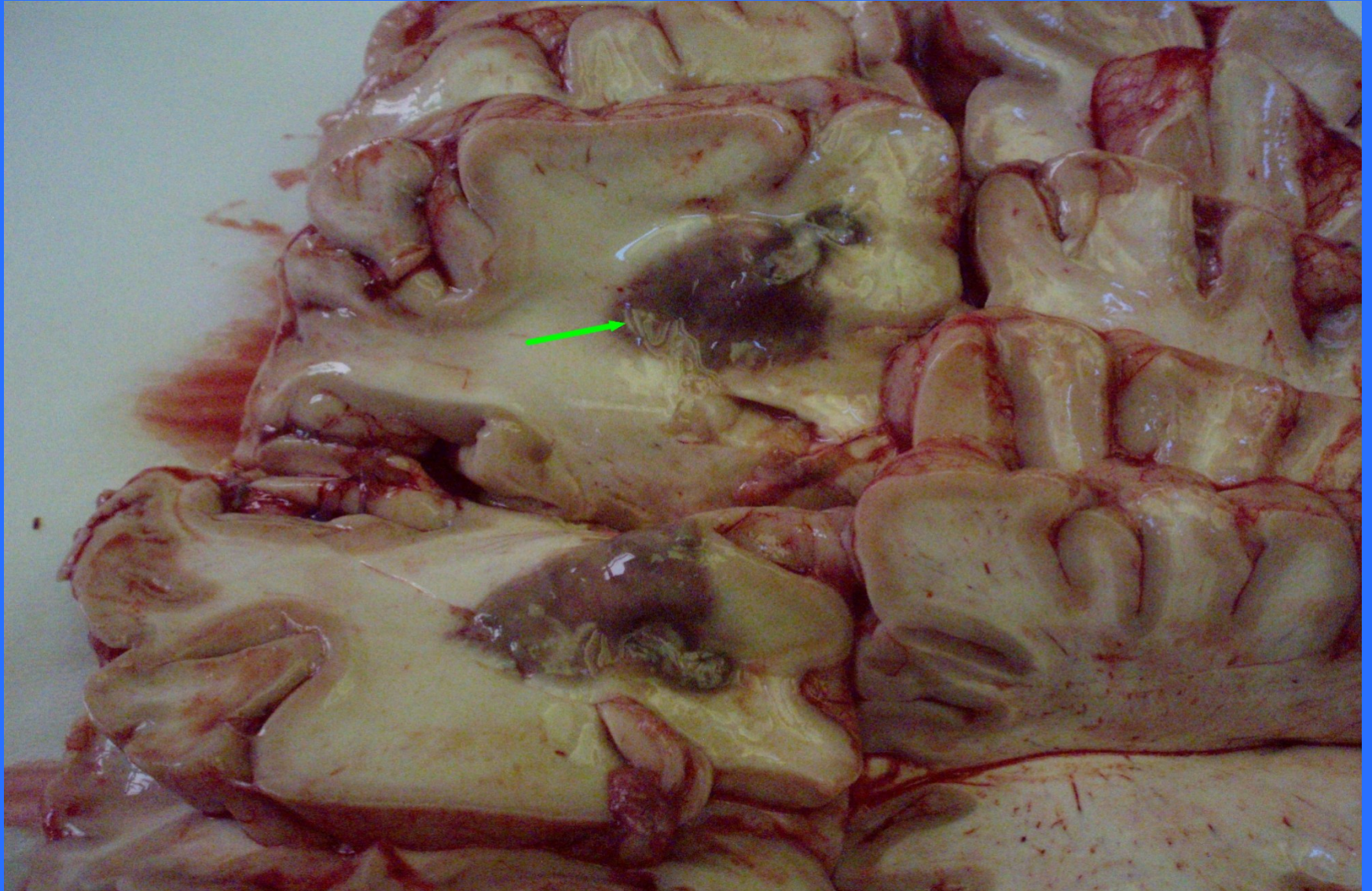
- neutropenia in bone marrow insufficiency  
(irradiation, immunosuppressant/cytostatic th.,  
some chemicals)
- autoantibodies
- ↑ loss in hypersplenism
- metabolic diaseases
- myeloid leukemia

# SECONDARY IMMUNODEFICIENCY

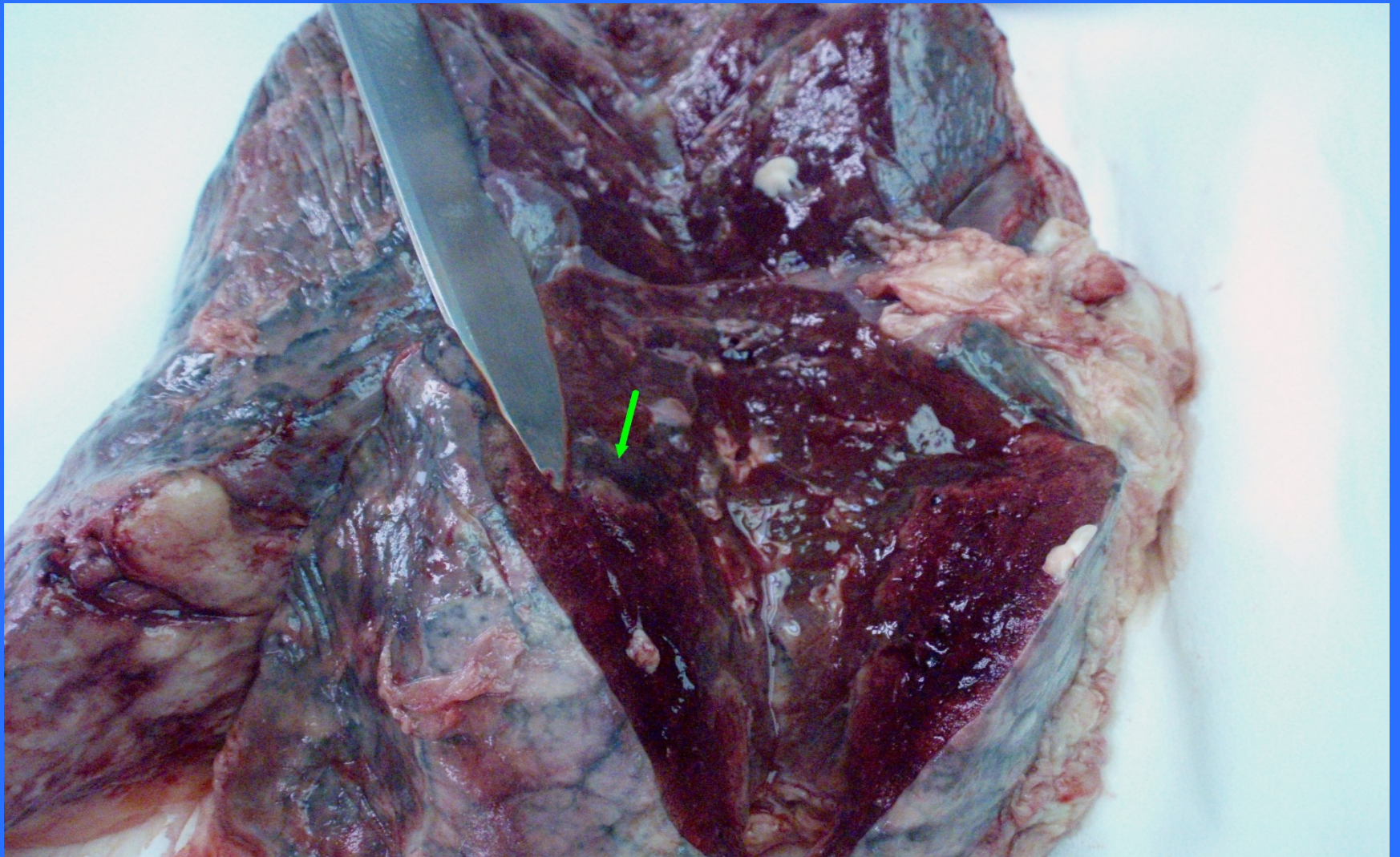
## Complement deficiency

- immunocomplex diseases
- sepsis
- severe liver disease

# Brain mycotic abscess

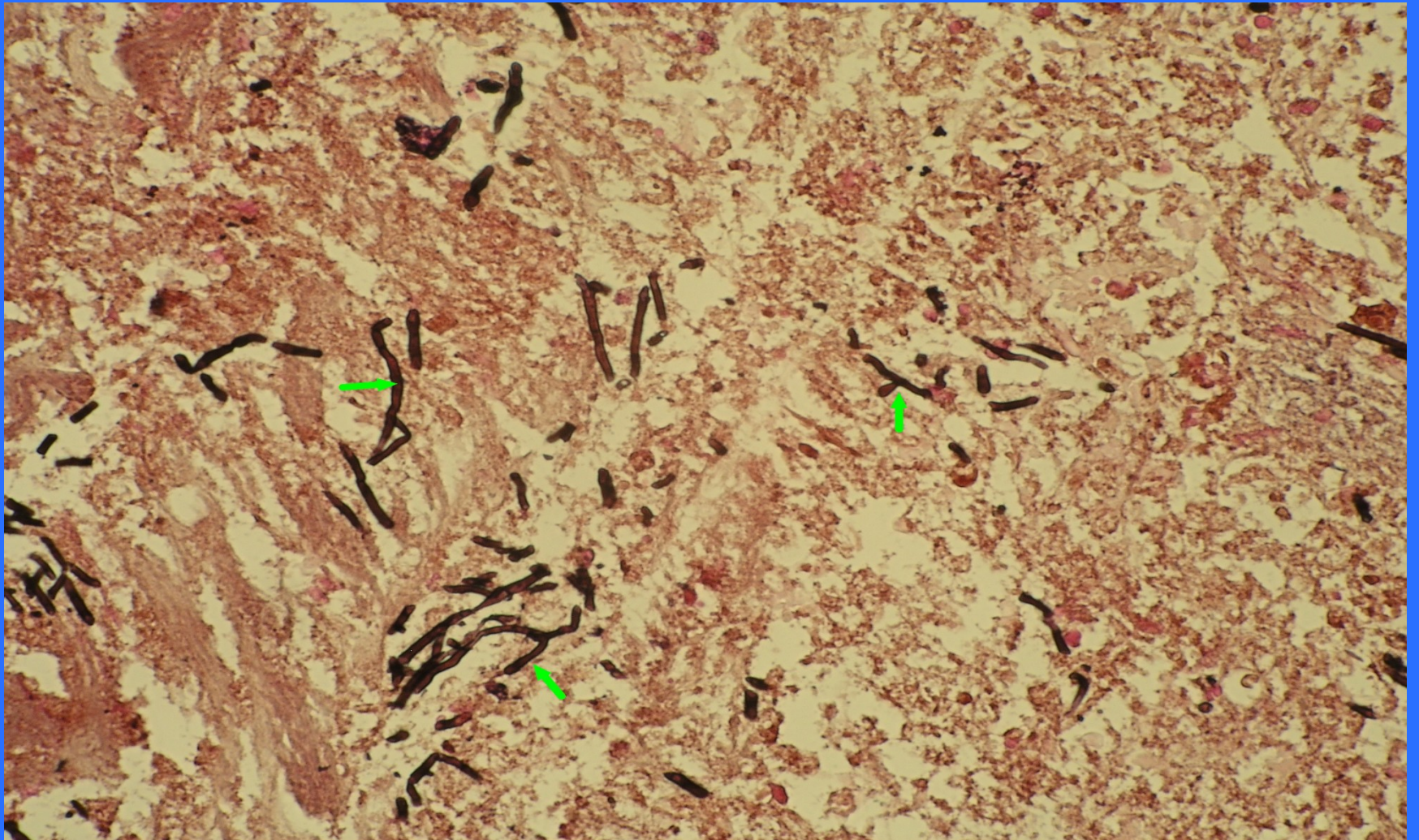


# Lung mycotic abscess

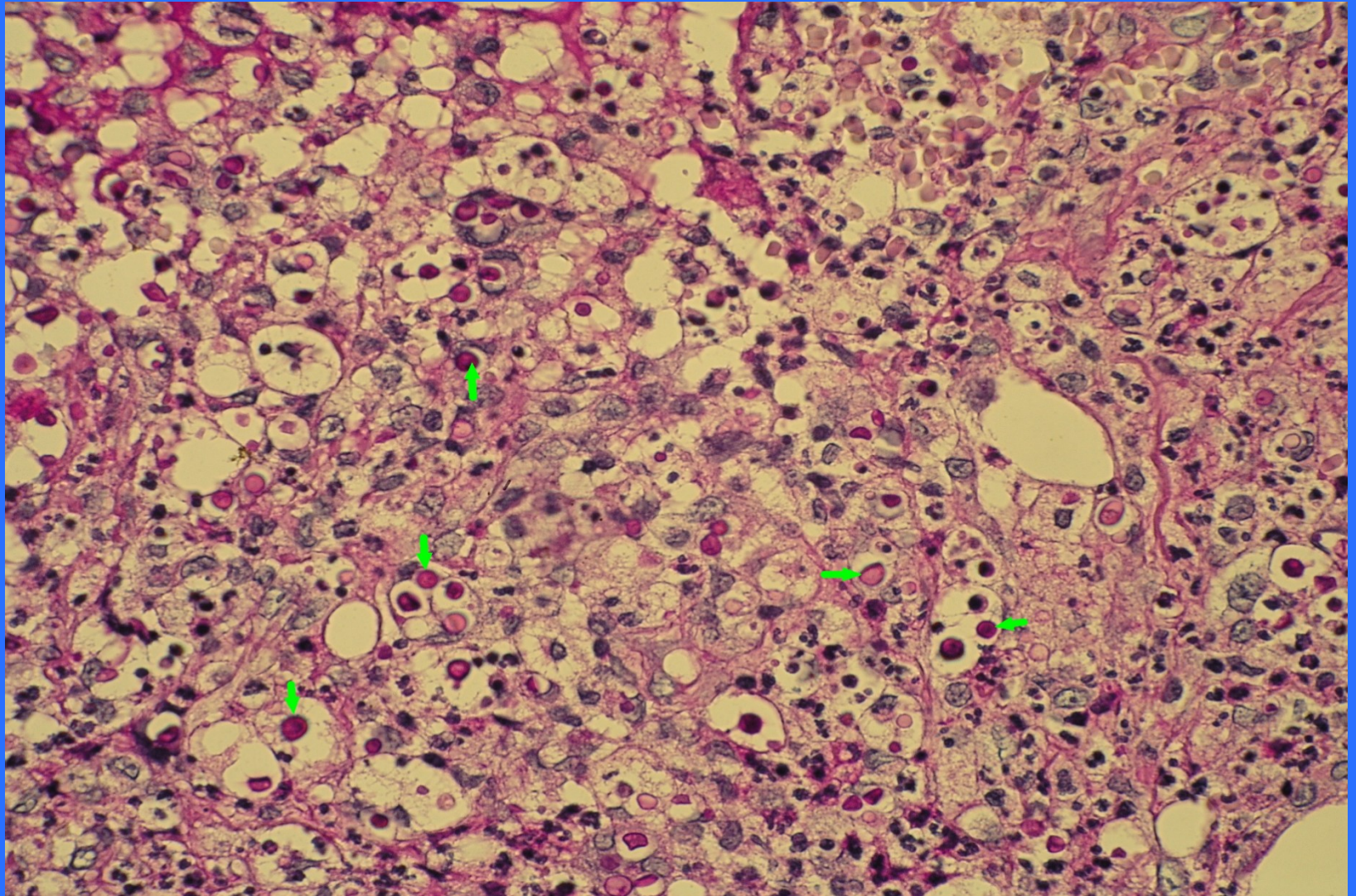




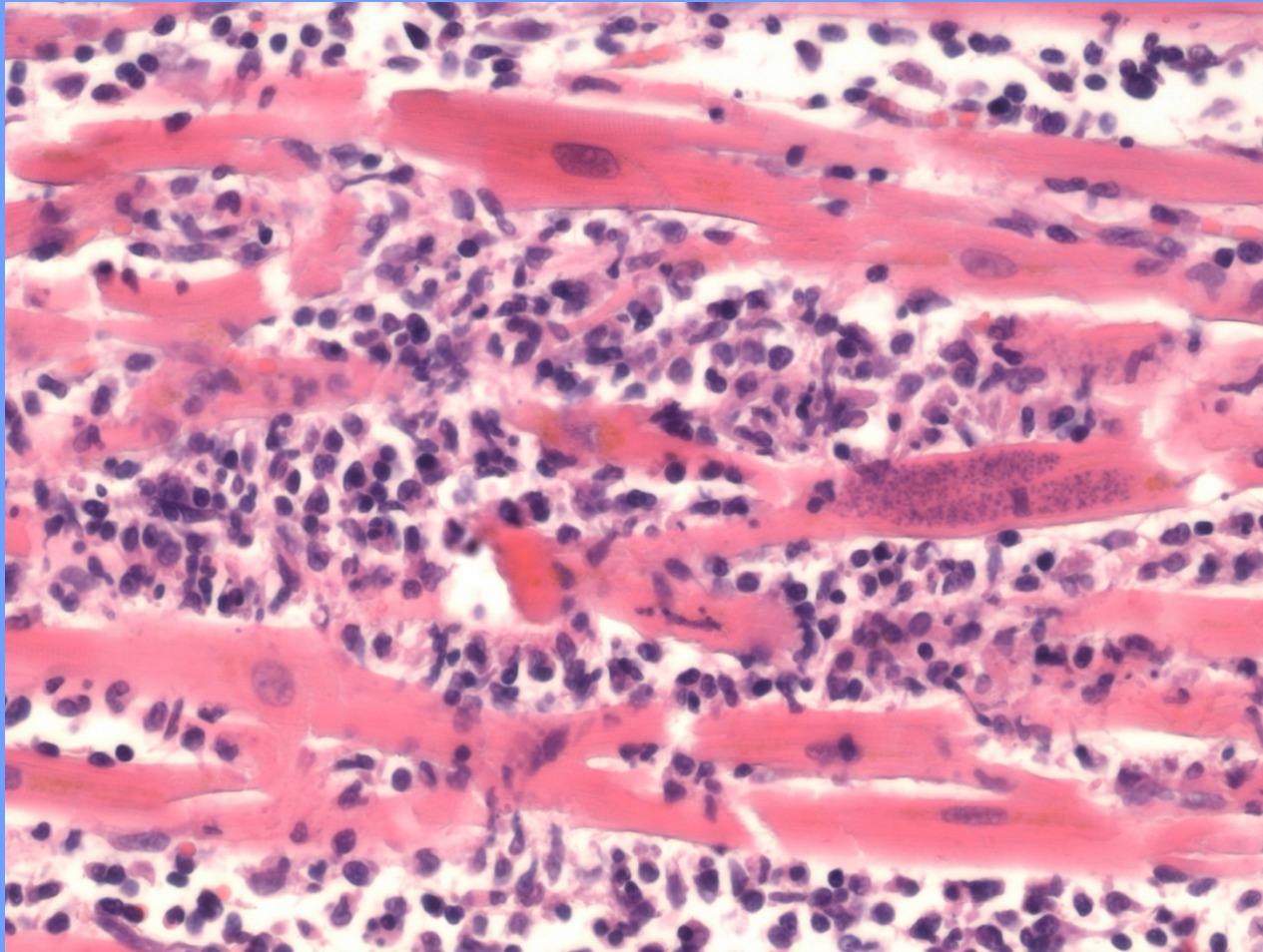
# Fungal structures in necrotic brain



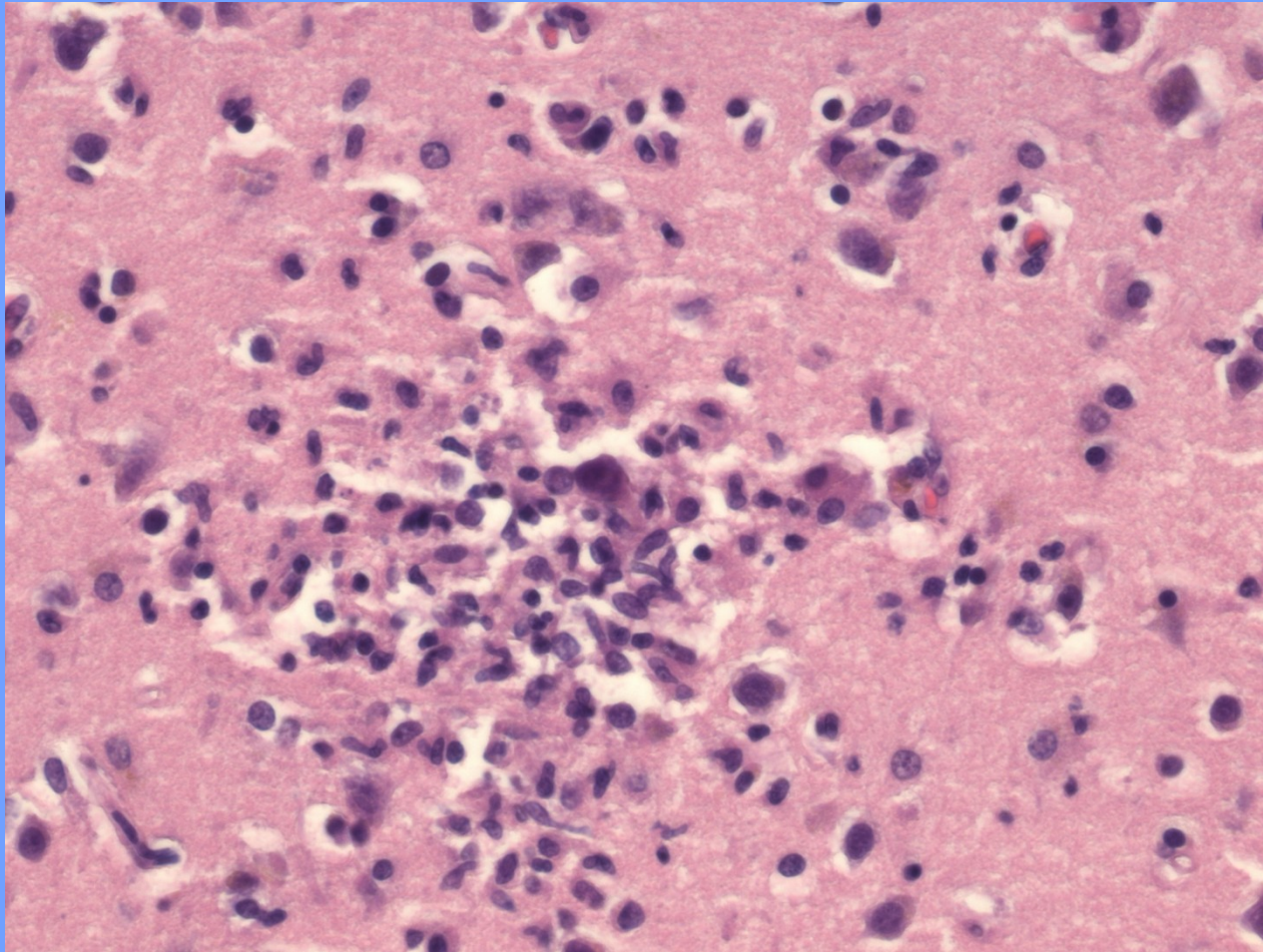
# Cryptococcus in skin



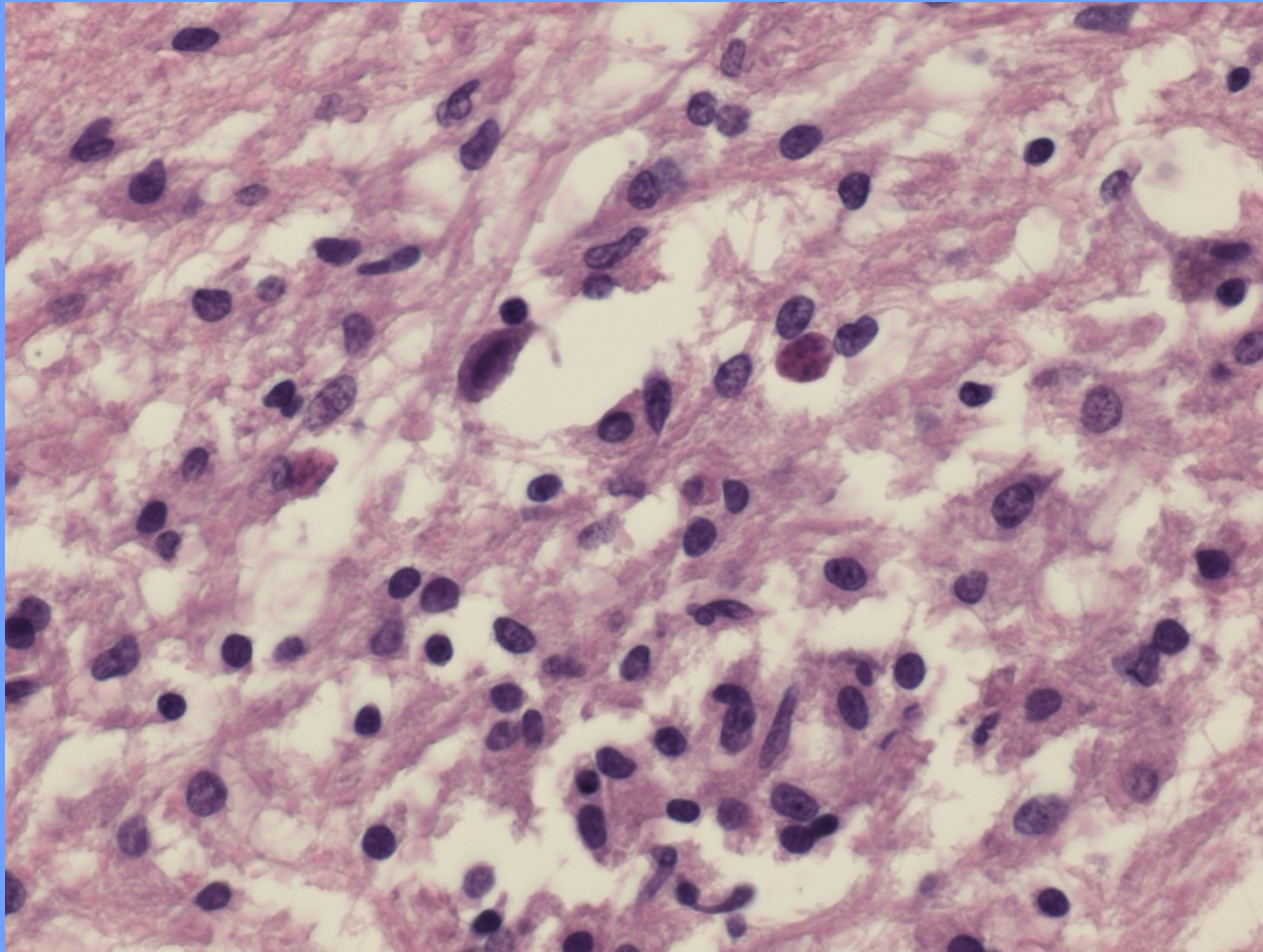
# Toxoplasmosis in myocardium



# Brain toxoplasmosis inflammation



# Brain toxoplasmosis cysts



# HIV - AIDS

- The goal – ending the *AIDS* epidemic by 2030
- Stopping the new infections
- Everybody infected should have access to treatment
- Pre-exposure prophylaxis

# AIDS epidemics

- Since the start of the epidemics: ~ 78 millions of infected; 35,4 millions have died
- Globally the spread of HIV peaked in the 1996, when 3.5 million new HIV infections occurred.
- 2019 estimated 1,7 newly infected
- AIDS related mortality max. in 2005 (1,9 million), 2019 0,69 million – access to HAART

# AIDS epidemics

- Estimated 38 million people living with HIV at the end of 2019.
- 81 % had been diagnosed
- 67 % were receiving treatment
- 59 % had achieved suppression of the HIV virus to the point at which they were at low risk of infecting others.



# AIDS epidemics

- AIDS related illnesses still the leading cause of death among women of reproductive age (15–49 years) globally
- Increases in AIDS infections over the past decade in the Middle East and North Africa (22%↑), Latin America (21% ↑) and eastern Europe and central Asia (72%↑).

# AIDS epidemics

- Decrease in new infections and deaths, increase in number of people living with HIV (Highly Active Antiretroviral Therapy - HAART)
- > 10 millions in need of treatment (+ preexposure prophylaxis)

# AIDS epidemics

- HIV infection in Europe: National epidemics concentrated among key populations at higher risk (men who have sex with men – MSM, injecting drug users; prisoners, sex workers, sexual partners of key population).

# HIV in the Czech Republic

- cca 3800 HIV+ cases in Czechia, 86 % males; 490 foreigners (mostly Eastern Europe, Sub-Sah. Africa)
- Transmission: MSM > heterosexual > IDU > blood derivatives (survivors) > vertical transmission (mother – child)
- Most cases in/around Prague (1828), South Moravia 312

# HIV ISSUES

- Blood safety
- HIV treatment: antiretroviral therapy should begin immediately after diagnosis
- Prevention of mother-to-child transmission
- Co-management of tuberculosis and HIV treatment
- HIV testing in the general and most-at-risk population
- Preexposure prophylaxis

# HIV - AIDS

More than 90% of children living with HIV acquired the virus during pregnancy, birth or breastfeeding - forms of HIV transmission that can be prevented.

# AIDS epidemics

- Europe, Australia and Canada: mortality rates among people living with HIV in the first five years after infection now ~ in the HIV-uninfected population
- Mortality among HIV-infected people increases with the duration of infection
- Increasing complications of chronic HAART – highly active antiretroviral therapy

# Noninfectious HIV-related comorbidities:

- The premature aging process in HIV-infected people
- 2x ↑ risk of myocardial infarction
- ↑ risk of osteoporosis incl. fractures (even in adolescents!)
- ↑ risk of chronic renal failure
- Non-AIDS tumors



# Noninfectious HIV-related comorbidities:

- hyper-activated immunological profile, accelerated T-cell senescence
- accelerated process of immune senescence and inflammatory aging during HIV infection → increased risk of age-related diseases
- long-term tolerability of HAART regimens

# HAART complications

- Diarrhea, nausea , and vomiting.
- Lipodystrophy: fat in adipous tissue redistributed to other regions, i.e.face and limbs → thin, breasts, stomach and/or neck enlarge.
- Glucose intolerance, diabetes. Lactic acidosis.
- Liver toxicity – acute hepatitis incl. liver failure. Pancreatitis.
- Nephrotoxicity
- Neuropathy
- Osteonecrosis, osteoporosis, osteopenia

# HAART complications

- Cardiovascular complications: toxicity, endothelial dysfunction, atherosclerosis, dyslipidemia. Myocardial infarction
- Reconstitution of the immune system (major goal of HAART treatment): risk of debilitating Immune reconstitution inflammatory syndrome (IRIS) - ↑ CD4 count + function. Immune response against antigens associated with infection diseases (TB, MAC, Pneumocystis pneumonia, CMV, HZV). 10-25% of patients
- Drug interactions

# HAART resistance

- Drug switching necessary
- New regimens/drugs
- Timely start of therapy

# HIV-2

- Endemic in West Africa.
- Limited spread outside this area, suspicion – in persons of West African origin/risk contact
- Prevalence of HIV-2 disproportionately high in countries with strong socioeconomic ties to West Africa (e.g., France; Spain; Portugal; and former Portuguese colonies such as Brazil, Angola, Mozambique, and parts of India near Goa).

# HIV-2

- Clinical course - longer asymptomatic stage, lower plasma HIV-2 viral loads, and lower mortality rates compared with HIV-1 infection
- Resistance-associated mutations develop commonly in HIV-2 patients on therapy

# HIV infection of cells

- T-lymphocytes (CD4+)
- macrophages/monocytes (viral reservoir, replication and transport)
- mucosal and follicular dendritic cells
- cells in CNS (microglia)

# Immune dysfunctions in AIDS

- **Lymphopenia** (selective loss of CD4+ T-cells – direct cytophatic effect, apoptosis of noninfected)
- **Decreased T-cell function in vivo** (loss of memory T-cells, susceptibility to opportunistic infections and neoplasms, decreased delayed-type hypersensitivity)
- **Polyclonal B-cell activation** (hypergammaglobulinemia, CIC, inability of new antibody response)
- **Altered monocyte or macrophage functions** (decreased chemotaxis, phagocytosis, antigen presentation; increased spontaneous secretion of TNF, IL-1 etc.)



# Phases of HIV infection

- **Acute retroviral syndrome** (3-6 wks after infection, in 40-90%, self-limited in 2-4 wks)
- **Chronic phase** (clinical latency, persistent generalized lymphadenopathy – PGL)
- **Progression to AIDS** (AIDS-related complex – ARC, AIDS indicator conditions: constitutional, neurologic, opportunistic infection, neoplasm)

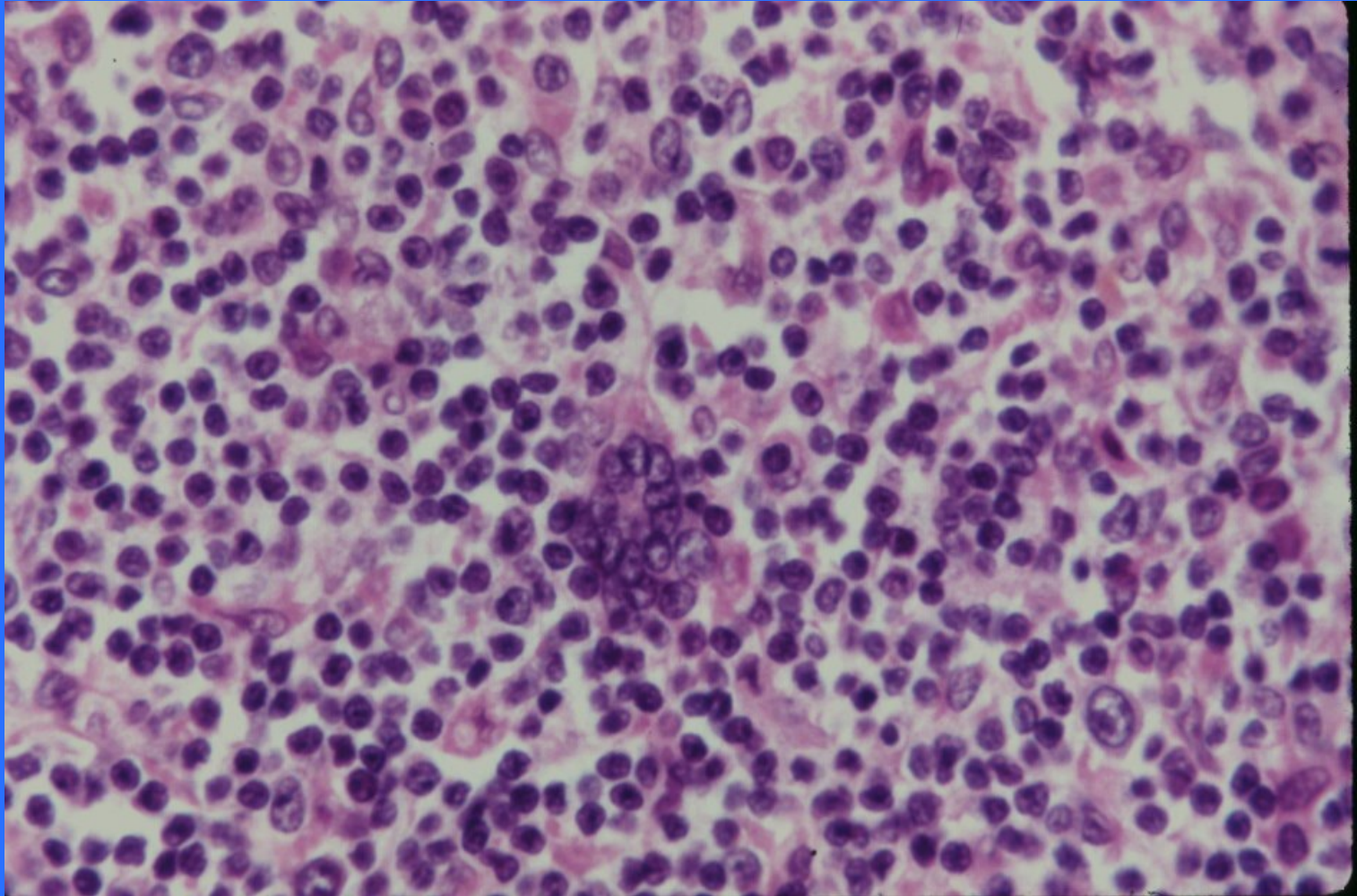
# Acute HIV infection

- **Suspect:** Signs or symptoms of acute HIV infection with recent (within 2–6 weeks) high risk of exposure
- **Possible signs:** fever, lymphadenopathy, skin rash, myalgia/arthralgia, headache, diarrhea, oral ulcers, leucopenia, thrombocytopenia, transaminase elevation.

# Acute HIV infection

- **High-risk exposures** include sexual contact with a person infected with HIV or at risk of HIV, sharing of injection drug use paraphernalia, or contact of potentially infectious blood with mucous membranes or breaks in skin.
- **Differential diagnosis:** Epstein-Barr virus (EBV)- and non-EBV (e.g., cytomegalovirus [CMV])-related infectious mononucleosis syndromes, influenza, viral hepatitis, streptococcal infection, syphilis

# Persistent generalized lymphadenopathy



# Opportunistic infections and neoplasms

- **Protozoal and helminthic** (cryptosporidiosis, toxoplasmosis, giardiasis, etc.)
- **Fungal** (Pneumocystis, candidiasis, cryptococcosis, coccidiomycosis, histoplasmosis)
- **Bacterial** (mycobacteriosis – atypical, TB; salmonellosis, nocardiosis)
- **Viral** (CMV, Herpes simplex, Varicella-zoster, progressive multifocal leukoencephalopathy – JC polyoma virus)
- **Neoplasms** ( Kaposi sarcoma – HHV 8, B-cell non-Hodgkin lymphomas, primary brain lymphomas – EBV, aggressive cervical and anal carcinomas – HPV)

# HIV neurologic disease

- *Acute* aseptic meningitis
- *subacute and chronic*: HIV-associated neurocognitive disorders
- HIV meningoencephalitis – AIDS-dementia complex, vacuolar myelopathy, myopathy and peripheral neuropathy
- before HAART, clinical signs of neurologic lesion in 40-60% of patients (HIV, opportunistic infection, tumor)
- now ↓ – chronic encephalitis – microglial nodules + multinucleated giant cell, microfoci of necrosis

10981-07

11/12/06

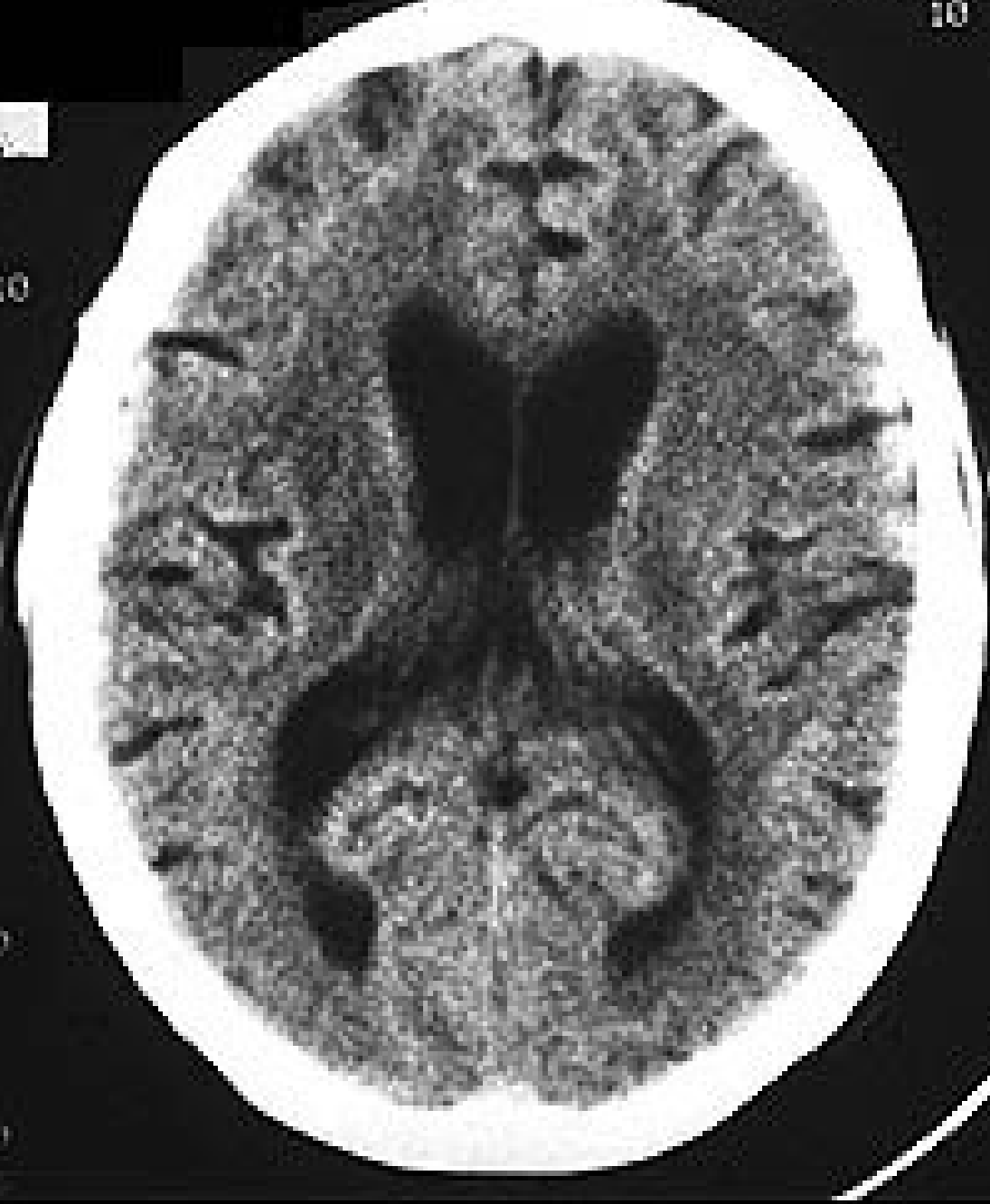20:21

0270 10

← H O U D

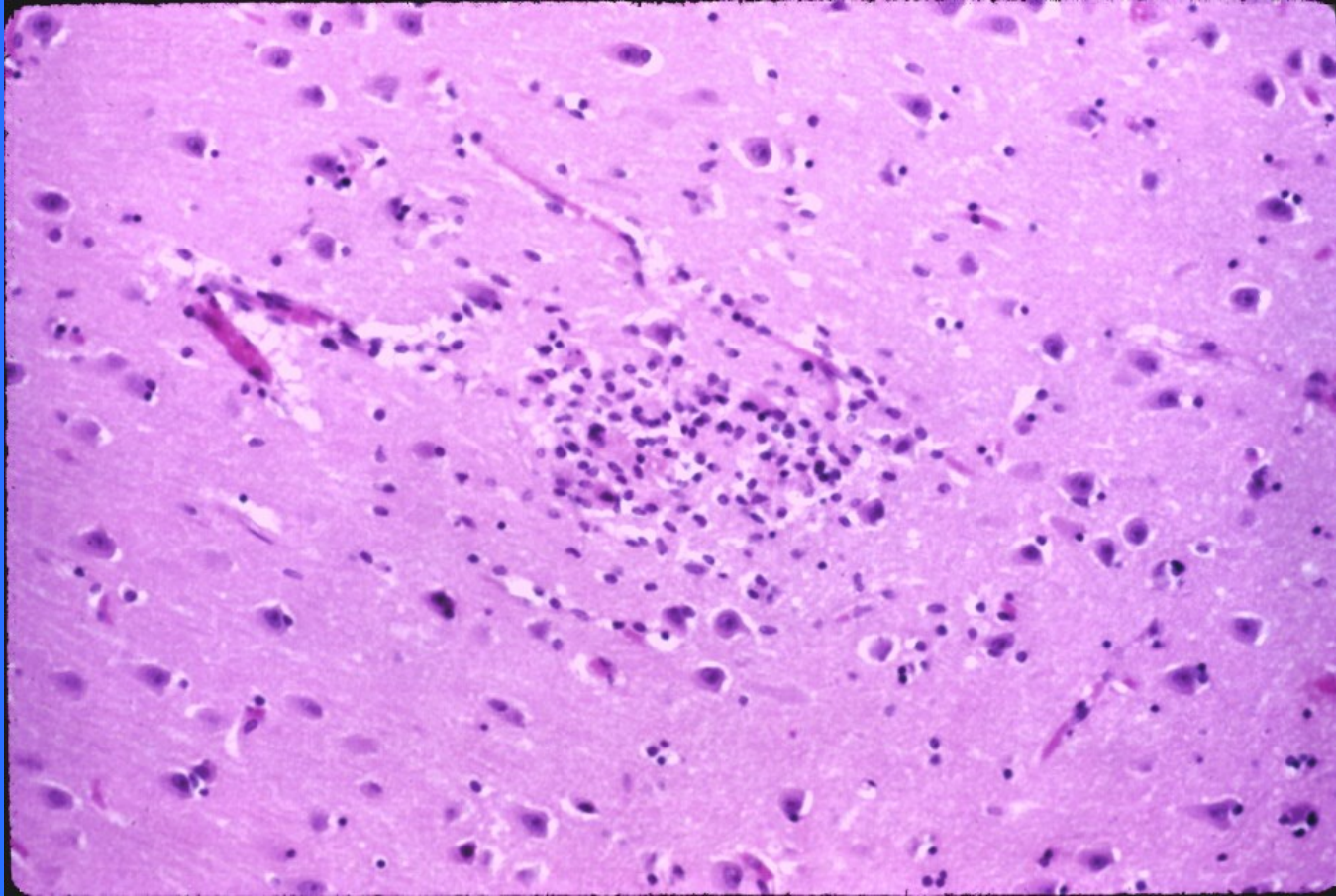


GRY LIN  
 CLR FED  
 ZOOM 1  
 HD: 100  
 LEVEL 15



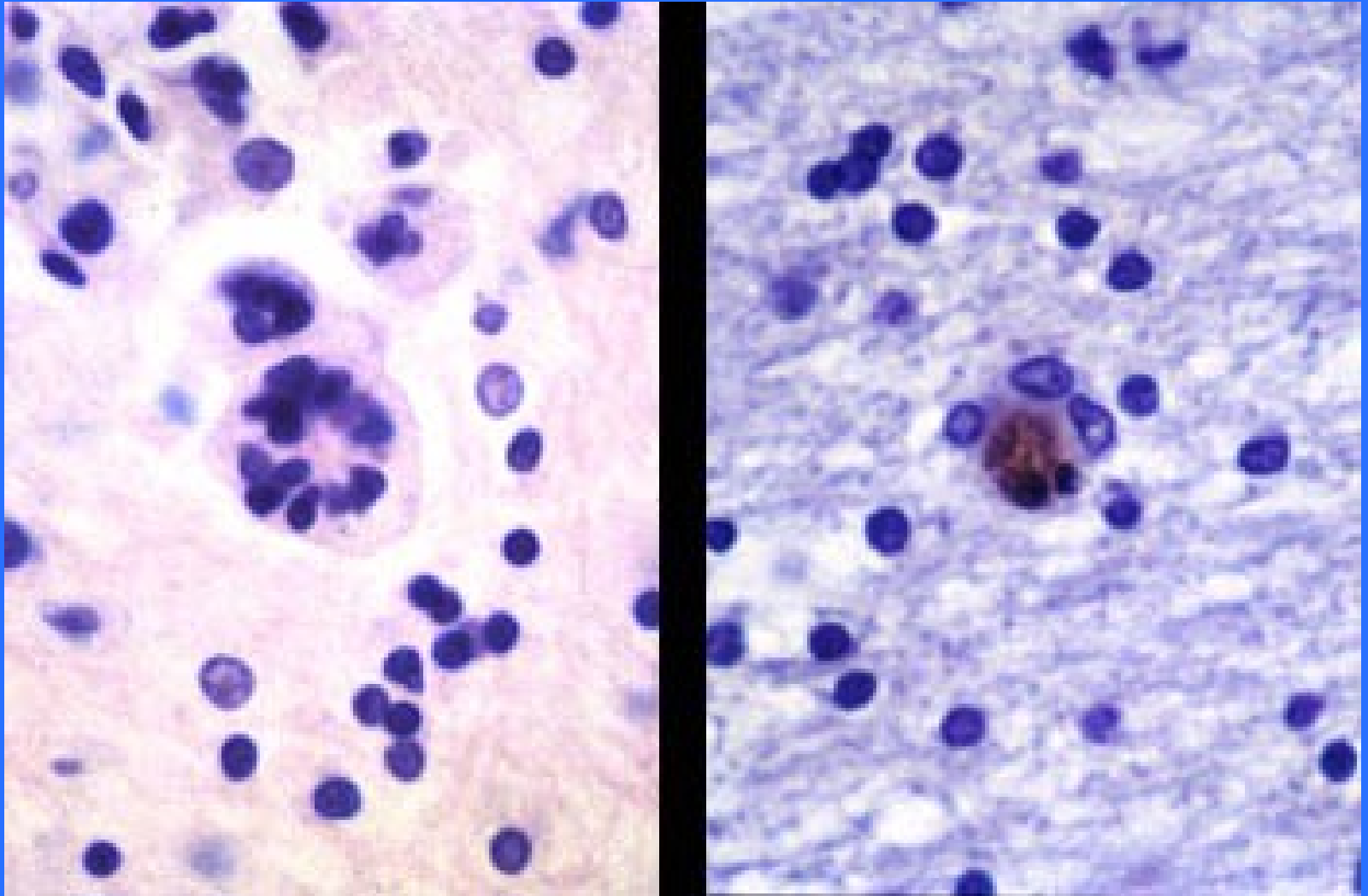
Copy HIV encephalopathy – brain atrophy

# HIV encephalopathy

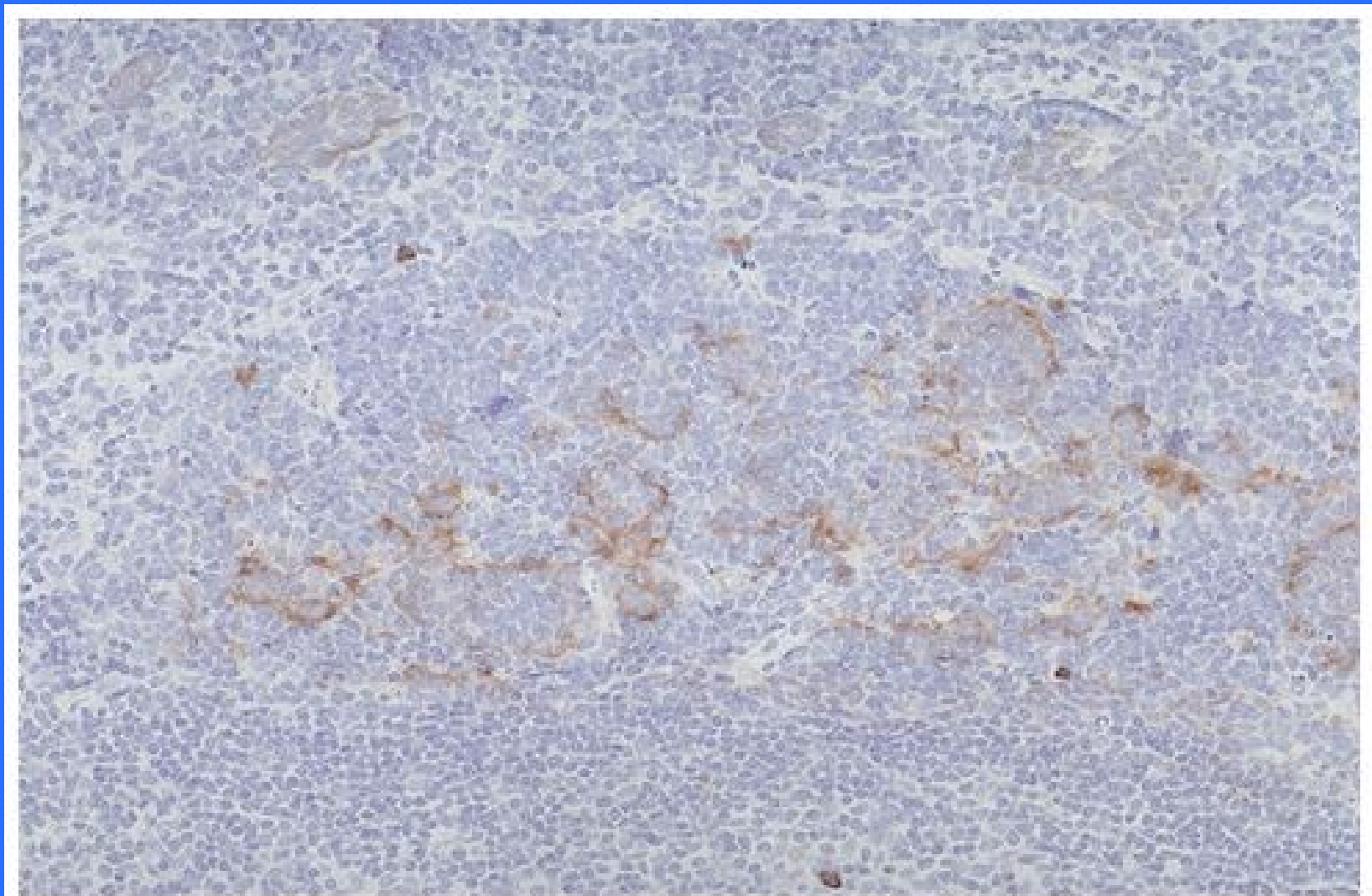




# HIV encephalitis



## p24 immunohistochemistry



Copyright © 2002, Elsevier Science (USA). All rights reserved.

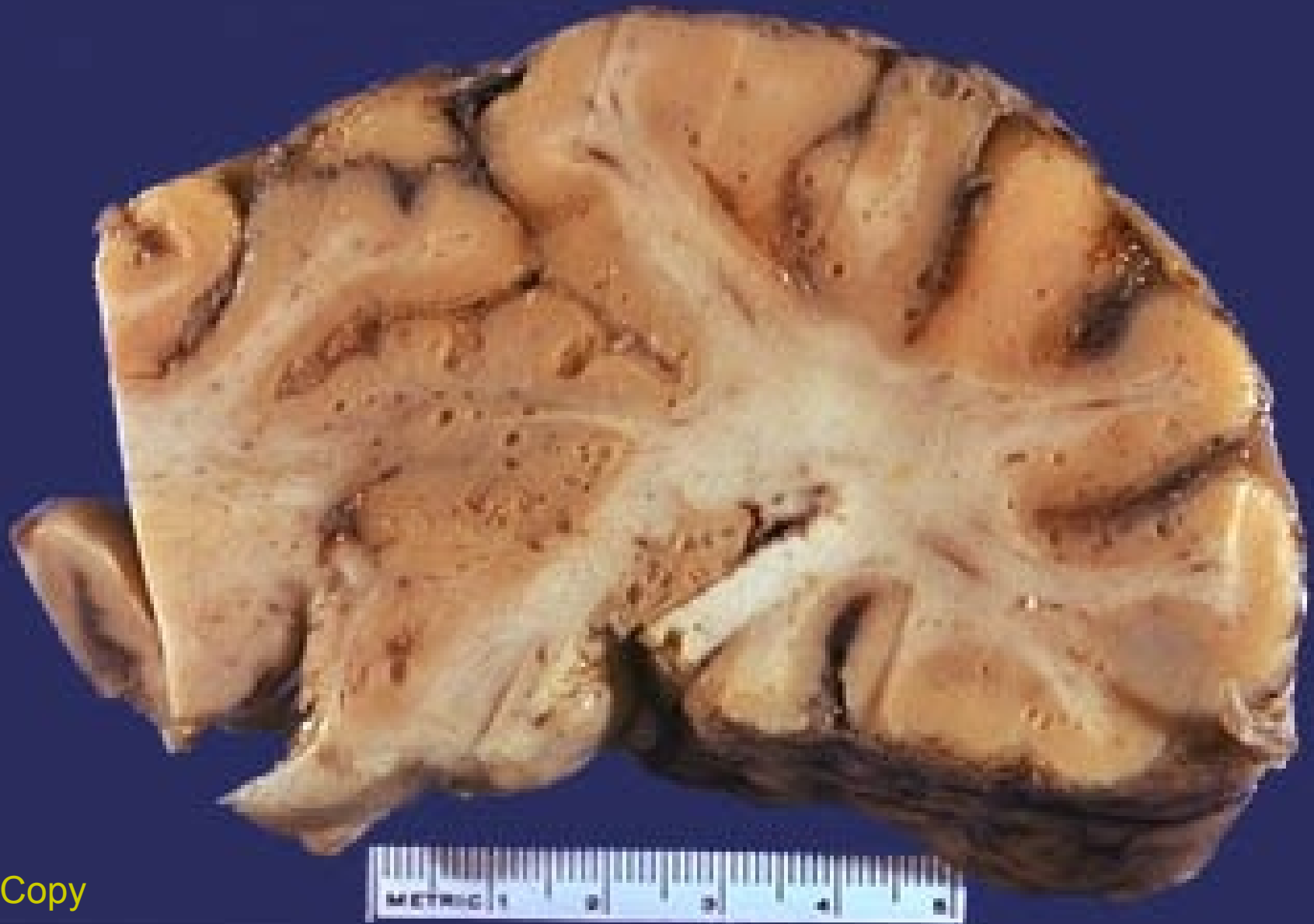# CNS infections

- Toxoplasmosis
- Cryptococcosis
- Progressive multifocal leukoencephalopathy (JC virus)
- Cytomegalovirus
- HSV, VZV in disseminated infections

# Toxoplasmosis

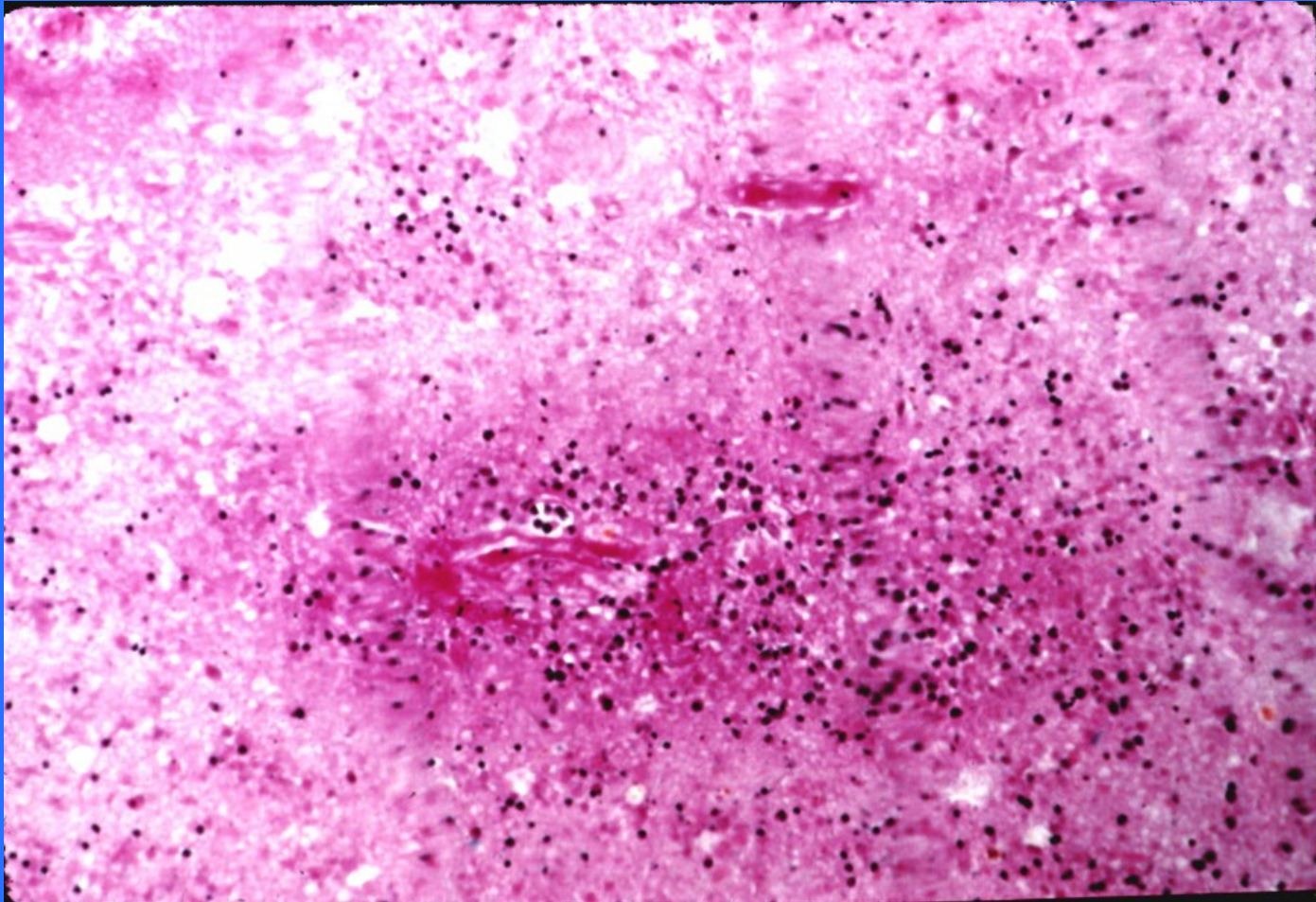
- protozoa with complicated life-cycle
- brain abscess, mostly in cortex and gray nuclei
- acute lesion: central necrosis, mixed inflammatory reaction, macrophages („soap bubble“), toxoplasma pseudocyst
- chronic lesion: cystic space with macrophages, hemosiderin

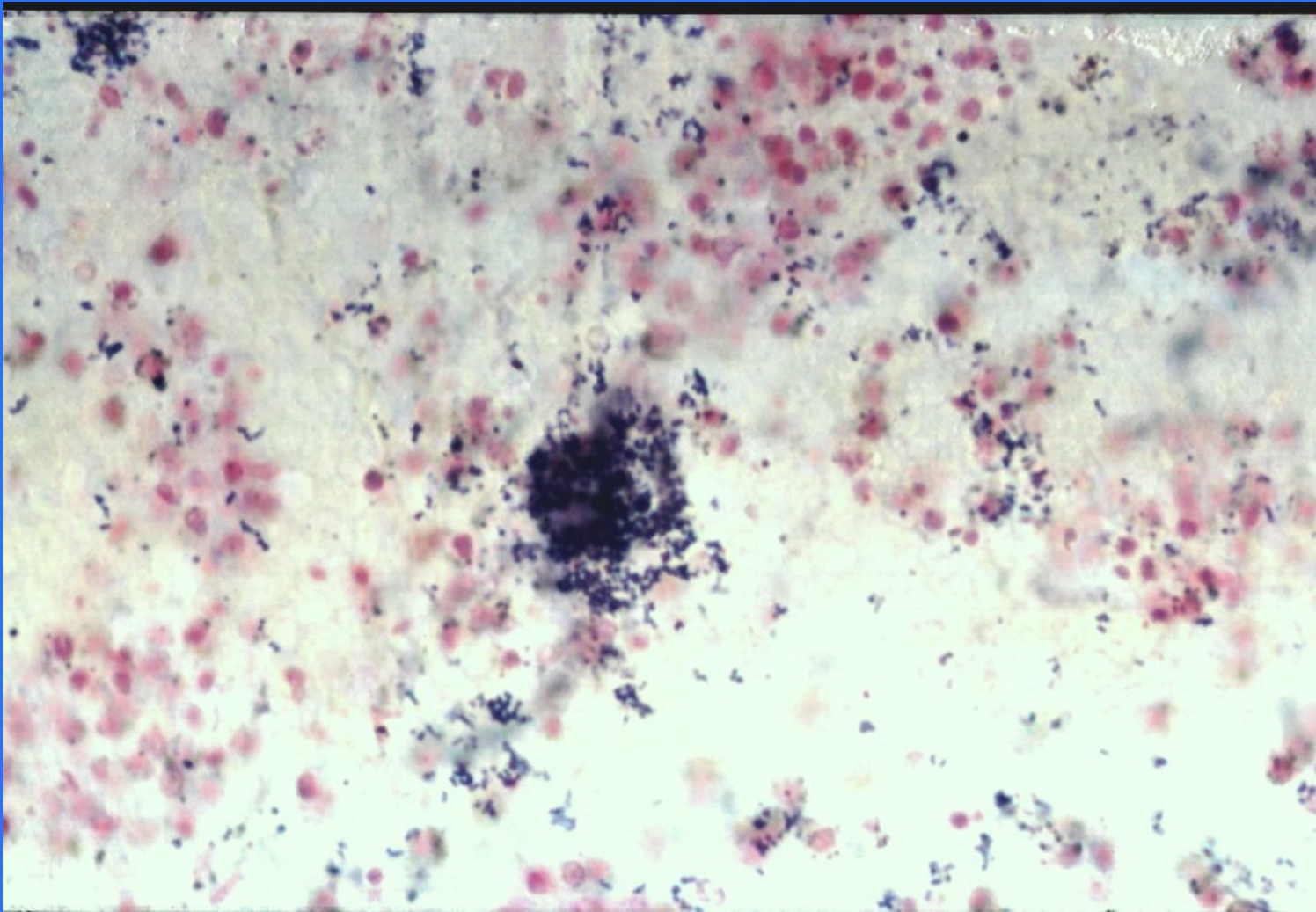
# Toxoplasmosis



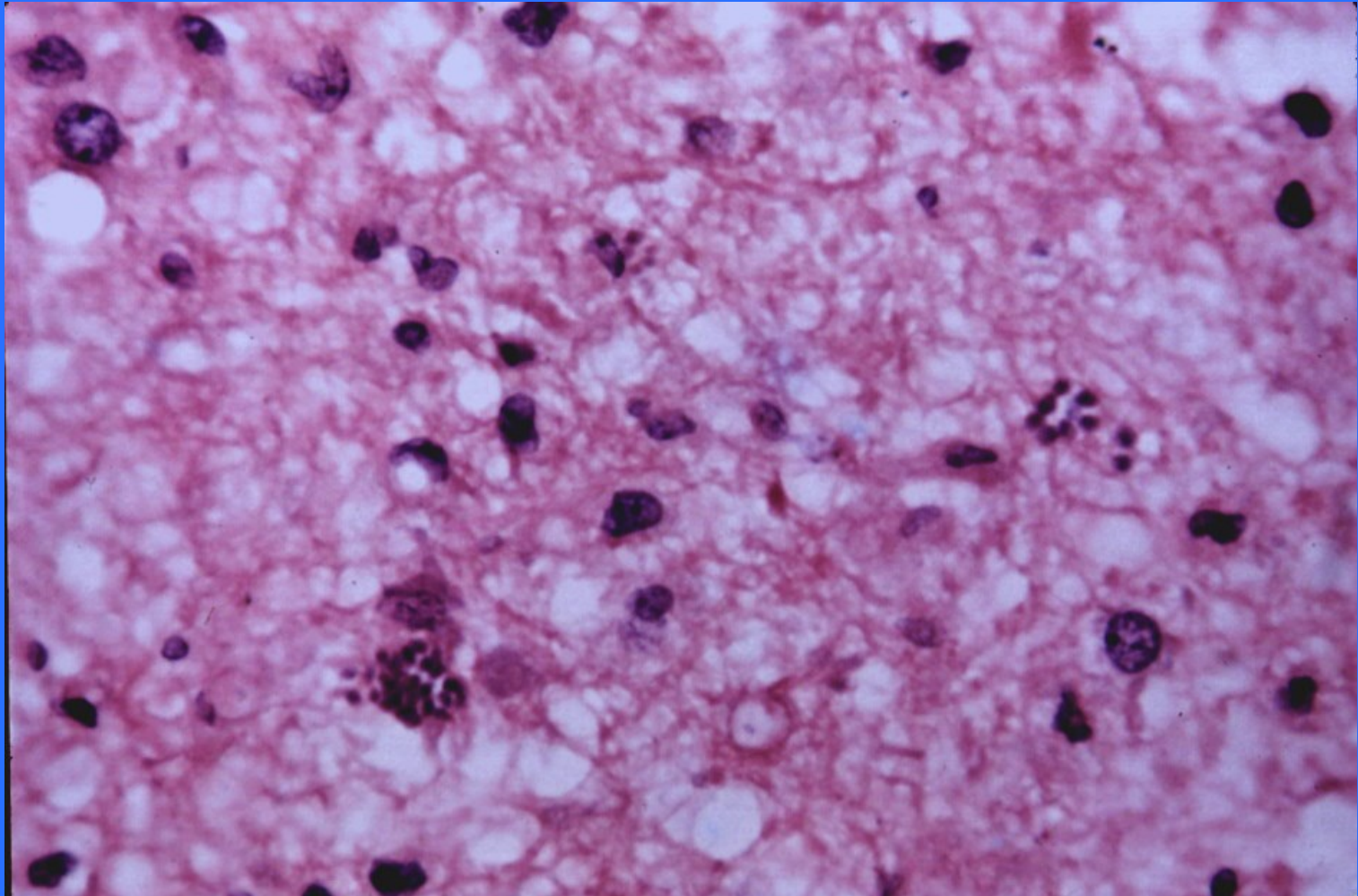
Copy

## Toxoplasma encephalitis





Toxoplasma encephalitis



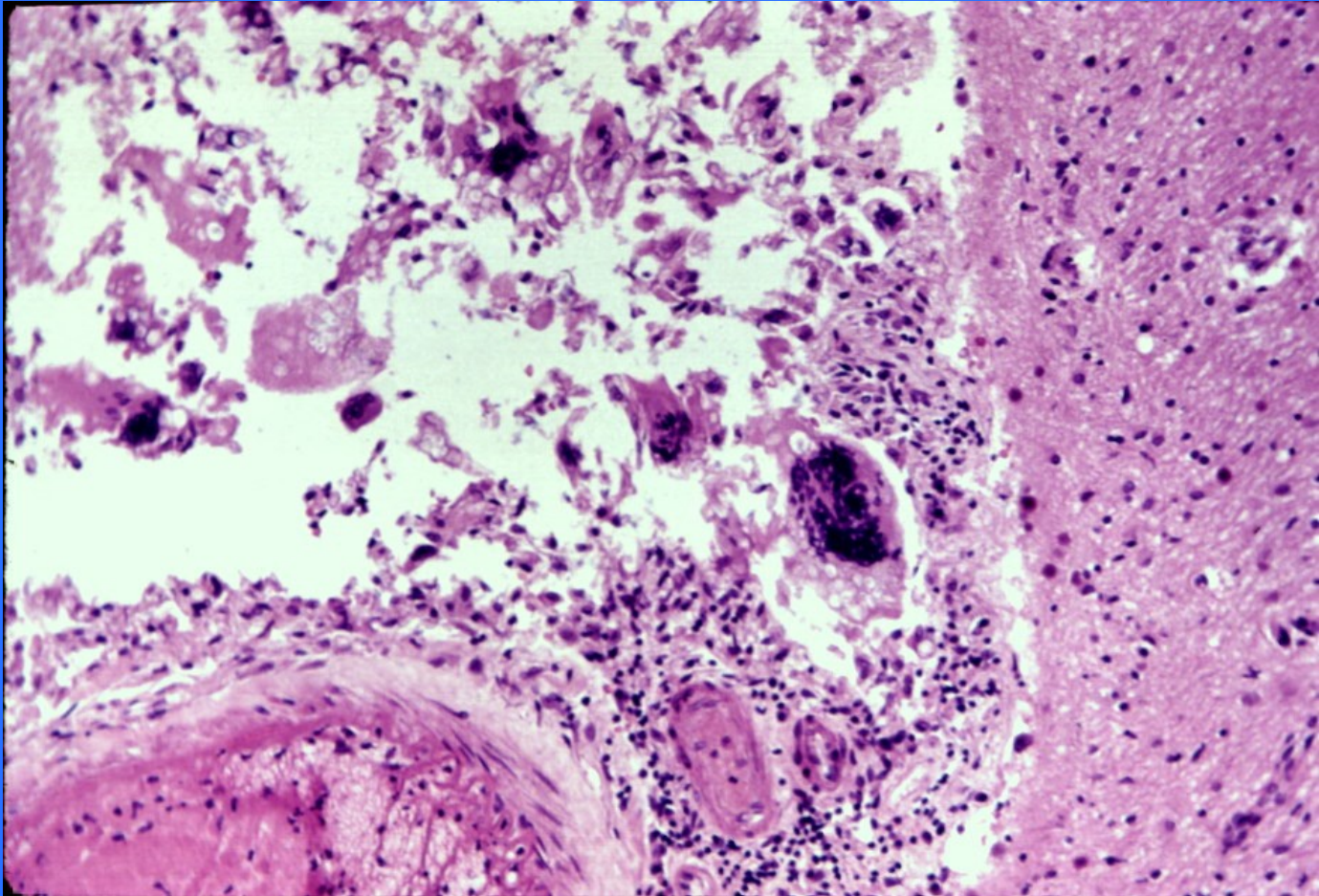
Toxoplasma encephalitis

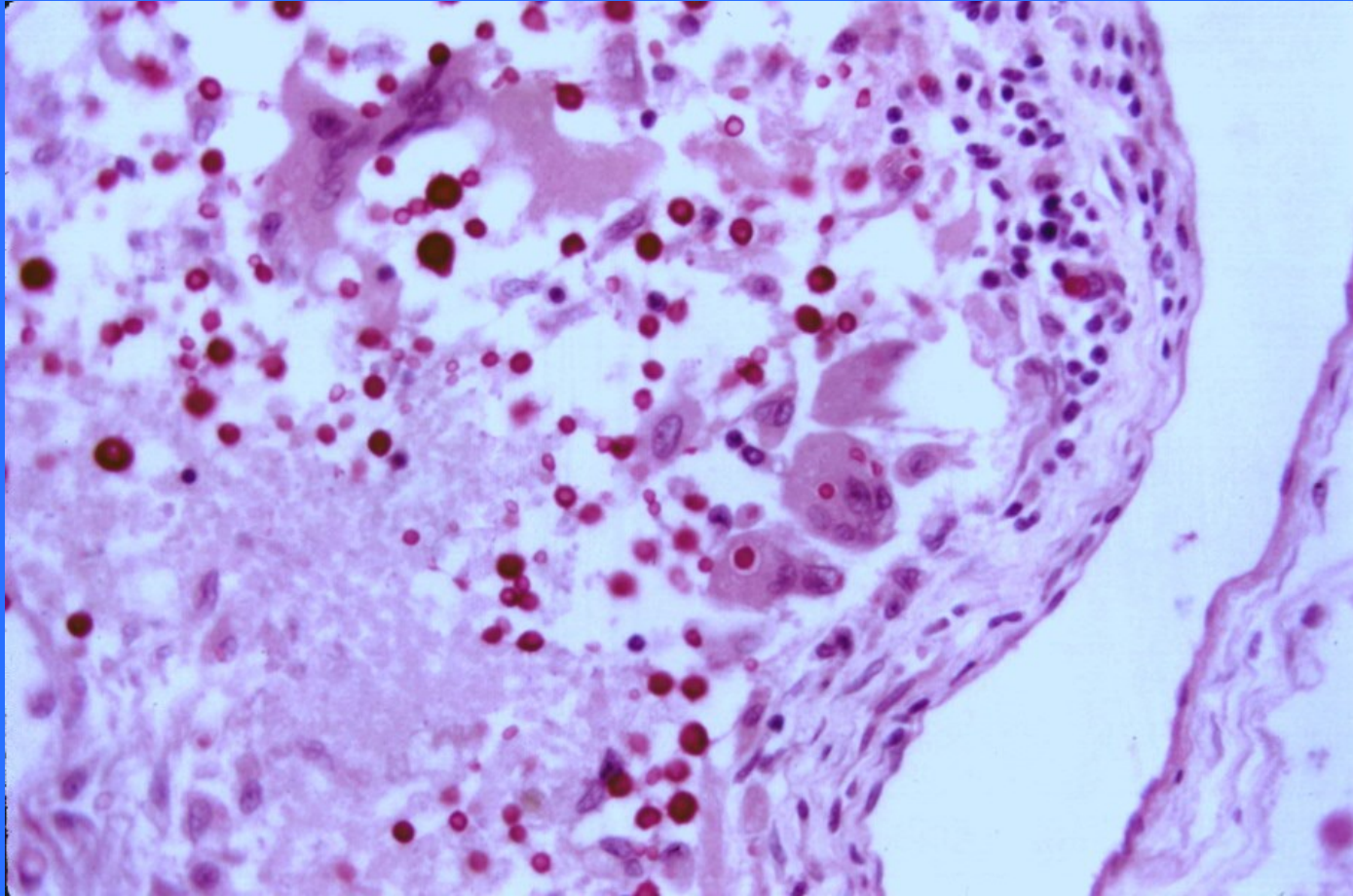


# Cryptococcus

- fungus, PAS+ capsule
- ~ 10% of AIDS patients, now ↑ diagnosis in Africa – prophylaxis started
- meningitis mostly

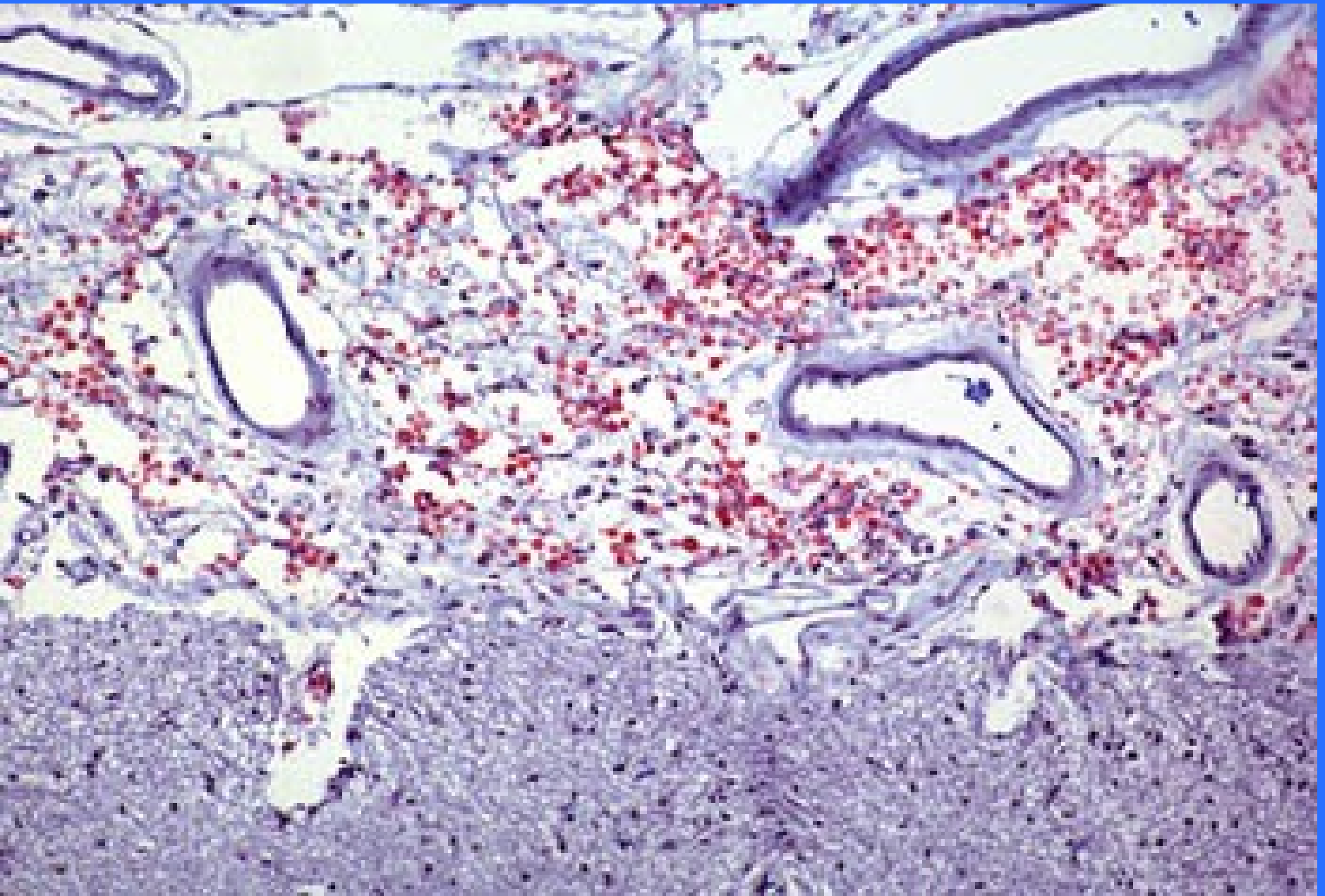
# Cryptococcal meningitis



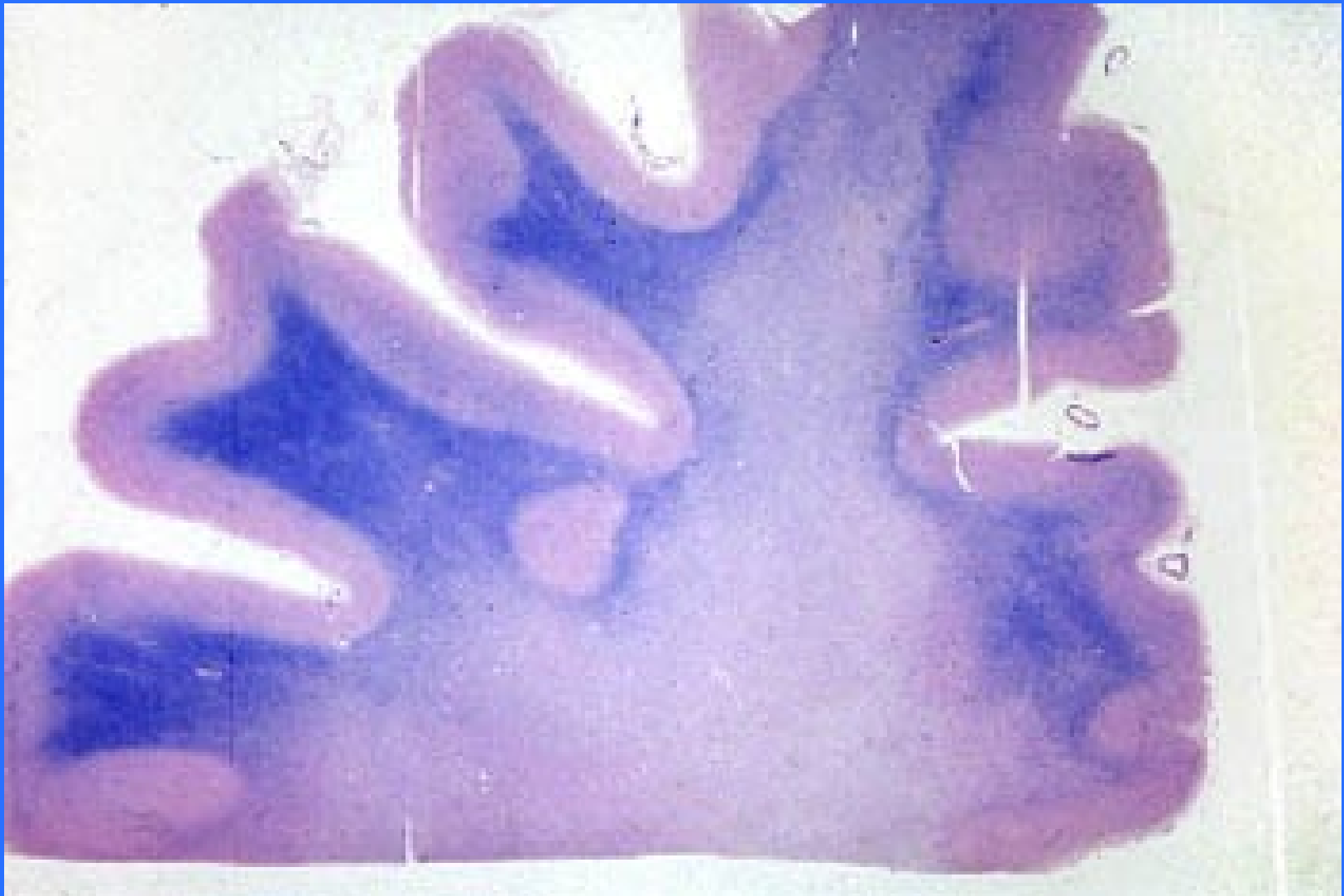

Cryptococcal meningitis

# Cryptococcal meningitis



PML: progressive multifocal leukoencephalopathy – demyelination



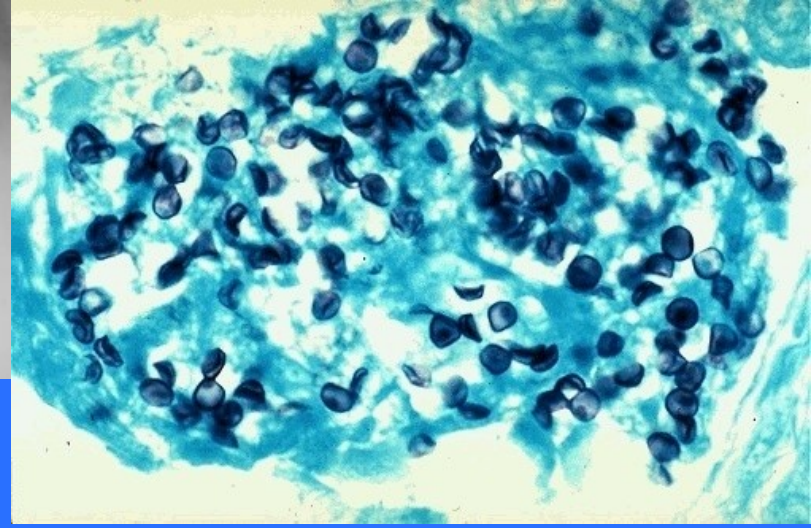
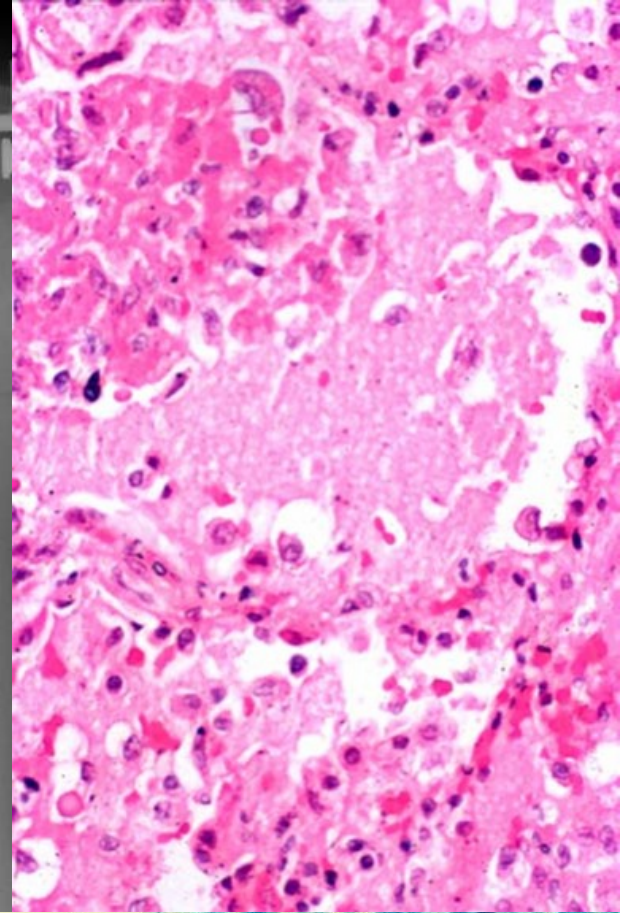
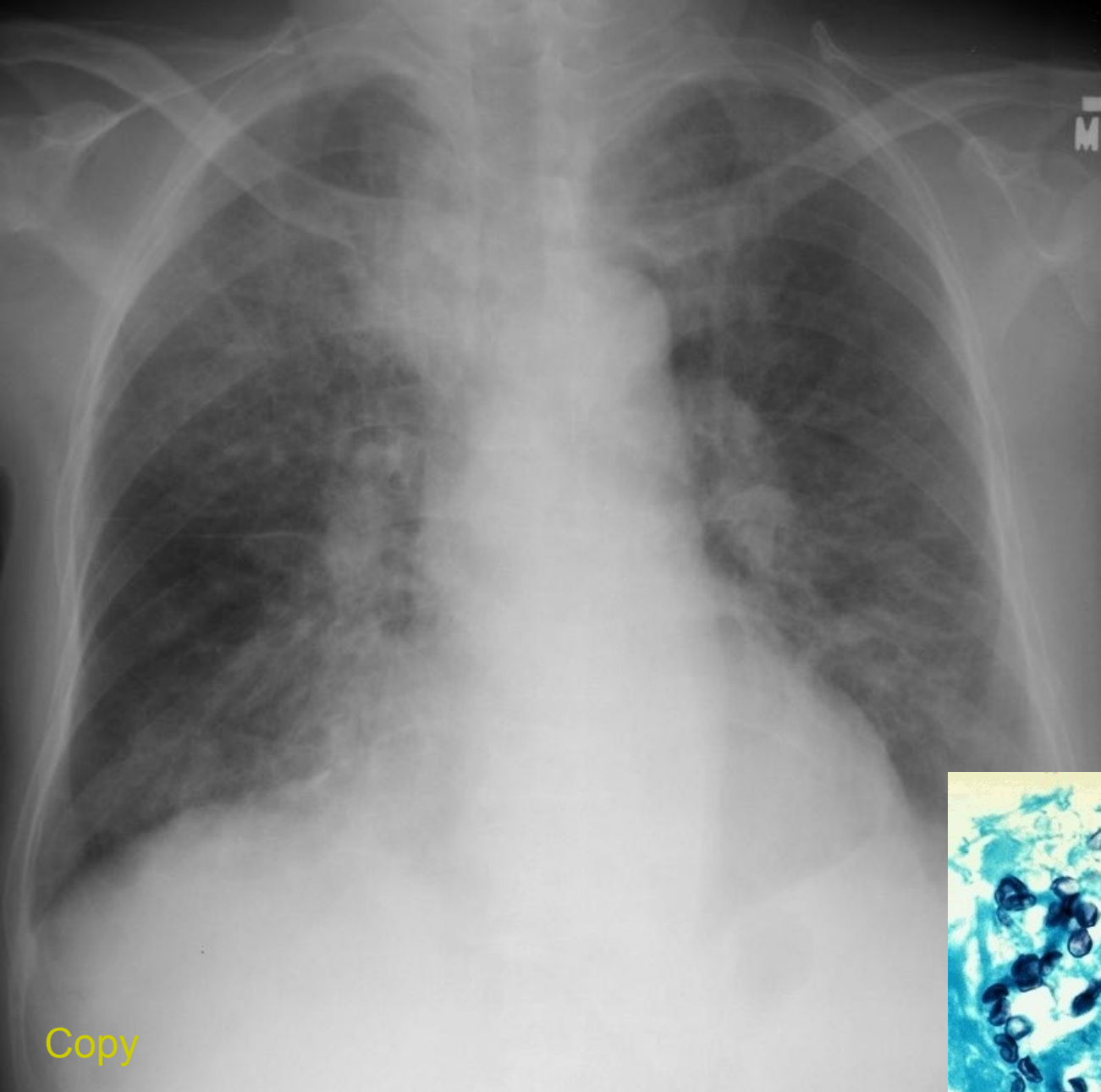
Copy

# LUNG INFECTIONS

- Pneumocystis
- Candidiasis, histoplasmosis, coccidiomycosis
- CMV (+ in combination)
- TBC
- Toxoplasmosis
- Nocardiosis

# LUNG INFECTIONS

- **Common, diffuse infiltrates:** CMV, Pneumocystis, drug reaction
- **Common, focal infiltrates:** Mycobacterium tbc, mycobacterium avium-intracellulare (MAC), G-rods, Staph. aureus, Aspergillus, Candida, malignant tumor
- **Uncommon, diffuse infiltrates:** bacteria, Aspergillus, Cryptococcus, malignant tumor
- **Common, diffuse infiltrates:** Cryptococcus, Mucor, Pneumocystis, Legionella

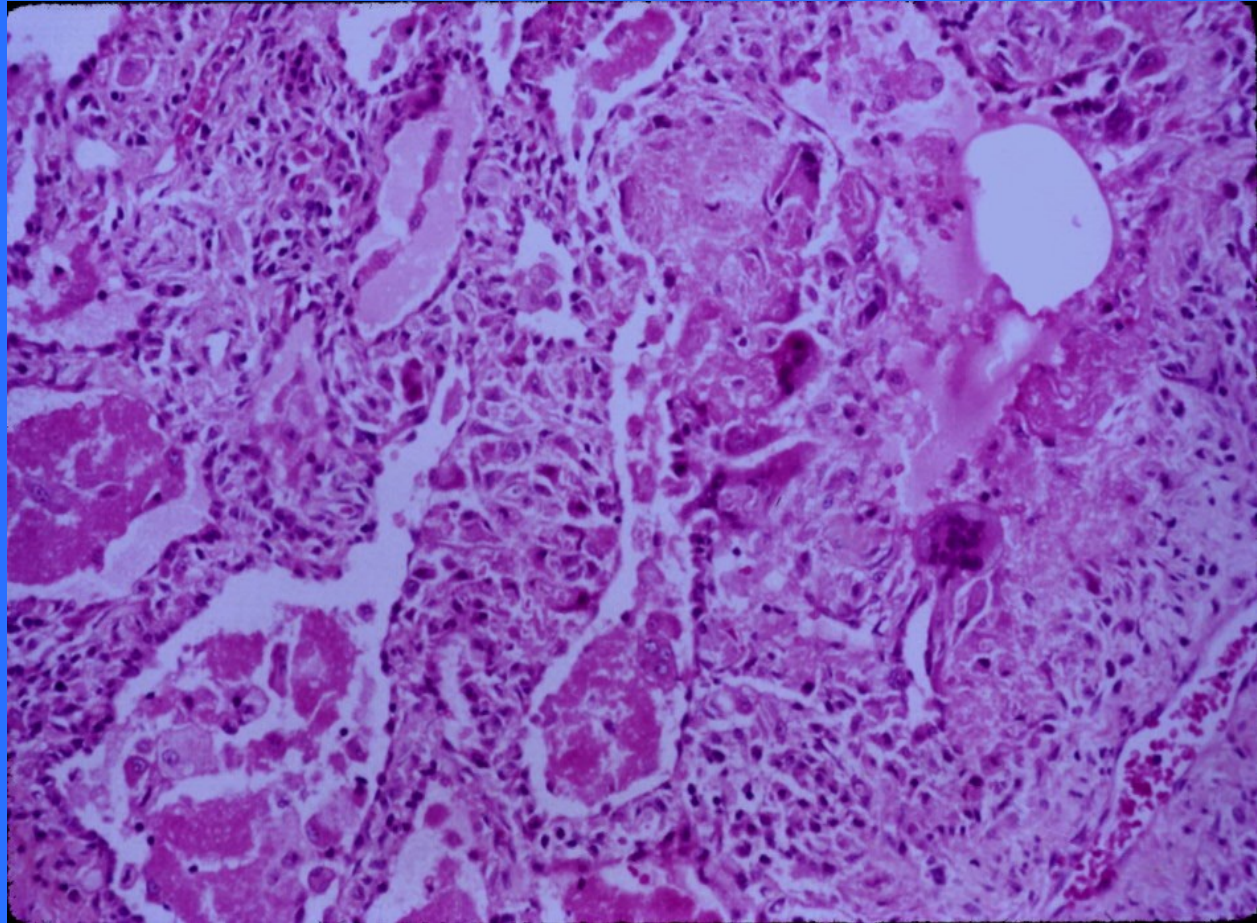


Copy

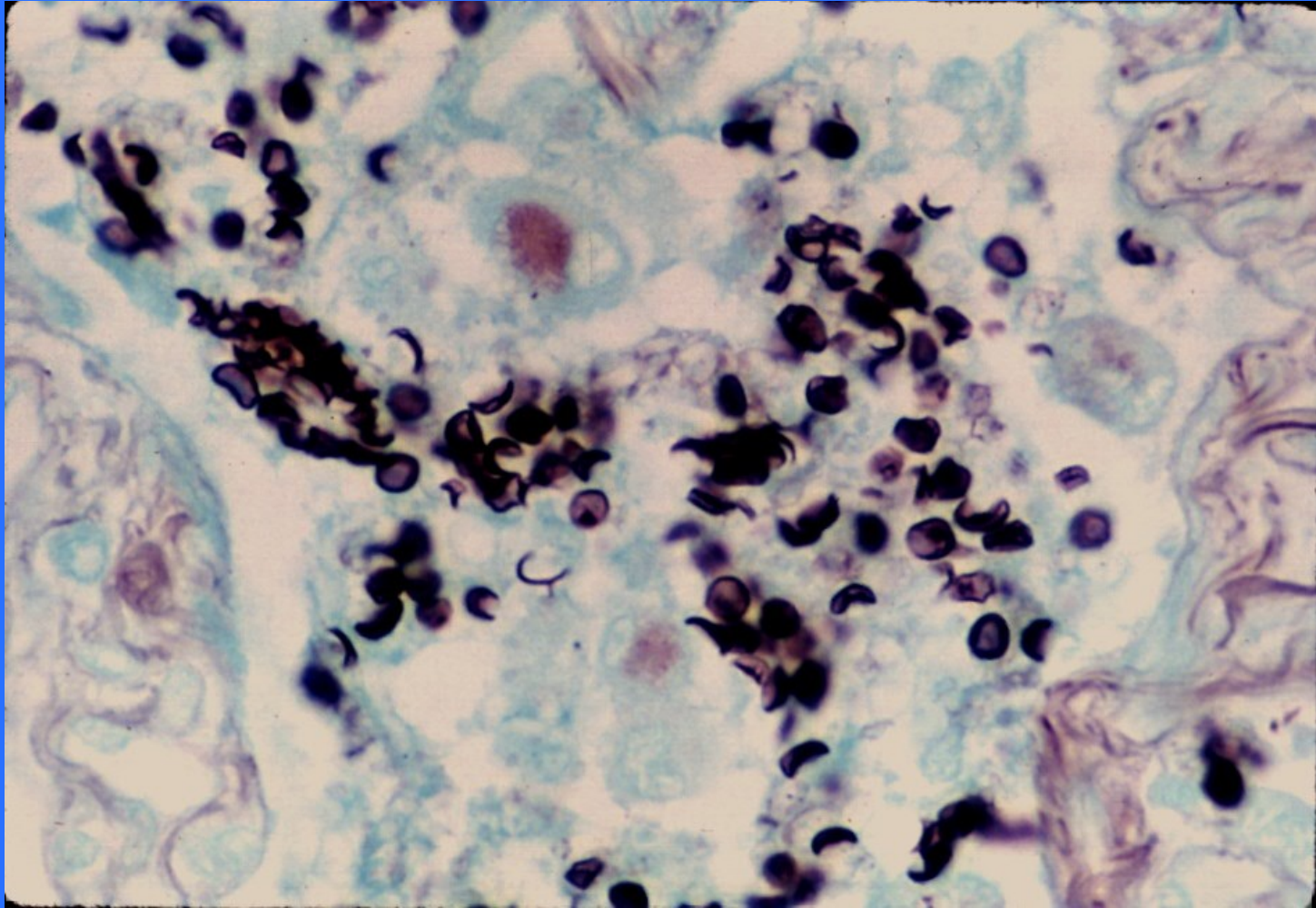
*Pneumocystis pneumonia*



# Pneumocystis pneumonia



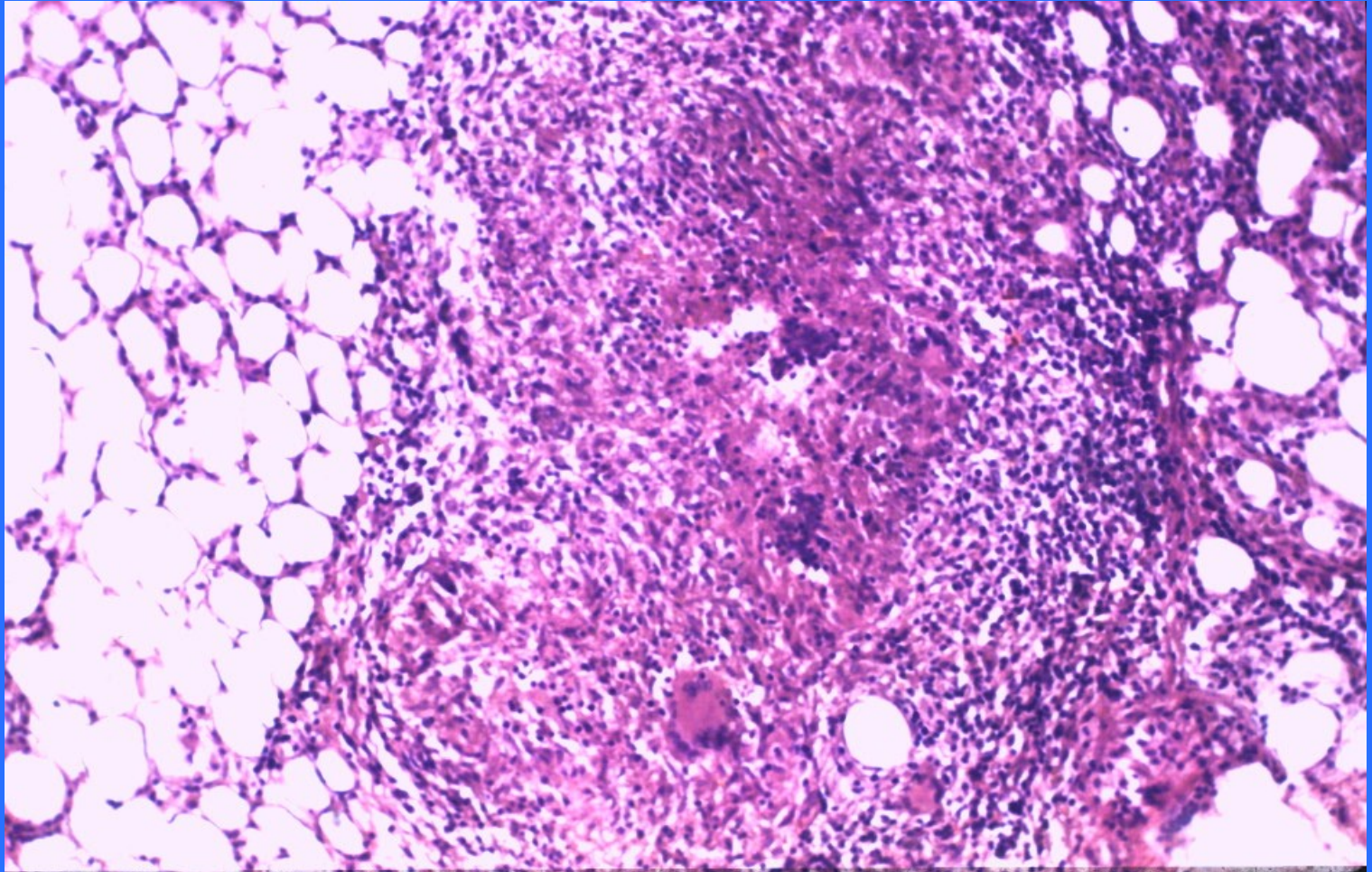
# Pneumocystis pneumonia



# TBC

- early in the course of HIV infection
- reactivation/reinfection
- pulmonary and/or disseminated
- multiple and/or highly resistant mycobacteria
- problems in combination therapy (HIV + TBC)

# TBC



# Invasive fungal infections

- *Aspergillus* spp (esp. *A. fumigatus*)

- Epidemiology

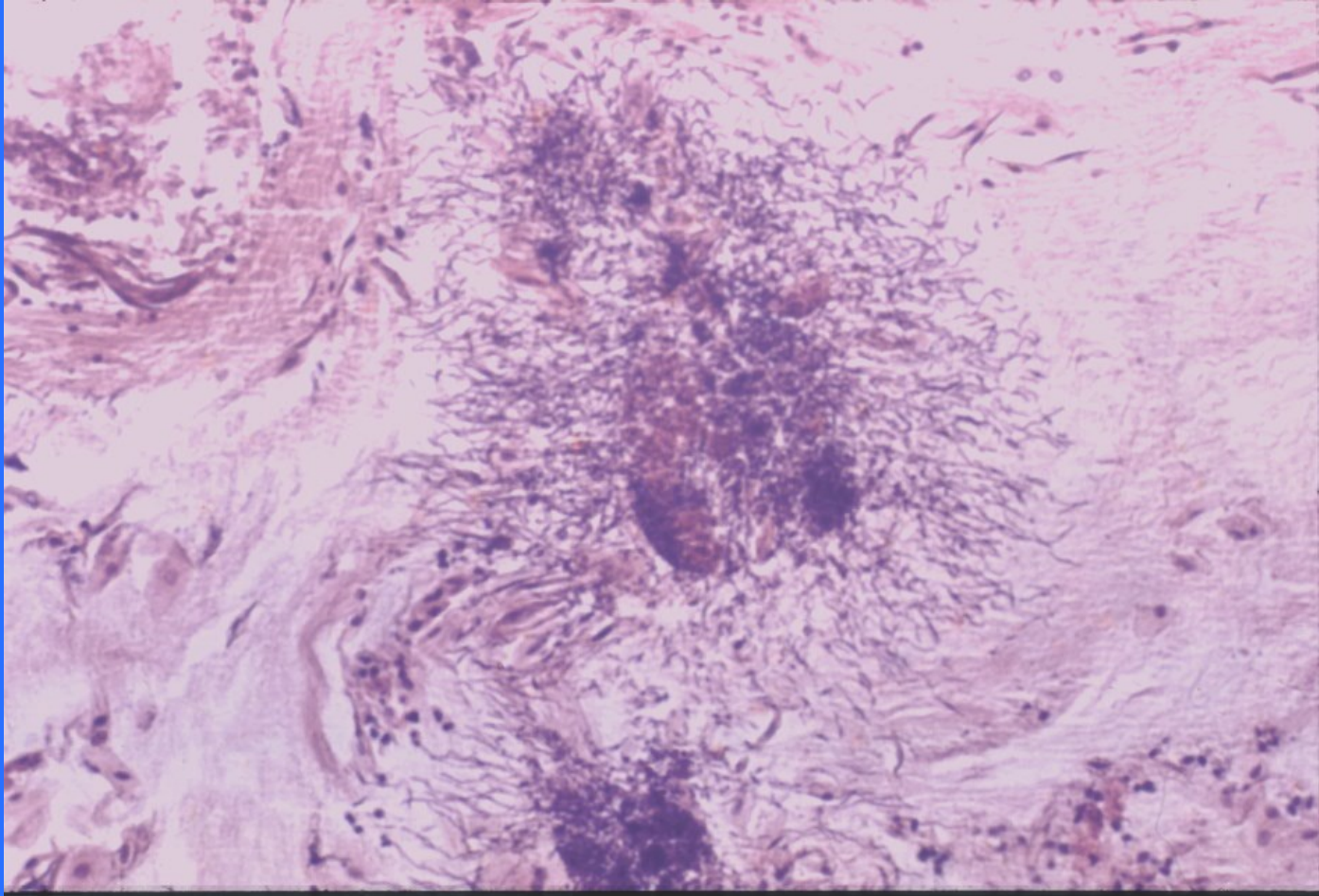
- Widespread, grows on rotting vegetation. Spores commonly present in air. Immunosuppression - important predisposing factor.

- Clinical presentations in HIV/AIDS

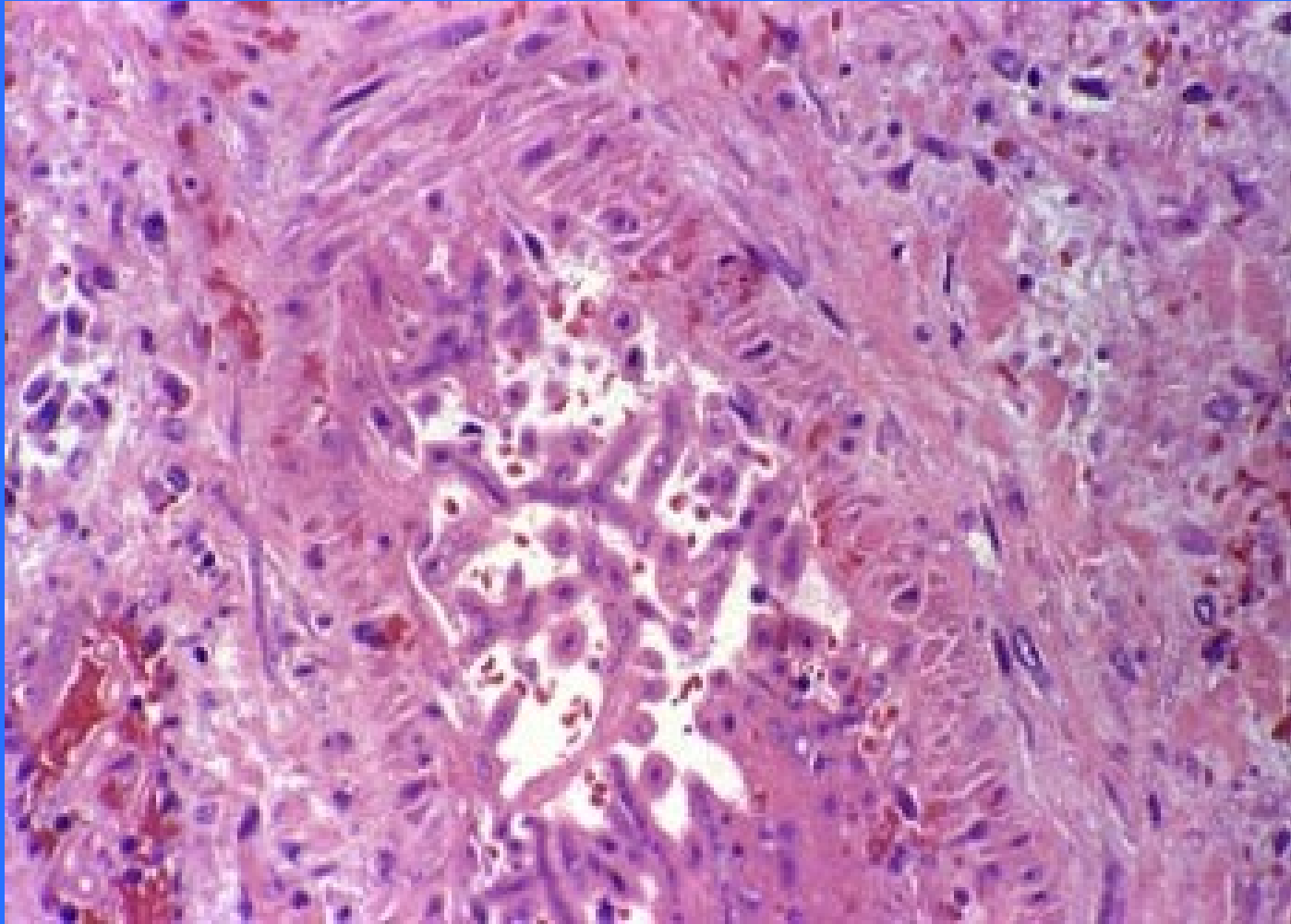
- Aspergilloma (fungal ball) - develops in cavities (lungs, sinuses, less common).

- Invasive disease - tissue destruction, pneumonia.

# Fungal colony



# Aspergillus pneumonia - angioinvasion



# Histoplasmosis

- macrophagic intracellular parasite - fungus
- clinical presentation + morphology ~tbc
- variable course: localized/self limited – coin lesion in the lung
- chronic progressive similar to tbc
- localized extrapulmonary (mediastinum, liver, adrenals, meninges)
- disseminated in immunocompromised

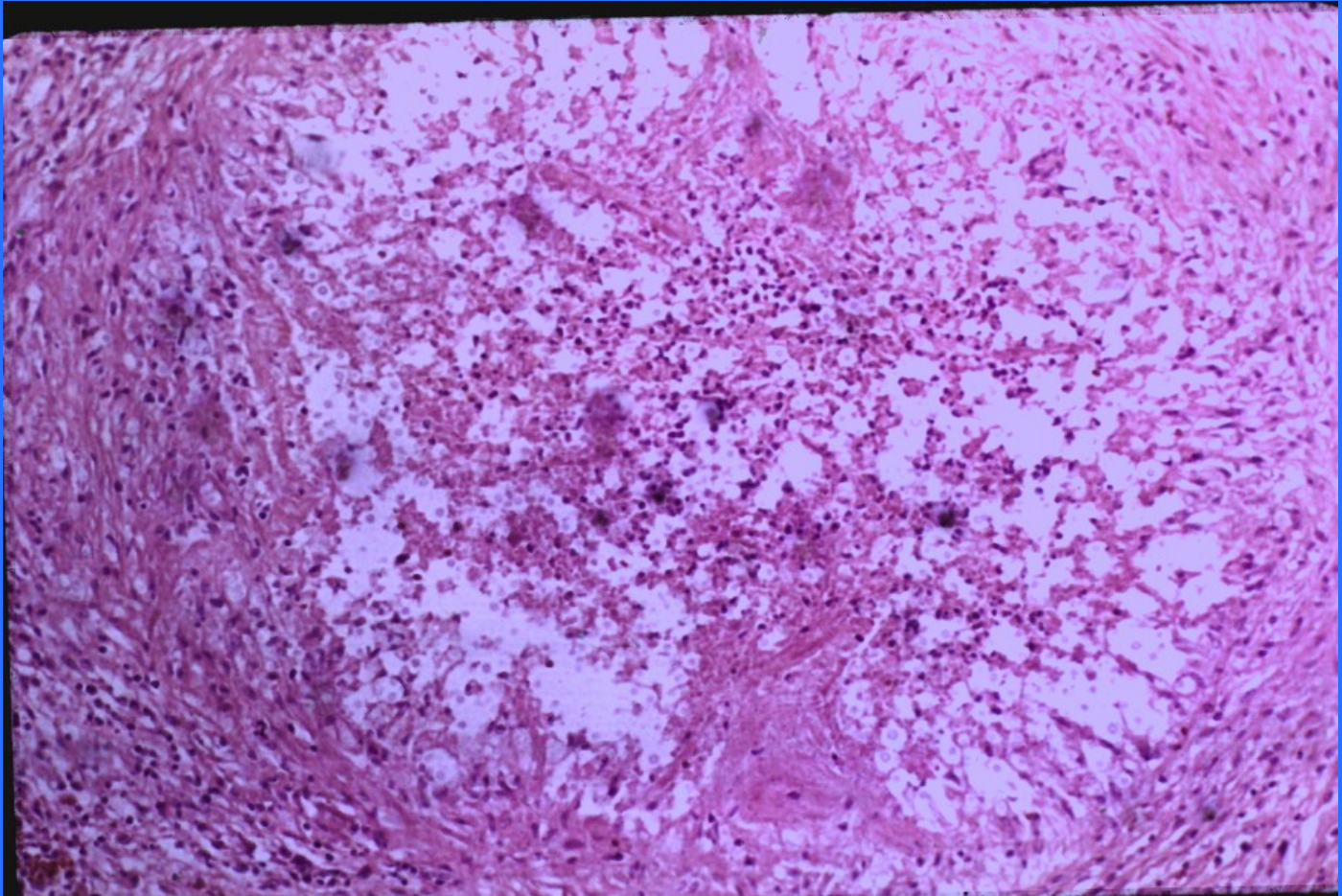


# Histoplasmosis

## Morphology

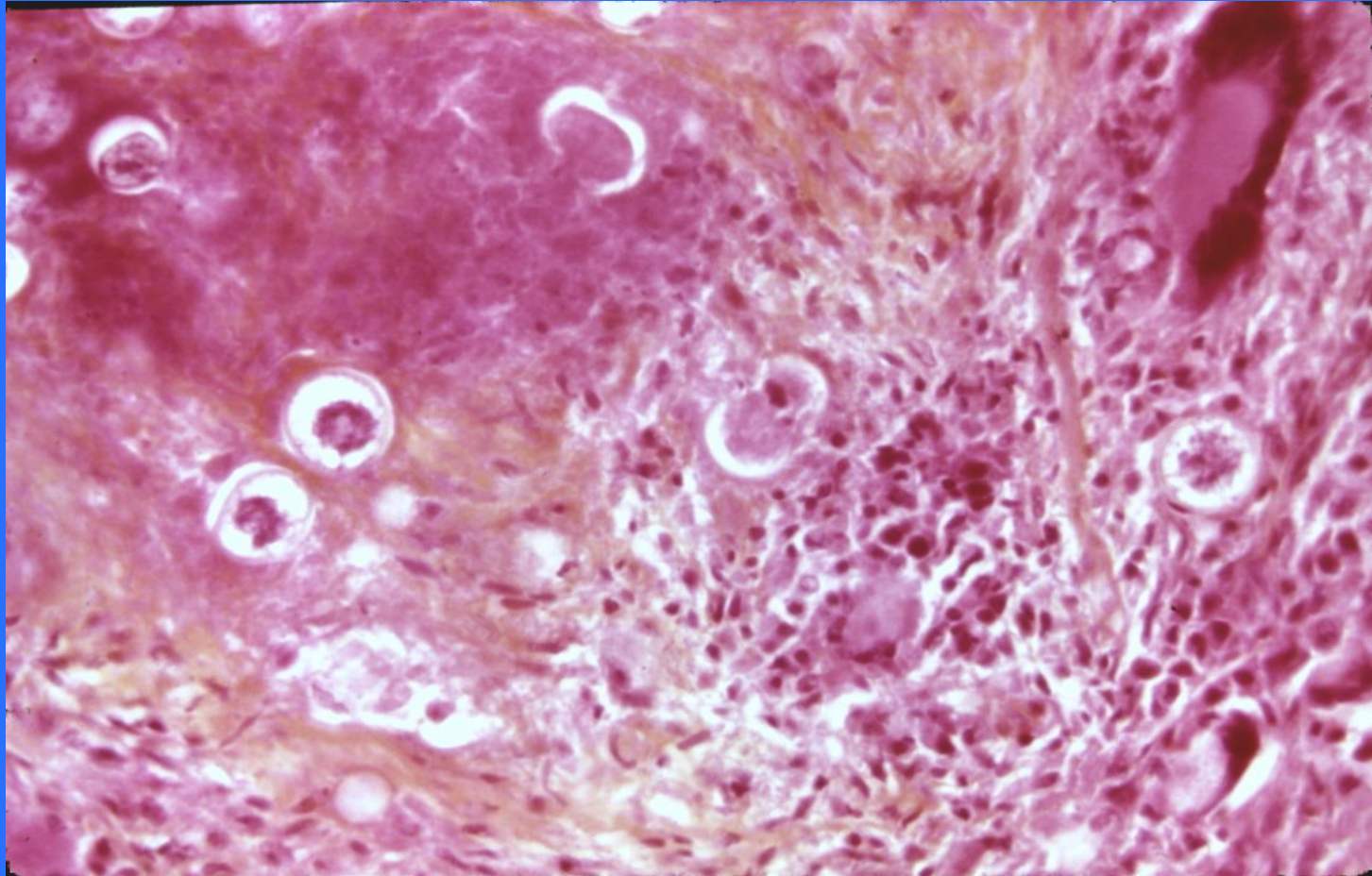
- epithelioid cell granuloma + caseous necrosis, cavities – fibrosis – calcification
- in immunodeficient – no granuloma; accumulation of macrophages with fungal yeasts
- dg. – identification of fungal bodies (x tbc, coccidiomycosis), culture, Ab

# Histoplasmosis

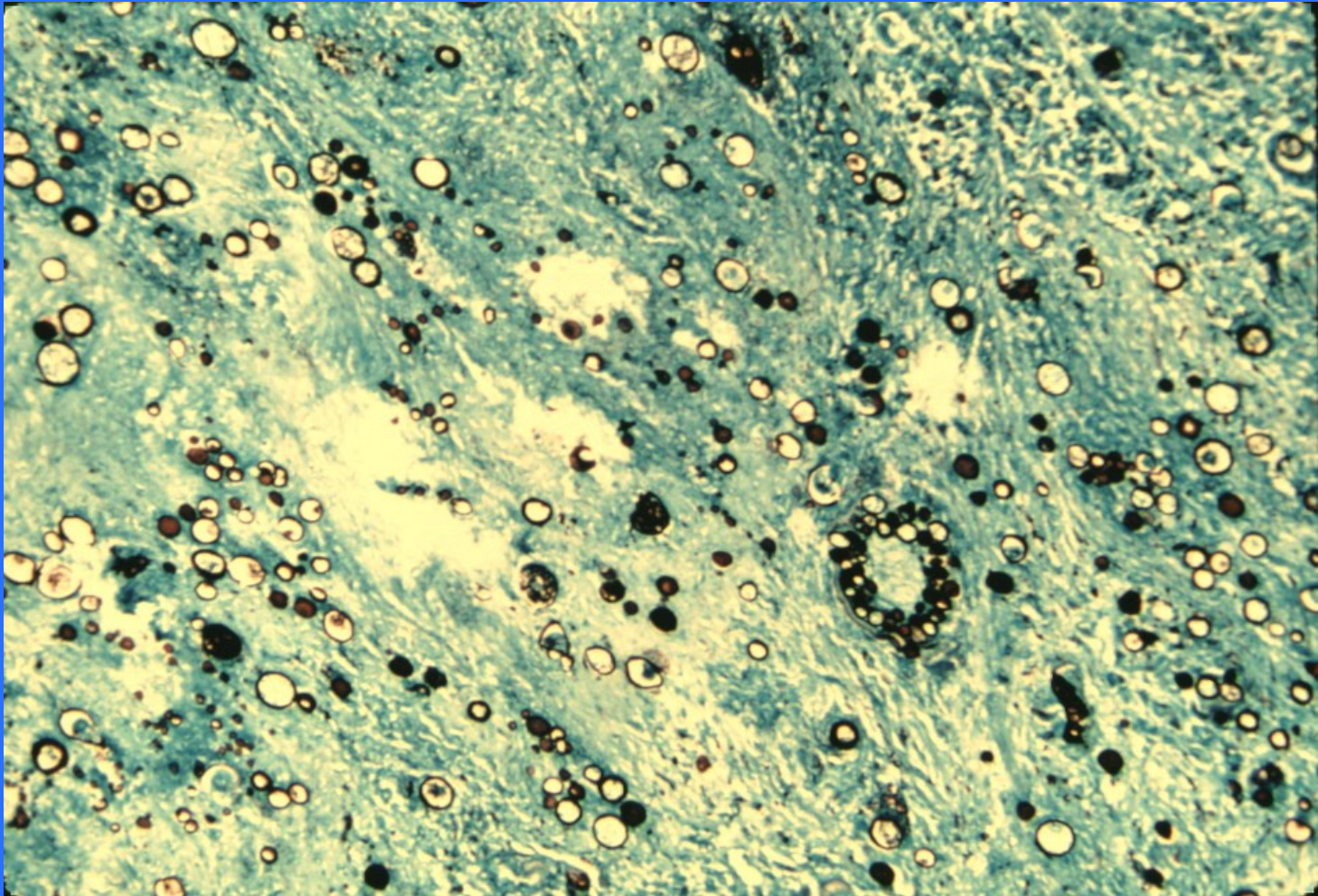


Copy

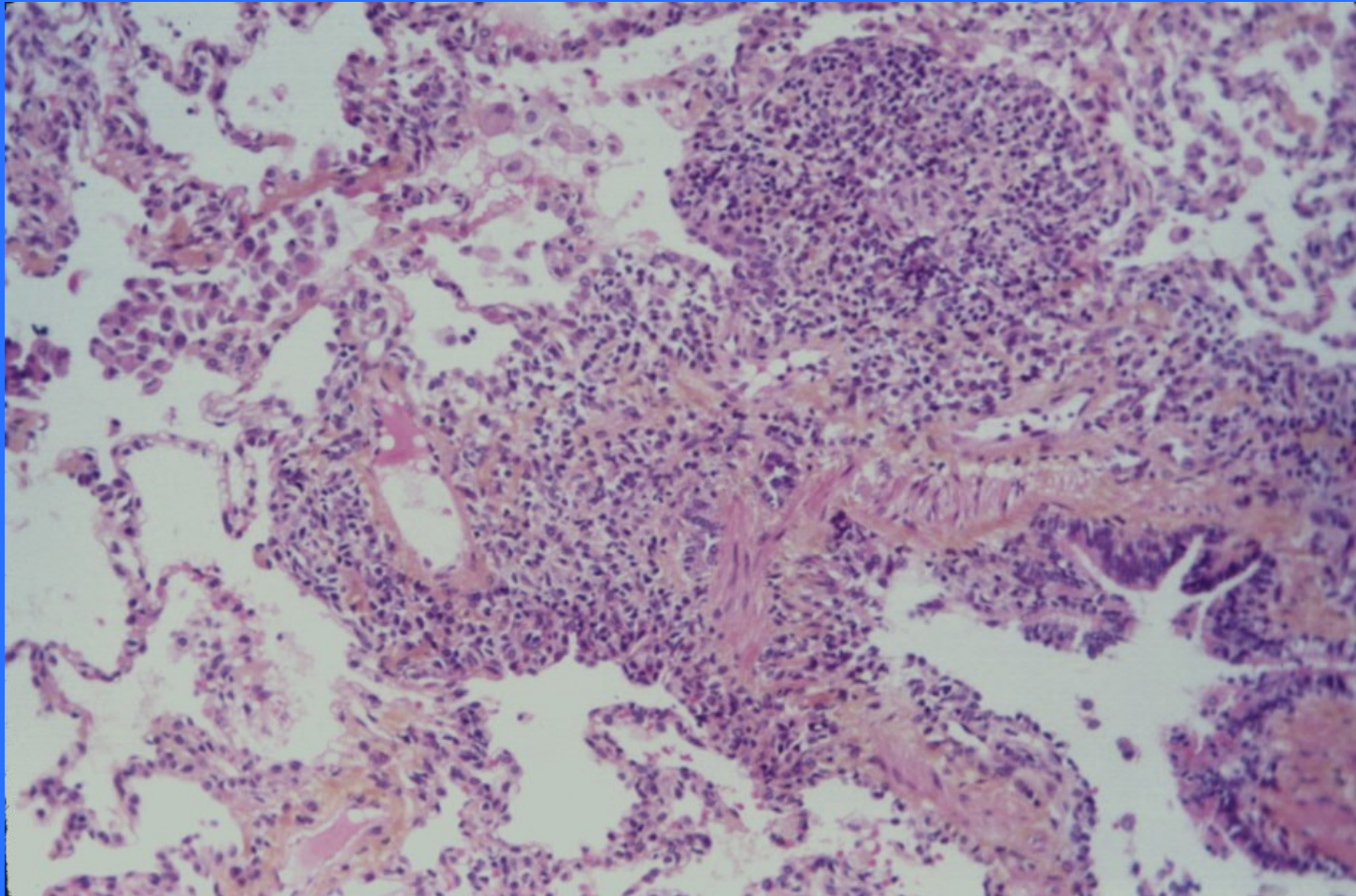
# Coccidiomycosis



# Coccidiomyces



# Interstitial pneumonia - viral

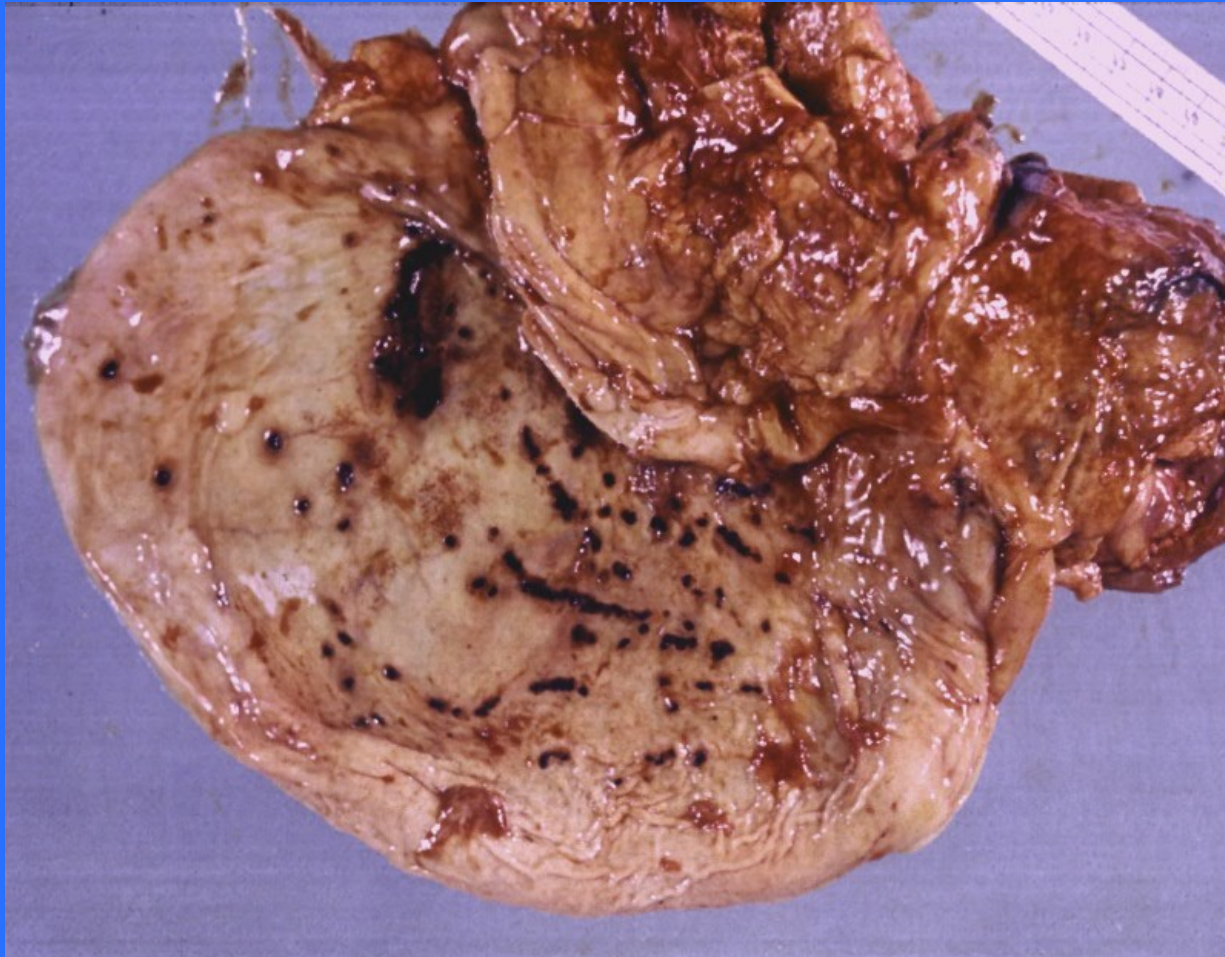


# GIT INFECTIONS

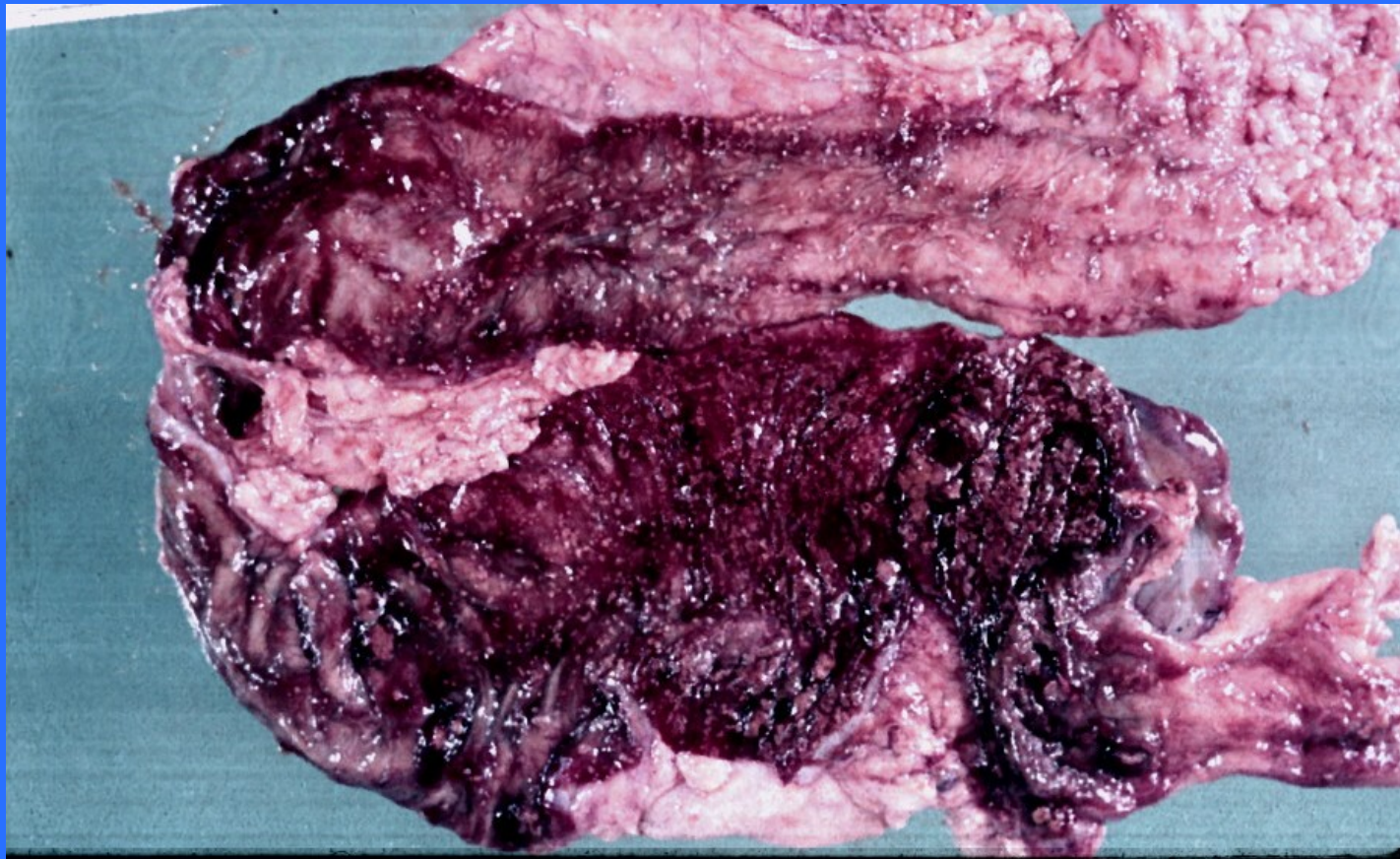
Very common, persistent diarrhea

- Cryptosporidiosis, isosporidiosis (protozoa; watery diarrhea, major fluid loss; dg.- oocysts in the stool)
- Atypical mycobacteriosis (M. avium-intracellulare complex)
- Salmonella, Shigella
- CMV

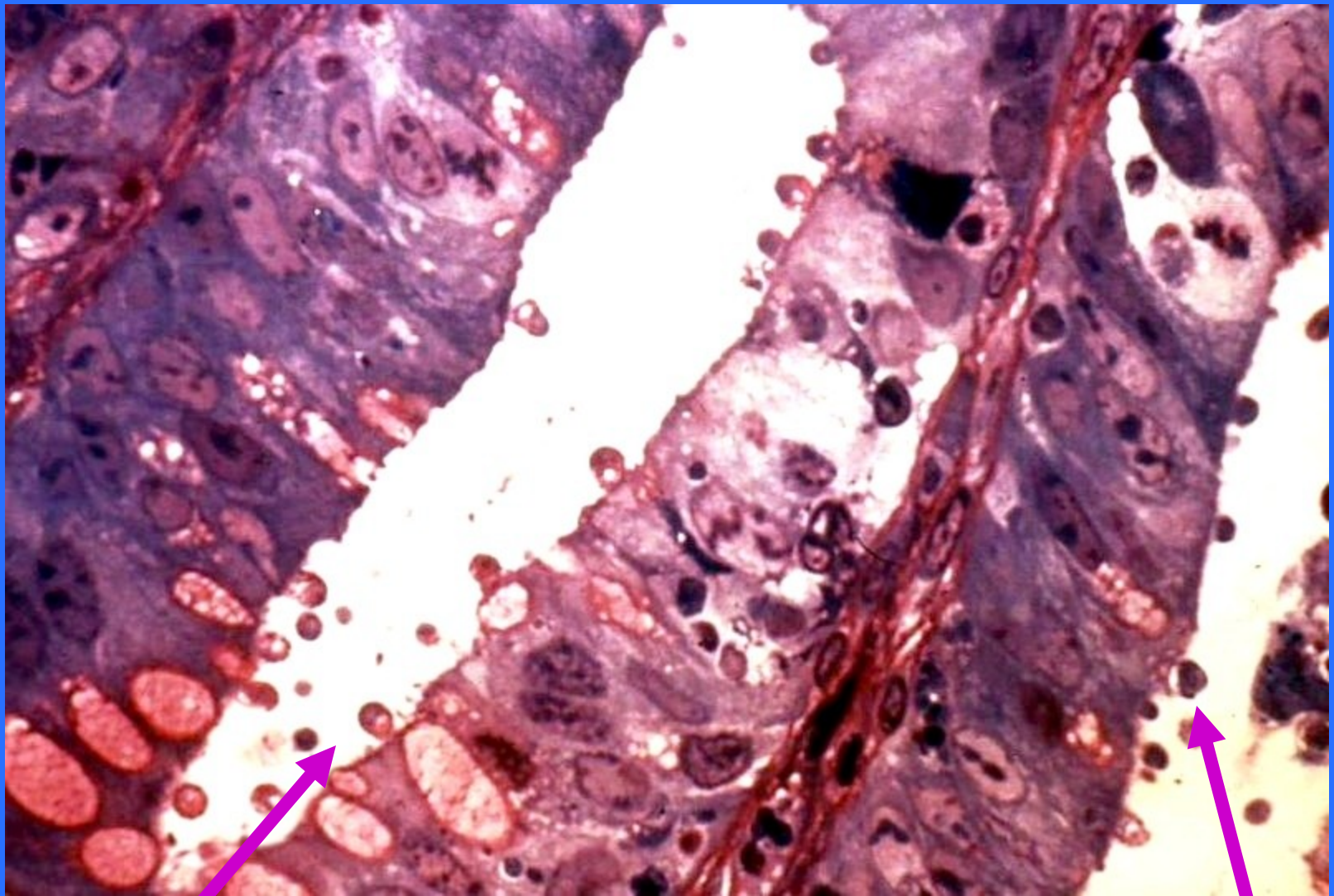
# Erosive gastritis



# Haemorrhagic colitis



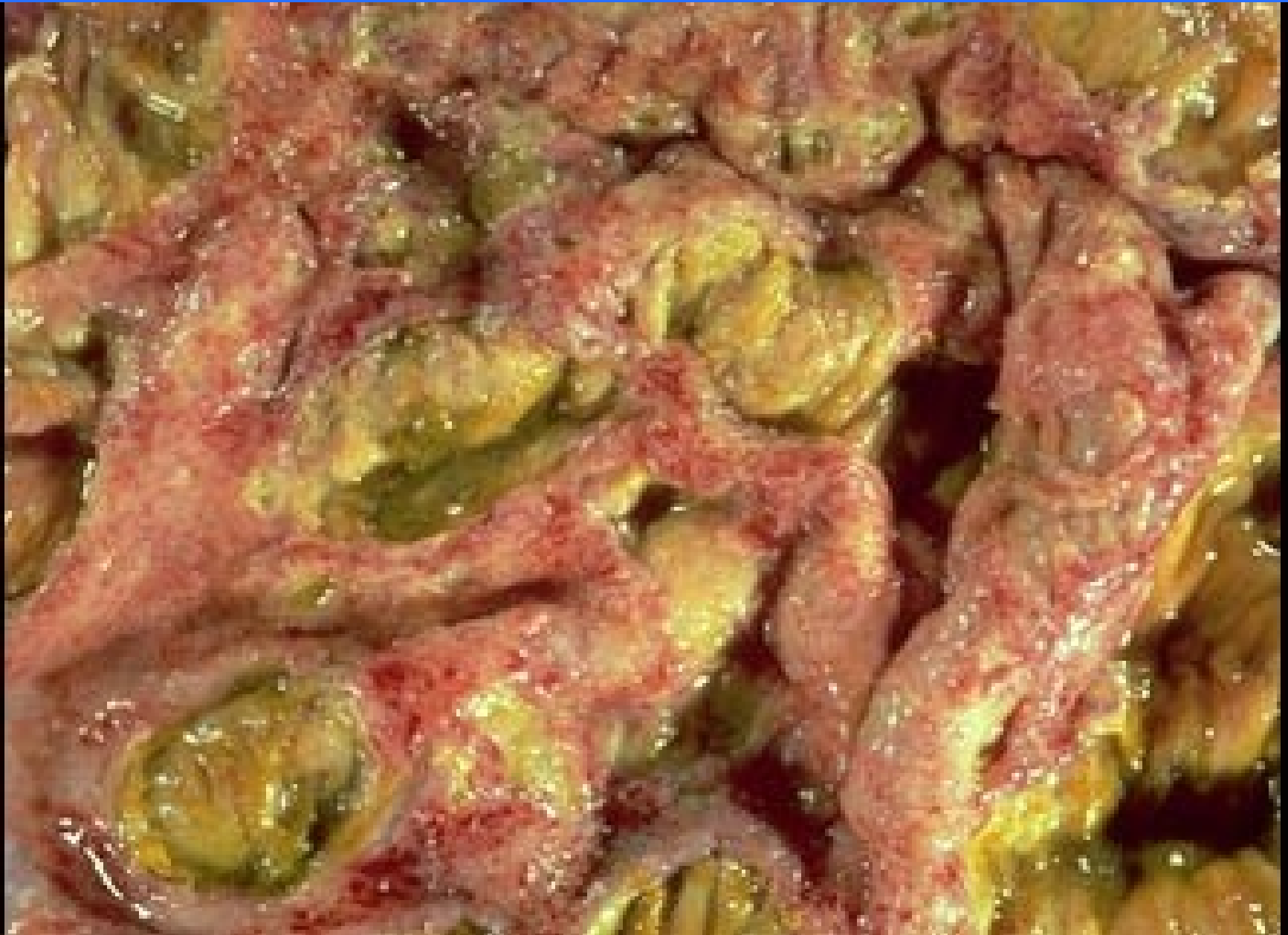



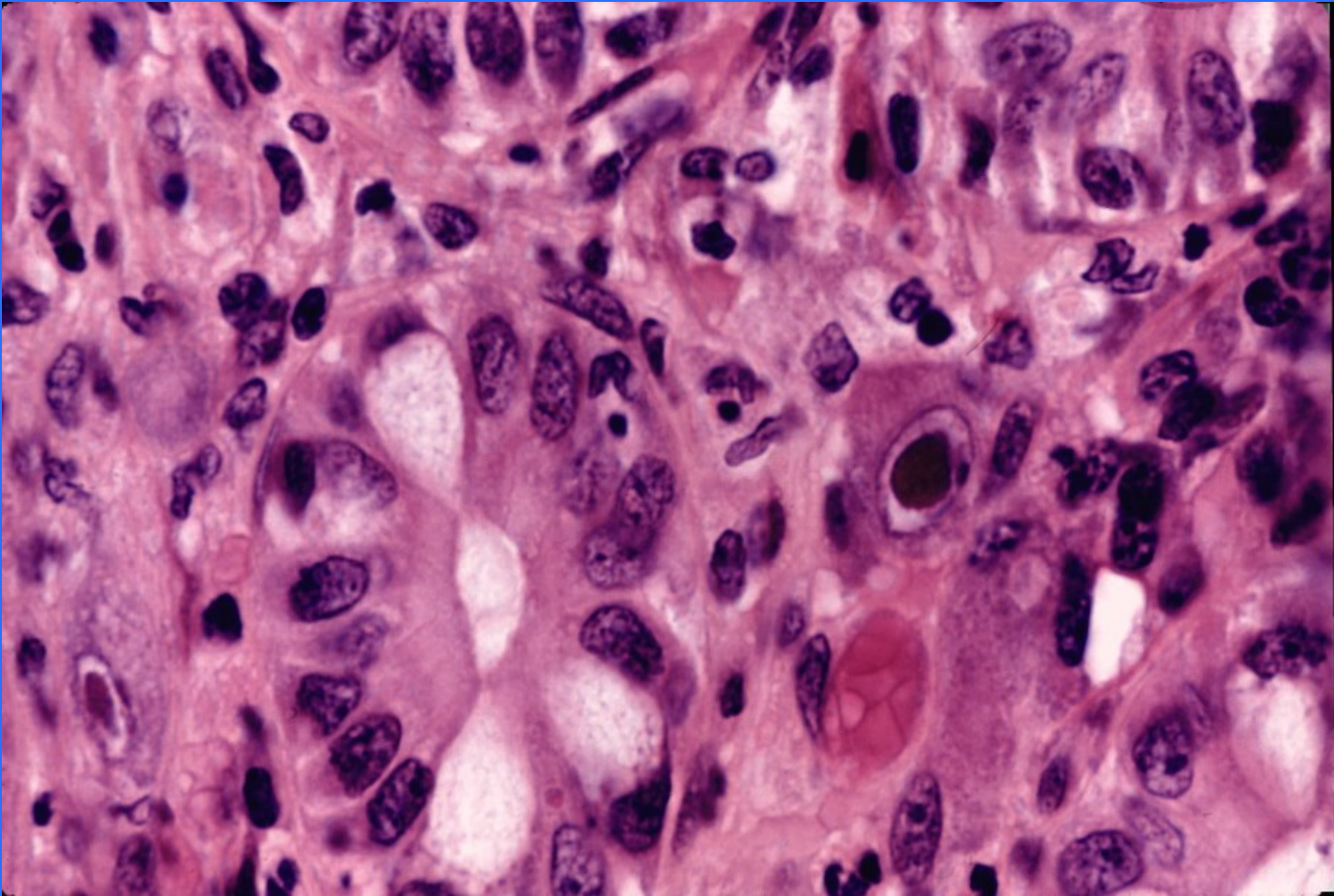
**CRYPTOSPORIDIUM**

copy

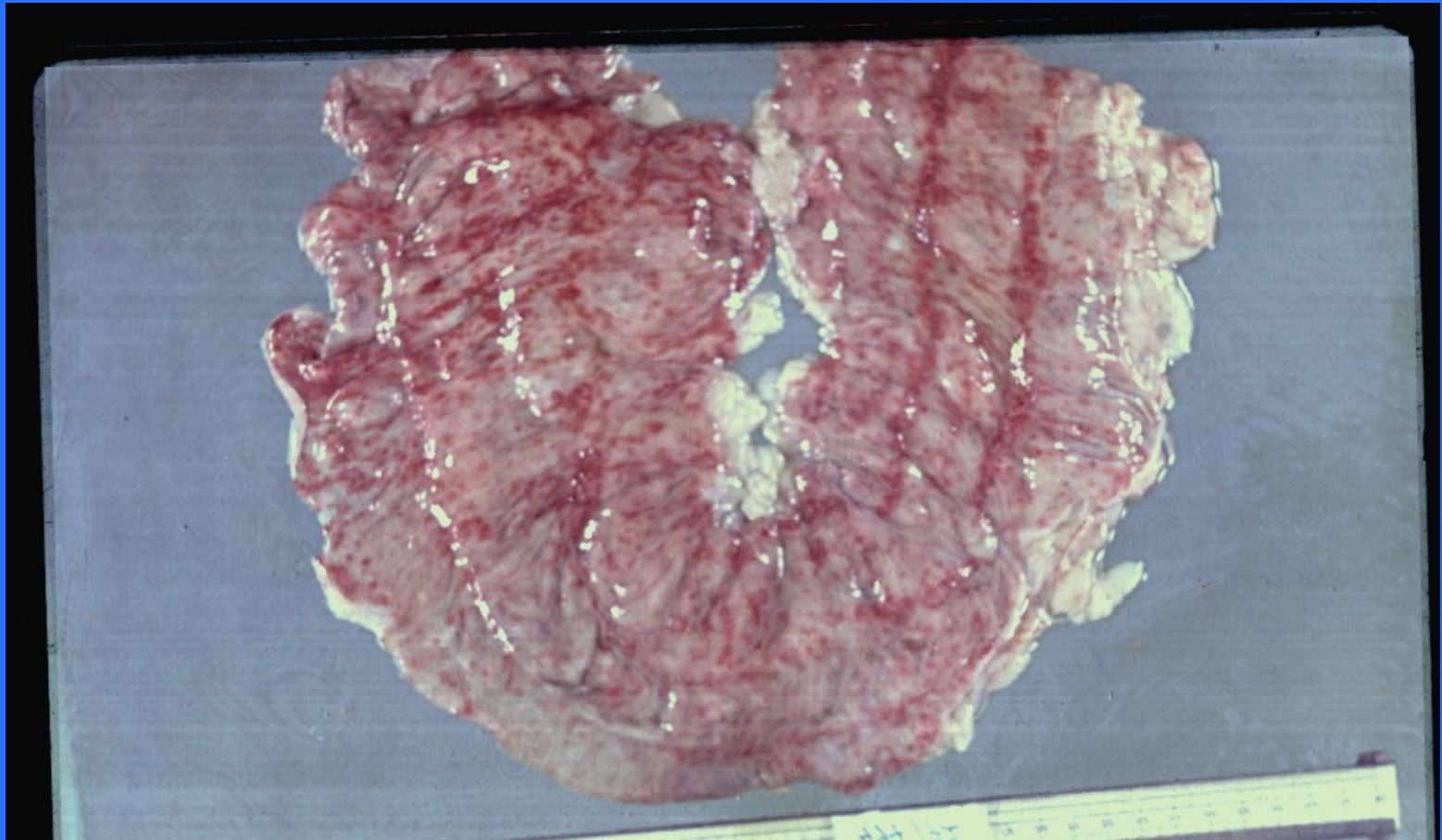
# CMV colitis



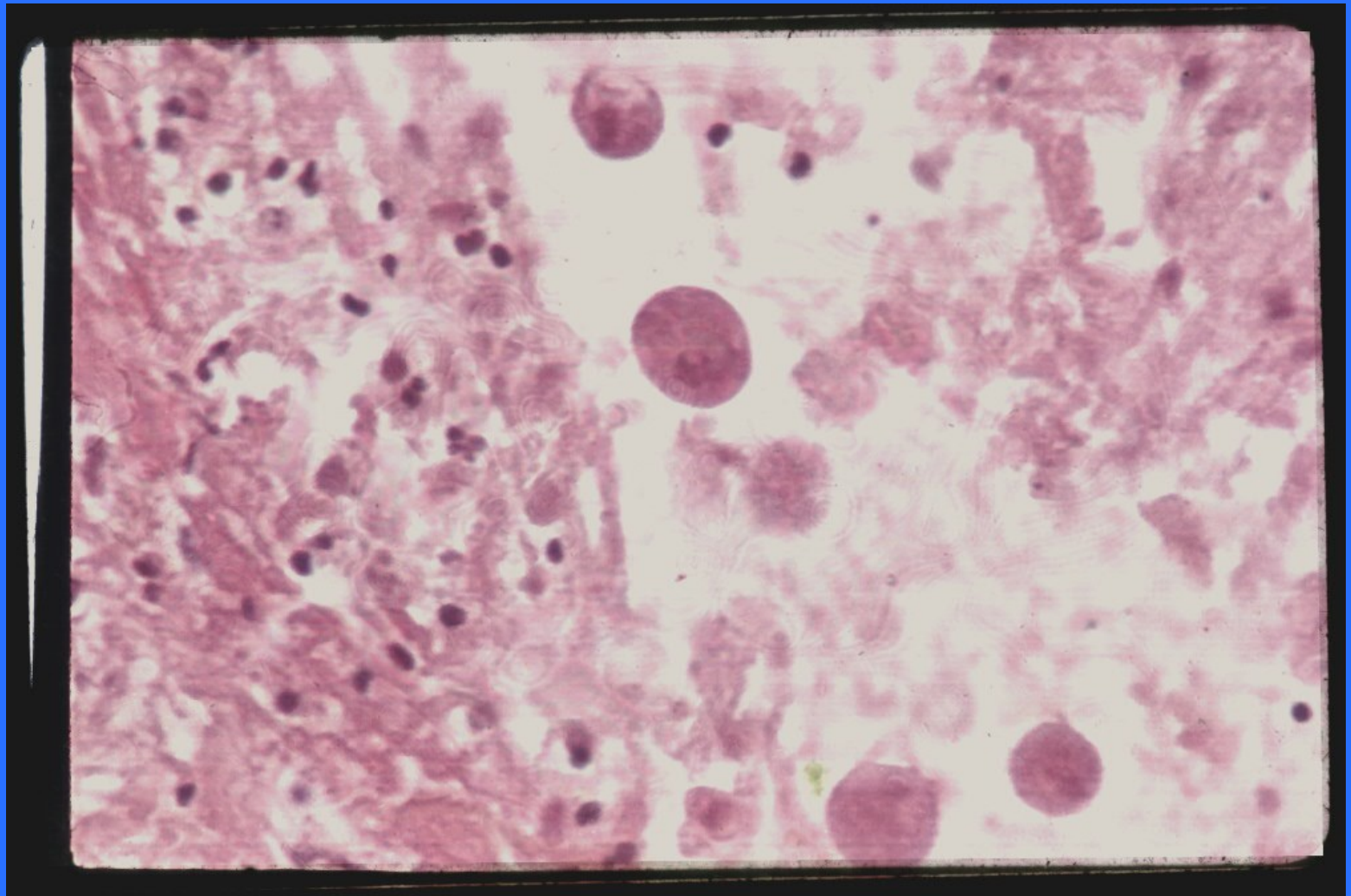
CMV colitis



# Protozoan colitis (amoebiasis)



# Protozoan colitis (amoebiasis)

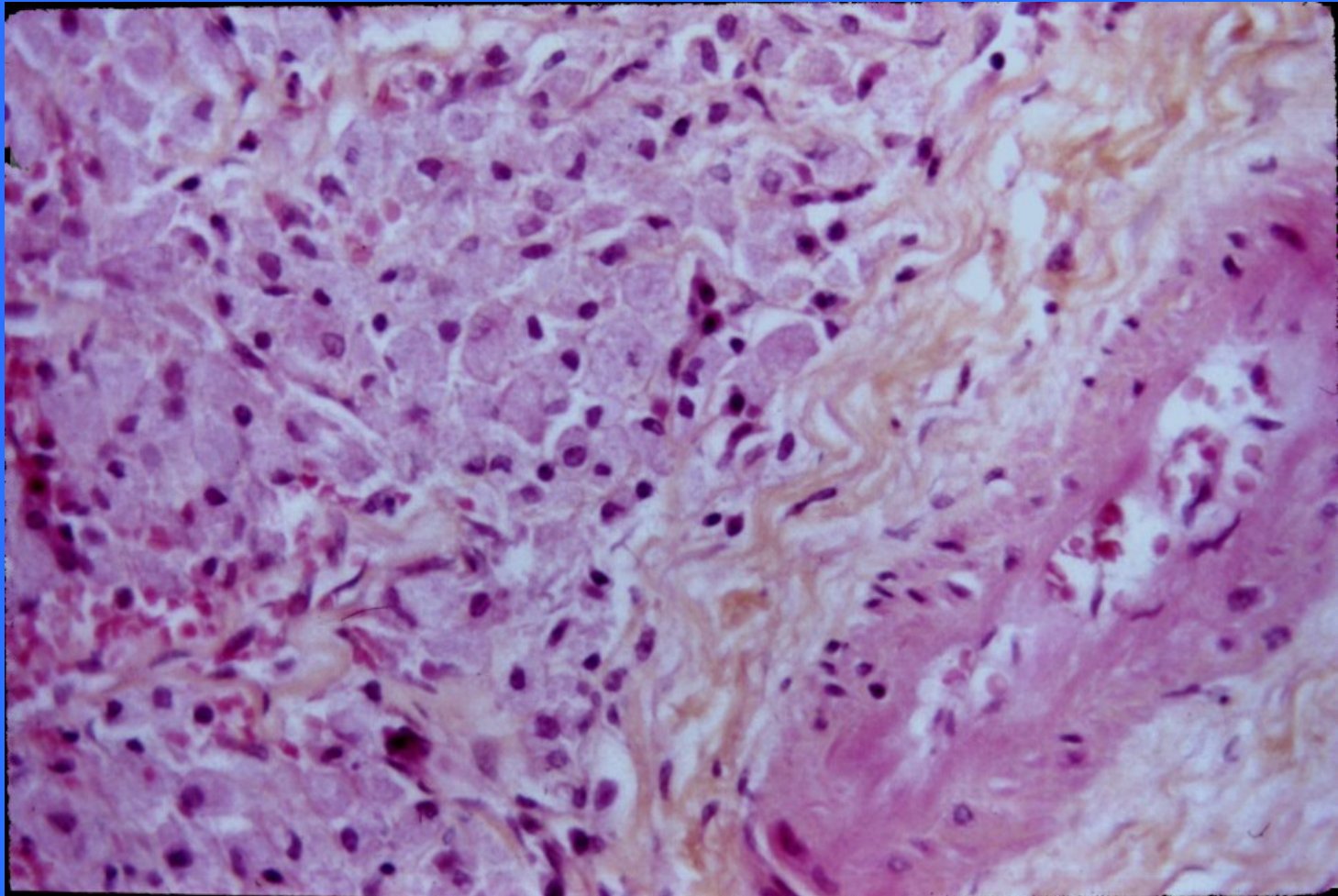


# **Mycobacterium avium complex (MAC) enteritis**



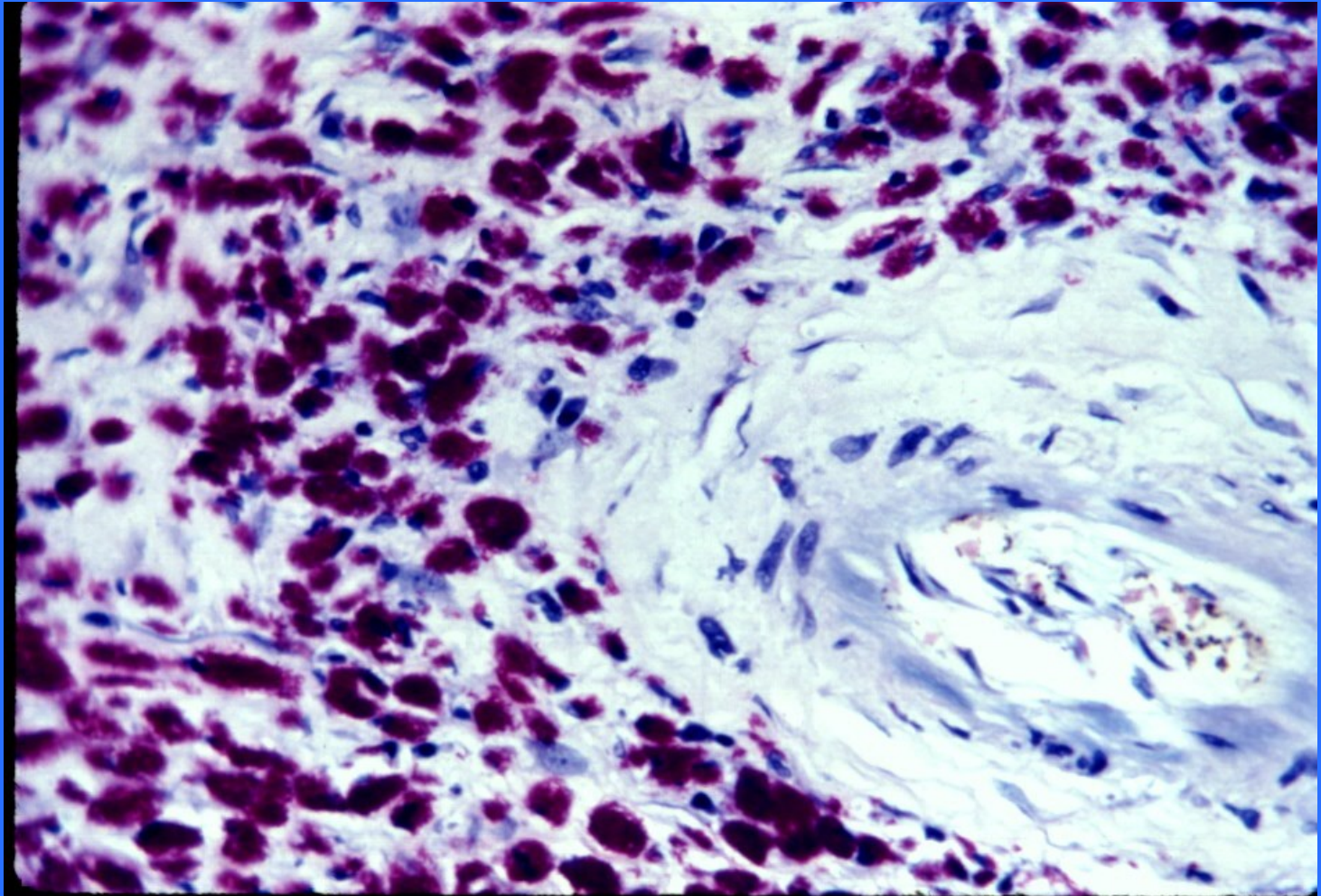
copy

# MAC enteritis



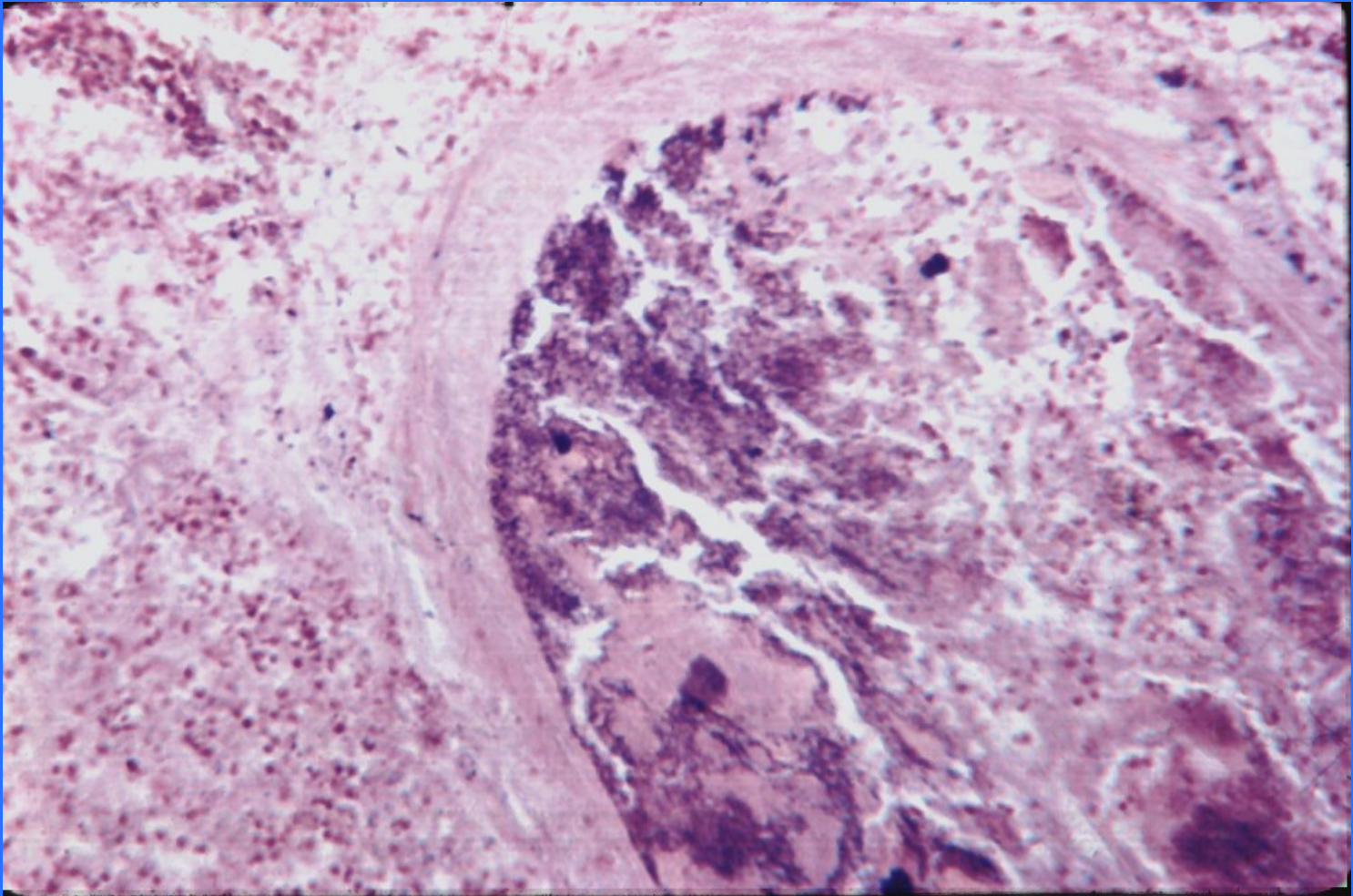
copy

# MAC enteritis





# Bacterial thrombus



# HIV + hepatitis co-infection

- Common coinfection of HIV + HBV and/or HCV
- ↑ acute HCV in HIV infected
- accelerated progression of chronic hepatitis to cirrhosis + liver failure
- problems in HAART / HCV drug interaction and toxicity
- value of the transplantation?

# SKIN + ORAL INFECTIONS

- Chronic, relapsing, non-healing
- Commonly ulcers
- EBV + HIV – oral hairy leukoplakia
- Candida
- HSV, VZV

# Oral lesions

- Oral lesions due and according to the rate of loss of T-helper cells.
- Oral lesions - prominent features of AIDS and HIV infection.
- Early studies: approximately 90% of HIV+ patients will present with at least one oral lesion in the course of their illness.
- Current studies report the prevalence of oral lesions has significantly declined (HAART)

# Oral hairy leukoplakia

- Associated with chronic shedding of EBV in the oral cavity.
- Presentation: Poorly demarcated, corrugated, white plaques on lateral aspect of tongue.
- Unlike thrush, cannot be removed by scraping.
- Occurs with immunosuppression (esp. AIDS) and warrants HIV workup.
- Diagnosis by microscopy and in situ hybridization
- Management includes establishing diagnosis and treating immunosuppression.

# HIV/AIDS oral-pharyngeal syndromes

- Interferes with oral hygiene
  - More oral pharyngeal pathology
- Interferes with nutritional intake
  - Wasting syndrome
- **HIV treatment compliance** may be impacted by oral pain, xerostomia, dysphagia
- Psychosocial dimensions
  - Avoidance of social contact due to facial appearance
  - Depressive effects of persistent oral pain

# Oral lesions strongly assoc. with HIV

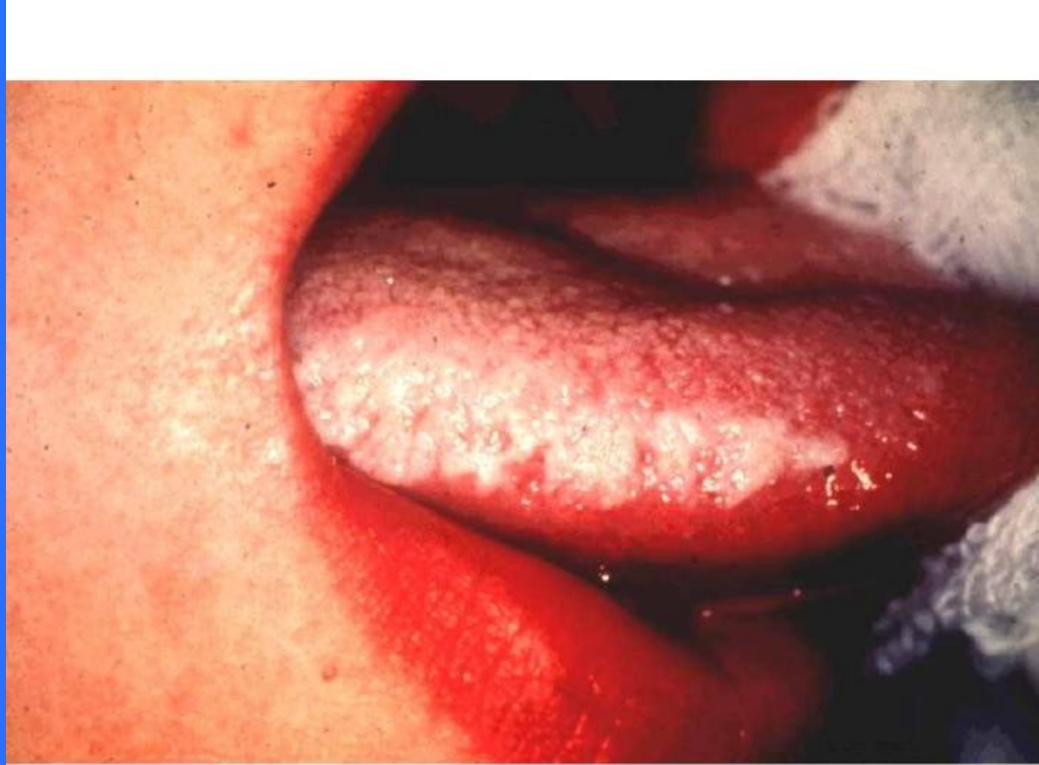- Candidiasis – erythematous, hyperplastic, pseudomembranous
- Hairy leukoplakia (EBV)
- HIV-associated periodontal disease – necrotizing ulcerative gingivitis, HIV periodontitis, necrotizing stomatitis
- Kaposi's sarcoma (HHV-8)
- Non-Hodgkin's malignant lymphoma (EBV)

# HIV/AIDS oropharyngeal syndromes – most common

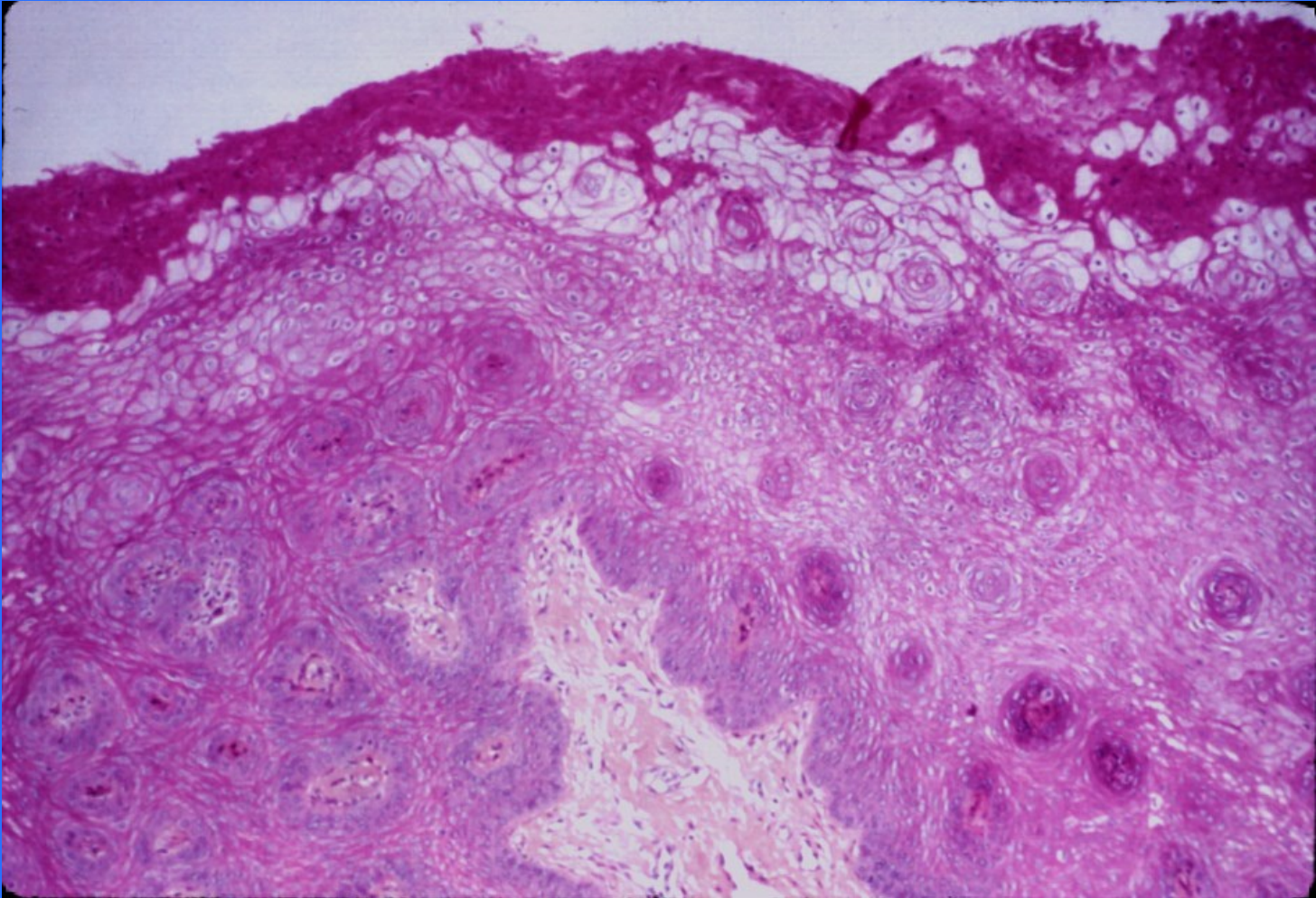
- Candidiasis 28%-75%
- Necrotizing gingivitis
- HSV, CMV, HIV, EBV ulcers
- Recurrent aphthous ulcers
- Zalcitabine ulcers
- Kaposi's sarcoma
- Dental abscesses



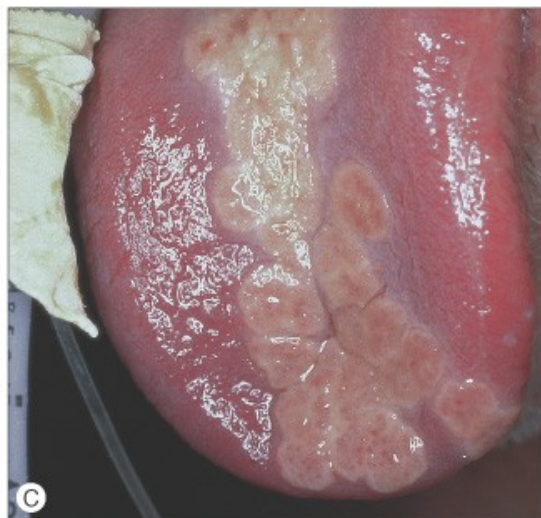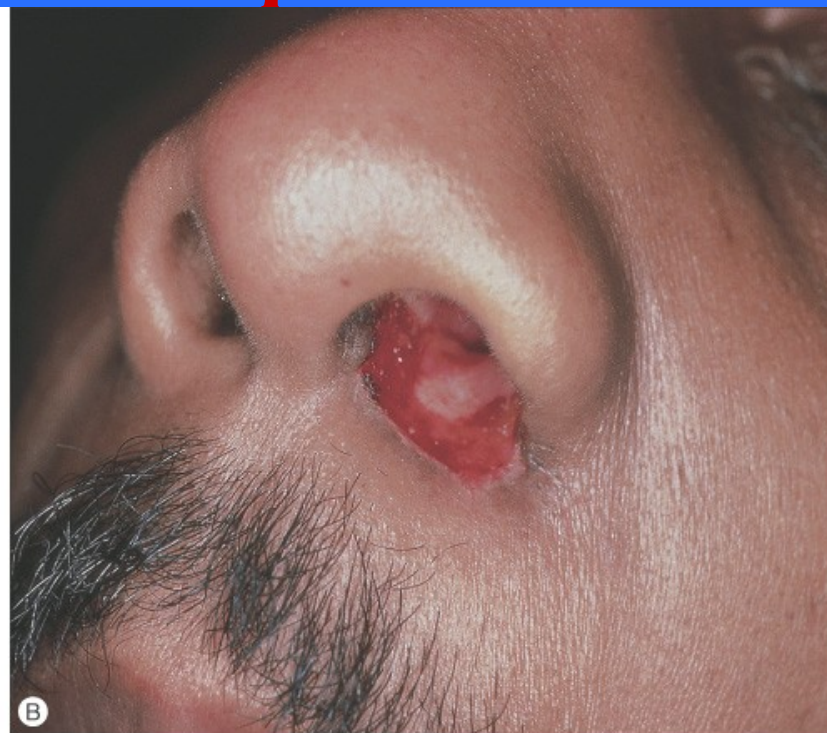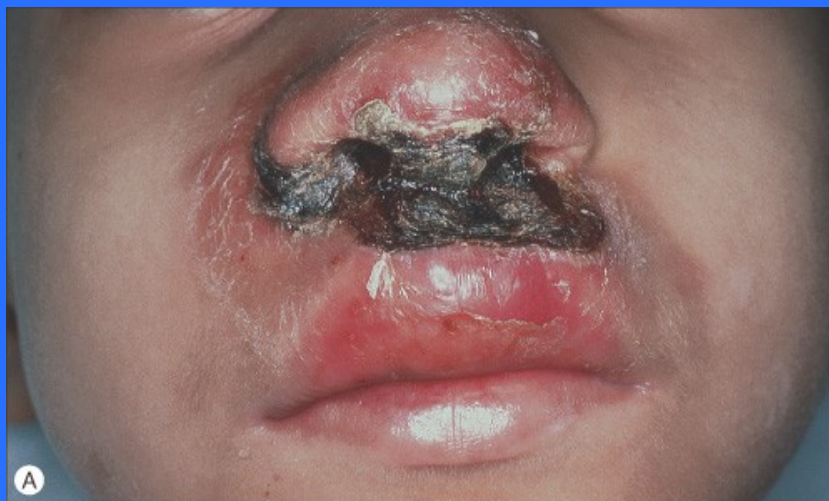
# Oral hairy leukoplakia



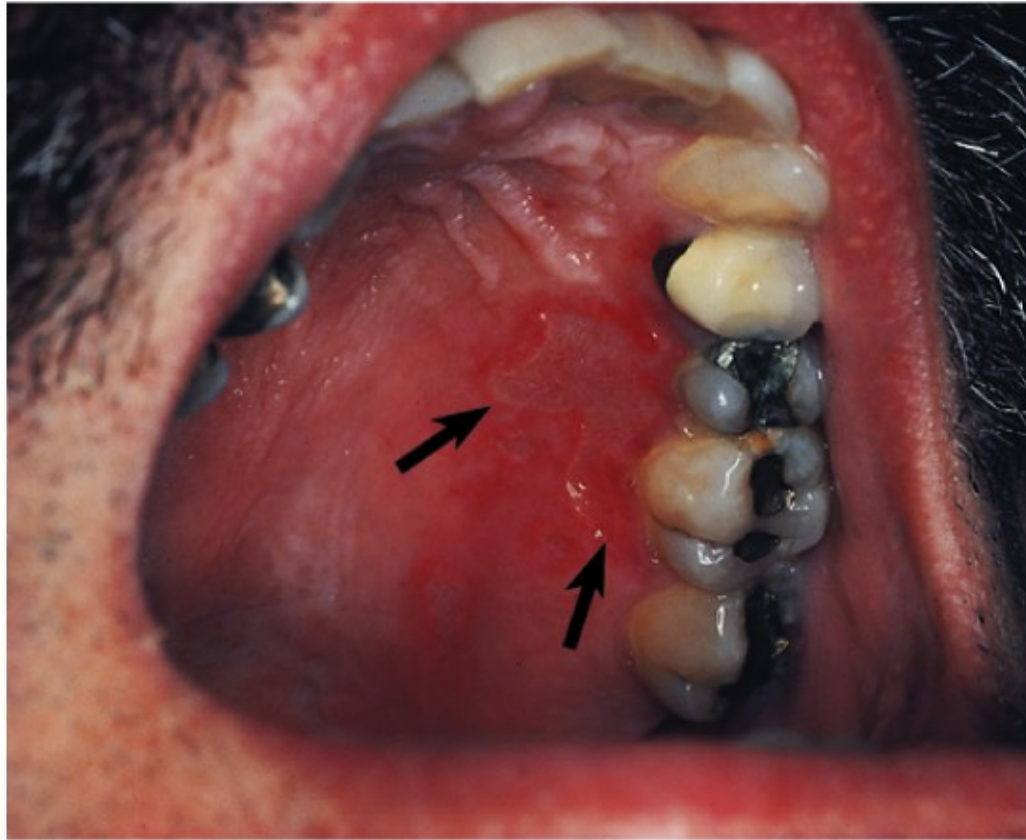
# Oral hairy leukoplakia



# HSV in immunocompromised

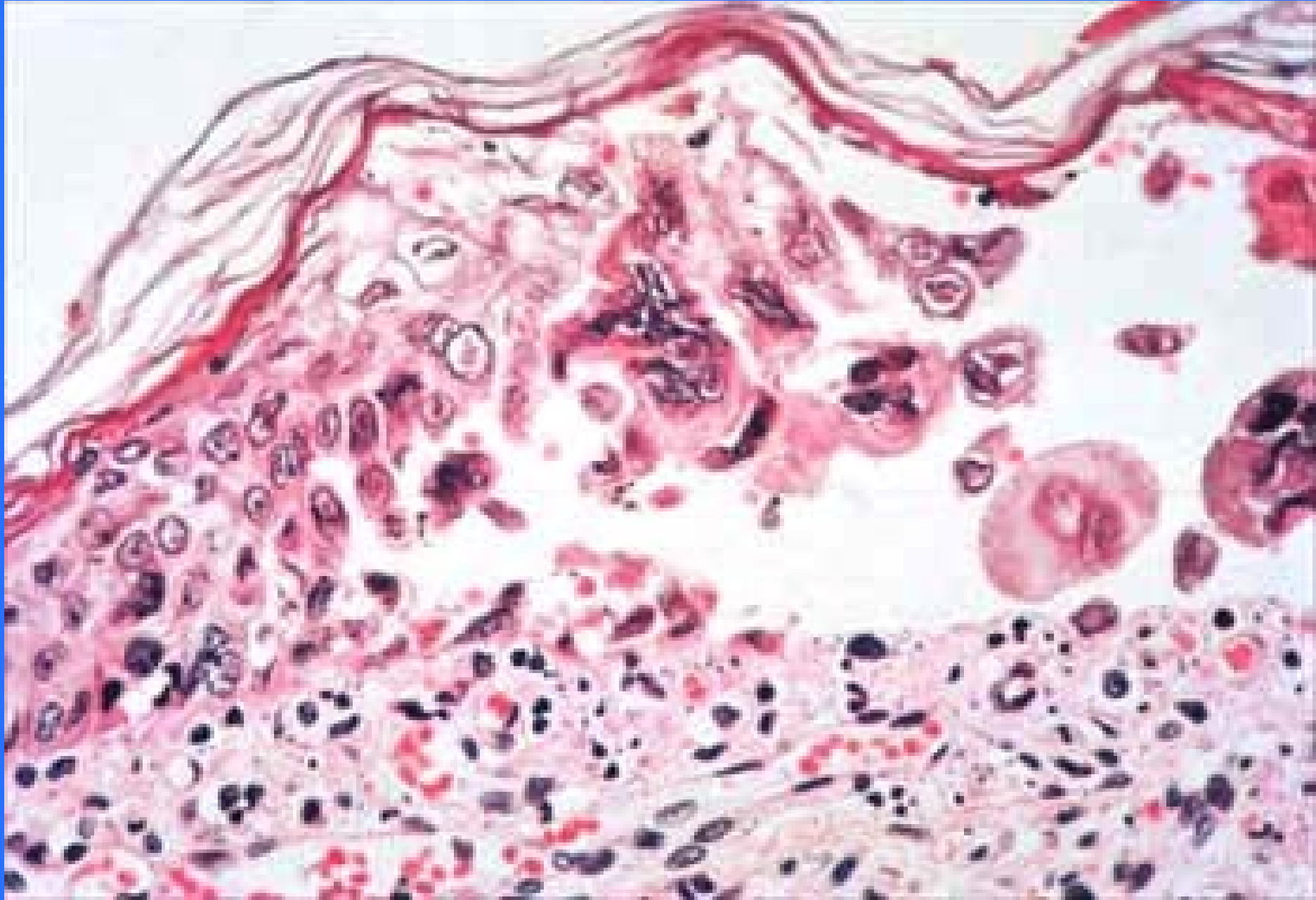


# Hard palate HSV in AIDS

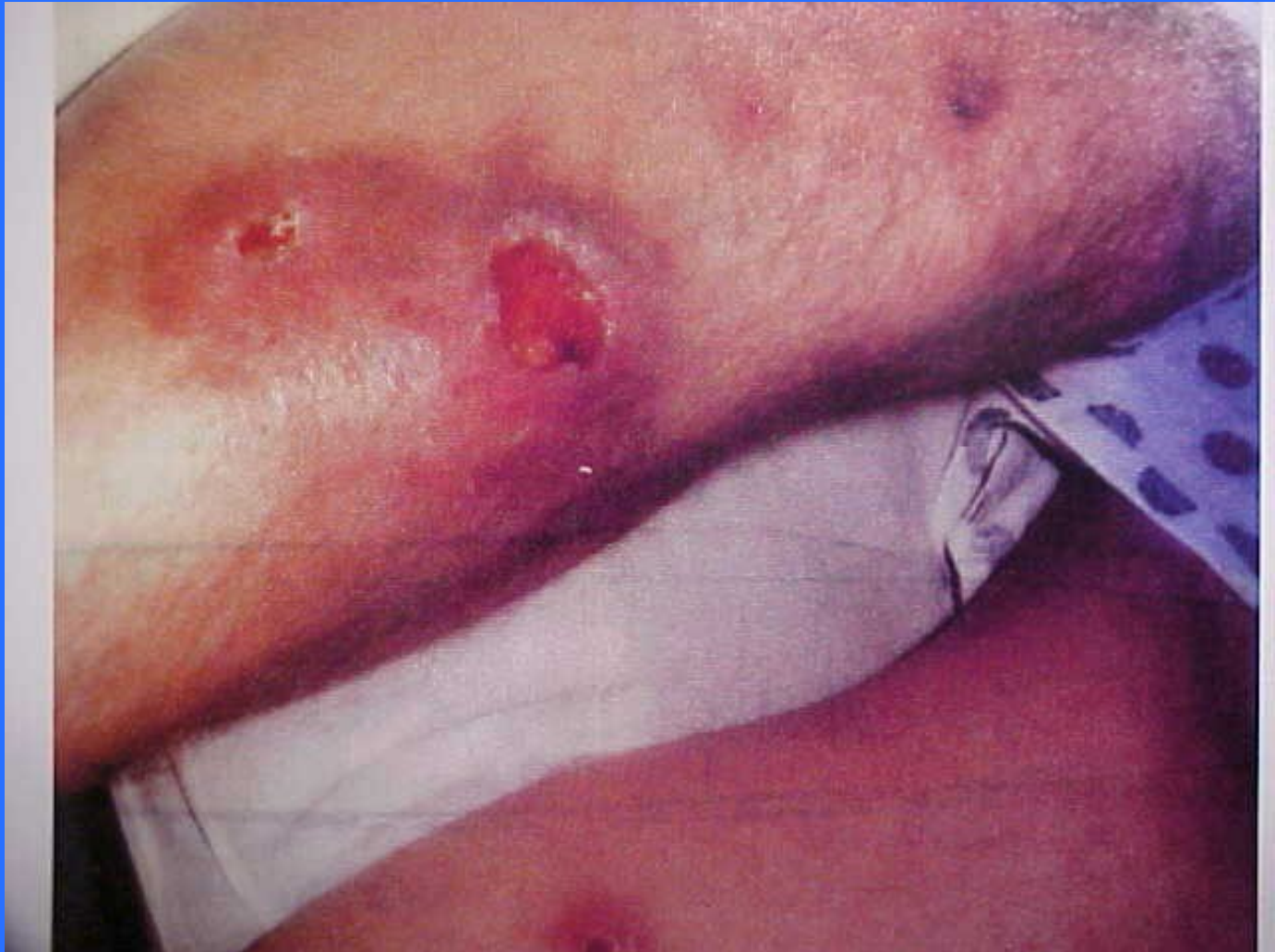

Copyright © 2003, Elsevier Science (USA). All rights reserved.

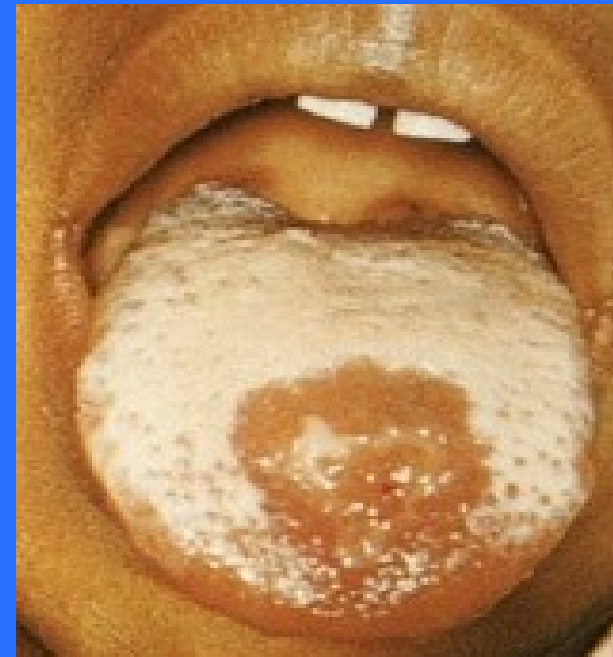
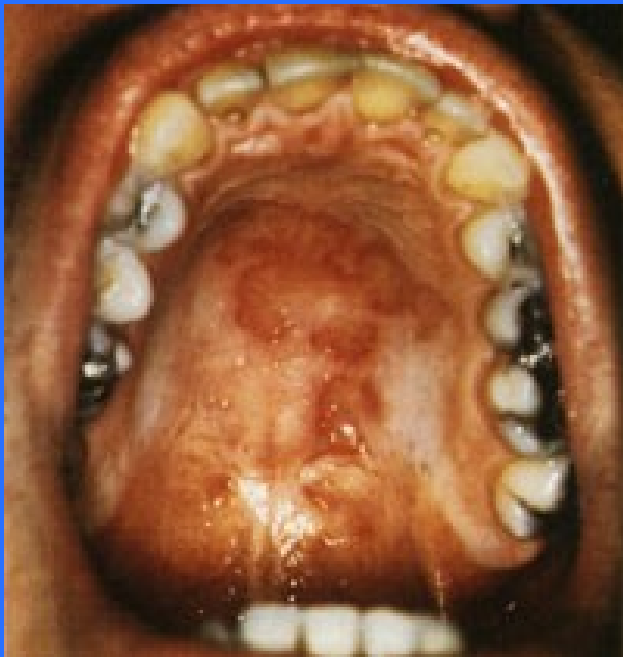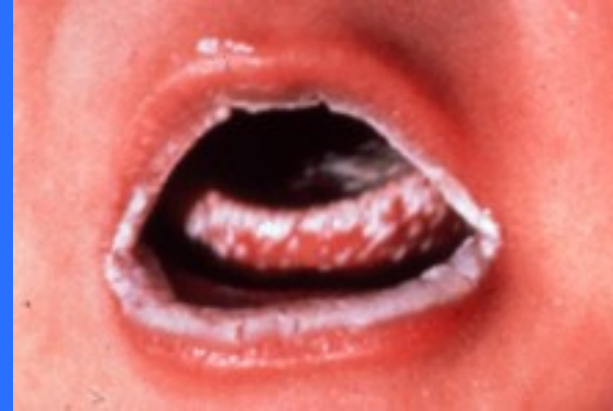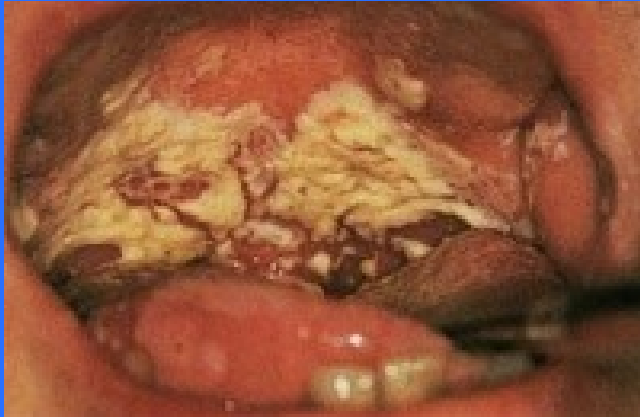# HSV



# CMV Ulcerations



# Oral-pharyngeal candidiasis



# HIV-associated neoplasia

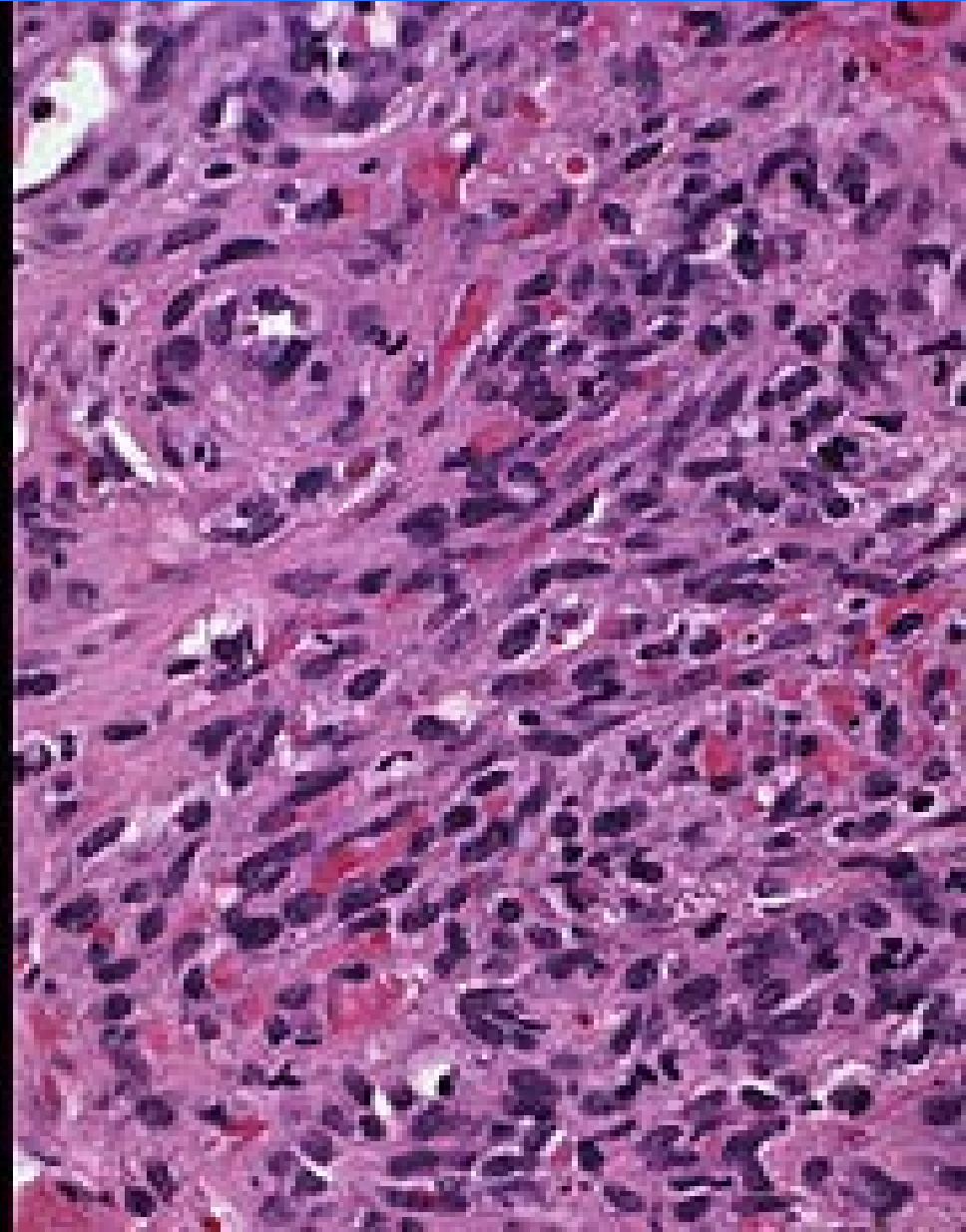
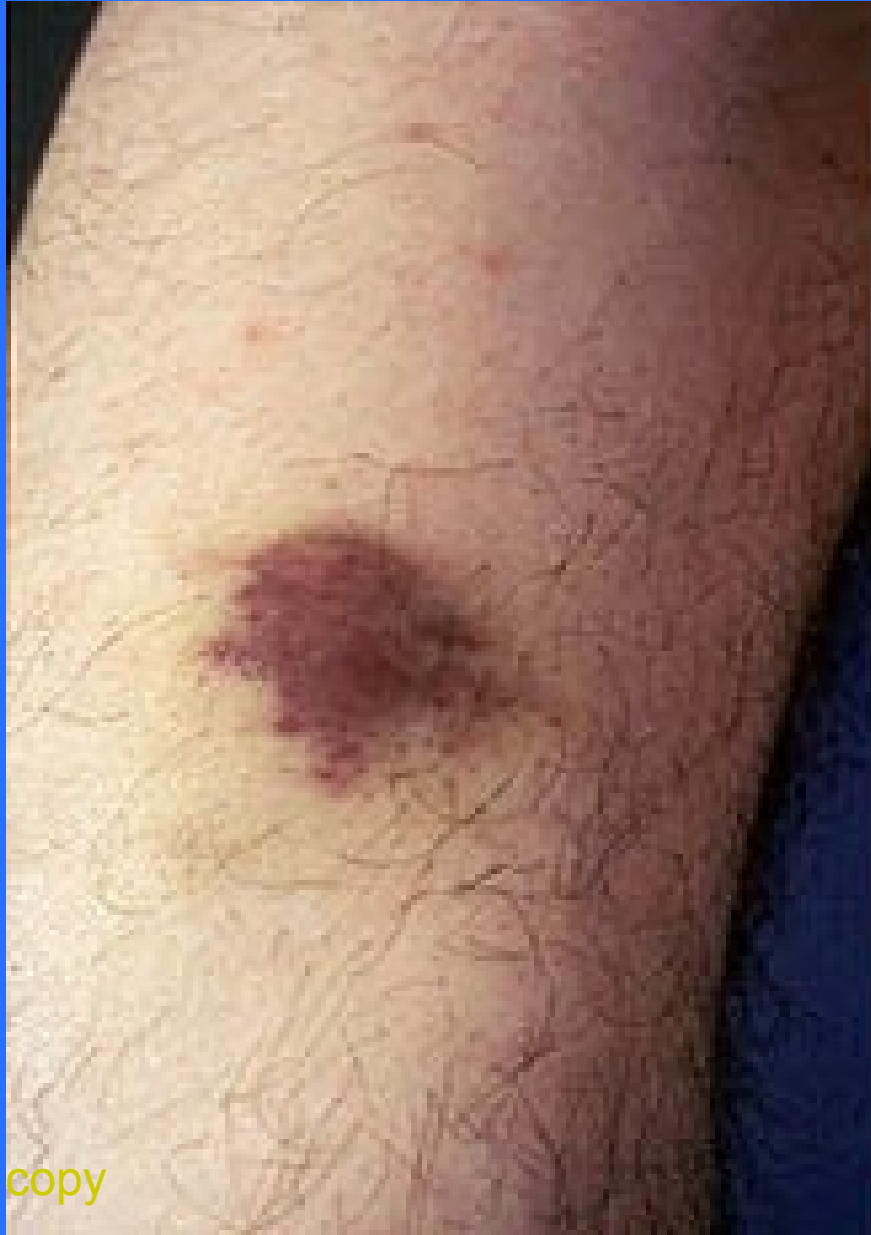- HHV-8: Kaposi sarcoma
- EBV: non-Hodgkin's malignant lymphoma, primary brain ML
- HPV: aggressive anal, cervical squamous cell carcinoma
- with HAART: general increased risk of malignancy



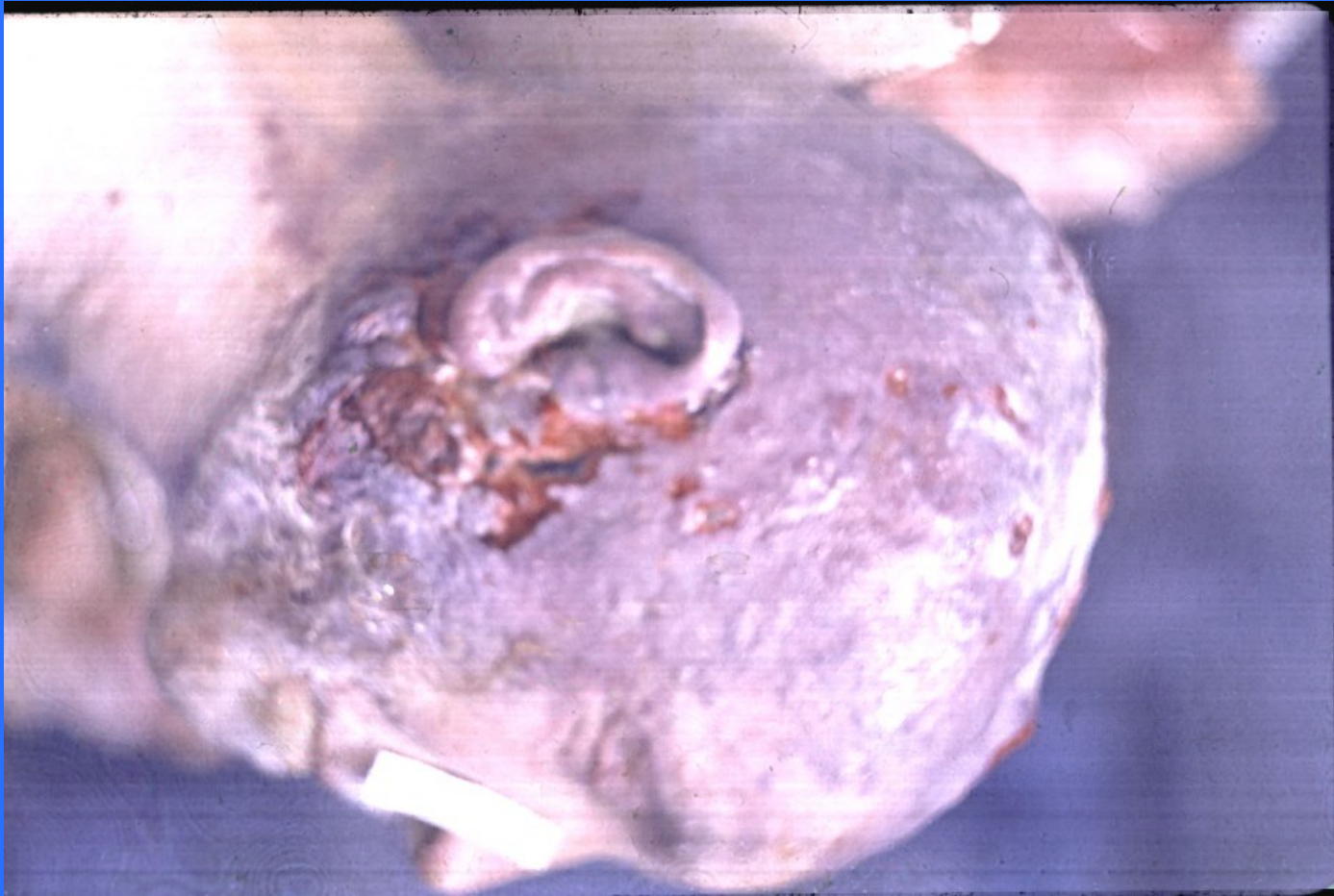# Human herpes virus 8

- HHV-8 is found to be associated with Kaposi sarcoma in virtually all cases.
  - Includes AIDS, post-transplant, African and Mediterranean cases.
  - HHV-8 is found in KS lesions, saliva, blood and semen of infected individuals.
- Associated with body cavity based B-cell lymphoma.
- Lesions on mucosal membranes possible, usually starts on skin.

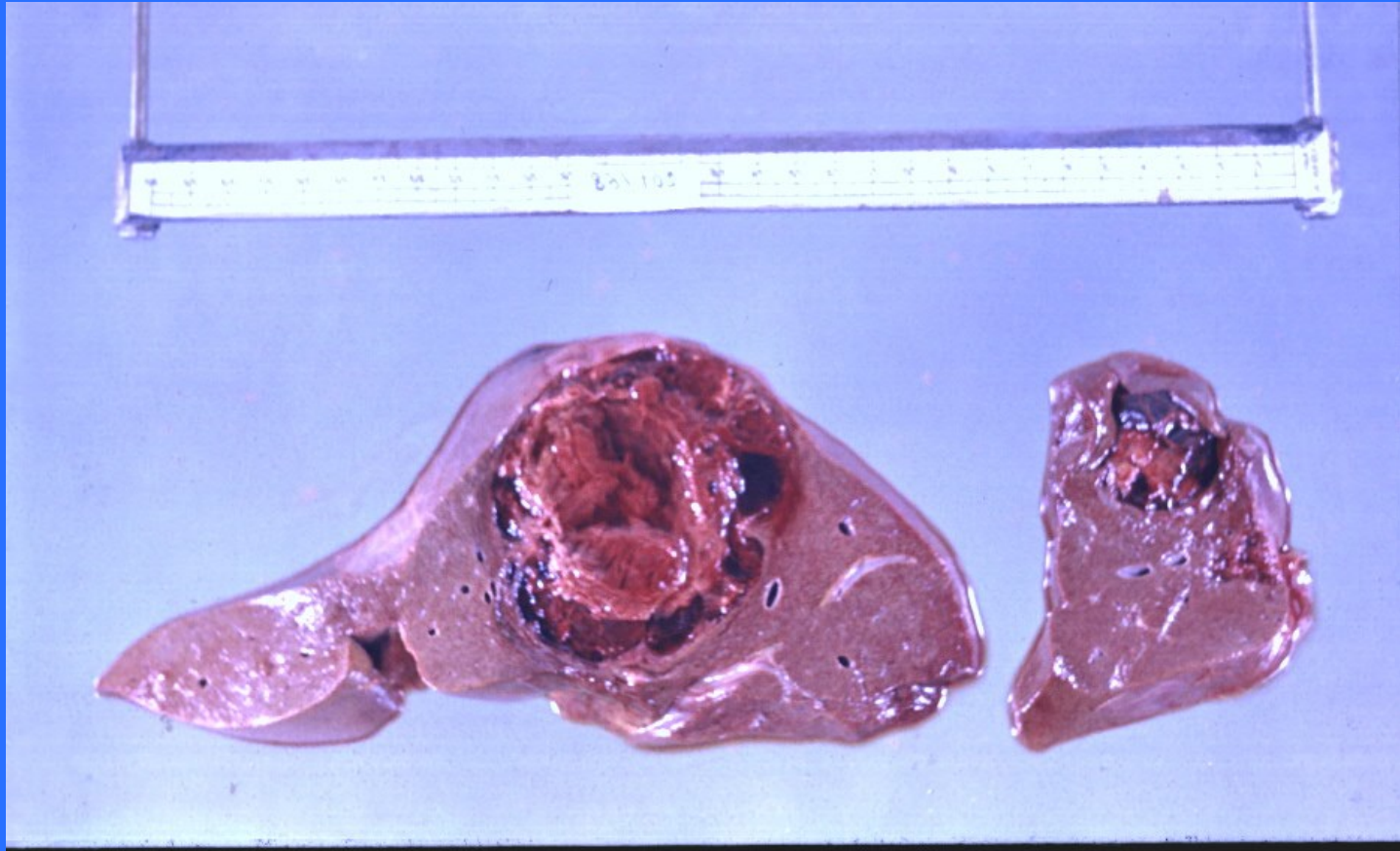
# Kaposi sarcoma



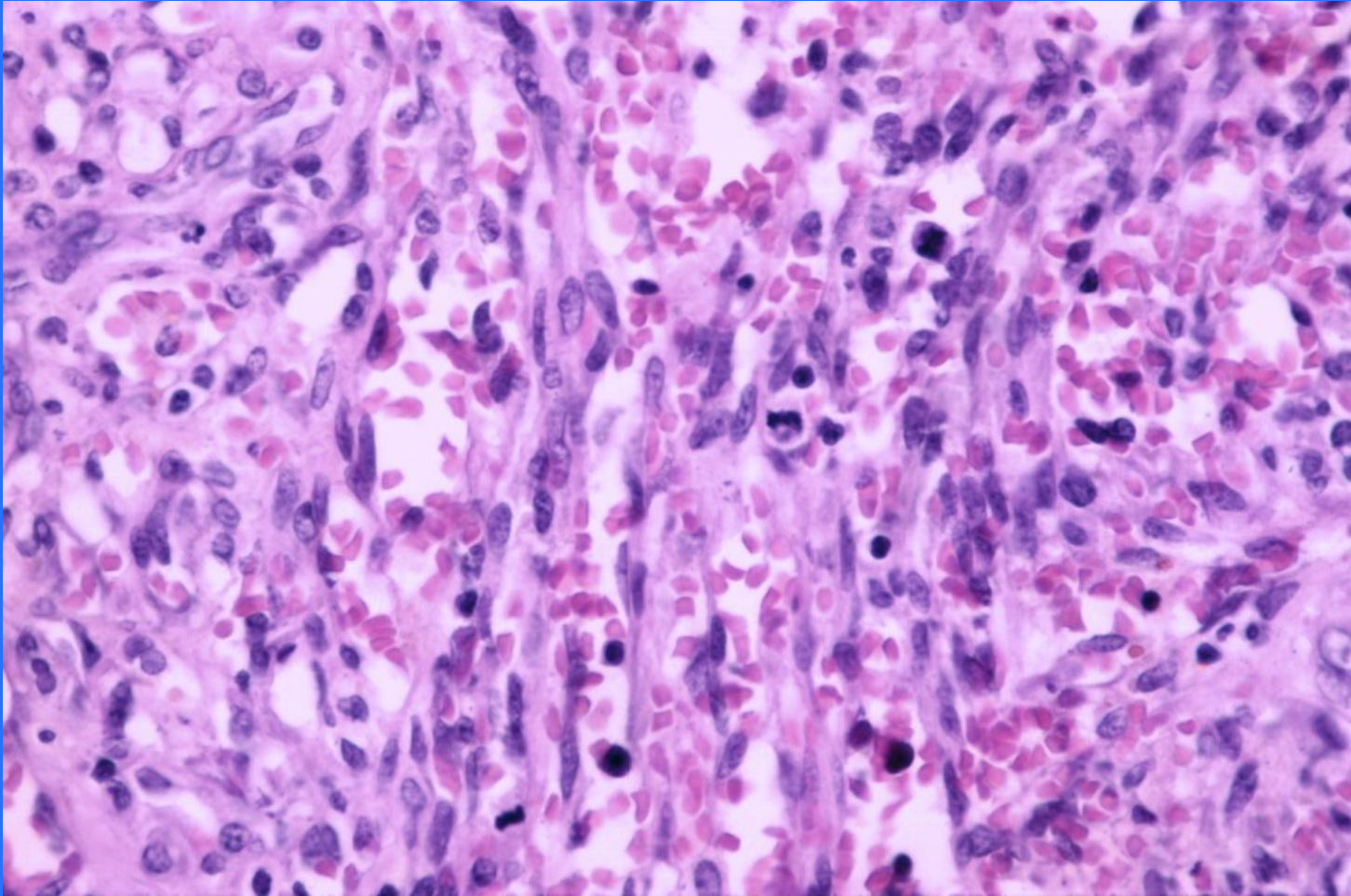
# Kaposi sarcoma



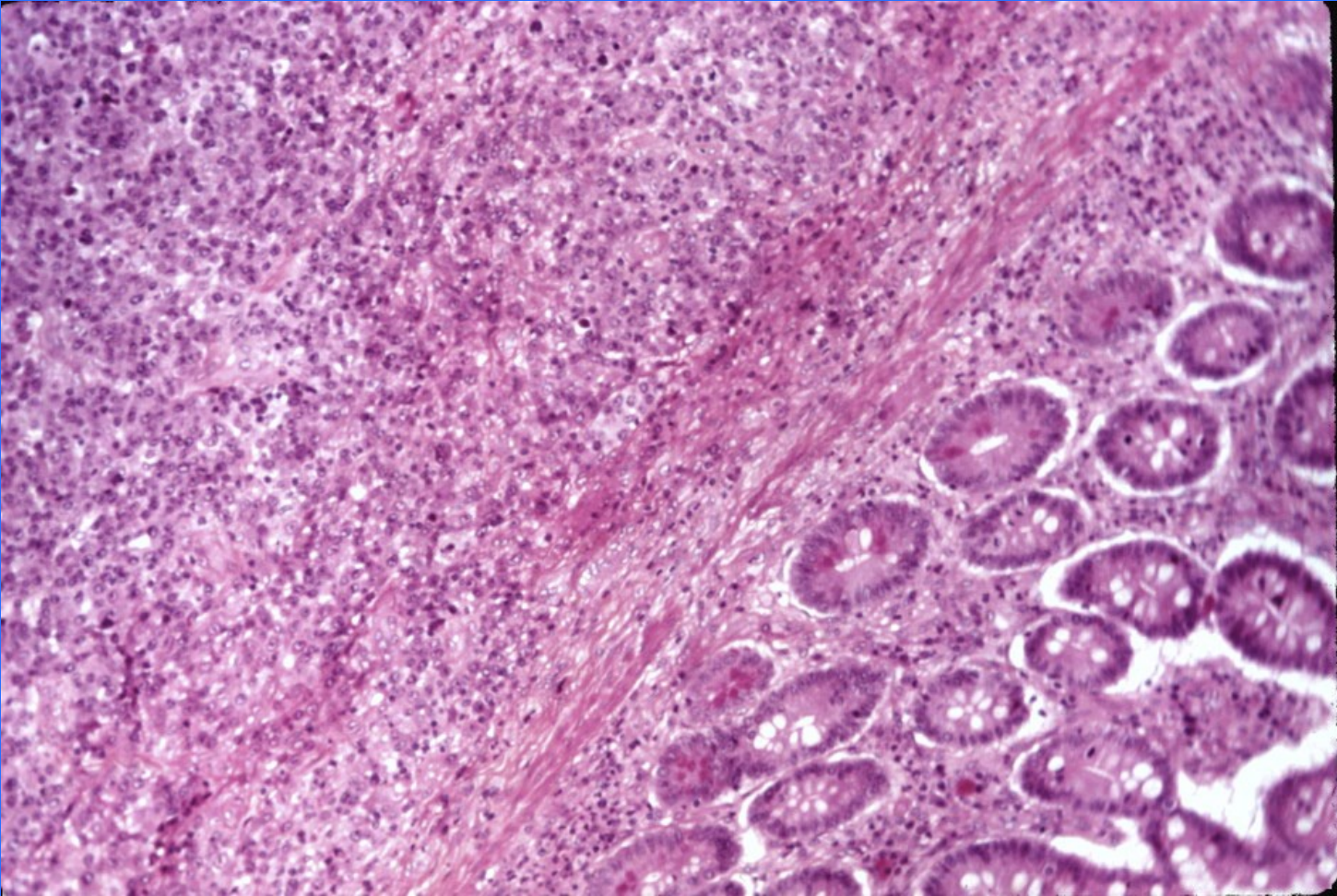
# Kaposi sarcoma



# Kaposi sarcoma



# Kaposi sarcoma + CMV colitis

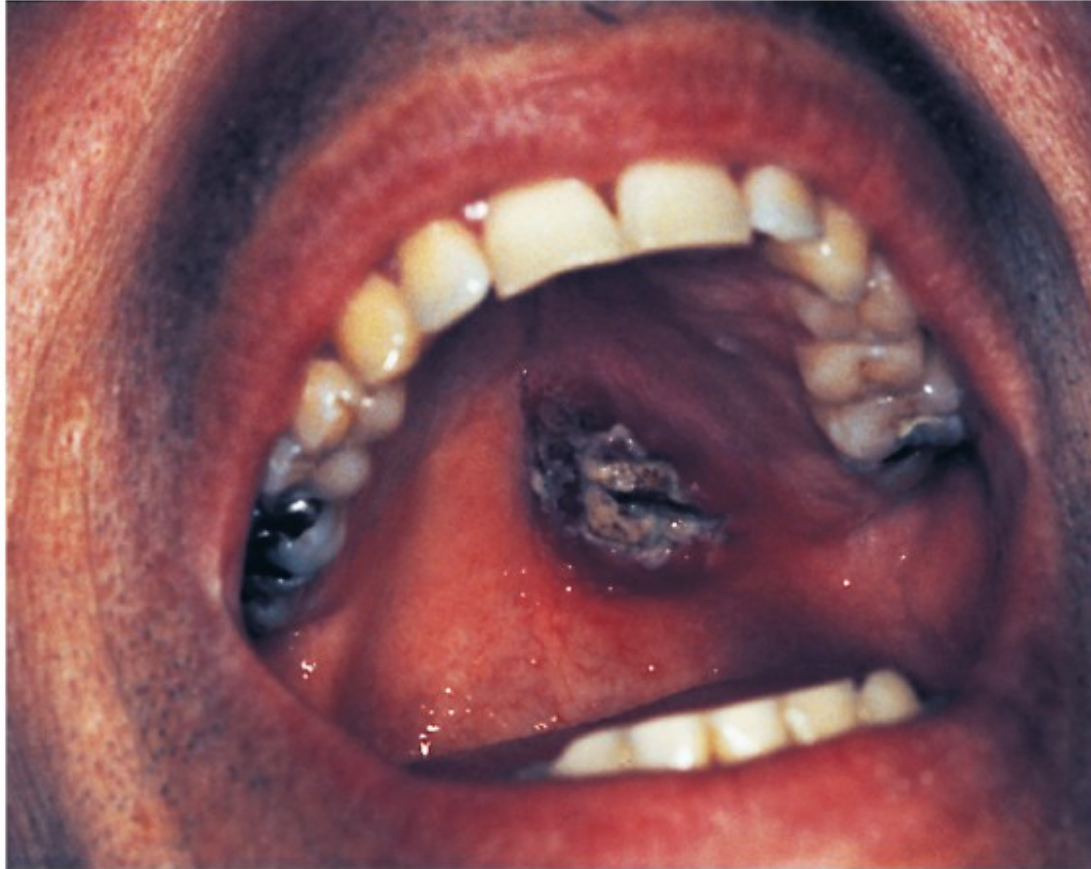

copy

# HIV lymphoma

- Solitary lump or nodule, swelling, nonhealing ulcer
- The swelling may be ulcerated or may be covered with intact, normal-appearing mucosa.
- Usually painful, rapid growth.
- Common association with EBV
- Several histopathologic types, atypical localization

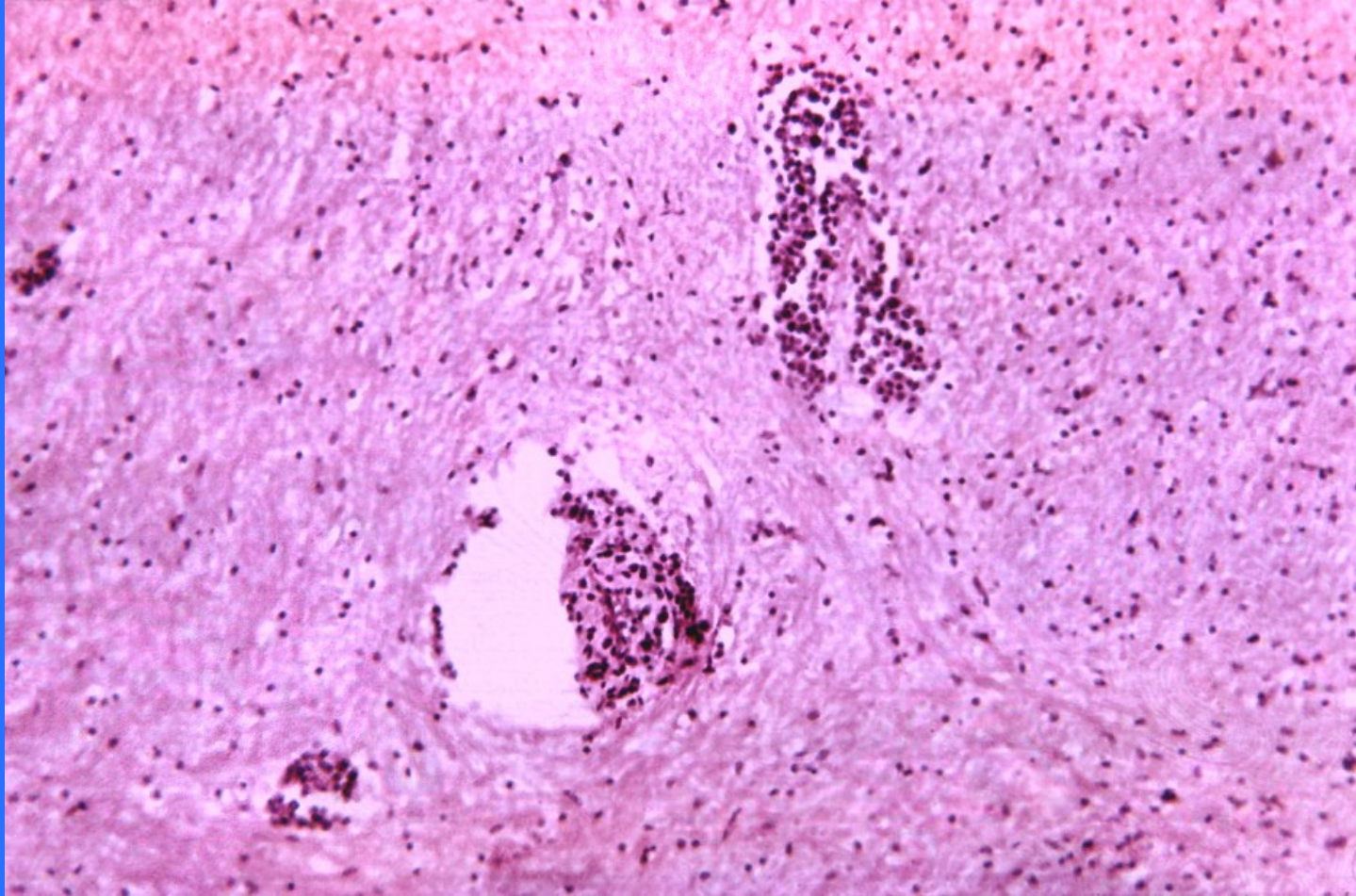
# HIV lymphoma.



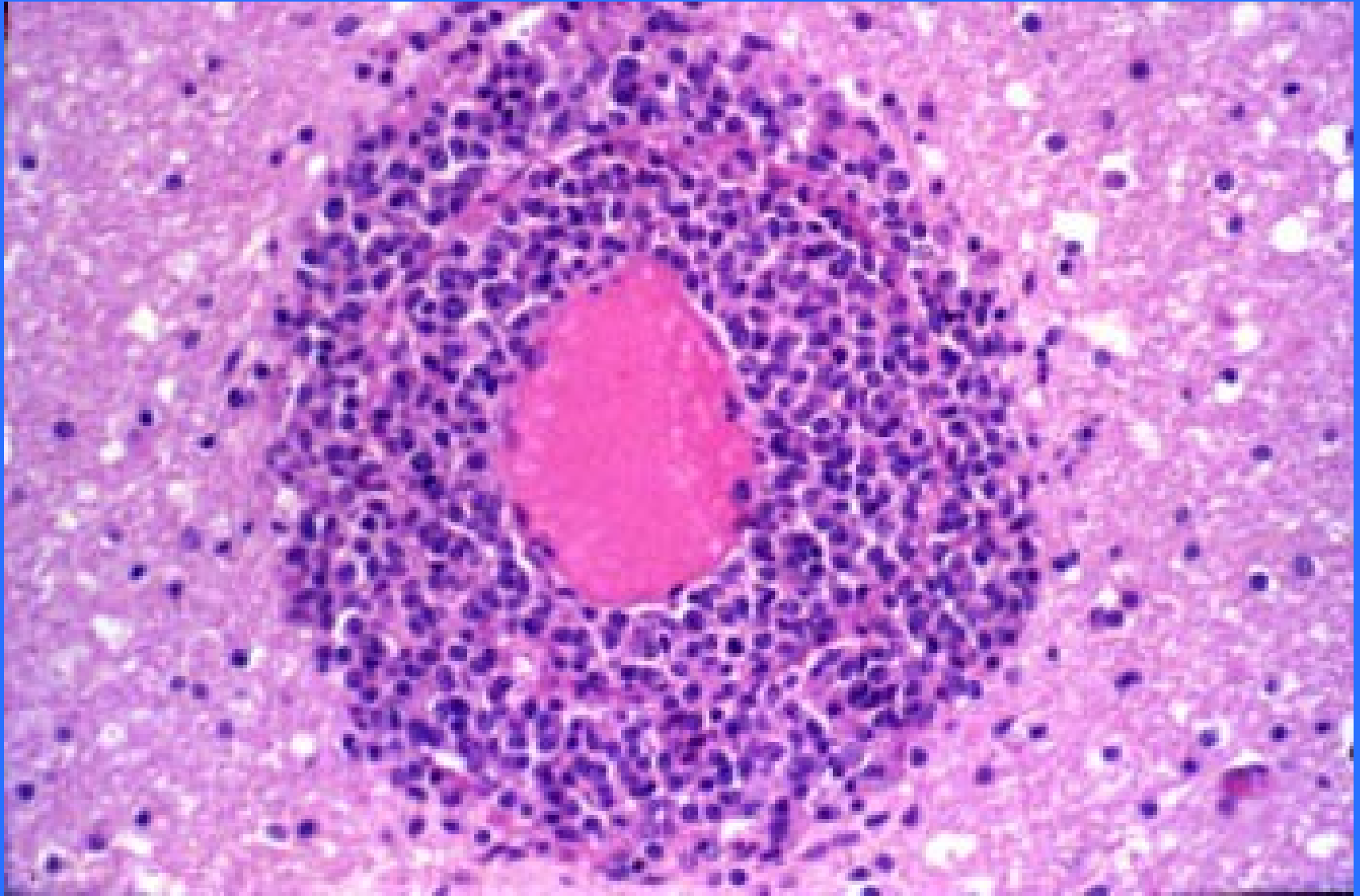
Copyright © 2003, Elsevier Science (USA). All rights reserved.



# Primary brain malignant lymphoma

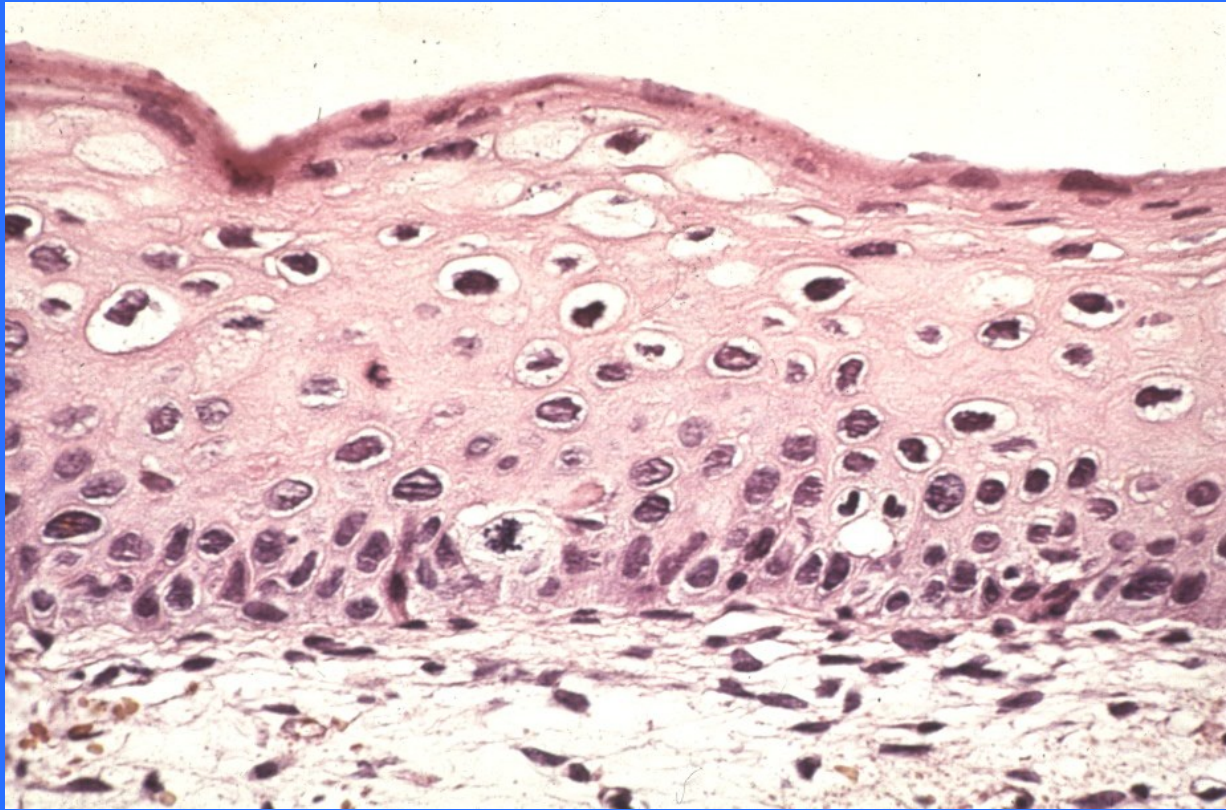


# Primary brain malignant lymphoma

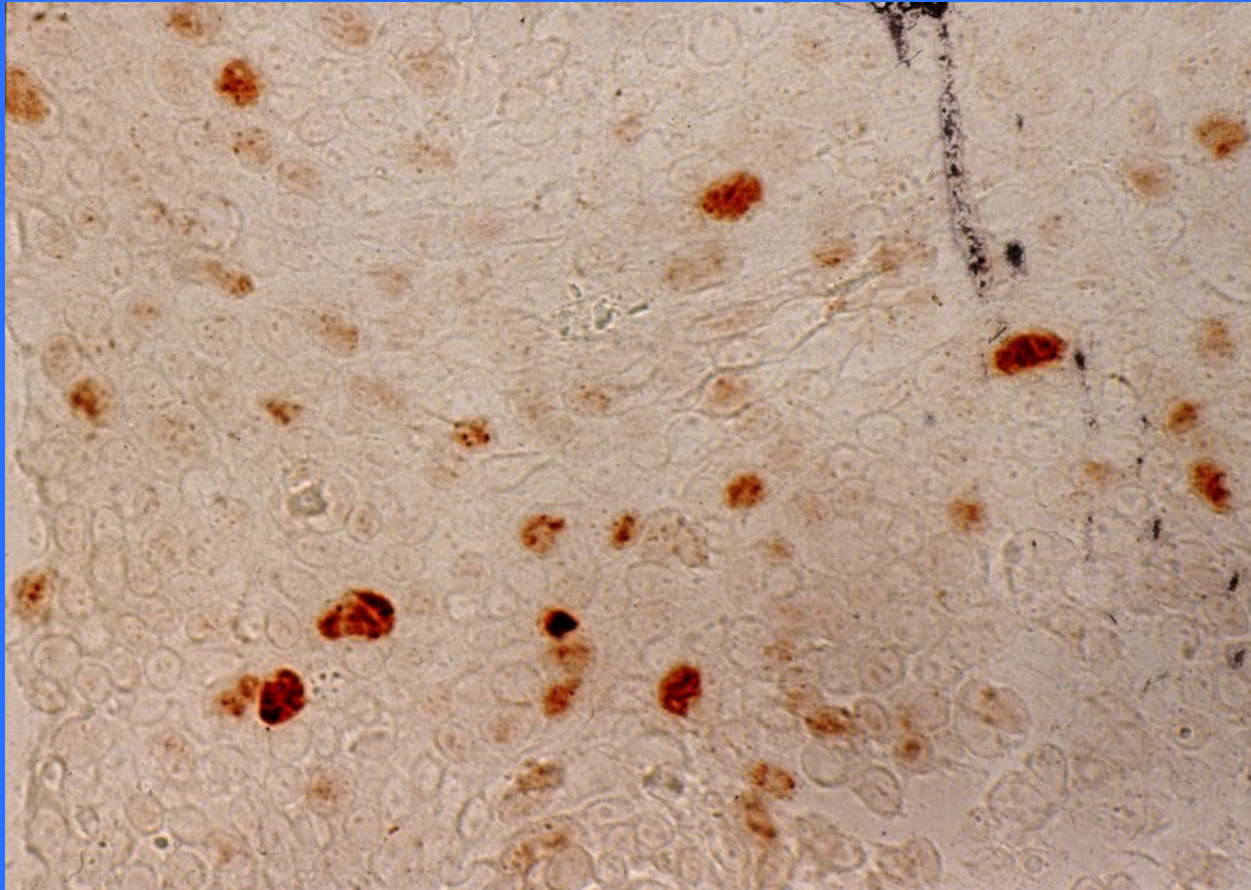


# Human papilloma viruses

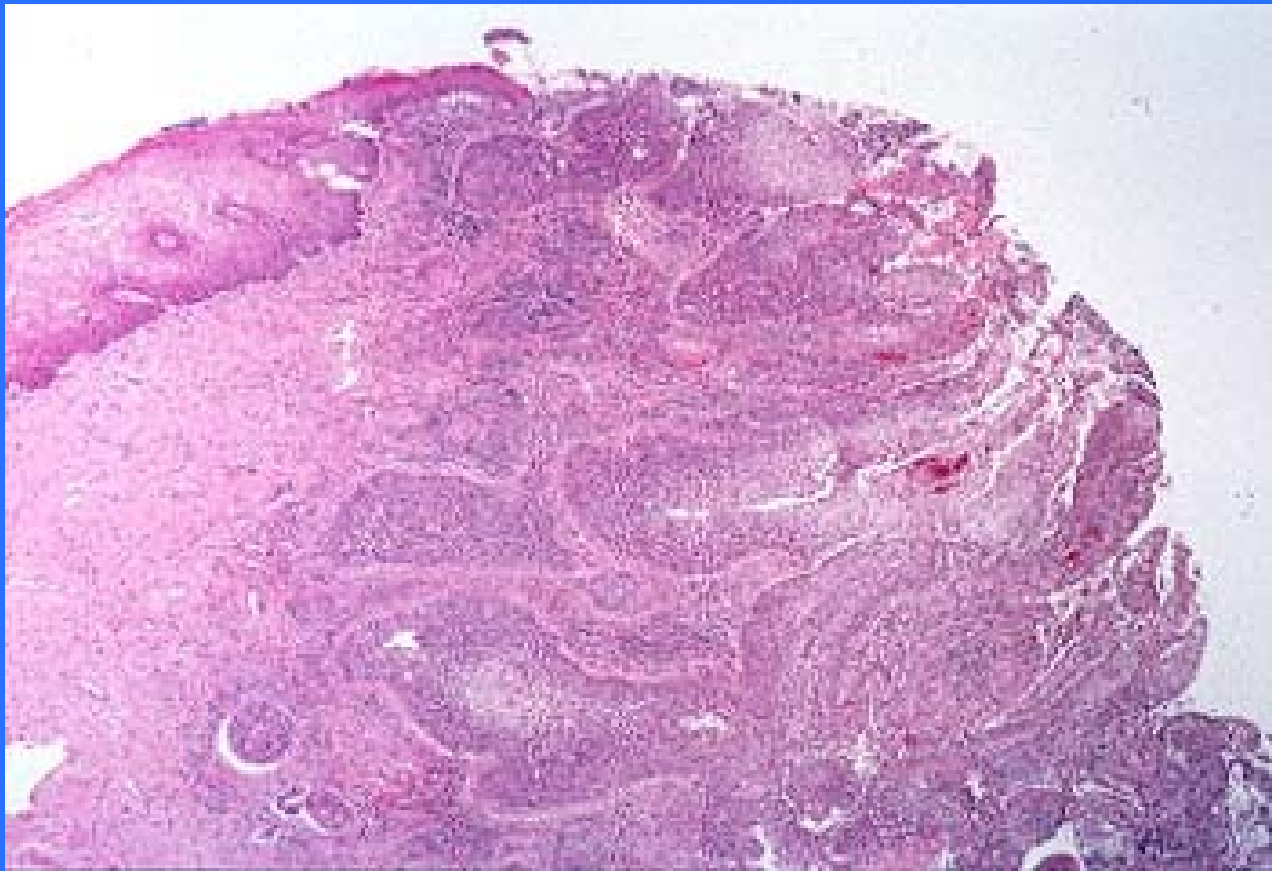
- Human papilloma virus lesions appear most commonly in immunocompromised individuals.
- Diagnosis based on history, clinical appearance, and biopsy.
- Common in early HIV infection.
- Spiky warts, raised, cauliflower-like appearance.



**HPV – koilocytosis - LSIL**

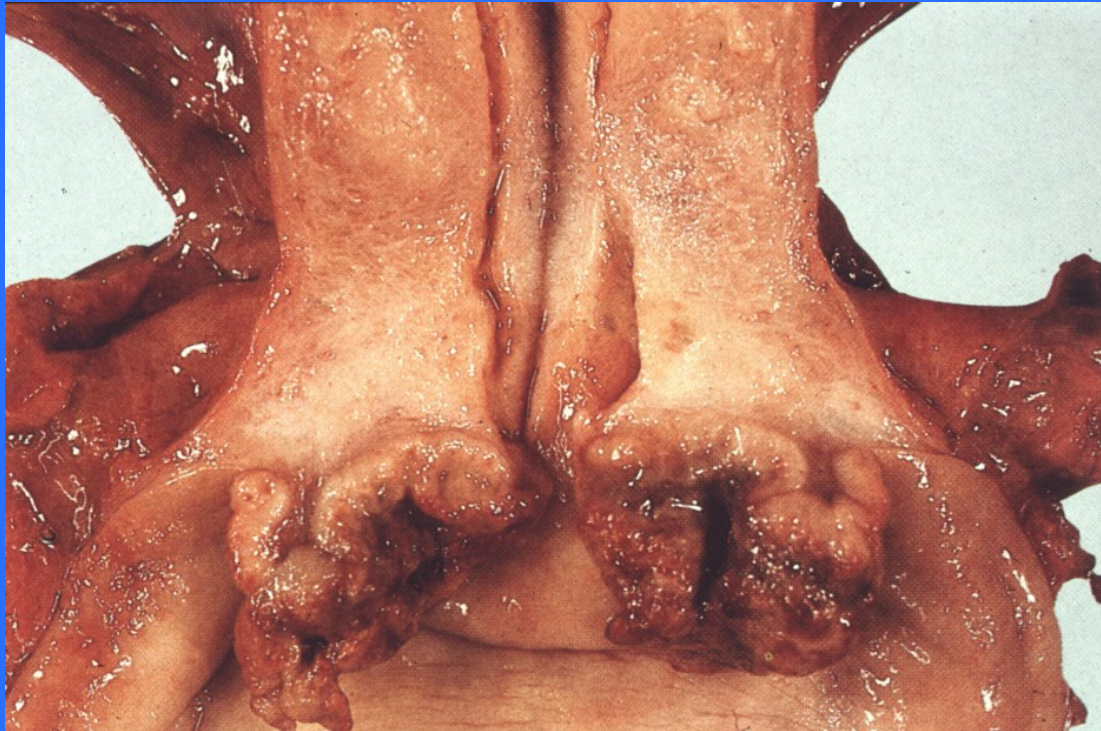

**HPV - immunohistochemistry**



**Invasive squamous cell carcinoma**

# Invasive cervical carcinoma



# Cervical squamous cell carcinoma

