

ORTHO DONTIC S

MUDR. ALENA BRYŠOVÁ, PH.D.



ORTHODONTICS

Stomatological specialisation dealing with prevention, diagnostics and therapy of irregular tooth position, relationship of tooth arches and jawbones



MALOCCLUSION is a manifestation of genetic and environmental interaction on the development of the orofacial region



GOALS OF TREATMENT:

- Ideal functional occlusion
- Ideal soft tissue proportions and adaptation
- Ideal jaw, skeletal and dental relationship



Ideal occlusion

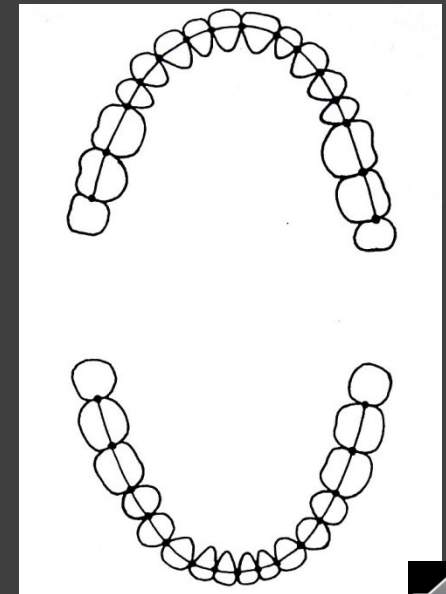
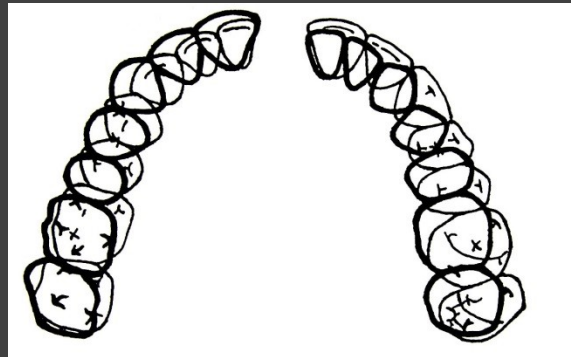
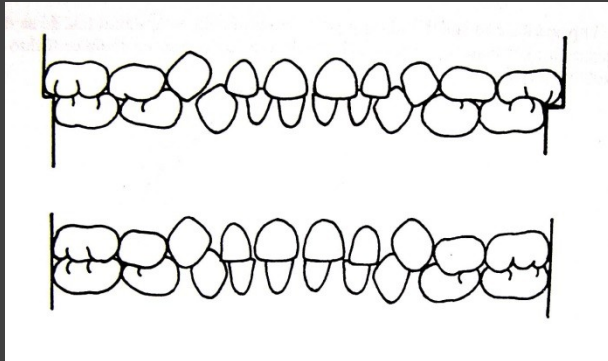
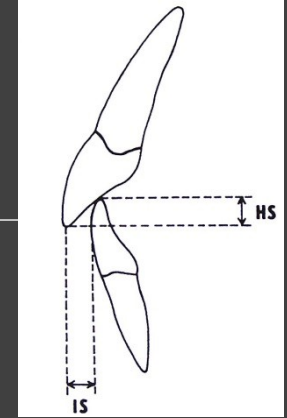
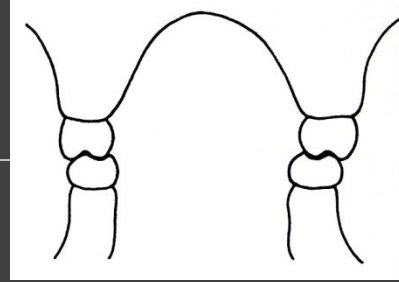
correct relationship of molars

correct overjet and overbite

Correct intercuspitation of teeth

Points of contact are lined in an regular arch

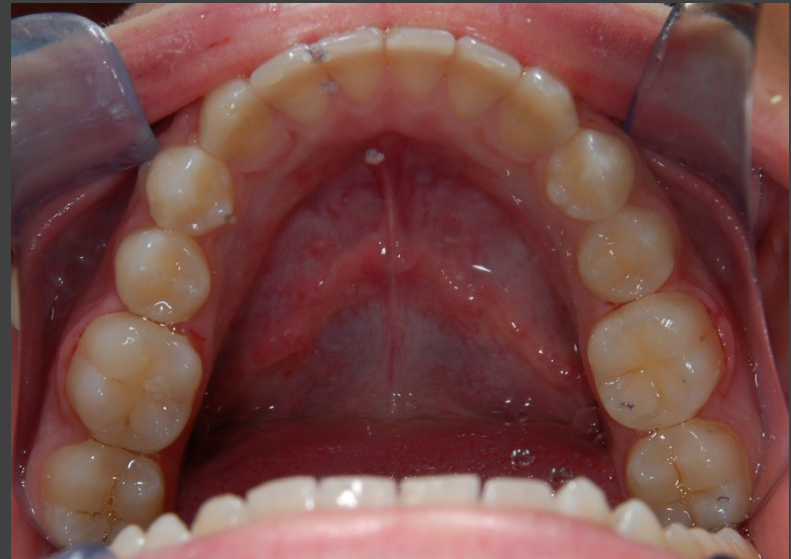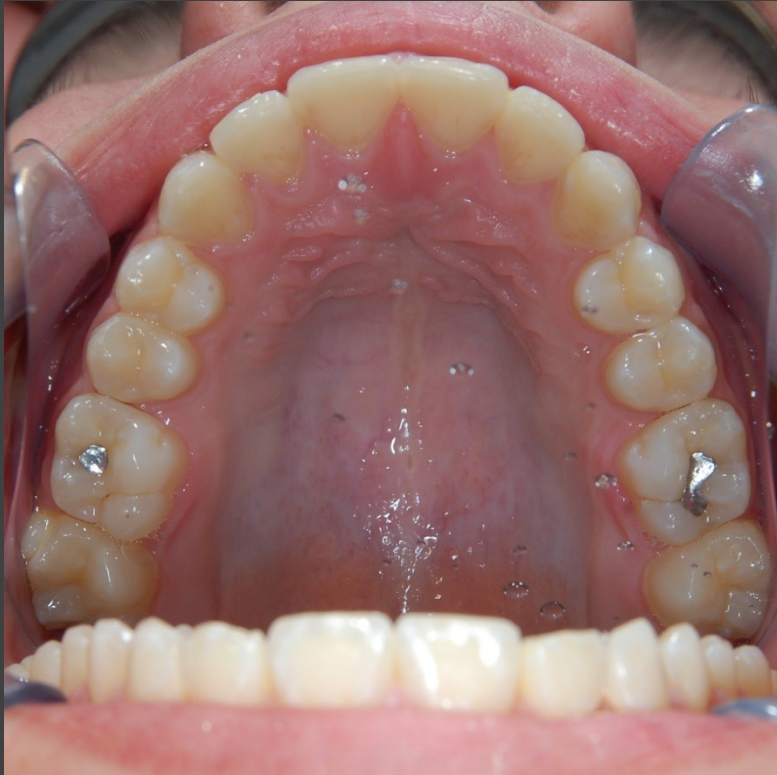Deciduous dentition is ended either by a small step or the posterior teeth facets are aligned

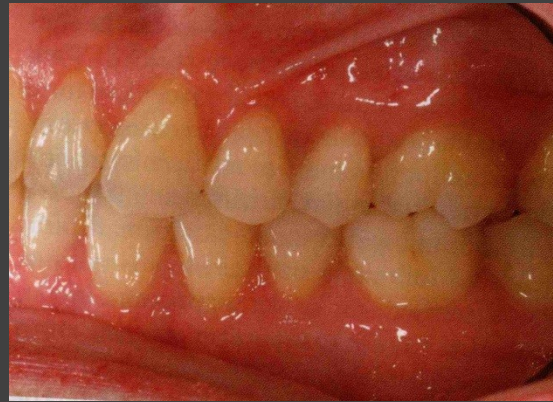
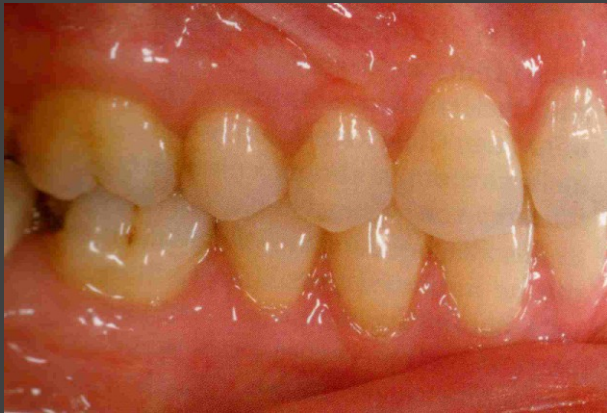
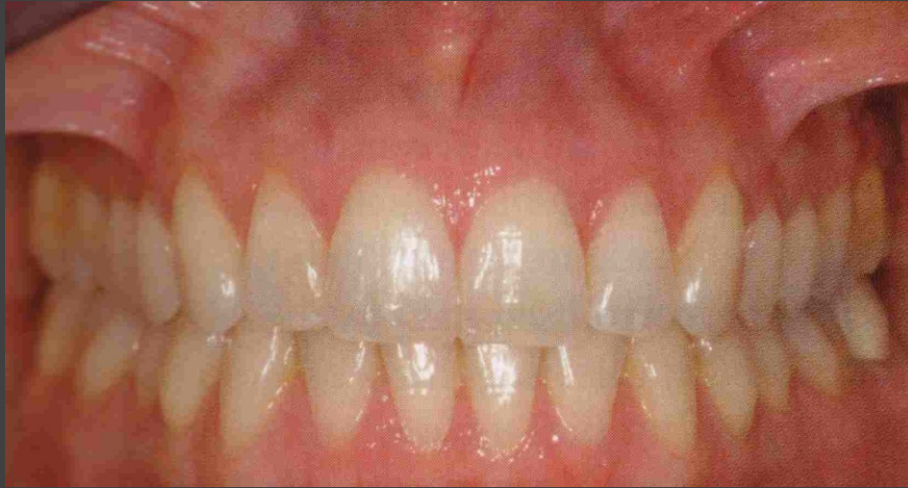Correct dentition has 6 keys of correct occlusion- Andrews



Ideal occlusion





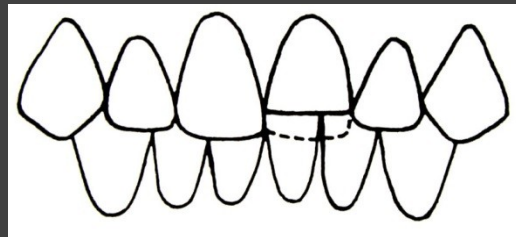
Classification of orthodontic anomalies

1. Anomalies of single tooth

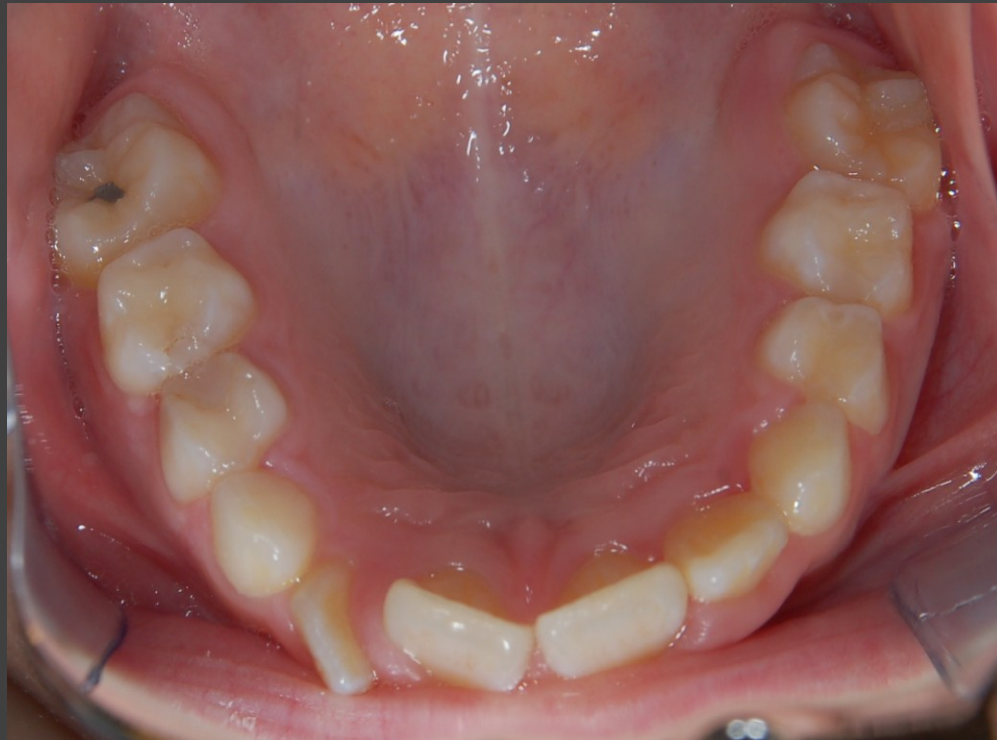Inclination – tooth tipping mesially, distally,

vestibular = protrusion, oral = retrusion, vestibular, lingual, palatal eruption

Vertical anomalies - supraocclusion, infraocclusion



rotation



Classification of orthodontic anomalies

1. Anomalies of single tooth

Nonocclusion – buccal, lingual, palatal

upper teeth are not in contact with lower teeth

Transposition – change of sequence of teeth in one arch, eg. the canine and first premolar or canine and lateral incisor



Classification of orthodontic anomalies

1. Anomalies of single tooth

Rotation - mesial, distal

Retention – the tooth is developed, but not erupted, most often:
wisdom teeth, upper canine

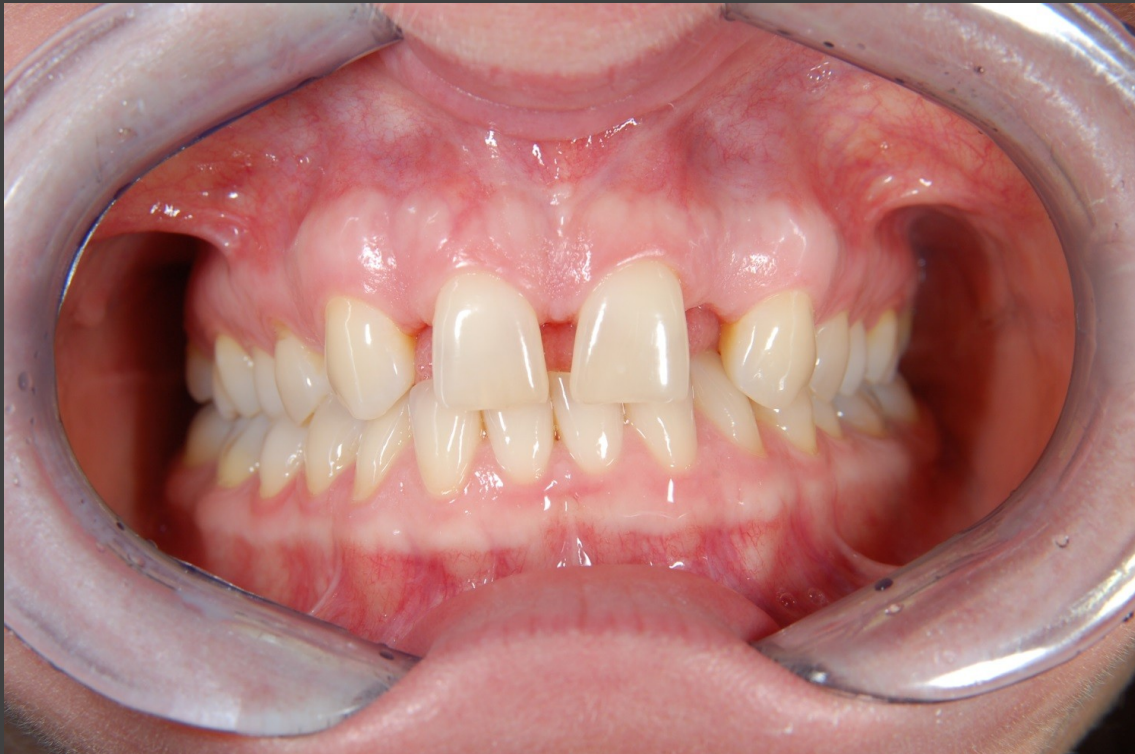Ankylosis, reinclusion

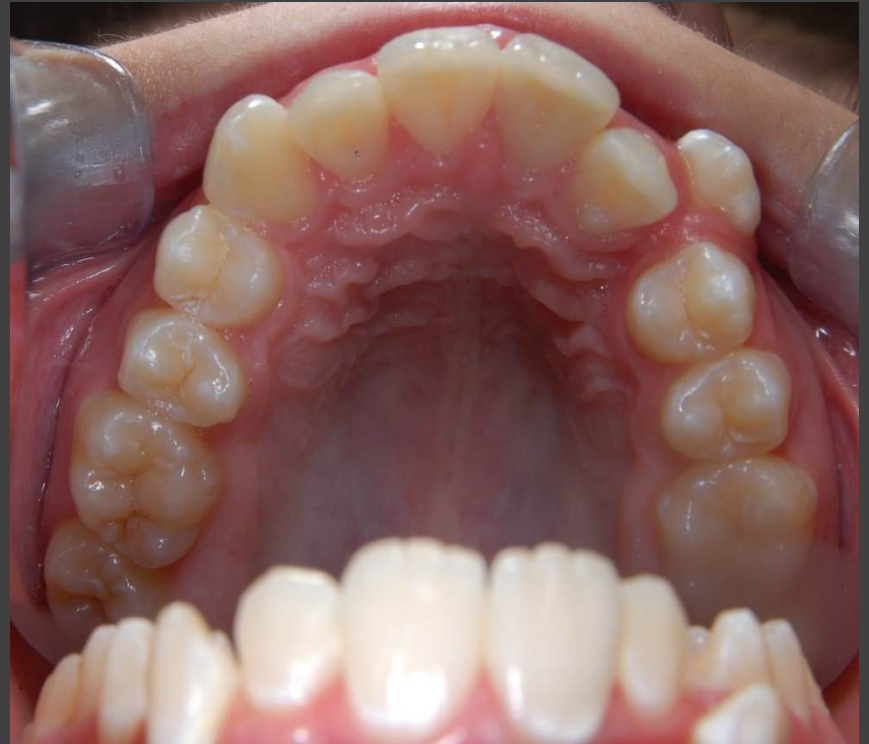
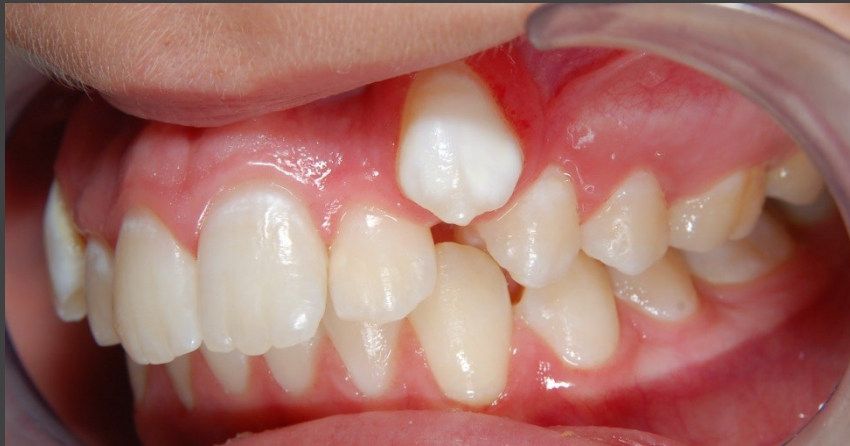Hyperodontia – the number of permanent teeth is higher
[supernumerary teeth, most frequently- mesiodens, upper
incisors]

Hypodontia – the correct number of teeth is reduced because
some teeth are absent due to agenesis of their germs [most
frequently- upper lateral incisors, third permanent molars,
premolars]

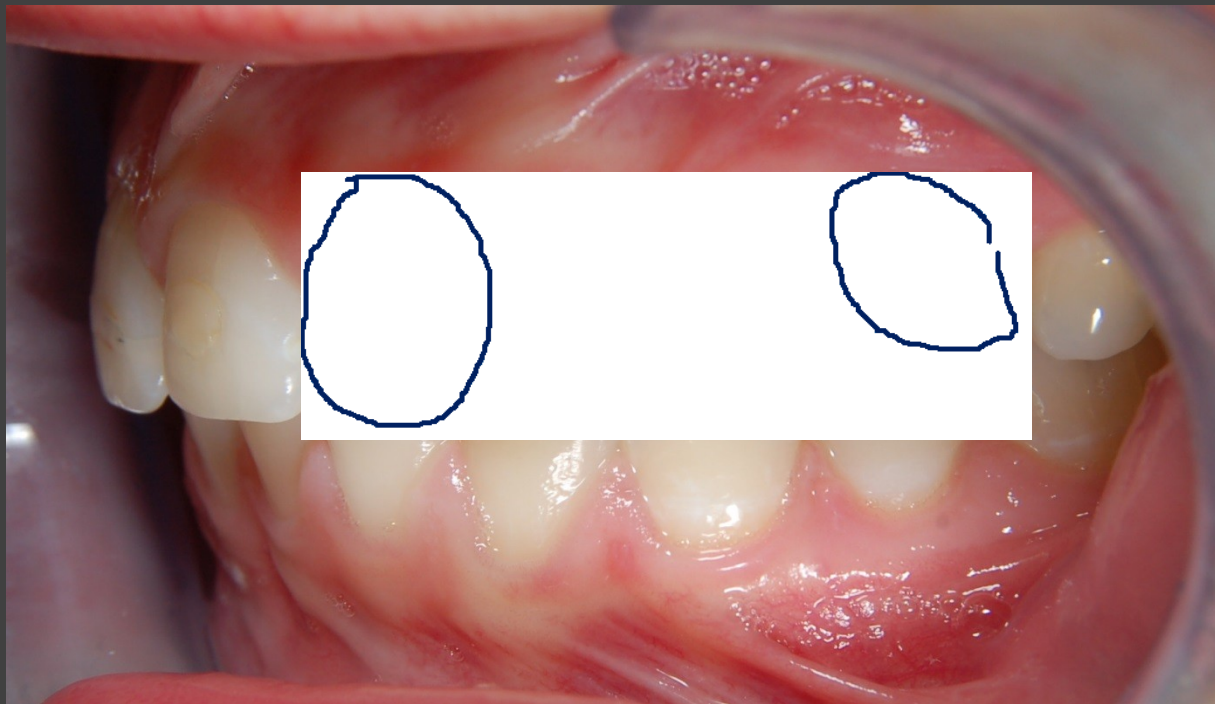


Hypodontia

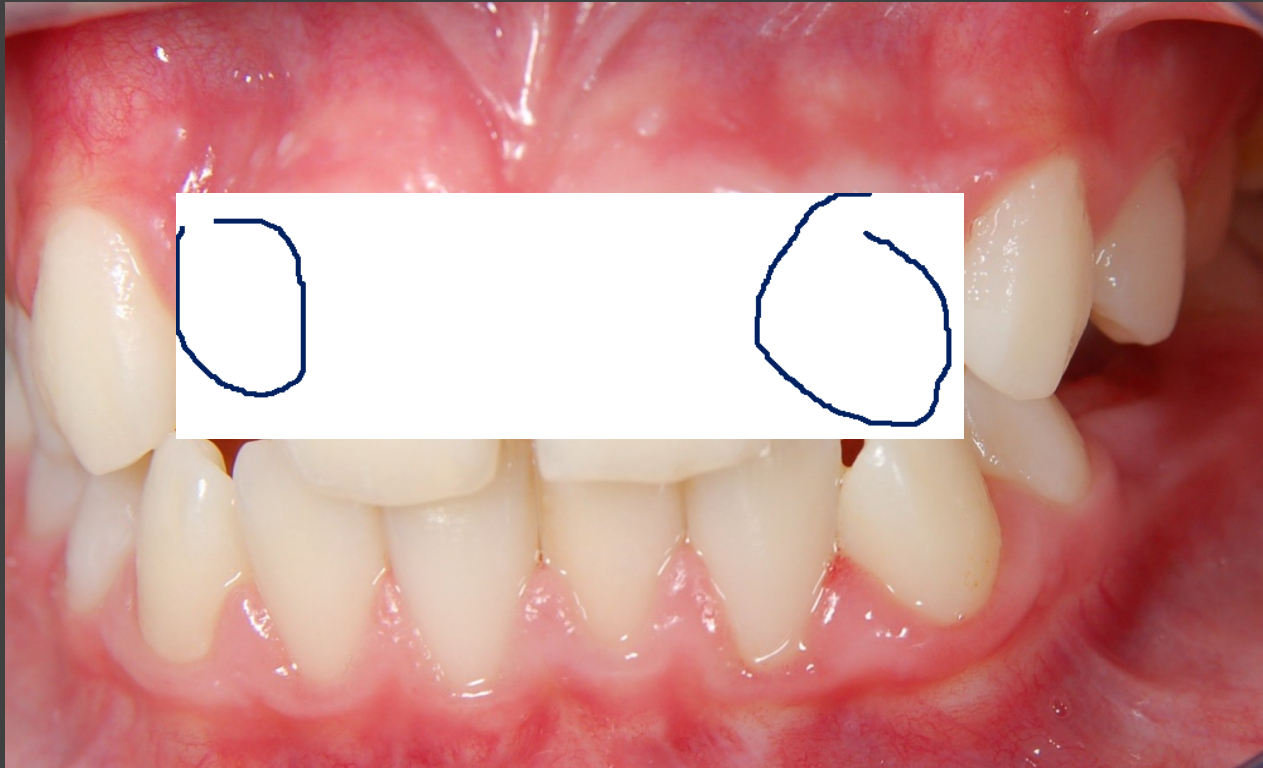




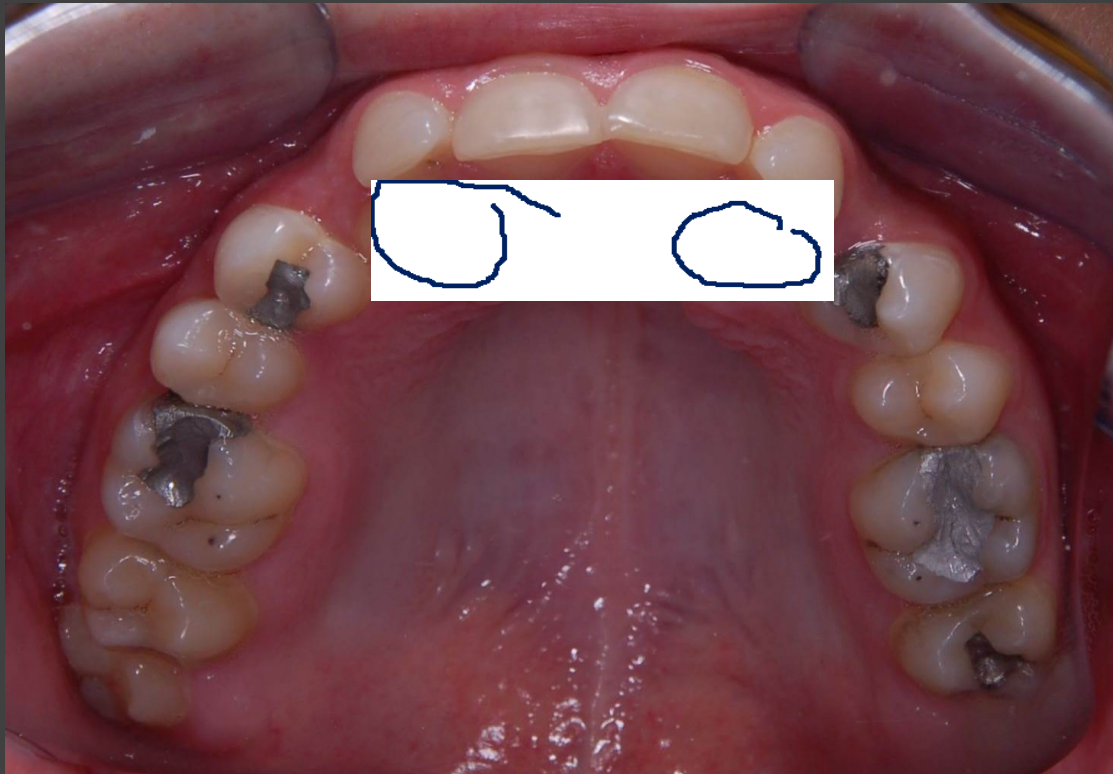
Anomalies of the shape of teeth



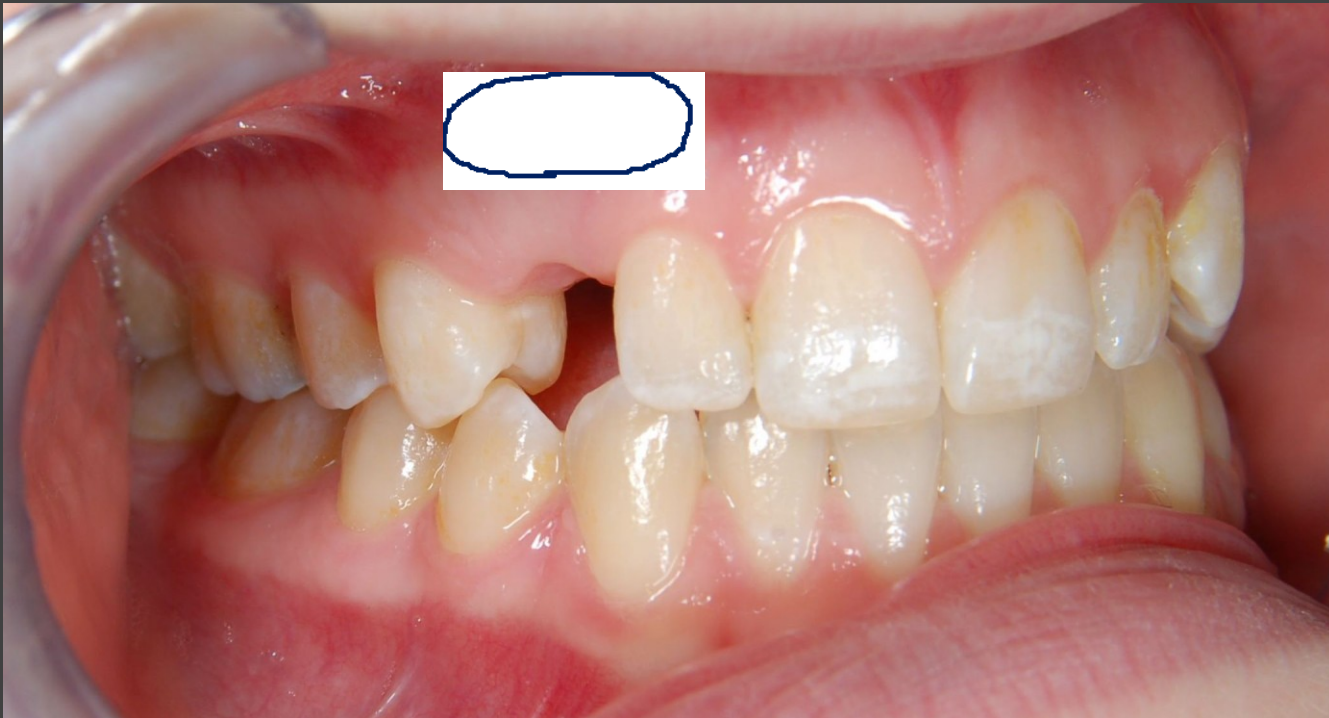Palatal eruption



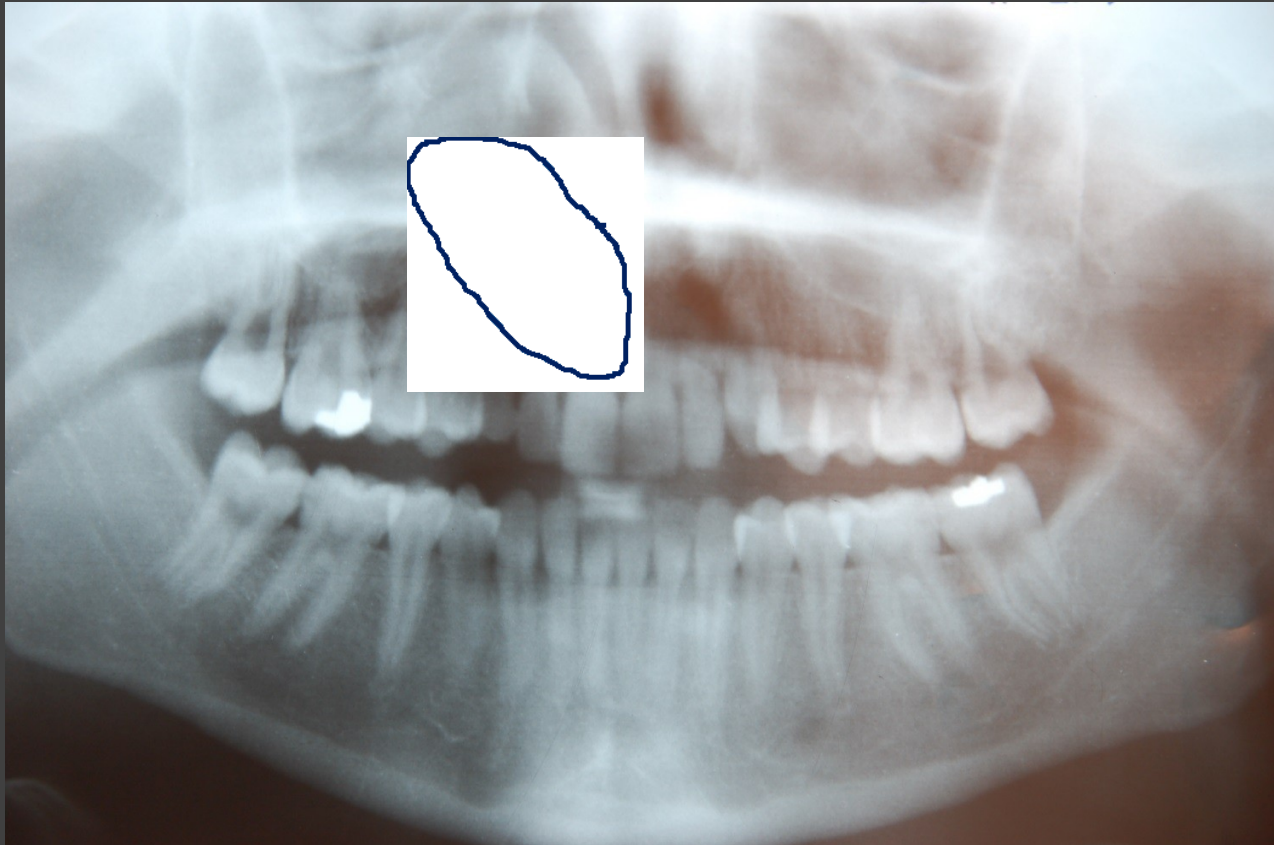
Palatal eruption



Retention of canine



Retention of canine




Classification of orthodontic anomalies

2. Anomalies of groups of teeth

-groups of teeth are in irregular position

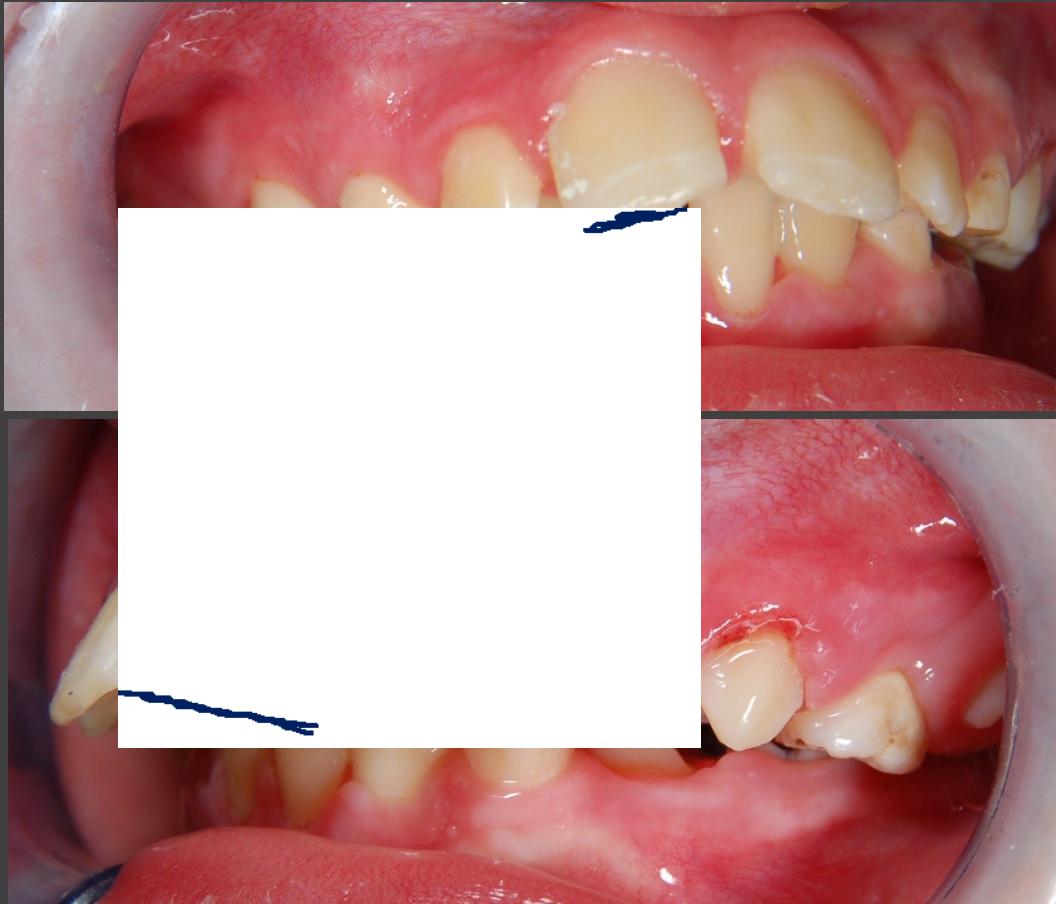Protrusion, retrusion



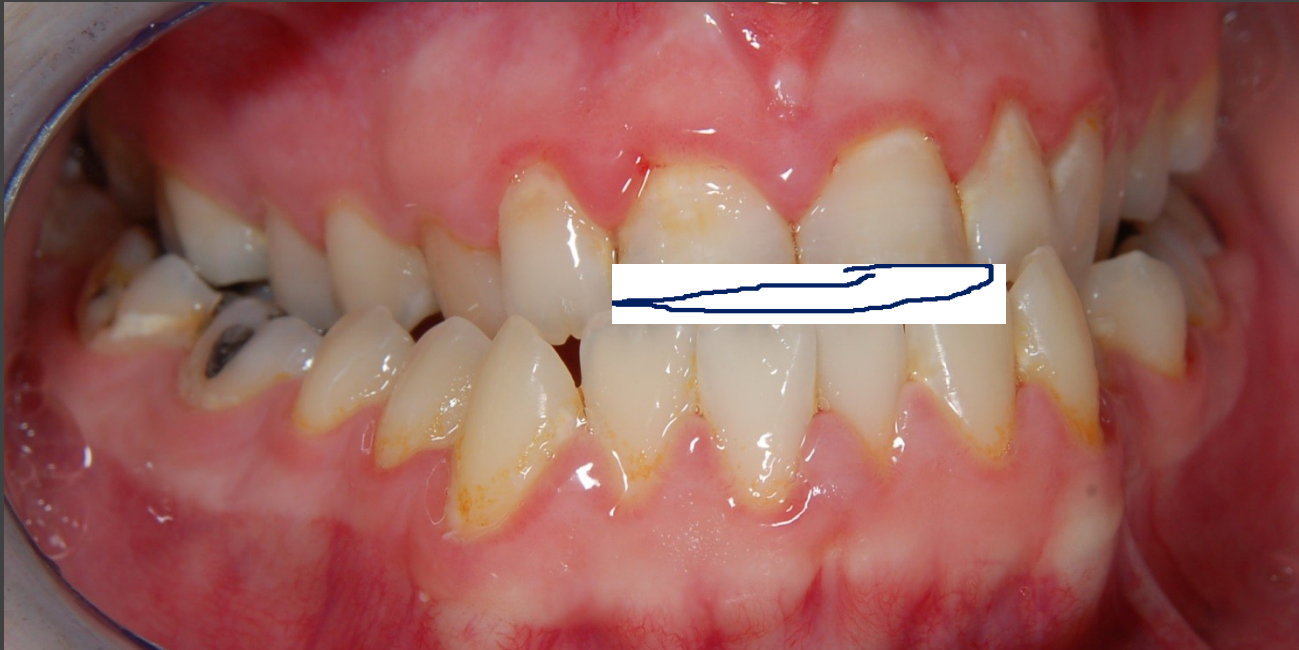Inverted bite – is in the frontal part – lower tooth is more anteriorly than the upper tooth



Protrusion with deep bite



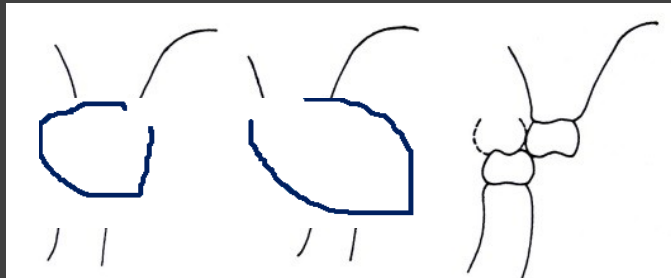
Inverted bite



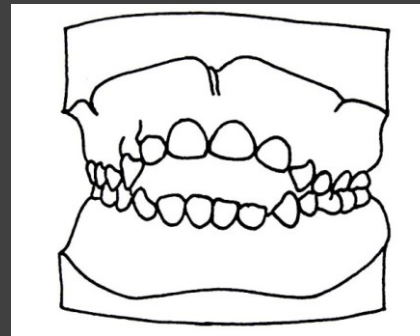
Classification of orthodontic anomalies

2. Anomalies of groups of teeth

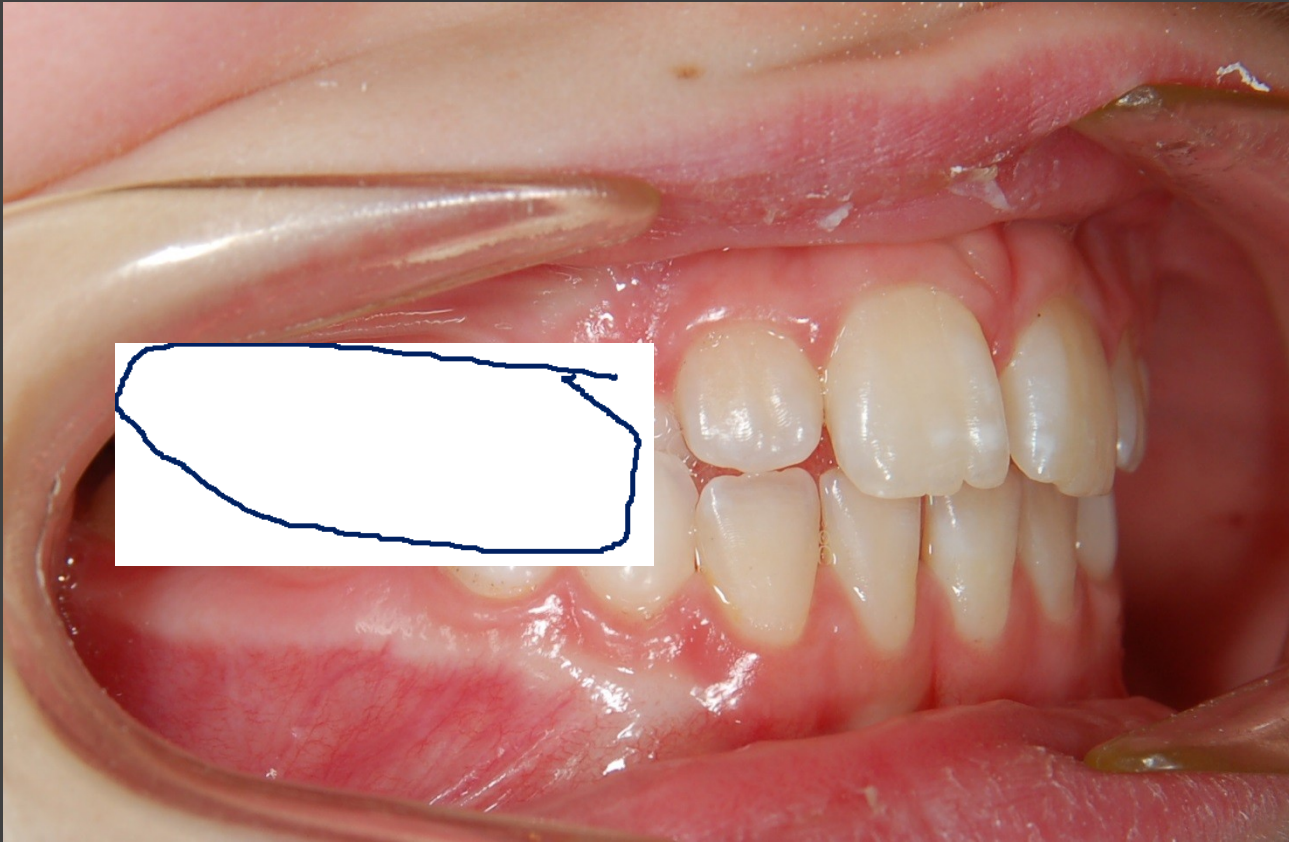
Cross bite – in lateral part the buccal cuspids of lower molars are more buccally than the in the intercuspidal line



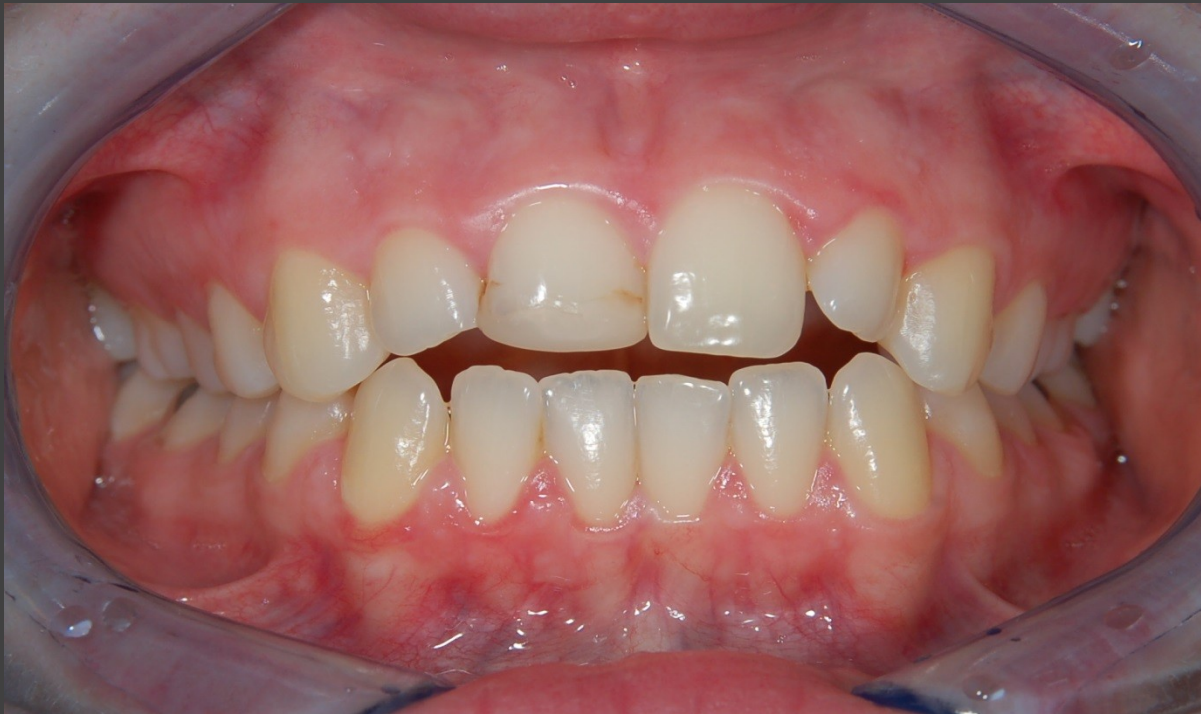Open bite - negativ overbite



Cross bite



Open bite



Classification of orthodontic anomalies

2. Anomalies of groups of teeth

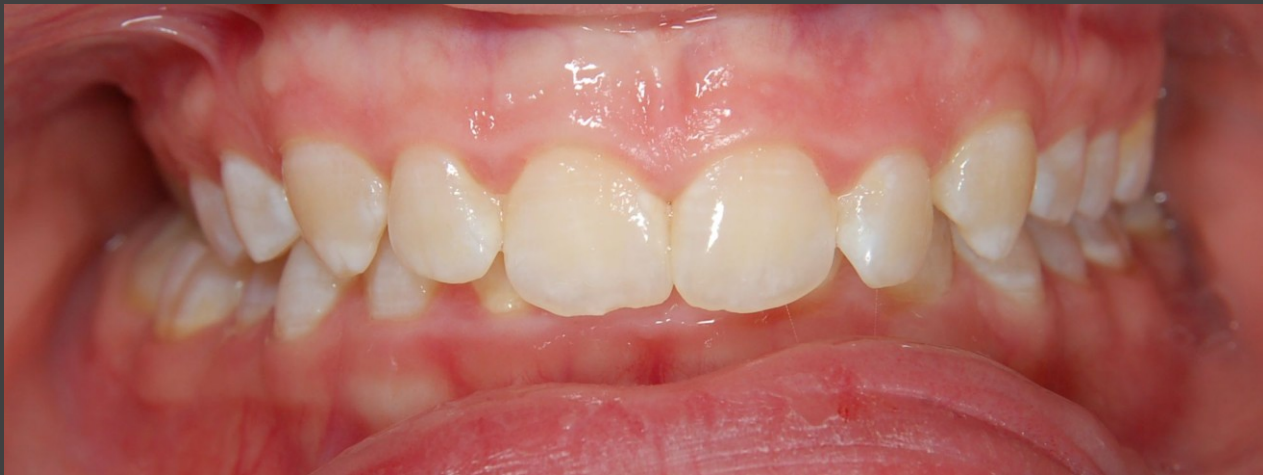Deep bite – the overbite is increased, the upper incisors cover more than the incisal third of the lower incisors

Spacing, diastema

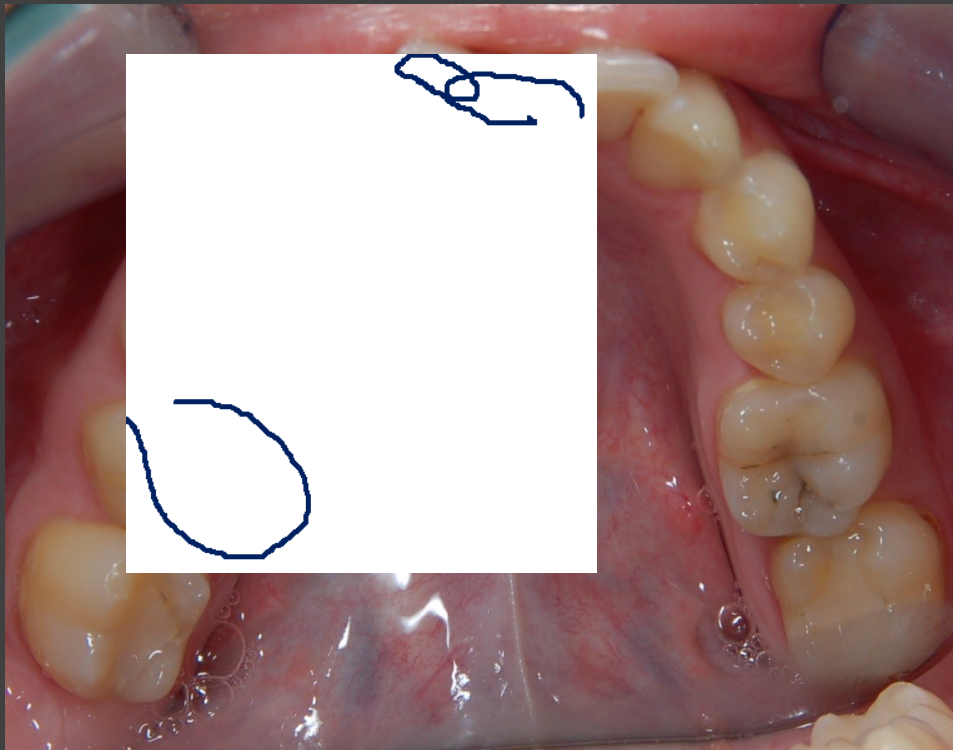
Crowding – primary, secondary, tertiary



Deep bite



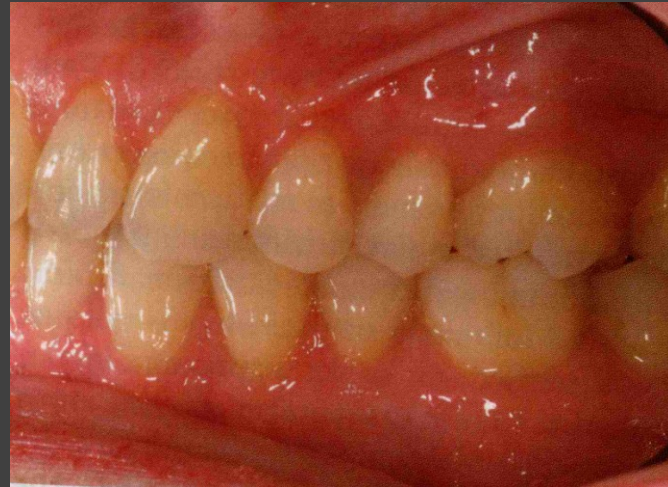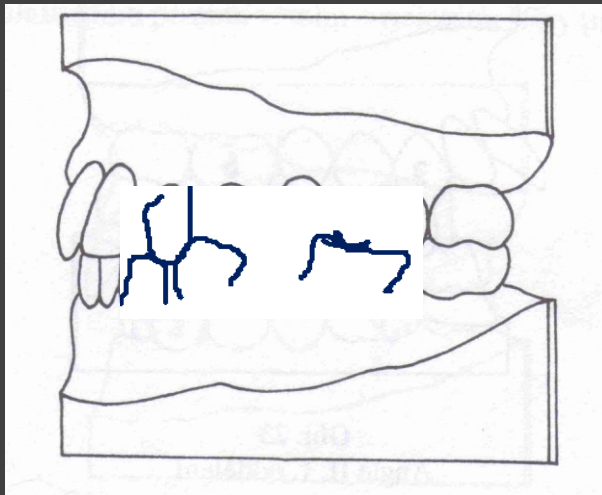
Crowding



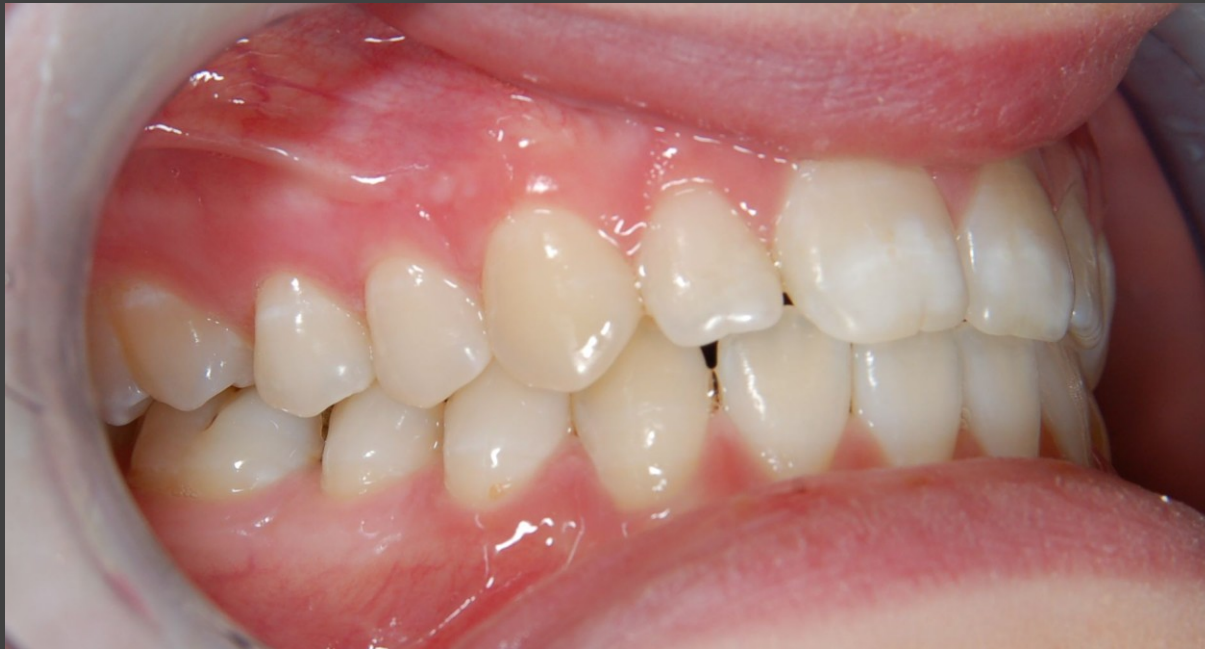Classification of orthodontic anomalies

3. Anomalies of the relationship of dental arches = Angles classification

Class I . normoocclusion



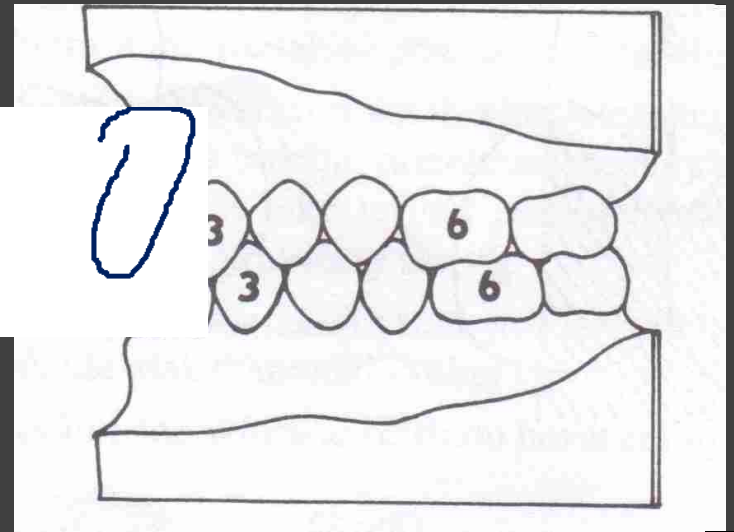
Angle I



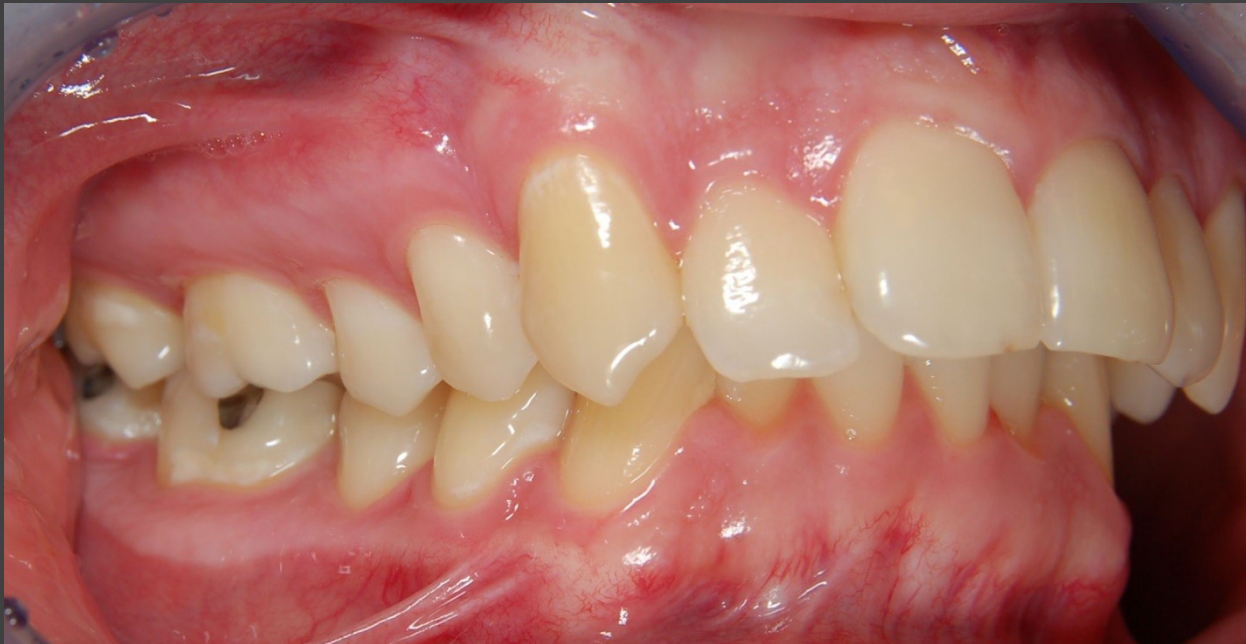Classification of orthodontic anomalies

Class II : distal occlusion

- with protrusion of upper incisors
- with retrusion of upper incisors

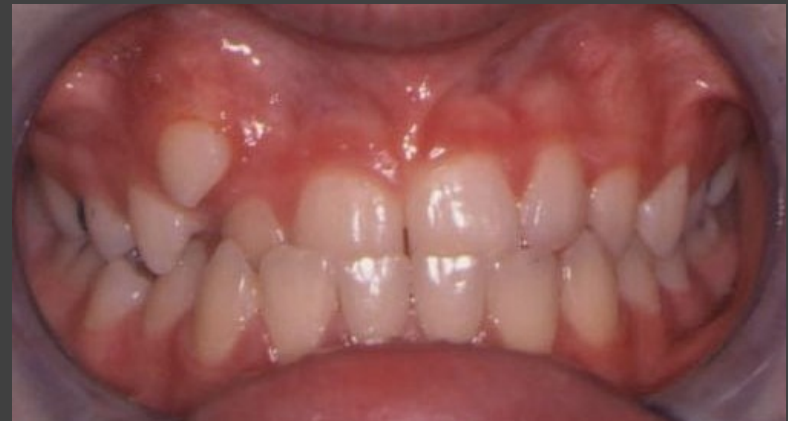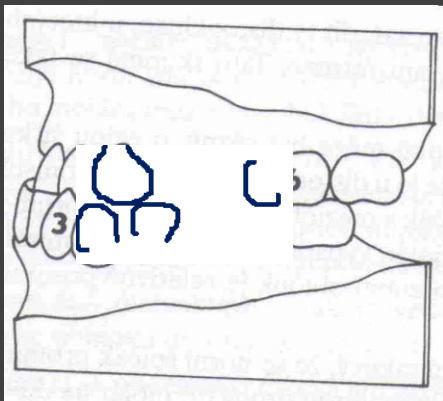


Angle II

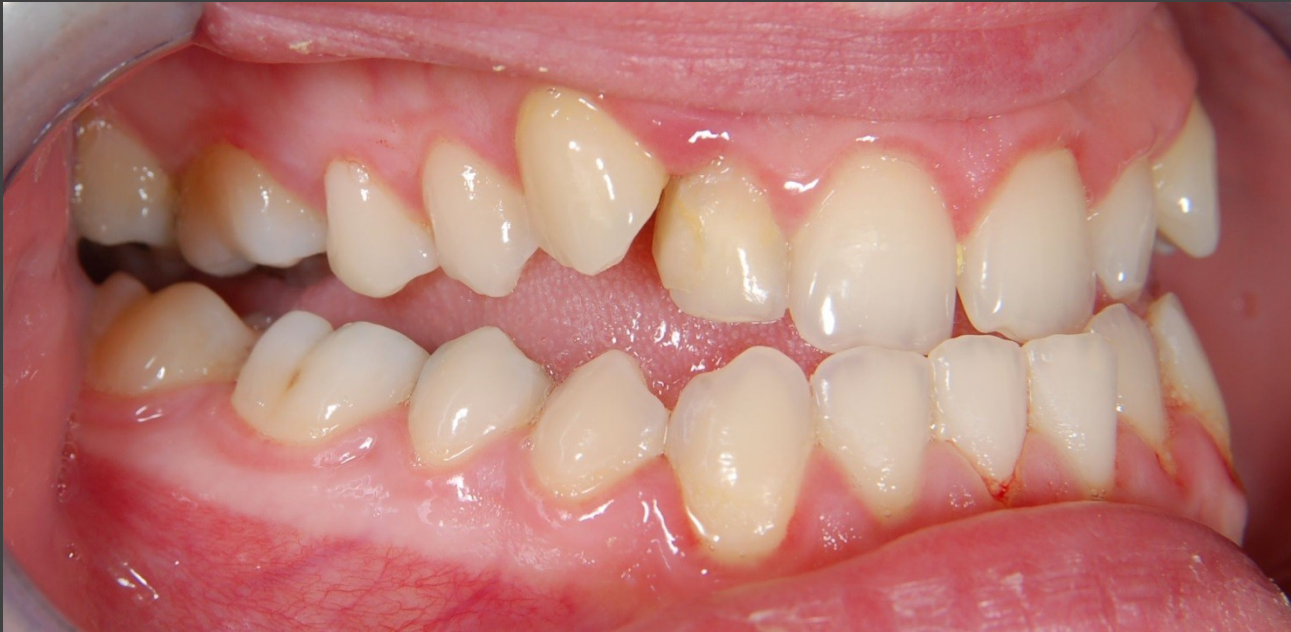

Classification of orthodontic anomalies

Class III : mesial occlusion




Angle III



Classification of orthodontic anomalies

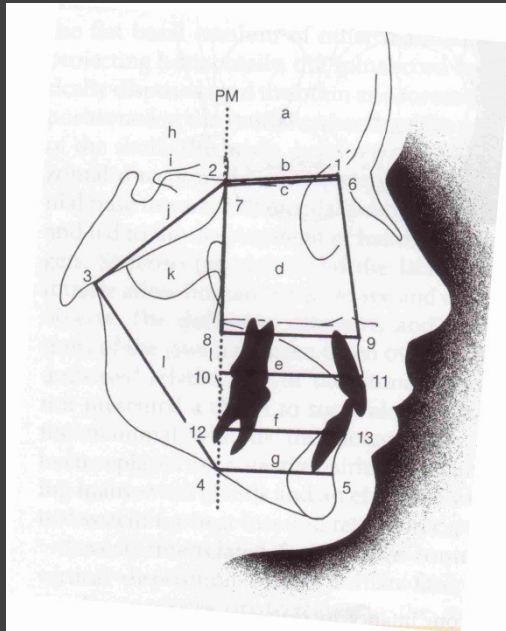
4. Anomalies of position, size and relationship of the jaws-bones



Classification of orthodontic anomalies

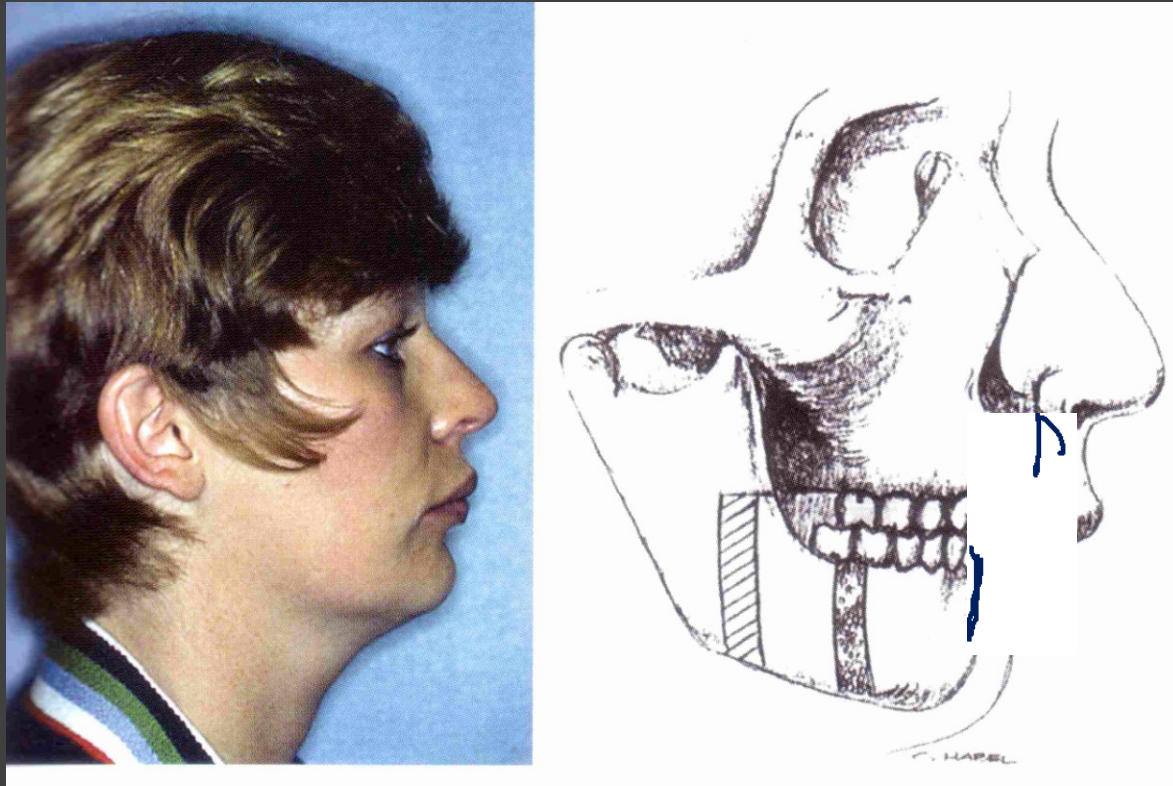
4. Anomalies of position, size and relationship of the jaws-bones

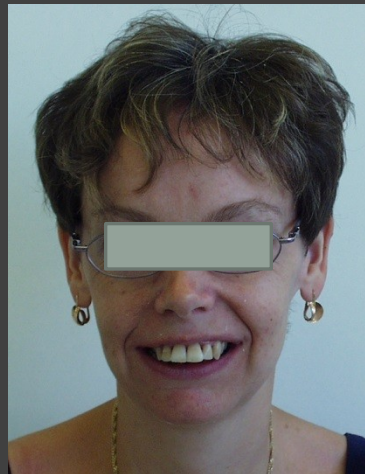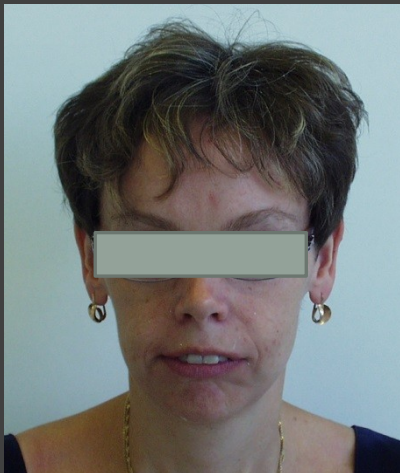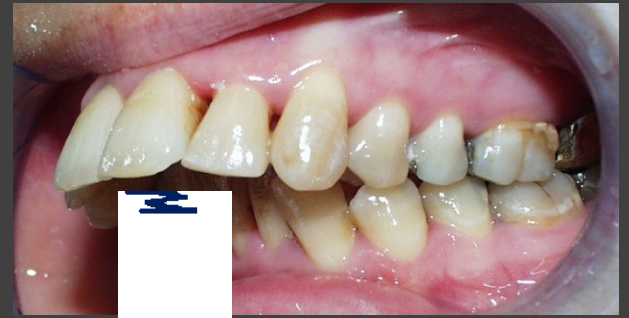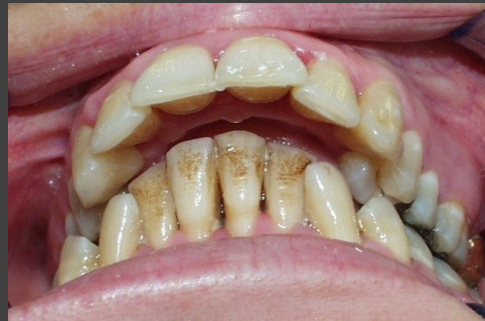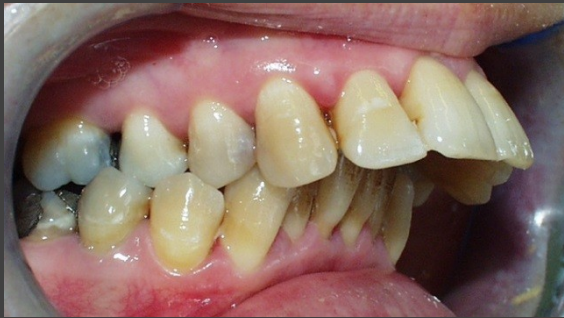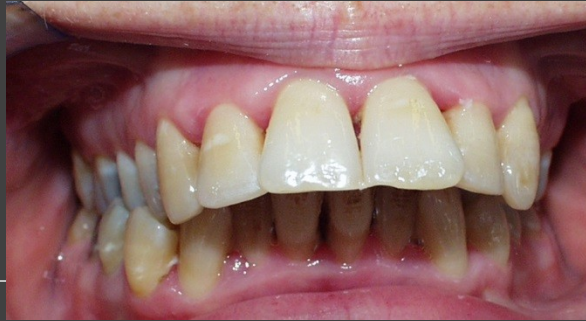Skeletal class I : relationship of jaws without any deviation



Classification of orthodontic anomalies

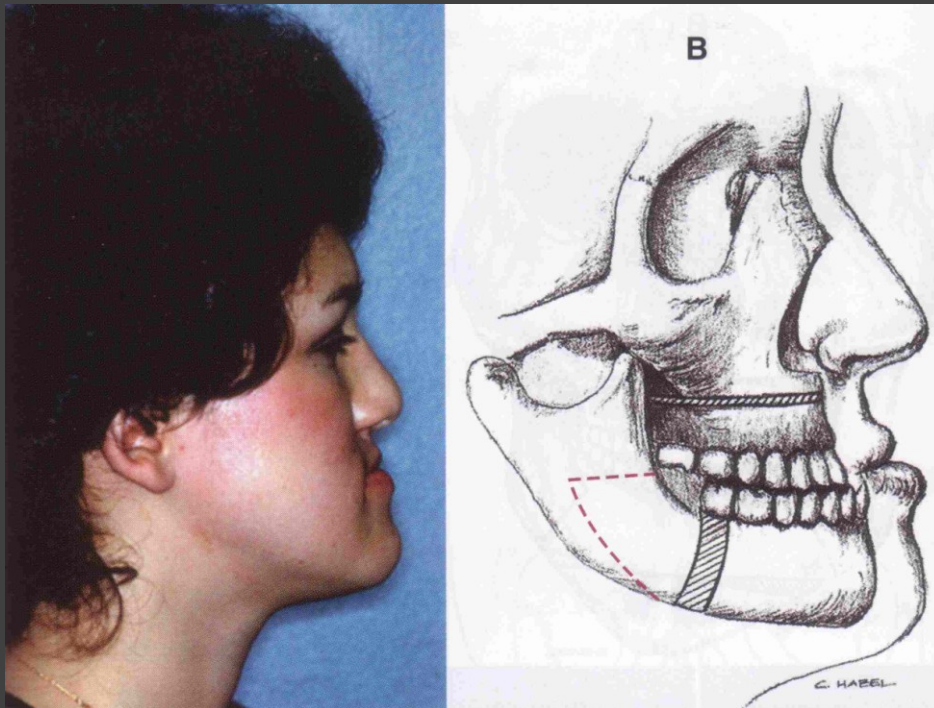
Skeletal class II : the lower jaw is more distally to the upper jaw
(small lower jaw, large upper jaw)





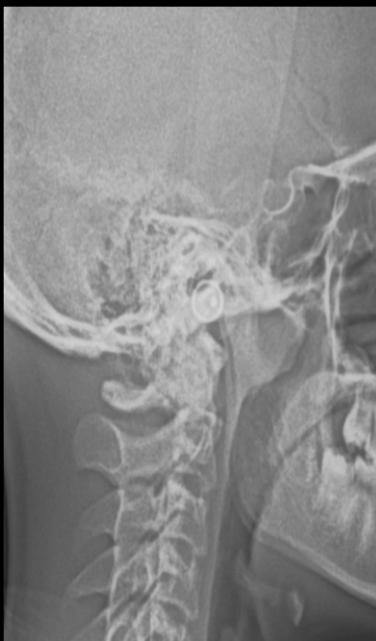

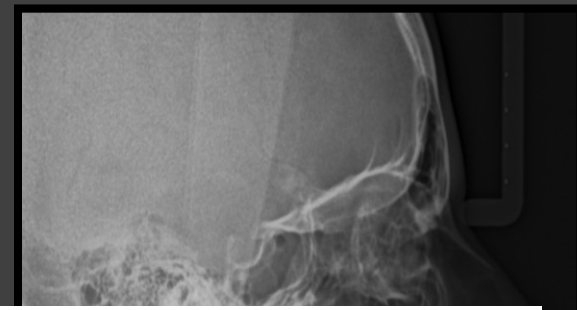
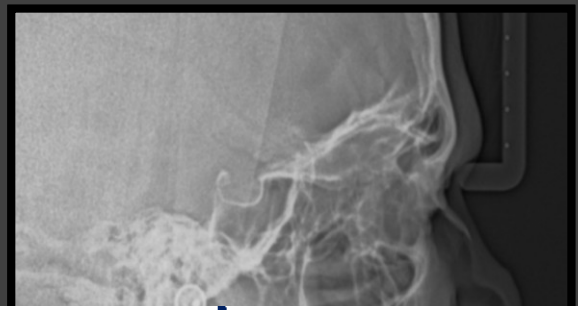
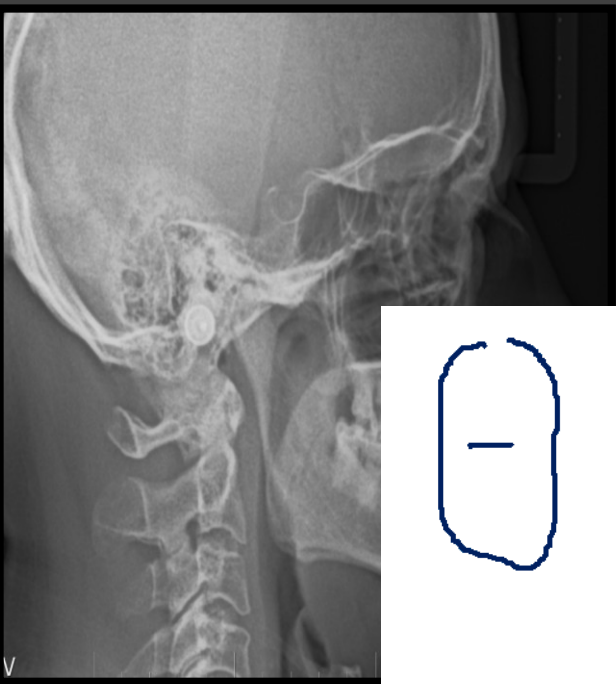
Classification of orthodontic anomalies

Skeletal class III : the lower jaw is ventral to the upper jaw
(progenia – large mandible, pseudoprogenia – small maxilla)



Classification of orthodontic anomalies





Diagnostic examination

1. ANAMNESIS

a] Family anamnesis

- dental problems of parents
- orthodontic anomalies of parents
- genetic health problems



Diagnostic examination

1. ANAMNESIS

b] health anamnesis of the patient

- medicaments
- allergy
- facial and dental injury
- contagious disease



Diagnostic examination

1. ANAMNESIS

c] special anamnesis of the patient

- frenulectomy
- adenotomy
- habits
- mouth breathing



Diagnostic examination

2. CLINICAL EXAMINATION

a] extraoral examination

- profile [convex, concave, straight]
- face symmetry
- temporomandibular joints



Diagnostic examination

2. CLINICAL EXAMINATION

b] intraoral examination

- Status of dentition, caries, fillings
- Anomalies of the relationship of dental arches –
Angles classification
- Overjet, overbite
- Status of oral soft tissues, frenulum
- Functional examination, centric occlusion
- hygiene



Diagnostic examination

3. MODEL EXAMINATION

- space analysis, discrepancy
- arch form
- dental anatomy
- intercuspitation



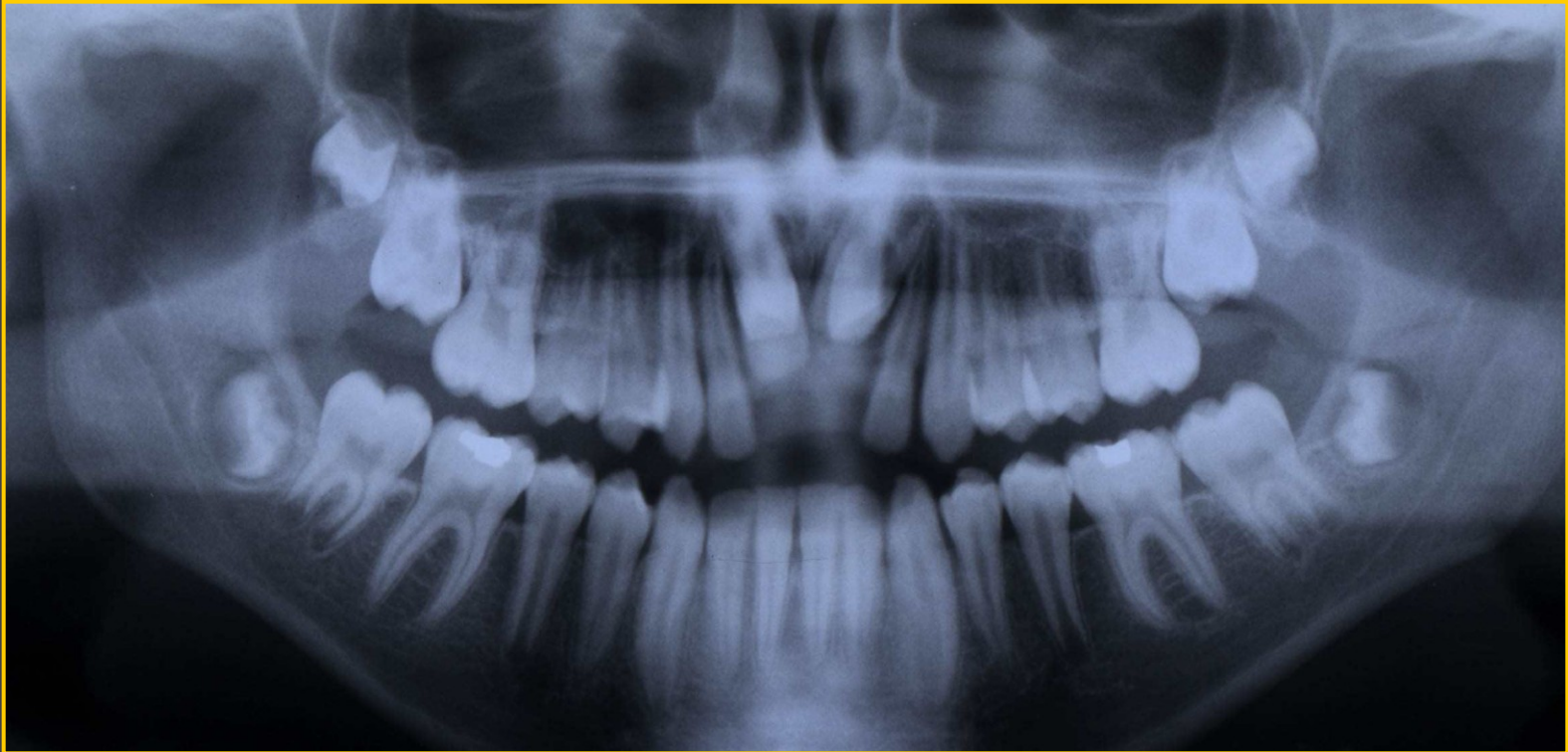Diagnostic examination

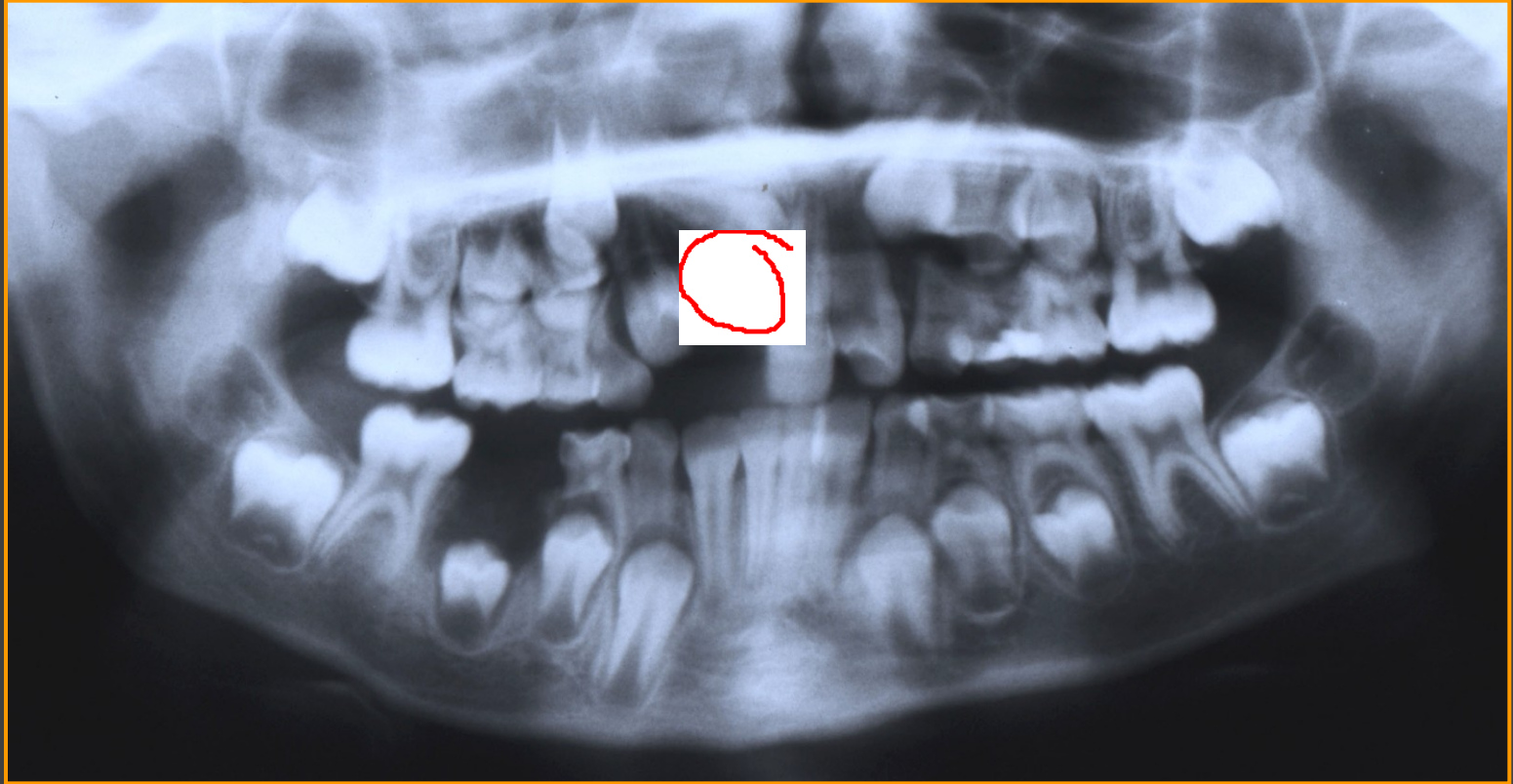
4. RADIOGRAPHS

a] Panoramic

- detection of congenital absences of teeth
- detection of supernumerary teeth
- evaluation of the dental health of the permanent teeth
- assessment of trauma to the teeth after injury
- determination of dental age of the patient
- calculation of root resorption
- condyles







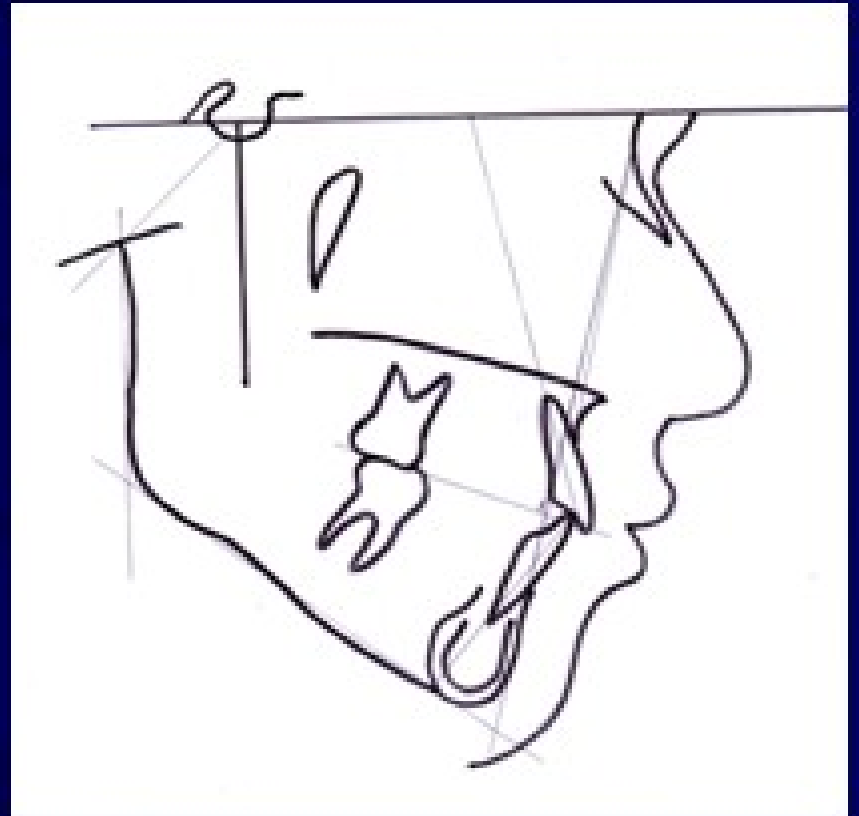
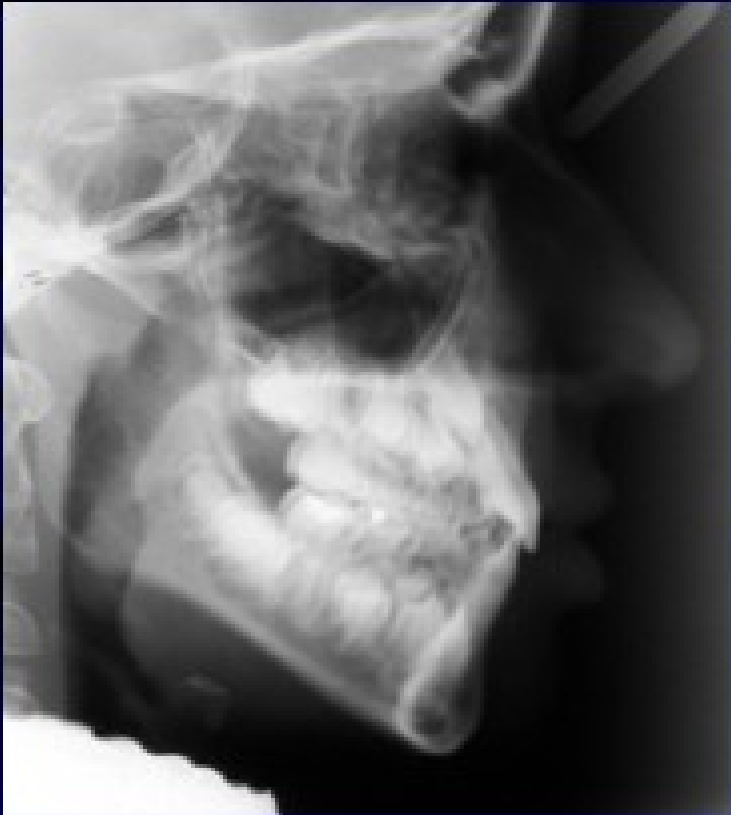Diagnostic examination

4. RADIOGRAPHS

b] Cephalometric radiographs

- evaluation of craniofaciodental relationship
- assessment of the soft tissue matrix
- determination of mandibular position
- prediction of growth and development
- detection of skeletal age





N - nasion (1)

S - sella (2)

a - articulare (3)

Me - menton (6)

Po - pogonion (7)

SpA - spina nasalis ant. (9)

SpP - spina nasalis post. (10)

A - bod A (11)

Is' - apex (12)

Is - incisale superius (13)

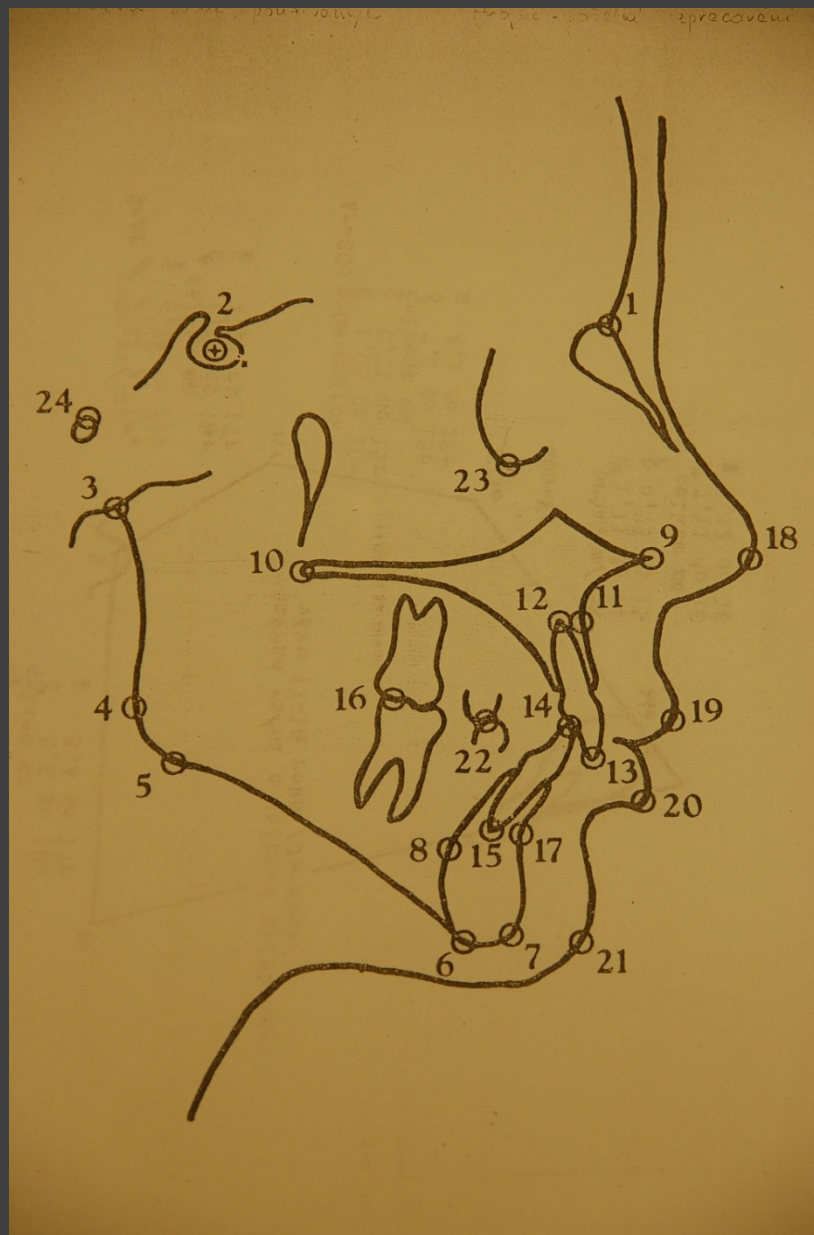
Ii - incisale inferius (14)

Ii' - apex (15)

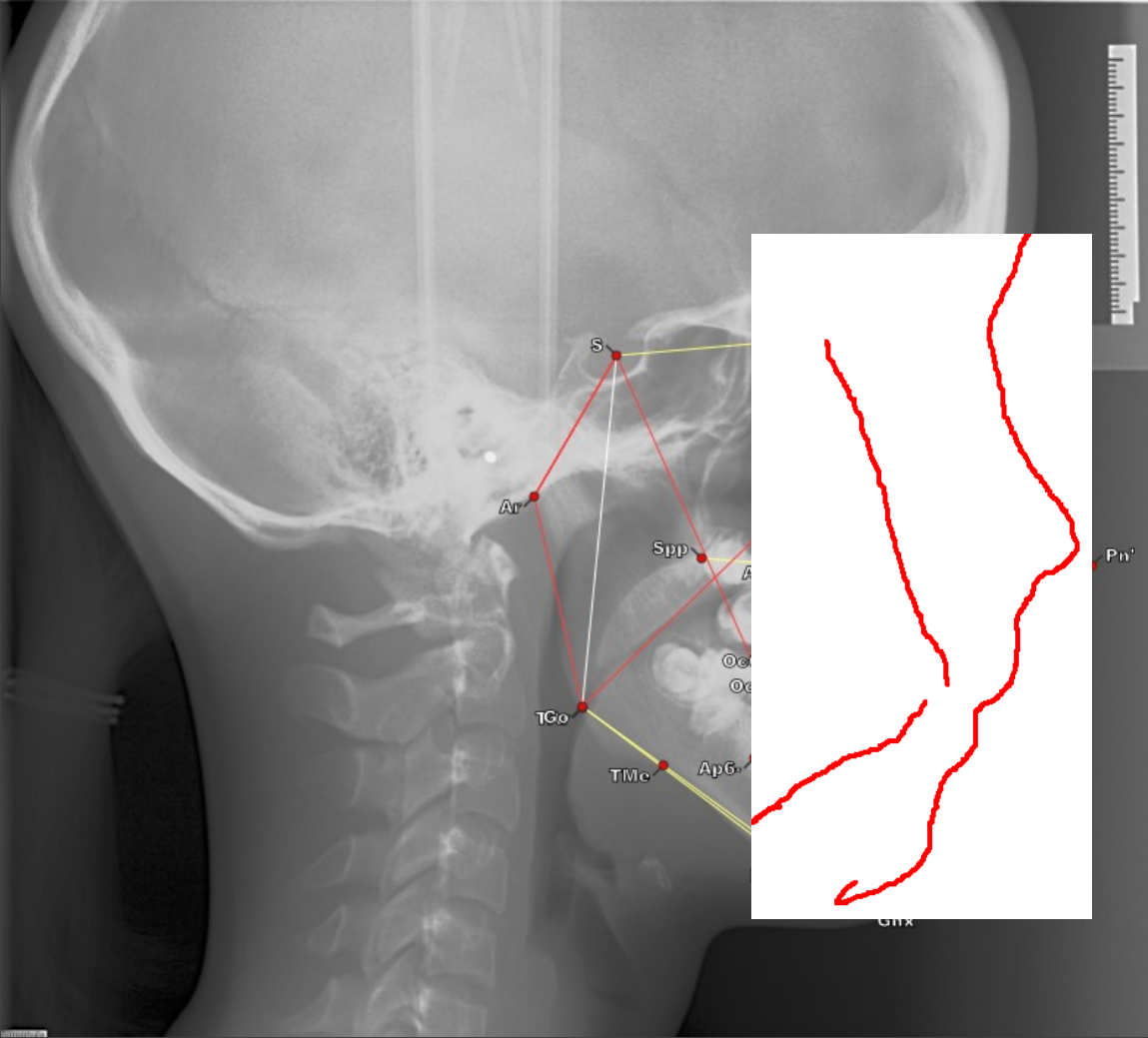
B - bod B (17)

Go - gonion (kontr. bod: 1. a-4, 2. ML)

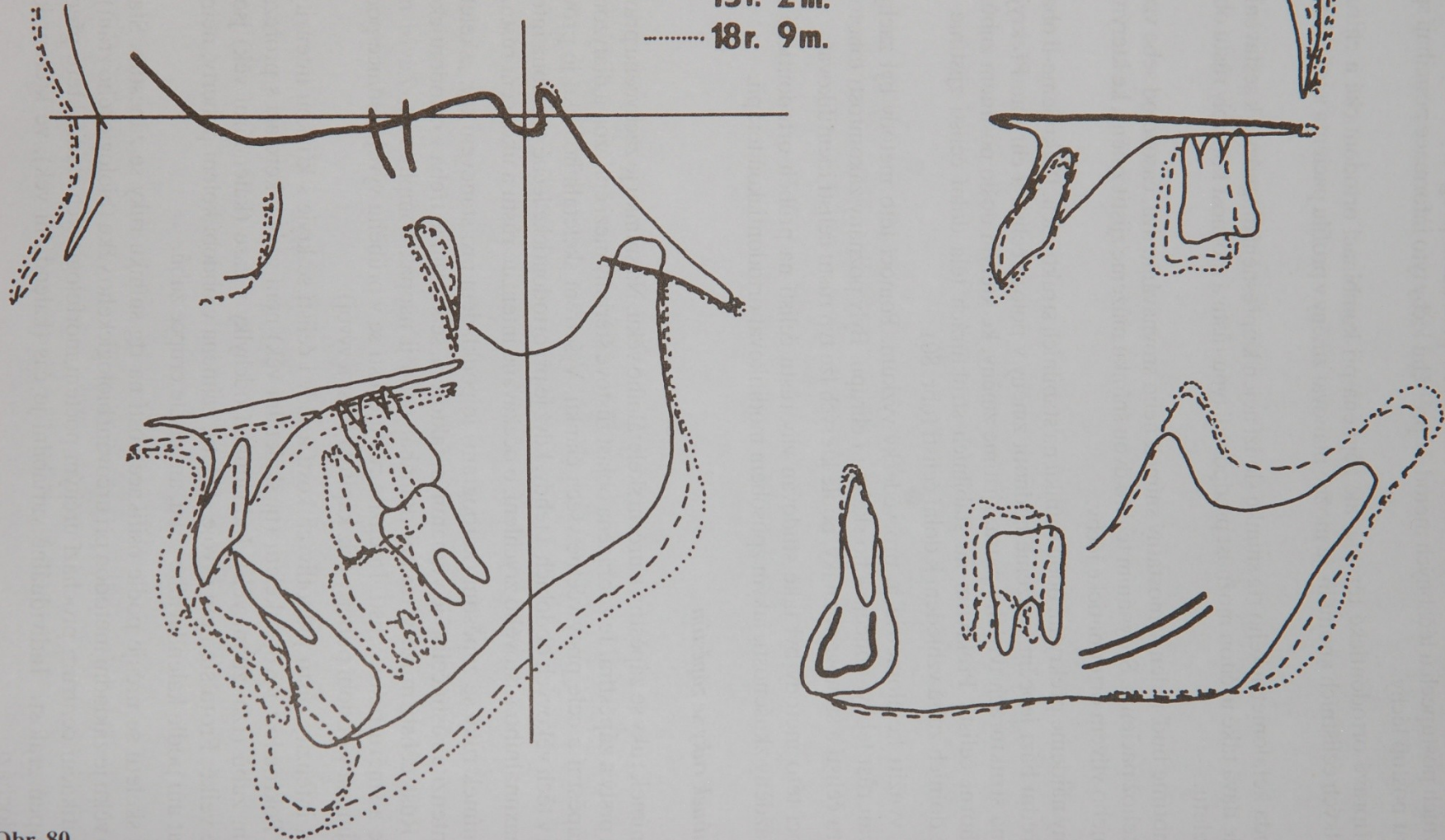
Gn - gnation (konstr. bod: 1. N-Po, 2. ML)



Cephalometric analysis



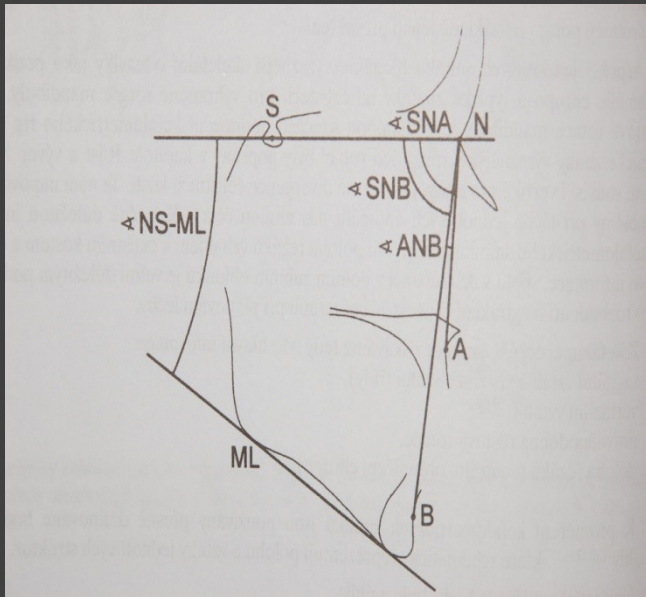
— 9r. 2m.
- - - 13r. 2m.
· · · · · 18r. 9m.



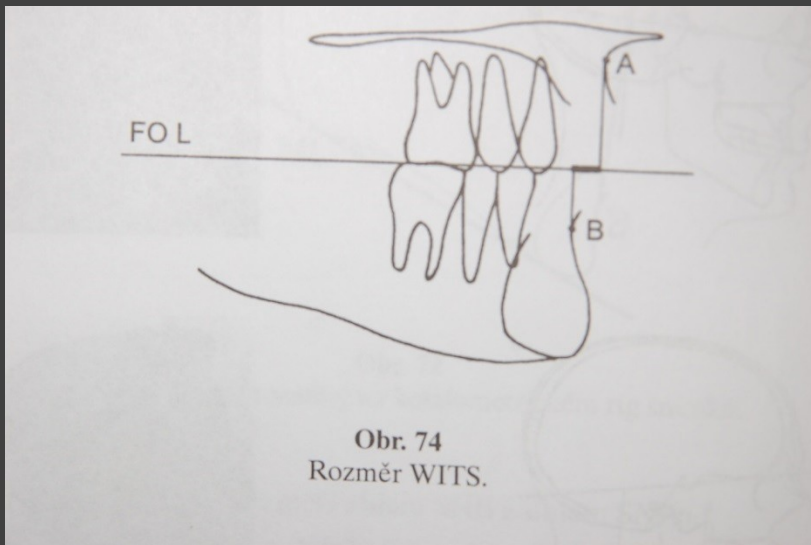
Obr. 80



skeletal analysis



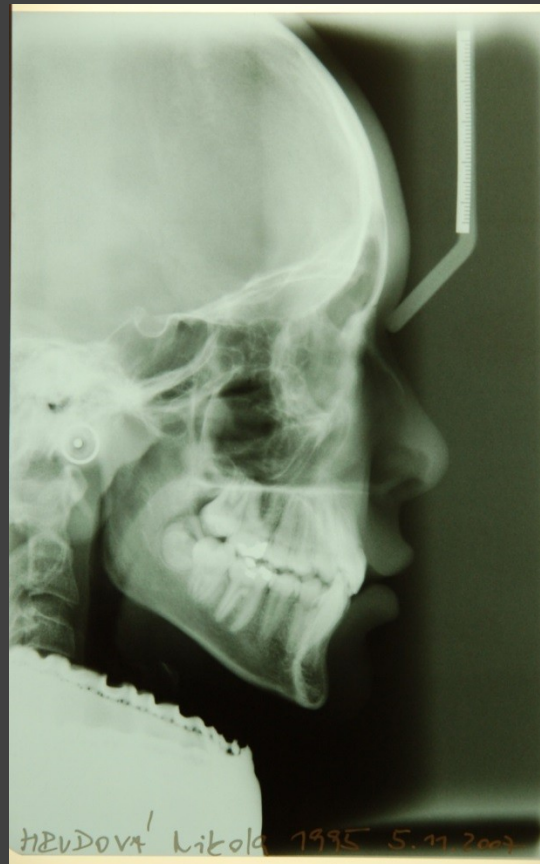ANB (-1° to $+5^{\circ}$)



WITS (-2 to +2mm)

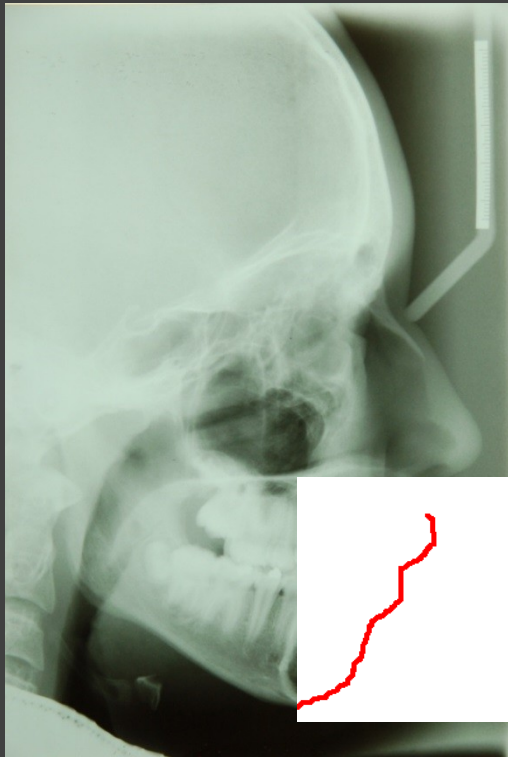

Skeletal class I

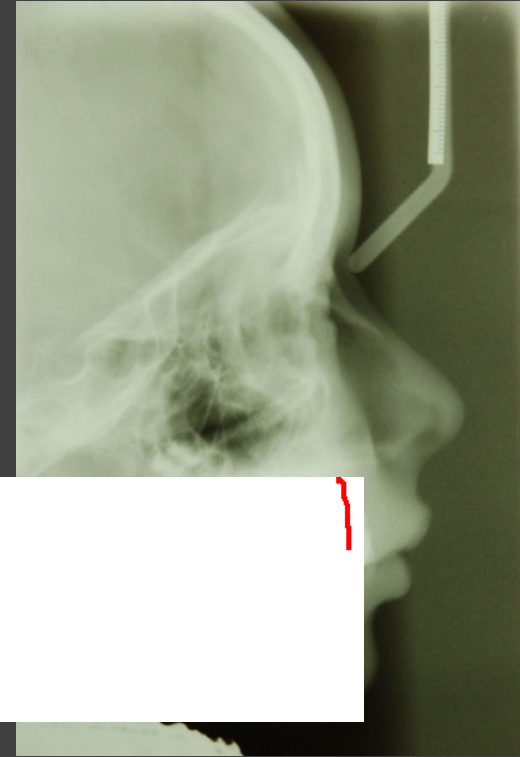

Skeletal class II

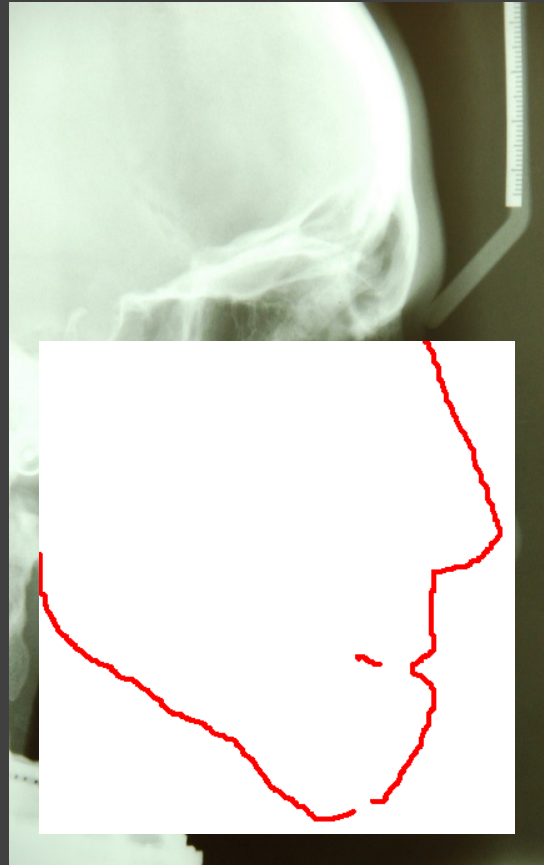with protrusion of incisors



with retrusion of upper incisors



Skeletal class III



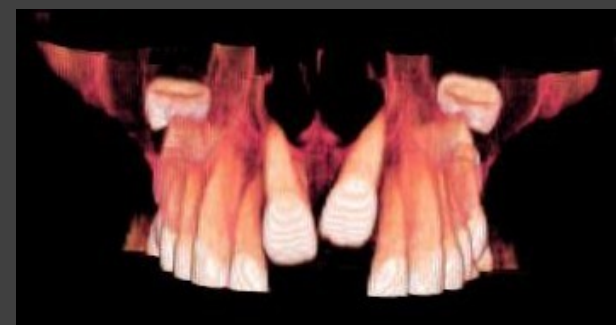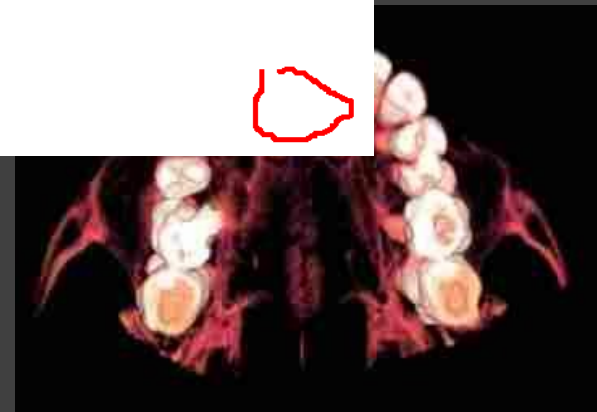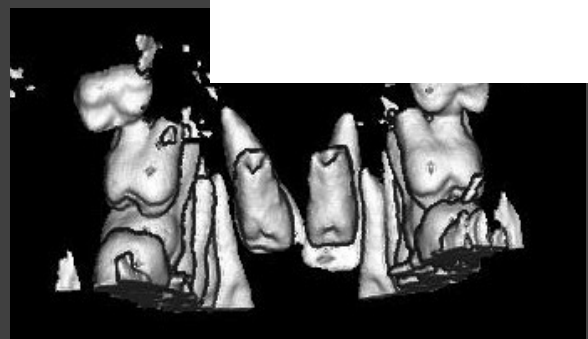

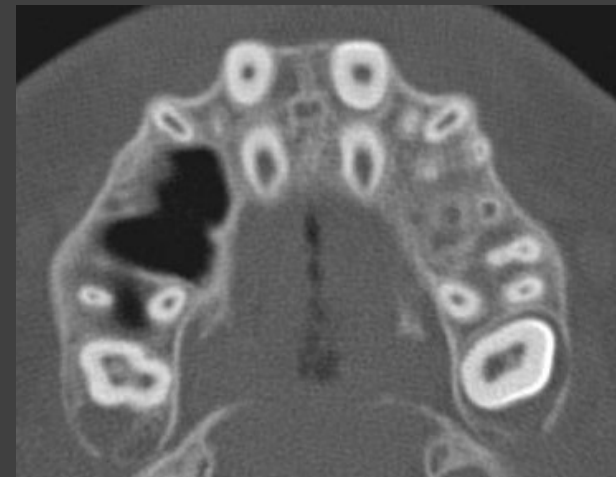Diagnostic examination

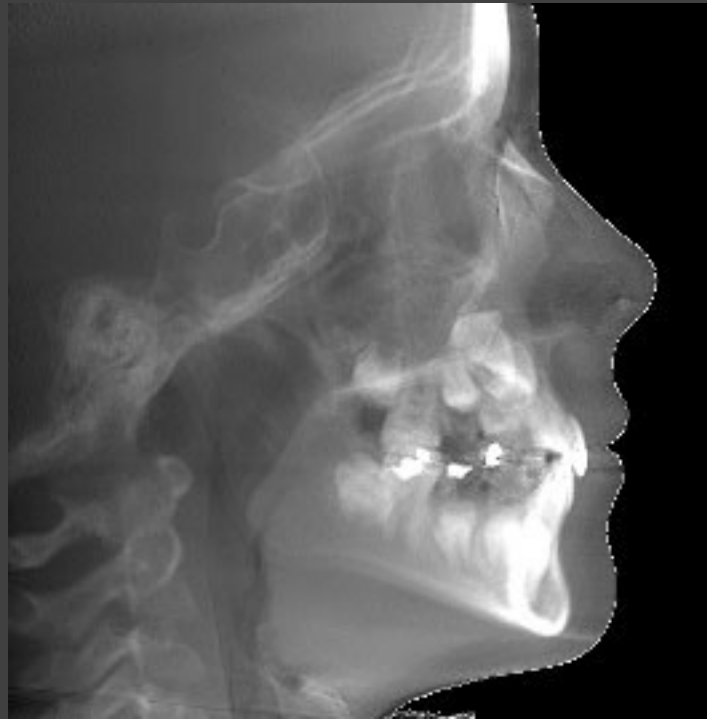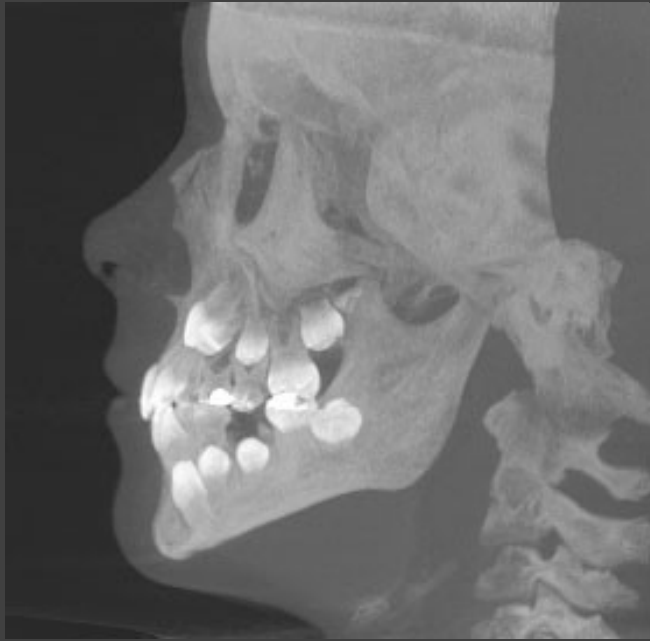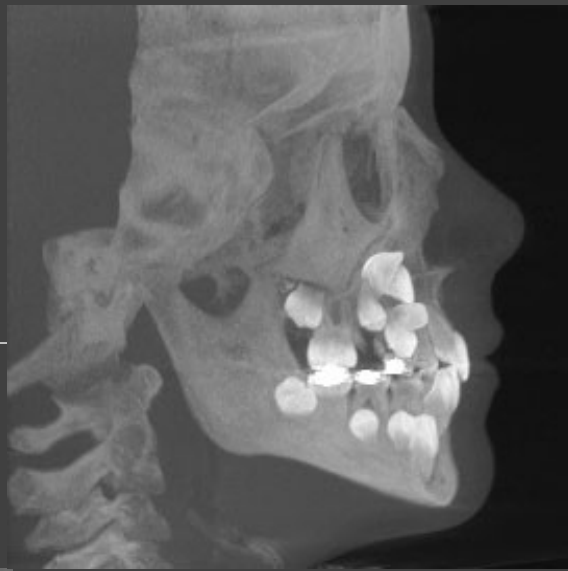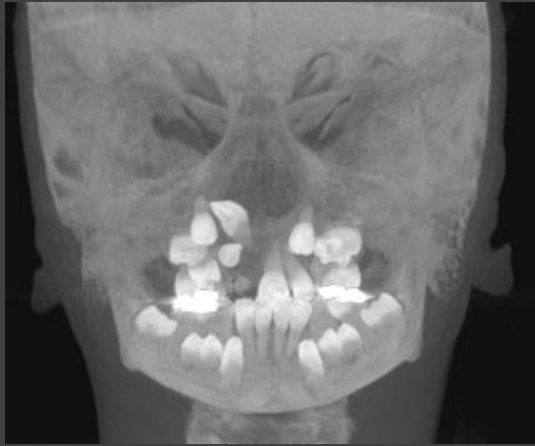4. RADIOGRAPHS

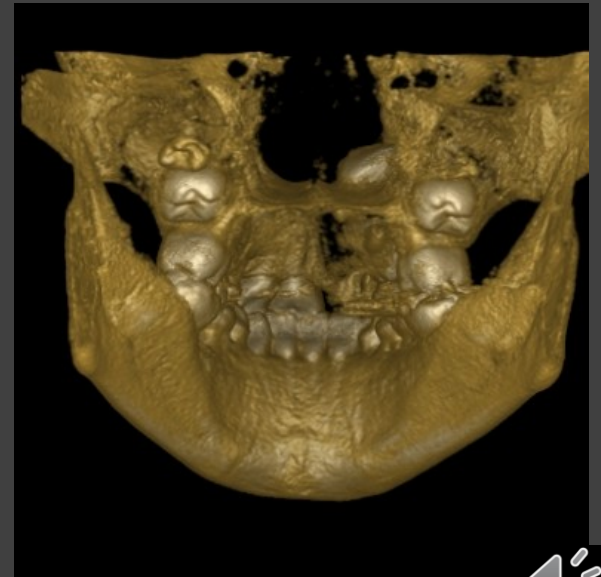
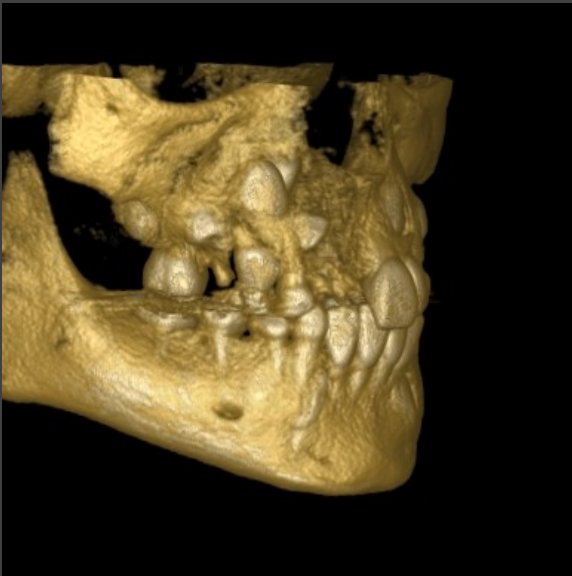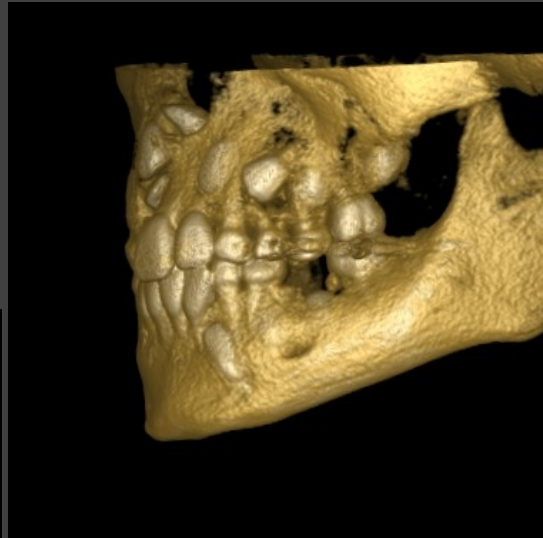
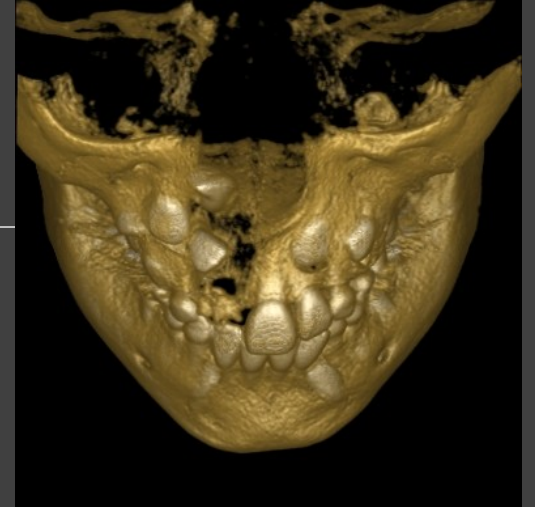
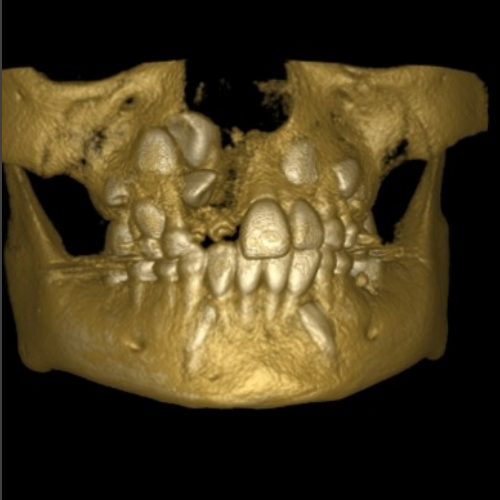c] Other radiographs

- Bitewing – caries detection
- Hand wrist – detection of skeletal age
- Computer tomography –CT scan [impacted tooth, ankylosed tooth, difficult skeletal anomalies
- Digital imaging – computer generated model reconstructed from the initial imaging data







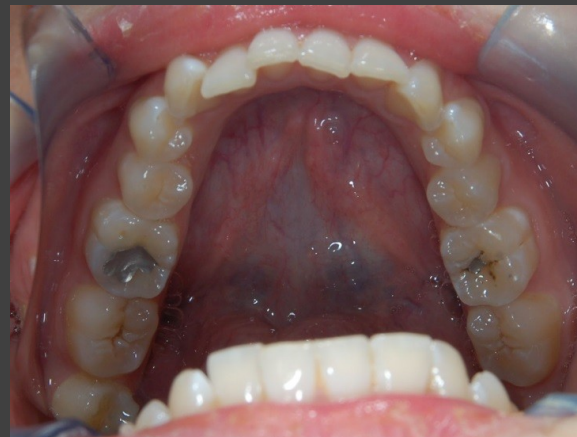
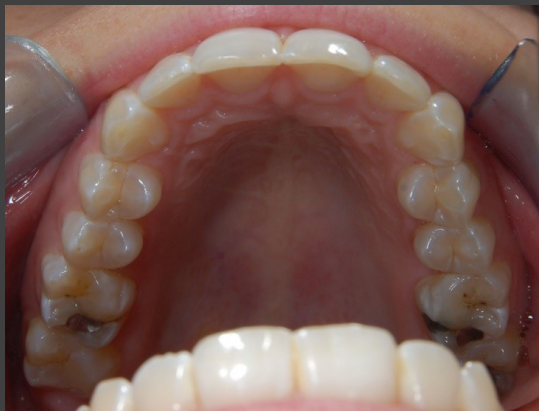
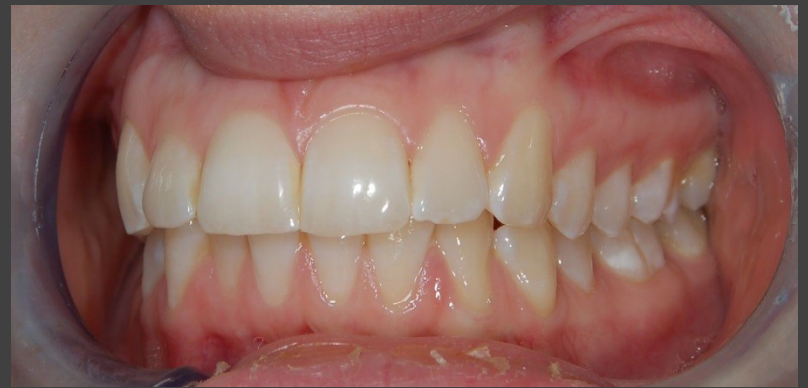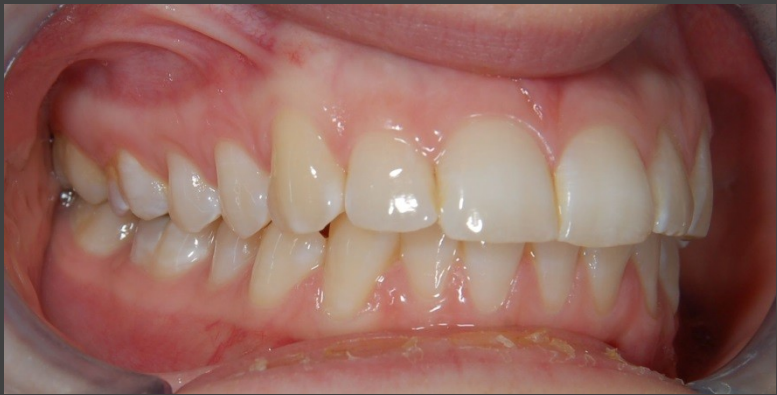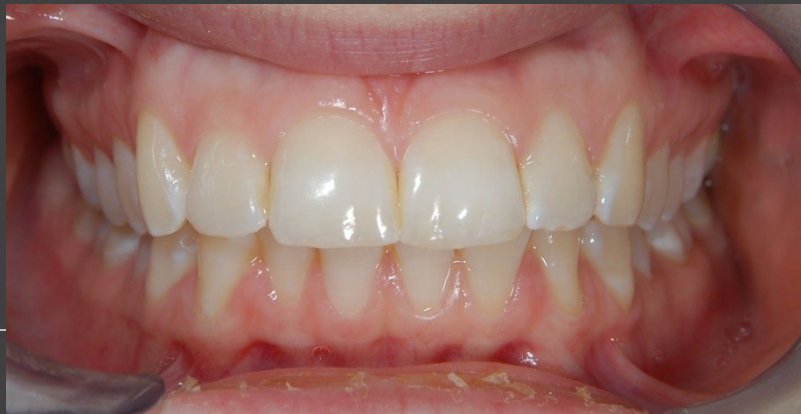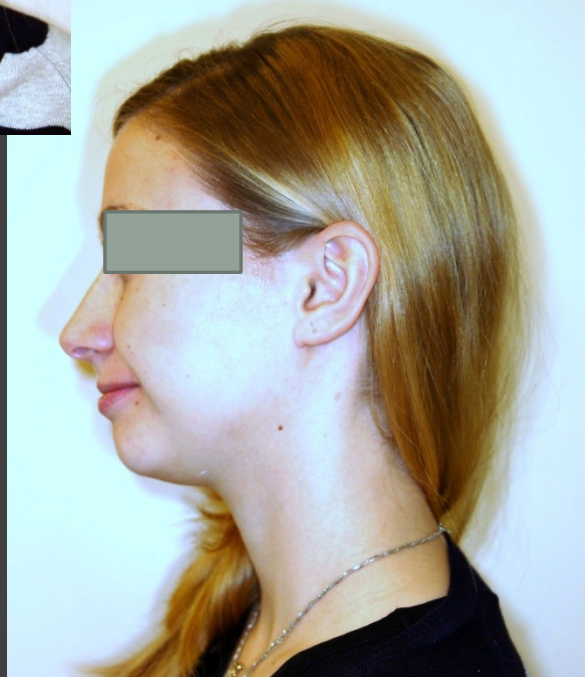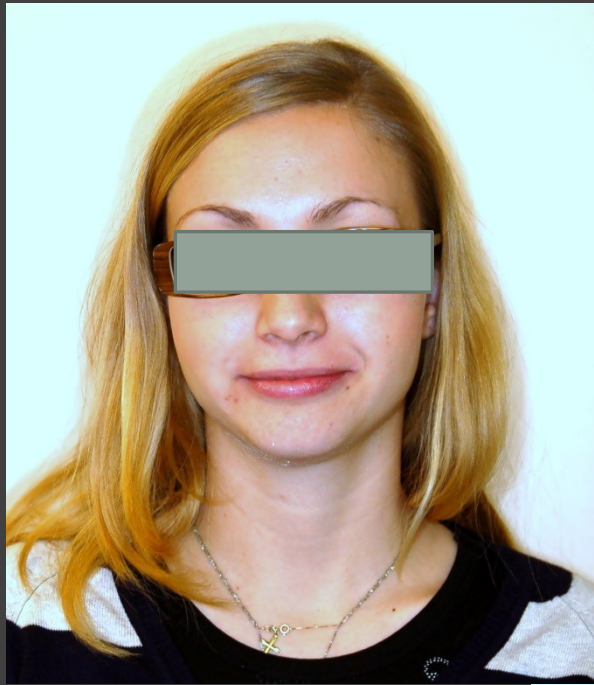Diagnostic examination

5. PHOTOGRAPHS

- extraoral photographs - frontal
 - profile
 - smile
- Intraoral photographs - frontal teeth
 - right and left side
 - upper and lower arch

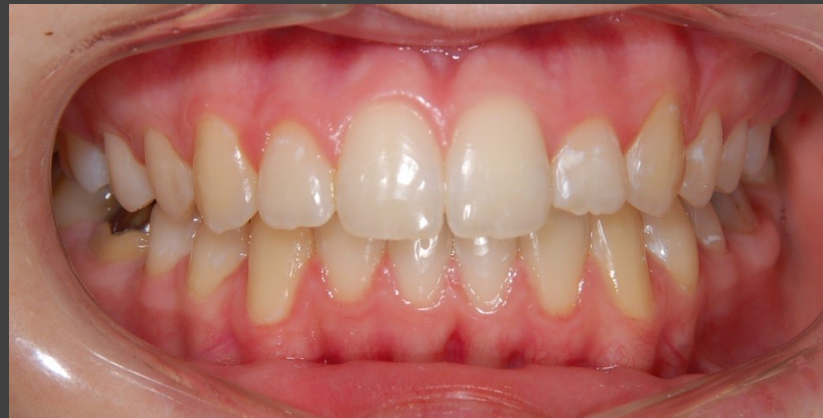





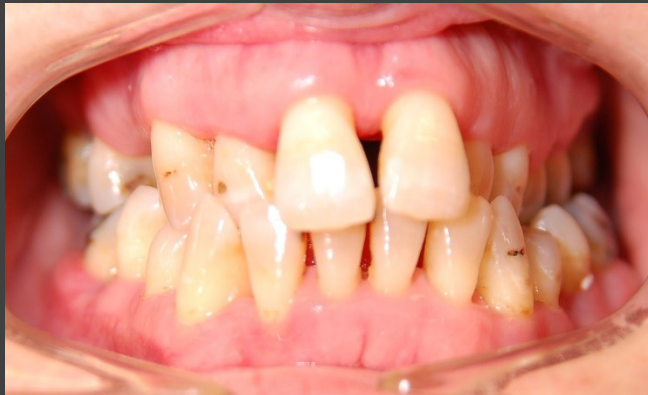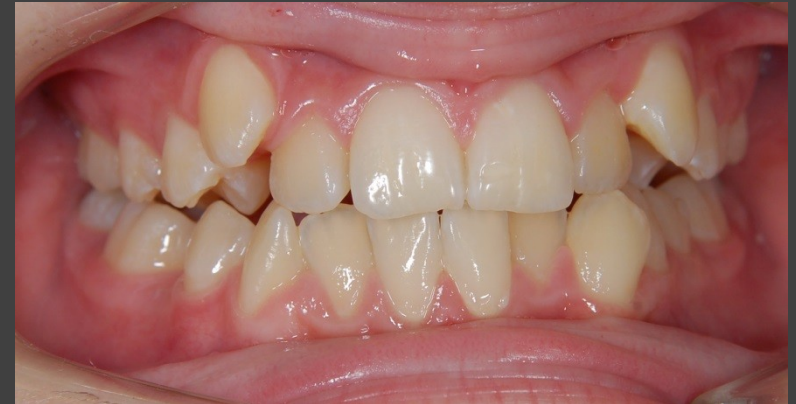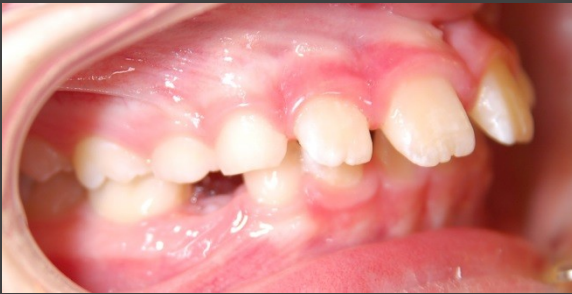Etiology of orthodontic anomalies

Ideal set of teeth can be seen in aprox. 25% of population
40% need treatment



Etiology of orthodontic anomalies

Malocclusion is a manifestation of genetic and environmental interaction on the development of orofacial region



Etiology of orthodontic anomalies

The etiological factors:

1. genetic influences
2. prenatal factors
3. postnatal, environmental influences



Etiology of orthodontic anomalies

Hereditary are mainly:

- Shape and size of tooth
- Teeth number
- Shape and size of jawbones
- Time of teeth eruption
- Time and type growing jawbones



Etiology of orthodontic anomalies

Mainly hereditary anomalies:

- True mandibular prognathia
- Skeletal open bite
- Skeletal deep bite
- Primary crowding
- Skeletal class II and III
- Hypodontia, hyperodontia
- Deep bite with retrusion of incisors
- Retention or impaction of teeth
- clefts



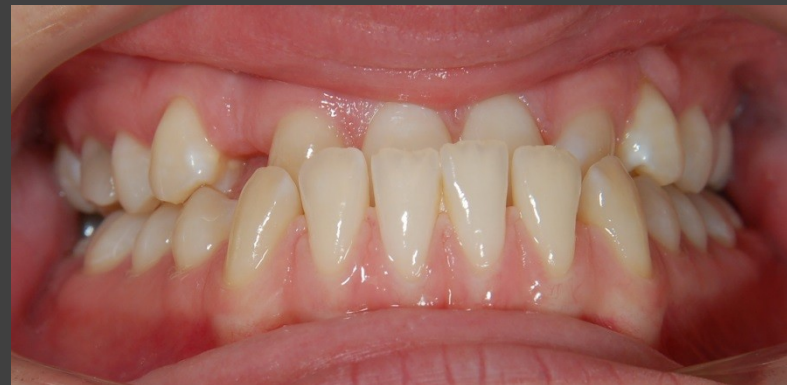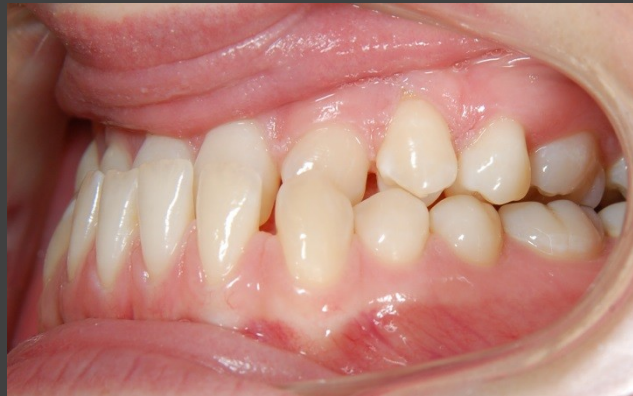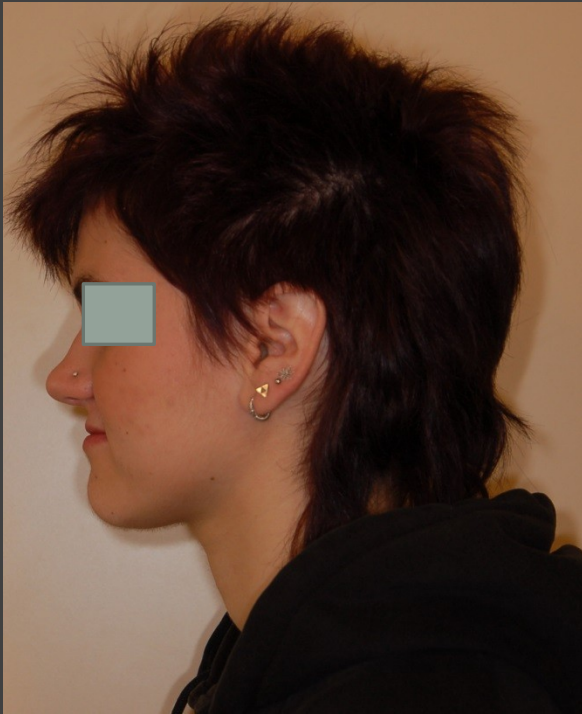Etiology of orthodontic anomalies

Mainly hereditary anomalies- mandibular prognatism in the Hapsburg family

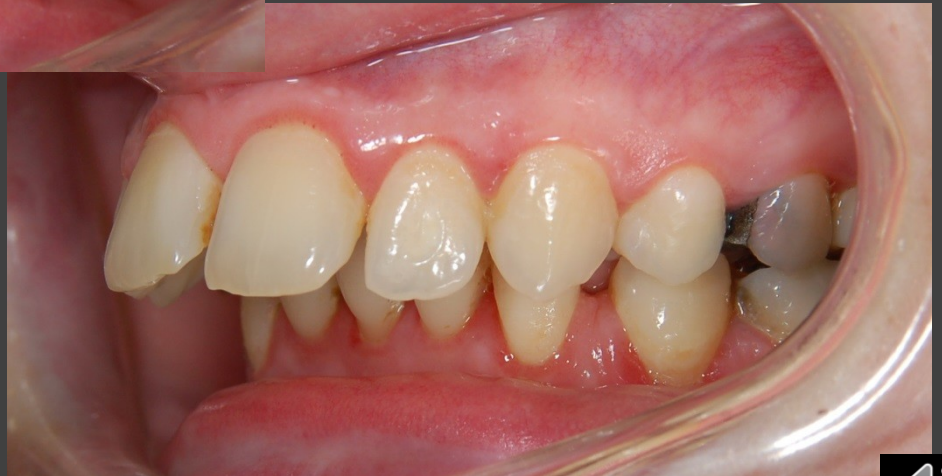
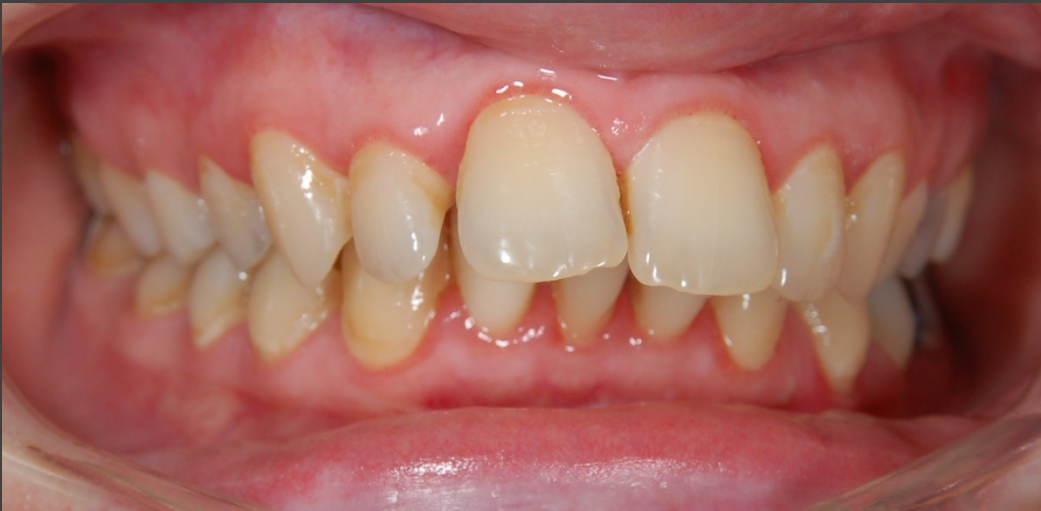
Etiology of orthodontic anomalies

Mainly hereditary anomalies – skeletal class III

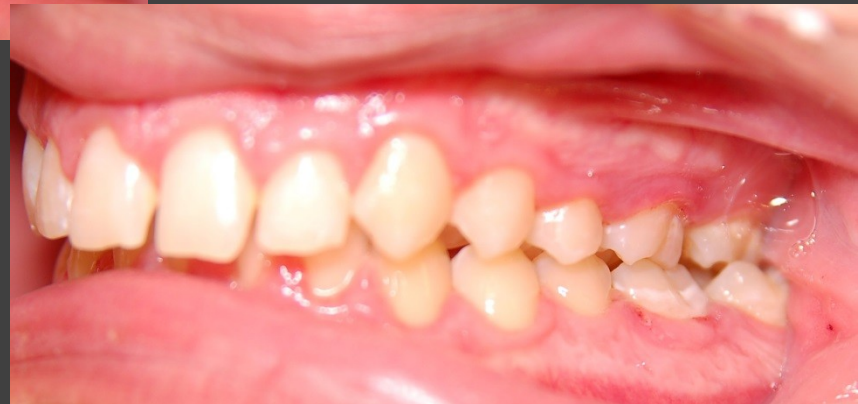
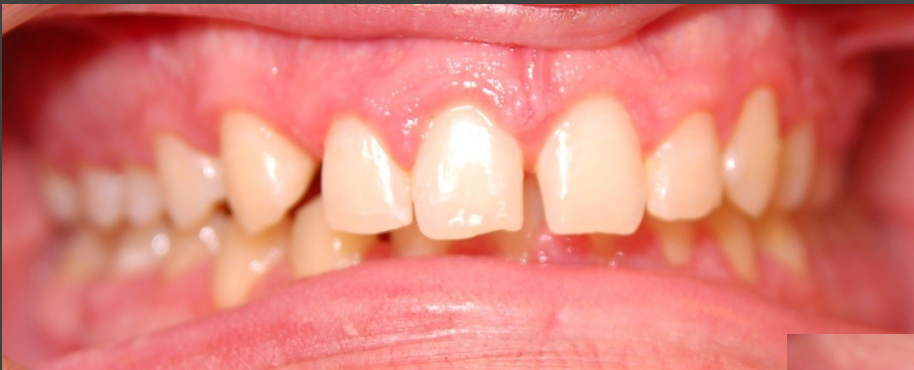
Etiology of orthodontic anomalies



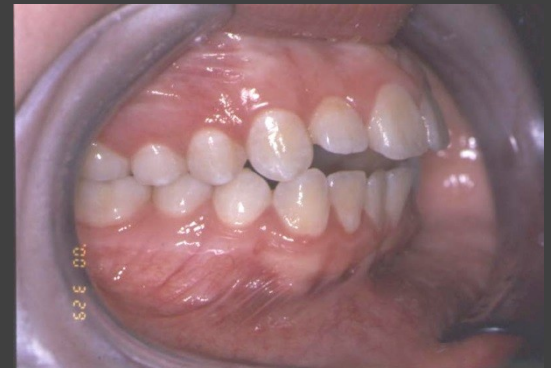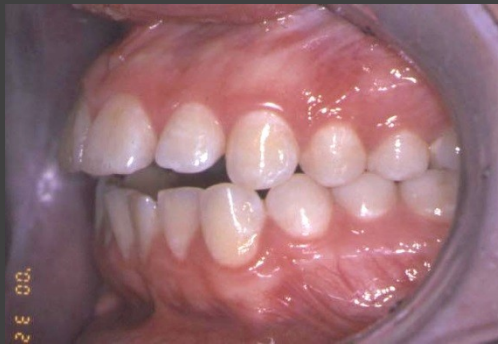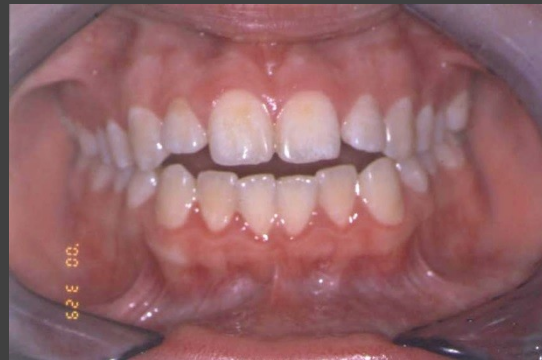Etiology of orthodontic anomalies

Mainly hereditary anomalies – skeletal deep bite



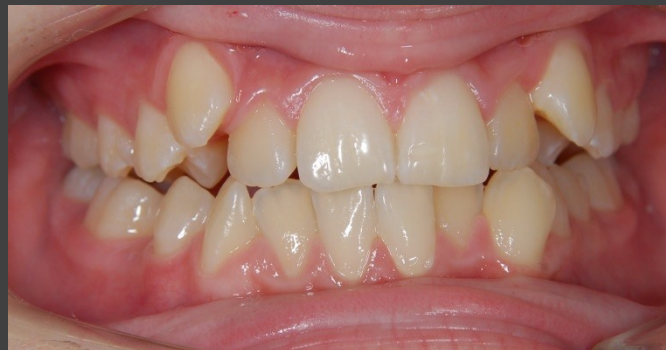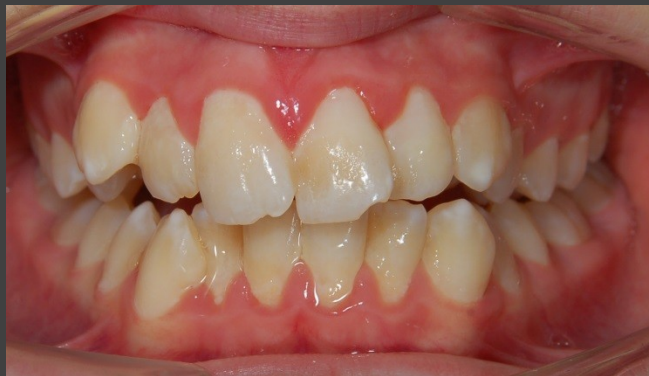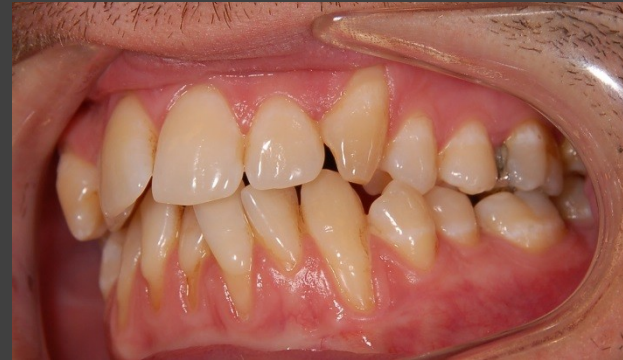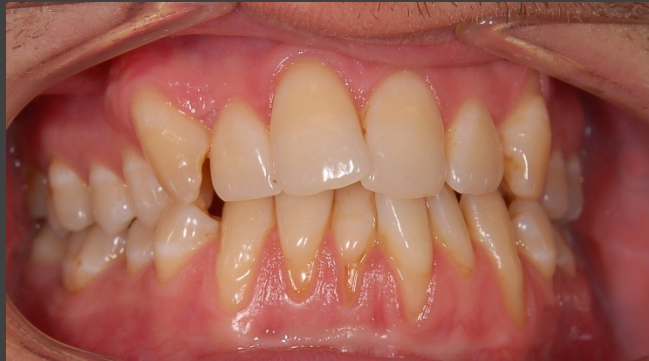Etiology of orthodontic anomalies

Mainly hereditary anomalies- skeletal open bite



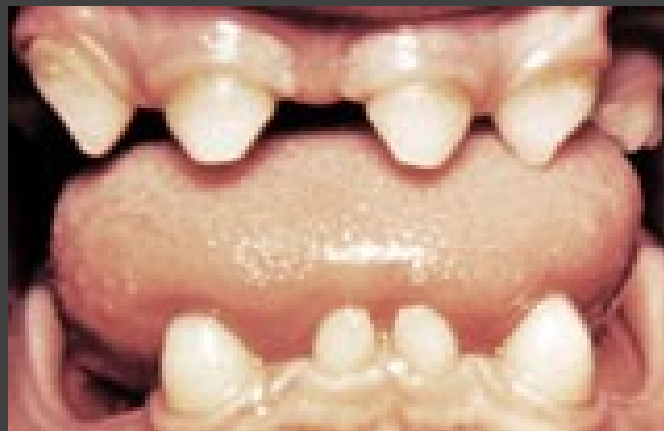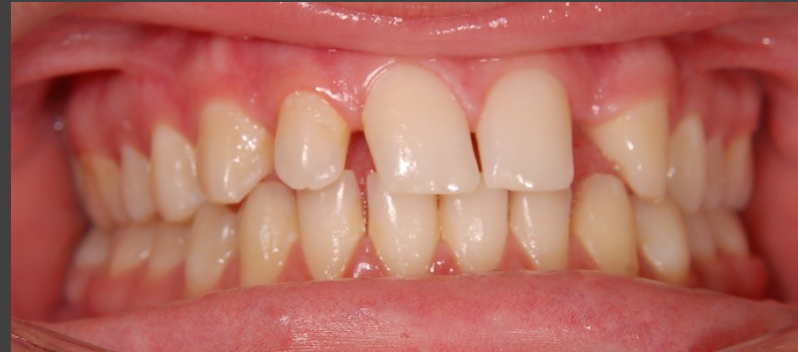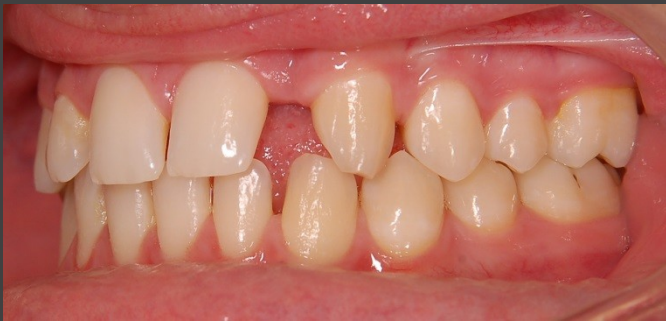Etiology of orthodontic anomalies

Mainly hereditary anomalies – primary crowding



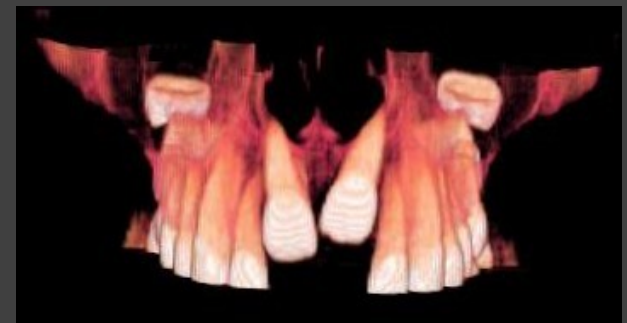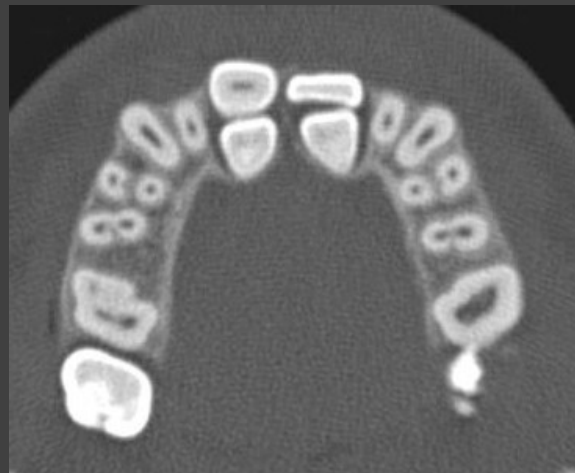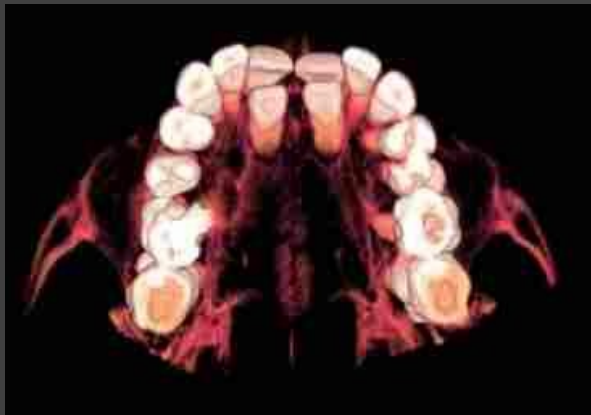
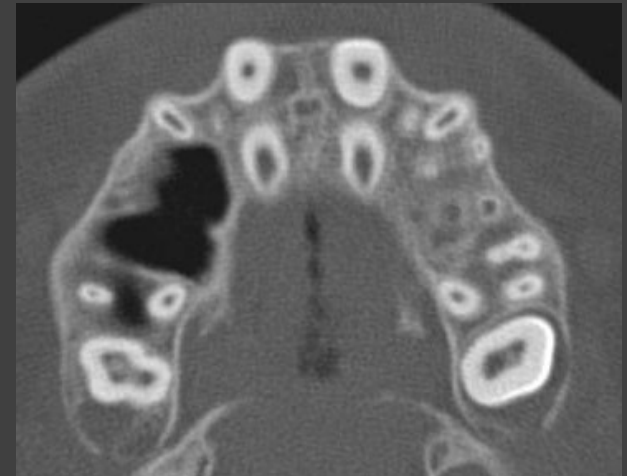
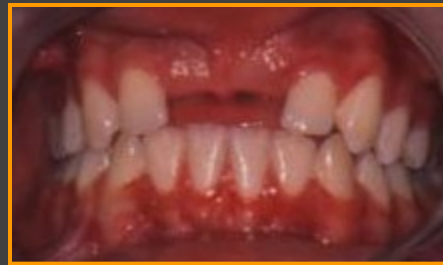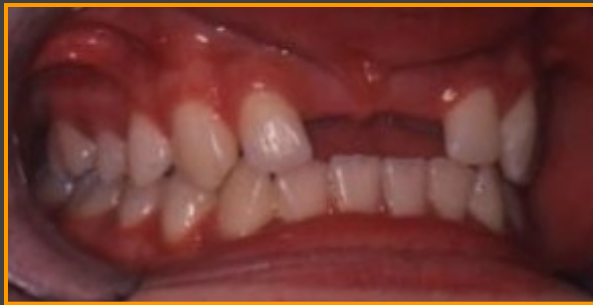Etiology of orthodontic anomalies

Mainly hereditary anomalies- hypodontia



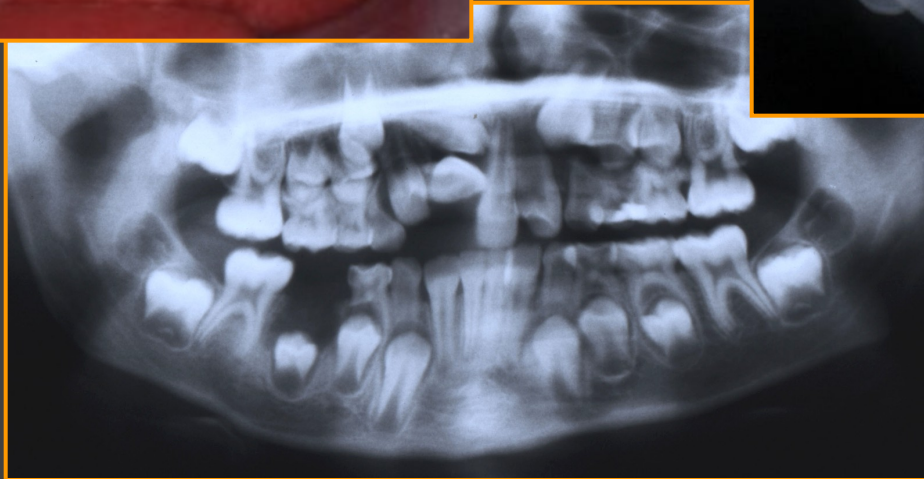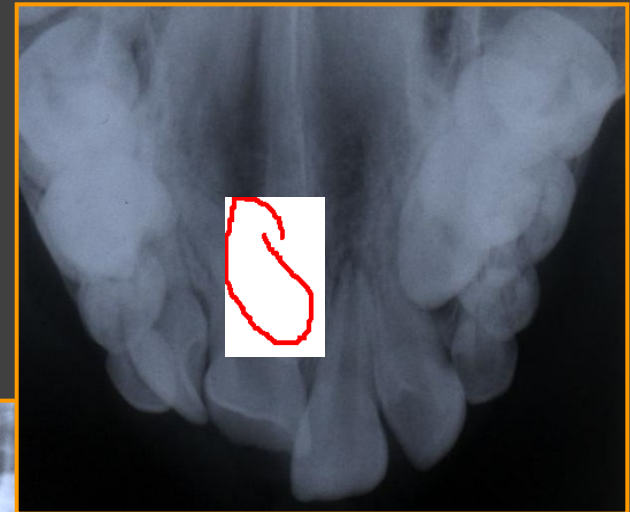
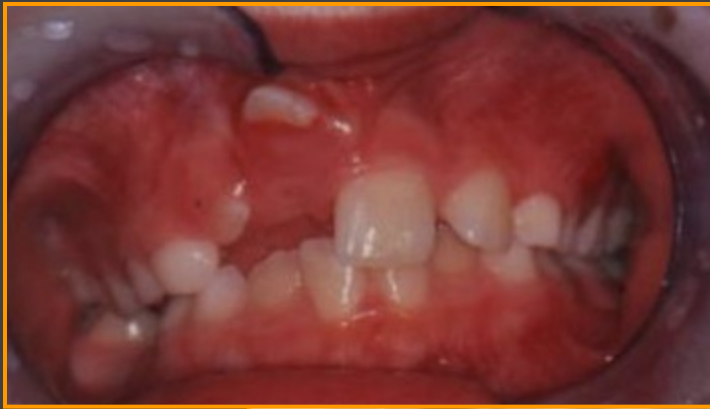Etiology of orthodontic anomalies

Mainly hereditary anomalies- hyperodontia



Etiology of orthodontic anomalies

hyperodontia



Etiology of orthodontic anomalies

2. Prenatal factors

A.- teratogens

influence of physical, chemical and infectional effects during gravidity-
if acting in critical time



Etiology of orthodontic anomalies

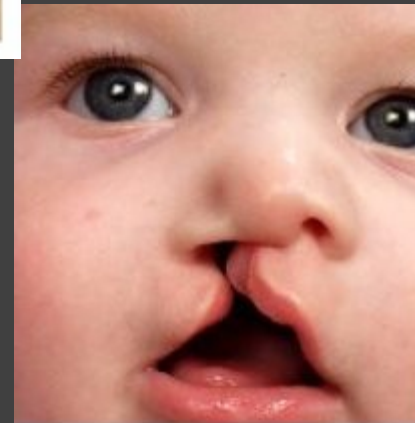
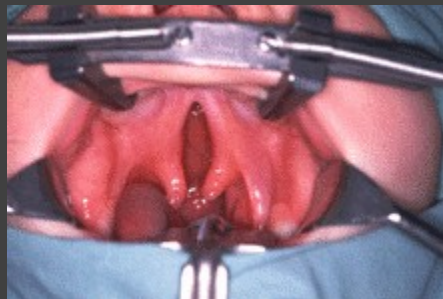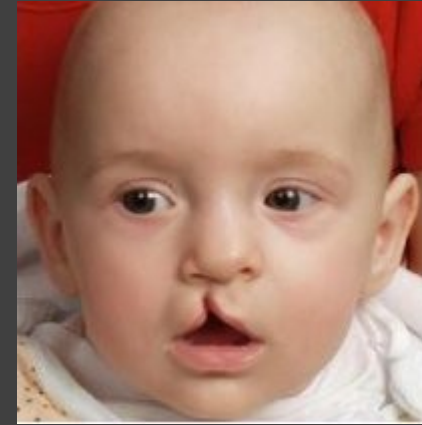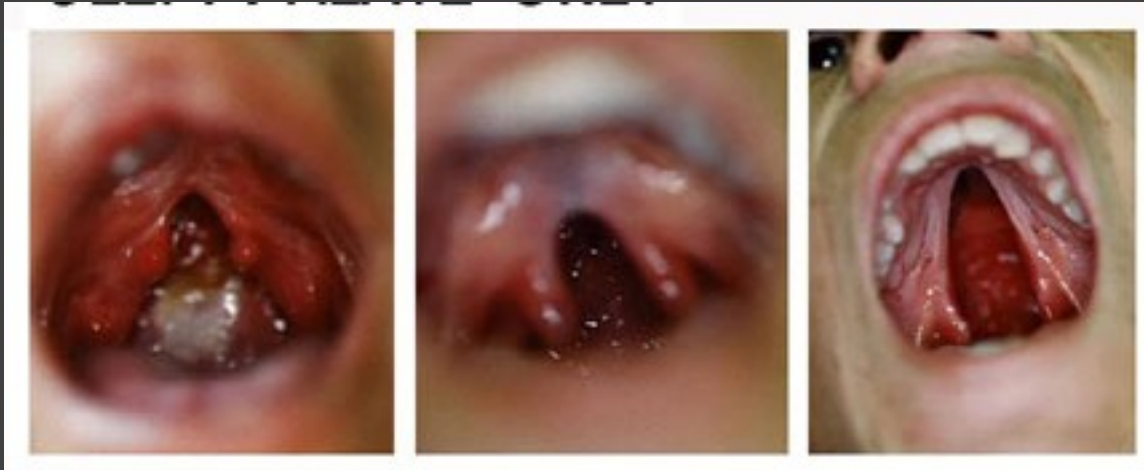
A.- teratogens affecting dentofacial development

Teratogens	Effect
Aspirin, Valium	cleft lip and palate
Cigarette smoke[hypoxia]	cleft lip and palate
Cytomegalovirus	microcephaly, hydrocephaly
Ethyl alcohol	central mid-face deficiency
6-Mercaptopurin	cleft palate
Rubella virus	microftalmia, cataracts
Thalidomide	hemifacial microsomia
Toxoplasma	microcephaly, Hydrocephaly
X-radiation	microcephaly
Vitamin D excess	premature suture closure



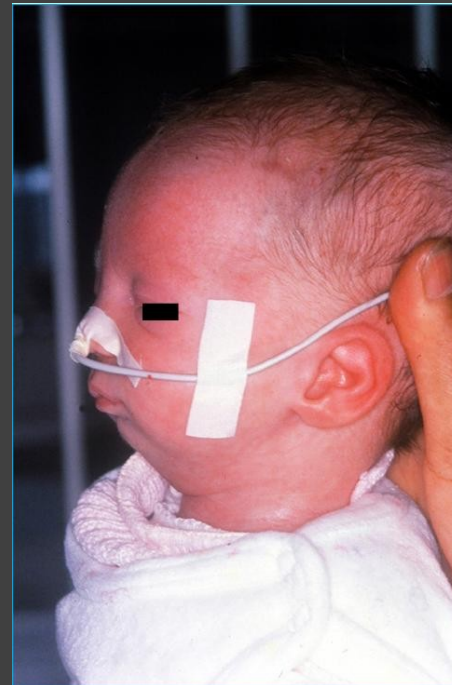
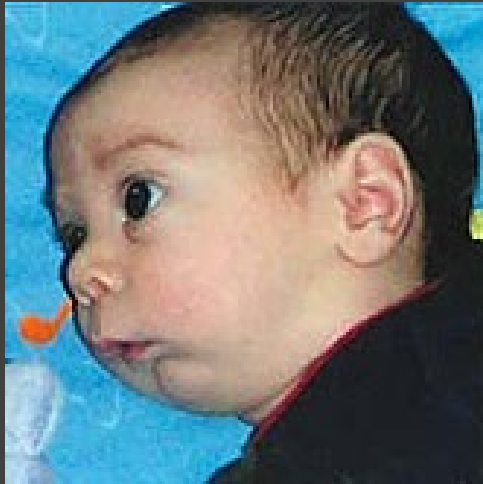Etiology of orthodontic anomalies

Clefts lip and palt



Etiology of orthodontic anomalies

Syndromes – Pierre Robin syndrome



Etiology of orthodontic anomalies

3. Postnatal influences

- Trauma – undiagnosed fractures of the mandibular condyles can cause disorders of the growth of the mandibular ramus =asymmetry
- Hormonal disorders – growth hormone deficiency, thyroid hormone deficiency – can contribute to the origin of acquired anomalies



Orthodontic treatment

Objectives of orthodontic treatment

Aesthetics

Treatment of impacted teeth

Prevention of dental injuries

Before prosthetic treatment

Decay prevention

Prevention and treatment of chewing malfunction and jaw joint disorders



Methods of orthodontic treatment

Orthodontics movement of teeth

Orthopedic movement – effects of growth

Myofunctional therapy

Serial extraction, controlled extraction

Ortho – prosthetic treatment

Ortho – surgical treatment



Orthodontic treatment

1. Orthodontic treatment by infants

- clefts
- syndromes and defects that complicate nutrition and breathing

We use - individual removable plates



Orthodontic treatment

2. Deciduous teeth

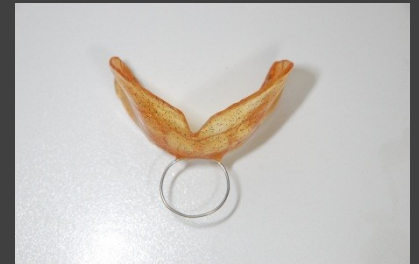We treat - bite defects

inverted bite

cross bite

- bad habits

We use – removable appliances



Orthodontic treatment

3. 6-9 years [1. phase of mixed dentition]

The best time for treatment :

- cross bite
- inverted bite
- impacted incisors
- diastema more than 3 mm
- big primary crowding

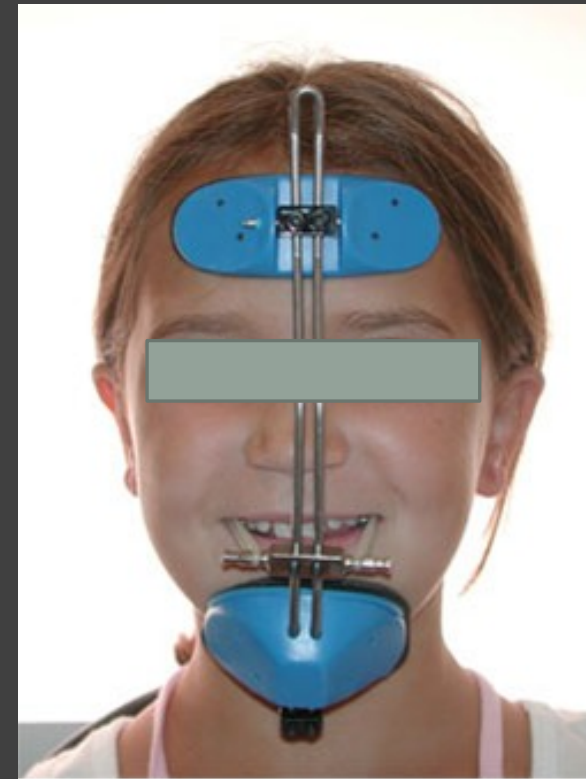
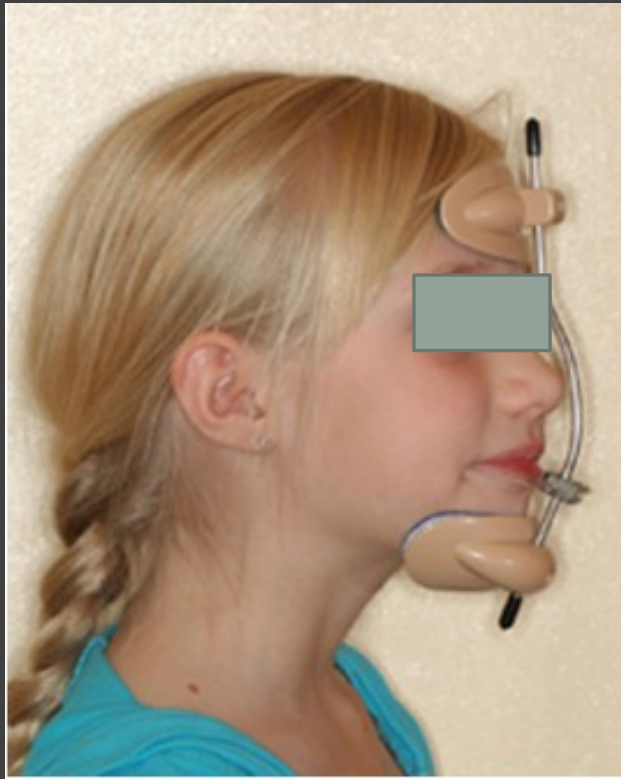
We use : removable appliances

small fixed appliances

face mask for inverted bite by class III



Face mask



Orthodontic treatment

4. 9-12 year [second phase of mixed dentition]

- Large forming ability of the tissues
- We can use and influence the growth
- Growth mandible from the joints

We treat: - previous untreated anomalies

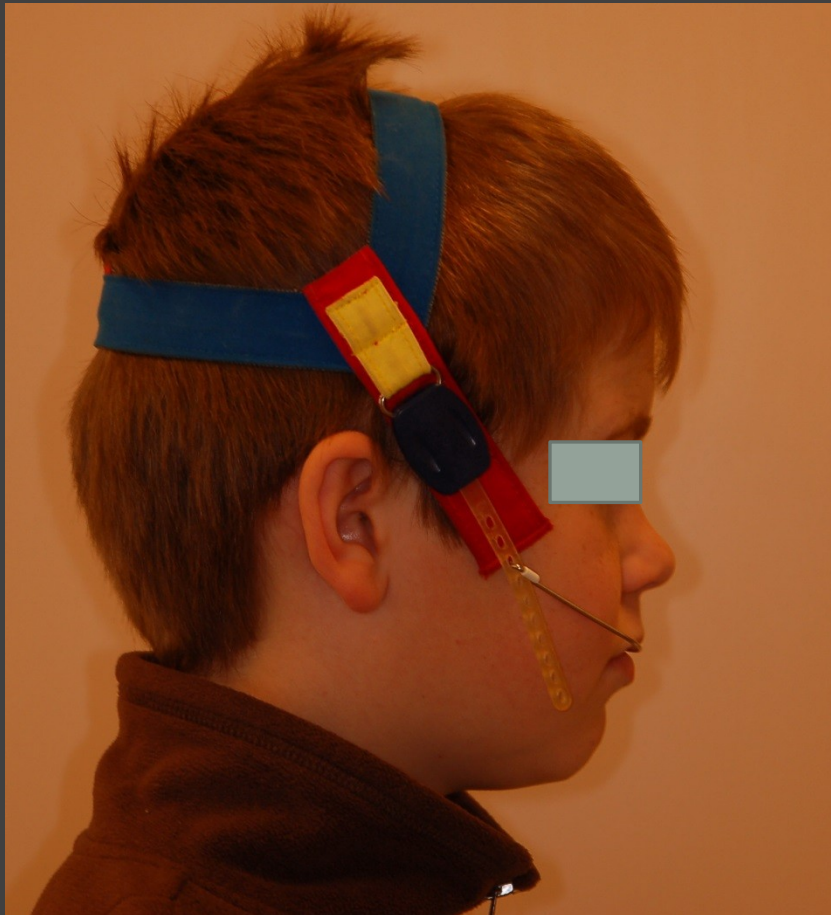
- crowding
- Angle class II – div. 1 and 2
- overjet more than 5 mm
- deep bite
- movements teeth after the early loss of teeth and anodontia
- Controlled tooth eruption
- Suspected retention of canines, premolars

The **best time for functional appliances**

- removable appliances
- Small fixed appliances
- Headgear appliance



headgear



Orthodontic treatment

5. Permanent teeth

We treat:

- All anomalies, previous untreated anomalies,
- Angle class III
- Crowding
- Open bite, deep bite
- Impacted tooth
- Skeletal anomalies

Adult therapy – periodontics problems, preprosthetic therapy

- problems with TMJ
- bruxism

We use : fixed appliances

extraction

surgical treatment by big skeletal anomalies



Othodontic treatment

Removable appliances:

1. Active
2. Passive
3. Functional



Therapy of ortodontical anomalies

Conservativ

orthodontical appliances :

removable

fixed

Surgical

extraction of teeth

surgical expositions of crowns of retined tooth

surgical movements of maxila, mandible

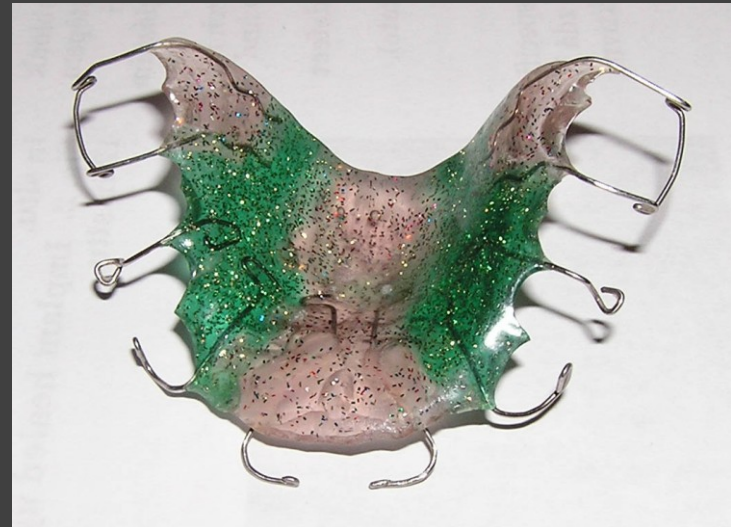

Active removable appliances

- Treatment of anomalous position of teeth [inclination, rotation of incisors]
- Treatment the dental arch shape
- Individual resin plates
- Active elements : springs, screws, wire bows



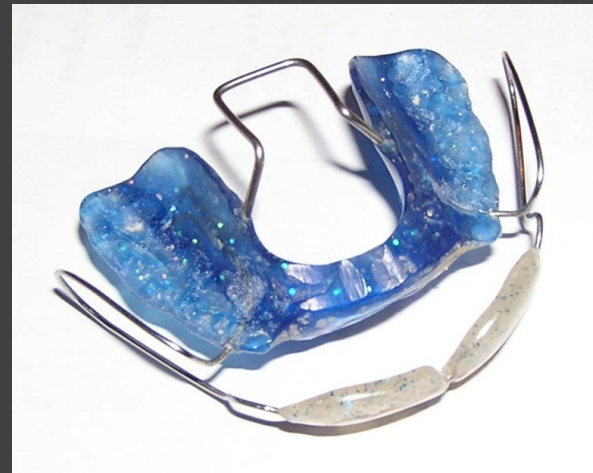
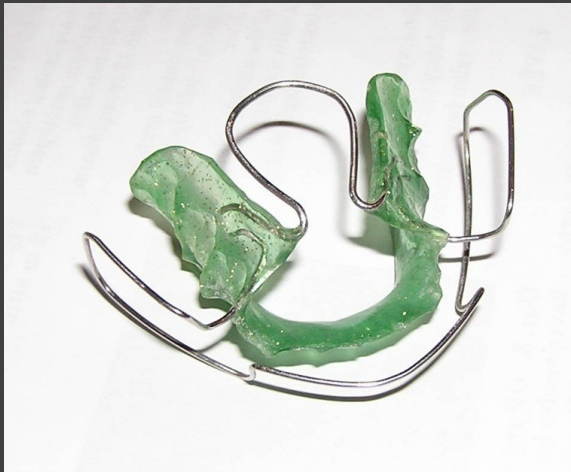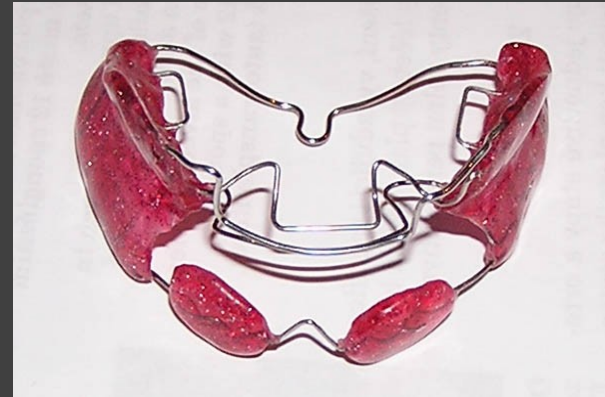Removable active appliances



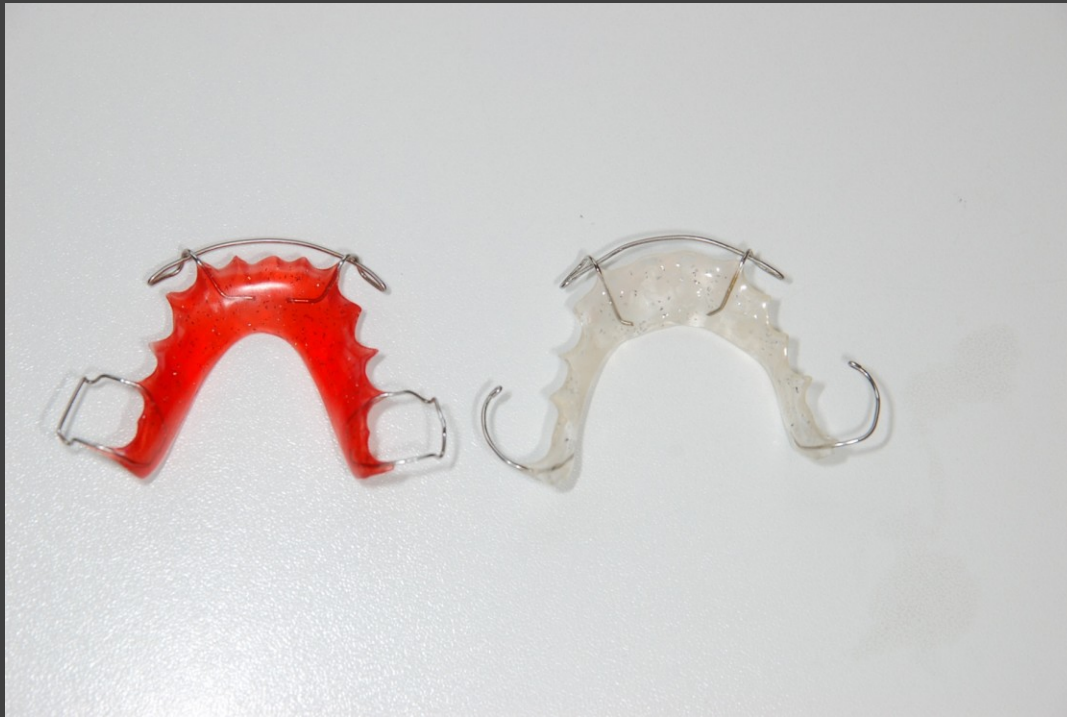Removable appliances - active



Removable functional appliances

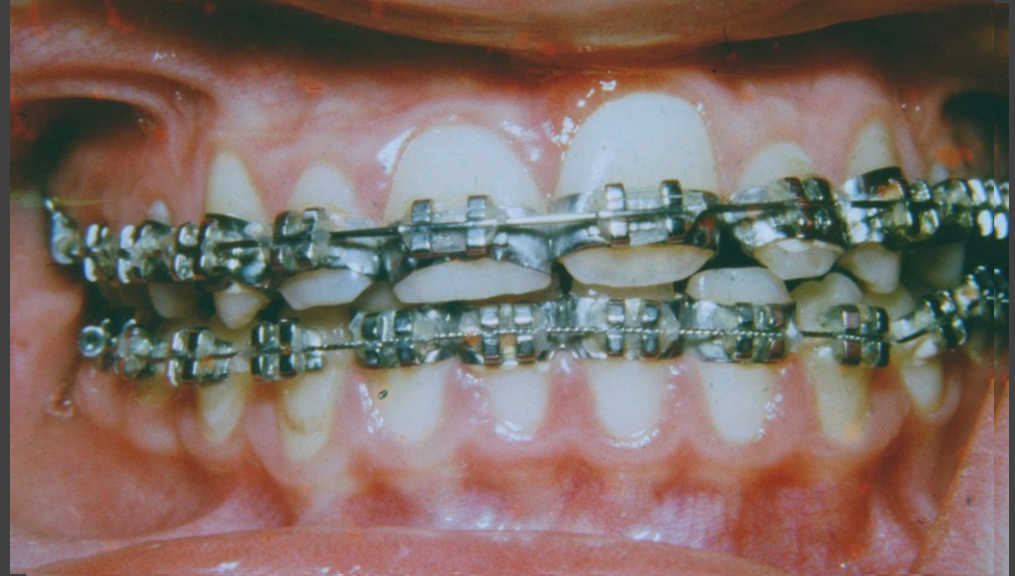
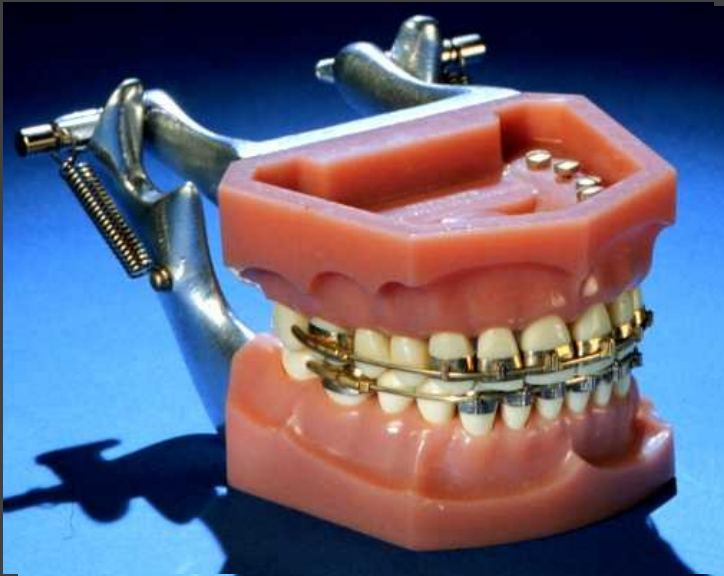

Removable appliances- passive



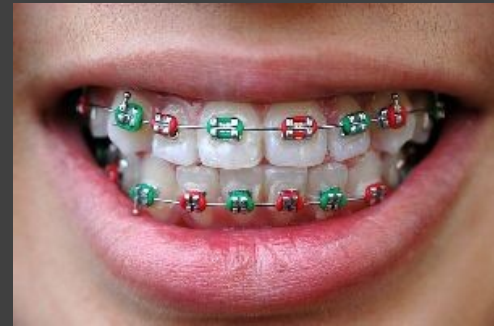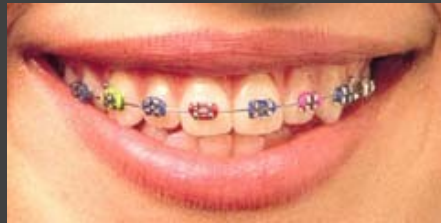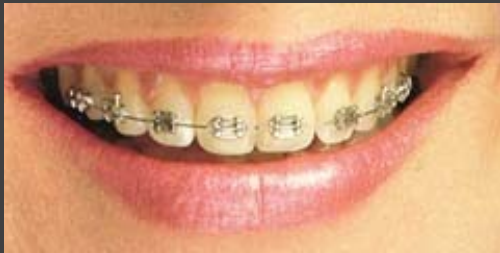Fixed appliances

-History



Orthodontics brackets

Stainless steel brackets



Advantages

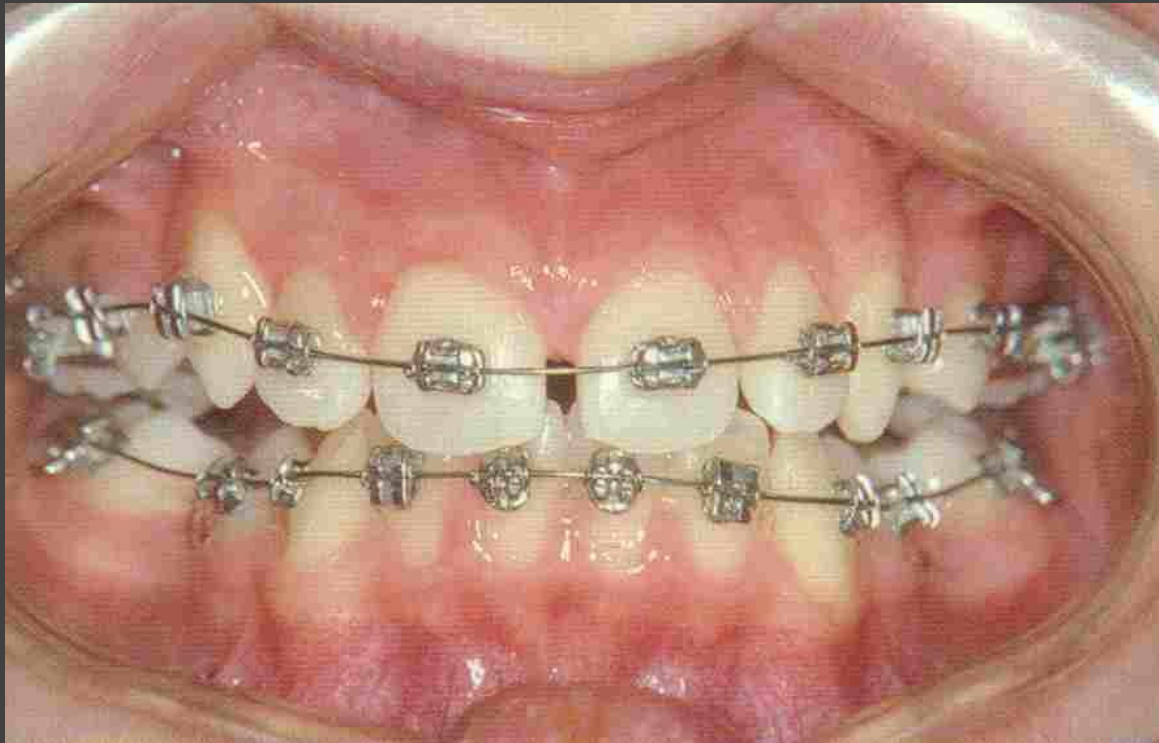- strong, do not crack
- smooth, low profile
- recyclable
- low friction
- price

Disadvantages:

- Aesthetic

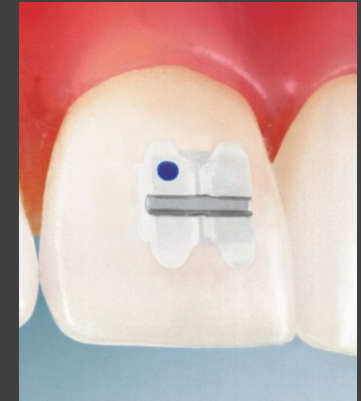
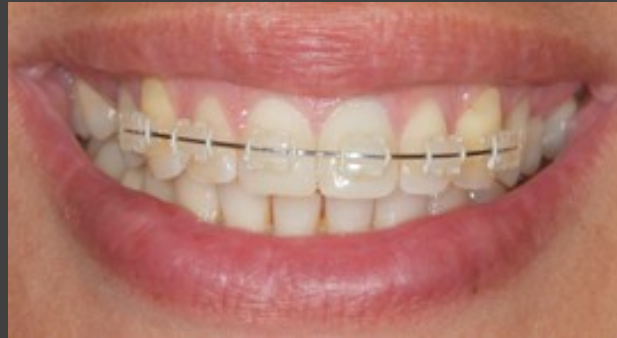
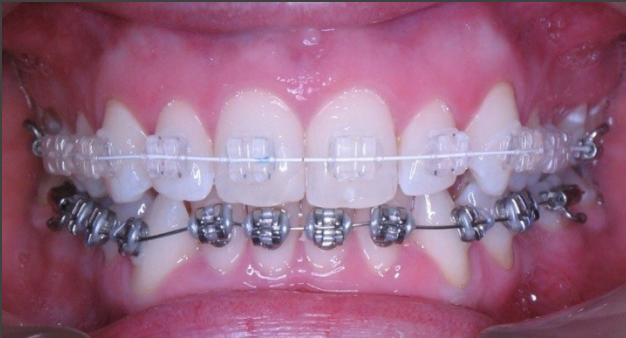
Stainless steel brackets



Orthodontics brackets

Ceramic brackets



Advantages:

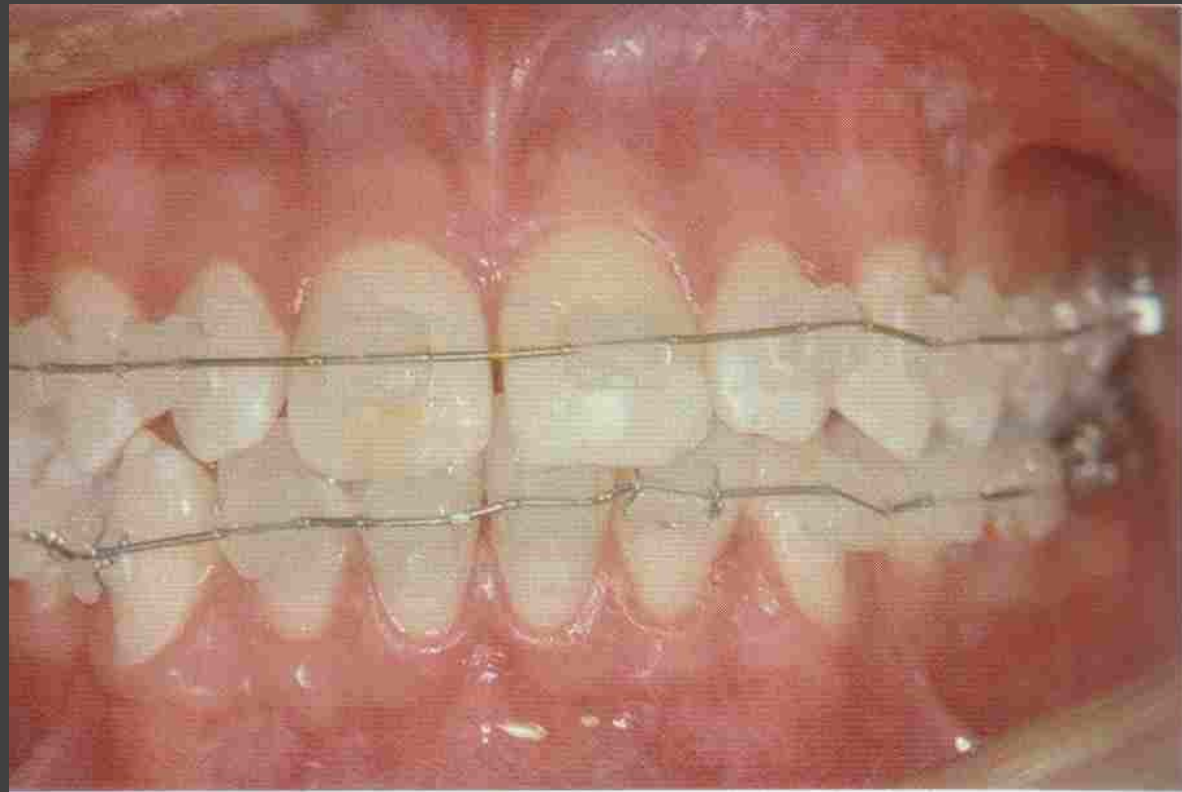- Aesthetics

Disadvantages:

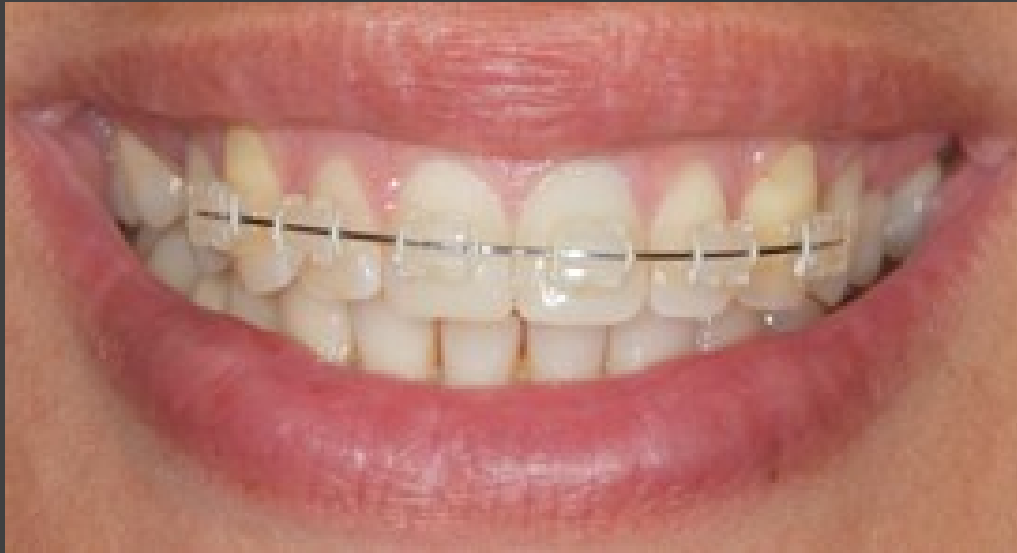- repeated bonding problem
- robust
- crack
- higher friction (avoid metal slot)
- price



Ceramic brackets

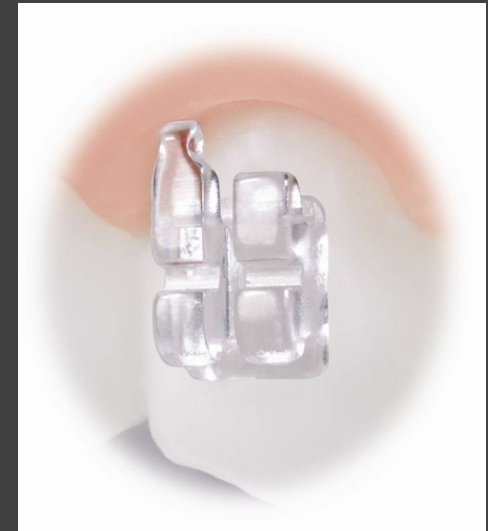
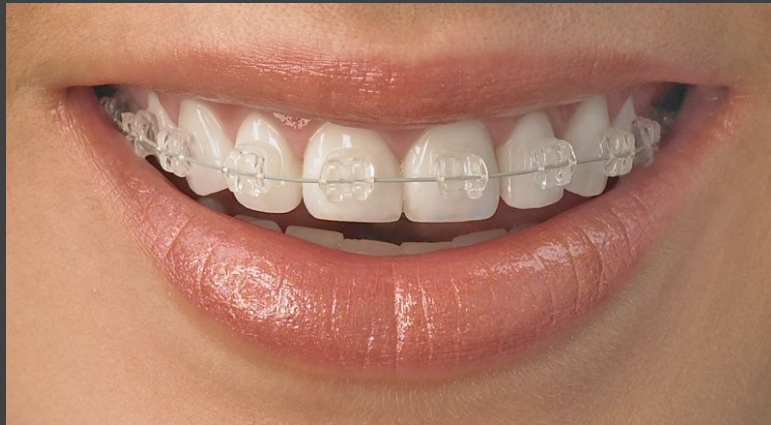

Ceramic brackets



Orthodontics brackets

Sapphire brackets



Advantages

- aesthetic

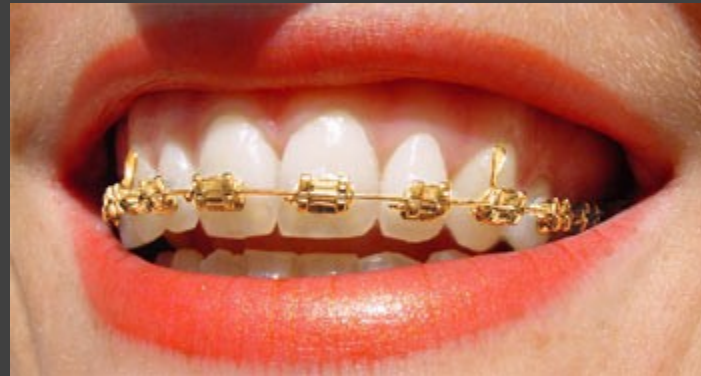
Disadvantages:

- repeated bonding problem
- robust
- crack
- higher friction (avoid metal slot)
- price



Orthodontics brackets

Gold-coated brackets



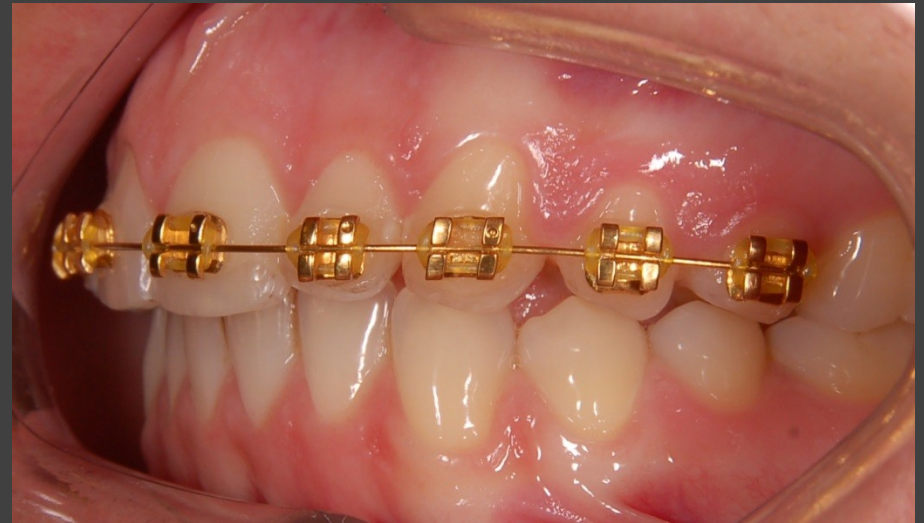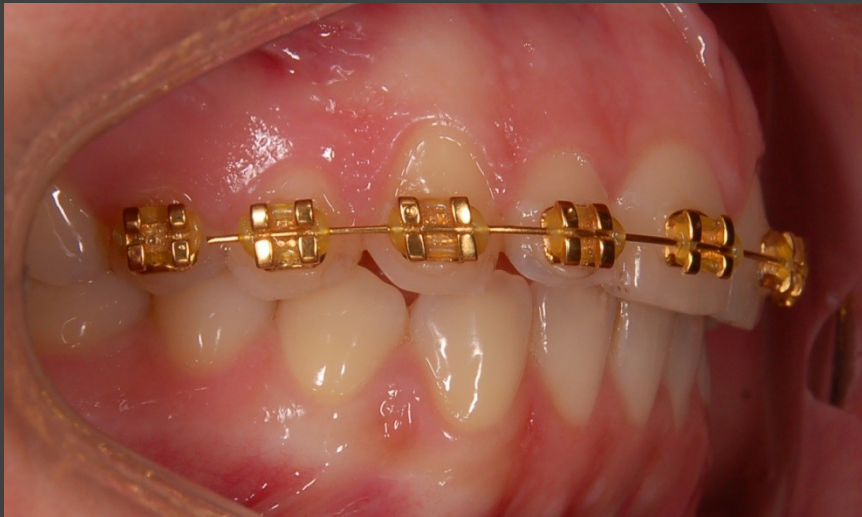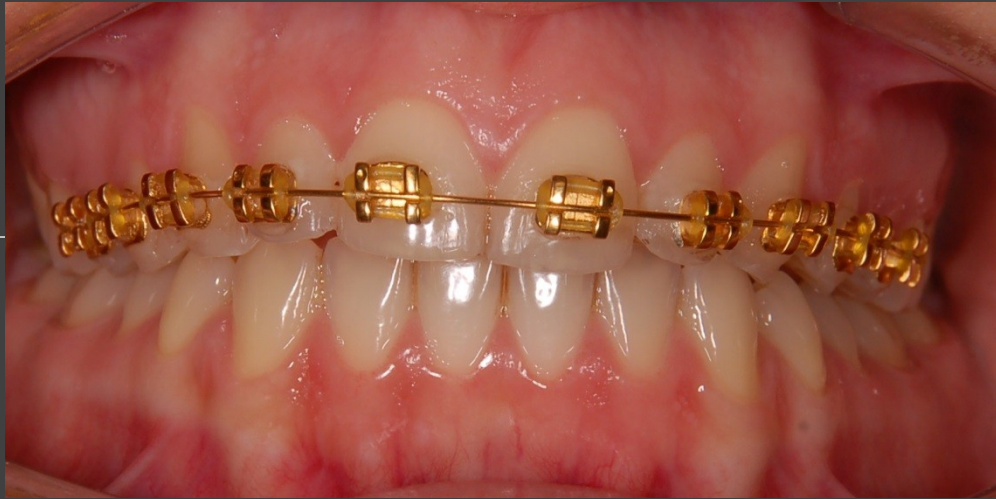Advantages:

- suitable for allergy sufferers
- strong, do not crack
- smooth, low profile
- recyclable
- Low friction
- Aesthetics

Disadvantages:

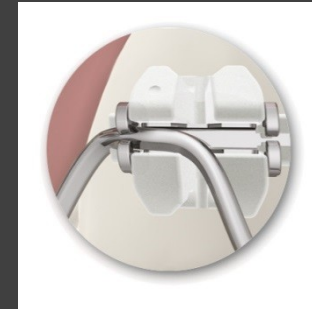
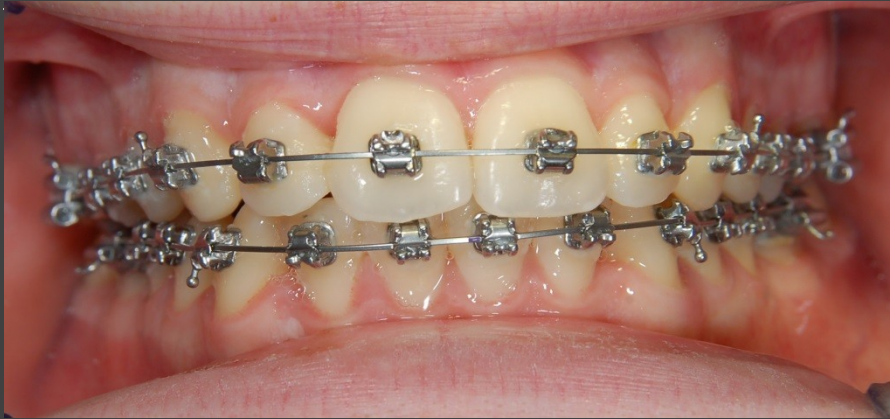- price





Orthodontics brackets

Selfligating brackets – metal and ceramic



Advantages:

- minimum friction
- low power
- faster treatment
- Fewer office visits

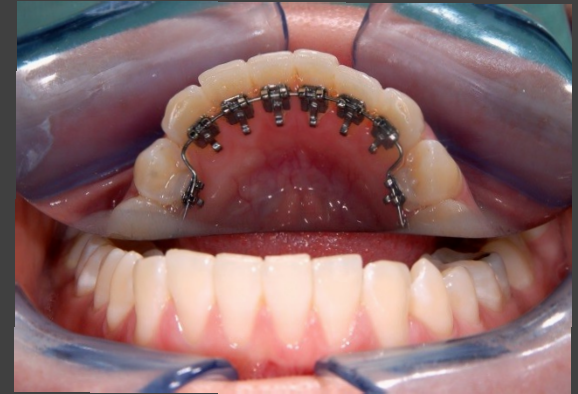
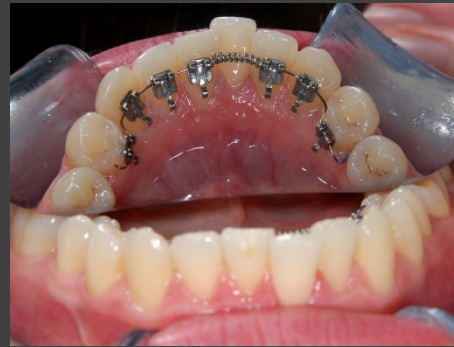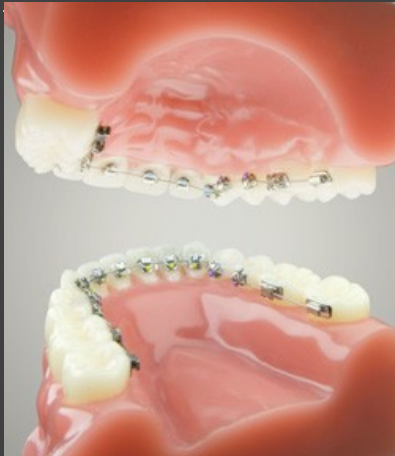Disadvantages:

- not suitable for all types of defects



Orthodontics brackets

Lingual brackets – 2D,3D



Advantages:

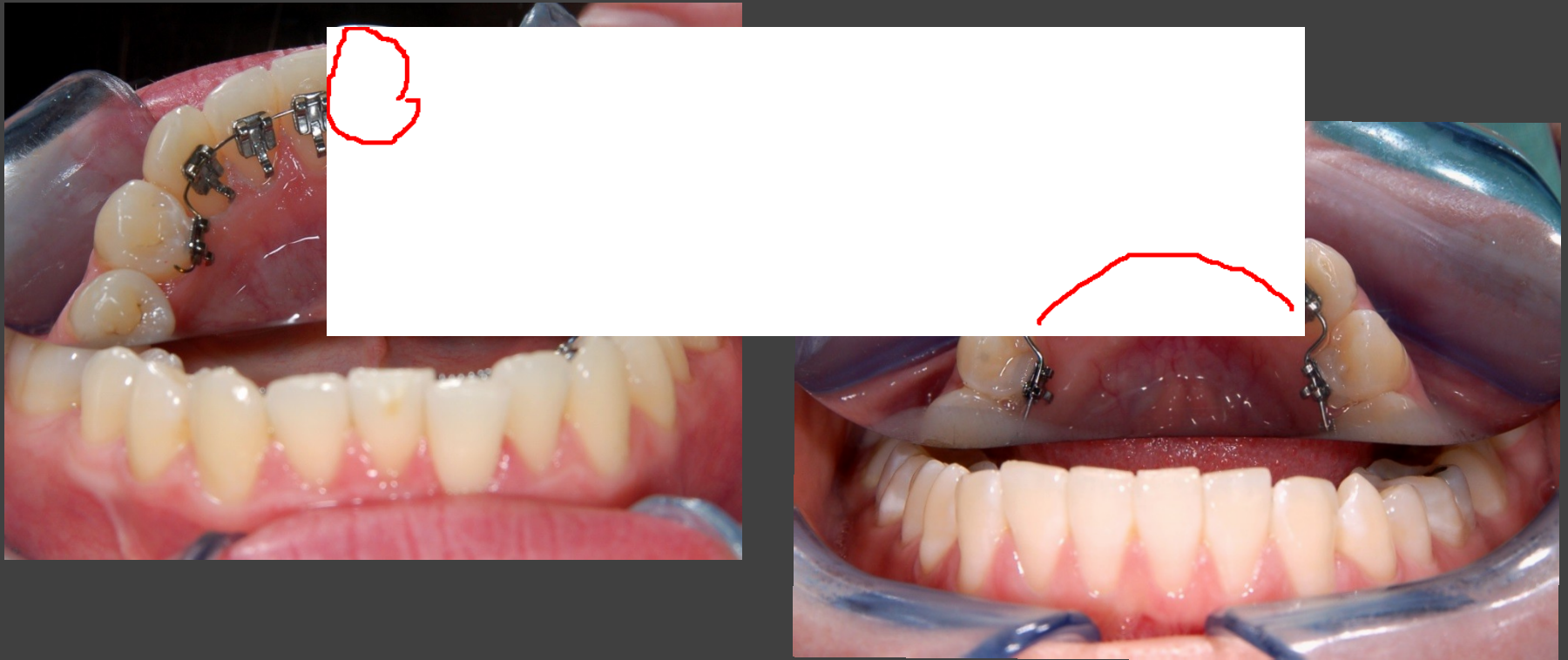- Aesthetics

Disadvantages:

- unsuitable for all types of defects
- Difficulty hygiene
- (patient discomfort)

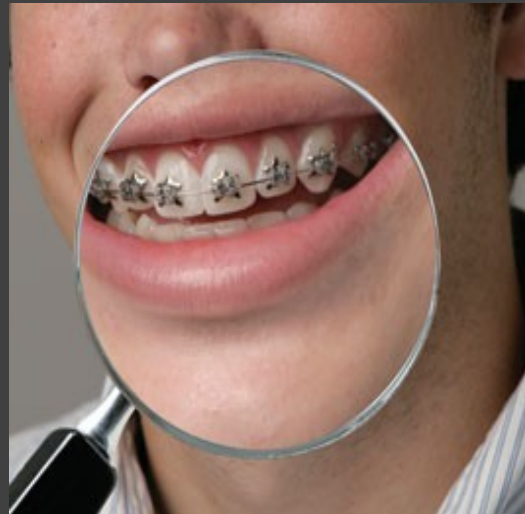

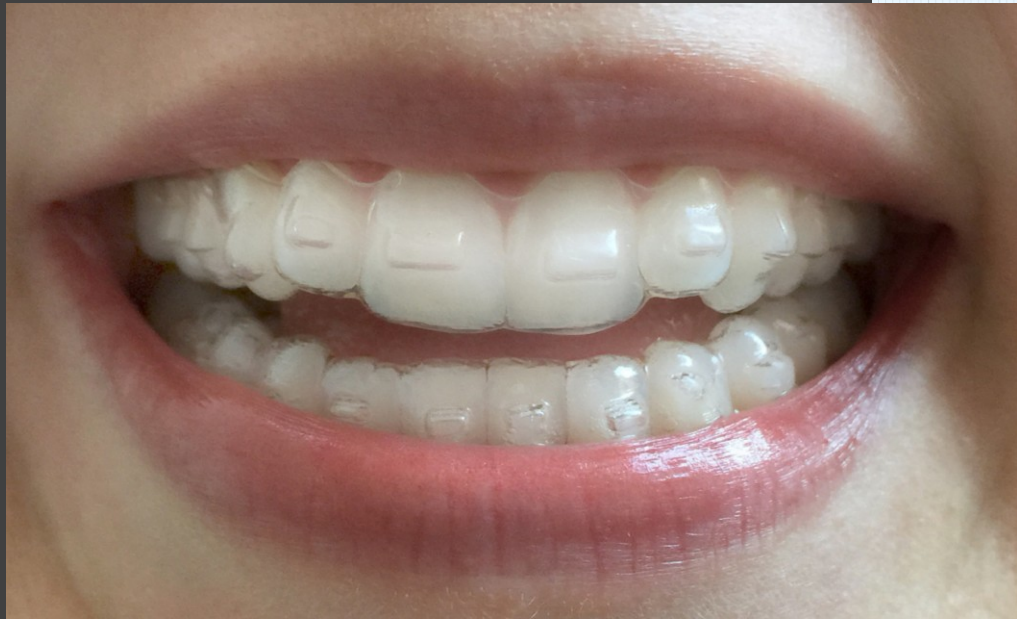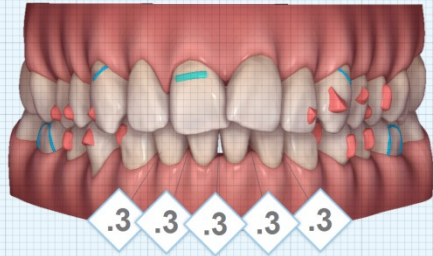

Lingual bracket



Orthodontics brackets

Decorative brackets



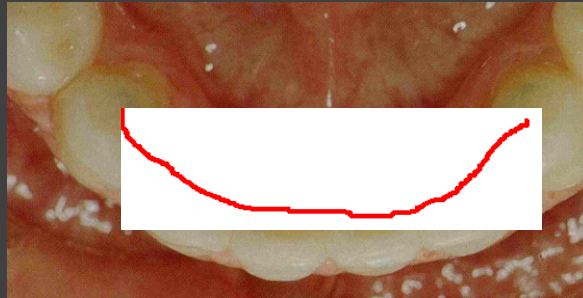


Software

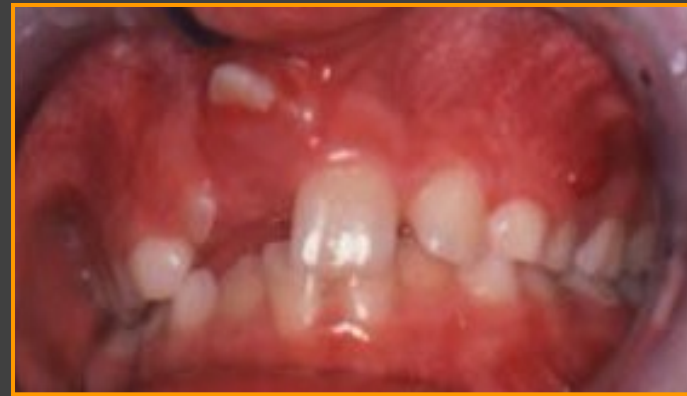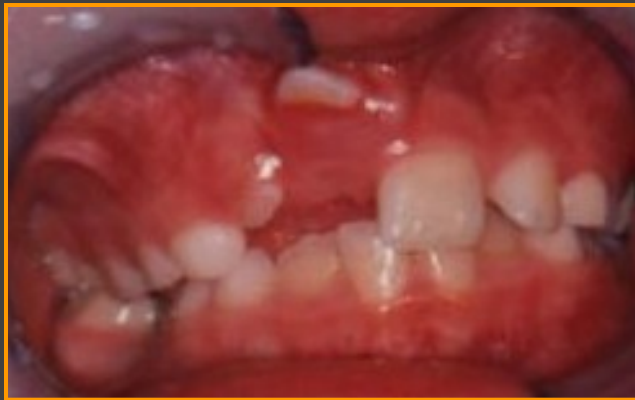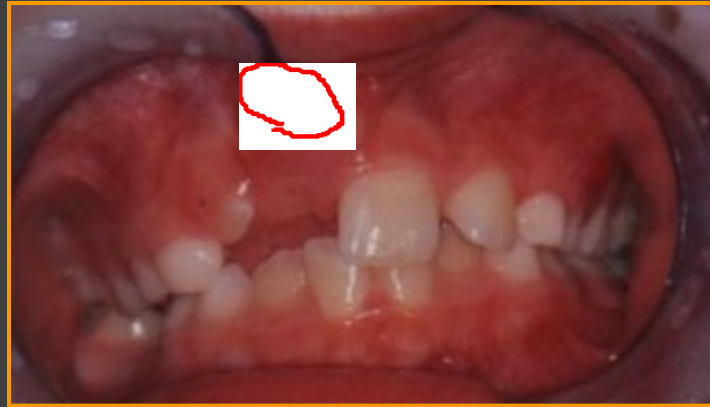movements, actual treatment results may vary.
treat and the actual treatment plan are determined by your doctor.

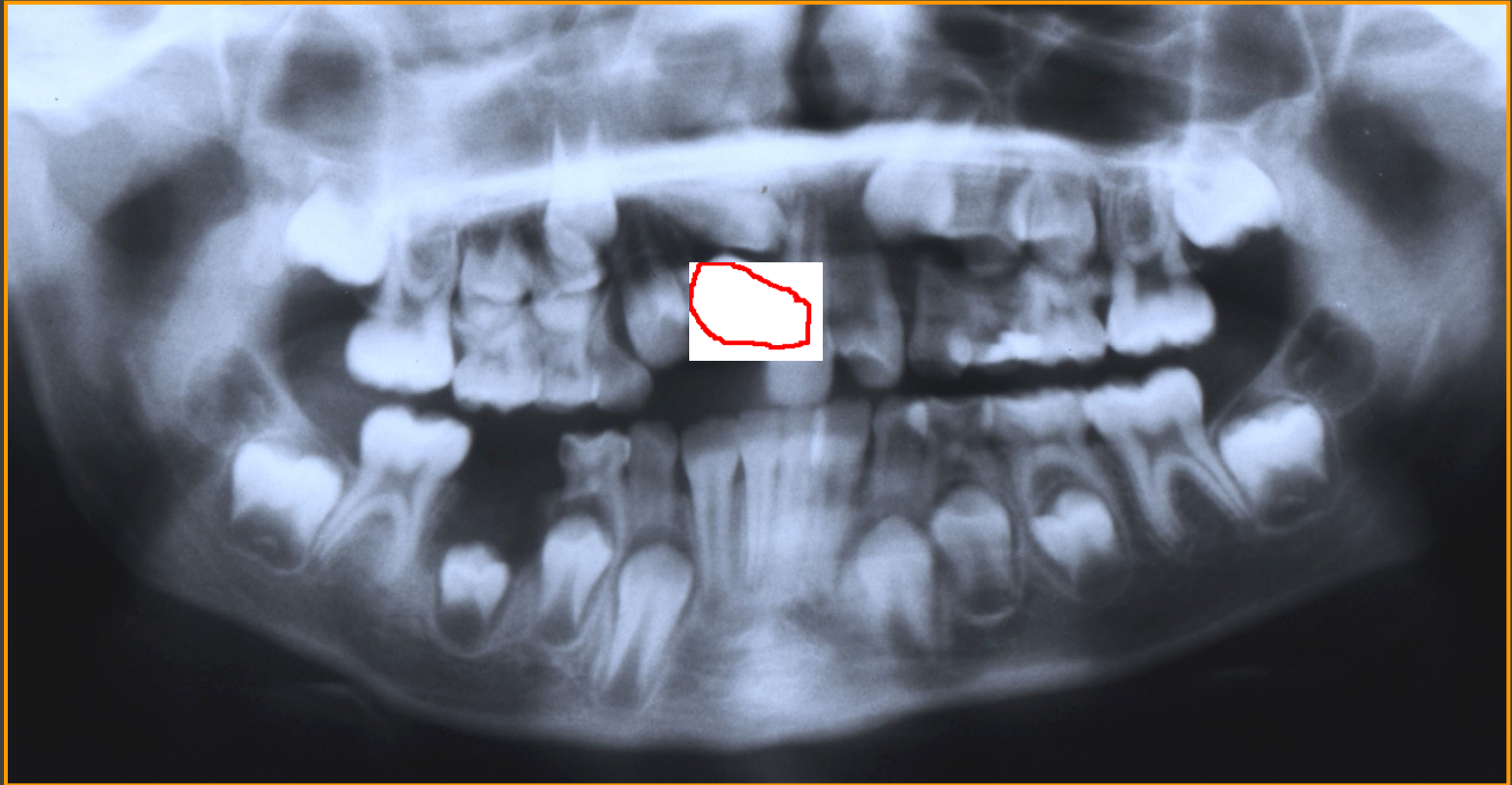


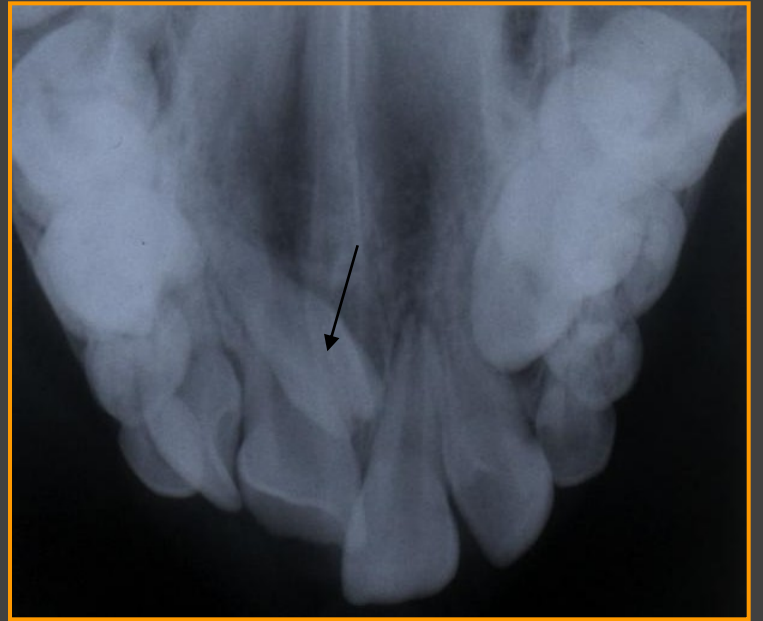
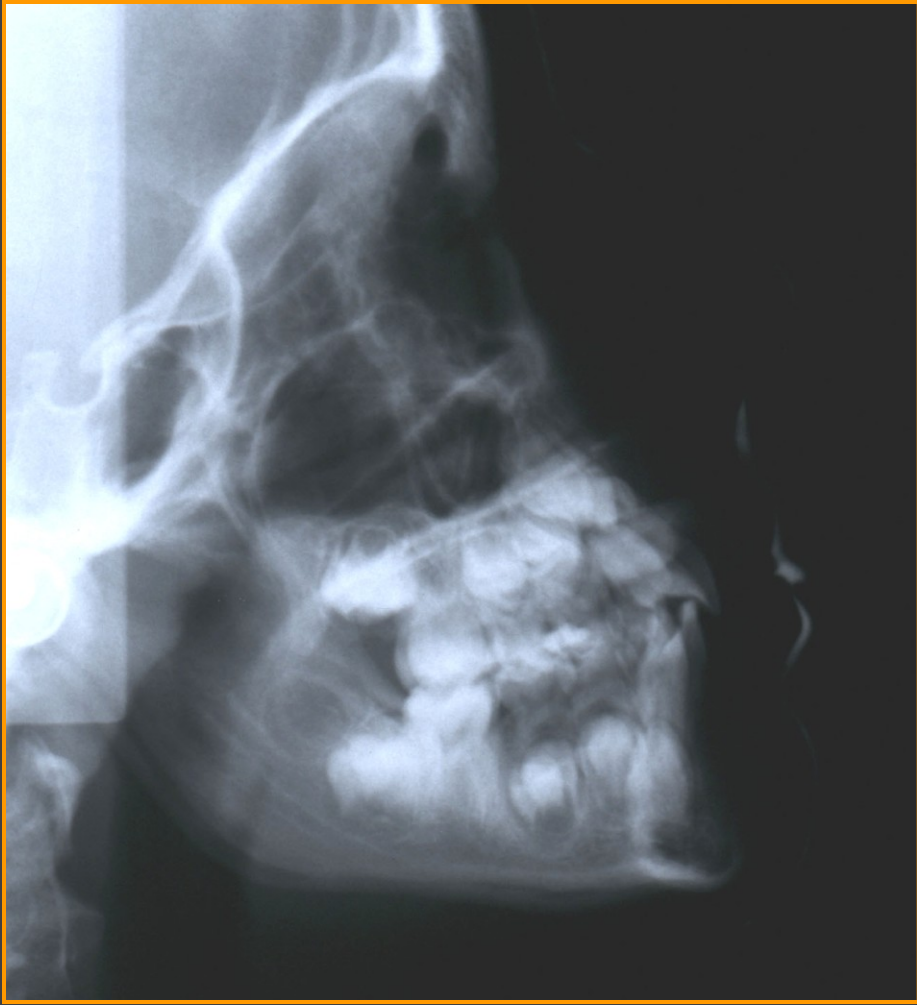Fixed lingual retainer

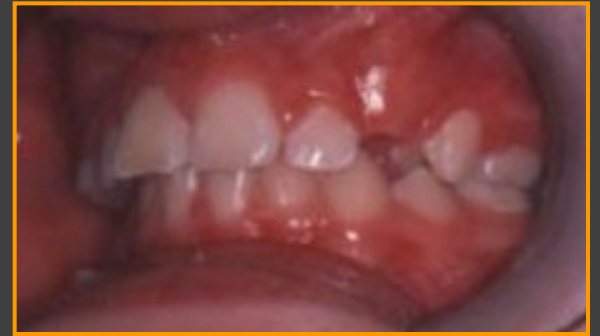
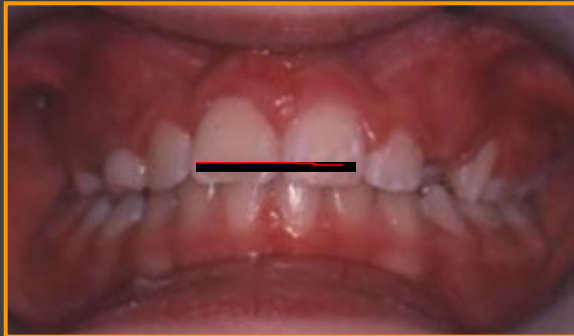
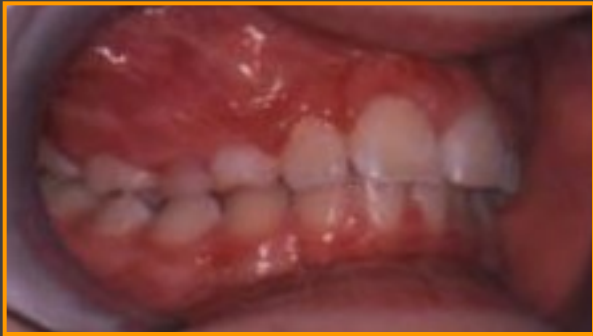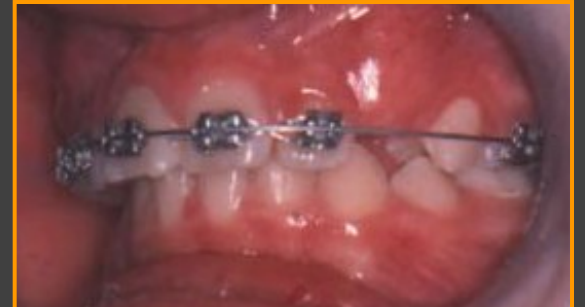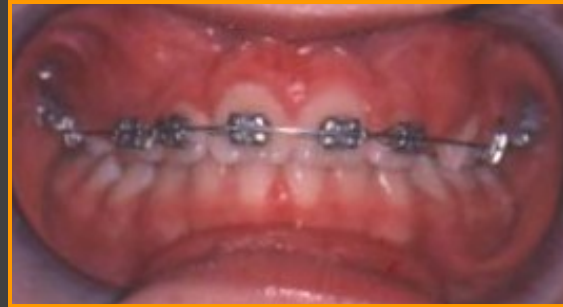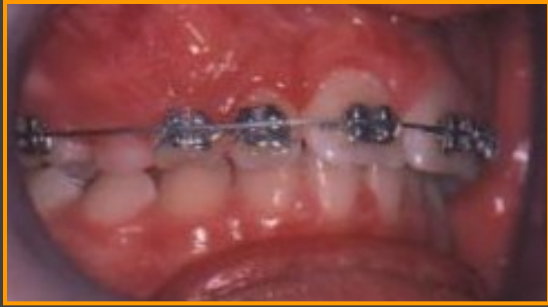Case 1 – hyperodontia - supernumerary incisor,
crowding





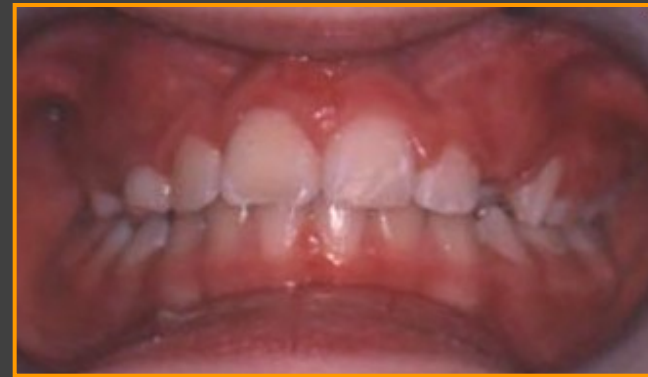
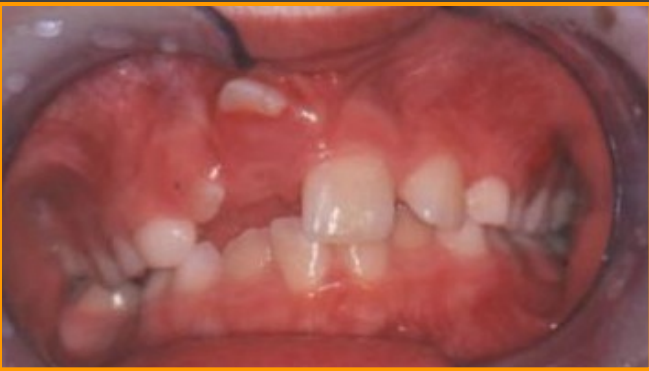


Case 1

before

after treatment

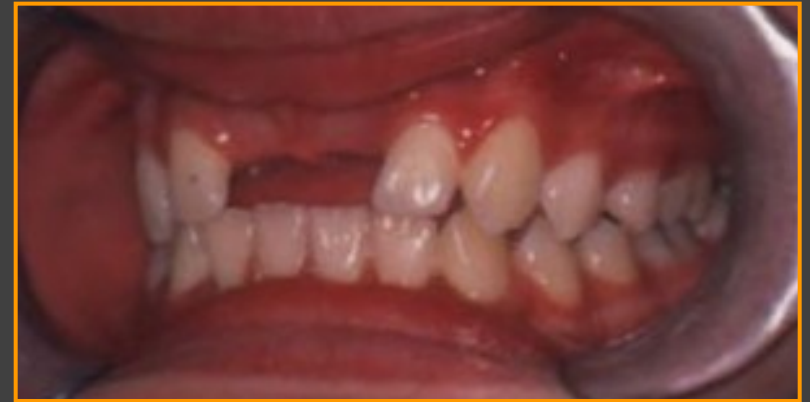
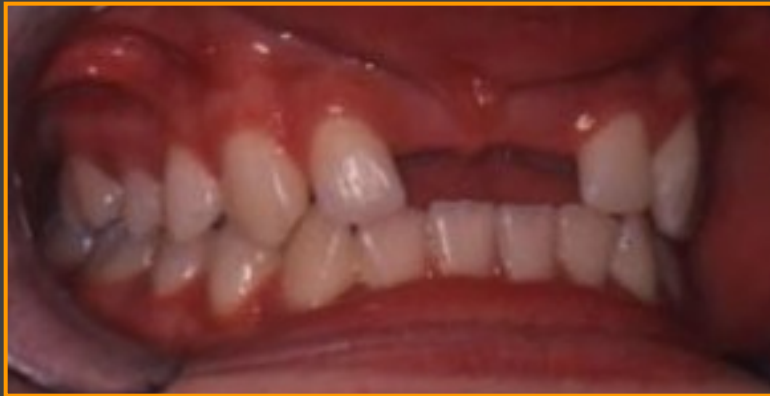
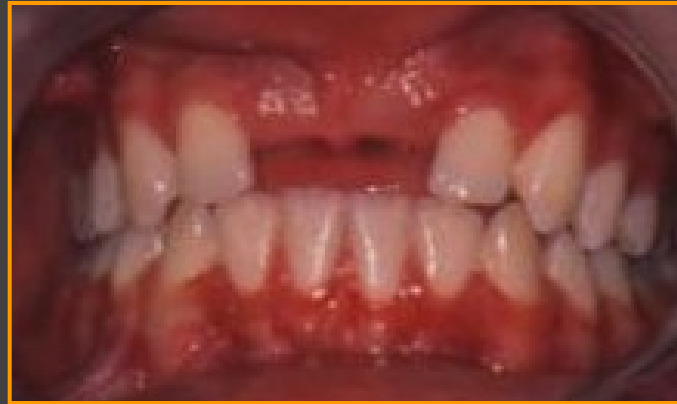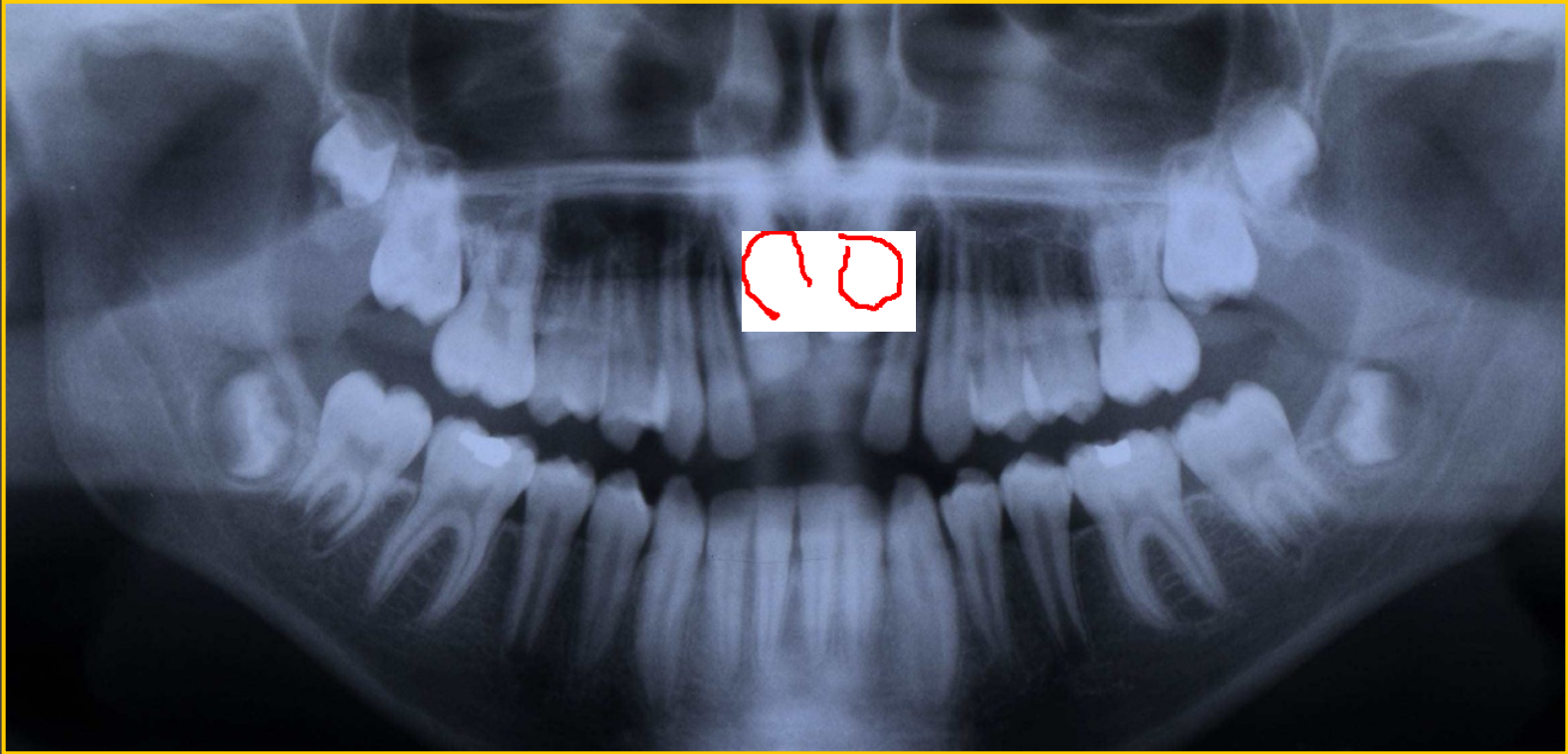
Treatment – fixed appliance – 11 months

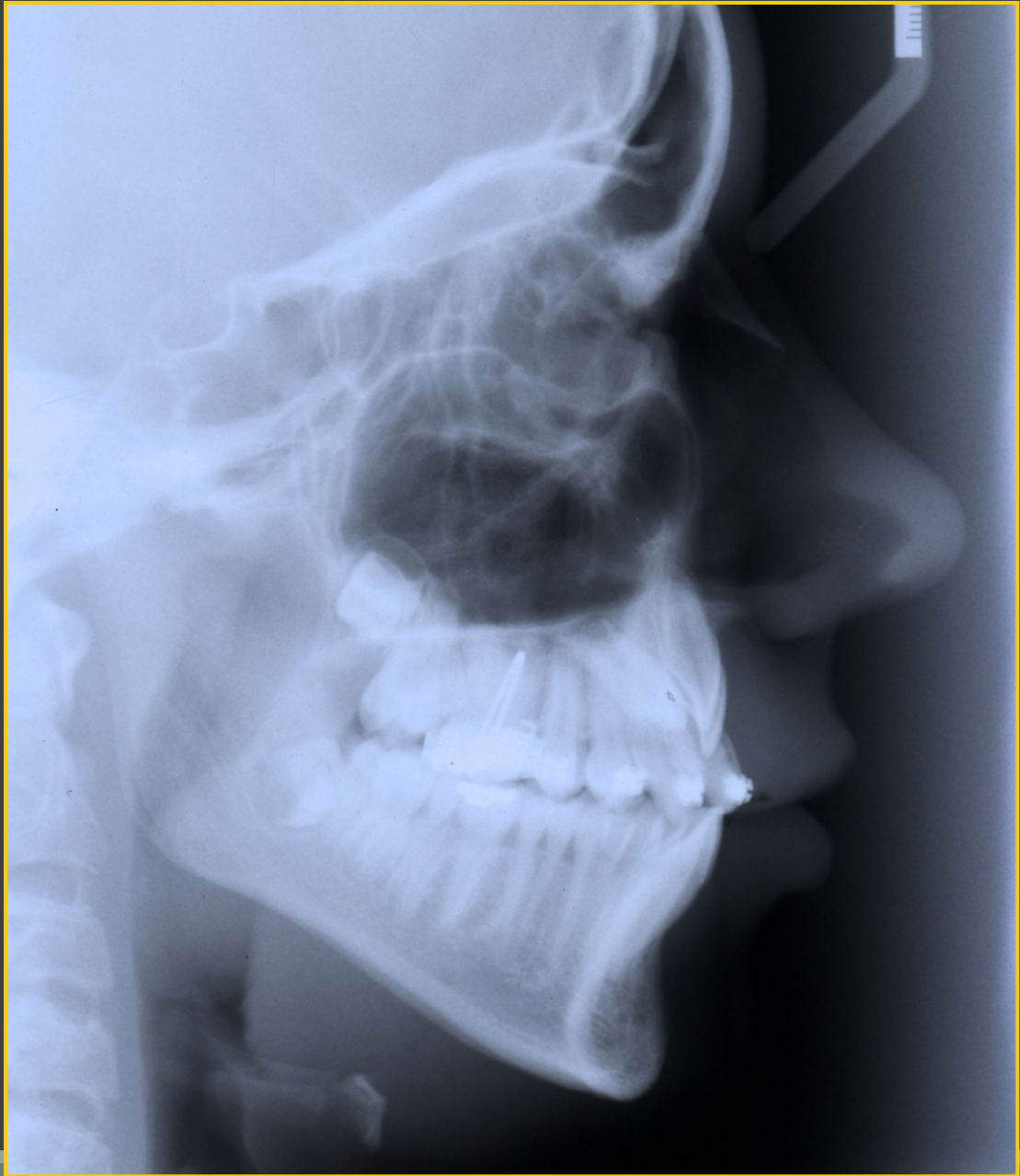Retention – removable appliance



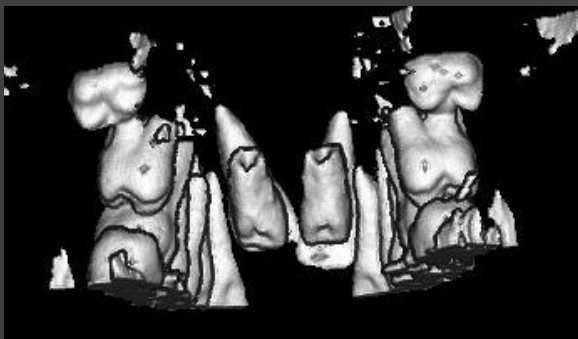
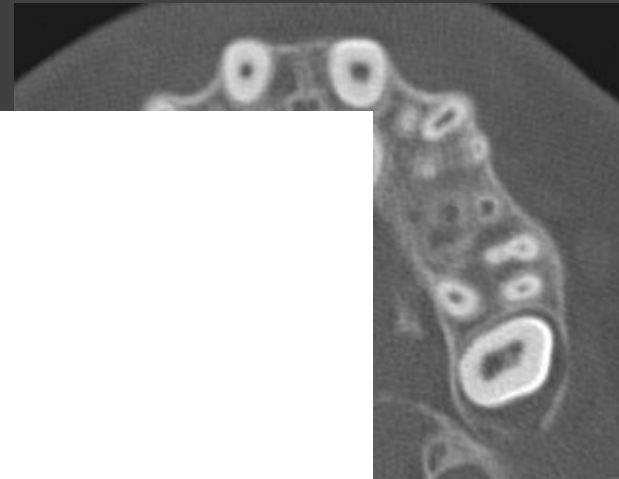
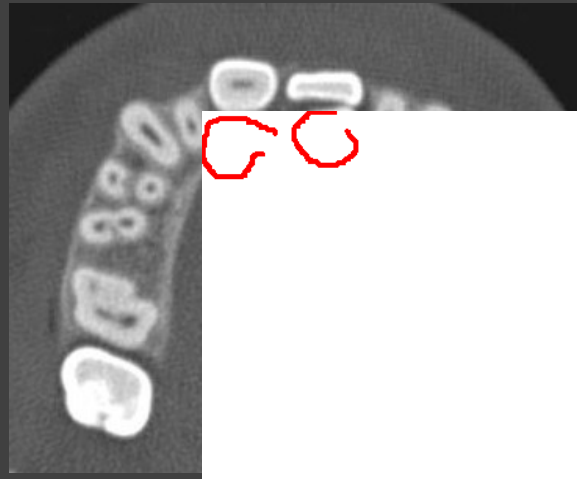
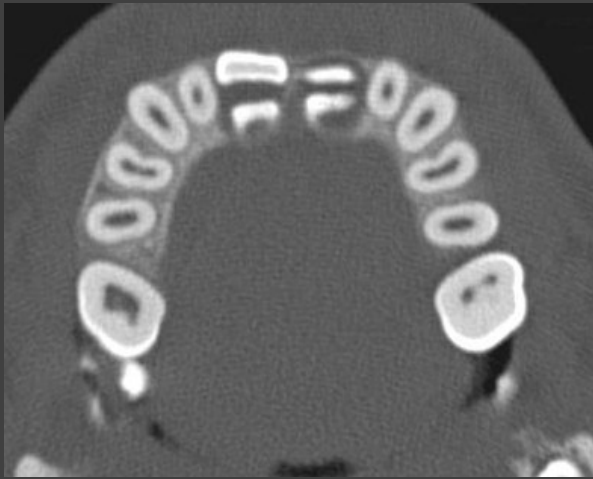
Case 2 – hyperodontia – supernumerary 2 incisors



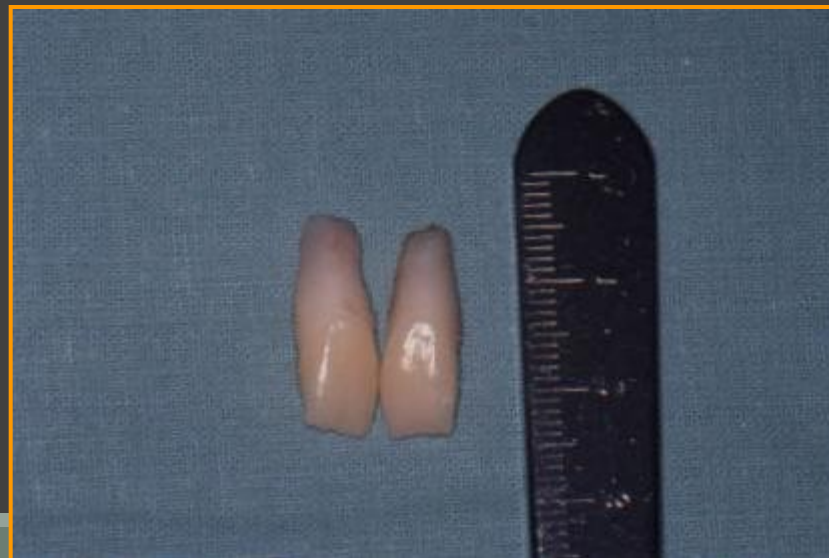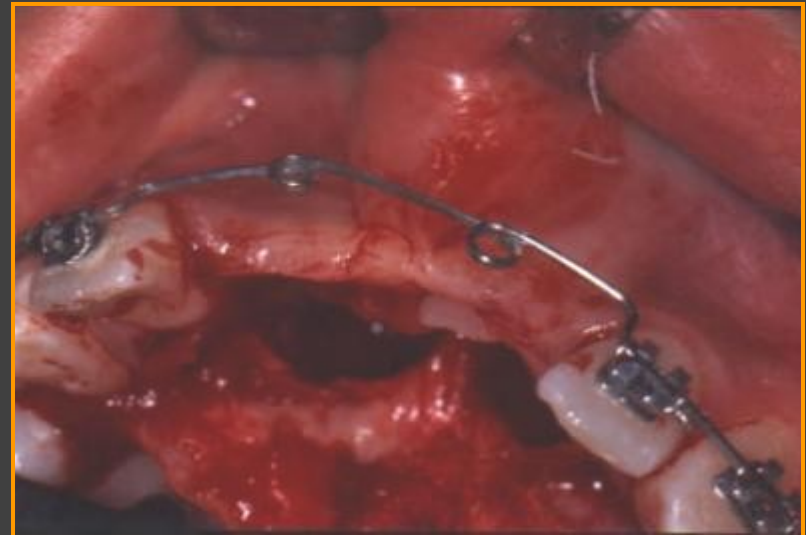
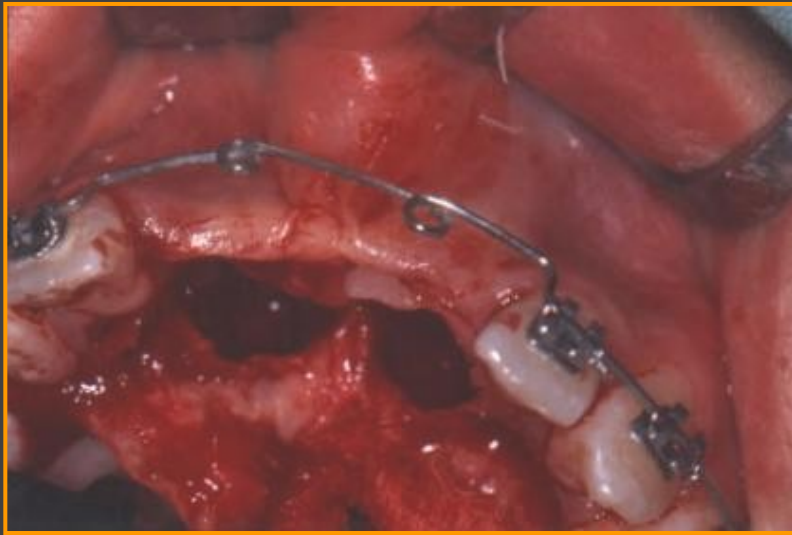



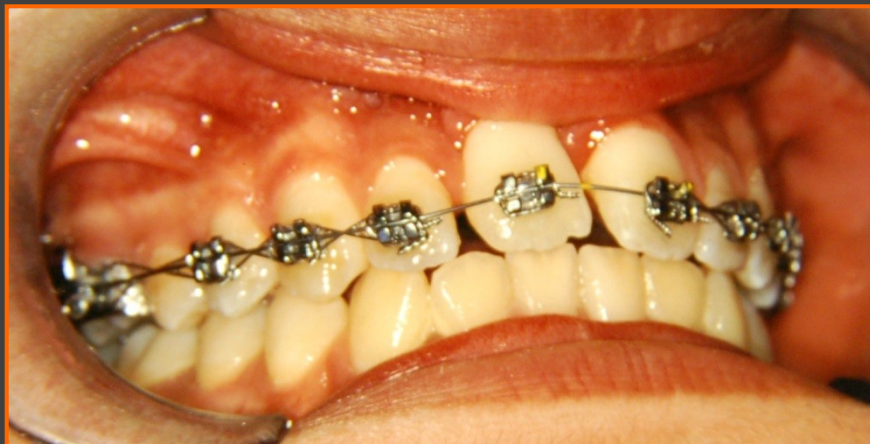
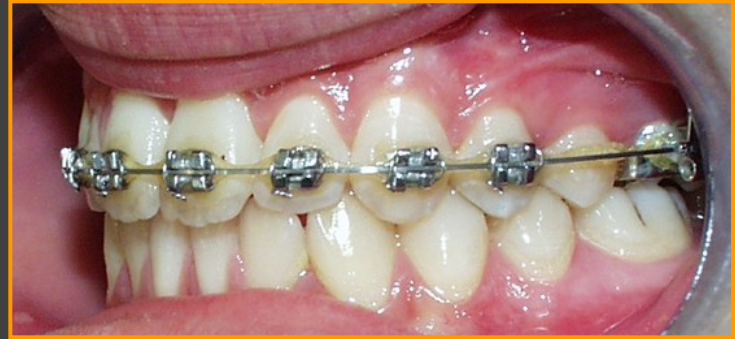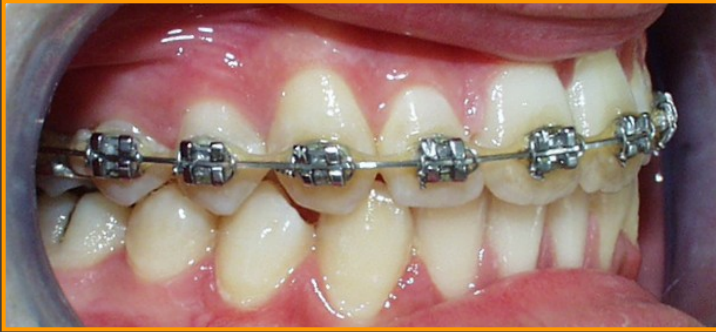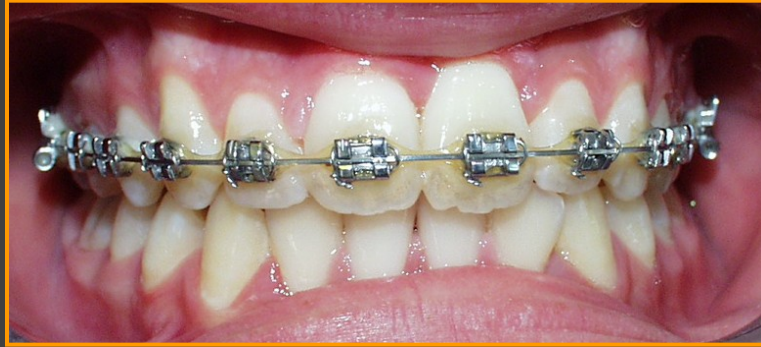CBCT

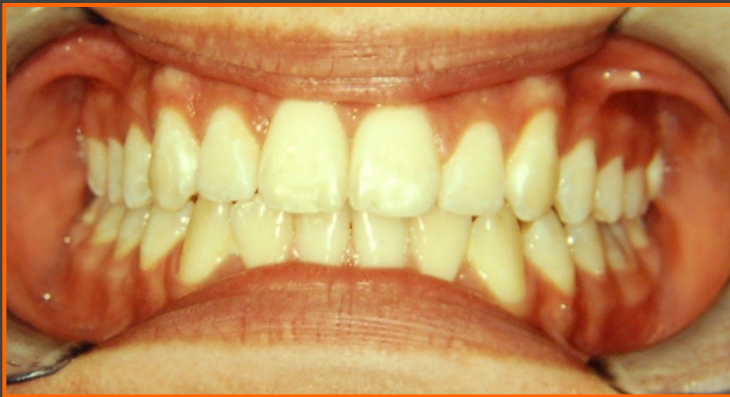
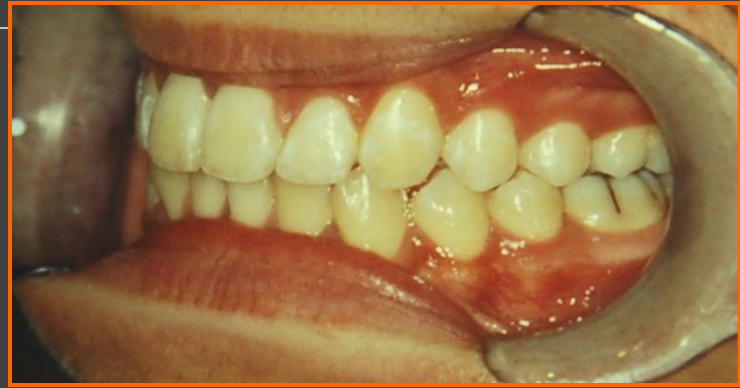
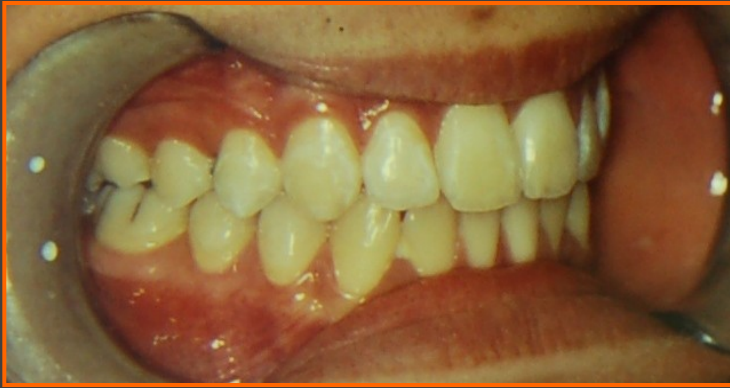Extraction of the supernumerary incisors



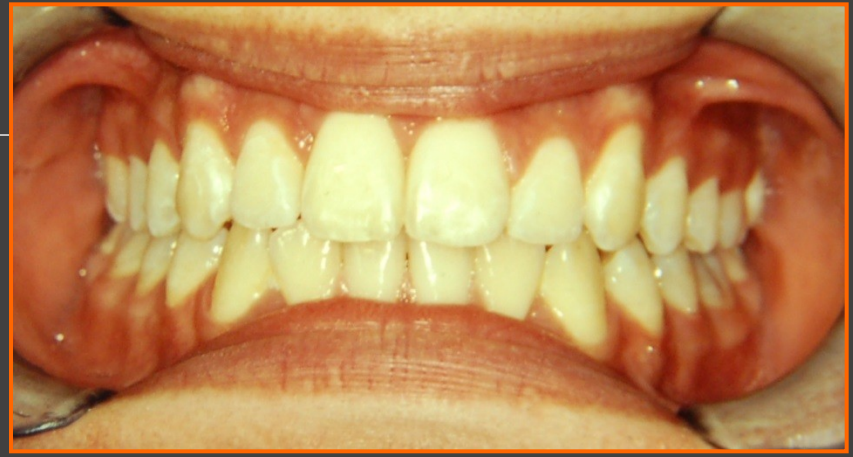
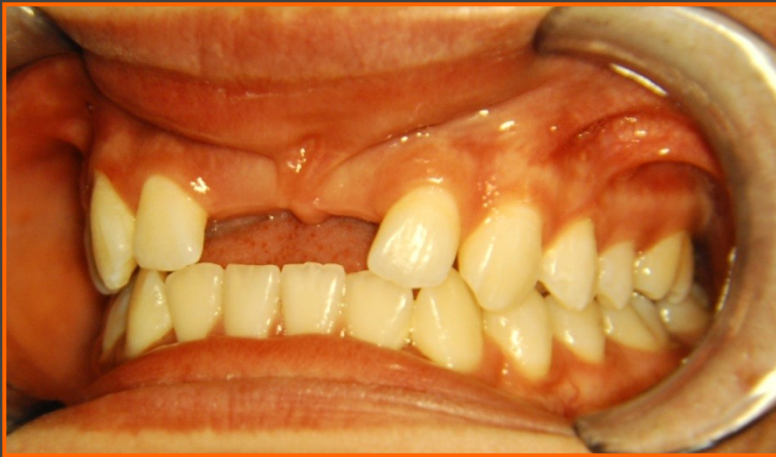




Case 2 - before

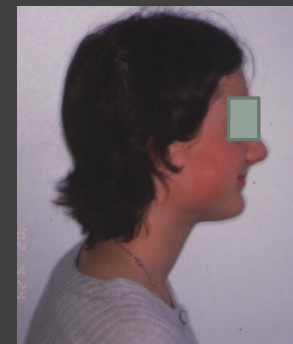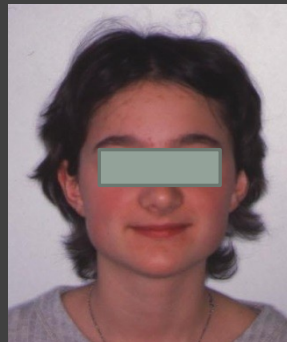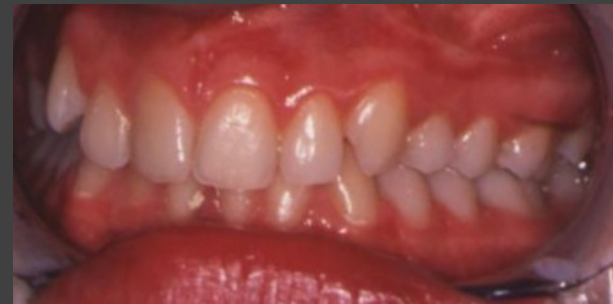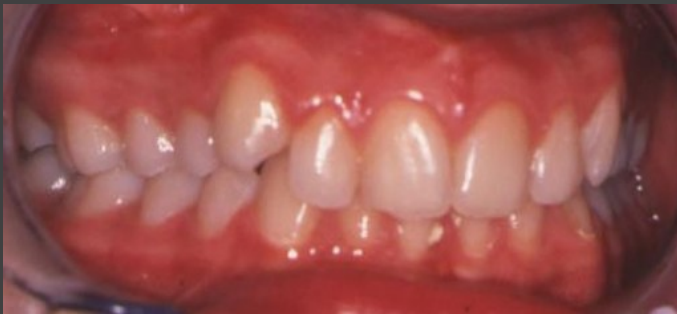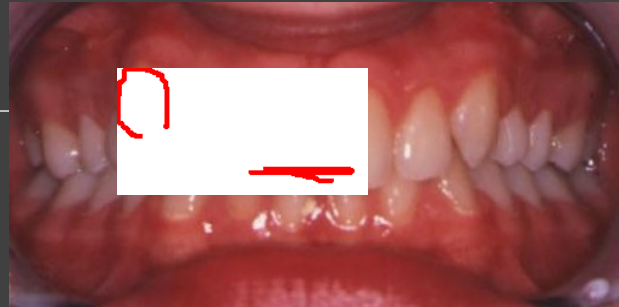after treatment



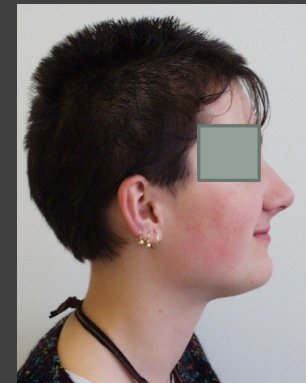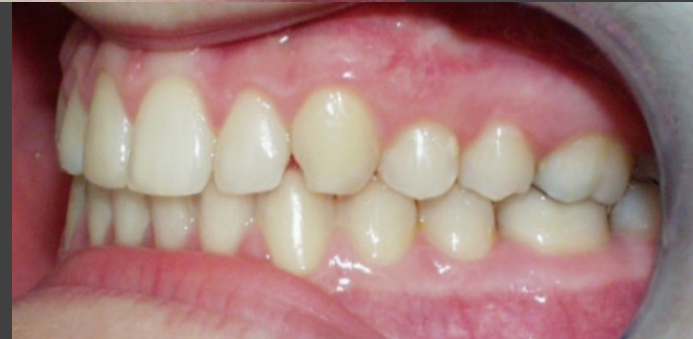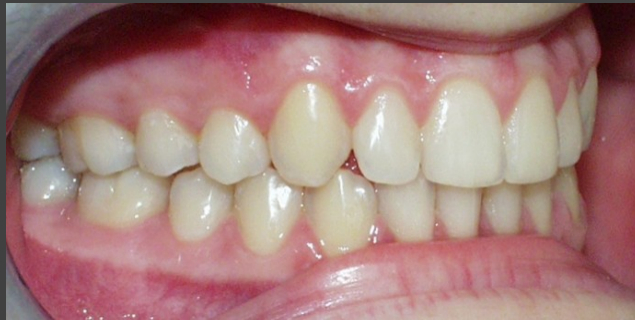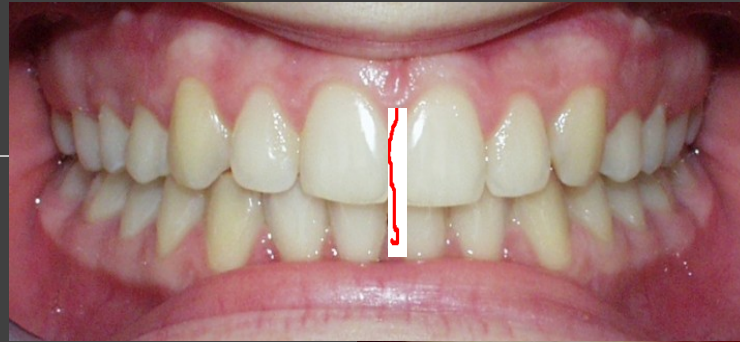
treatment – 16 months



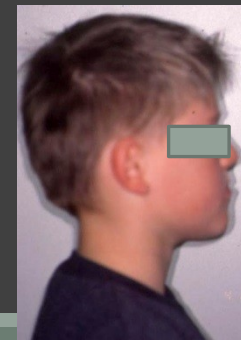
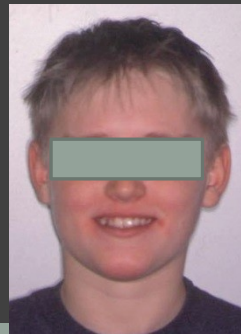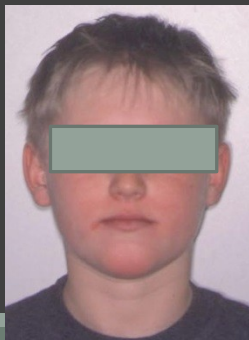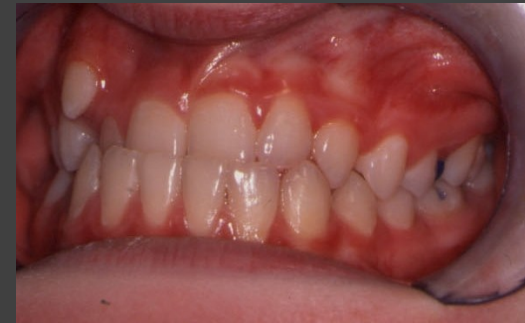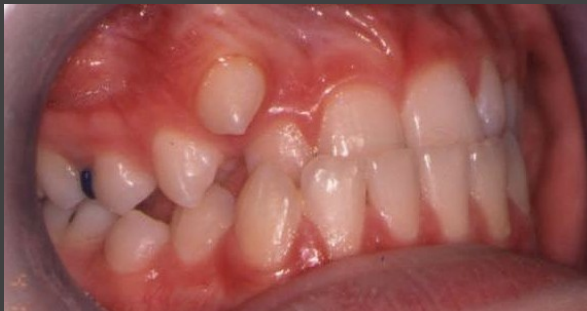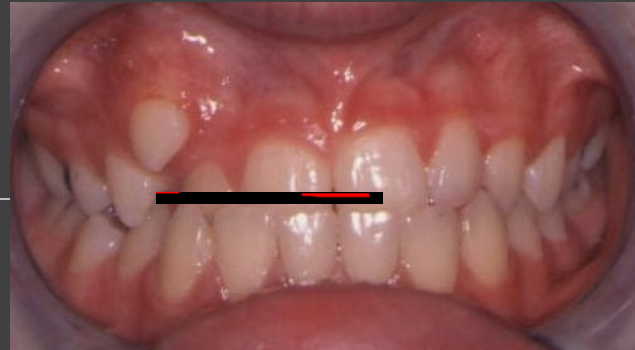Case 3 – deep bite, crowding



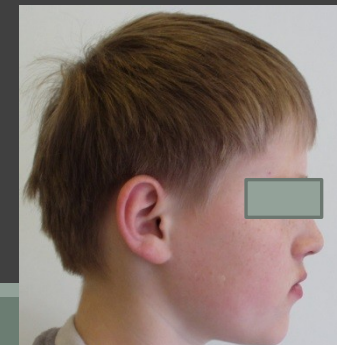
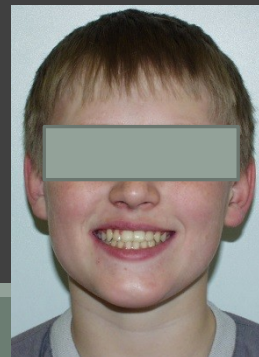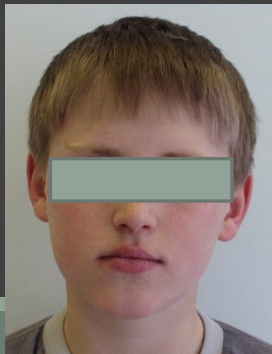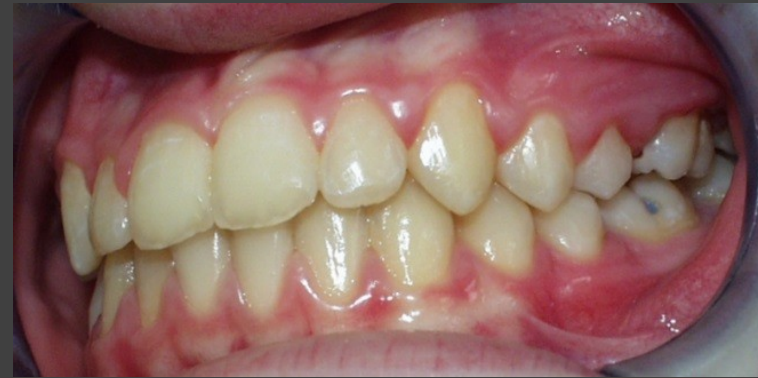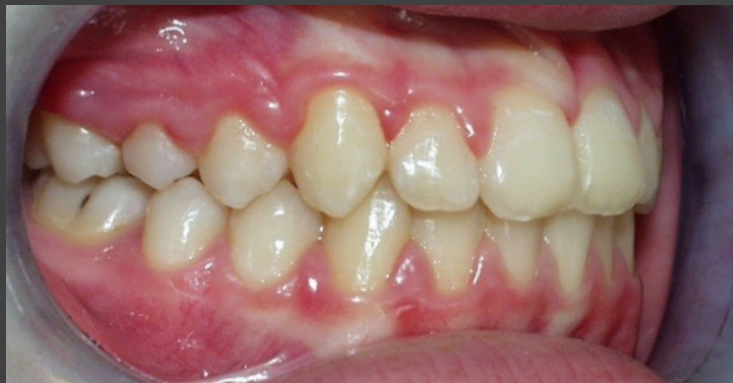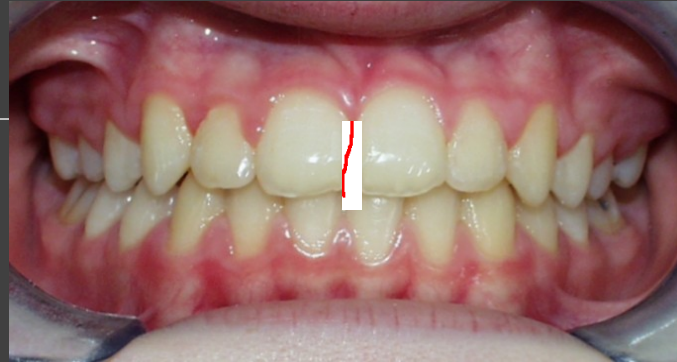Case 3 – deep bite, crowding – after treatment with fixed appliance – 1,5 year



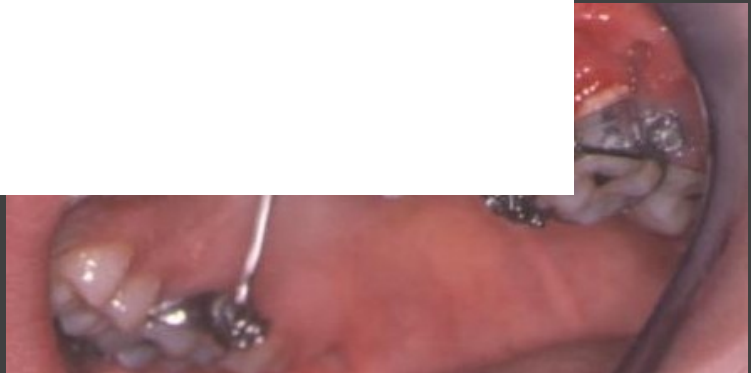
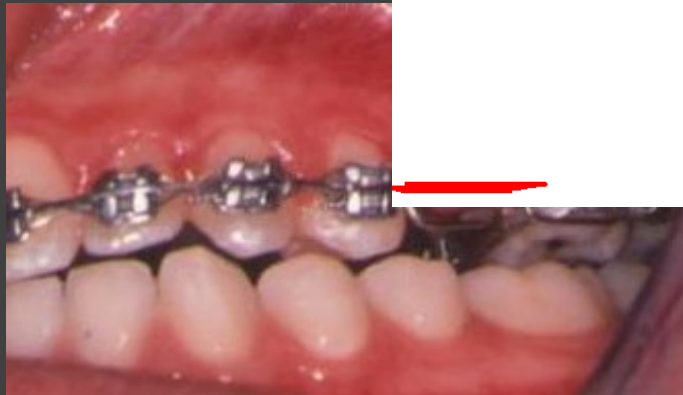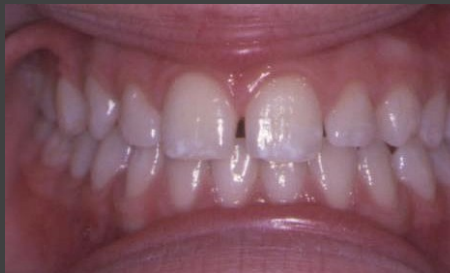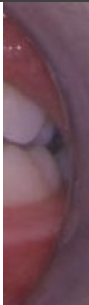
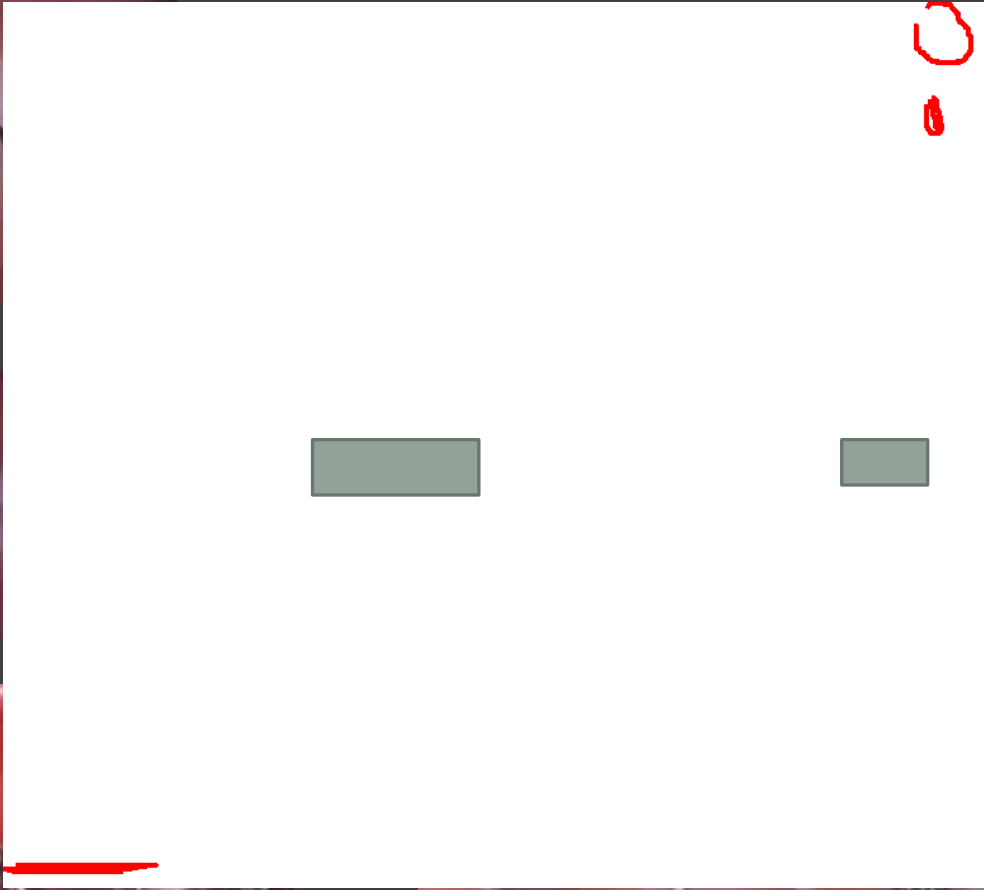
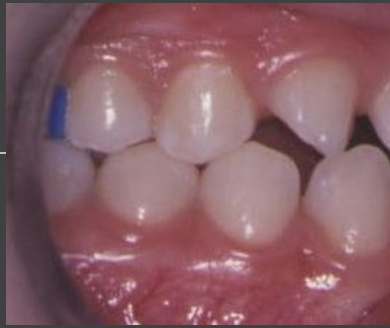Case 4 – inverted bite, crowding, vestibular eruption canine



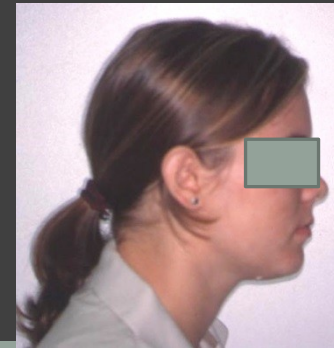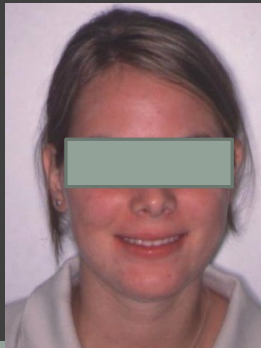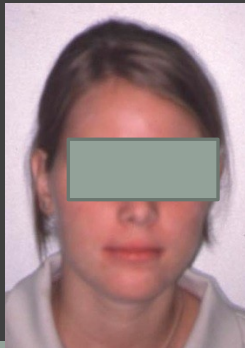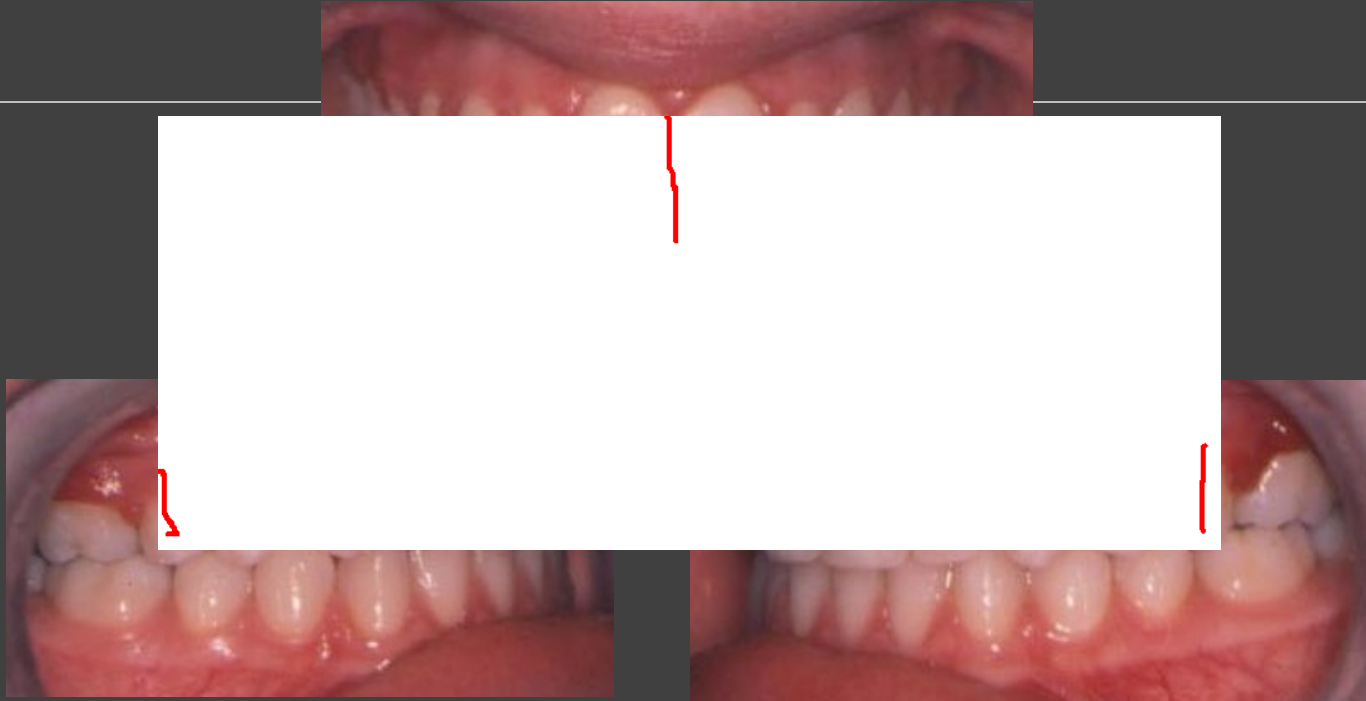Case 4 – inverted bite, crowding, vestibular eruption canine – after treatment with fixed appliance – no extraction, 2 years



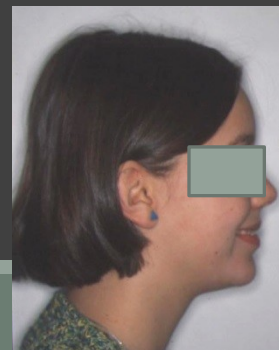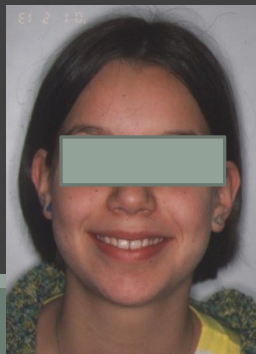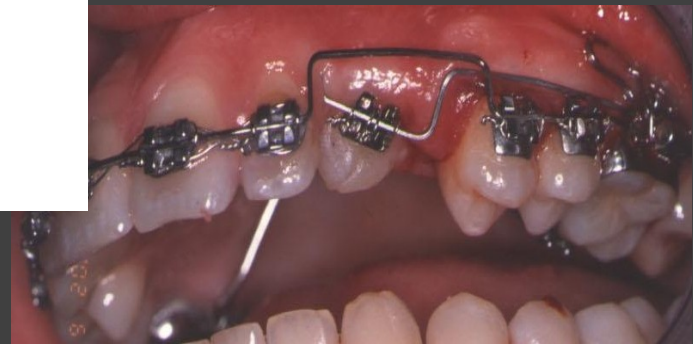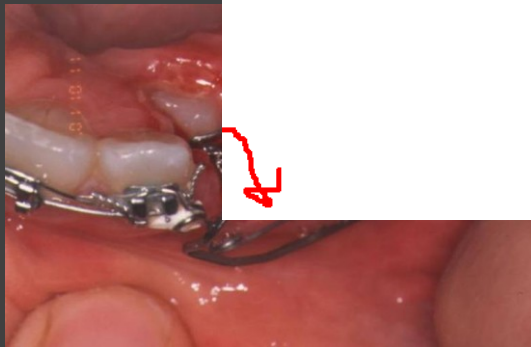
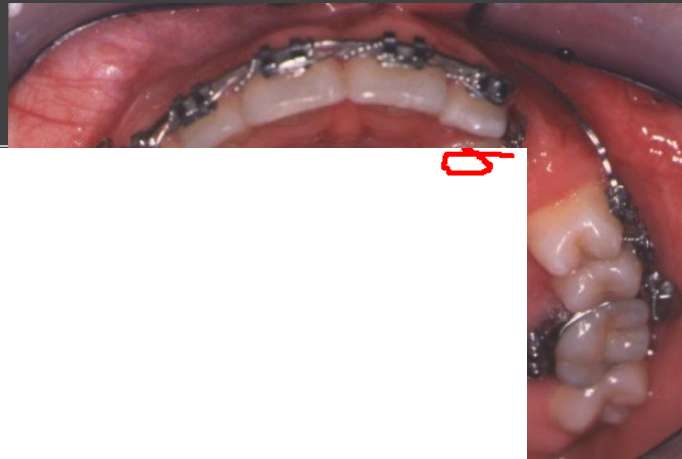Case 5 – retention of second premolars no space for eruption



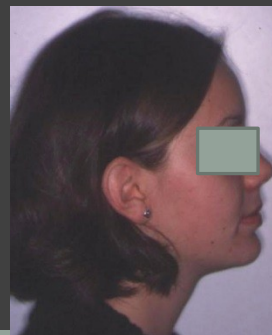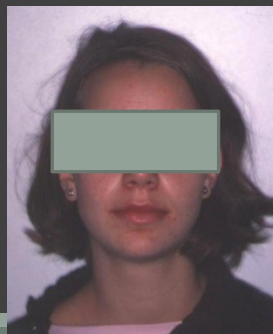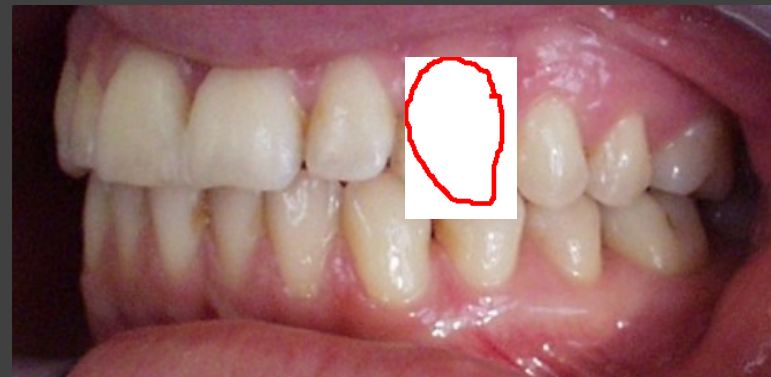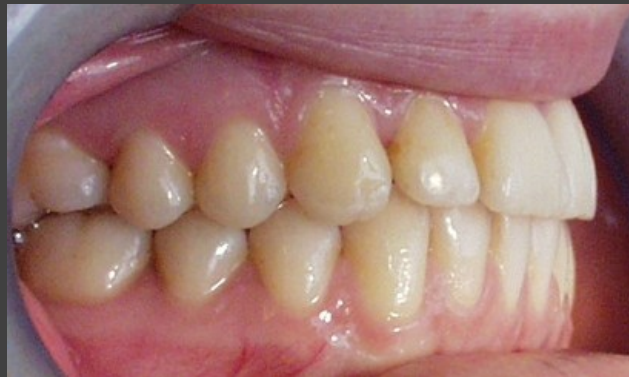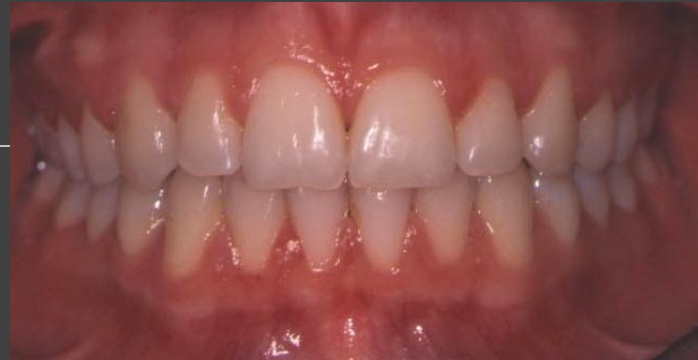Case 5 – retention of second premolars no space for eruption – after treatment – expansion, no extraction – 2 years




Case 6 – retention of canine, palatal eruption



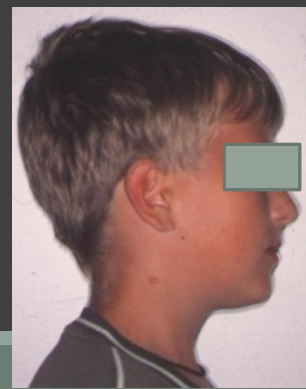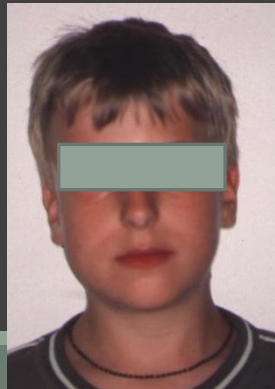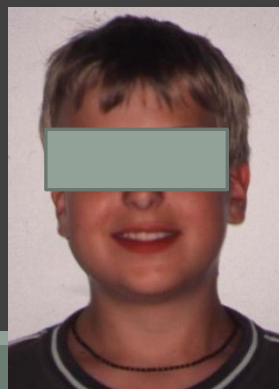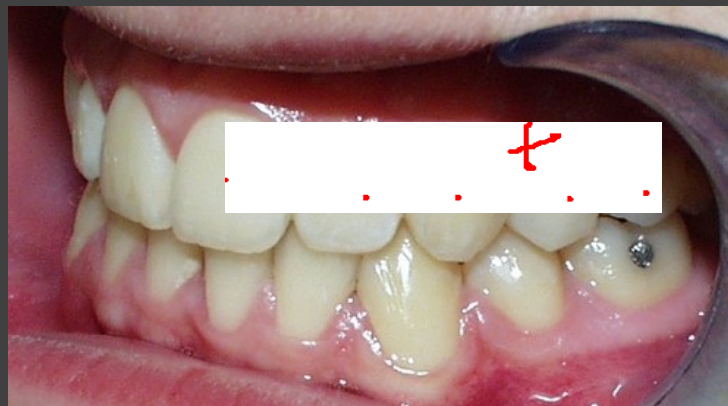
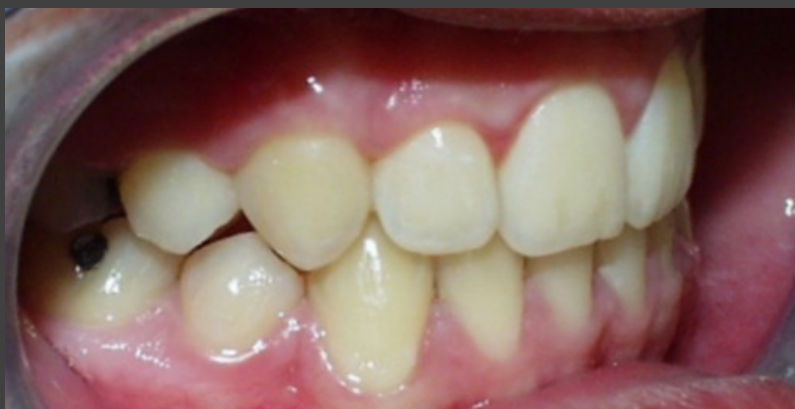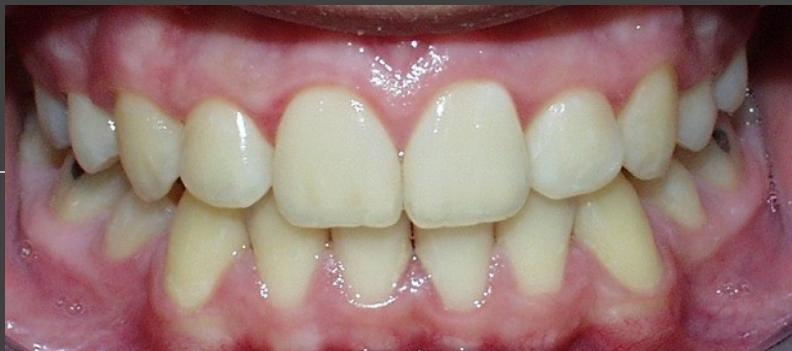Case 6 – after treatment – expansion, alignment canine



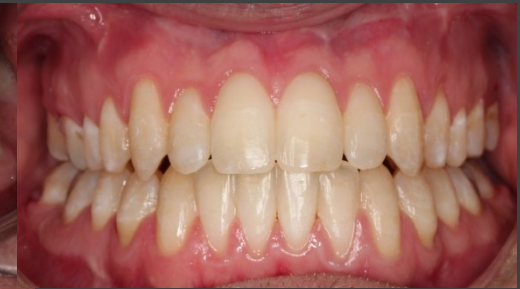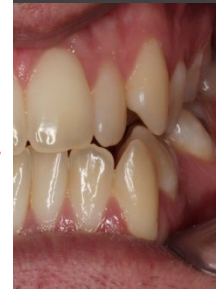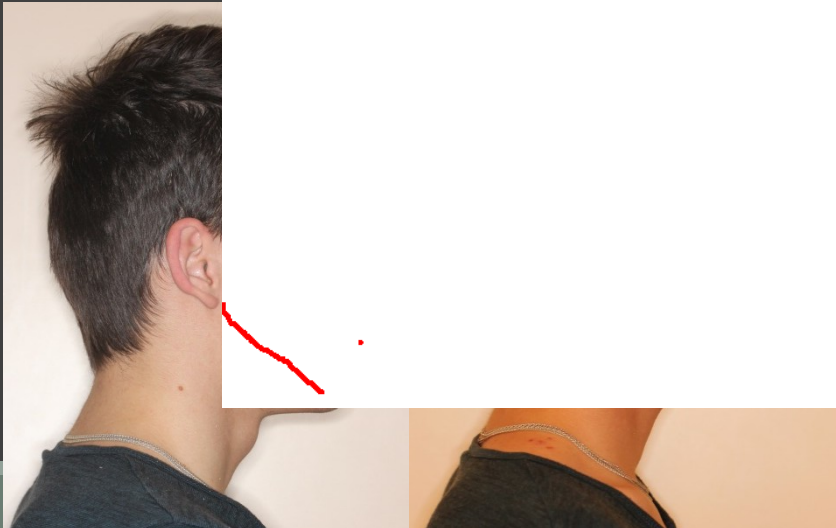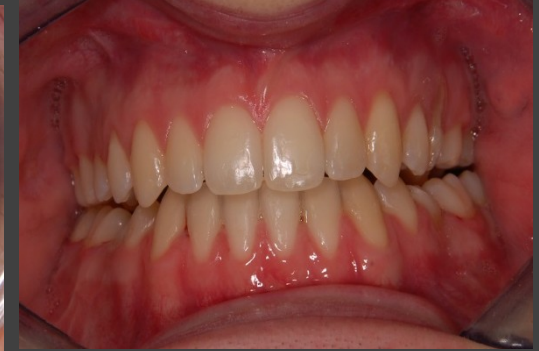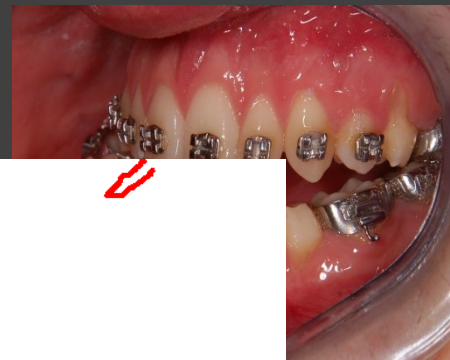
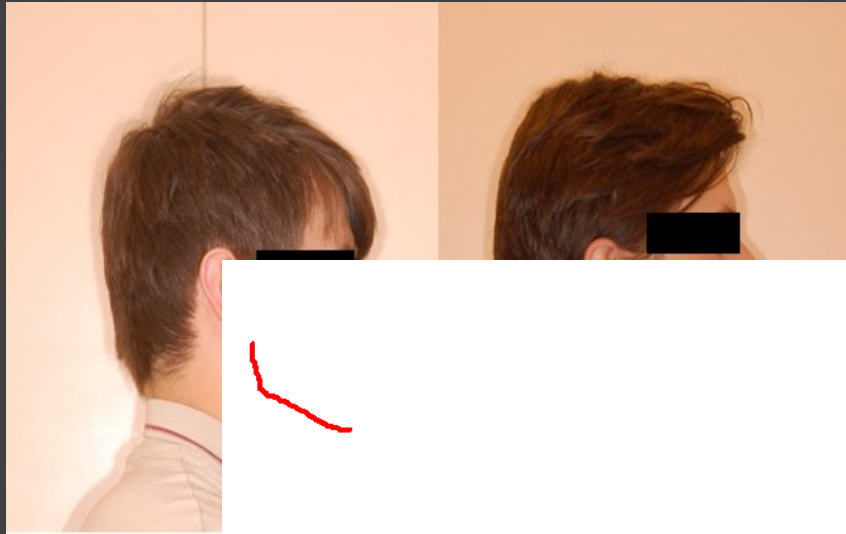Case 7 - retention of upper and lower canines, no space for eruption



Case 7 - retention of upper and lower canines, no space for eruption
– after treatment with extraction of 4 first premolars, canines on place

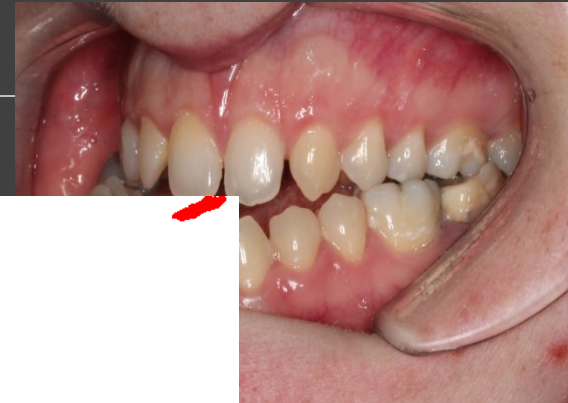
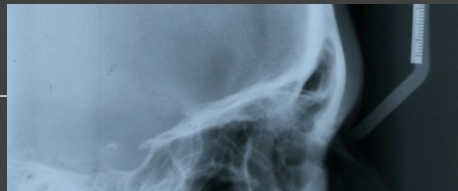
Case – orthodontic treatment with surgery correction – mandibular progenia, skeletal class III, open bite, crowding


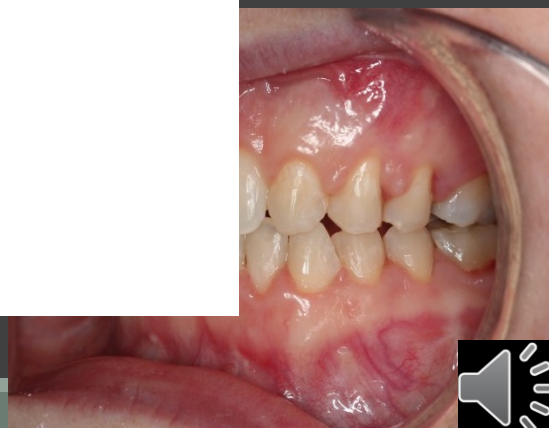
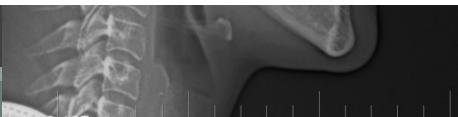



Case – orthodontic treatment with surgery correction – mandibular progenia, skeletal class III, open bite, crowding

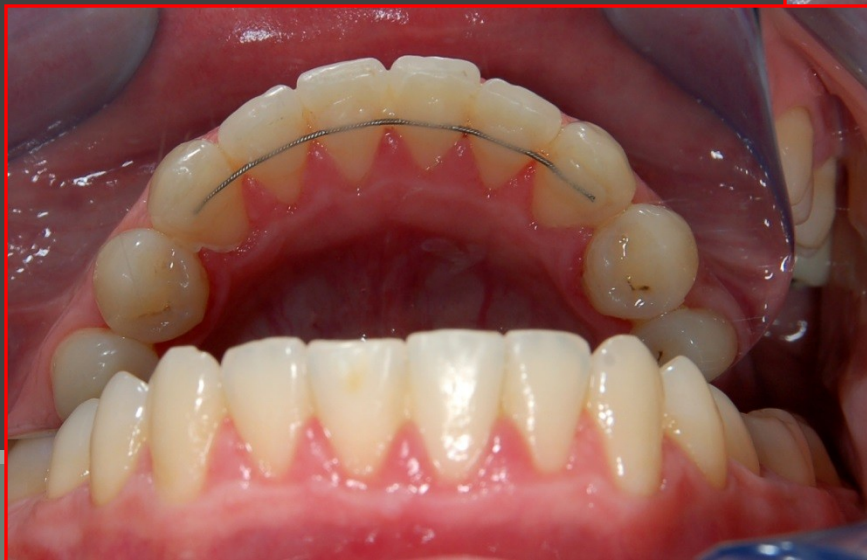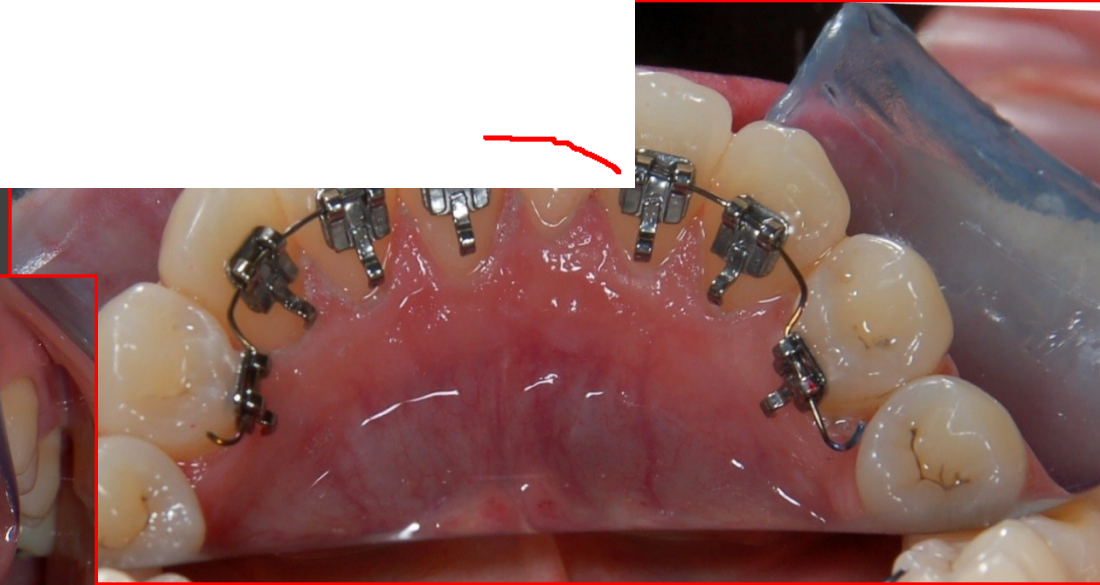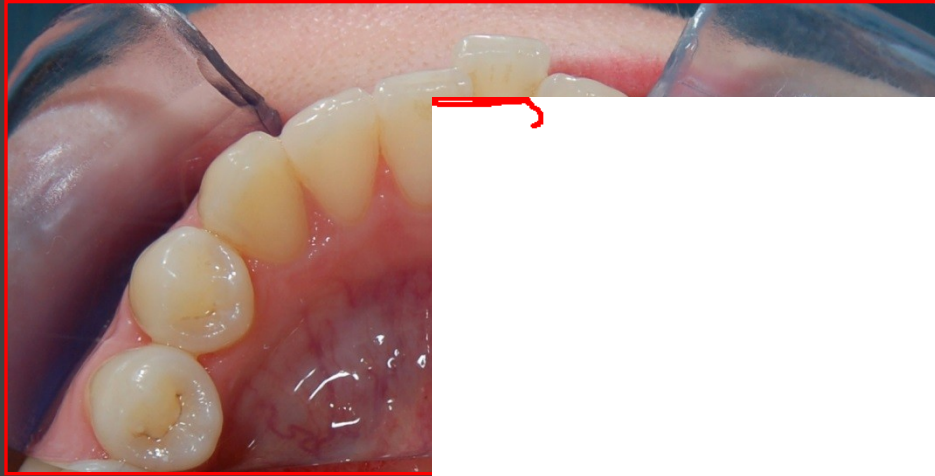
Before treatment



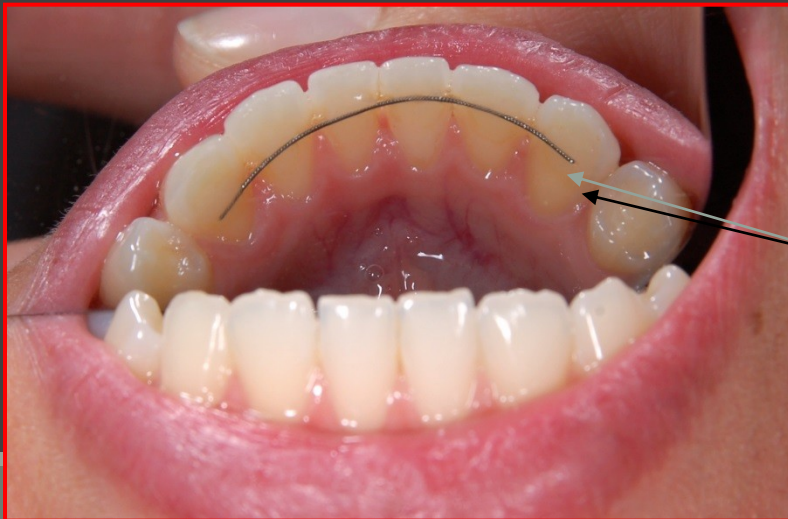
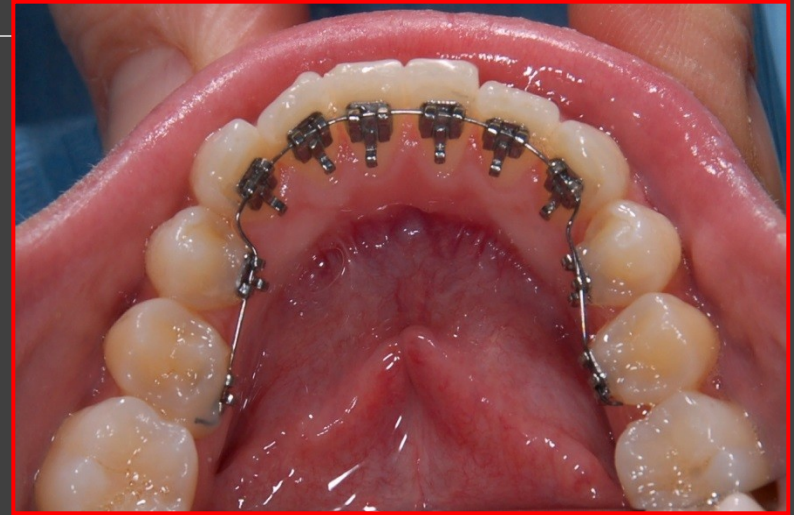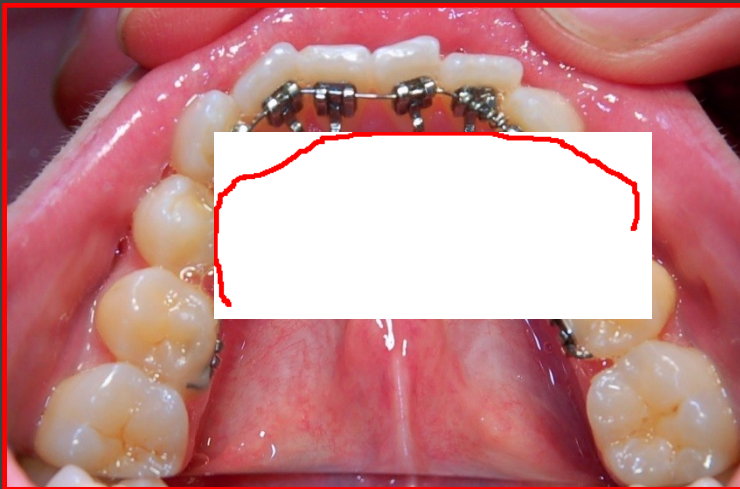
After treatment



Orthodontic treatment with lingual appliance



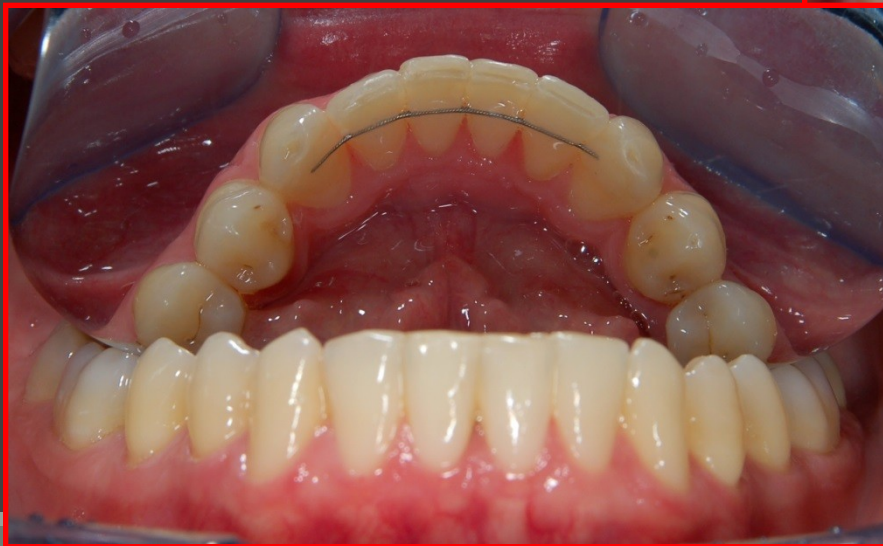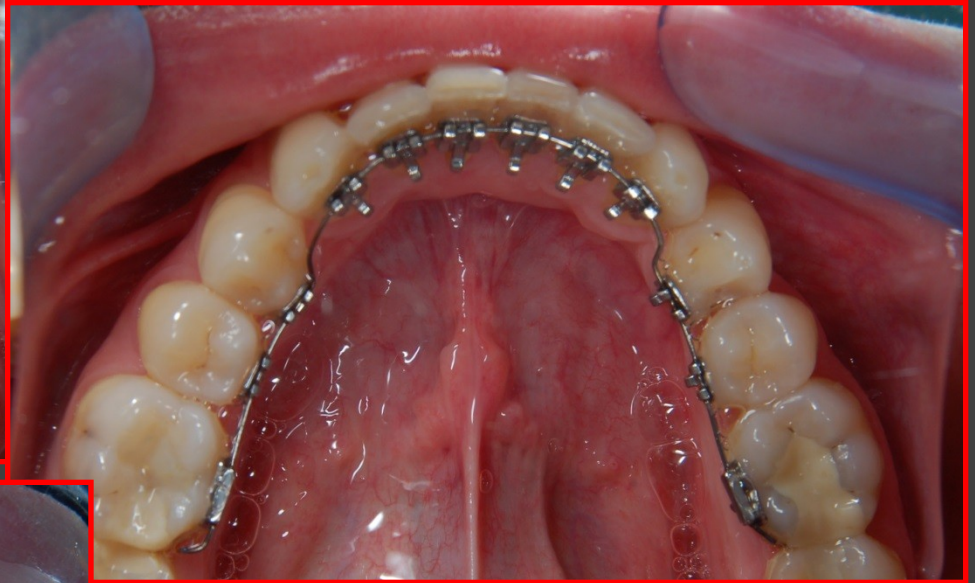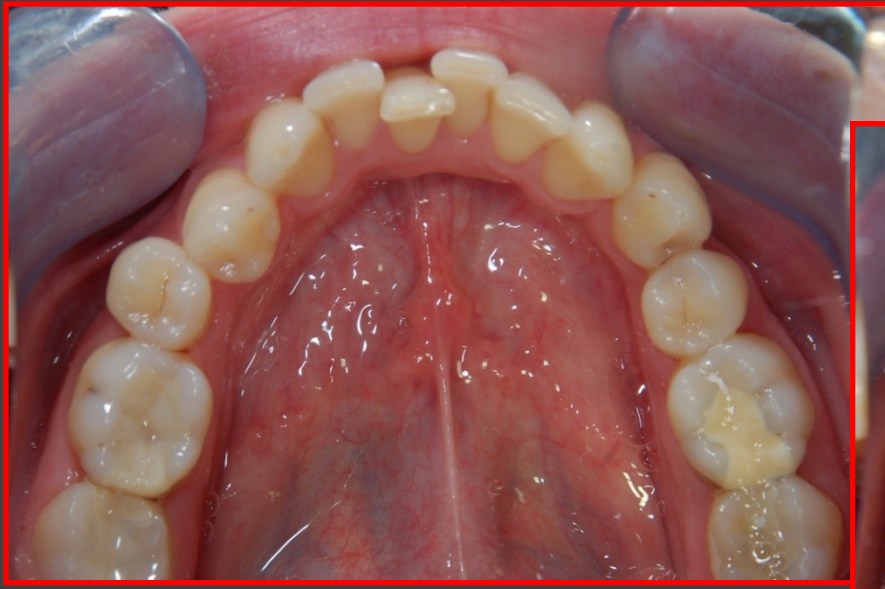Orthodontic treatment with lingual appliance

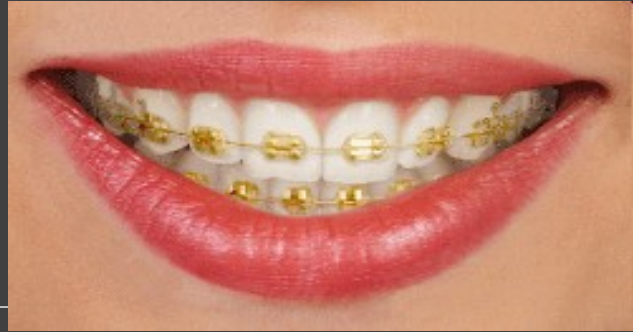
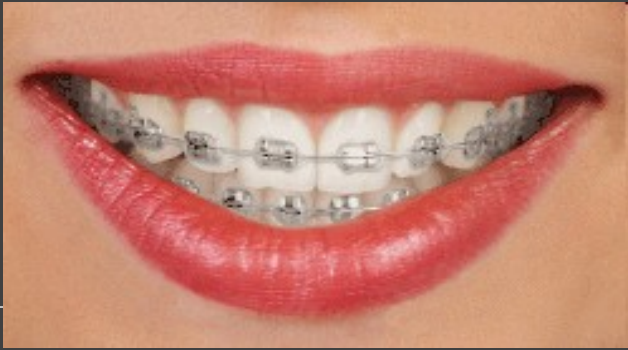
Fixed retainer after treatment



Treatment - crowding - with lingual appliance





Thank You four Your attention

Questions – email – alena.brysova@fnusa.cz

Consultation – Orthodontic department - St. Anne's Hospital, building D2b –
Thursday 1-2 p.m.

