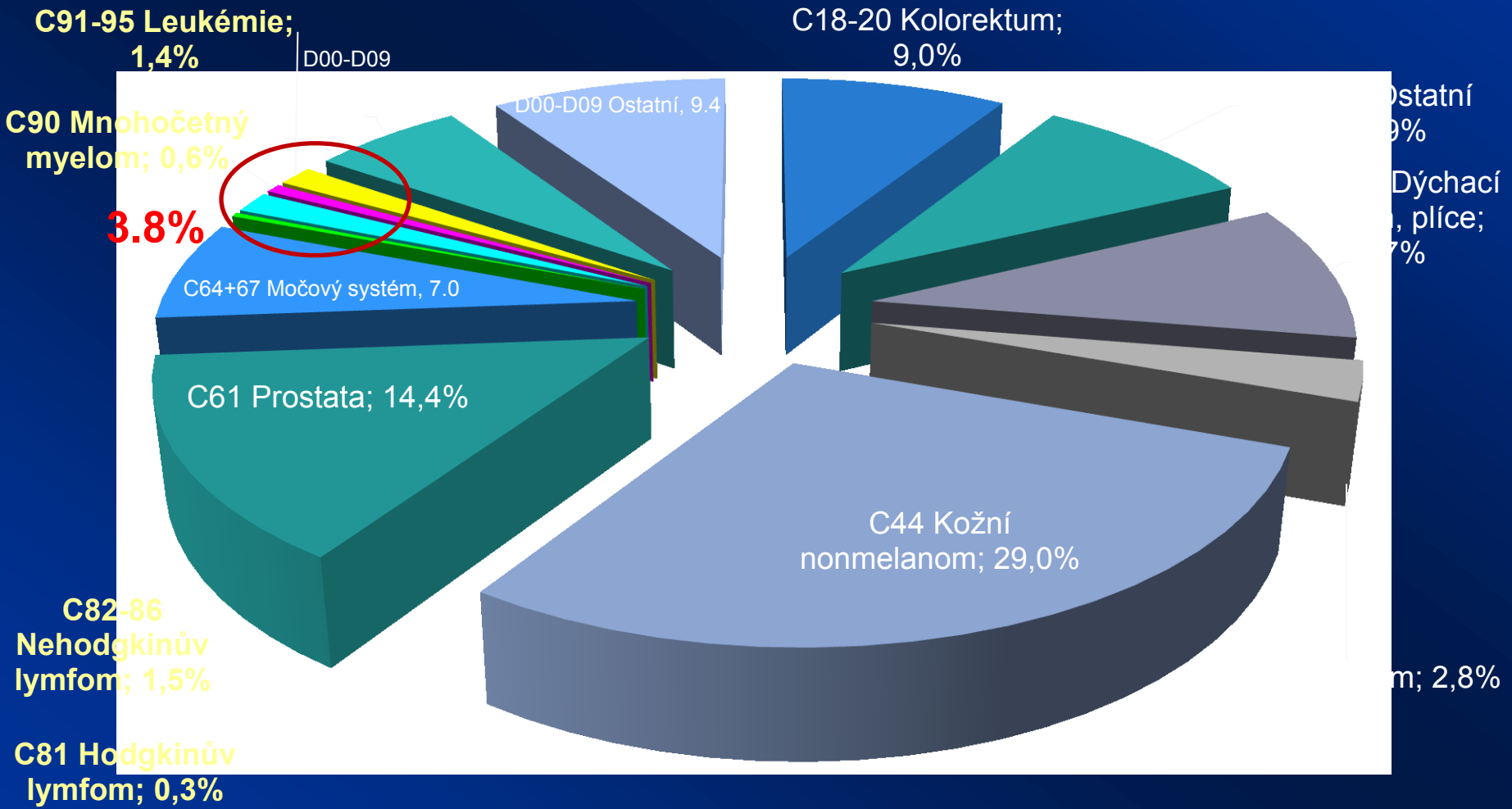


Lymphoproliferative disorders

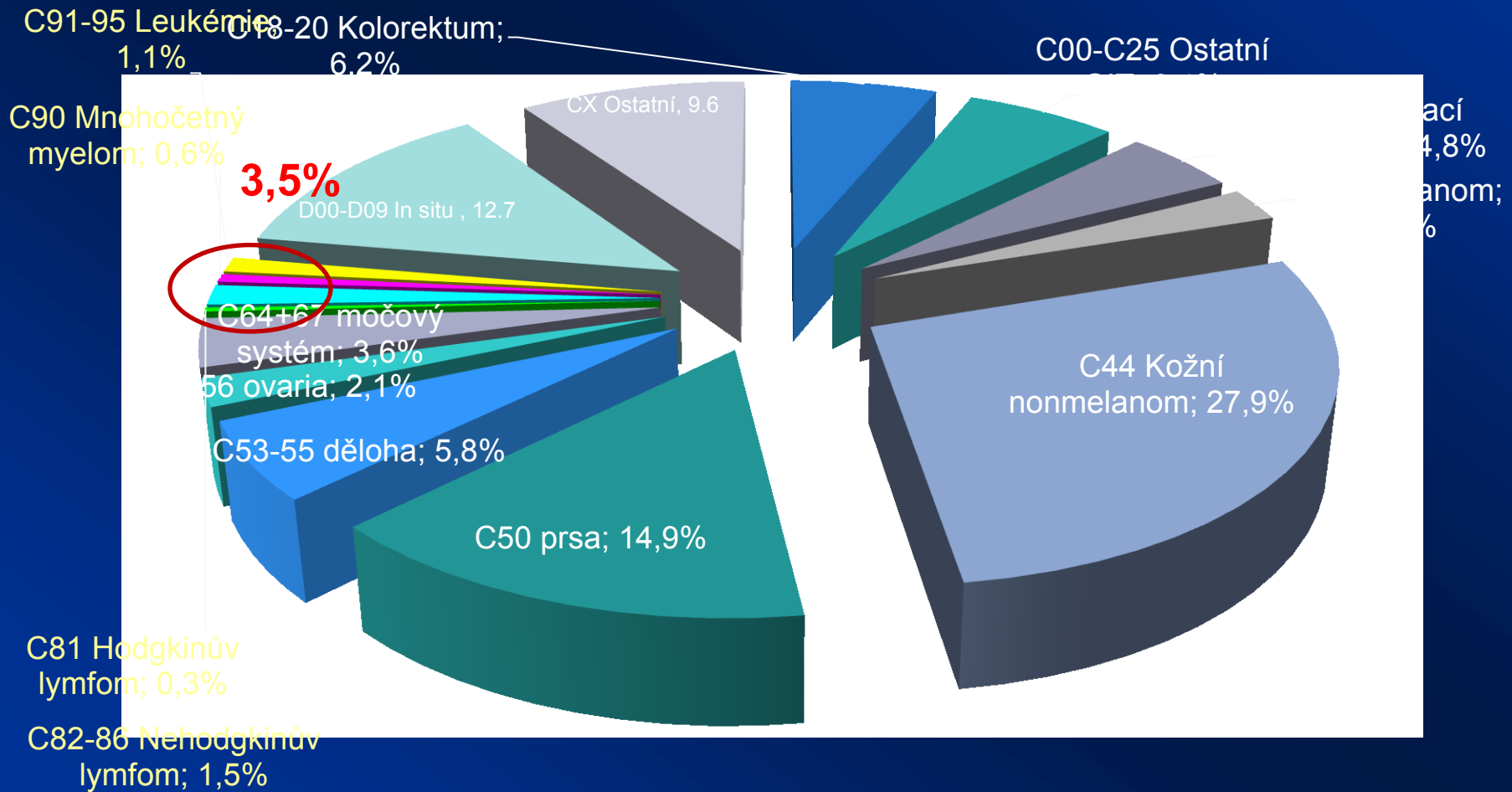
What's essential to remember – Take home message

- **For students and non-hematologists:**
- *Clinical manifestation – when the disorder is to be suspected*
- *Diagnostic algorithm – how the correct diagnosis is the best to be made*
- *Basic overview of disorders – main groups of diseases and basic information about treatment modalities*
- **For hematology specialists:**
- *Recent optimal treatment algorithms*

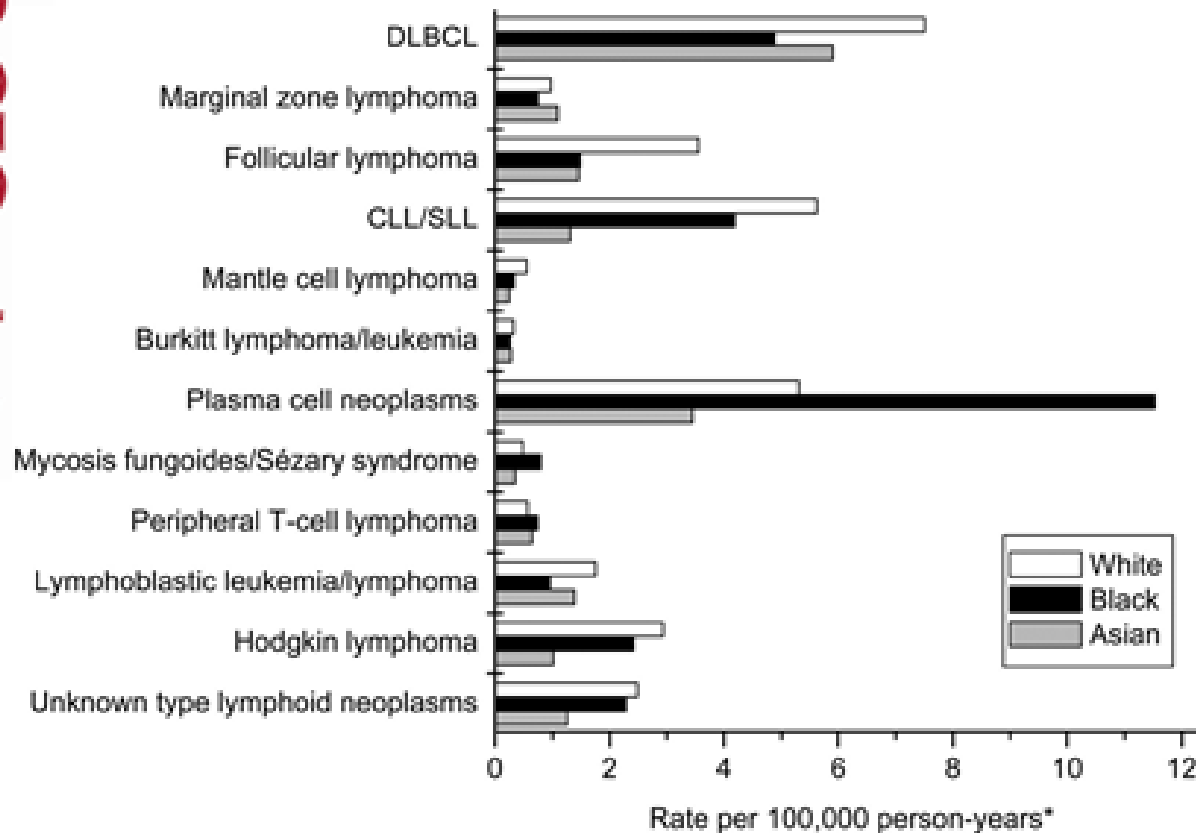
CANCER TYPES INCIDENCE CZECH REPUBLIC 2016 (men; ÚZIS)



CANCER TYPES INCIDENCE IN CZECH REPUBLIC 2016 (women; ÚZIS)



Incidence of lymphoid neoplasms by subtype and race, 12 SEER registries, 1992-2001. *All incidence rates are age adjusted to the 2000 United States population.



Morton L M et al. *Blood* 2006;107:265-276

PROGNOSIS AND SURVIVAL OF PATIENTS WITH HEMATOLOGICAL MALIGNANCIES

-world data

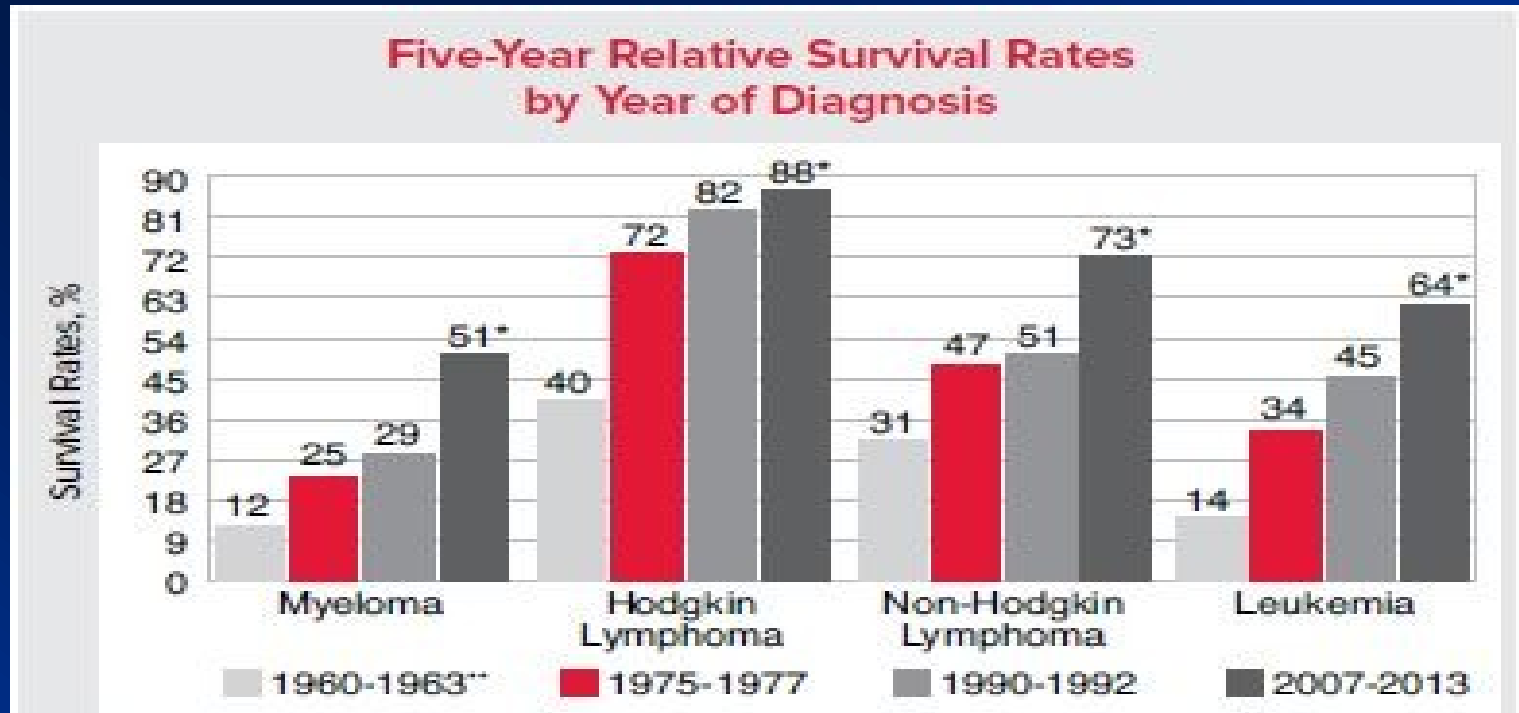


Figure 2. Source: SEER (Surveillance, Epidemiology and End Results) Cancer Statistics Review, 1975-2014. National Cancer Institute; 2017.

*The difference in rates between 1975-1977 and 2007-2013 is statistically significant ($p < .05$).

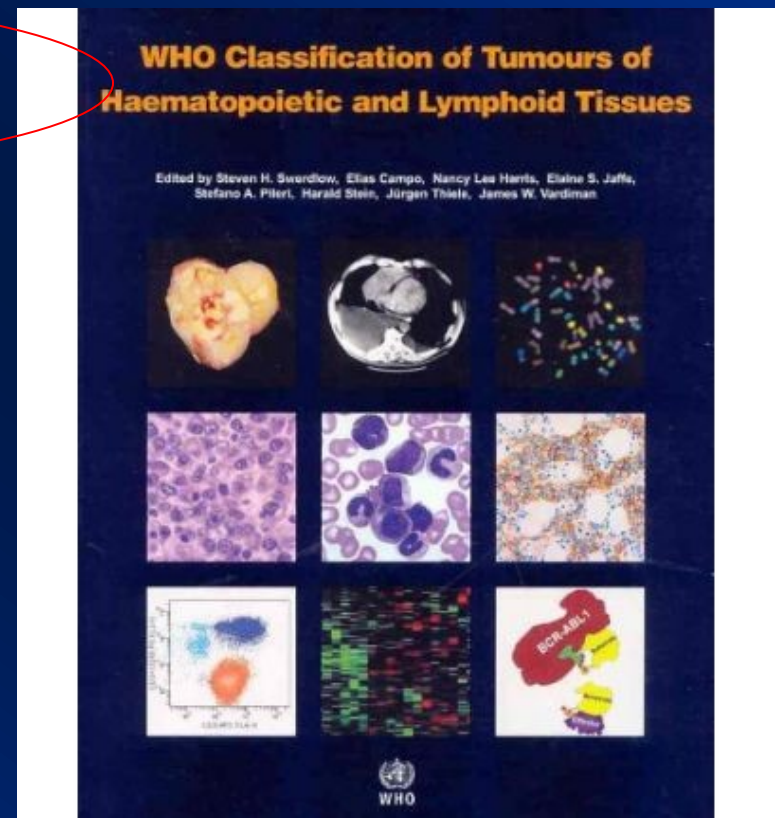
**Survival rate among whites.

Basic overview of hematological malignancies

Based on WHO classification 2018

Hematological malignancies come:

- from lymphoid cell-line
- from myeloid cell-line
- from histiocytic cell-line
- from monocytoid-macrophagocytic system



LYMPHOMA CLASSIFICATION HISTORICAL OVERVIEW

- Rappaport (1970)
- Kiel (1974)
- Working Formulation (1980)
- REAL (Revised European American Clasification of Lymphoid Neoplasms)
- WHO (5-th revision) 2018

Symptoms accompanying malignant lymphoproliferative diseases

We can recognise

- *Systemic (General) symptoms*
- *Symptoms of local expansion*
 - *Nodal*
 - *Extranodal*

GENERAL SYMPTOMS

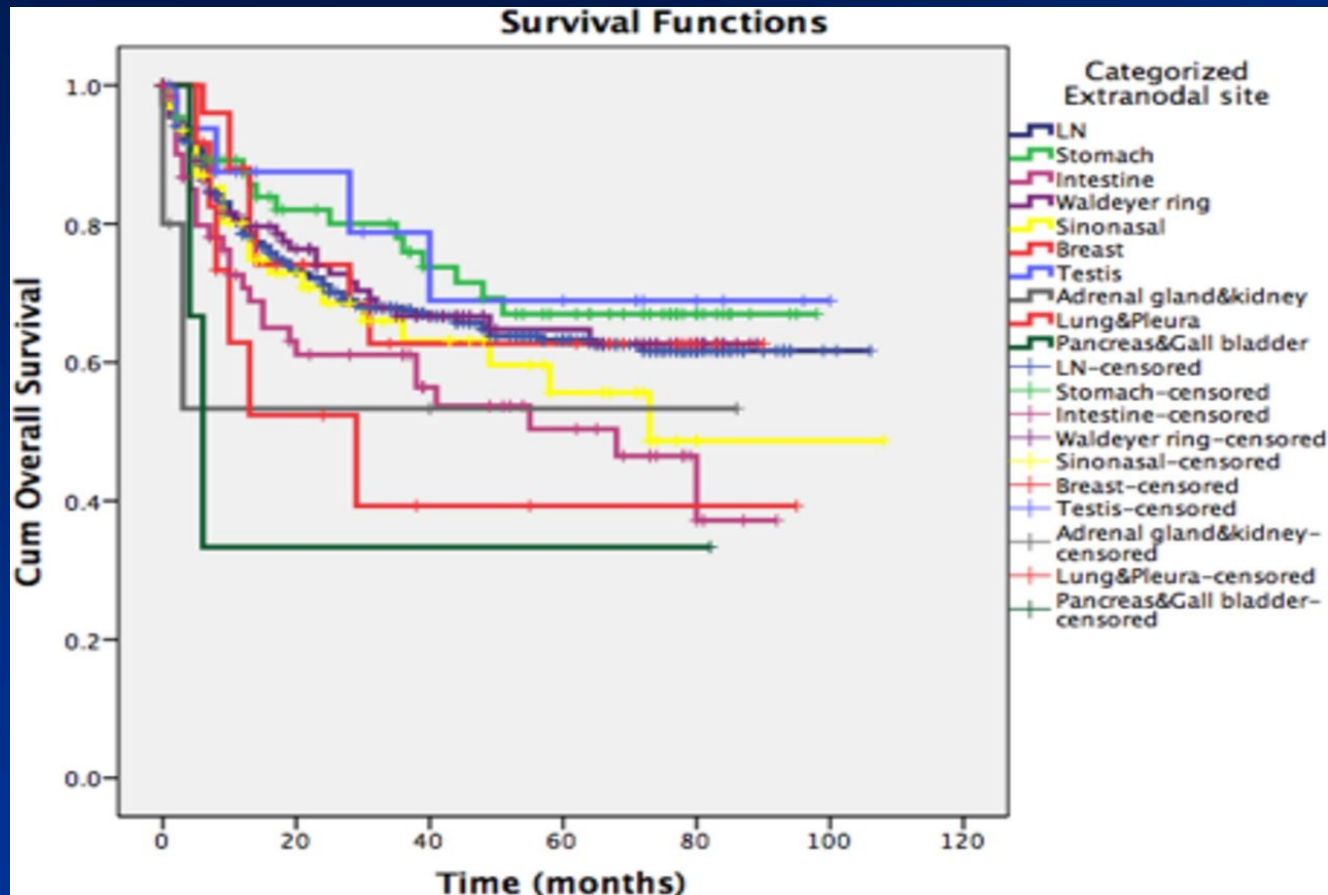
- WEIGHT LOSS
($\geq 10\%$ during 3 months; GIT disorders, chronic inflammatory diseases...)
- SUBFEVER/FEVER
(lasting > 3 weeks, dif dg infections, other tumors or autoimmunity disorders)
- ITCHING (usually without skin lesions)
- NIGHT SWEAT (need to change clothes)
- FATIGUE (pathological tiredness)

SYMPTOMS OF LOCAL EXPANSION

1. **Peripheral (palpable) lymphadenopathy:** „lumps“
2. **Mediastinal lymphadenopathy:** irritative dry cough, feeling of pressure, vena cava superior syndrom
3. **Abdominal lymphadenopathy:** stomach and intestinal dyspepsia, hydronephrosis due to urethral compression.
4. **Splenomegaly:** enlarged spleen compressing stomach, feeling of fullness after small meal
5. **Bone marrow infiltration:** (pan)cytopenia
6. **Osteolytic destruction of bones:** pain (backbone), fractures

EXTRANODAL LOCAL SYMPTOMS

- Extranodal involvement in systemic lymphoma
- Primary extranodal lymphomas (~ 30% NHL!)



Diagnostic algorithm

Periferal lymphadenopathy



Infection must be excluded
EBV, HIV, toxoplasma



Lymph node biopsy and histological examination

Native sample is preferred

Non-specific (general) symptoms

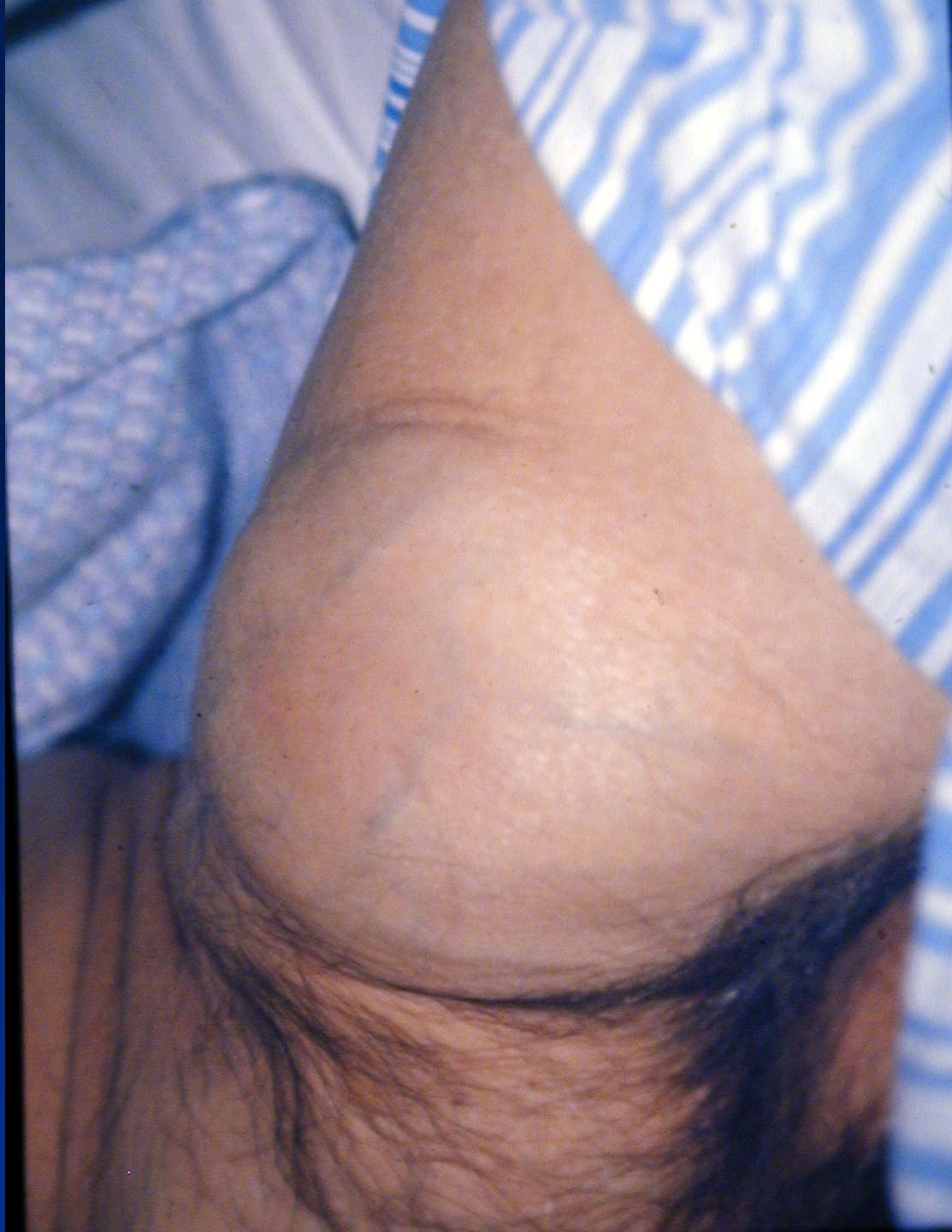

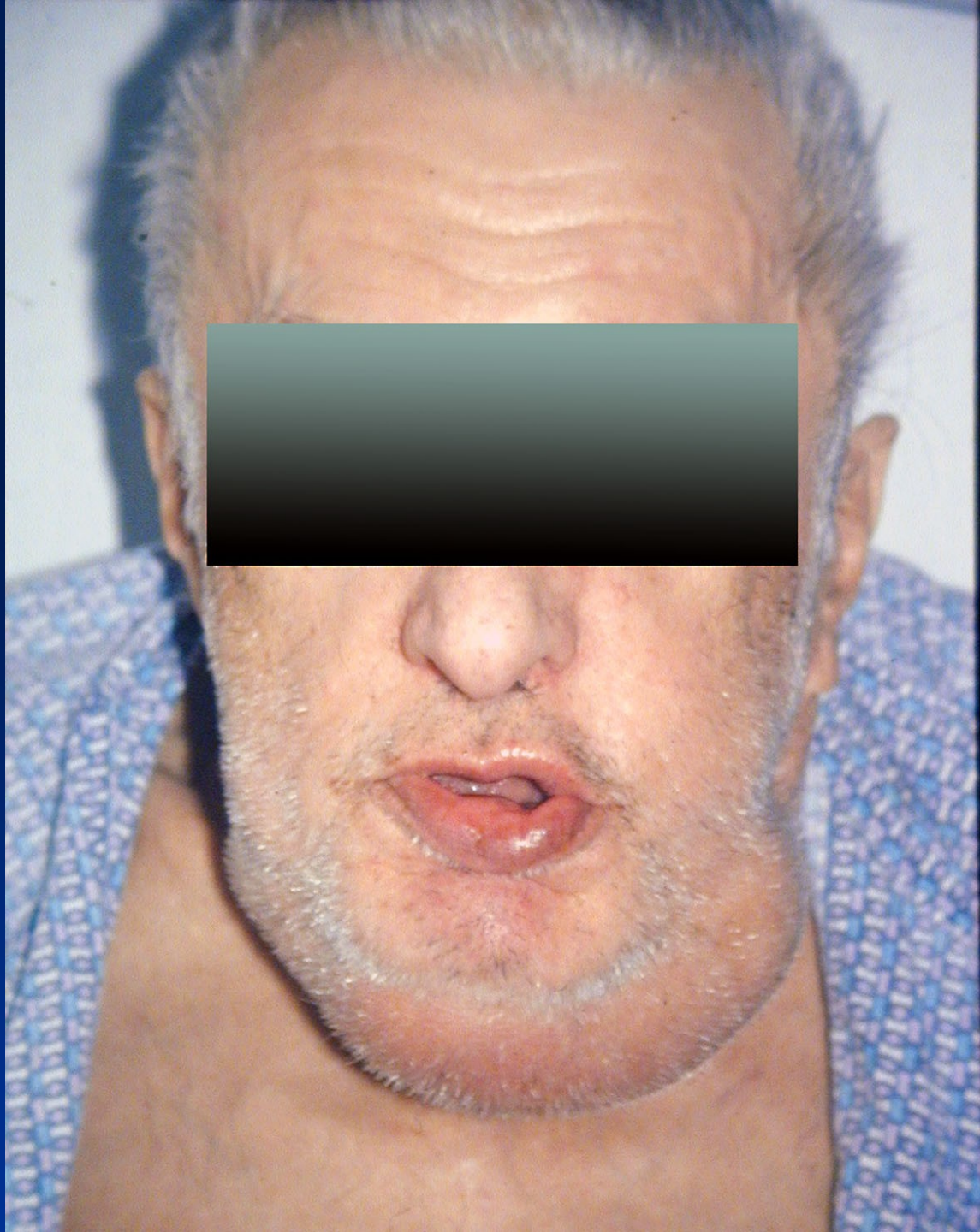
Clinical examination (lumps)

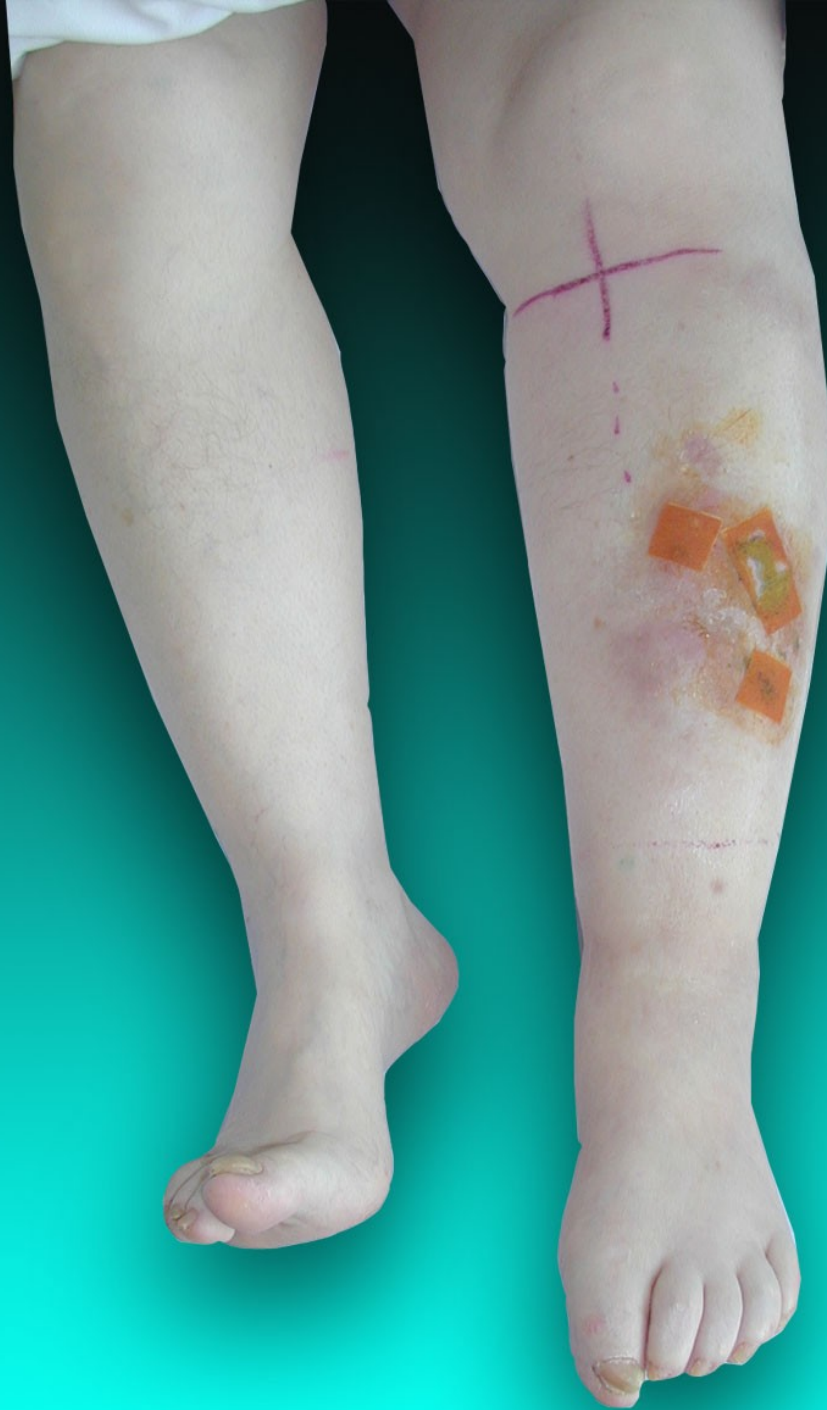


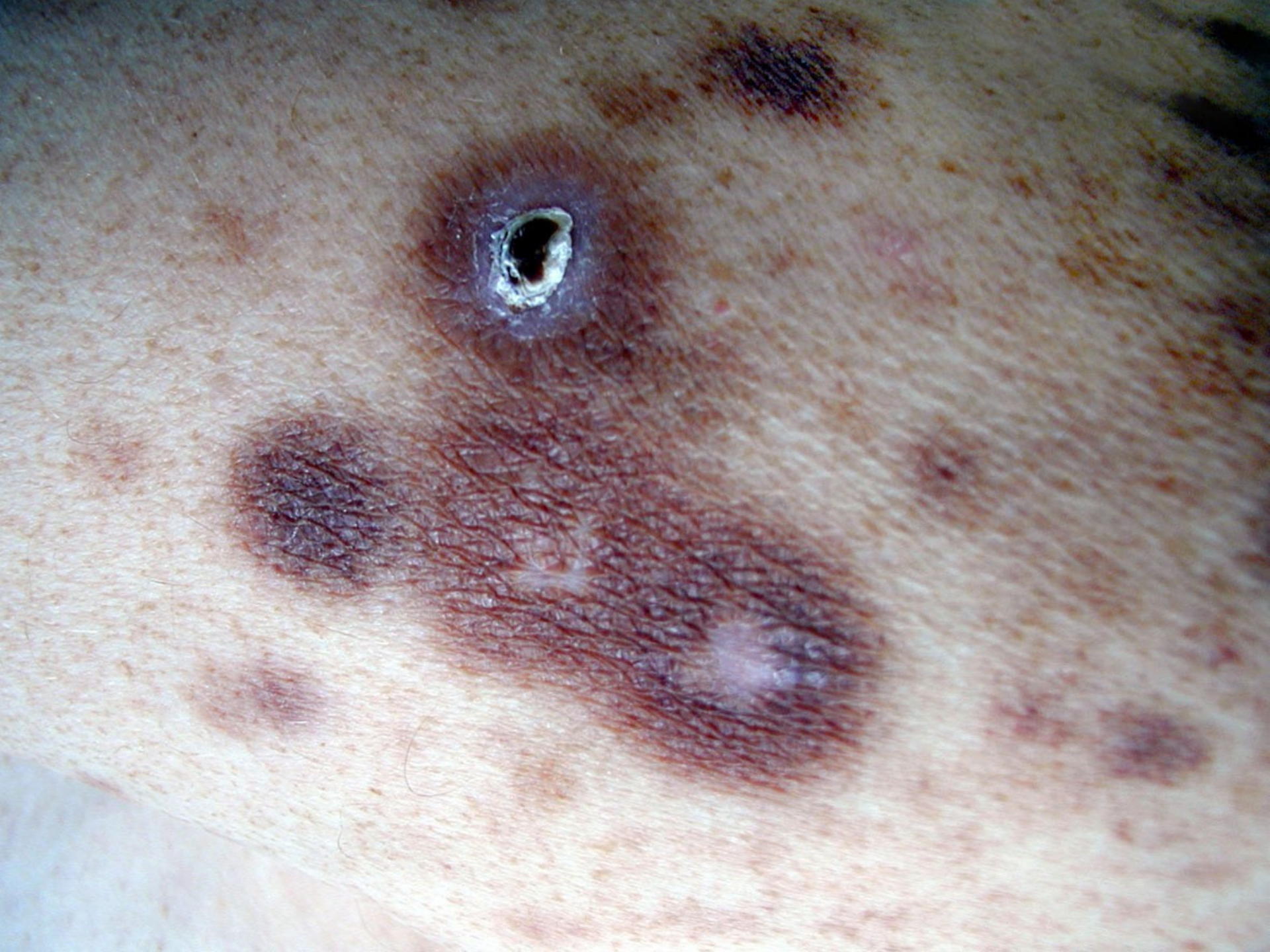Imaging examination:
Ultrasonography- peripheral lymph node, abdomen
CT mediastinum + retroperitoneum
PET
MR

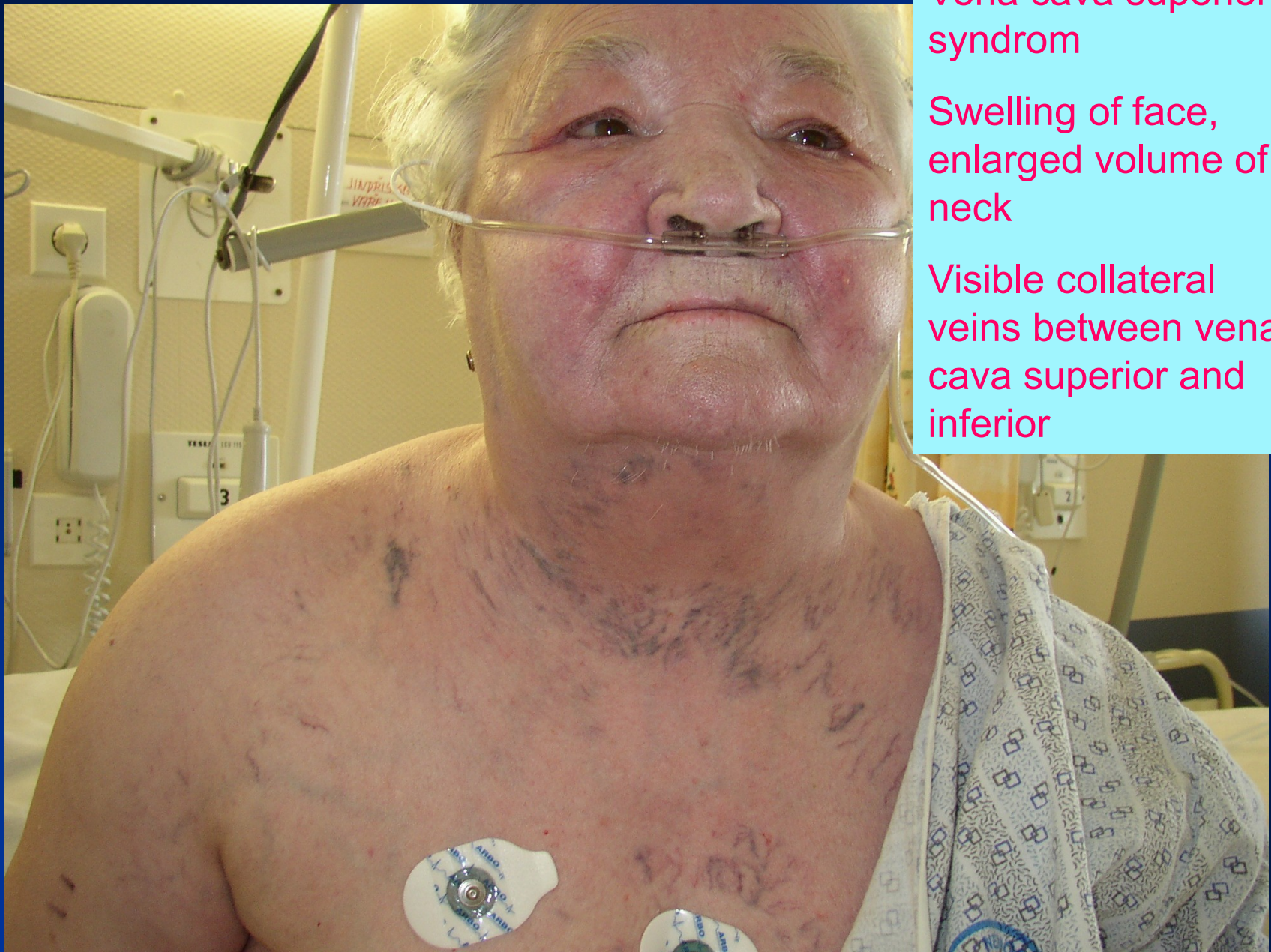








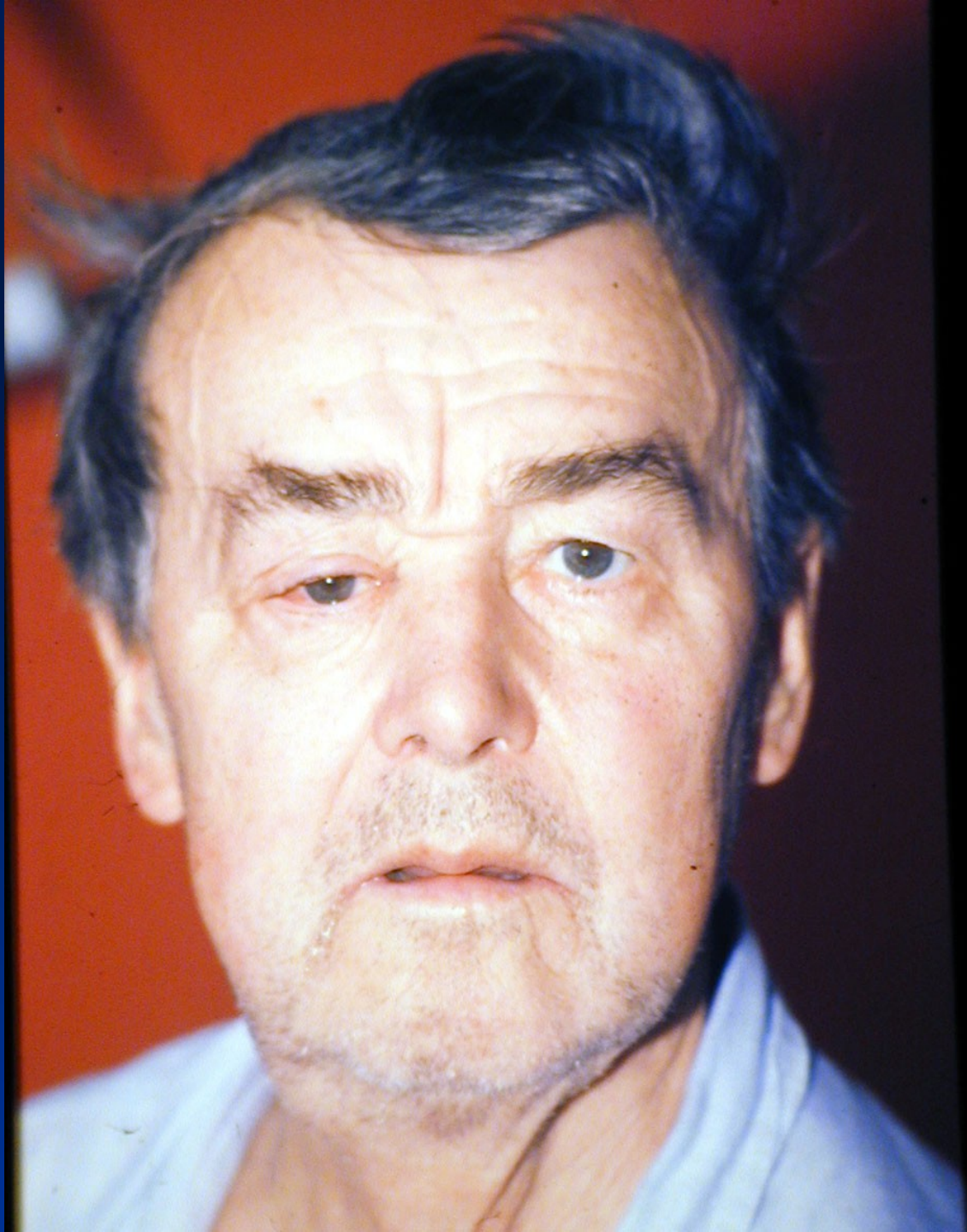


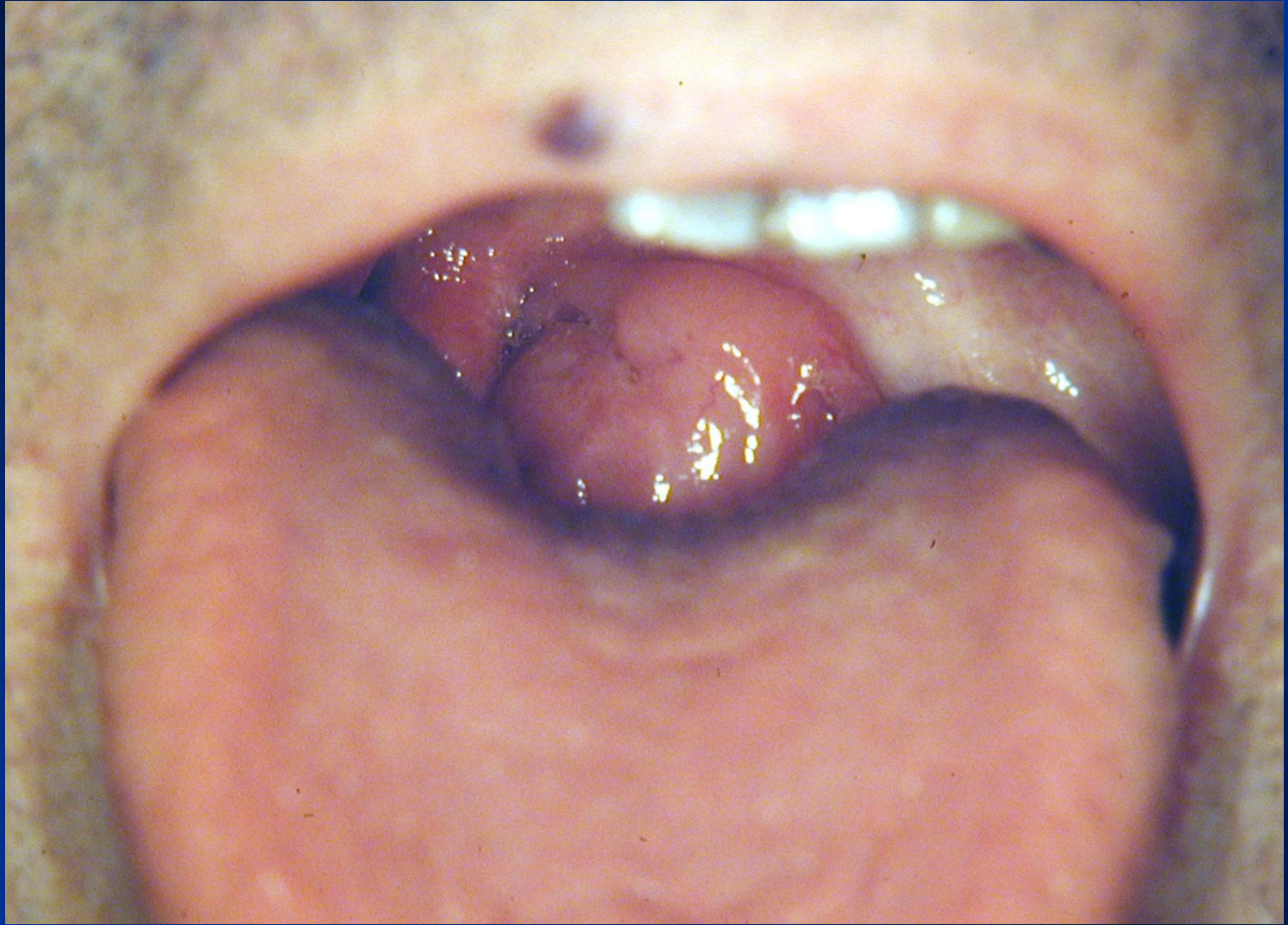Vena cava superior
syndrom

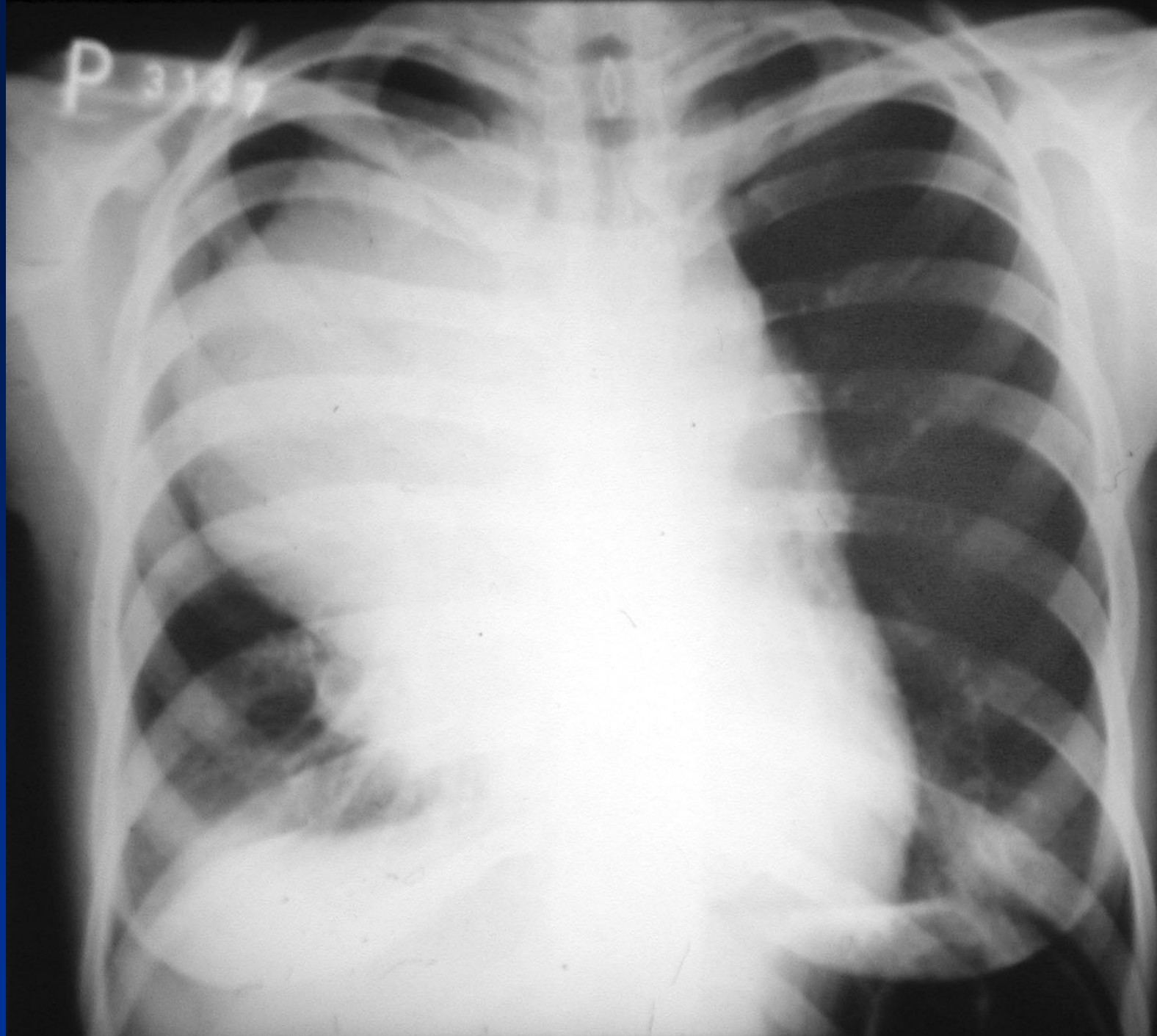
Swelling of face,
enlarged volume of
neck

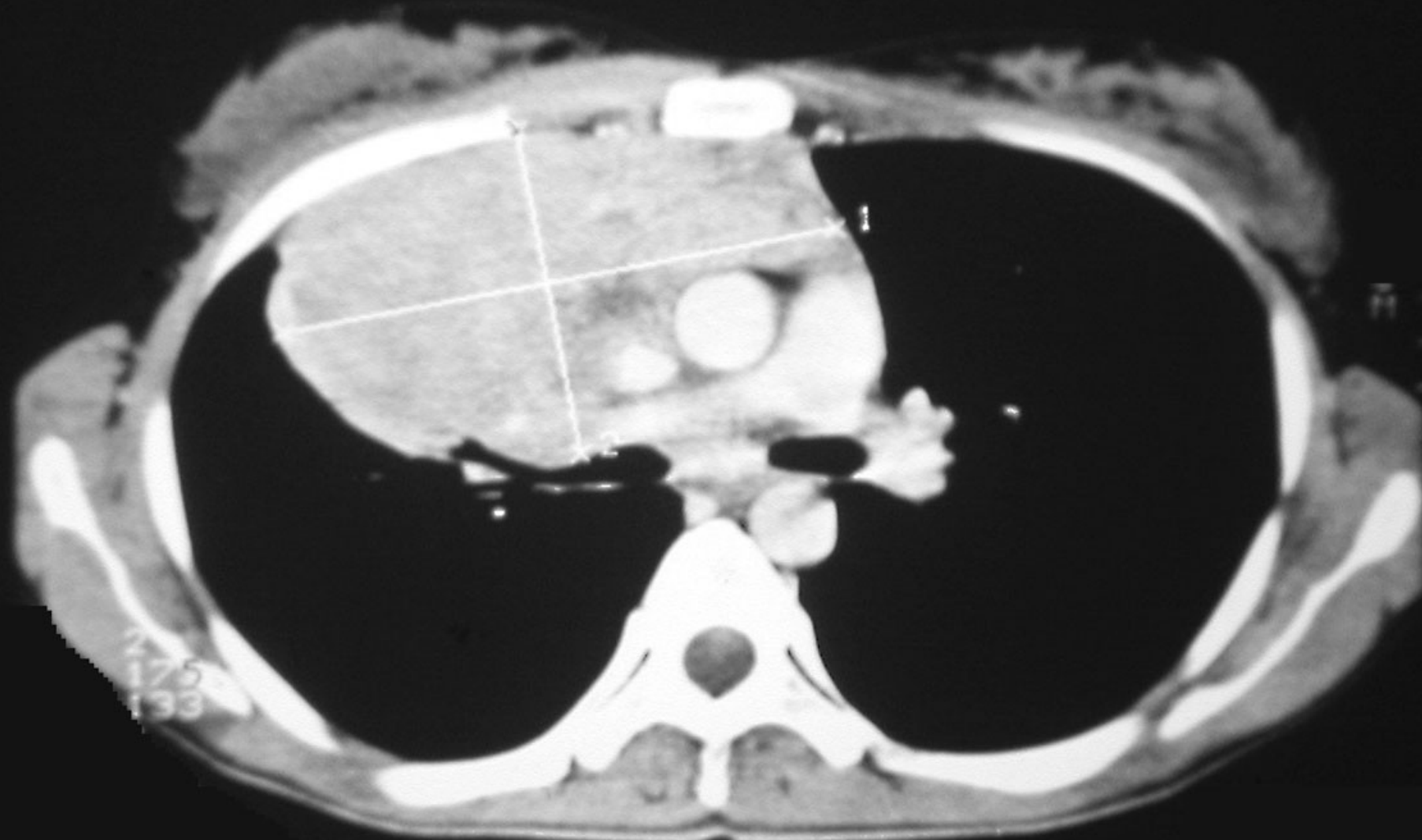
Visible collateral
veins between vena
cava superior and
inferior



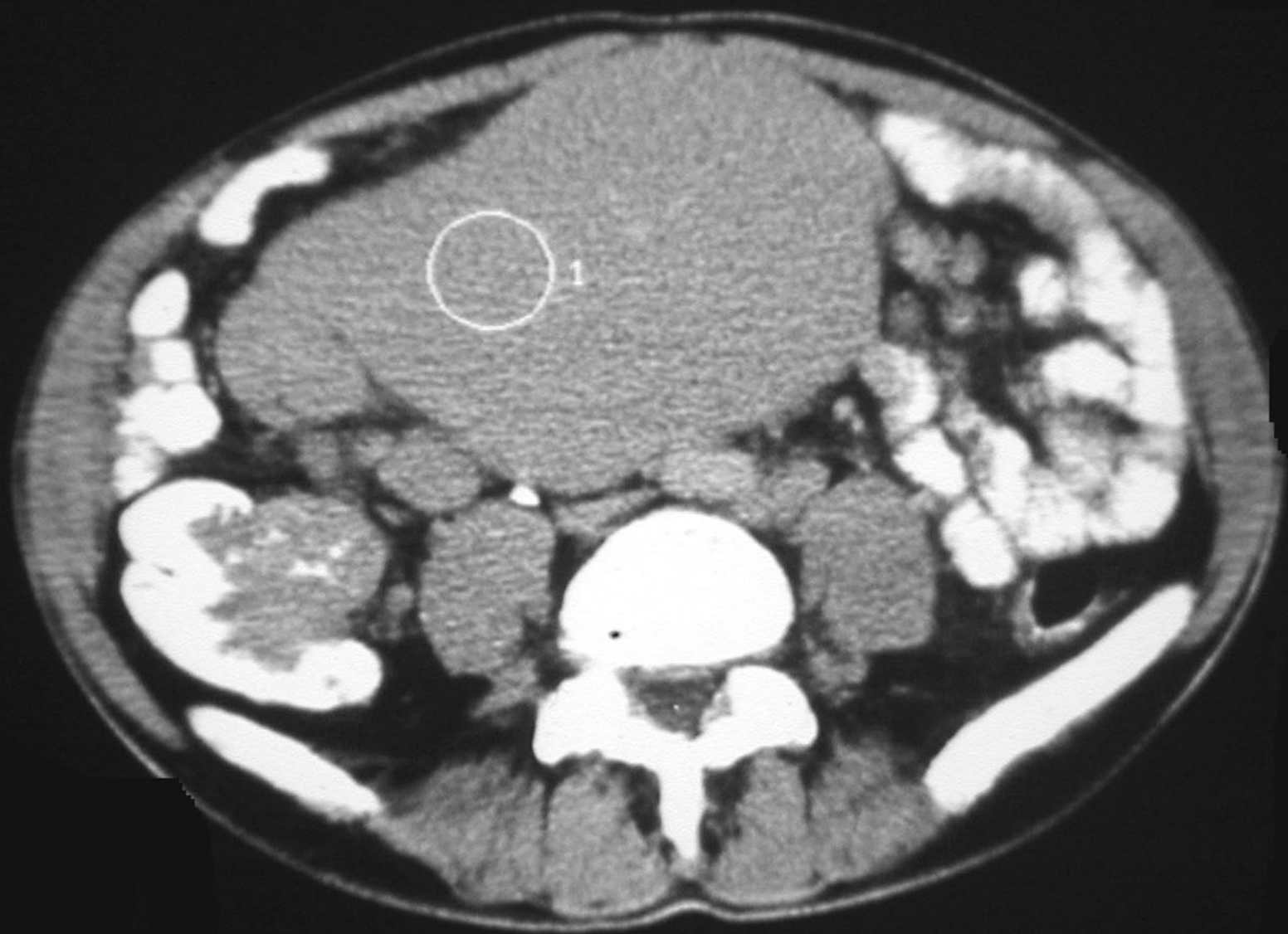


P 3187

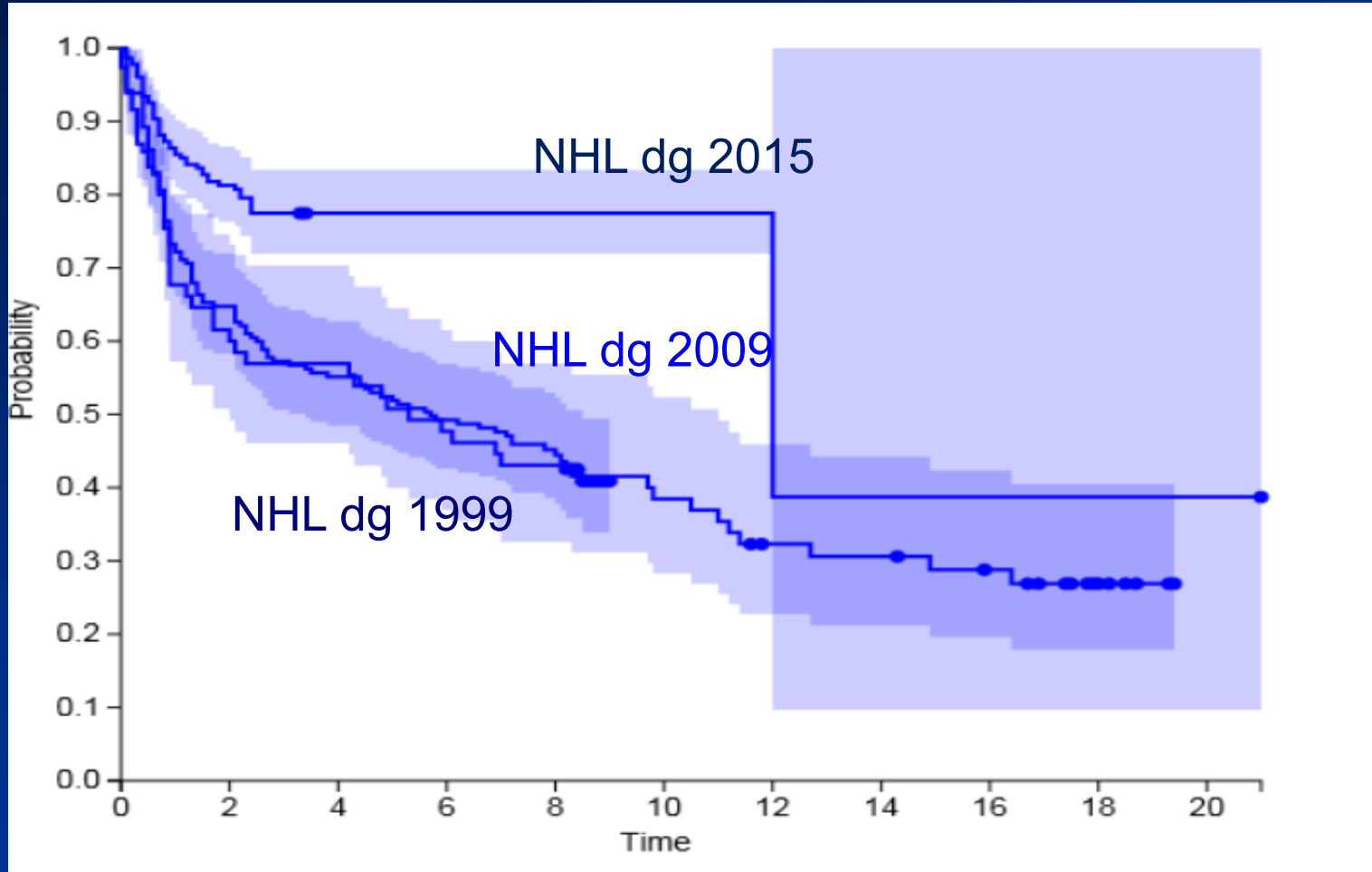




2
175
133



OVERALL SURVIVAL OF NHL PATIENTS (NIHIL; CLSG)



PROGNOSIS OF THE PATIENT WITH LYMPHOMA IS BASED ON:

- Histology
- Performance status according to ECOG/WHO
- Laboratory examination
- Physical examination, imaging (CT, MRI, US±PET)
- Bone marrow examination (trephine biopsy)

Extent of disease = clinical stage

STAGING - ANN ARBOR CLASSIFICATION (modified)^{1,2,3}

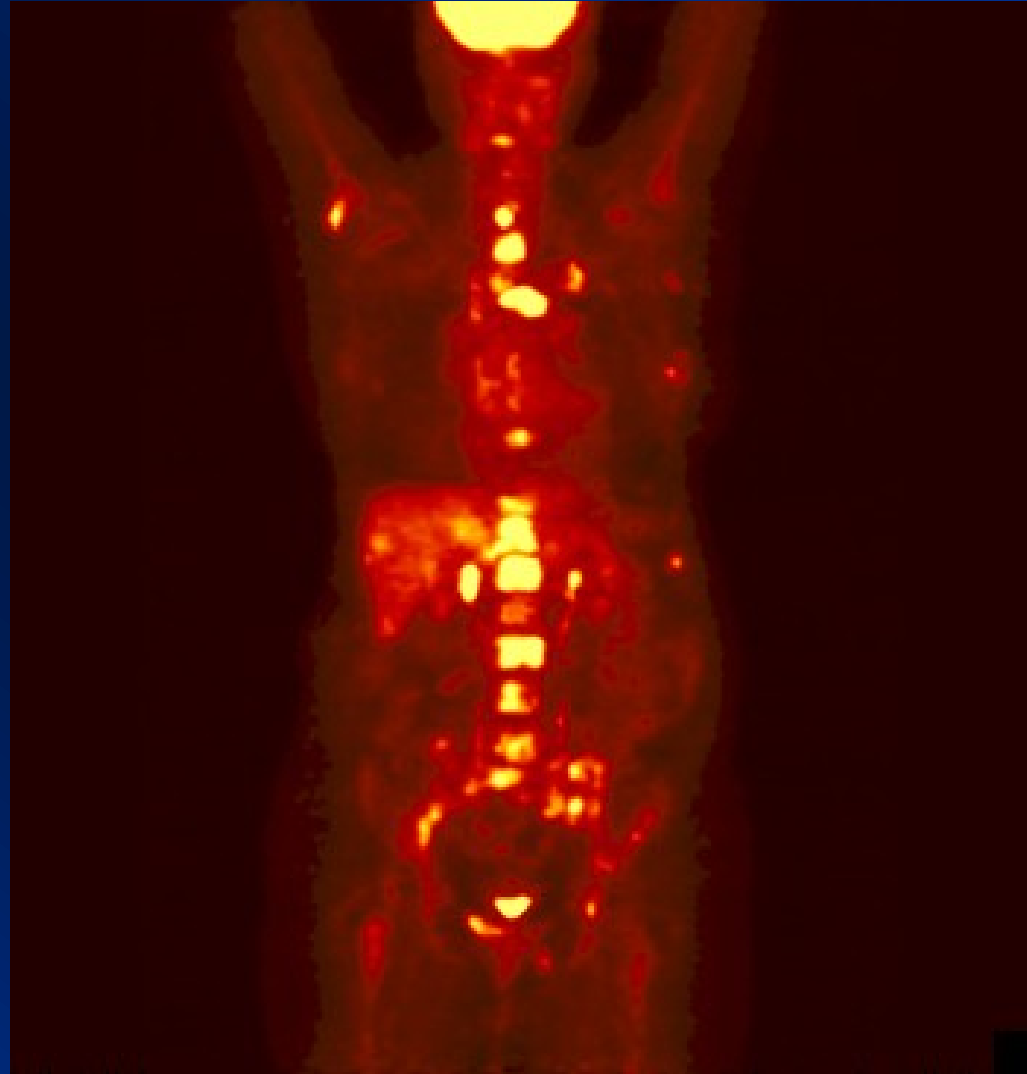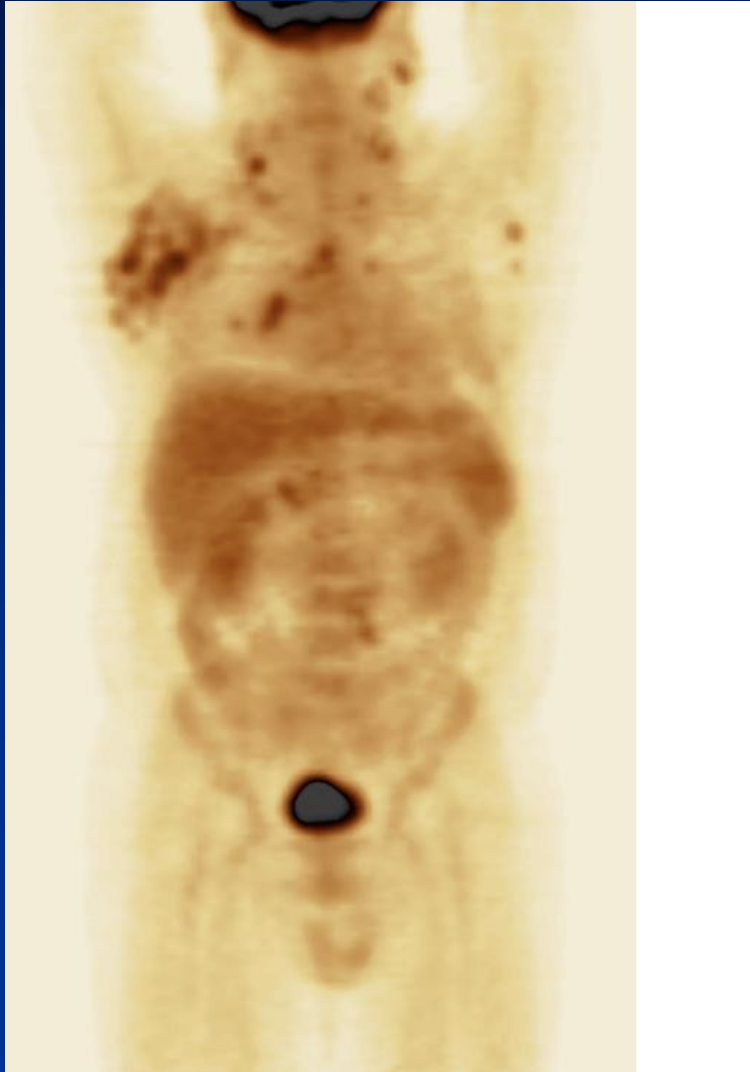
Stage I	Involvement of 1 lymph nodes (LN) group or 1 extralymphatic organ (EN) (IE)
Stage II	Involvement 2 or more LN regions on the same side of diaphragm or LOCALISED involvement of 1 EN organ (IIE) including lymph node involvement of 1 or more groups LN on the same side of diaphragm
Stage III	Involvement of LN or lymphatic organs (spleen, Waldeyer circle) on both side of diaphragm, which can be accompanied with LOCALISED involvement of 1 EN organ (IIIE)
Stage IV	<u>Difuse or disseminated</u> involvement of 1 or more EN organs or tissues with or without LN involvement

¹Carbone PP, Kaplan HS, Musshoff K, et al. Report of the Committee on Hodgkin's Disease Staging Classification. Cancer Res 1971; 31(11):1860-61.

²Rosenberg SA. Report of the committee on the staging of Hodgkin's disease. Cancer Res 1966; 26: 1310.

³Lister TA, Crowther D, Sutcliffe SB, et al. Report of a committee convened to discuss the evaluation and staging of patients with Hodgkin's disease: Cotswolds Meeting. J Clin Oncol 1989; 7(11):1630-36.

FDG-PET (^{18}F Fluorodeoxyglucose - positron emission tomography)



FDG-PET – what can we really see???

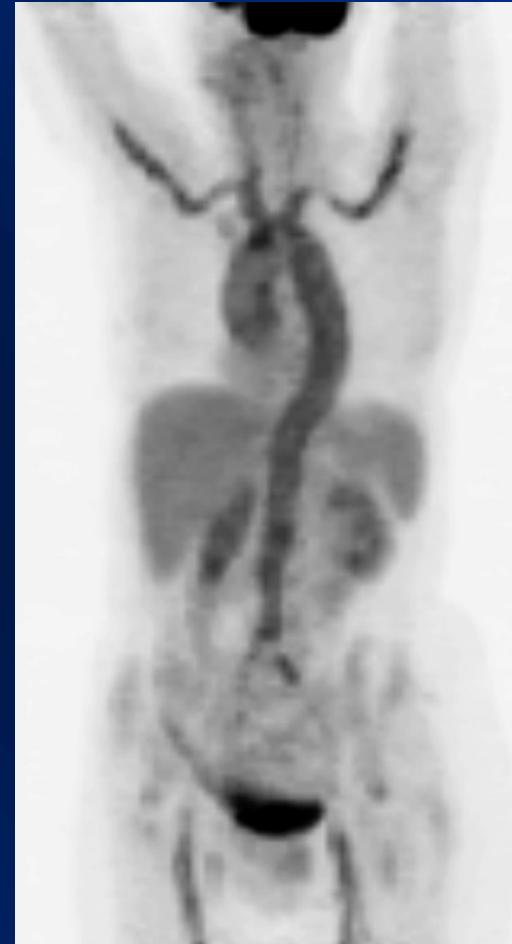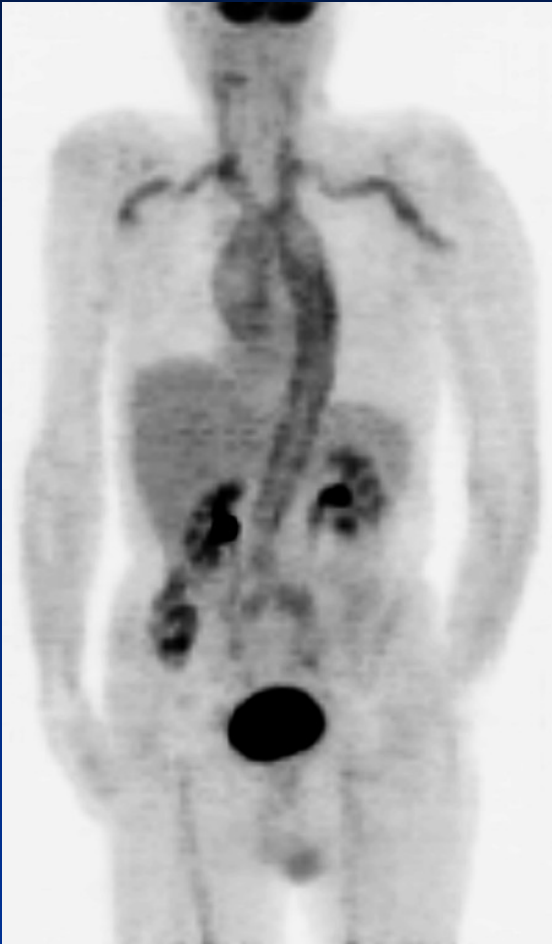PET image/scan

REALITY



PET is sensitive but not specific for tumor!

Fever of unknown origin – vasculitis proven by FDG-PET



WHY IS IMPORTANT TO KNOW STAGE OF THE LYMPHOMA?

Limited stage
I and II

vs.

Advanced stage
III a IV



TREATMENT STRATEGY (I+II vs III+IV stage) IS
SIGNIFICANTLY DIFFERENT
IN ALL LYMPHOMA SUBTYPES!

BASIC INFORMATION ABOUT HISTOLOGICAL CATEGORIES

LYMPHOPROLIFERATIONS = malignancies from lymphoid tissue

- LYMPHOMAS

- Morbus Hodgkin (Hodgkin's lymphogranuloma) ~30%
 - Classical (~95%)
 - Nodular lymphocyte predominant
- NonHodgkin's lymphomas (NHL) ~70%
 - B-NHL (~90%)
 - T-NHL (~10%)

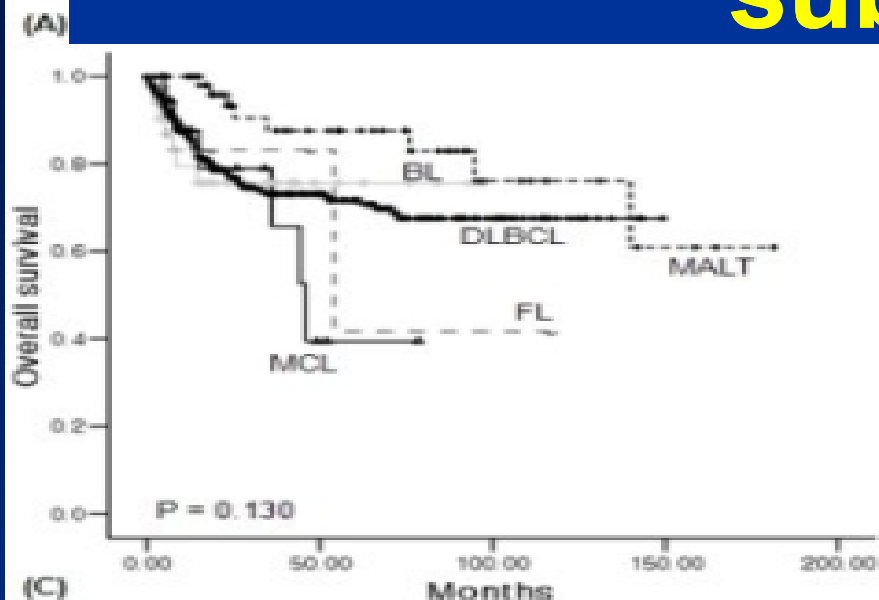
- LYMPHATIC LEUKEMIAS

B-line: B-CLL, Hairy cell, prolymphocytic leukemia

T-line: T-prolymphocytic leukemia, T-LGL, adult T-cell leukemia

- MULTIPLE MYELOMA

Survival according lymphoma subtype



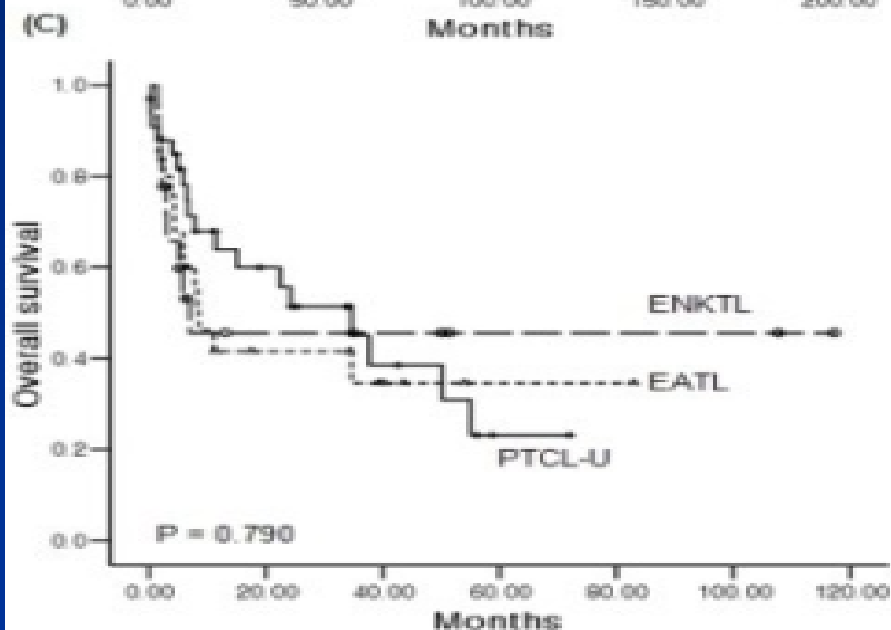
MCL – mantle cell lymphoma

BL – Burkitt lymphoma

DLBCL- diffuse large B-cell lymphoma

FL –follicular lymphoma

MALT- mucosa associated lymphoma tissue lymphoma



ENKTL –extranodal NK/T lymphoma

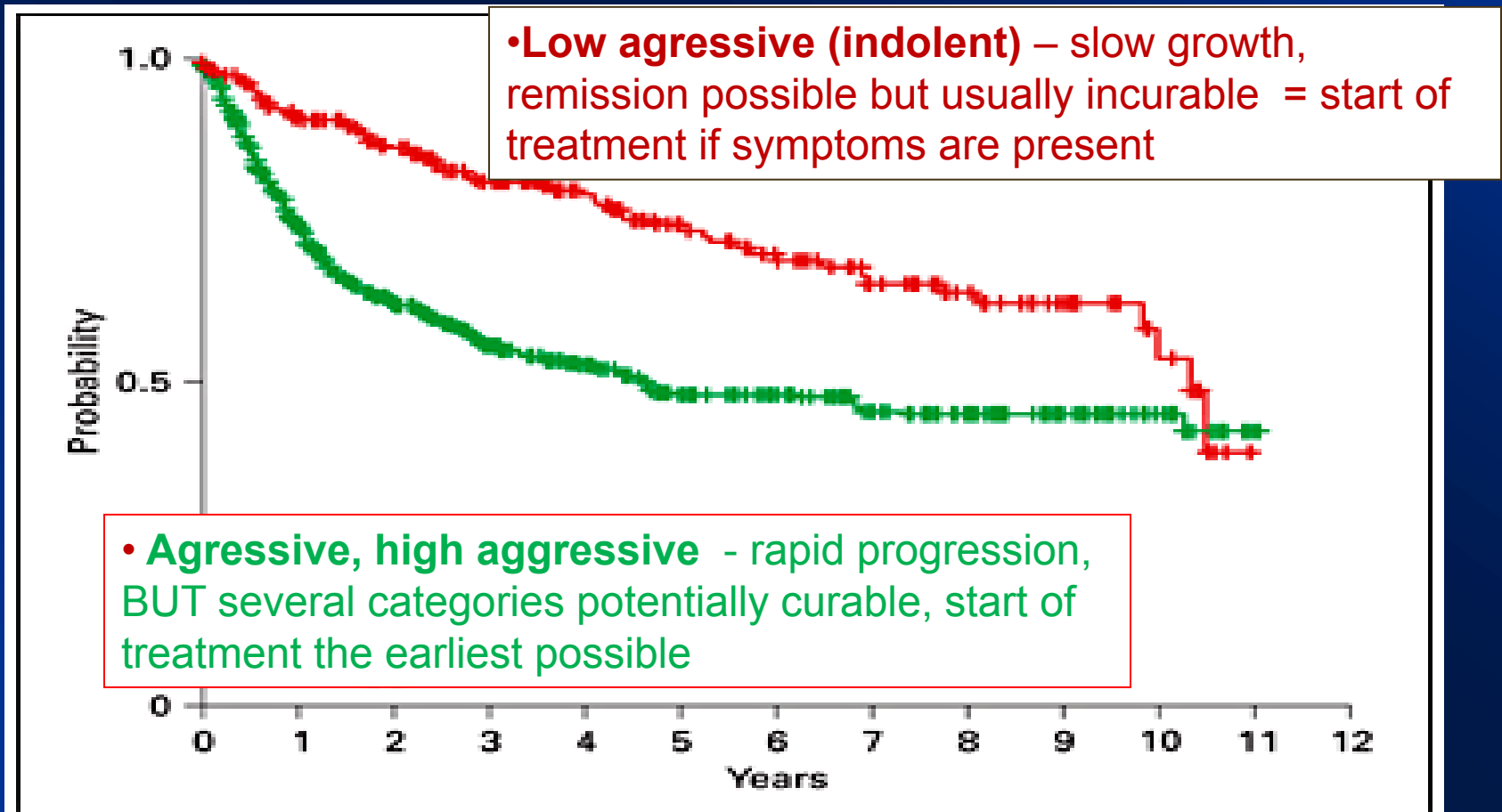
EATL- enteropathy associated lymphoma

PTCL U –peripheral T-cell lymphoma (unspecified)



Malignant lymphoproliferative diseases

- about 50 units (recent WHO 2008 classification)
- from practical point of view two subgroups:



LOW GRADE LYMPHOPROLIFERATIONS

B - line

Lymphoplasmacytic lymphoma
Hairy-cell leukemia
Chronic lymphatic leukemia (CLL)
Small lymphocytic lymphoma
(SLL/CLL)
Follicular lymphoma
Marginal zone lymphomas

T- line

T-cell large granular
lymphocytic leukemia (LGL)
NK chronic
lymphoproliferation
Mycosis fungoides/ Sézary
syndrom
T- cell lymphatic
leukemia/lymphoma
Primary cutaneous T-cell
lymphoma (CD30+)

LOW GRADE LYMPHOMAS

– basic characteristics and principles

- Overall survival even without treatment in years to 10 ys
- Radiotherapy indicated and with curative effect in limited extent (stage I or II)
- Advanced stages (III/IV) are generally incurable, chemotherapy-based (CHT) indicated and induces remission, BUT relapses are the rule
- Curative therapy has to be started immediately
- Non-curative treatment (CHT) initiated in symptomatic patients only

FOLLICULAR LYMPHOMA

clinical behavior

- Slow growing (sometimes vanish) lymphadenopathy with relapsing spontaneous remissions are not general symptoms
- Global median overall survival > BUT 20% dies during 2 years since diagnosis
- FL is considered incurable with chemotherapy (limited stages I/II) which is relevant only
- Cause of death – treatment toxic (~25-60%) to more aggressive N



Follicular Lymphoma – Principles of Therapy

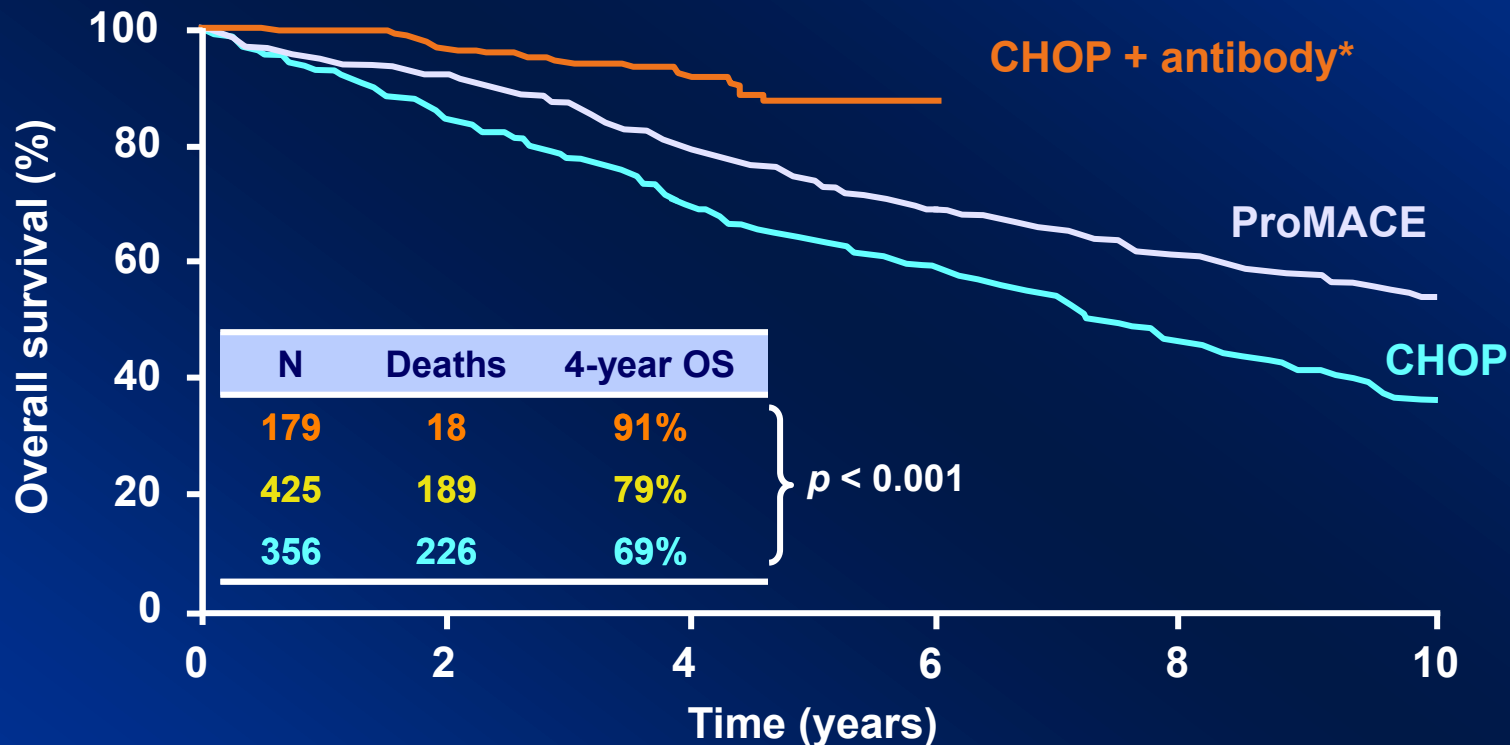
PRIMARY THERAPY (first line)

- Localised FL (stage I+II): IF RT 24Gy
- Advanced FL (stage III+IV):
 - /large tumor/: antiCD20+ chemotherapy + antiCD20 maintenance (2ys)
 - /low tumor/: watch and wait

THERAPY OF RELAPSE

- Chemotherapy + antiCD20 maintenance
- High-dose chemotherapy + autologous stem cell support
- **Allogeneic bone marrow transplantation**
- Radioimmunotherapy
- Radiotherapy even very low dose (~4Gy!!!)

Anti-CD20 antibody therapies have changed the course of FL



ProMACE: prednisone, methotrexate, doxorubicin, cyclophosphamide, etoposide

* SWOG 9911: CHOP + ¹³¹I-tositumomab;

SWOG 9800: CHOP + MabThera

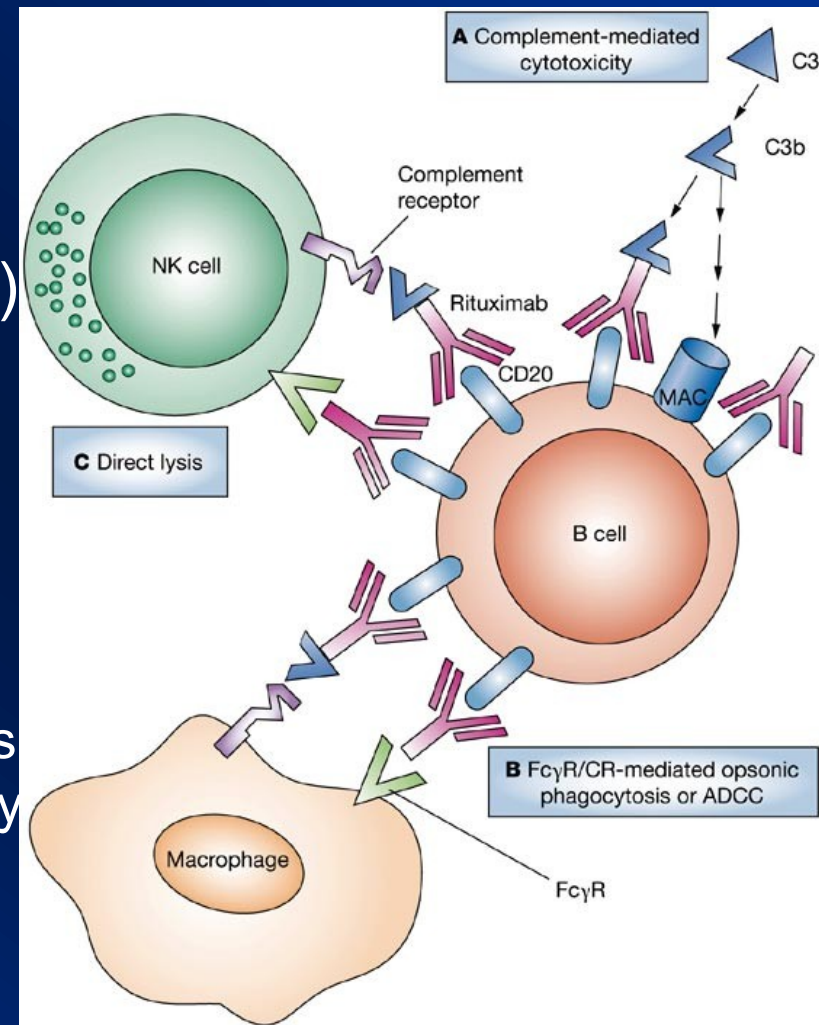
OS = overall survival

1. Fisher RI, et al. *J Clin Oncol* 2005; 23:8447–8452.

Anti CD20 monoclonal antibody

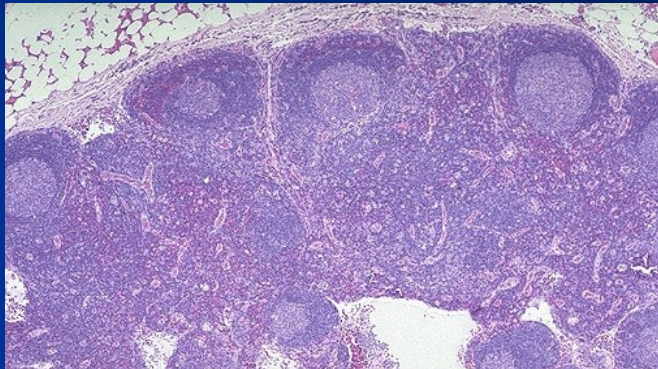
Rituximab – Mabthera[®], Rituxan[®]

- Chimeric humanized IgG1 type
- CD20 receptor present on surface of nearly all B-lymphoid cells
- including malignant lymphocytes
- Approved for clinical practice (FDA)
- R is standard component of treatment of CD20+lymphoma
- Favourable efficacy/toxicity ratio
- Mechanism of action
 - CDC (complement dependent cytotoxicity)
 - ADCC (antibody dependent cytotoxicity)
 - Apoptosis induction
 - Direct antiproliferative effect

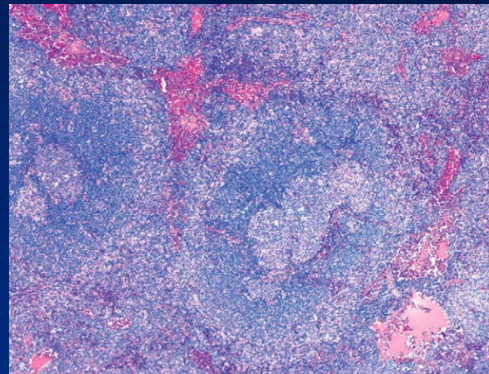


MARGINAL ZONE LYMPHOMAS (MZL)

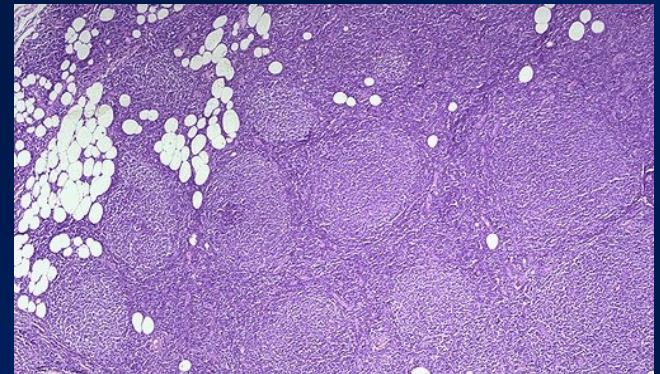
- **Nodal** – very similar to FL or SLL
- **Splenic** with/without vilous lymphocytes
 - Splenomegaly leading symptom
 - Treatment options: splenectomy
rituximab monotherapy
- **Extranodal (MALT)**



LYMPHADENITIS



MZL

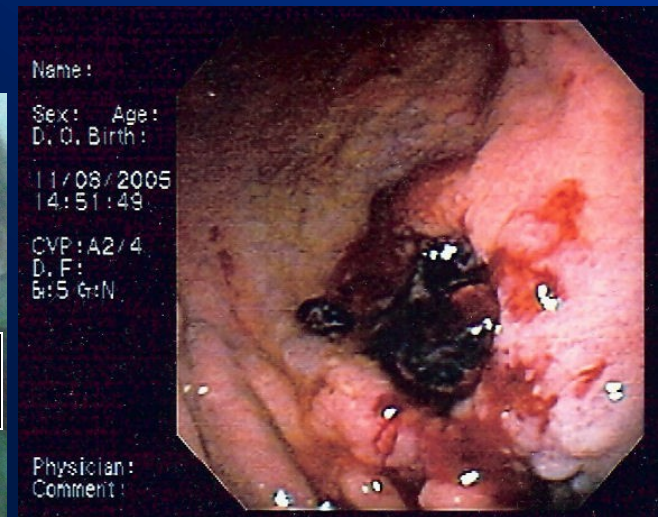
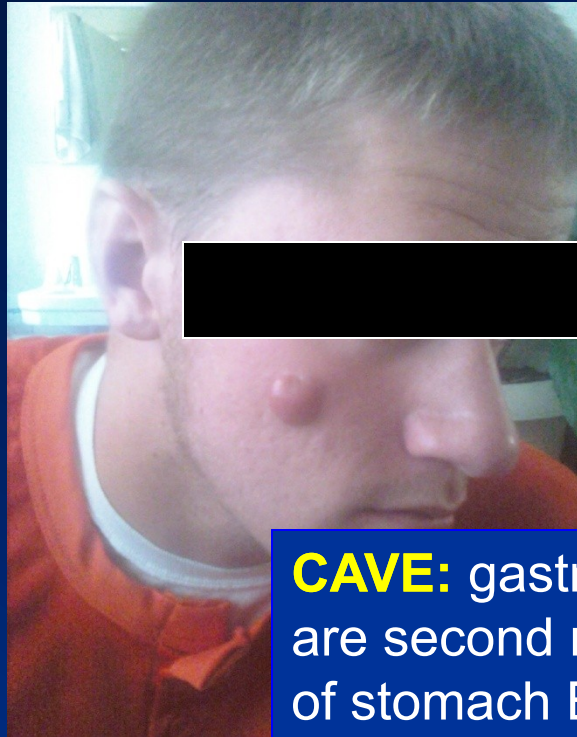
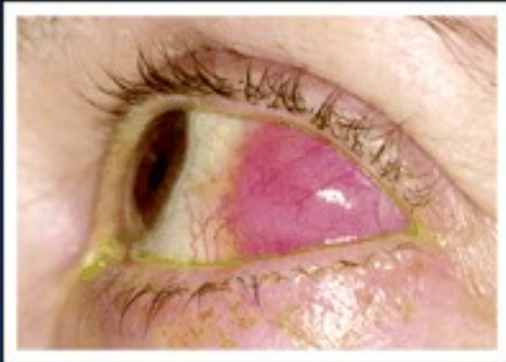
FOLLICULAR LYMPHOMA

MARGINAL ZONE LYMPHOMAS (MZL)

- **MALT – Mucosa associated lymphatic tissue lymphoma**
- **Etiology: antigen stimulation (H.pylori, Borellia, Chlamydia, HCV...)**
- **Dominating MALT-lymphomas of stomach**
- **Symptoms: „gastric ulceration“ (reccurent or non-healing)**

MALT- lymphomas (examples)



CAVE: gastric MALT or DLBCL are second most frequent tumor of stomach BUT with excellent curability!!!

MALT- lymphomas treatment principles

- **Limited stage (I and II)**
- **Antibiotics, curative radiotherapy (30Gy)**
- **Generalized stage (III and IV)**
treatment like in FL (RCOP/RCHOP)

IN STAGING IS SPECIFIC:

Multiple biopsy of mucosa (even normally looking)

Helicobacter pylori must be ALWAYS examined

AGGRESSIVE LYMPHOMAS

B line

Prolymphocytic B-cell leukemia
Multiple myeloma
Mantle cell lymphoma
Follicular lymphoma (grade III),
Diffuse large B-cell lymphoma
Primary mediastinal large B-cell
lymphoma
Burkitt lymphoma

- Some units are curative
- Rapid progression with short history
- Treatment indicated immediately

T line

Prolymphocytic T-cell
leukemia
Peripheral T-cell lymphoma
Angioimmunoblastic
lymphoma
Angiocentric lymphoma
Intestinal T-cell lymphoma
Anaplastic large T-cell
lymphoma
Hepatosplenic $\gamma\delta$ lymphoma
Paniculitis like T-cell
lymphoma

DIFFUSE LARGE B-CELL LYMPHOMA

- An aggressive subtype of lymphoma that typically originates in lymphoid tissues
- The largest subtype of NHL (~ 35%) with about 100,000 new cases per year worldwide
- Clinically and biologically a heterogeneous disease with recent data documenting at least 2 distinct subtypes
- Clinical course is characterized by aggressive, rapid progression and symptoms
- 50% long term cure with current standard therapy

DIFFUSE LARGE B-CELL LYMPHOMA

- Several morphological variants: centroblastic, immunoblastic, anaplastic
- Several subtypes according to WHO 2008
 - DLBCL
 - Primary mediastinal DLBCL
 - Plasmablastic lymphoma
 - EBV associated DLBCL in elderly
 - Primary DLBCL of CNS
 - T-cell histiocyte rich
 - Primary cutaneous leg-type
 - ALK+ anaplastický DLBCL
 - DLBCL associated with chronic inflammation
 - Intravascular DLBCL
 - Primary effusion lymphoma
 - HHV8 associated DLBCL

Borderline DLBCL

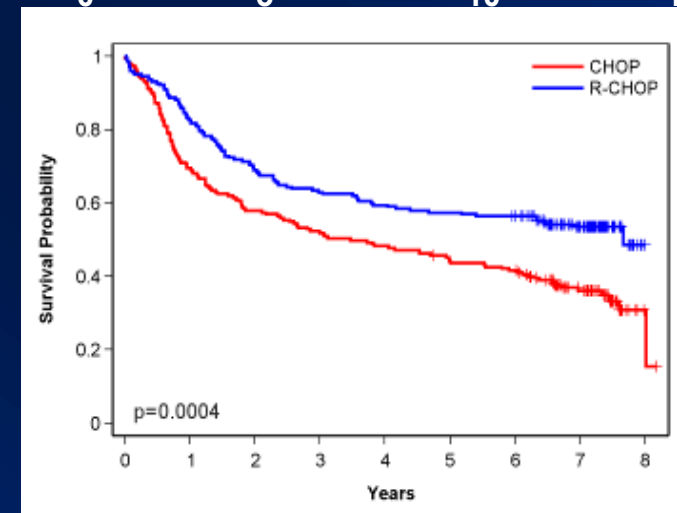
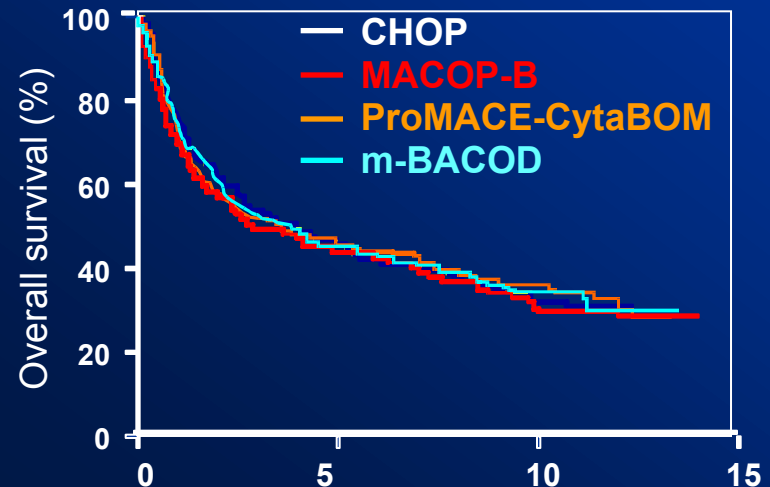
provisional entity to avoid contamination of „classical cases of DLBCL or BL
high-grade B-lymphoma between BL and DLBCL
double hit lymphoma (bcl2+ cmyc)
childhood DLBCL with cmyc
BL lacking cmyc

Gray zone lymphoma

mediastinal lymphoma
two morphological and immunophenotype features
B-cell transcriptional programme (BOB1, PAX5, OCT2)
activation programme: CD30+ CD15

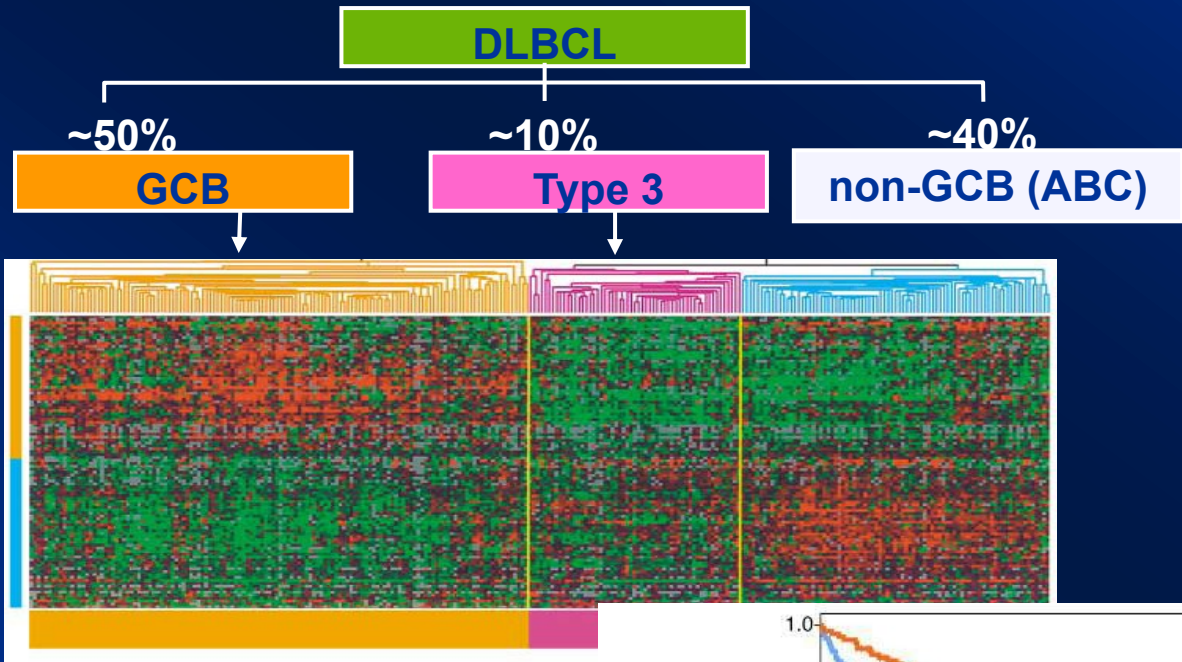
DLBCL – the global standard care

- CHOP (Cyclophosphamide, Doxorubicin, Vincristine, Prednisolone) was developed empirically over ~ 30 years ago
- Doxorubicin & Cyclophosphamide are considered to be essential drugs in high grade lymphomas
- R-CHOP is current global standard treatment with significant improvement in PFS and overall survival

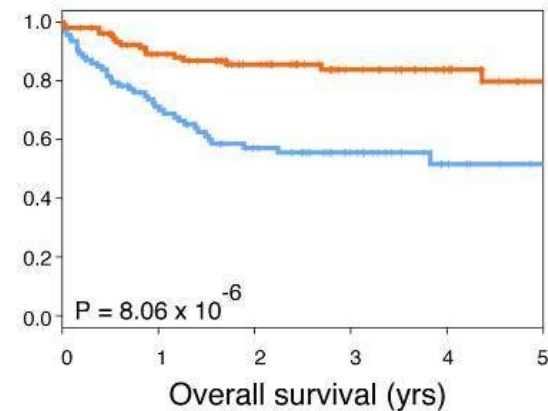
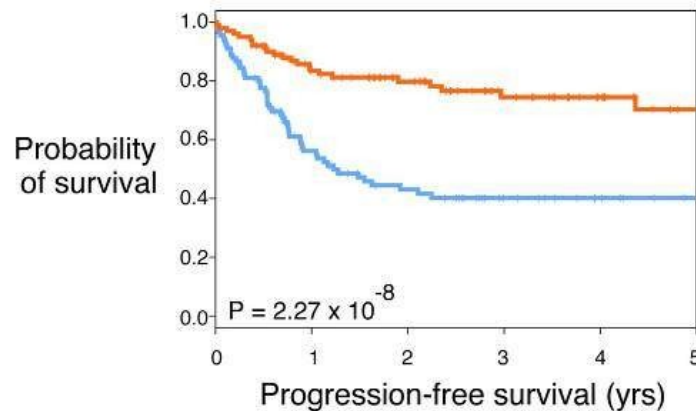


Patients over 60 (LNH98-5) 2002

DLBCL – molecular classification



1. Alizadeh et al, Nature 2000
2. Davis et al, Exp Med 2001
3. Rosenwald et al, NEJM 2002
4. Hans et al, Blood 2004
5. Ngo et al, Nature 2006
6. Lenz et al, J Clin Oncol 2007



Lenz et al, 2008

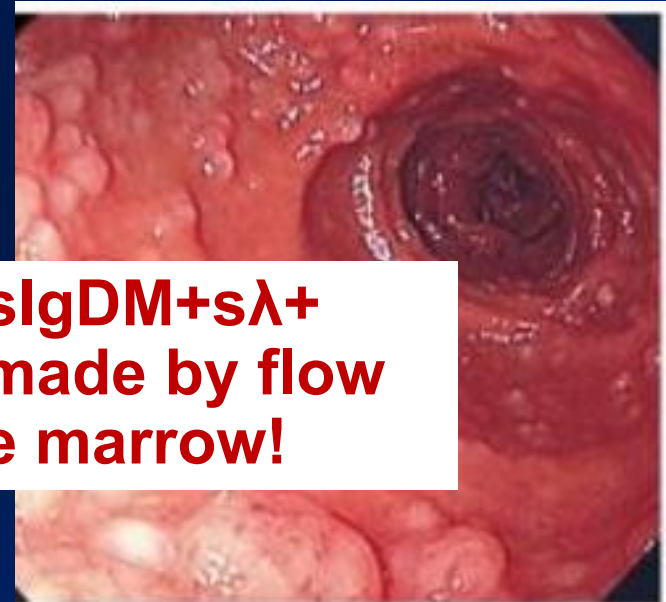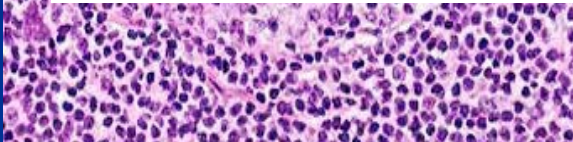
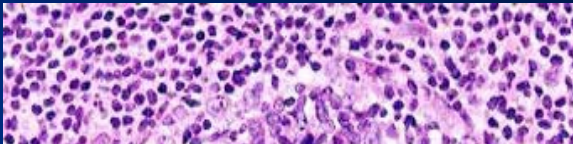
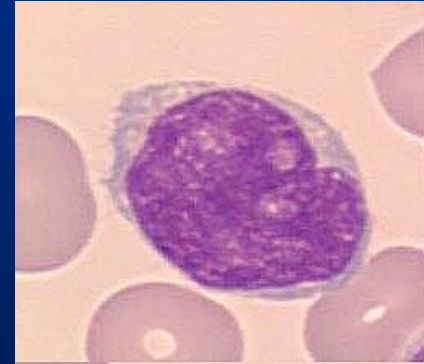
■ GCB DLBCL
■ ABC DLBCL

DLBCL – pathogenesis

- GC-DLBCL (germinal center) phenotype
 - Bcl2, c-myc
 - Rare mutation in BCR subunits
- nonGC (ABC=activated B-cell) phenotype
 - CARD11, BCL10, MALT1, NF- κ B
 - mutation in BCR receptor subunits (CD79a/CD79b)

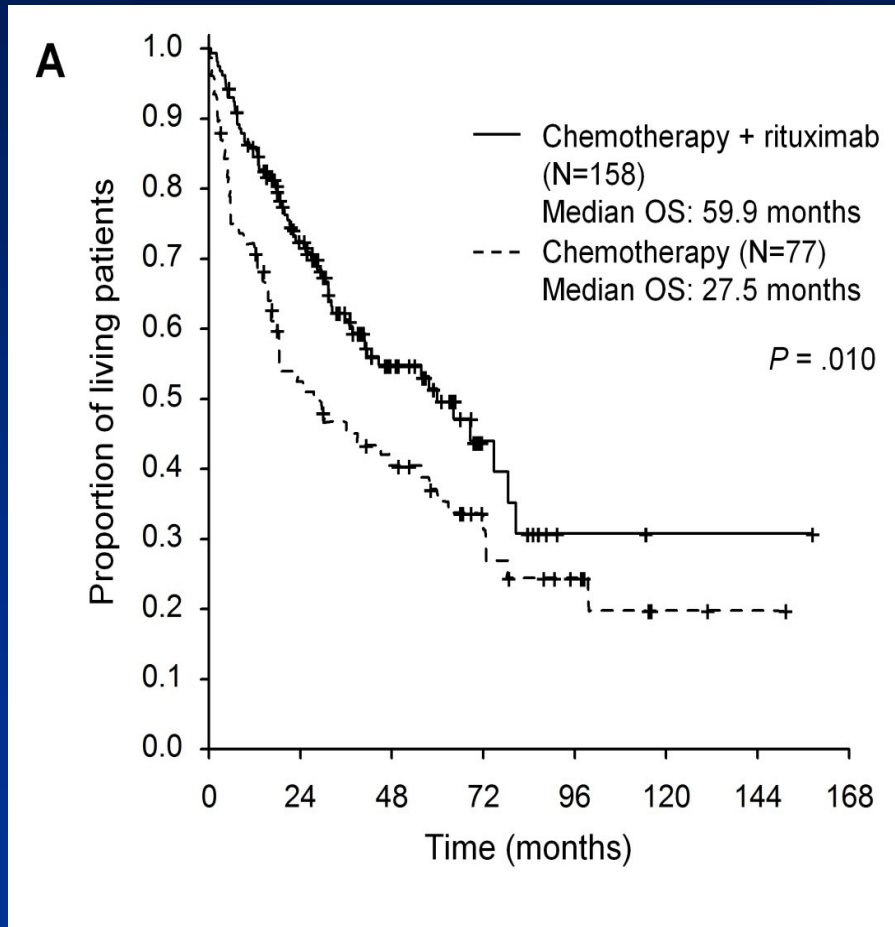
MANTLE CELL LYMPHOMA

- mantle cell lymphoma = lymphoma from „mantle cells“ of lymphatic follicle, CD20+
- Defined as a nosological unit since 1992
- 6-8 % of all Nonhodgkins´ s lymphomas
- Typically in older men
- Frequent extranodal involvement (>80%cases)
 - Blood, bone marrow
 - Gut (multiple lymphomatous polyposis)



CD5+10-19+20+23-79b+sIgDM+sλ+
Diagnosis of MCL can be made by flow
from blood and/or bone marrow!

Prognosis of MCL (Czech Lymphoma Database)



- Prognosis is poor
- New drugs are needed
- Chemotherapy has limited efficacy
- Targeted therapy
- Molecular pathogenesis
- t(11;14) is hallmark
- cyclinD1 overexpression

MCL- treatment

- intensive chemotherapy is recommended
R-MaxiCHOP/high dose Arac/ high dose BEAM
- transplantation therapy is indicated in younger patients
- majority of MCL patients not able to receive intensive treatment
- new „smart“ drugs (biological agents) focused on **BCR signaling** are efficace
- **Ibrutinib, bortezomib, temsirolimus** +/- rituximab

B-CELL RECEPTOR (BCR) SIGNALING

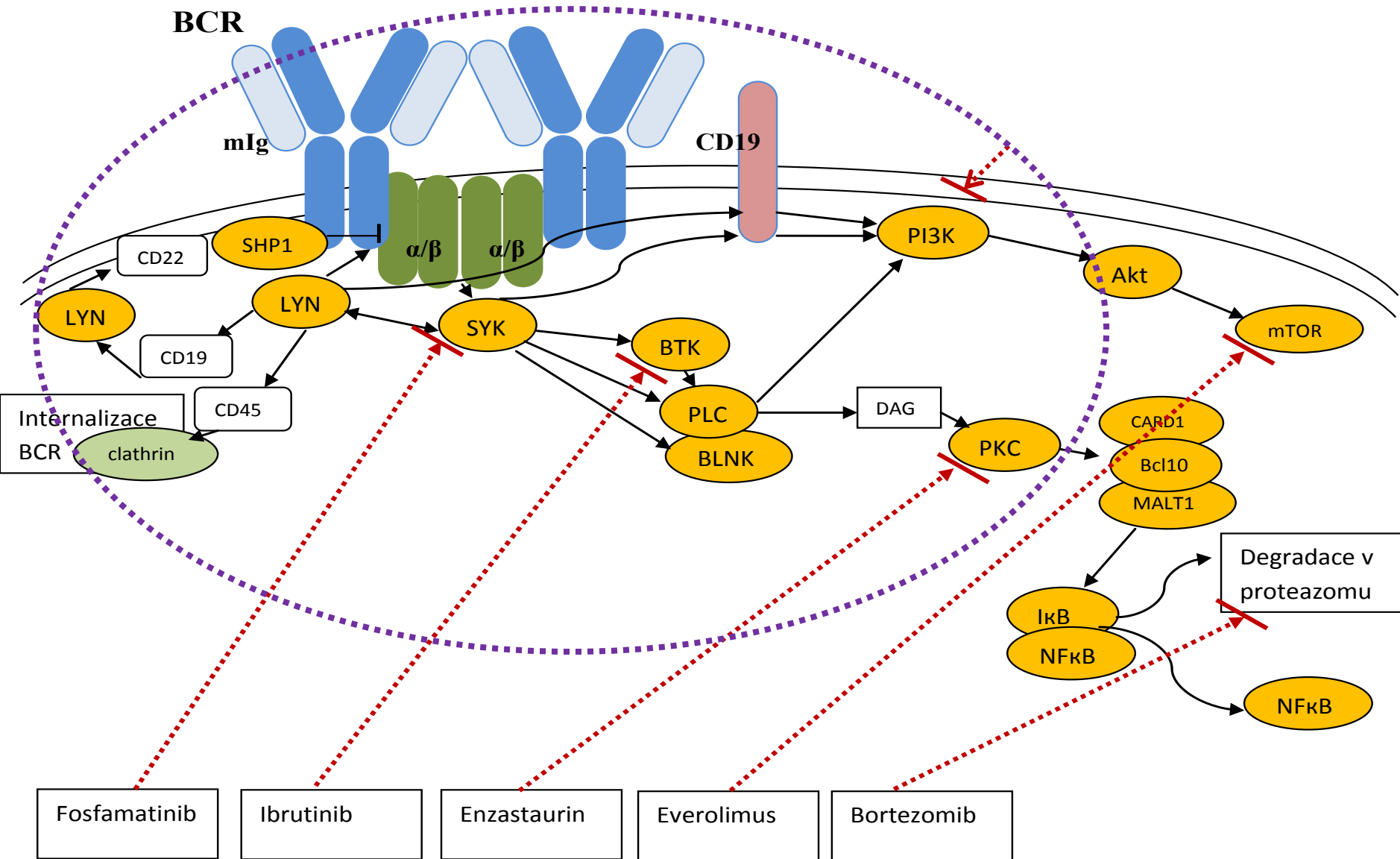


Schéma upraveno dle Gold 2010 a Roschewski 2012.

BCR signaling

Active BCR signaling

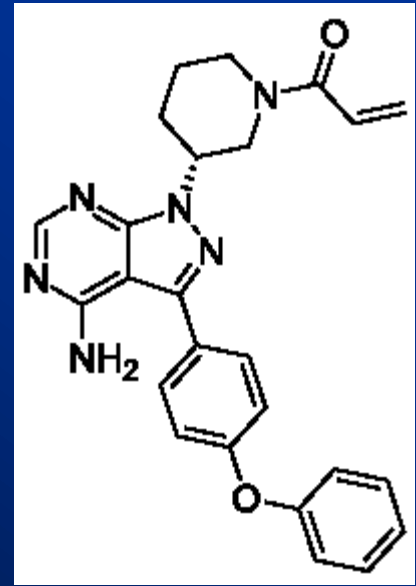
- Antigen driven
- BCR immobile clusters
- activation of downstream pathways NF- κ B, PI3, MAPkinase
- NF- κ B activated by BTK
- ABC-DLBCL (BTK inhibitor)

Tonic BCR signaling

- antigen independent, necessary for B-cell survival
- BCR freely mobile
- namely PI3 pathway
- Burkitt lymphoma

IBRUTINIB

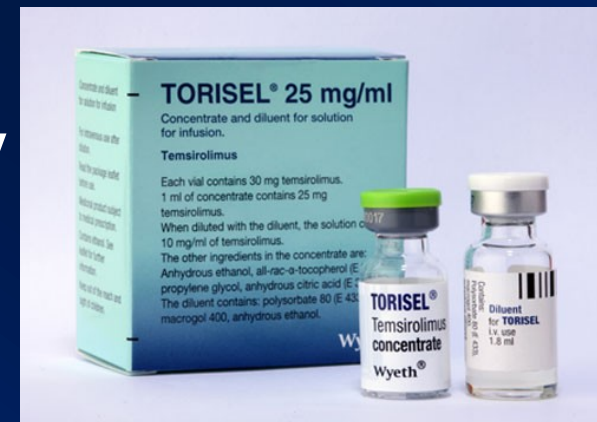- Irreversible inhibitor of Bruton's tyrosine kinase (BTK)
- Inhibition of autophosphorylation and phosphorylation by physiological substrate, blockage of phosphorylation of PLC γ , ERK (extracellular signal-regulated kinase), PI3K, NF- κ B...
- Proliferation inhibition, triggering of apoptosis
- Increase resistance to microenvironment signals



TEMSIROLIMUS (Torisel®)



- Selective inhibitor mTOR –
- protein kinase (mammalian target of rapamycin)
- Inhibition mTOR → cell cycle arrest in G1 and angiogenesis (VEGF)
- PI3Kinase/Akt/mTOR pathway – konst. active in MCL

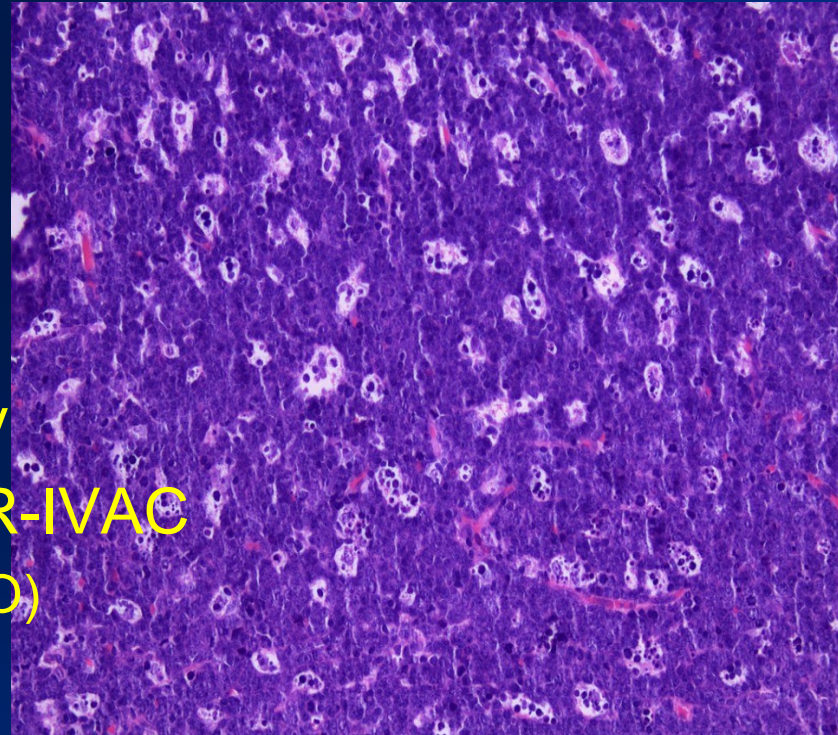


BURKITT LYMPHOMA

- Very rapidly growing; aggressive; high-grade B-cell lymphoma
- Rare disease in central Europe
 - Endemic (Africa, young boys, jaw or facial mass, EBV associated)
 - Sporadic (any age, abdominal mass)
 - Epidemic (immunodeficiency associated)
- Different behavior compared to DLBCL
- Abdominal symptomatology (intususception, appendicitis-like)
- BM and CNS involvement in 30% of cases
- Tumor lysis syndrome (!)
- CR 80%, long-term survival 50%

BURKITT LYMPHOMA

- „Starry sky“ morphology (medium-sized lymphocytes)
- WHO recognizes:
 - Burkitt lymphoma with plasmacytoid differentiation
 - Atypical Burkitt/Birkitt-like lymphoma
 - Phenotype: CD10+, bcl6+, bcl2-, CD20+, sIgM+, Ki67≥95%
- t(8;14) ~80% pts
- c-myc translocation
- Therapy: intensive chemotherapy
- Magrath protocol: R-CODOX-M/R-IVAC
 - (MTX+ CHOP; high dose AraC + IFO)



PRIMARY CNS LYMPHOMA

- Rare type of aggressive lymphoma; about 4% of CNS tumours and about 4-6% of all extranodal lymphoma (1% of all lymphoma)
- Localization: most common in hemispheres (38%), thalamus and basal gangliae (16%), c.calosum (14%)
- Median age 60-65 ys
- Belong to lymphomas with the worst prognosis (5-year OS 30-50%)
- Histologically: DLBCL in 95% cases

PRIMARY CNS LYMPHOMA

- Symptoms: neurological deficits, epi-paroxysms, attention, lethargy
- Diagnosis: MRI (typical pattern)+ stereotactic biopsy
- Corticoids given in antiedematic setting can completely destroy tissue for histological evaluation!!!!
- Treatment: cytostatics must have sufficient level in CSF
 - high-dose MTX (3g/m²) and AraC (2g/m²) + whole brain radiotherapy (24-36Gy)

T-CELL LYMPHOMAS

– Nodal

- PTCL –NOS peripheral T-cell lymphoma not otherwise specified (25%)
- ALCL anaplastic large cell lymphoma (12%)
- AITL angioimmunoblastic lymphoma (19%)

– Extranodal (tissue tropism)

- Hepatosplenic $\gamma\delta$ lymphoma (1.4%)
- Enteropathy associated T-lymphoma (EATL) (5%)
- Panniculitis-like T-cell lymphoma (0.9%)

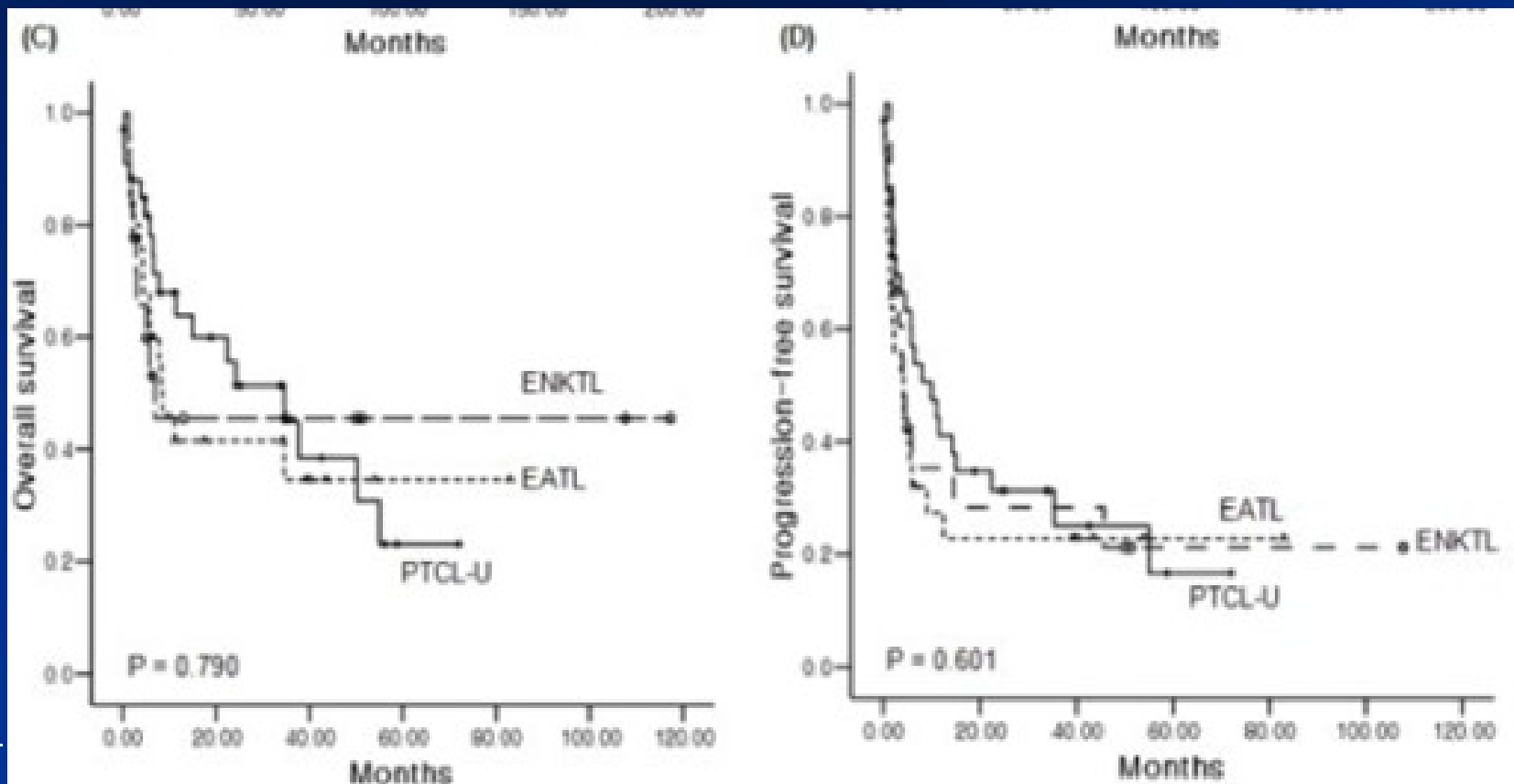
– Leukemic

- Adult T-cell leukemia, LGL-leukemia, NK-cell leukemia, T-prolymphocytic leukemia

T-CELL LYMPHOMA - prognosis

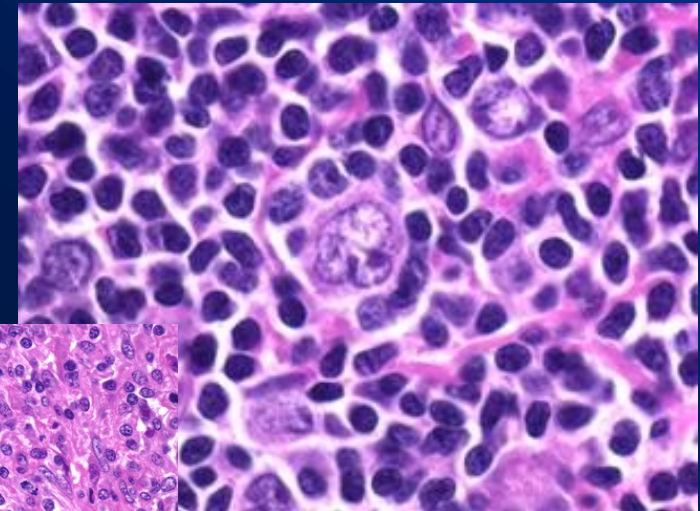
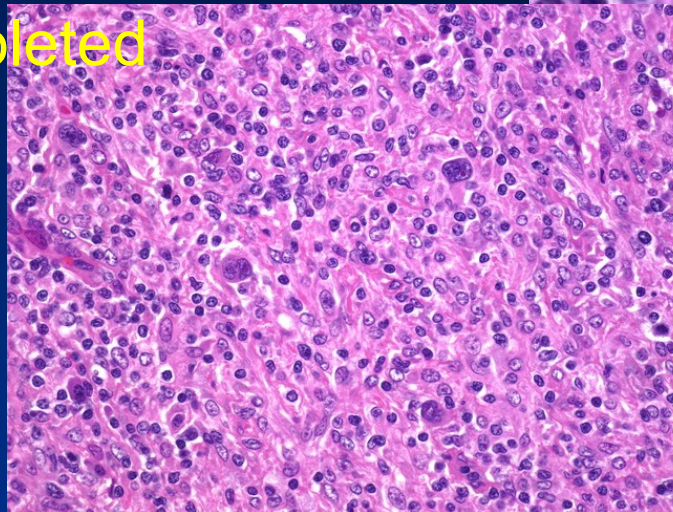
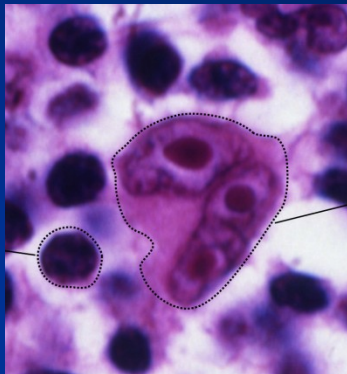
Non-cutaneous T-lymphoma have very poor prognosis

- Heterogeneity of units
- Too small populations for clinical trials
- Treatment used in B-cell lymphoma is insufficient



HODGKIN'S LYMPHOMAS

- CLASSICAL M.H.
 - CD30+, CD15+
 - Reed-Sternberg cc.
 - Nodular sclerosis
 - Mixed cellularity
 - Lymphocyte-rich
 - Lymphocyte-depleted
- NODULAR LYMPHOCYTE PREDOMINANT
 - CD20+
 - „popcorn“ cells



HODGKIN'S LYMPHOMAS

BASIC

- Pathological Hodgkin's cells (HRS) are derived from B-lymphocytes
- Peaks of incidence around 20 and 60 ys
- Hodgkin's lymphomas account for 30% of all lymphomas
- Highly curable disease

SYMPTOMS

- Lymphadenopathy with/without systemic symptoms:
- Fever
- Weight loss
- Itching
- Alcohol-related pain (LN)

HODGKIN'S LYMPHOMAS – treatment strategy

- Localised M.H.

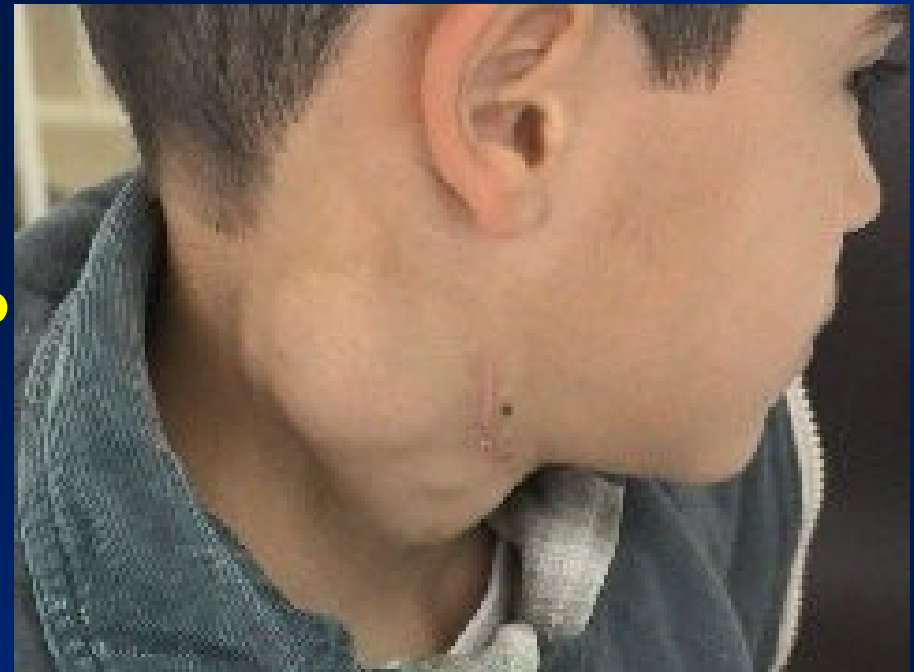2 x cycle of
chemotherapy ABVD
+ IF RT 20Gy

- Intermediate M.H.

2xABVD + 2x BEACOPP
escalated
+ IF RT 30Gy

- Advanced M.H.

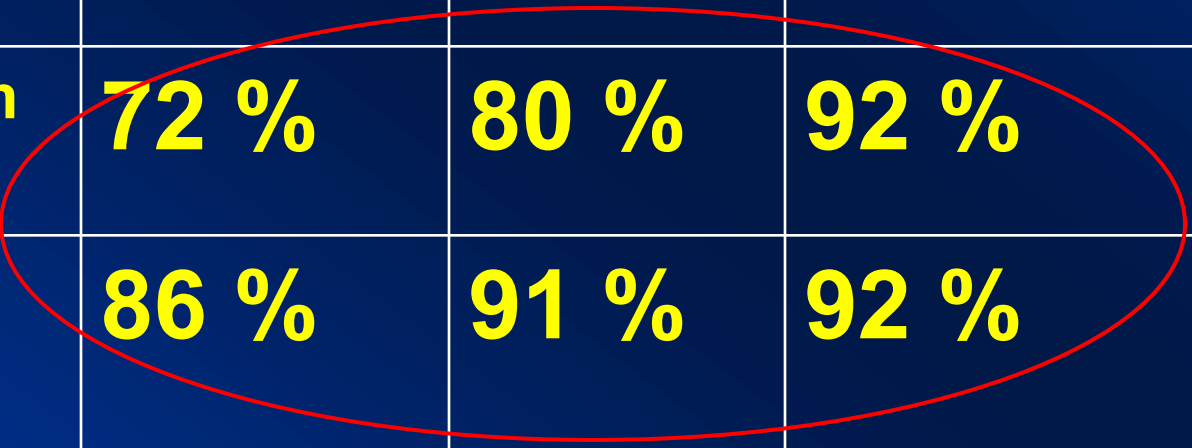
6 cycles BEACOPP
escalated



M.Hodgkin - Treatment results

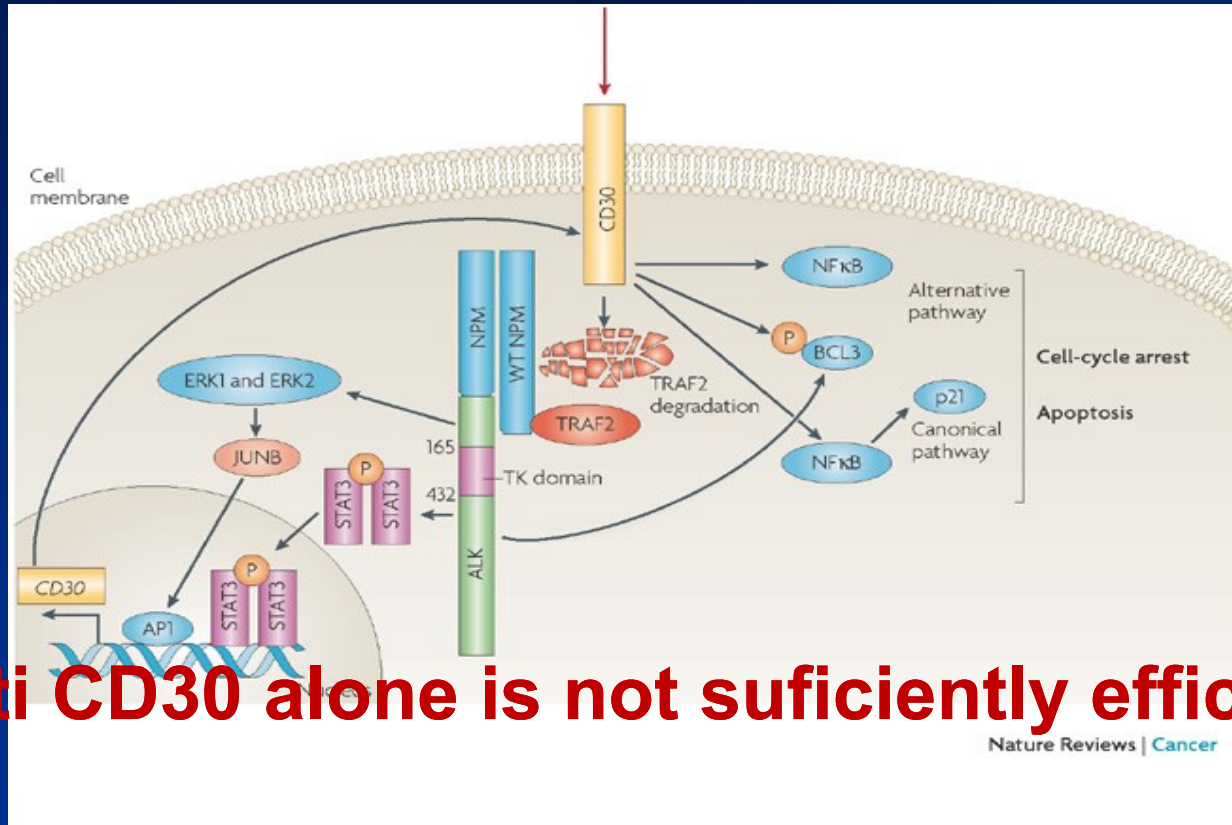
(DHG 2001)

Effect	COPP/ ABVD	BEACOP basal	BEACOP escalated
Complete remission	84 %	88 %	96 %
Progression	12 %	8 %	2%
3-ys symptom free survival	72 %	80 %	92 %
3-ys Overall survival	86 %	91 %	92 %



CD30 signal pathway

- CD30 is expressed
 - on RS-cells of M.Hodgkin, ALCL, and on primary cutaneous T-lymphomas



Brentuximab Vedotin Mechanism of Action



Brentuximab vedotin (SGN-35) antibody-drug conjugate (ADC)

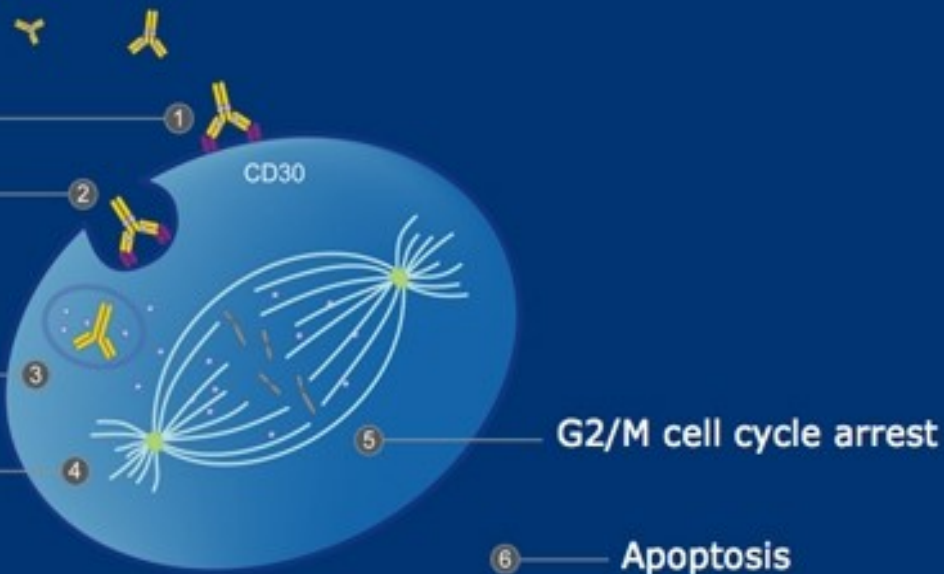
monomethyl auristatin E (MMAE), potent antitubulin agent
protease-cleavable linker
anti-CD30 monoclonal antibody

ADC binds to CD30

ADC-CD30 complex
traffics to lysosome

MMAE is released

MMAE disrupts
microtubule network



Long-term problems related to treatment of Hodgkin's disease

- Increased incidence of secondary malignancies
- Damage of gonadal functions (sterility)
- Long-term adverse events (toxicity)
cardiomyopathy, lung fibrosis,
myelodysplastic syndrome

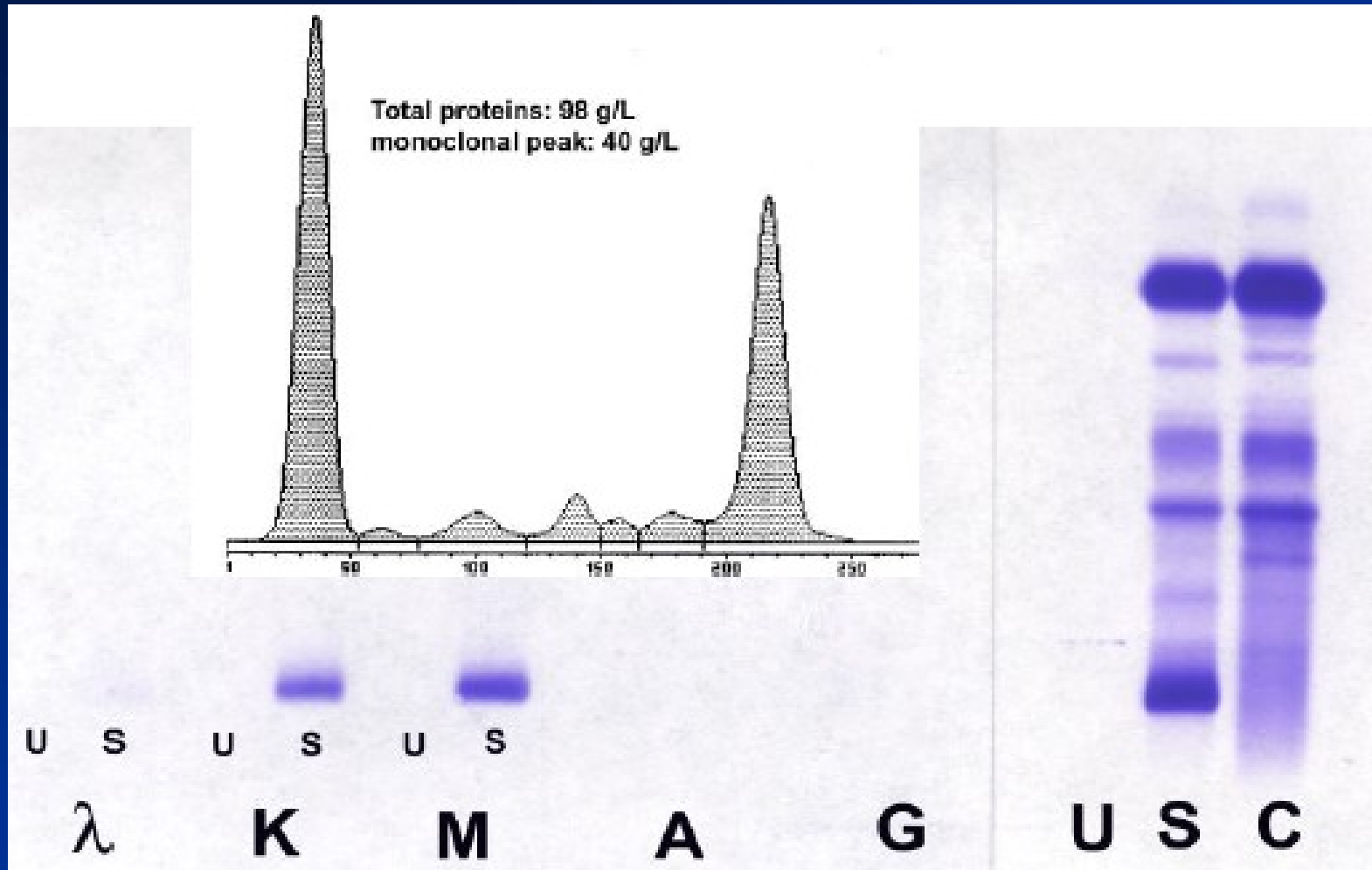
MULTIPLE MYELOMA - SYMPTOMS

Clonal expansion of malignant plasmocyte-derived cells
- local infiltration of bone marrow and bones
- production of monoclonal Ig

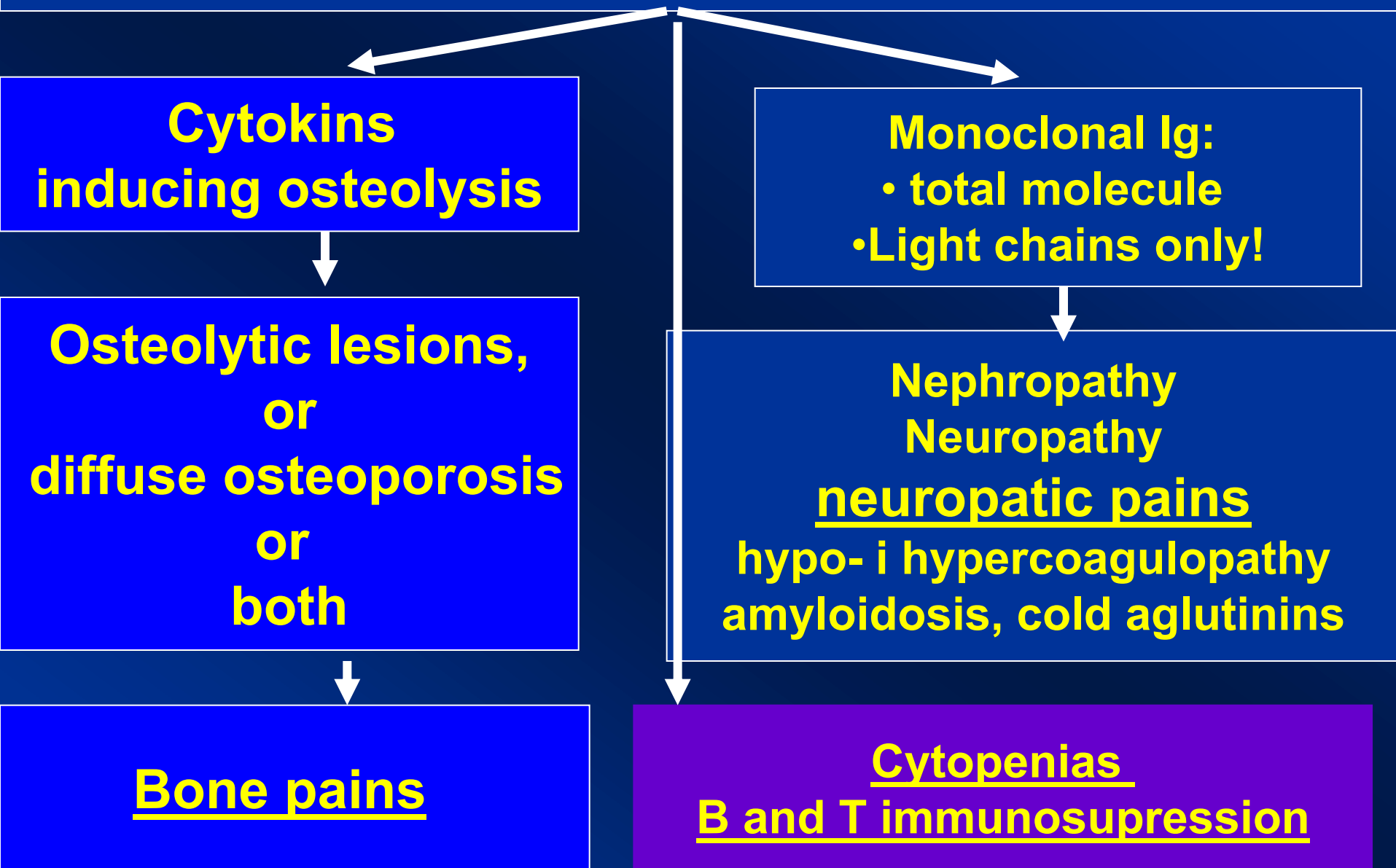
Disease damaging (really multiple):

- Bones (pains, fractures)
- Kidneys (renal failure, nephrotic syndrome)
- Peripheral nerves
- Etc.....

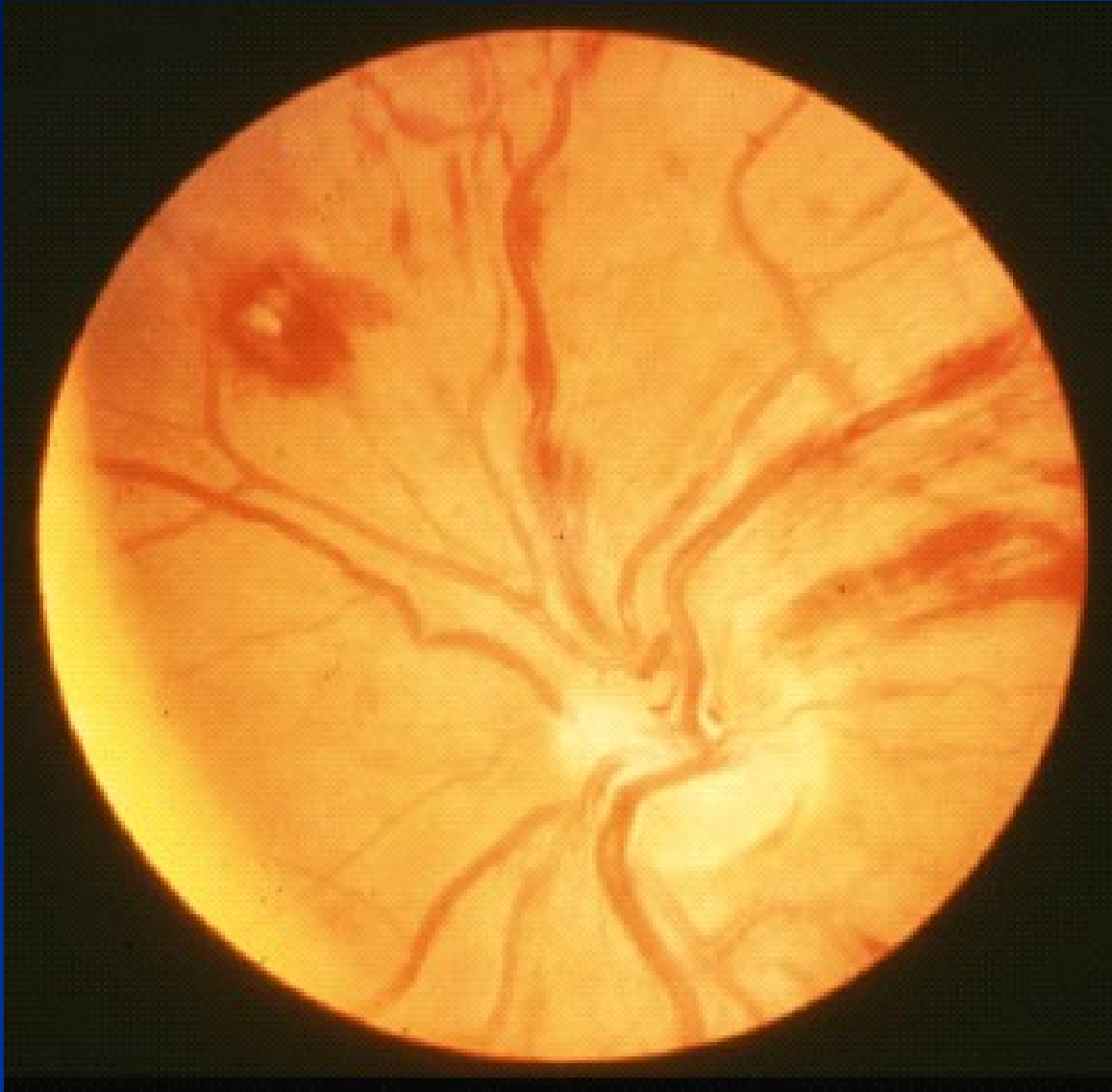Immunofixation and electrophoresis with densitometry (quantification) of monoclonal immunoglobuline



Clinical symptoms of myeloma cells



Fundus paraproteinemicus



MM criteria acc. Durie and Salmon, 1975

Big criteria	Small criteria
1) Plasmocytoma (histology)	a) 10 – 30 % plasmocytes in BM
2) Plasmocytes in BM > 30 %	b) M-Ig fewer than under point 3
3) M-IgG > 35 g/l, IgA > 20 g/l or light chains in urine > 1g/24h	c) Osteolytic lesions d) Decreased levels of normal Igs: IgM < 0,5 g/l, IgA < 1,0 a IgG < 6,0 g/l

MULTIPLE MYELOMA

- **Criteria IMWG 2003**
- **Monoclonal plasmocytes >10 % biopsy proven plasmocytoma**
- **Monoclonal Ig present in blood and urine**
- **At least dysfunction of one organ**

- **C – Calcium > 2,8 mmol/l**
- **R - Renal insufficiency (creatinin >176,8 umol/l)**
- **A – Anemia**
- **B – Bone osteolysis**

Characteristics of tumor pain

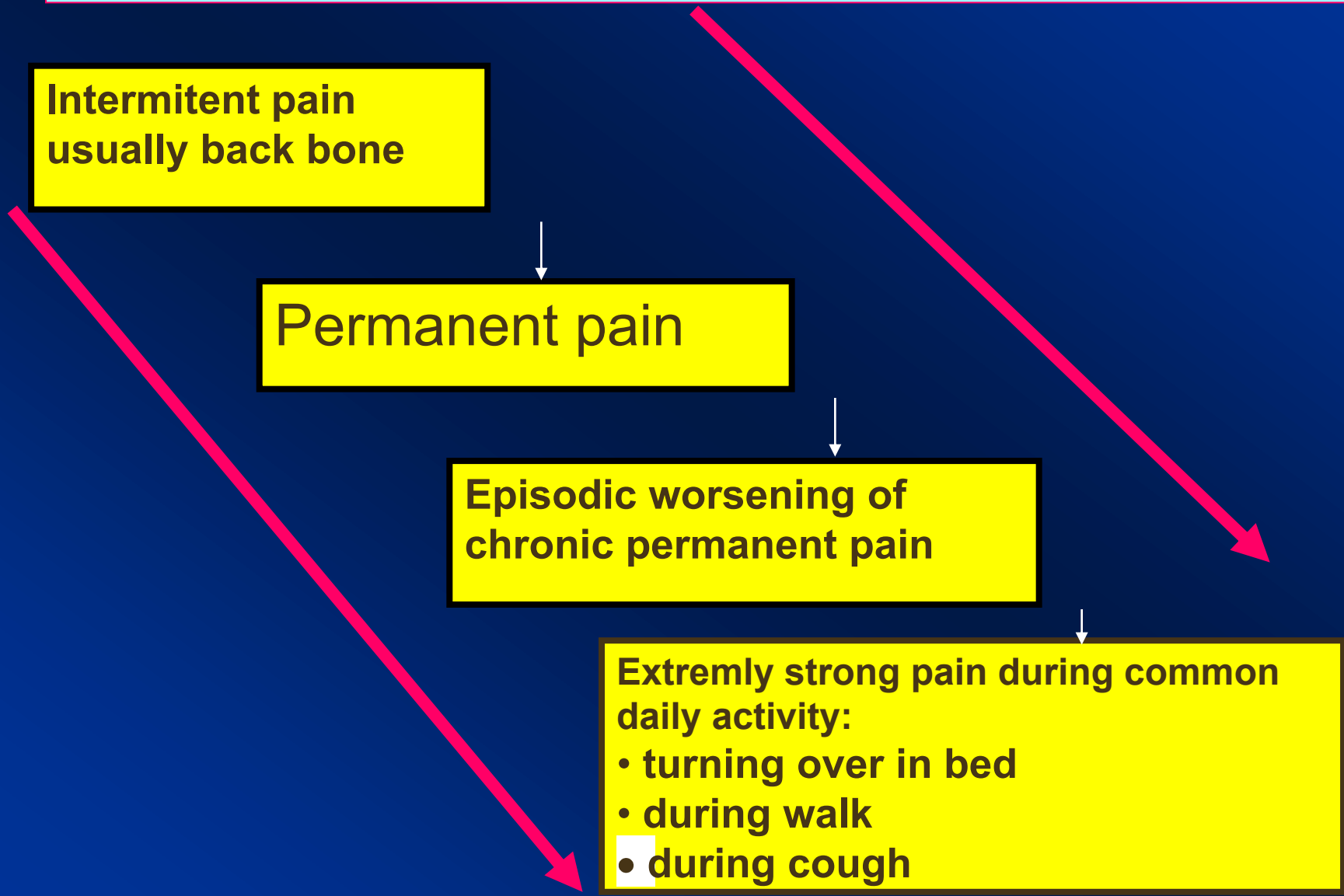
**Intermittent pain
usually back bone**

Permanent pain

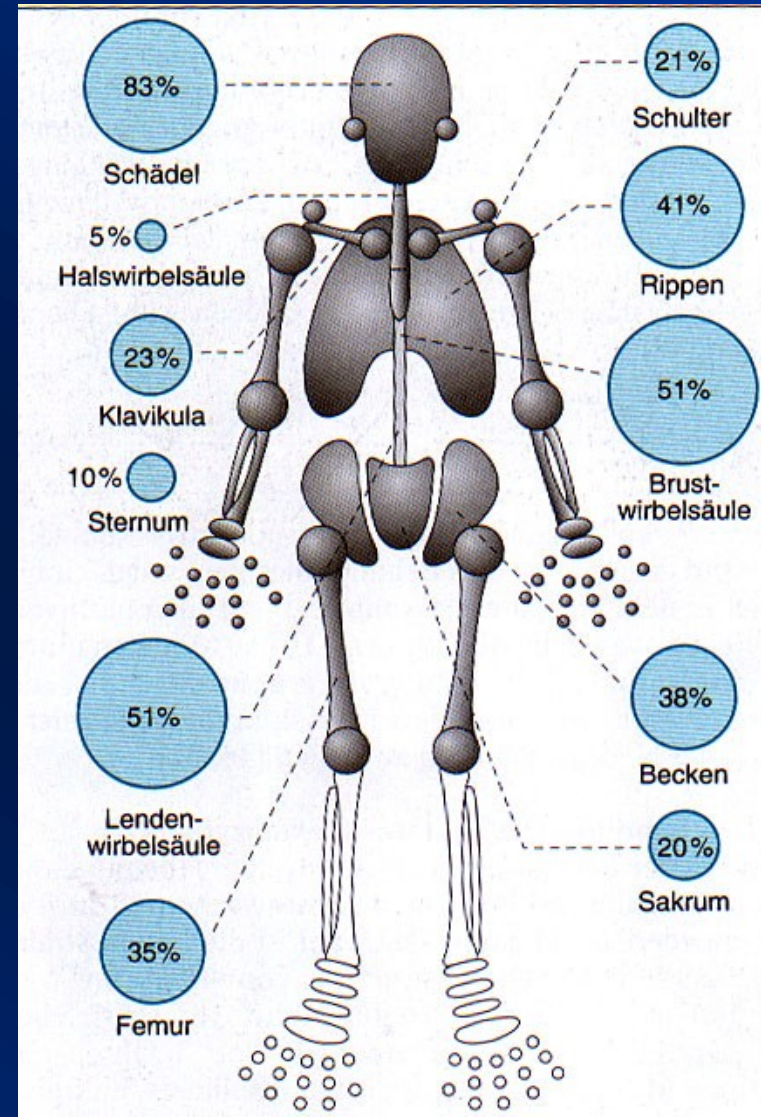
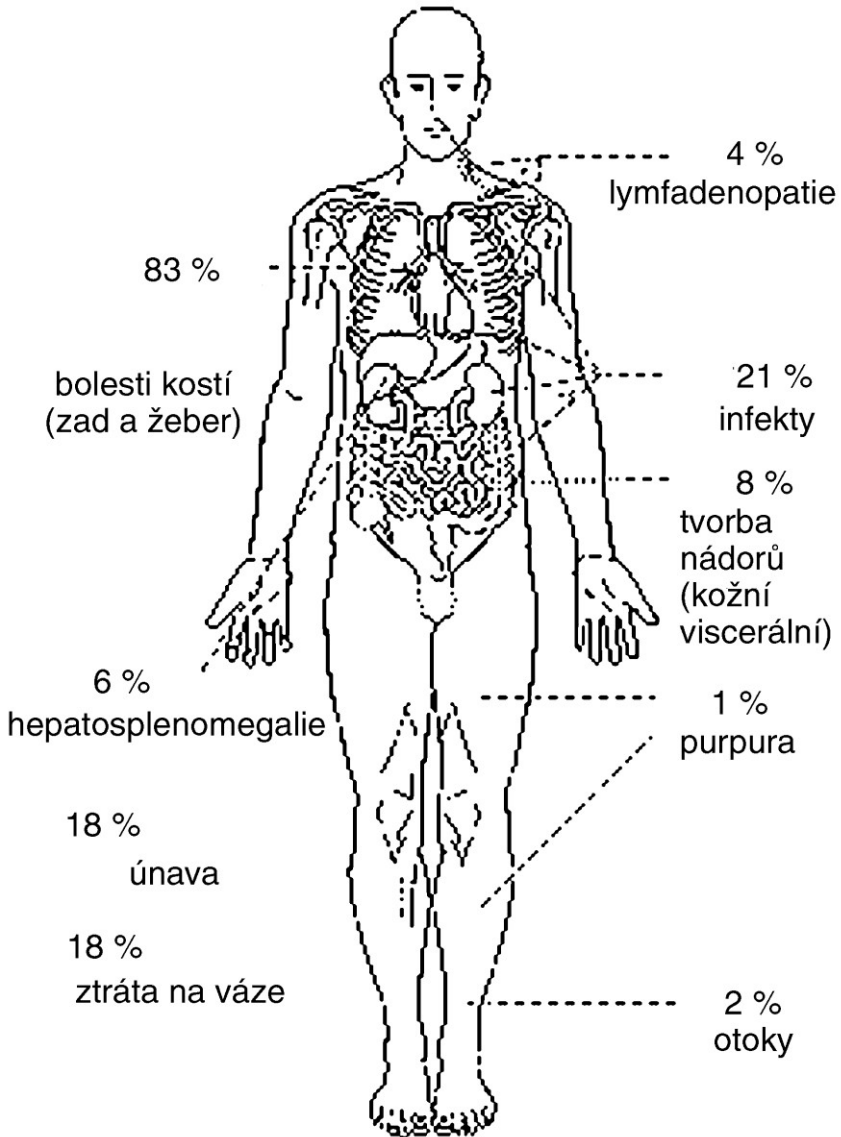
**Episodic worsening of
chronic permanent pain**

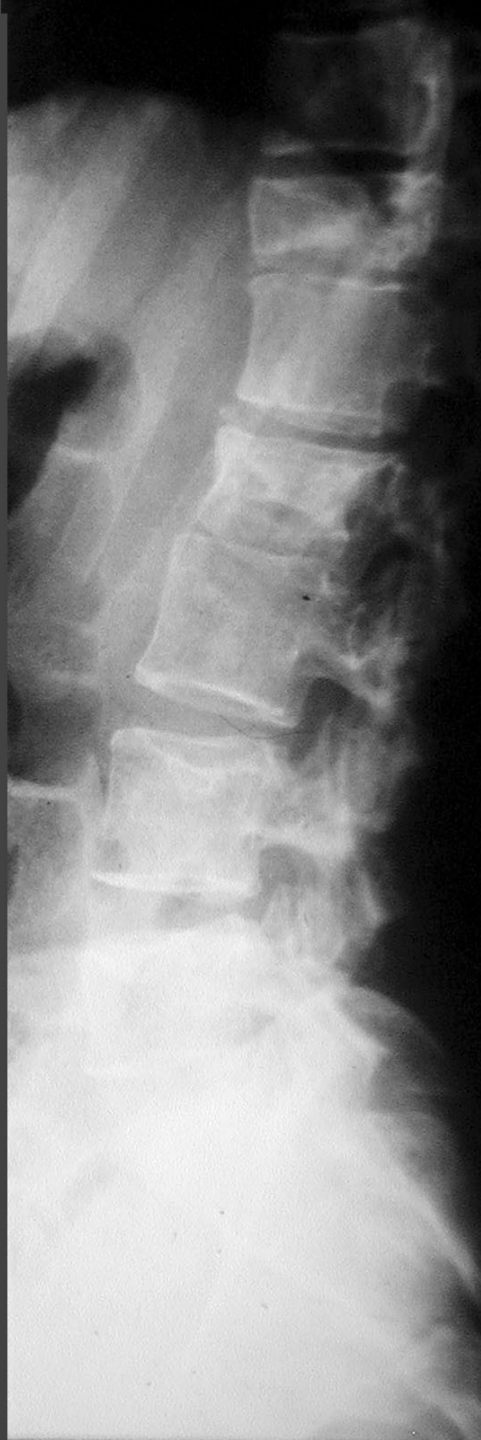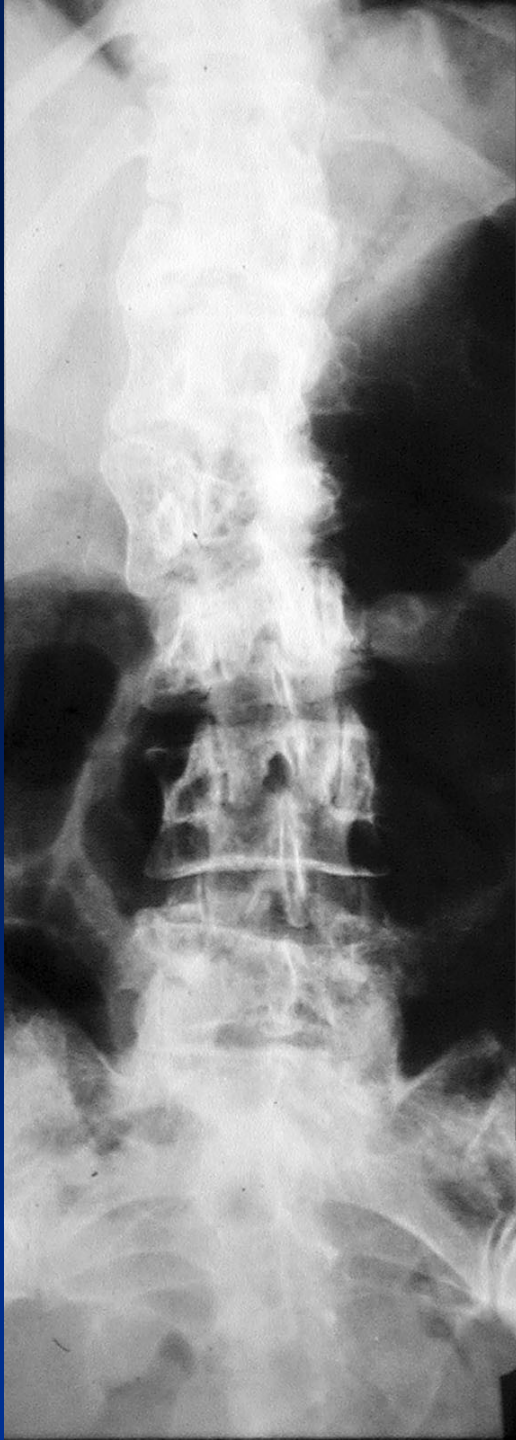
**Extremely strong pain during common
daily activity:**

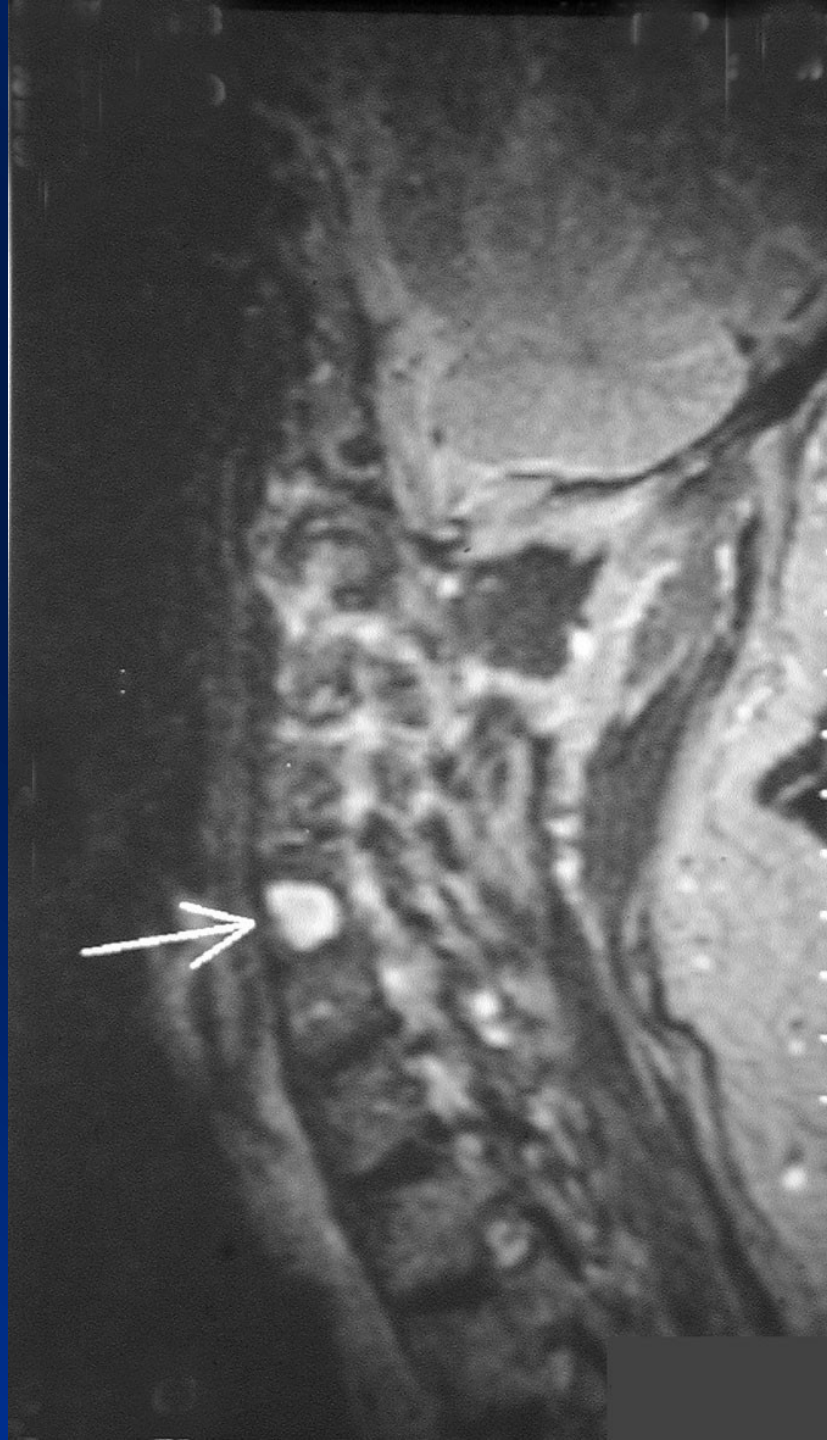- turning over in bed
- during walk
- during cough

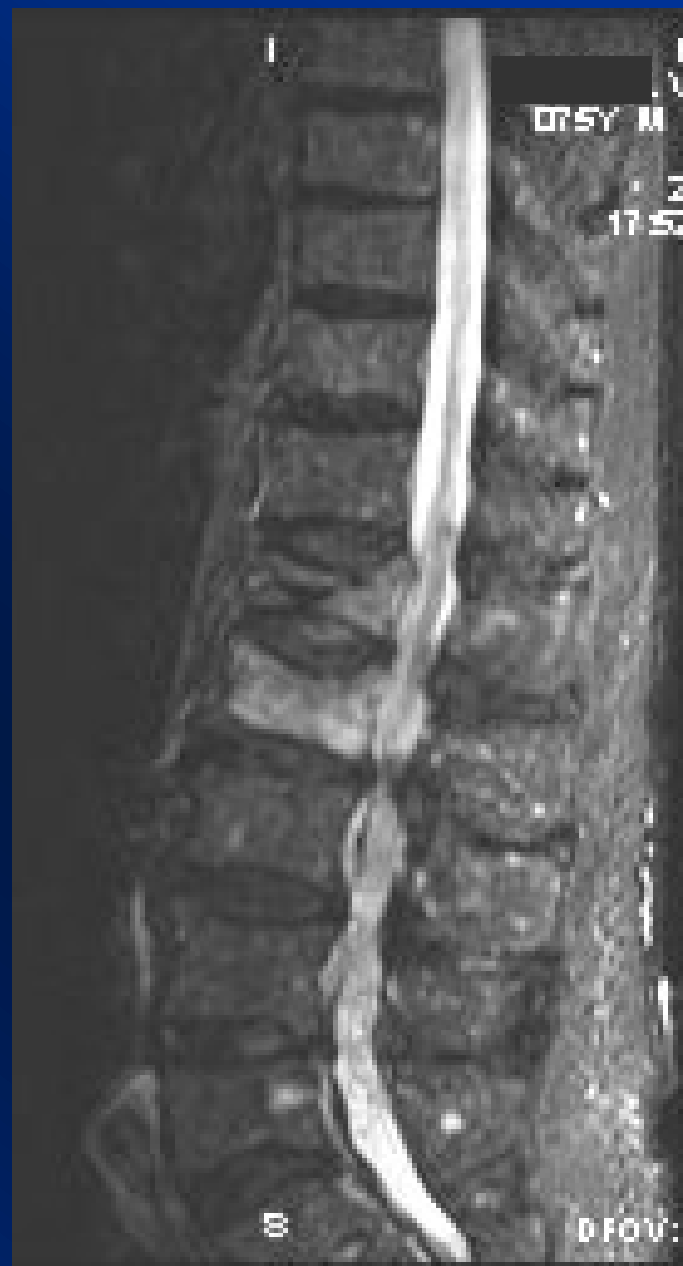
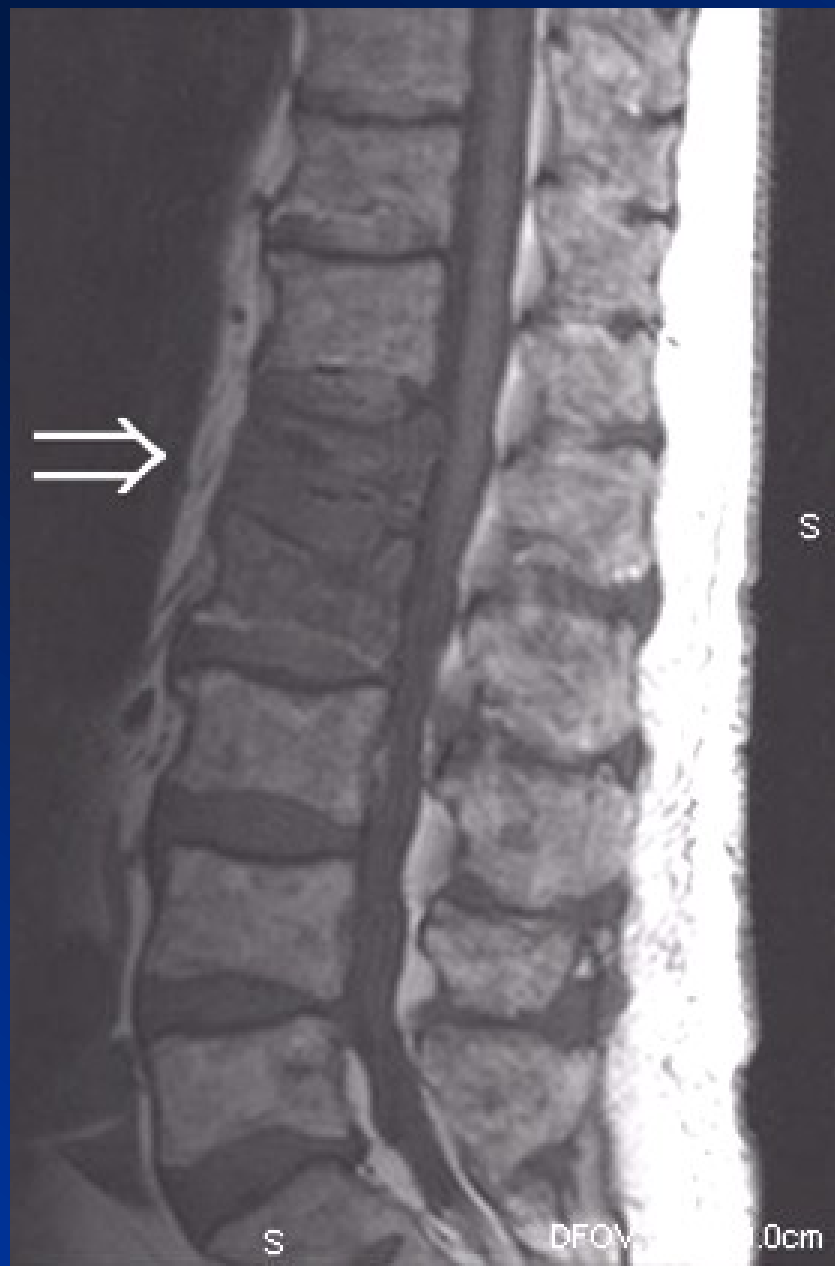
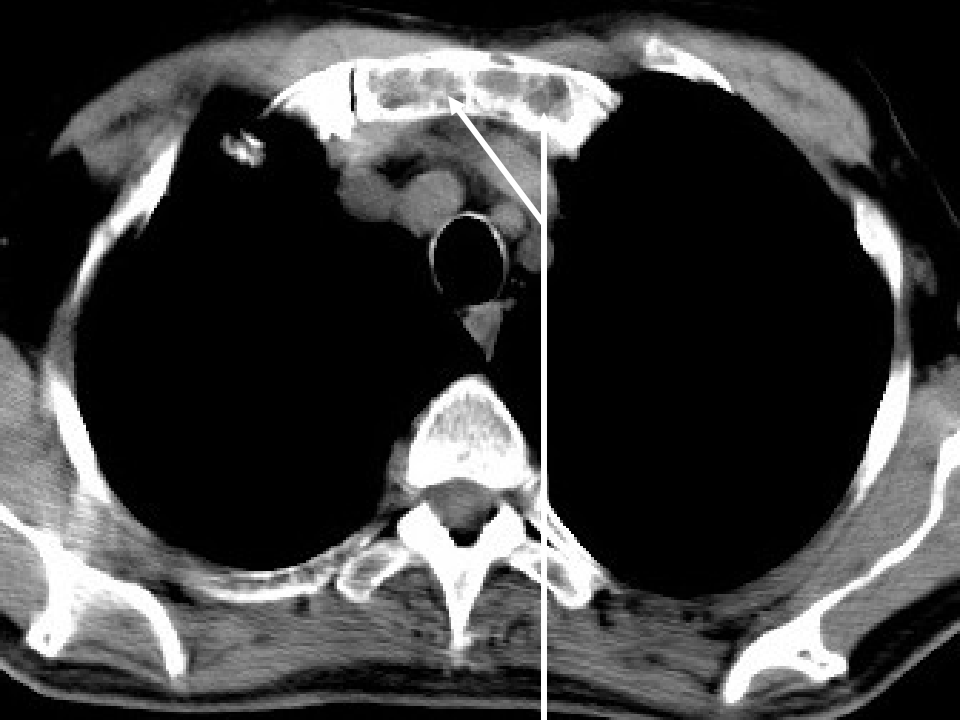Symptoms of multiple myeloma



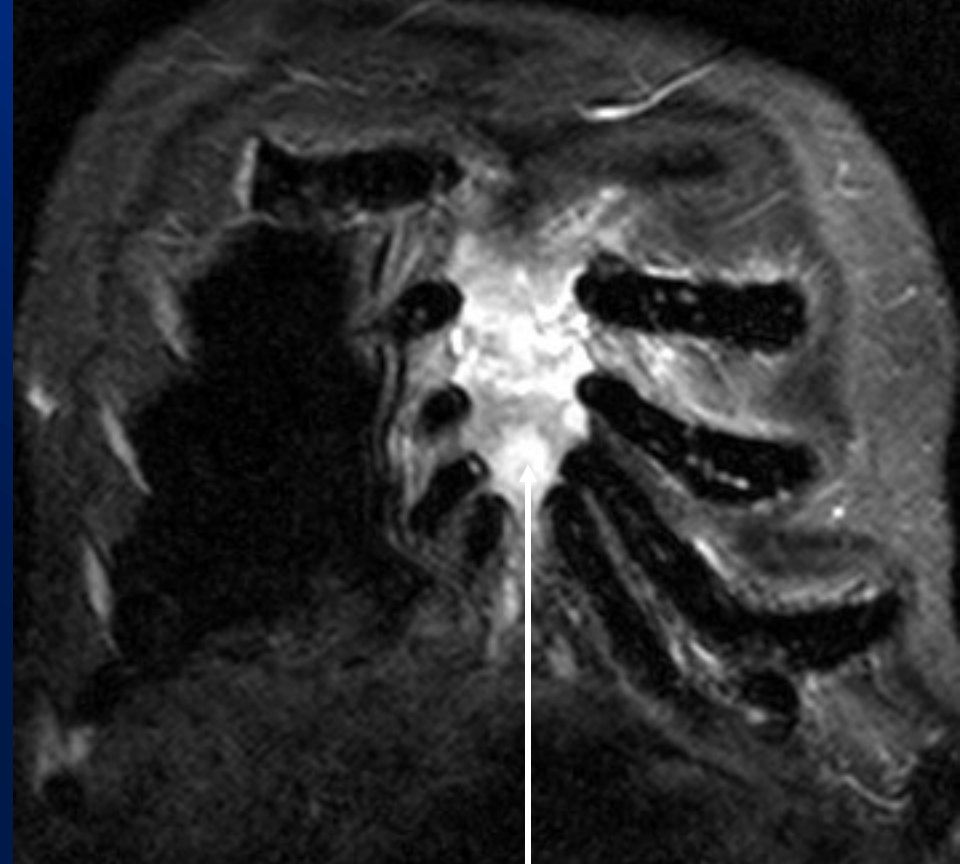








obr.3



obr.4

CT vyšetření: osteolytická ložiska
sterna s okrajovou usurací
kortikalis

MR vyšetření: patrna nádorová
aktivita a infiltrace celého sterna

Diferencial diagnostics of back bone pain

Lumbago
without any
radicular
irritation

1 month of
standard
treatment

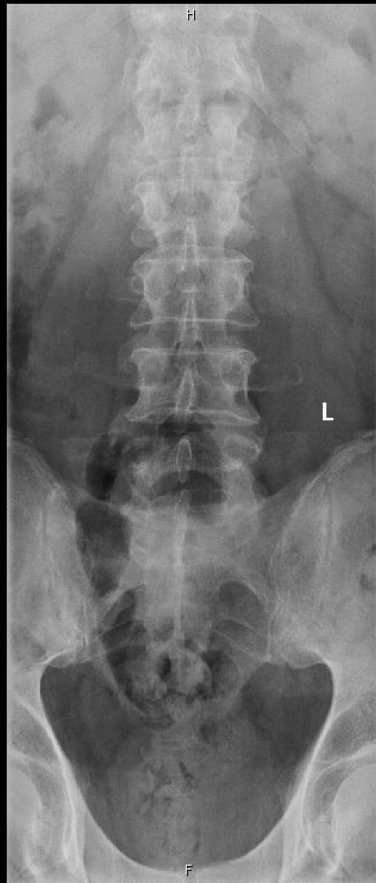Laboratory and imaging examination

- Back bone pain with radicular irritation
- Night back bone pains
- Rapidly worsening pains
- Osteoporosis and back bone pains

Patient v remission of multiple myeloma with rapidly worsening of back bone pain irradiating into both legs with muscle atrophy. What's the cause?

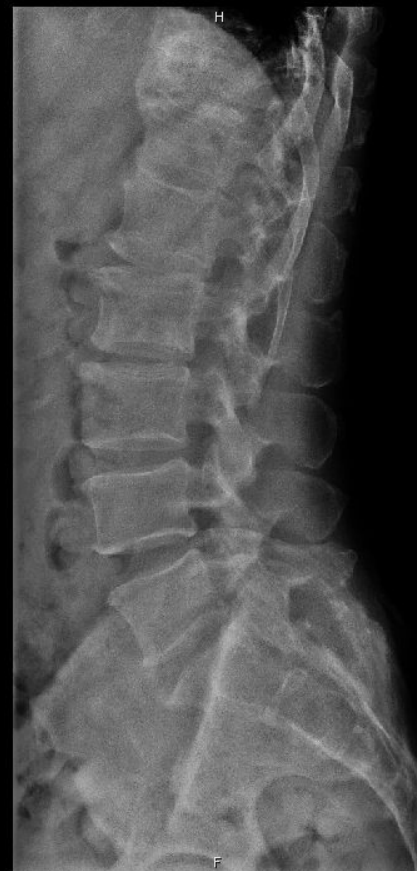X-ray of back bone with no substantial pathology explaining the troubles.

Tomastik Ivan^^
ID:470511/219
DoB:1947-05-11
2006-10-10
12:45:35
No.1



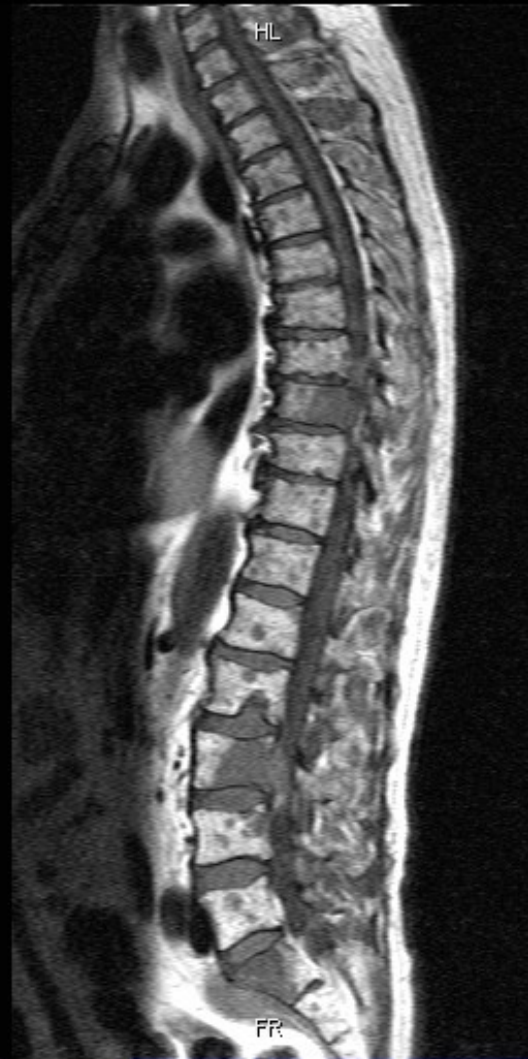Q: 95% 

Tomastik Ivan^^
ID:470511/219
DoB:1947-05-11
2006-10-10
12:51:21
No.2



Q: 95% 
FN Erno
"Thunder Platform"

MRI: Extramedullar expansion in L3 and Th8



Q: 95%



FN BRNO-Bohunice
MAGNETOM IMPACT



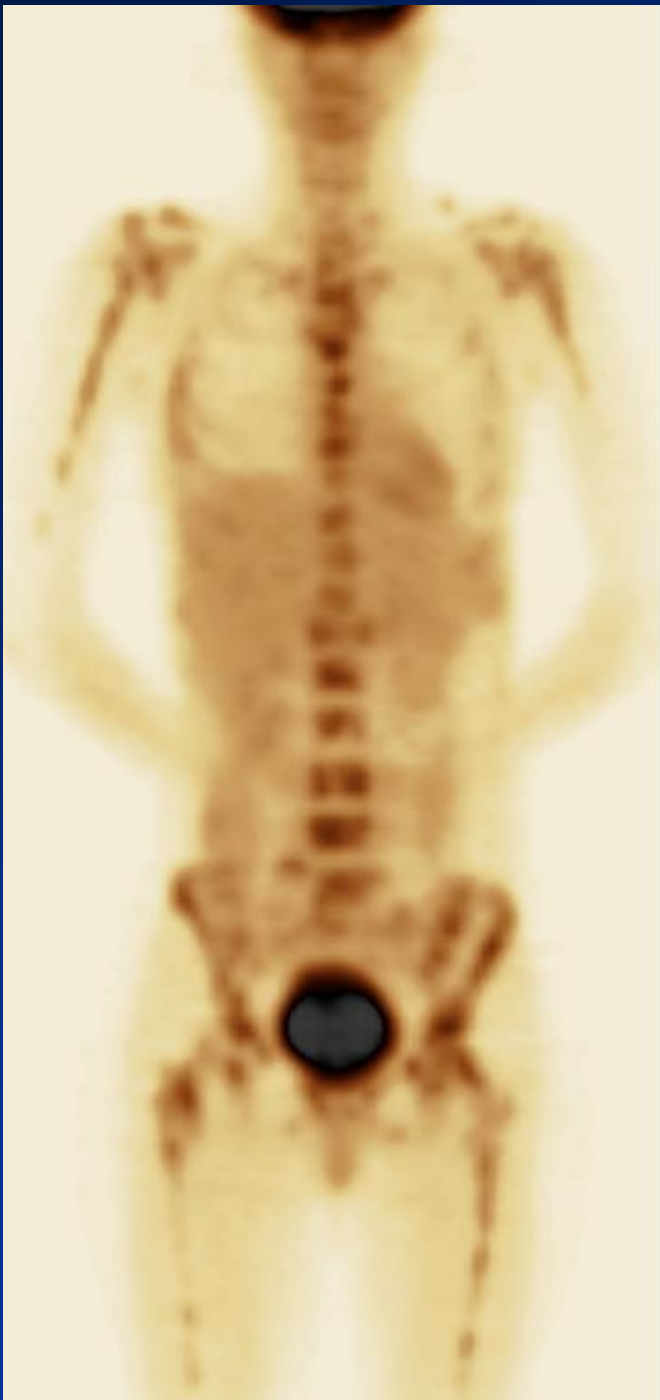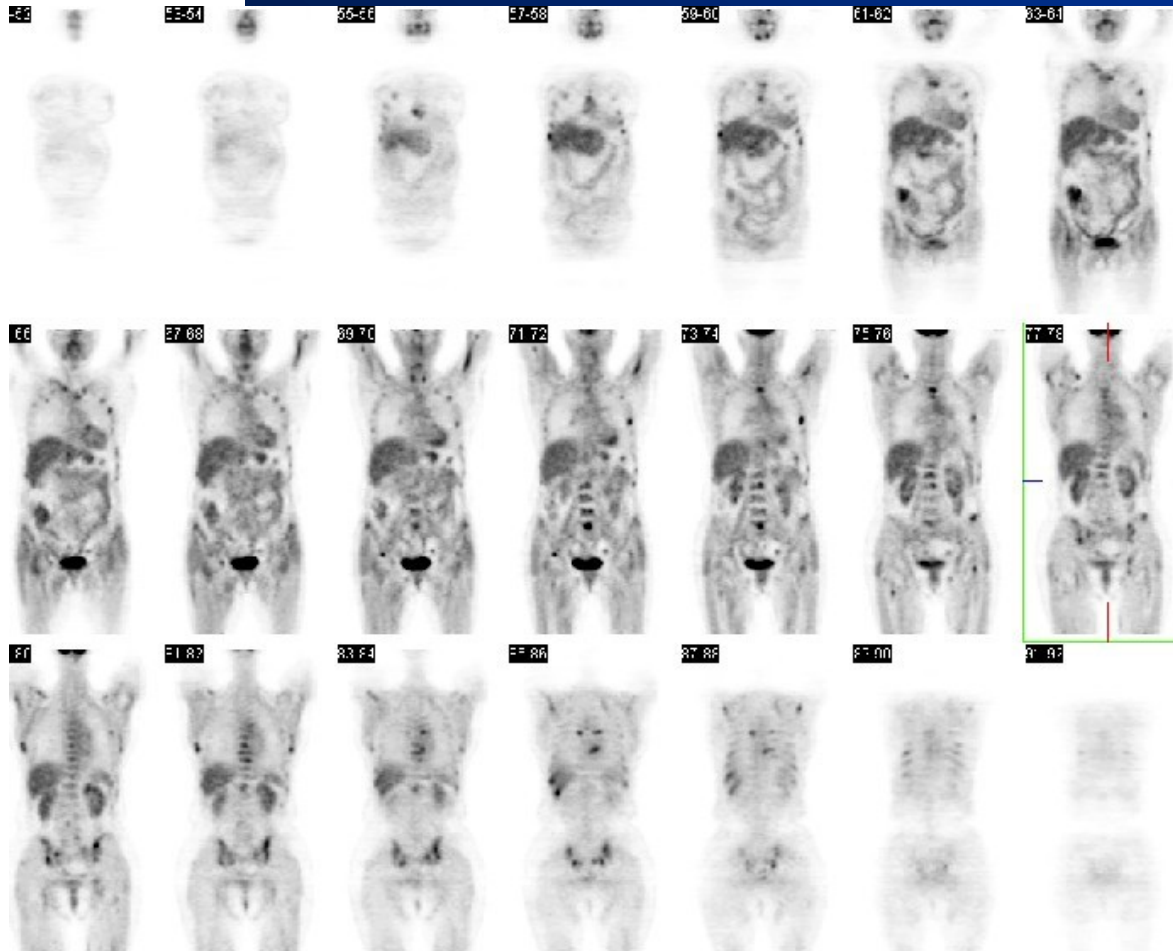
P

A

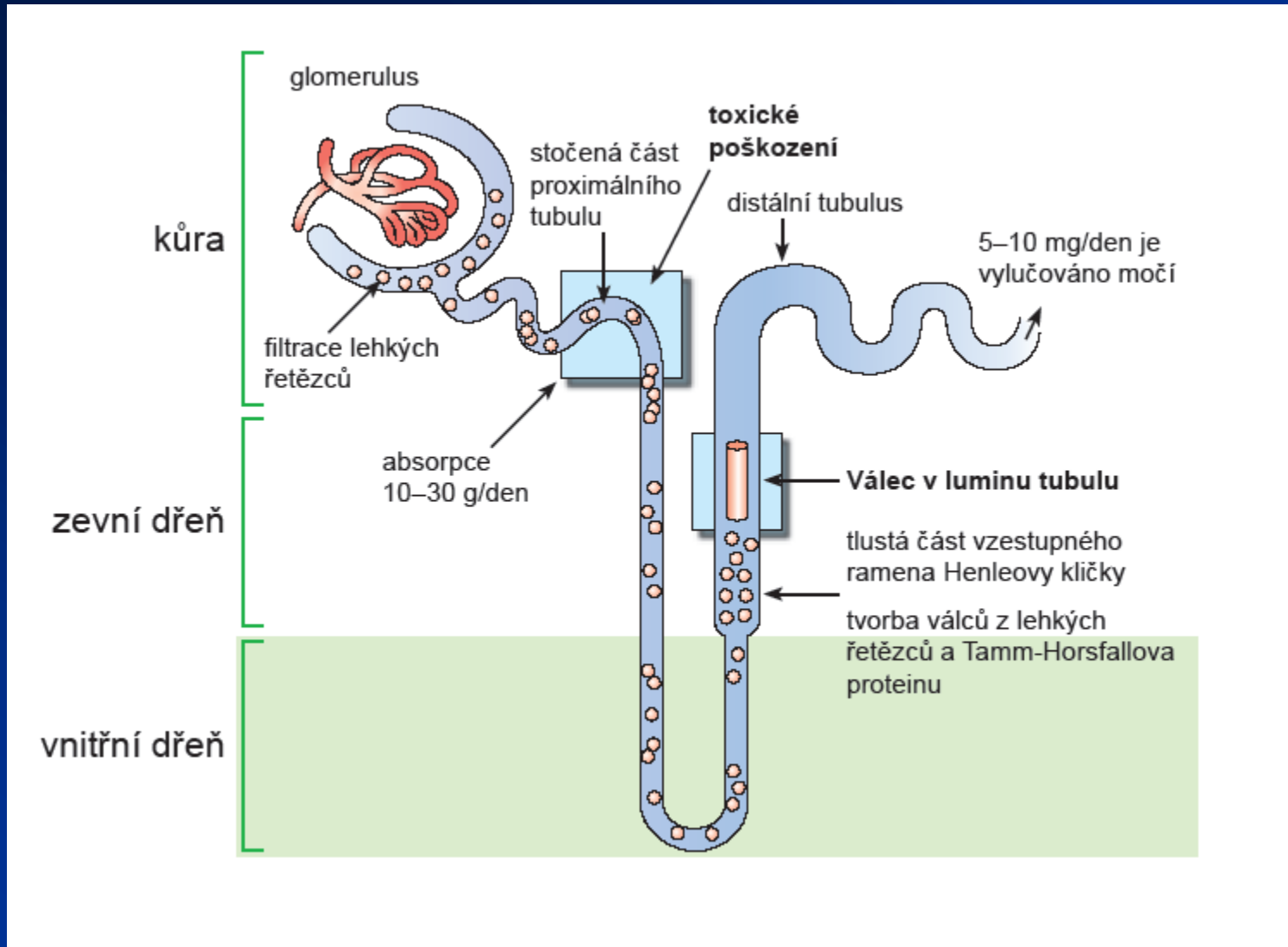
RM
TR:939
TE:12
SP:-3.14645
SL:4
CM:

C: 686
W: 1399

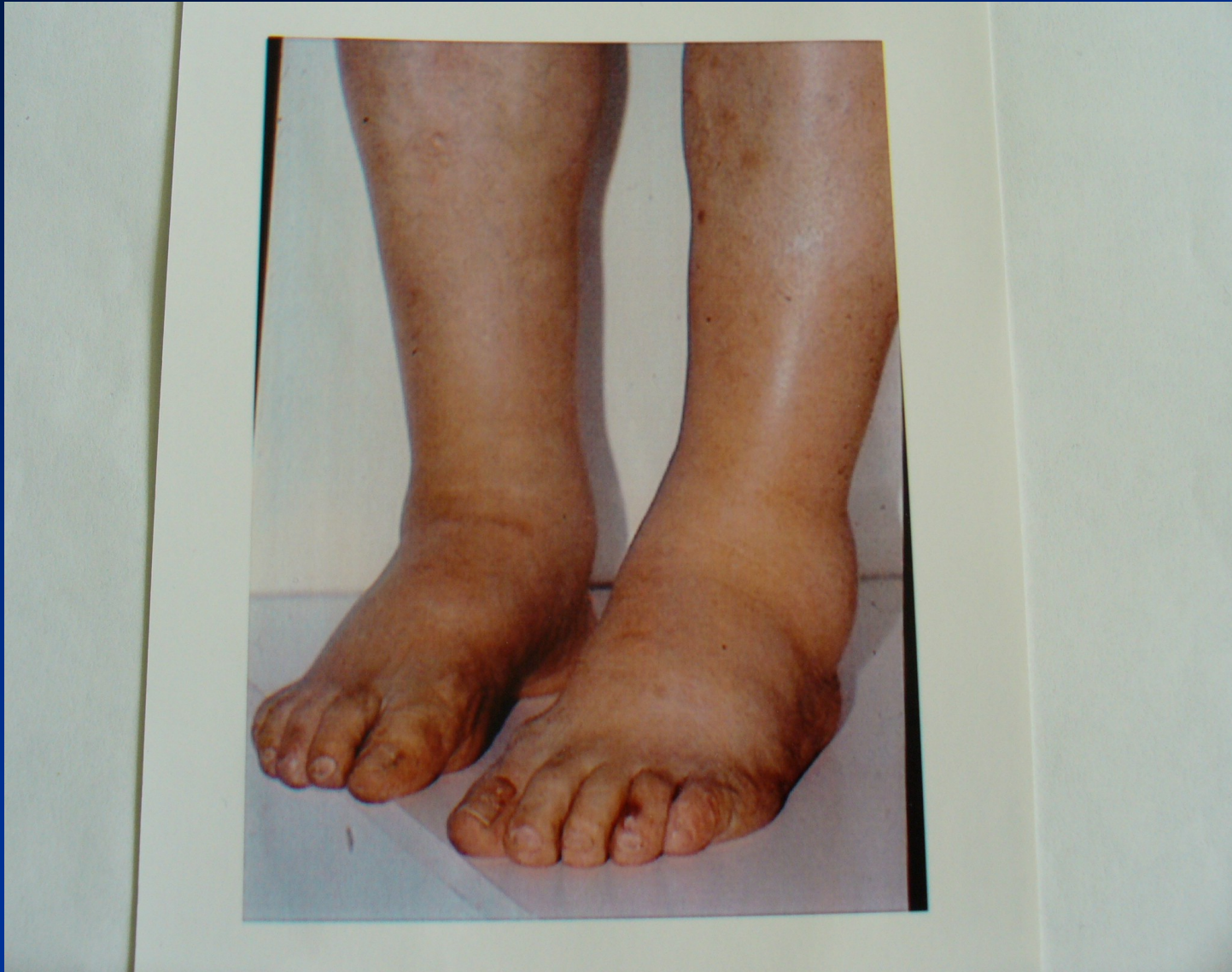FDG-PET: is able to show bone and extrabone myeloma lesions



Can monoclonal Ig cause renal failure requiring hemodialysis?



Leg oedema in nephrotic syndrome

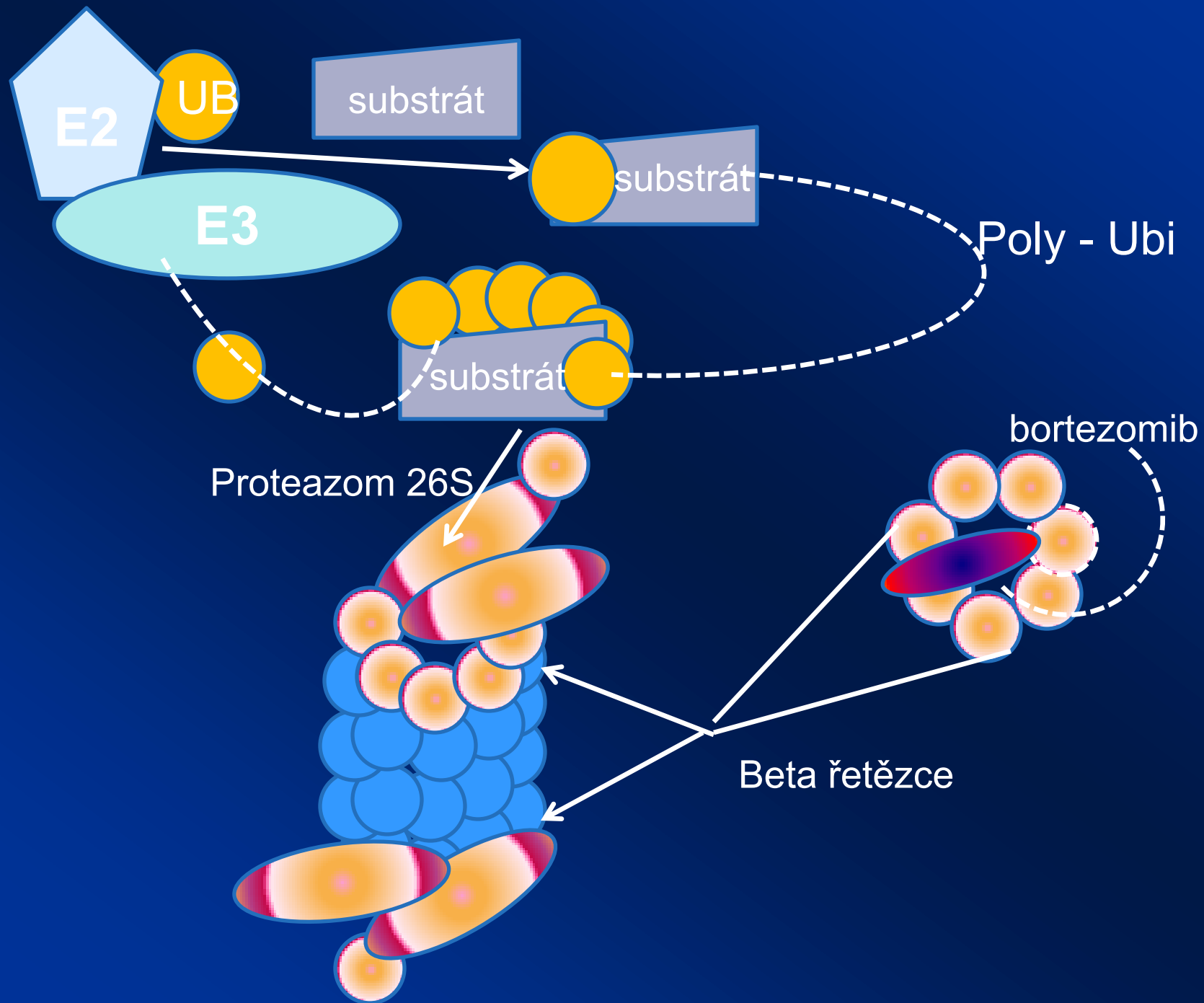


Multiple myeloma - therapy

- Conventional chemotherapy – median 3– 4ys
- High dose chemotherapy with autologous stem cell transplantation
 - prolongs median +1,5 y
 - increases proportion of patients surviving more than 5ys
 - is a standard procedure for patients in good condition younger than 65ys
- New drugs used in clinical standard care:
Thalidomid, bortezomib

Proteasome inhibition

- Stabilisation:
 - CDK inhibitors (p21, P27) \approx decreasing of proliferation
 - P53 \approx apoptosis increasing
 - Proapoptotic proteins (BAX, BID, BAK) \approx apoptosis increasing
- Increased inhibition of NF κ B
 - \approx apoptosis increasing
 - \approx proliferation decrease
 - \approx angiogenesis decrease

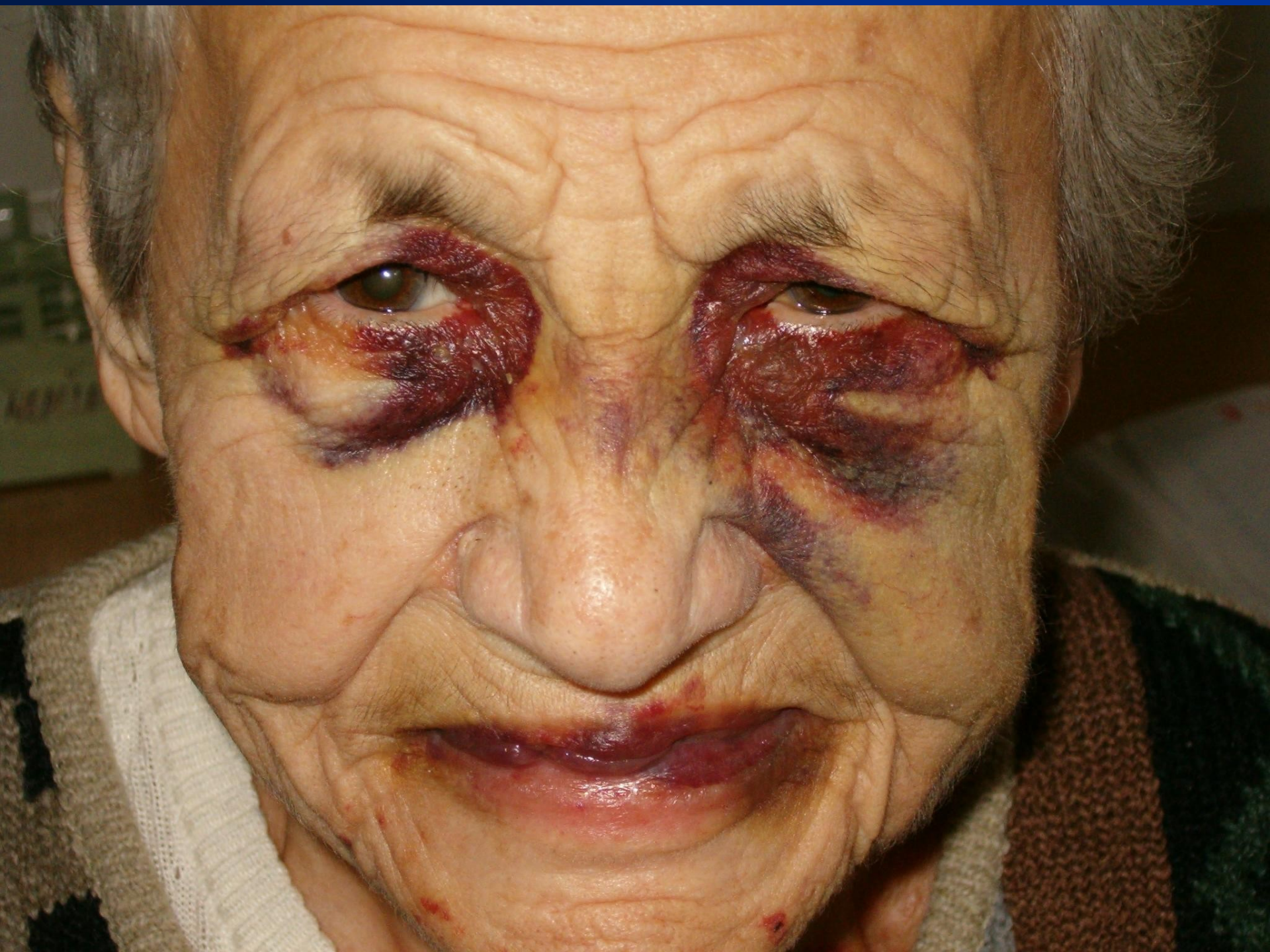


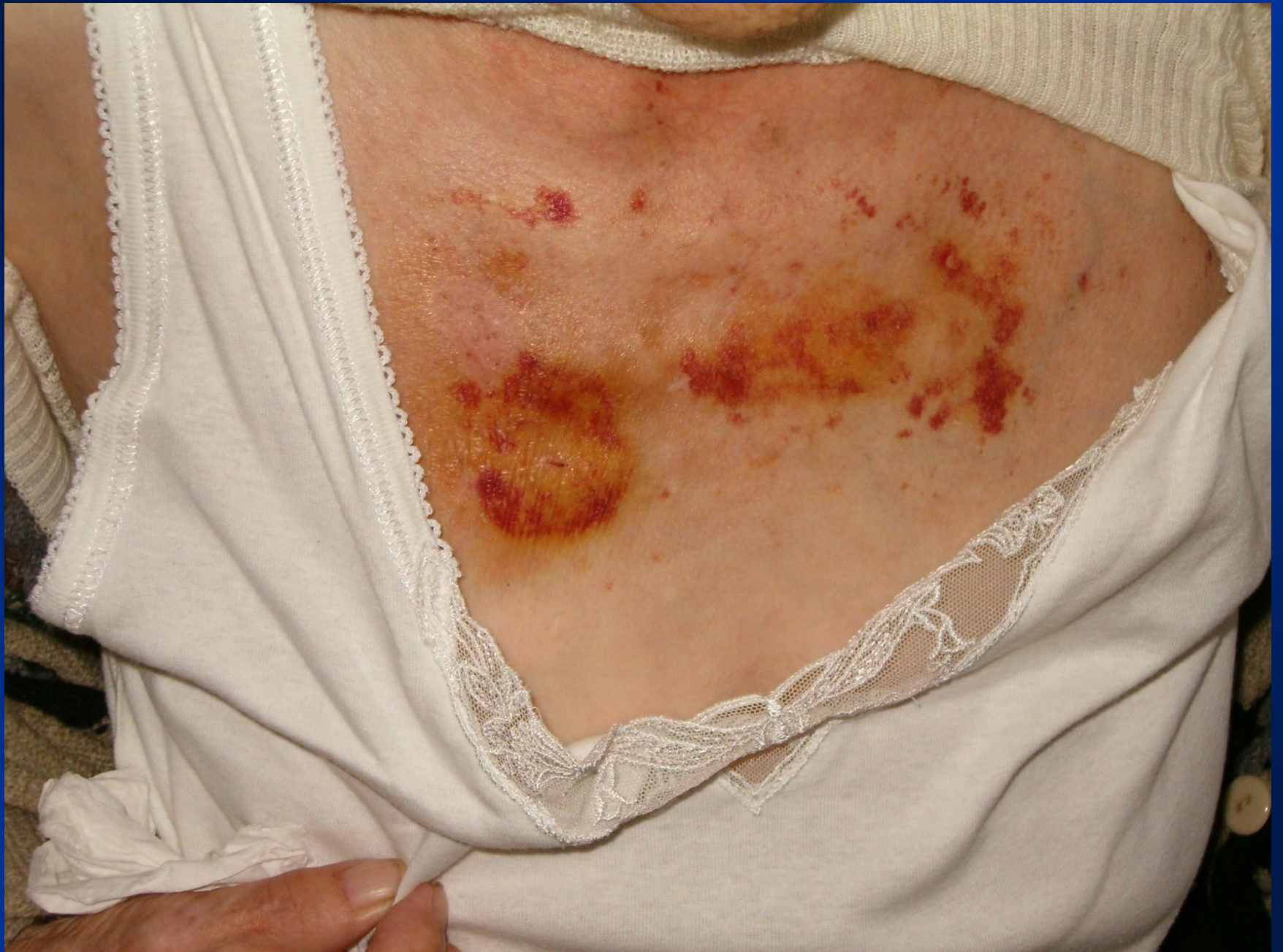Multiple myeloma – supportive care

- Bisfosfonates
- Hemodialis
- Plasmapheresis
- Antiinfective therapy, Ig substitution
- Anaemia therapy
- Radiotherapy
- Analgetic therapy

Primary AL amyloidosis

- Deposits of light chains generally or in selected organs according to „tropism“ of these proteins
- Patients are diagnosed in very advanced stage of disease (heart failure)
- Treatment can remove amyloid deposits, but time is needed (\approx 6 months at least)





Changes of tongue



